

PRACA ORYGINALNA
ORIGINAL ARTICLE

DIAGNOSTIC INFORMATION OF COMPUTED TOMOGRAPHY OF THE UPPER JAW IN PATIENTS REQUIRED IMPLANT REHABILITATION

INFORMACJE DIAGNOSTYCZNE UZYSKIWANE DZIĘKI TOMOGRAFII KOMPUTEROWEJ SZCZĘKI U CHORYCH WYMAGAJĄCYCH REHABILITACJI IMPLANTU

Pavlo I. Tkachenko, Artur I. Pankevych, Inna A. Kolisnyk, Andriy M. Gogol

UKRAINIAN MEDICAL STOMATOLOGICAL ACADEMY, POLTAVA, UKRAINE

ABSTRACT

Introduction: Dental implantation in conditions of bone deficiency in the loss of lateral group of teeth of the upper jaw is impossible without the maxillary sinus floor augmentation. Preparation for surgical intervention requires a thorough assessment of the anatomical features of the sinus, relationship between the sinus and adjacent teeth, detection of foci of chronic infection of the Schneiderian membrane. In the complex of the objective methods of investigation, computed tomography is the most informative approach to study the state of the bone and soft tissue structure of the sinus.

The aim of the paper is to evaluate the state of the bone structures and maxillary sinus membrane to determine the technique for selection the optimum alternative for management of patients, who required sinus lift, based on the computed tomography.

Materials and methods: Computed tomographic examination of 206 patients with bounded and free-end edentulous spaces in the lateral area of the upper jaw was carried out over a period of 2010-2017 to evaluate the appropriateness of sinus lift approach and selection of its technique. The state of the bone tissue and presence of the auxiliary septa, intranasal structures, including ostiomeatal complex, presence of edema and exudates, lesions of the mucosa, as well as the state of ostium maxillaris has been estimated.

Results: In the projection of the maxillary sinus the thickness of the bone tissue ranged within 1 mm to 10,5 mm; the density of bone tissues was of the D3-D4 type. Inflammatory events were detected in 60,1%, including: thickening of the mucous membrane on the right and on the left (40,6% and 41,1%, respectively), the total edema (8,6% and 9,7%, respectively). Bilateral thickening was found in 38,8%, and bilateral total edema in 28,0% of cases. Remnants of the filling material were found in 1,4% of sinuses on the right and in 2,8% on the left. Bone septum was visualized on the right in 18,8%, and in 17,4% on the left, bilateral in the 31,8%. Cystic masses were detected on the right in 4,2% of cases and in 6,2% on the left, bilateral in 16,7%.

Conclusions: Computed tomographic examination provides thorough evaluation of the parameters of the bone tissues, state of mucous membrane and peculiarities of architectonics of maxillary sinuses at the pre-implantation stage.

KEY WORDS: dentistry, maxillary sinus, implantology, otorhinolaryngology, sinus lift, computed tomography

Wiad Lek 2018, 71, 9, 1645-1652

INTRODUCTION

Insufficient volume of the bone tissue in the loss of lateral group of teeth of the upper jaw complicates the task for an oral surgeon in the planning of implantological rehabilitation of such patients. Wide range of causes of deficiency includes bone resorption after surgical tooth extraction or odontogenic pathology, anatomic features of maxillary sinus (e.g. hyperpneumatic type of its structure), alteration of mucous membrane in its inflammation. In some cases the problem is solved by the insert of short implants without disintegration of the sinus floor. However, it is often followed by a combination of the above conditions with frequent occurrence of cases when only thin (less than 1 mm in height) cortical bone is preserved between the oral cavity and sinus cavity. In such patients dental implantation is impossible without additional surgical training [1, 2].

Currently, regardless the risks, maxillary sinus floor augmentation is considered one of the most predictable techniques, enabling to gain the bone tissue of proper quality and in sufficient volume. Consequently, the area becomes suitable for installation and subsequent functioning of dental implants.

Preparation for surgical intervention requires careful planning. During the examination, a dentist must pay attention to the anatomical features of the sinus, relationship between the sinus and adjacent teeth, detection of foci of chronic infection of the Schneiderian membrane. In the complex of the objective methods of investigation, computed tomography (CT) is the technique that most informatively reflects the bone and soft tissue structure of the sinus. In the complex of objective methods of research

computed tomography (CT) is a technique that most informatively reflects the bone and tissue structure of the sinus. It is undoubtedly considered a kind of golden standard of the sinus study [3, 4, 5].

CT visualizes the existing changes in the mucous membrane, caused by various pathological processes: inflammation, allergy, trauma, or tumor. CT scans can clearly determine the presence of bone septum, which significantly increases the risk of intraoperative perforation of the mucous membrane. Computed tomography contributes to assessment of the quality of root canal sealing, which could cause sinusitis, and determine the state of the ostiomeatal complex. The assessment of the latter is advocated in the planning of surgical intervention, since the reduced diameter of the foramen, caused by edema, leads to insufficient aeration of the sinus, hence, increasing the risk of the development of inflammatory complications [6].

The resulting data enable prediction of the threat to a planned surgical intervention, minimizing the possible postoperative problems. Undoubtedly, chronic inflammation or swelling statistically increases the risk of sinusitis exacerbation following argumentation. This can lead to the loss of the graft or implant, prolonging the period of patient's treatment or even to refusal from the planned procedures [5].

THE AIM

The paper is aimed at evaluation of the state of the bone structures and maxillary sinus membrane to determine the technique for selection the optimum alternative for management of patients, who required sinus lift, based on the computed tomography.

MATERIALS AND METHODS

206 patients with bounded and free-end edentulous spaces in the lateral area of the upper jaw were examined in the clinic of the Department of Pediatric Oral Surgery with Propedeutics of Oral Surgery and Department of Otorhinolaryngology with Ophthalmology over a period of 2010-2017. Replacement of lost teeth (1 to 4) with dental implants in combination with maxillary sinus floor elevation was planned for all patients. Computed tomography of the upper jaws was made to evaluate the quality of bone tissue, the architectonics of the maxillary sinus, the state of the mucous membrane, the necessity and selection of sinus lift technique. The study was carried out using spiral computer tomograph "Siemens Somatom Emotion" (Siemens Healthcare GmbH) with the following specifications: power (kV): 80-130; tube current capacity (mA): 20-140; time of reconstruction (s) < 20, thickness of the cut (mm): 0.63; time of scanning (s): 10-15.

The images were analyzed using the SimPlant Pro 11.04 software. The parameters were estimated in the three planes (axial, coronal, and sagittal) with 0.63 mm step [3]. The study group involved patients with CT scans of the whole maxillary sinus, intranasal structures, including

the ostiomeatal complex. While examining the CT-images, special attention was given to thickening, mucosal masses, the presence of exudate in the sinus, and the state of the ostium maxillaris. The presence of auxiliary septa was established by axial sections. On the coronal projections, the thickening of the sinus floor mucosa and the state of the natural foramen was determined. The thickness of the visible mucosa was measured perpendicularly to the adjacent bone, and the data was recorded. Schneiderian membrane thickness up to 2 mm (i.e., if no lesions occur) was almost nonvisualized. Thickening over 2 mm was considered as pathological edema of the sinus mucosa. The ostiomeatal complex was characterized as "open" in the absence of the apparent swelling, and "closed" if the mucosa blocked the foramen [8].

The optical endoscopy of the nasal cavity was carried out in patients with complaints of nasal respiration disturbances and sinusitis in the past history, if necessary.

RESULTS AND DISCUSSION

We have examined 206 patients with extracted (or affected by chronic periodontitis) maxillary molars and premolars, not subjected to conservative treatment. Implant installation in the maxillary sinus projection was possible in all patients. The spectrum of adentia ranged from partial to complete edentulism of the upper jaw that affected the oral rehabilitation planning and in some cases allowed to avoid sinus interventions. Patients (male n=101; female n=105) aged 21 to 69 years were involved into study.

Edentulism of the upper jaw was as follows: 13 patients with edentulous upper jaws; 39 patients with unilateral free-end edentulous spaces; 31 patients with bilateral free-end edentulous spaces; 56 patients with bounded unilateral edentulous spaces (2 and more teeth); 37 patients with bounded bilateral edentulous spaces; 30 patients with single edentulism in the lateral area. Generally, surgical interventions were planned in the projection of 287 sinuses (Table I).

We estimated the CT data in two major aspects: first studied the state of the bone tissue to find out its residual volume and density and then the features of anatomical structure of the sinus and its mucous membrane. This approach facilitates obtaining the predicted outcomes of the surgical intervention.

The resulting measurements contribute to presenting quantitative and qualitative characteristics of the bone tissue. Linear measurement demonstrated the average bone width of $6,38 \pm 0,41$ mm. The average height of the alveolar ridge beneath the maxillary sinus was $5,98 \pm 0,95$ mm (Table II). Noteworthy, the height ranged 1 mm to 10.5 mm that was caused by the long-standing and traumatic tooth extraction, the level of bone destruction due to odontogenic infection, volume of edentulism, as well as anatomical features of sinus structure, etc. The absolute values are usually a decisive criterion for the choice of mode of surgical intervention. In the planning of treatment we were guided by the conventional protocols for the conduct

Table I. The structure of the edentulism of the upper jaw

| Type of edentulism | Number of patients | % | Number of sinuses |
|---------------------------------------|--------------------|-------|-------------------|
| Edentulous upper jaws | 13 | 6,3 | 26 |
| Unilateral free-end | 39 | 18,9 | 39 |
| Bilateral free-end | 31 | 15,0 | 61 |
| Bounded unilateral (2 and more teeth) | 56 | 27,2 | 56 |
| Bounded bilateral (2 and more) | 37 | 18,0 | 74 |
| Single | 30 | 14,6 | 30 |
| Total | 206 | 100,0 | 287 |

Table II. Bone height and type of planned surgical intervention in patients

| | Planned type of sinus lift 3,83±0,43 | Average height of the bone (mm) | |
|------------------------------|---|---------------------------------|------------|
| | | 7,02±0,58 | |
| Open (lateral) | with simultaneous implant installation | 31 (64,6%) | - |
| | with delayed implant installation | 17 (35,4%) | - |
| Closed (osteotome technique) | with osteoplastic material | - | 82 (51,9%) |
| | without osteoplastic material | - | 76 (48,1%) |

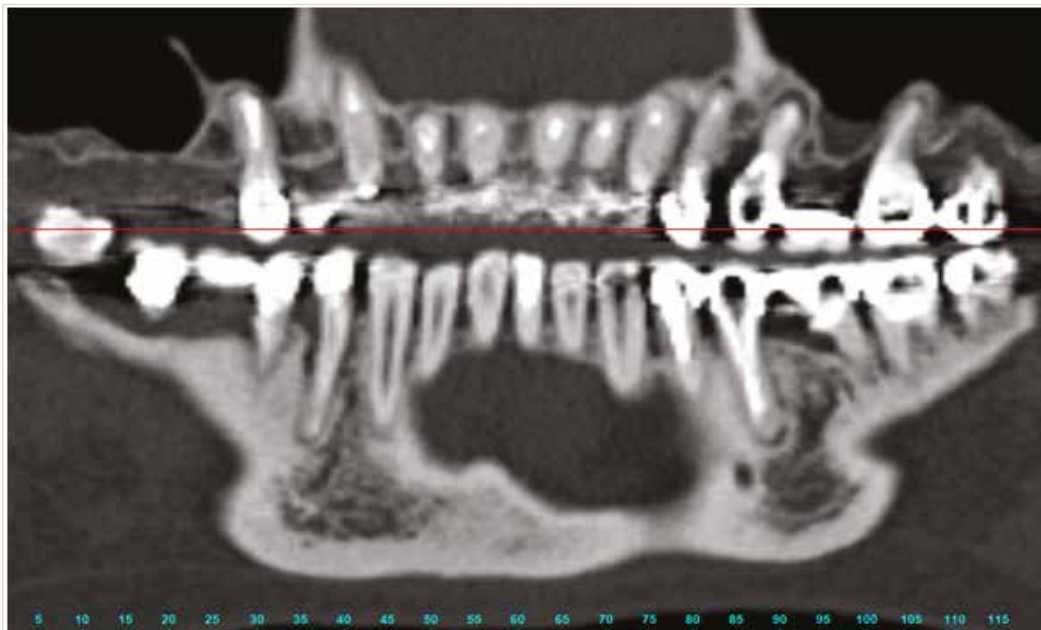

Fig. 1. Fragment of computed tomography of the upper jaw of the 52-year-old female patient G., case record No.214. Diagnosis: edentulism of the upper jaw, Kennedy ClassII-2. In the area of the lost tooth #16 in the projection of the alveolar ridge only cortical plate is presented. In projection of the lost tooth #26, manifestations of intoxication of the mucosa from tooth #25.

of sinus lift [9]. For patients with bone height of 6 mm and more (average $7,02 \pm 0,58$ mm), we planned a method of closed maxillary sinus floor elevation. The total number of such patients was 158 (76.7%), and in 76 (48.1%) of cases there was no need to use osteoplastic material (8 mm and more), whereas its use was planned in 82 (51.9%) of cases (from 6 to 8 mm).

In 48 (23.3%) patients the residual bone height was less than 6 mm (the average $3,83 \pm 0,43$ mm) and, following the recommendations, they were suggested the open (lateral)

maxillary sinus floor elevation. Among them 31 (64.6%) patients showed favorable conditions for simultaneous installment of dental implants (3 mm height and more) and in 17 (35.4%) patients the delayed installation of dental implants (height less than 3 mm) was planned.

Bone density in patients varied and was of D3-D4 type, which is specific for lateral area of the upper jaw. Only in cases of significant atrophy the bone type was nearly D1 due to the almost total loss of cancellous tissue between the cortical plates (Figure 1).

Table III. Anatomic-radiological description of the sinus mucosa in examined patients

| Features | Right sinus | Left sinus | Patients with bilateral lesion |
|---|-------------|------------|--------------------------------|
| Thickening of mucous membrane (from 2 mm) | 71 (40,6%) | 72 (41,1%) | 40 (38,8%) |
| Total edema | 15 (8,6%) | 17 (9,7%) | 7 (28,0%) |

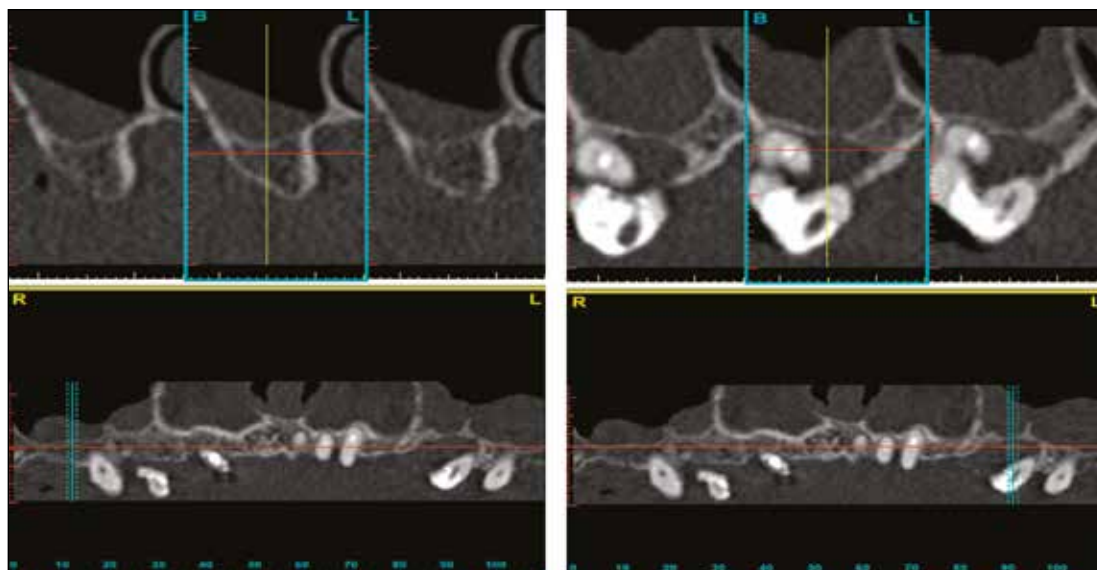


Fig. 2. Fragment of computed tomography of the upper jaw of the 61-year-old female patient A., case record No.63. Diagnosis: edentulism of the upper jaw, Kennedy Class III-2, chronic periodontitis of teeth #16, 26, 27. Bilateral thickening of mucous membrane and cystic mass on the left.

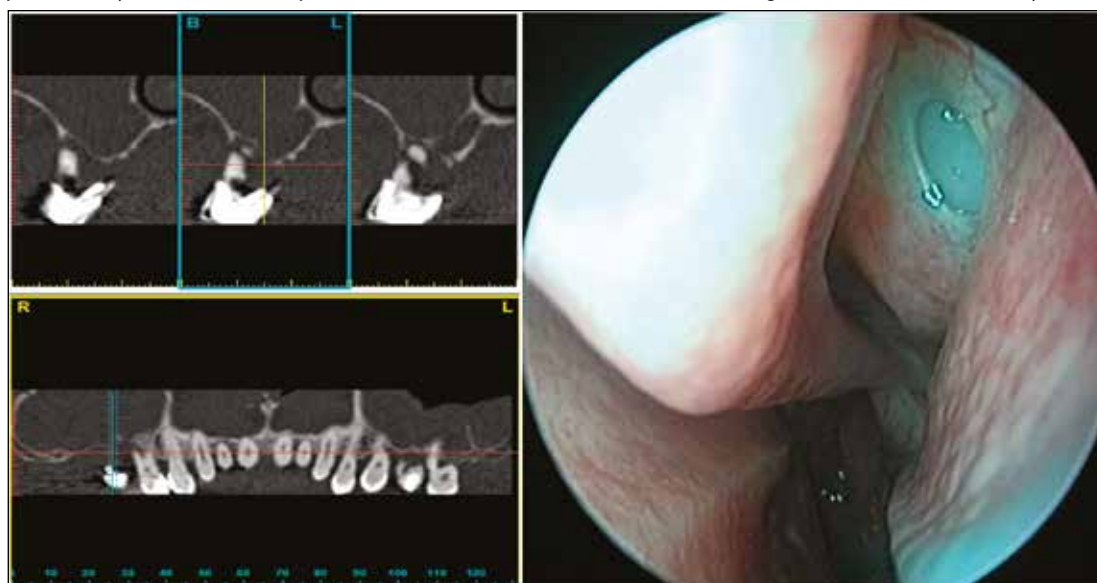


Fig. 3. Fragment of computed tomography of the upper jaw of the 59-year-old male patient G., case record No.89. Bilateral total thickening of mucous membrane, obstruction of the ostiomeatal complex. On the right: demonstration of the blocked insolation of the maxillary sinus.

Measurements of altered thickness of Schneiderian membrane demonstrated 2.5 mm to 14.2 mm (average 4.95 ± 0.34 mm). Thickening of the mucosa was detected in 71 sinuses on the right (40,6%) and in 72 sinuses on the left (41,1%) and in 40 patients these alterations were noted in both sinuses (Fig.2). In 16 (22,5%) sinuses partial blockade of the maxillary foramen was detected on the right, in 14 sinuses it was on the left and in 9 patients it was bilateral.

Total thickening that led to obstruction of the ostiomeatal complex was revealed in 15 (8,6%) sinuses on the right, in 17(9,7%) sinuses on the left, and bilateral in 7 patients (Fig.3).

Data on the altered sinus mucosa are presented in Table III. Filling material that penetrated into the sinus in endodontic treatment was detected in 4 (1,4%) patients on the right and in 8 (2,8%) patients on the left (Fig. 4). Bone septum is presented in 54 (18,8%) sinuses on the

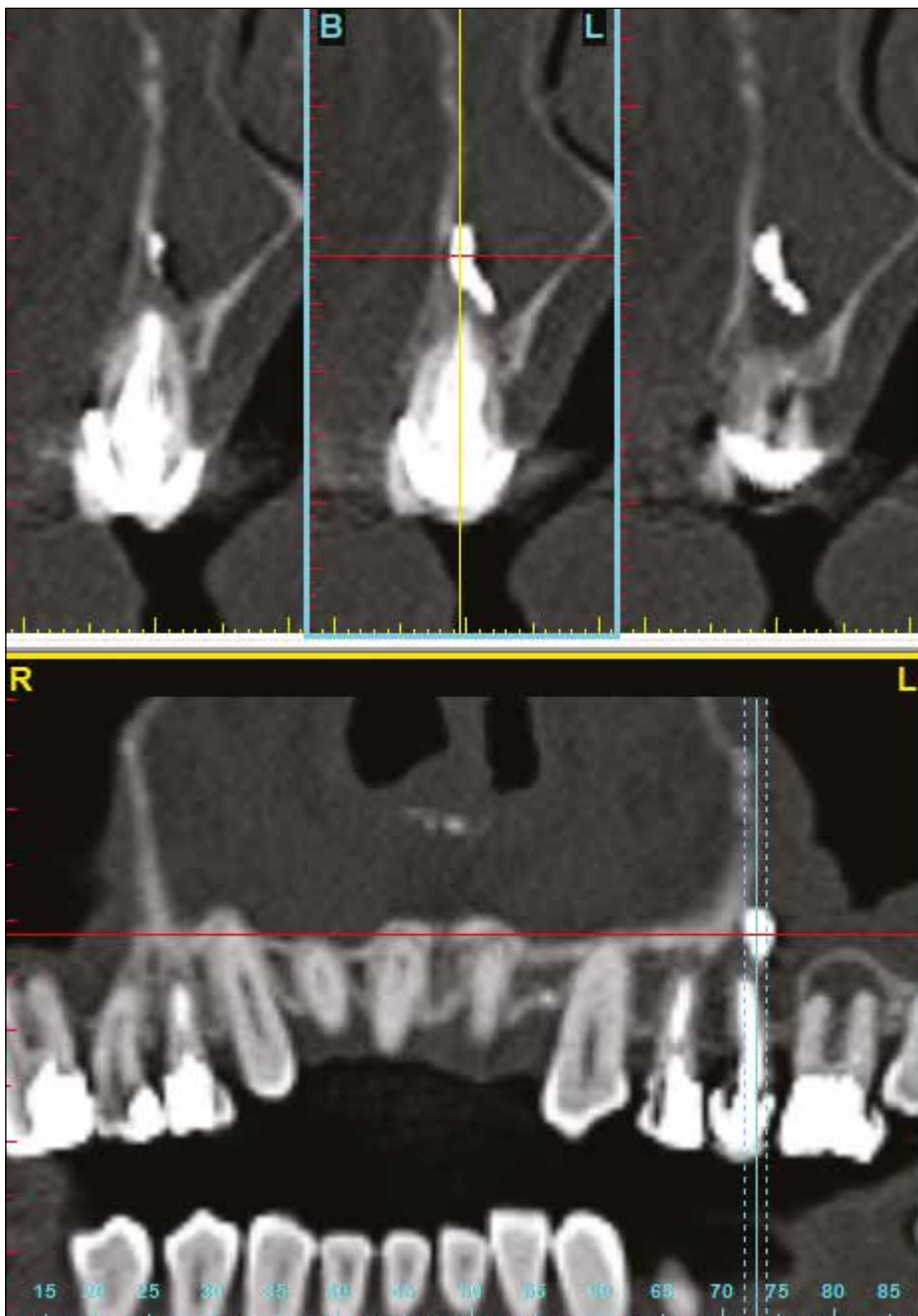


Fig. 4. Fragment of computed tomography of the upper jaw of the 52-year-old female patient L., case record No.203. Filling material in the left maxillary sinus.

right, in 50 (17,4%) sinuses on the left and bilateral in 28 patients (Fig. 5).

Cystic masses were diagnosed in 5 patients in the both sides and in 12 (4,2%) sinuses on the right and in 18 (6,2%) sinuses on the left (Fig. 6). The described changes were not dependent on the age and gender of the patients. Data analysis of the anatomical peculiarities and changes of non-inflammatory genesis is presented in Table IV.

Generally, inflammation -related alterations of mucosa were revealed in 175 (60,1%) sinuses of 287 ones, subjected to planned dental implantation. They were mainly unilateral and located in the projection of the foci of odontogenic

infection; importantly, they were preserved for a long time even after extraction of the “causative tooth” (Fig.7). At the same time, changes related to periapical infection were not established in certain category of patients. All patients, regardless of the cause of the alterations, visited otorhinolaryngologist for medical advice. Subsequently, the decision on activities conducted in the area of surgical rehabilitation was made.

Findings of the study showed that maxillary sinus floor elevation, that was planned in 287 sinuses, was performed only in 144 cases (39,7%) in 72 patients (34,9%). Generally, following the examination, surgical intervention was not performed:

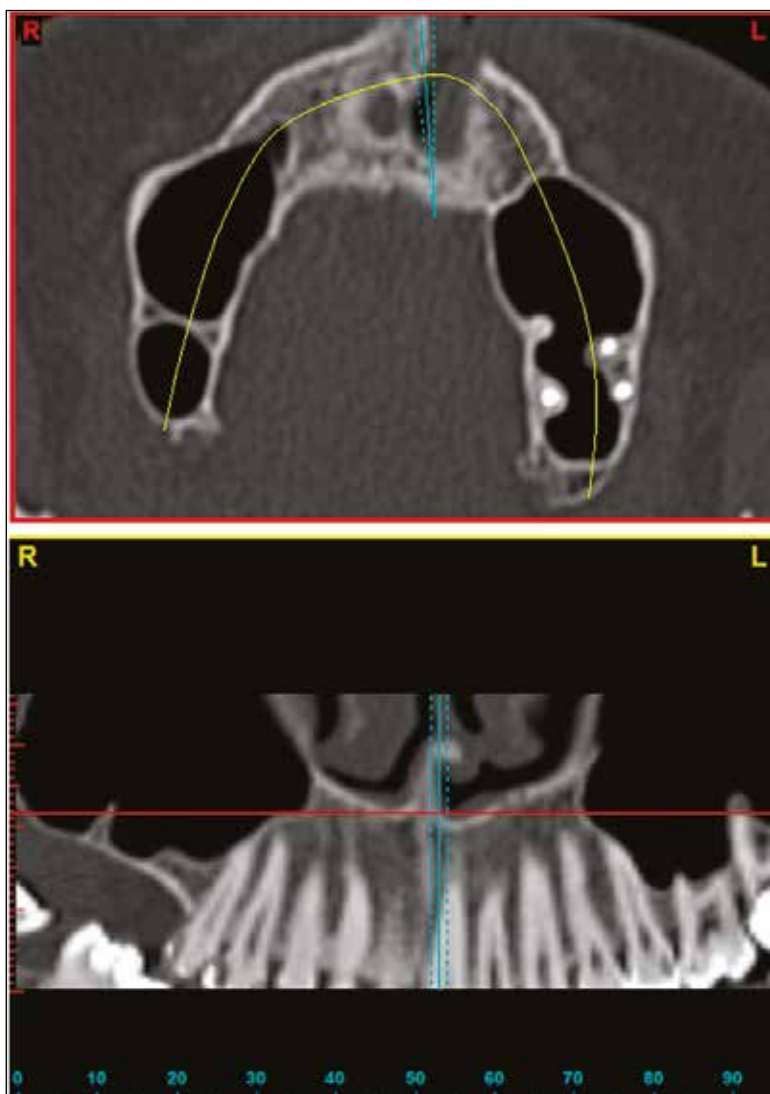


Fig. 5. Fragment of computed tomography of the upper jaw of the 49-year-old male patient G., case record No.105. Bone septum is presented in the right maxillary sinus.

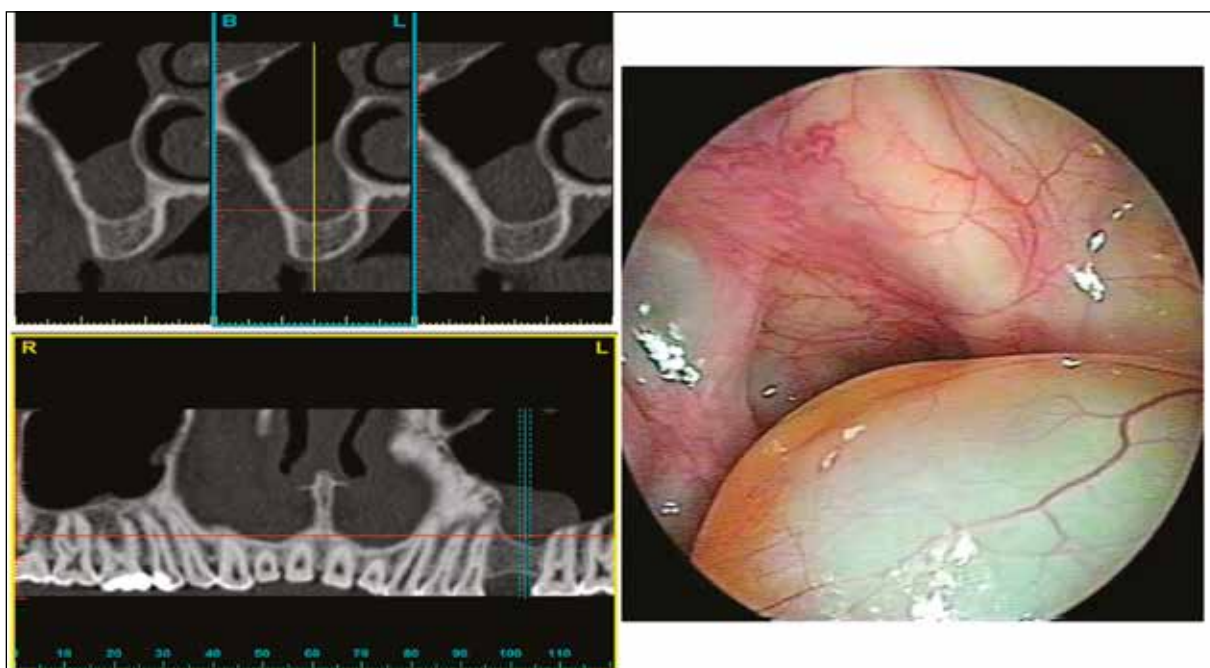


Fig. 6. Fragment of computed tomography of the upper jaw of the 31-year-old male patient P., case record No.133. Diagnosis: edentulism of the upper jaw, Kennedy Class III. Endonasal visualization of cyst in the left maxillary sinus.

Table IV. Anomato-radiological description of the bone structures and sinus mucosa alterations of non-inflammatory genesis

| Revealed features | Right sinus | Left sinus | Both sinuses |
|---------------------|-------------|------------|--------------|
| Filling material | 4 (1,4%) | 8 (2,8%) | – |
| Presence of cristae | 54 (18,8%) | 50 (17,4%) | 28 (31,8%) |
| Cyst | 12 (4,2%) | 18 (6,2%) | 5 (16,7%) |

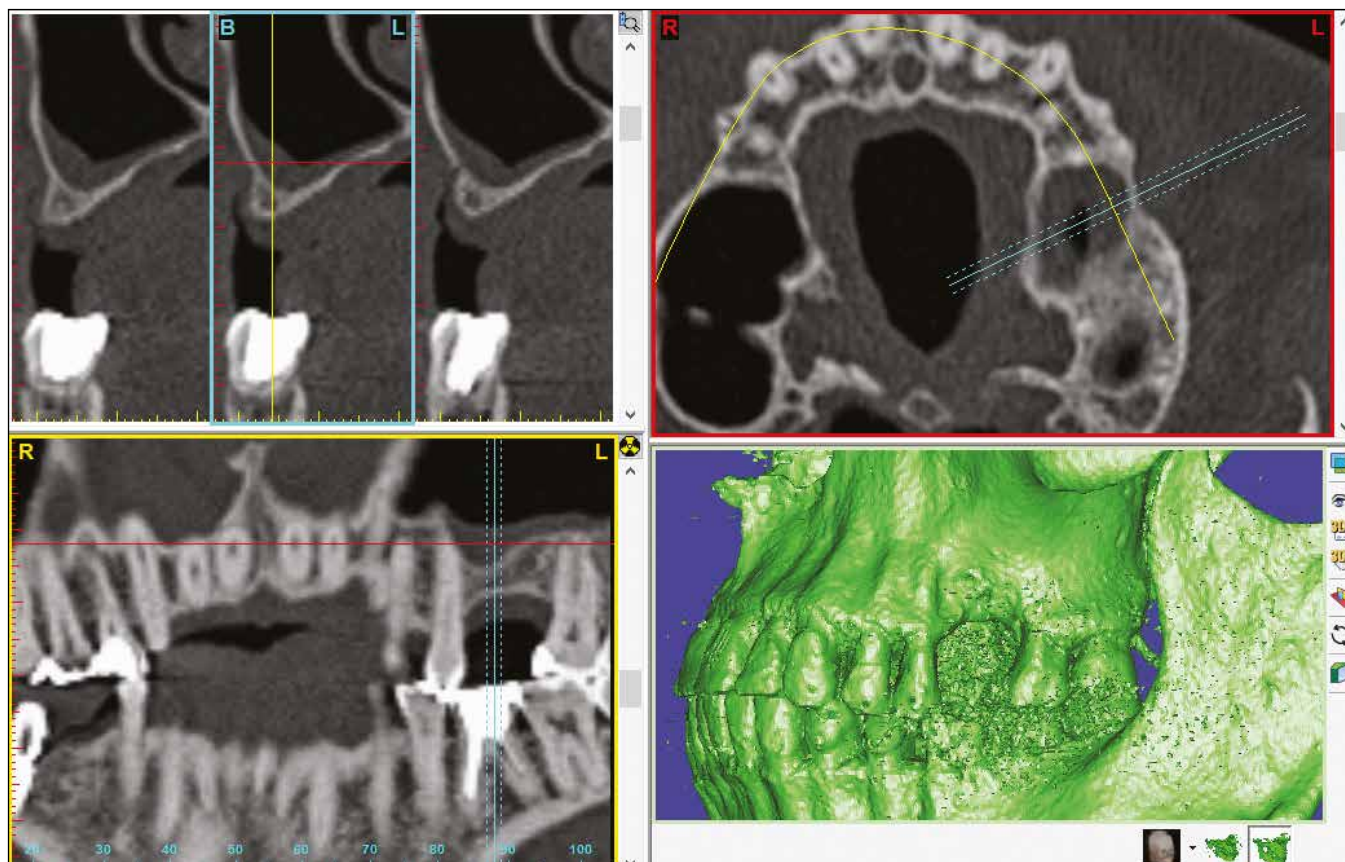


Fig. 7. Fragment of computed tomography of the upper jaw of the 44-year-old male patient T., case record No.471. Diagnosis: edentulism of the upper jaw, Kennedy Class III. Thickening of the mucous membrane of the left maxillary sinus in the projection of extracted tooth #16 associated with chronic granulating periodontitis.

- in 10 patients (4,9%) with edentulous upper jaws (in some cases the decision was made to install implants behind the projection of maxillary sinus and use of implant-supported removable dentures), total of 20 sinuses (7,0%);
- in total alterations of mucous membrane (due to impossibility of manipulations performance) in 18 patients (8,7%), constituting 32 sinuses (11,2%);
- due to refusal of 106 patients (51,5%) from the suggested approach and rehabilitation with fixed bridge or removable dentures. In this case surgical interventions were not made in 121 sinuses (42,2%).

CONCLUSIONS

Finding of our investigation showed that the height of the bone of patients who required installment of dental implants in the projection of the maxillary sinus ranged

from 1 mm to 10,5 mm, caused by anatomical features of the sinus structure. Bone density in patients was of the D3-D4 type that is specific to the lateral surface of the upper jaw.

Inflammation-related alterations were revealed in 60,1% of maxillary sinuses, subjected to installment of dental implants, namely: thickening of mucous membrane in the right sinus was accounted for 40,6% and 41,1% in the left sinus, and its total edema was revealed in 8,6% and 9,7%, respectively. Bilateral thickening of the mucosa was noted in 38,8%, and bilateral total edema in 28,0% of cases. Remnants of filling material were found in 1,4% of sinuses on the right and in 2,8% on the left; no bilateral. Bone septa was visualized on the right in 18,8% of cases, in 17,4% on the left and bilateral in 31,8% of cases. Cystic masses were revealed on the right in 4,2% of cases, in 6,2% on the left, bilateral in 16,7%.

The findings of the study confirm the fact that implant rehabilitation of patients with edentulism of the upper jaw requires a thorough assessment of bone tissue parameters,

the state of the mucous membranes and architectonics of the sinuses. Currently, computed tomography of the upper jaw is considered as the “golden standard”. The presence of the pathological processes in the sinus is the basis for collaboration with otorhinolaryngologist, who can directly eliminate the adverse factors that exist in the maxillary sinus. The comprehensive approach will contribute to selection of the predicted modality of surgical intervention in the maxillary sinus with minimal risk for development of post-operative complications.

REFERENCES

1. Beaumont C. et al., Prevalence of maxillary sinus disease and abnormalities in patients scheduled for sinus lift procedures. *J. Periodontol.* 2005;76:461
2. Tkachenko P.I. Planuvannia dentalnoi implantacii pry skladnyh anatomo-topografichnyh umovah. *Visnyk problem biologii i medycyny.* 2016;4,(126):371-375.
3. Edwards S. P. Computer-assisted craniomaxillofacial surgery. *Oral Maxillofac. Surg. Clin. North. Am.* 2010;22:117-134.
4. Fatterpekar G. M. et al., Imaging the paranasal sinuses: where we are and where we are going. *Anat. Rec.* 2008;72:291-1564.

5. Ilze Dobele et al., Radiographic assessment of findings in the maxillary sinus using cone-beam computed tomography. *Stomatologija, Baltic Dental and Maxillofacial Journal.* 2013;4(15):119-122.
6. Manor Y. et al., Late signs and symptoms of maxillary sinusitis after sinus augmentation. *Oral Med. Oral. Pathol. Oral. Radiol. Endod.* 2010;4:110.
7. Pignataro L. et al., ENT assessment in the integrated management of candidate for (maxillary) sinus lift. *Acta Otorhinolaryngol Ital.* 2008;9:28-110.
8. Zijderveld S.A. et al., Anatomical and surgical findings and complications in 100 consecutive maxillary sinus floor elevation procedures. *American Association of Oral and Maxillofacial Surgeons. J. Oral Maxillofac Surg.* 2008;66:1426.
9. Pankevich V.L., *Dentalnaia implantologija. Moskva. Medicynskoje iformacionnoje agenstwo.* 2006.400 s.

The theme of the scientific research work: Integrative-differentiated justification of the choice of optimal methods for surgical interventions and the volume of therapeutic measures at surgical pathology of maxillofacial area.

Authors' contributions:

According to the order of the Authorship.

Conflict of interest:

The Authors declare no conflict of interest.

CORRESPONDING AUTHOR

Artur Pankevych

Ukrainian Medical Stomatological Academy
Shevchenko Street, 23, 36011 Poltava, Ukraine
tel: +380634022319
e-mail: artur68@ukr.net

Received: 09.08.2018

Accepted: 12.11.2018