

SYMMETRY OF ELEMENTS OF TEMPOROMANDIBULAR JOINT (TMJ)

SYMETRIA ELEMENTÓW STAWU SKRONIOWO-ŻUCHWOWEGO

Vera D. Kuroedova, Aleksey A. Stasiuk, Alexandra N. Makarova, Katya L. Trofimenko, Evheniy E. Vyzhenko

DEPARTMENT OF POST-GRADUATE EDUCATION OF ORTHODONTISTS, EDUCATIONAL AND RESEARCH INSTITUTE OF POST-GRADUATE EDUCATION, HIGHER STATE EDUCATIONAL ESTABLISHMENT OF UKRAINE «UKRAINIAN MEDICAL STOMATOLOGICAL ACADEMY», POLTAVA, UKRAINE

ABSTRACT

Introduction: Dysfunction of temporomandibular joint is present in 70-75% of orthodontic patients. Evaluation of TMJ and detailed characteristics of its elements with additional methods of examination in children and adults is necessary for clinical definition of proposed disturbances of the structure and functions of the joint.

The aim of the investigation is to study morphological symmetry of TMJ in patients with dentofacial abnormalities and with dentofacial abnormalities complicated by secondary edentulism.

Materials and Methods: 57 patients were involved in the examination. Based on gender principle patients' distribution was almost equal: there were 30 women and 27 men. Cone-beam computerized tomography (CBCT) Galileos (SIRONA DENTAL, Germany) was used to all patients.

Results: It was done analysis of parameters (height and length) of right and left heads (condyles) of temporomandibular joint in both groups. Asymmetry of parameters of heads' length in saggital area in patients of the second group was defined. It was proved statistically (left $10,38 \pm 0,76$, right $8,16 \pm 0,78$).

Conclusions: Increase of asymmetry of length of heads of TMJ in saggital area with age was determined. It can be explained by complication of dentofacial abnormalities and the presence of secondary edentulism. Depending on bite type length of condyle, especially at prognathism (in saggital) area peculiar clinical problems with TMJ can be present due to asymmetry of condyles. The size of joint gaps of TMJ due to the presence of dentofacial abnormalities with age demonstrates compensatory ability and saves its.

KEY WORDS: symmetry index, temporomandibular joint, dentofacial abnormality.

Wiad Lek 2017, 71, 6 cz. I, 1079-1082

INTRODUCTION

Dysfunction of temporomandibular joint is present in 70-75% of orthodontic patients [1]. Diseases of TMJ develop very early in particular in childhood [2]. It is necessary to consider orthodontic treatment can also cause dysfunction of temporomandibular joint (TMJ) because it is associated with disintegration of dentition, change of occlusion, displacement of mandible, functional asymmetry of masseters muscles [3, 4, 5, 6].

Evaluation of TMJ and detailed characteristics of its elements with additional methods of examination in children and adults is necessary for clinical definition of proposed disturbances of the structure and functions of the joint [7, 8]. Biometrical approach on control-diagnosed models was developed and used in practice to evaluate the stage of asymmetry of jaws [2]. The etiology of saggital asymmetry of bite at different dentofacial abnormalities gives an opportunity to define the author method of evaluation of orthopantomogram (OPTG) [9].

Subsequent detailed study of morphological, functional and topographic peculiarities of TMJ and also the evaluation of symmetrically these indices plays an important meaning for theoretical and practical orthodontics.

THE AIM

The aim of the investigation is to study morphological symmetry of TMJ in patients with dentofacial abnormal-

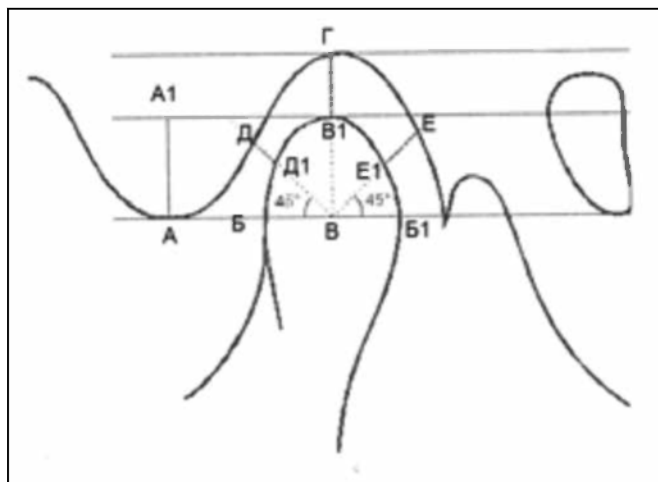
ities and with dentofacial abnormalities complicated by secondary edentulism.

MATERIALS AND METHODS

57 patients were involved in examination who applied in regional stomatological polyclinic of Poltava and who have dentofacial abnormalities (39 patients)-the first group, and secondary edentulism (18 patients)-the second group. Based on gender principle patients' distribution was almost equal: there were 30 women and 27 men. The age of patients ranged from 8 to 40 years old. The first group included patients with dentofacial abnormalities from 8 to 20 years old (21 men and 18 women). Depending on period of bite development all patients were divided into two subgroups: the first one included 18 patients (8-13 years old) with mixed bite (12 boys and 6 girls); the first subgroup-b included 21 patients with permanent occlusion (14-20 years) (9 men and 12 women).

According to Angle's classification of malocclusion without age, patients' distribution was the next: the first class included 18 patients (9 men, 9 women), the second one contained 12 patients (6 men, 6 women) and the third one included 6 patients (3 boys and 3 girls).

18 patients of orthopedic department (32-40 years) were involved in the second group. Patients have secondary



Picture 1. Scheme of roentgenomorphometric investigation of components of TMJ. A-A1- height of joint cusp; B-B1 – length of condyle; B-B1 – height of condyle; D-D1 – length of joint gap anteriorly; B1-Г – length of joint gap above; E-E1 – length of joint gap posteriorly. Measurements of length (B-B1) of joint head were done in three areas: sagittal, axial coronal, height (B-B1) in sagittal area.

edentulism and they require teeth replacement (prosthetics). There were 6 men and 12 women. Patients of the second group also have different types of malocclusion but they have never applied to orthodontist and more than half of these patients knew about their abnormalities.

Quantitative percentage of patients in groups and subgroups was the next: the first group contained 68,4% (1a-31,6%, 1b-36,8%), the second one included 31,6%. Written parent agreement was received to examine children of the first group.

Cone-beam computerized tomography (CBCT) Galileos (SIRONA DENTAL, Germany) was used to all patients. Radiological pressure on patient contained 9mk3v that positively differentiates this method from such diagnostics as digital orthopantomogram, where dose of X-rays in 5 times is higher and contains 48 mk3v.

Statistical package of licensed program “Statistica® for Windows 6.0” (StatSoftInc., № AXXR712D833214FAN5) was used to process results of investigations and also “SPSS17.0”, “Microsoft Exel 2003” was also used. Accurate results >95% were considered.

57 cone-beam computer tomograms of TMJ were the subject of the investigation. Measurement and scoring of cone-beam computerized tomography (CBCT) was done based on N.A. Rabukhina’s method in modification by I.E. Androsova, A.A. Anikienko, L.I. Kamysheva (Picture 1).

Length of joint gap was measured in three areas: anterior, upper, posterior. Measurement of height and length of condyle of TMJ was performed.

Based on data of measurements coefficient of the shape of condyle F was calculated (correlation of length of condyle to its height) according to formula F If condyle is wider and shorter the meaning of coefficient will be higher [8,12].

Index of symmetry based on formula $I_{sim} \times 100\%$ was calculated for each studied parameter of TMJ (length of condyle, height of condyle, shape of condyle, length of joint gap). If index of symmetry is 100%, studied indices will be more symmetrical. Symmetry of condyles of TMJ was studied. Radiological density of condyles of TMJ was evaluated by densitometric indices of Hounsfield scale (HU).

RESULTS AND DISCUSSION

All results of examined indices are presented in I-IV tables.

It was done analysis of parameters (length and height) of right and left condyles of TMJ in both groups (table I). Height of condyles has a tendency (statistically inaccurate) to increase with age (1a -5,63±0,81, 1b-0,01±0,56 left and 1a-4,6±0,76, 1b-7,00±0,88), and it confirms age change. Length of condyles of TMJ also can increase and it can be seen during evaluation of this parameter axial area (1a-14,66±1,09, 1b-19,12±1,04)- $p < 0,01$ both left and right (15,01±0,85-1a, 18,81±11-16)- $p < 0,01$ – (table 1).

Comparison of average sizes of length of condyles of the first and the second groups in studied areas (coronal, sagittal, axial) demonstrates the absence of statistically accurate difference. Symmetry is between indices of length of condyles of TMJ of right and left sides in both groups.

Asymmetry of parameter of length of condyles of TMJ in sagittal area in patients of the second group (table1) is proved statistically. So, in patients with permanent occlusion who have dentofacial abnormalities complicated by teeth lost there is anatomical asymmetry in the formation and structure of condyles of TMJ and especially the length of condyle from left side increases.

Comparison of sizes of height of condyles of TMJ demonstrates decrease of indices from the first-b subgroup to the second one from 7,01 ±0,56 to 5,94 ±0,53 left and from 7,00±0,88 to 6,95±0,30 right, without statistical accuracy.

Type of malocclusion changes length of condyle only in patients with prognathism in sagittal area. So, length of condyle of TMJ from left side predominates analogical index from right side with statistical accuracy ($p < 0,05$) (table 2). So, asymmetry of condyles of TMJ was proved only in patients of the second class, (Angle’s classification) i.e. distal bite than other types of malocclusion is prone to further formation of clinical problems with TMJ.

Sizes of joint gap of TMJ in three parts: (anterior, upper, posterior) both in the first group and in the second one and also it depends on types of bite and they do not have statistical differences (table 3), i.e. joint gap and joint disc have, compensatory ability to functional leveling of non-significant morphological incongruence.

The evaluation of calculated by us symmetry index ($I_{sim} \times 100\%$) of TMJ elements demonstrated that the first group with age (comparison 1a and 1b subgroups) asymmetry increases in further parameters: length of condyle and length of joint gap, while length of condyle and length of joint gap are permanent i.e. symmetrical (table 4)

Table I. Evaluation of middle sizes of height and length of condyles of TMJ (mm)

TMJ	Left				Right				
	area	Length		Height axial	area	Length		Height Axial	
		coronal	sagittal			coronal	sagittal		
subgroups	1a	14,84±0,9	8,46±0,5	14,6±1,09	5,63±0,81	14,5±0,76	8,5±0,39	15,01±0,85	4,6±0,76
	1b	13,38±1,18	8,5±0,32	19,1±1,04	7,01±0,56	14,9±1,44	8,24±0,41	18,8±1,1	7,00±0,88
1 st gr.		14,1±1,04	8,48±0,41	16,89±1,06	5,85±0,66	14,72±1,1	8,37±0,4	16,91±1,21	6,11±0,49
2 nd gr.		15,25±1,76	10,38±0,76	15,38±1,9	5,94±0,53	15,4±1,9	8,16±0,78	16,28±1,97	6,95±0,30

P < 0,05 in sagittal area between left and right condyles of TMJ in the 2nd group rpyrnn

Table II. Evaluation of symmetry of condyles's sizes depending on bite type (in mm)

Temporomandibular joint	Left				Right			
	Density	Length		Height	Density	Length		Height
		coronal	sagittal			axial	coronal	
The first class	13,5±1,5	8,1±0,5	16,7±1,9	5,9±0,93	14,7±1,6	8,3±0,6	17±2,2	6,12±1,78
The second class	13,7±1,9	9,2±0,2	19,6±1,6	6,8±0,63	13,9±2,2	8,2±0,3	18,7±1,3	6,52±0,83
The third class	14,5±0,2	7,9±0,6	15,3±2,4	4,35±1,35	16,6±0,8	8,8±0,7	16,6±0,1	3,6±0,2

p < 0,05 in the second class in sagittal area between left and right condyles of TMJ

Table III. Evaluation of average indices of length of joint gap of TMJ

TMJ	LEFT			RIGHT			
	Gap part	Anterior	Upper	Posterior	Anterior	Upper	Posterior
Subgroups	1a	3,23±0,46	2,54±0,51	2,95±0,21	2,4±0,22	2,71±0,18	2,9±0,16
	1b	2,12±0,51	2,68±0,50	2,88±0,20	2,92±0,19	2,62±0,16	2,65±0,19
1st group		2,67±0,59	2,61±0,16	2,91±0,39	2,66±0,40	2,66±0,31	2,77±0,34
2nd group		3,07±0,58	2,45±0,27	2,11±0,50	3,89±0,9	2,51±0,44	2,067±0,27
Bite type							
The first class		2,3±0,28	2,75±0,11	3,35±0,3	2,7±0,27	2,77±0,24	2,76±0,1
The second class		2,7±0,44	2,65±0,33	2,3±0,49	3,32±0,27	2,65±0,31	2,25±0,4
The third class		2,7±0,44	3,25±1,6	2,7±0,9	4,05±2,7	3,25±1,6	2,4±0,5

Table IV. Average symmetry index of condyles of TMJ and joint gap (%)

Groups	TMJ	Isim				
		Condyle		Length of joint gap		
		Length	Height	Parts		
				Anterior	Upper	Posterior
1	1 a	95,12%	99,32%	91,72%	90,87%	98,87%
	1 b	94,61%	99,92%	78,12%	82,75%	82,61%
	In general	94,87%	99,62%	84,92%	86,81%	90,74%
2		67,53%	78,41%	81,39%	82,56%	84,81%

In patients with dentofacial abnormalities and secondary edentulism (the second group) significant increase of asymmetry in length of condyle (67,53%) and its height (78,41%), and also in length of joint gap correspondingly: 81,39%, 82,56%, 84,81% was found in anterior, upper and posterior parts. (Table 4)

According to computer tomography based on Ilo Isim it was defined by us asymmetry of condyles of condyles of TMJ with age increases. So, in the first subgroup a (with mixed occlusion) symmetry index of length of condyles of TMJ is equal to 95,12%, and in the subgroup 1b (with

permanent bite) is equal to 94,61%, that approaches to available physiological norms of asymmetry $\pm 6\%$ [8], while in patients with dentofacial abnormalities and secondary edentulism index of symmetry is significantly decreased and is equal to 67,5%. (Table 4).

Index of symmetry of height of condyles of TMJ in the subgroup with mixed bite (1a) is equal to 9,32%, in subgroup with permanent bite is equal to 1-b 99,9%, that is within norm and in group with dentofacial abnormalities and secondary edentulism (2group) contain 78,4%, that is proved by pathological asymmetry of height of condyles of TMJ.

So, in people with dentofacial abnormalities especially with secondary edentulism with age there is increase of asymmetry in the structure of condyles of TMJ. But there is difference of the shape of right and left condyles ($p < 0,05$), and difference of symmetry of length of joint gap is permanent (table 4). Coefficient of the shape of condyle (f) between groups was compared: the first group (dentofacial abnormality) and the second one (dentofacial abnormality + secondary edentulism), and also between subgroups: 1-a (mixed), 1-b (permanent bite). It was determined that asymmetry of the shape of condyle of TMJ with age increases and its shape changes. Condyles of TMJ in patients of the second group are narrower and longer in comparison with patients of the first group.

Coefficient of shape of condyle of TMJ has tendency to decrease from 1-a subgroup and to the second subgroup from the left and right sides 1,88; 1,26; 1,23 correspondingly.

CONCLUSIONS

Increase of asymmetry of condyles length in saggital area with age was detected. It is associated with complication of dentofacial abnormalities and the presence of secondary of edentulism.

Depending on type, bite length of condyle changes, especially during prognathism (in saggital) area. Peculiar clinical problems with TMJ can increase and also due to asymmetry of condyles.

The size of joint gap of TMJ at presence of dentofacial abnormalities with age demonstrates compensatory ability and saves its size.

Asymmetry of shape of condyle with age increases and changes its (in the second group condyles of TMJ are narrower and longer).

REFERENCES

1. Богатырьков Д.В., Оспанова Г.В. [Диагностический алгоритм при обследовании пациентов с асимметрией лица] Ортодонтия. 2009;1: 49.
2. Ивасенко П.И., Савченко Р.К., Мискевич М.И., Фелькер В.В. [Заболевания височно-нижнечелюстного сустава]. Медицинская книга, Москва. 2009.
3. Фадеев Р.А., Зотова Н.Ю., Кузакова А.В. [Методы обследования височно-нижнечелюстных суставов с использованием денальной компьютерной томографии]. Дентал Юг. 2012; 5: 56-60.
4. Хватова В.А. [Заболевания височно-нижнечелюстного сустава]. Медицина, Москва. 1982.
5. Рабухина Н.А., Аржанцев А.П. [Рентгенодиагностика в стоматологии]. ООО «Медицинское информационное агентство» Москва 1999.
6. Kuroyedova V.D., Makarova A.N., Chicor T.A. [Functional condition of masseters muscles of patients with class II subdivision] Wiadomosclie Lekarskie. 2017;4:762-766.
7. Li H. [Studying the spatial character of the temporomandibular joint] Am J Orthod Dentofacial Orthop. 2011; 140 (6): 752-753.
8. Vitral. R., Campos M., Rodrigues A., Fraga M. [Temporomandibular joint and normal occlusion: Is there anything singular about it? A computed tomographic evaluation]. Am J Orthod Dentofacial Orthop. 2011; 140 (1): 18-24.
9. Куроедова В.Д., Макарова А.Н. [Роль ортопантомографії в діагностиці одностороннього II класу зубощелепних аномалій за E.N. Angle] Український стоматологічний альманах. 2013;5:64-66. Україна.

ADDRESS FOR CORRESPONDENCE

Vera D. Kuroedova

Department of Post-graduate Education of orthodontists,
Higher State Educational Establishment of Ukraine
«Ukrainian Medical Stomatological Academy»,
23, Shevchenko str., 36011, Poltava, Ukraine
tel: +380663218542
e-mail: polo_nnipo@ukr.net

Received: 14.07.2017

Accepted: 10.11.2017