

OPTICAL DENSITY OF UPPER JAW IN PATIENTS WITH MALOCCLUSION

GĘSTOŚĆ OPTYCZNA SZCZĘKI U PACJENTÓW Z WADĄ ZGRYZU

Vera D. Kuroedova, Evheniy E. Vyzhenko, Alexandra N. Makarova, Ludmila B. Galych, Tatyana A. Chikor

DEPARTMENT OF POST-GRADUATE EDUCATION OF ORTHODONTISTS, EDUCATIONAL AND SCIENTIFIC INSTITUTE OF POST-GRADUATE EDUCATION, HIGHER STATE EDUCATIONAL ESTABLISHMENT OF UKRAINE, "UKRAINIAN MEDICAL STOMATOLOGICAL ACADEMY", POLTAVA, UKRAINE

ABSTRACT

Introduction: The growth and formation of facial skeleton is in interrelation with growth of cervical spine. Computer tomography plays an important role to examine and investigate the density of bony tissue resulting from total increase of osteopenic diseases and diseases of periodontal tissue.

The aim of the paper is to compare indices of mineral density of bony tissue of the upper jaw and mineral density of the second cervical vertebra in patients with malocclusion.

Materials and Methods: 37 orthodontic patients were involved in the investigation. They were divided into three age groups depending on the period of formation of dento-facial system. Density measurement of bone of the second cervical vertebra was done and also density measurement of upper jaw in the area of alveolar process between central incisors, canines and the first premolar on the level of the middle of roots, in the area of the first molars under the level of bifurcation and in cusp was performed.

Results: Optical density of bone of the second cervical vertebra with age increases from $501 \pm 61,06$ to $587,6 \pm 48,81$. The densest area on the upper jaw is alveolar process between central incisors, which increases with age from $1045,14 \pm 59,81$ to $1318 \pm 69,28$.

The least indices of optical density were determined in area of the cusp of the upper jaw: the first group presented $174,21 \pm 38,94$, and the third one included $338,87 \pm 26,91$.

Conclusions: Densitometry of bony tissue with computer tomography is diagnostically informative and available method for investigation and it can be used for diagnostics of bony tissue condition and for evaluation of orthodontic treatment.

KEY WORDS: malocclusion, bone density, upper jaw.

Wiad Lek 2017, 70, 5, 913-916

INTRODUCTION

Disturbances of metabolic processes of bony tissue of jawbones based on general somatic abnormality and also action of unfavorable factors of environment are the main etiological factors which cause the development of malocclusion [1, 2]. It was proved that the shape of cervical region of vertebral column affects the growth and formation of facial skeleton [3-6].

X-ray investigations of malocclusion and defects play an important role for planning orthodontic treatment [7]. Computer tomography (CT) is informative and available method of objective investigation of patients in orthodontic practice.

CT plays an important role to examine and investigate the density of bony tissue resulting from total increase of osteopenic diseases and diseases of periodontal tissue. Recently osteoporosis as systemic disease of skeleton has a tendency to rejuvenation and it occurs in childhood and teenage age and is characterized by loss of mass of bony tissue and damage of its microarchitectonics.

Based on Bondarenko N.N. and co-authors information (2012), that in person with healthy parodontium indices of optical density of bony tissue of alveolar process are from 583,1 to 1429,75 depending on teeth positioning [8].

Lekholm U. and Zarb G. (1985), and also Mish C. (1990) propose the interpretation of density of bony tissue. So, indices of more than 850 units were characterized by them as

intact dense bone from 350 to 850 units as relatively intact soft bone and less than 350 units as local osteoporosis [9].

In modern literature to nowadays, there are individual papers which are devoted to peculiarities of changes of mineral density of bony tissue of jawbones in patients with malocclusion.

THE AIM

The aim of the paper is to compare indices of mineral density of bony tissue of upper jaw and mineral density of the second cervical vertebra (C2) in patients with malocclusion.

MATERIALS AND METHODS

CT of jawbones was done on odontic computer tomograph «VATECH PAX-ZENITH 3D», the step of scanning was 1 mm, the duration of scanning was 15 sec. with general radiation exposure 50 mksv.

37 orthodontic patients were involved in the investigation. They were divided into three age groups depending on the period of formation of dento-facial system [10]. The first group presented 7 patients (6-12 years old, the period of mixed dentition), middle age was 9,4 years, the second group contained 15 people (from 13 to 20 years old and

Table I. Density of bony tissue of the upper jaw and C2 (HU)

Place of measurement	Group	I	II	III
C2		501±61,06 p ₁₋₃ >0,05	550,6±45,32 p ₁₋₂ >0,05	587,6±48,81 p ₂₋₃ >0,05
between 11 and 21		1045,14±59,81 p ₁ <0,01 p ₁₋₃ <0,01	1220,8±82,24 p ₂ <0,01 p ₁₋₂ >0,05	1318±69,28 p ₃ <0,01 p ₂₋₃ >0,05
between 13-14 and 23-24		877,21±33,13 p ₁ <0,01 p ₁₋₃ >0,05	924,4±40,49 p ₂ <0,01 p ₁₋₂ >0,05	930,97±29,44 p ₃ <0,01 p ₂₋₃ >0,05
bifurcation of roots 16, 26		476±63,51 p ₁ >0,05 p ₁₋₃ >0,05	644,67±45,53 p ₂ >0,05 p ₁₋₂ <0,05	531,47±36,82 p ₃ >0,05 p ₂₋₃ >0,05
cuspid		174,21±38,94 p ₁ <0,01 p ₁₋₃ <0,01	302,3±36,41 p ₂ <0,01 p ₁₋₂ <0,05	338,87±26,91 p ₃ <0,001 p ₂₋₃ >0,05

Note: p₁ – statistical difference of bone density between C2 and studied areas on the upper jaw in the first group;
 p₂ – statistical difference of bone density between C2 and studied areas on the upper jaw in the second group;
 p₃ – statistical difference of bone density between C2 and studied areas on the upper jaw in the third group;
 p₁₋₂ – statistic difference of bone density of identical zones between the first and the second groups;
 p₂₋₃ – statistic difference of bone density of identical zones between the second and the third groups;
 p₁₋₃ – statistic difference of bone density of identical zones between the first and the third groups.

this stage is characterized by the termination of permanent bite formation, middle age was 15,1 years. The third group included 15 patients aged 21-40 years old (middle age was 26,6), that corresponds the period of active functioning of dento-facial system.

Applied programs were used in each computer tomographs. In the program Ez3D2009 density of bony tissue is measured by the instrument «Profile – measurement of bone density between two points» in units Hounsfield (HU).

In 1979 the Nobel prizeman Hounsfield G.N. proposed corresponding scale of density measurement for X-rays which are used in tomography. X-ray density of distilled water was accepted by author 0 HU, air was 1024 HU at standard pressure and temperature.

The program measures the coefficient of absorption of X-ray which came through object. When tissue is denser, x-ray will absorb and suppress coming through it. Respectively, the coefficient of decrease and meaning is higher HU. Bone absorbs X-rays and has the biggest coefficient. The air practically doesn't absorb their and has the least coefficient of absorption. That's why the bone is white and air is black on computer screen.

Measurement procedure: after standard procedure of CT and receiving reconstructed image on screen by pressing button one activate the instrument of panel «Profile». One performs by pointer secant line in the window of multiplane reconstruction and after that on histogram one defines the meaning of X-ray density in definite area. Borders of density were established in the base of lift on histogram that corresponds the beginning of compact bone with vestibular and oral sides (Picture 1).

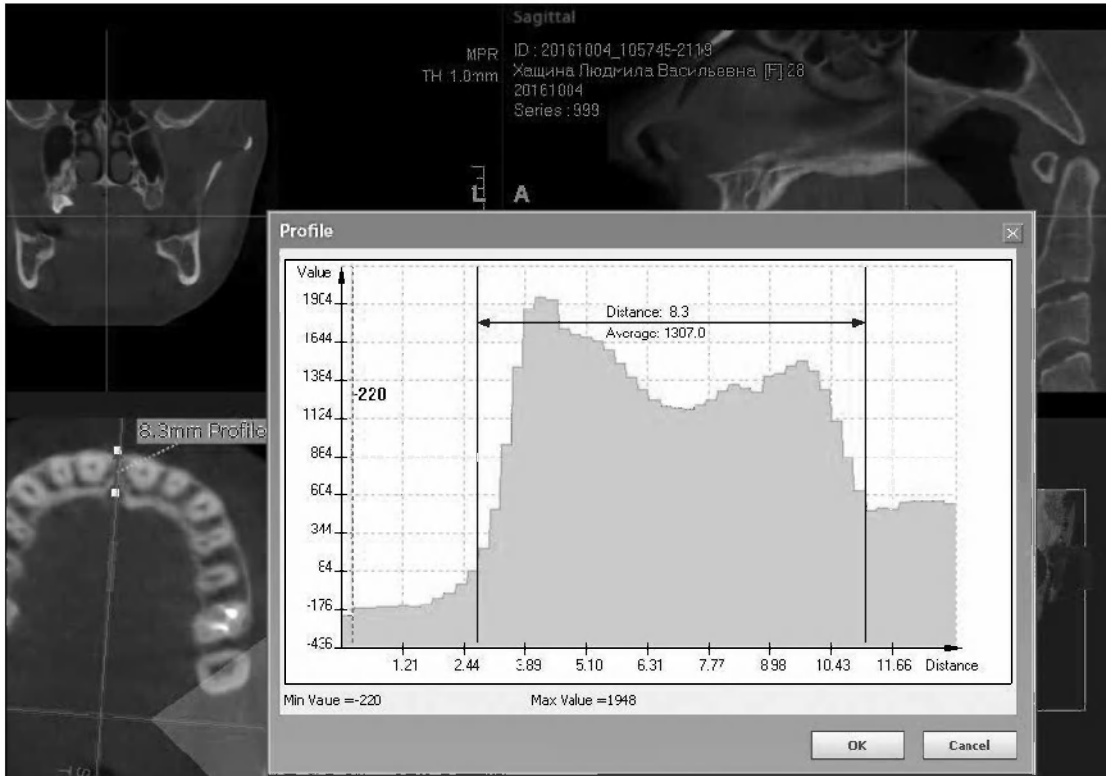
Cervical vertebrae C2, C3, and C4 are well seen on studied CT in saggital window. That's why, for comparison C2 was done for bone density measurement which was done in saggital projection through middle height of vertebra. On the upper jaw measurements were done on axial sections in vestibule-oral direction in alveolar process between central incisors, between canine and the first premolar on the level of middle part of roots, and in the area of the first molars under the level of bifurcation and in the area of cusp.

Meanings of investigated indices were statistically processed by methods of medical statistics with the use of program of statistic analysis Microsoft Excel 2010, version Windows 7. T-criterion Student was used to compare indices, differences were accurate at p<0,05.

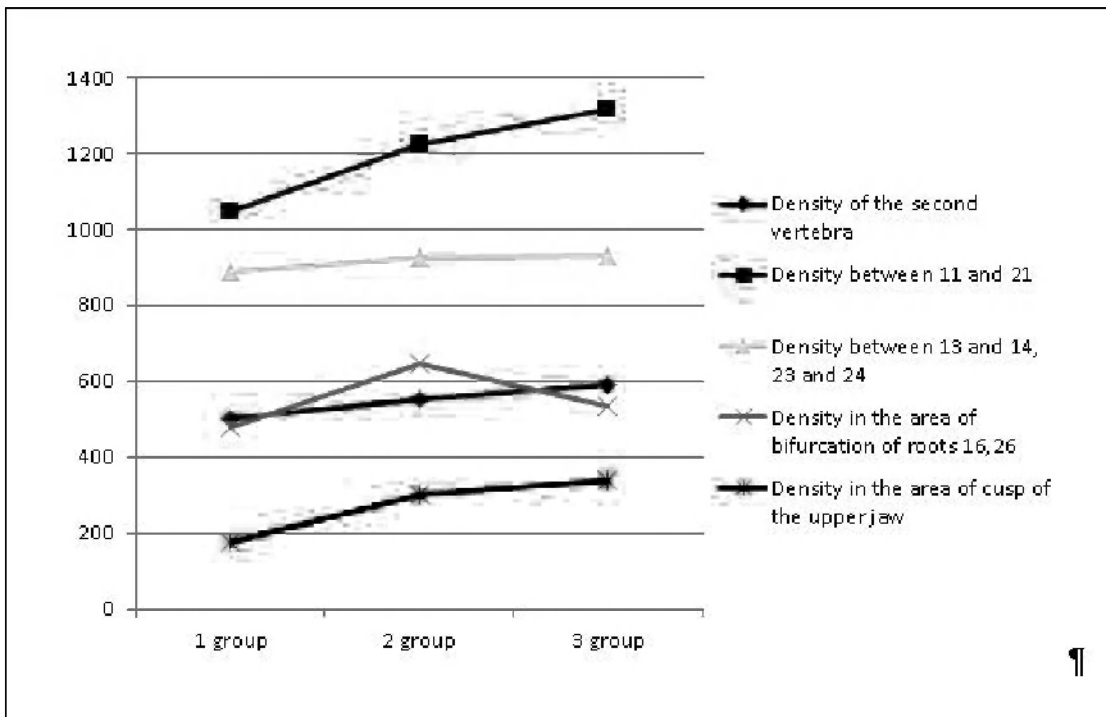
RESULTS I DISCUSSION

Results of measurement of bony tissue of the upper jaw density and C2 are presented in table I. To determine average meaning of density of bony tissue between 13-14 and 23-24 teeth, based on bifurcation of roots 16, 26 and in the area of cusp of the upper jaw all indices were summed up right and left so accurate statistic difference between sides was not indicated.

Based on results of the investigations C2 with age has a tendency to increase of mineralization so to growth of densitometric indices of its density as all bony skeleton of a person. So, comparison of average indices C2 in groups demonstrates increase of bony tissue density with age from 6 to 40 years with 501±61,06 to 587,6±48,81 respectively (table I). Comparison of received data be-



Picture 1. Definition of bone density between 11 and 21 teeth.



Picture 2. Age dynamics of changes of densitometric indices in studied area.

tween groups statistically accurate difference did not demonstrate.

Age dynamics of changes of densitometric indices of density in studied areas is presented in picture 2.

The densest area on the upper jaw is alveolar process between central incisors which increases from $1045,14 \pm 59,81$ to $1318 \pm 69,28$. Accurate difference of density was indicated in the area between central incisors in the first and the third

groups ($p_{1-3} < 0,01$), data of indices in 2-2,5 times exceed the density of C2 (table I, picture 2).

Such dynamics i.e. the increase of bony tissue density is presented during the analysis of indices of the upper jaw between canine and the first premolar: $877,21 \pm 33,13 - 930,97,29,44$ in the first and the third groups correspondingly (table I). Statistically accurate difference between groups was not indicated. These indices in average on 50% are higher, than the density of bone in C2.

The similarity of densitometric indices of bone density was determined between C2 and the area of bifurcation of the first molars (in all three groups $p > 0,05$). Maximal indices of density were determined in the second group ($644,67 \pm 45,53$) and accurately exceed the indices in the first one - $476 \pm 63,51$ ($p_{1,2} < 0,05$). Based on our opinion decrease of bone density in the area of bifurcation of roots of the first molars of the upper jaw in patients of the third group ($531,47 \pm 36,82$) can be associated with age periodontal problems (picture 2).

Optical density in the area of cusp of the upper jaw is accurately lower from C2 density in all age groups and it is the lowest densitometric index. With age the density of bone of cusp of maxilla increases, that is proved statistically between patients of the first group $174,21 \pm 38,94$, and the second and the third one $302,3 \pm 36,41$ and $338,87 \pm 26,91$ correspondingly ($p_{1,2} < 0,05$, $p_{1,3} < 0,01$) (table I). Optical density of the second cervical vertebra exceeds in 2,9, times, in the second one in 1,8, in the third one in 1,7 times in the area of cusp of the upper jaw in the first group. Based on modern X-ray methods received data confirm that cusp of the upper jaw is the zone of the growth of upper jaw.

CONCLUSIONS

Densitometry of bony tissue with computer tomography is diagnostically informative and available method for investigation and it can be used for diagnostics of bony tissue condition and for evaluation of orthodontic treatment.

Indices of the second cervical vertebra in all age groups are relatively permanent and stabile index of mineral density. Such data allow using indices for comparative characteristics of mineral density measurement in the area of alveolar processes of jawbones in dynamics of orthodontic treatment.

The densest areas of bony tissue on the upper jaw are areas between central incisors and between canine and the first premolar.

Based on results of investigation there is a tendency to increase of mineral density of bony tissue with age.

In all groups the density of bone of the second cervical vertebra is higher than density in the area of cusp, because cusp of the upper jaw is the zone of growth of maxilla.

REFERENCES

1. Осипенко О.В., Вахлова И.В., Трифонова Е.Б. [Клинические и лабораторные признаки дефицита кальция у подростков]. *Вопросы современной педиатрии*. 2009; Т8 (4): 56-62.
2. Muñoz-Calvo M.T. [Nutritional and Puberal Disorders]. *J. Argente Endocr Dev*. 2016; 29: 153-173.
3. Карпова В.С., Польша Л.В., Бугровецкая О.Г., и др. [Взаимосвязь постурального дисбаланса в шейном отделе позвоночника с параметрами лицевого скелета у пациентов с дистальной окклюзией]. *Ортодонтия*. 2013; 4 (64): 9-16.
4. Cericato G.O., Bittencourt M.A., Paranhos L.R. [Validity of the assessment method of skeletal maturation by cervical vertebrae: a systematic review and meta-analysis]. *Dentomaxillofac Radiol*. 2015; 44 (4): doi:10.59/dmfr.20140270.
5. Crawford B., Kim D.G., Moon E.S., et al. [Cervical vertebral bone mineral density changes in adolescents during orthodontic treatment]. *Am J Orthod Dentofacial Orthop*. 2014; 146 (2): 183-189.
6. Prasad C.K., Reddy V.N., Prasad C.K., Sreedevi G., [Objective evaluation of cervical vertebral bone age` its reliability in comparison with hand-wrist bone age: by TW3 method]. *J Contemp Dent Pract*. 2013; 14 (5): 806-813.
7. Куроедова В.Д., Выженко Е.Е., Стасюк А.А. [Экспресс-метод определения типа роста челюстных костей на ортопантограмме]. *Georgian Medical News*. 2016; 7-8 (256-257): 14-17.
8. Бондаренко Н.Н., Балахонцева Е.В. [Измерение оптической плотности костной ткани альвеолярного отростка челюстей при заболеваниях пародонта с помощью трехмерной компьютерной томографии]. *Казанский медицинский журнал*. 2012; Т.93 (4): 660-662.
9. Misch С.Е. [Contemporary Implant Dentistry]. 3rd Edition, Mosby Elsevier, St. Louis, Missouri. 2008.
10. Головкин Н.В. [Профілактика зубощелепних аномалій]. Нова Книга, Вінниця. 2005.

ADDRESS FOR CORRESPONDENCE

Tatyana A. Chikor

тел. +380994594539

e-mail: tatyana_chikor@mail.ru

Received: 15.06.2017

Accepted: 25.10.2017