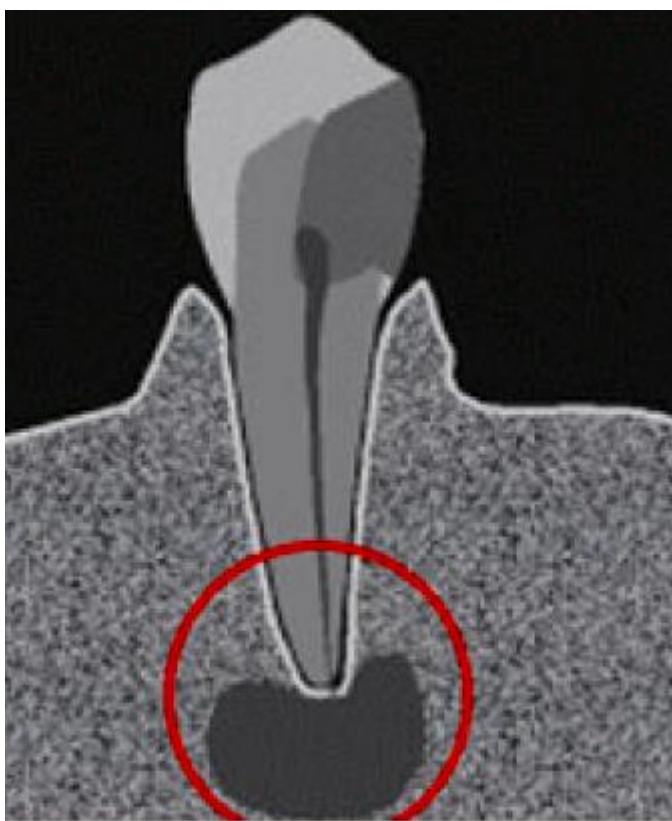


D.S.Avetikov, K.P. Lokes, I.V.Yatsenko, S.O. Stavickij

MODERN METHODS OF TREATMENT OF CYSTS OF JAWS



Poltava - 2014

МІНІСТЕРСТВО ОХОРОНИ ЗДОРОВ'Я УКРАЇНИ
ВИЩИЙ ДЕРЖАВНИЙ НАВЧАЛЬНИЙ ЗАКЛАД УКРАЇНИ
«УКРАЇНСЬКА МЕДИЧНА СТОМАТОЛОГІЧНА АКАДЕМІЯ»

АВЕТІКОВ Д.С., ЛОКЕС К.П., ЯЦЕНКО І.В., СТАВИЦЬКИЙ С.О.

AVETIKOV D.S., LOKES K.P., YACENKO I.V., STAVICKIJ S.O.

**MODERN METHODS OF SURGICAL
TREATMENT OF CYSTS OF JAWS**

**СУЧАСНІ МЕТОДИКИ ХІРУРГІЧНОГО
ЛІКУВАННЯ КІСТ ЩЕЛЕП**

Навчальний посібник

Text-book

Полтава – 2014

UDC 611-616.3 617

LBC 55.6+56.6]я73

A 19

Рекомендовано до друку Вченою радою ВДНЗУ «Українська медична стоматологічна академія». Протокол № 1, від 27 серпня 2014 р.

Аветіков Д.С. – д.мед.н., професор, завідувач кафедри хірургічної стоматології та щелепно-лицевої хірургії з пластичною та реконструктивною хірургією голови та шиї ВДНЗУ «УМСА»

Локес К.П. – к.мед.н., асистент кафедри хірургічної стоматології та щелепно-лицевої хірургії з пластичною та реконструктивною хірургією голови та шиї ВДНЗУ «УМСА»

Яценко І.В. – к.мед.н., доцент кафедри хірургічної стоматології та щелепно-лицевої хірургії з пластичною та реконструктивною хірургією голови та шиї ВДНЗУ «УМСА»

Ставицький С.О. – к.мед.н., асистент кафедри хірургічної стоматології та щелепно-лицевої хірургії з пластичною та реконструктивною хірургією голови та шиї ВДНЗУ «УМСА»

Avetikov D.S. – doctor of medical science, professor, chief of department of surgical stomatology and maxillo-facial surgery with plastic and reconstructive surgery of head and neck “Ukrainian medical stomatological academy”

Lokes K.P. – candidate of medical science, assistant of department of surgical stomatology and maxillo-facial surgery with plastic and reconstructive surgery of head and neck “Ukrainian medical stomatological academy”

Yacenko I.V. – candidate of medical science, docent of department of surgical stomatology and maxillo-facial surgery with plastic and reconstructive surgery of head and neck “Ukrainian medical stomatological academy”

Stavickij S.O. – candidate of medical science, assistant of department of surgical stomatology and maxillo-facial surgery with plastic and reconstructive surgery of head and neck “Ukrainian medical stomatological academy”

Рецензенти:

Г.П. Рузін, завідувач кафедри хірургічної стоматології та щелепно-лицевої хірургії Харківського Національного медичного університету, д.мед.н., професор.

О.О. Гудар'ян, завідувач кафедри хірургічної стоматології, імплантології та парадонтології Дніпропетровської державної медичної академії, д.мед.н.

П.І. Ткаченко, завідувач кафедри дитячої хірургічної стоматології ВДНЗ України «Українська медична стоматологічна академія», д.мел.н., професор.

У навчальному посібнику наведені дані щодо етіології, патогенезу, клінічної картини, діагностики та методів лікування одонтогенних та неодонтогенних кіст щелеп. Наведені сучасний інструментарій, місцево знеболюючі препарати, шовні матеріали та матеріали для репаративного остеогенезу, які використовуються при хірургічному лікуванні кіст щелеп.

Призначено для лікарів-стоматологів, студентів стоматологічного факультету та клінічних ординаторів з фаху «хірургічна стоматологія» англomовної форми навчання вищих медичних закладів III-IV рівнів акредитації.

Data about ethiology, pathogeny, clinical picture, diagnostic and methods of treatment of odontogenic and non-odontogenic cysts of jaws are published at this text-book. Modern instruments, local anesthetics, suture matherials and matherials for reparative osteogenesis that are used at surgical treatment of jaw cysts

CONTENT

INTRODUCTION

CHAPTER I. MORPHOLOGY OF JAW CYSTS

CHAPTER II. STATISTICS OF CYSTS FORMATION IN JAWS BONES

CHAPTER III. CLASSIFACATION OF JAW CYSTS

CHAPTER IV. ETHIOPATHOGENESIS, MECHANISM OF FORMATION AND CLINICAL SYMPTOMS OF DIFFERENT TYPES OF CYSTS.

CHAPTER V. EXAMINATION AND PREPARATION OF THE PATIENT FOR OPERATION

CHAPTER VI. INSTRUMENTS AND MATERIALS THAT ARE USED IN SURGICAL TREATMENT OF JAW CYSTS

CHAPTER VIII. CHOICE OF SUTURE MATERIAL IN SURGICAL TREATMENT OF JAW CYSTS

CHAPTER VII. CHOICE OF ANESTHESIA IN SURGICAL TREATMENT OF JAW CYSTS

CHAPTER IX. SELECTION OF MATERIALS FOR REPARATIVE OSTEOGENESIS IN SURGICAL TREATMENT OF JAW CYSTS

CHAPTER X CHOICE OF SURGICAL METHODS AT TREATING THE JAW CYSTS

CHAPTER XI. COMPLICATIONS ARISING IN SURGICAL TREATMENT OF JAW CYSTS

REFERENCES

INTRODUCTION

Cysts of jaws are widespread pathology. Suffice it to say that among the operations performed by surgeons and dentists in an outpatient setting, an operation concerning odontogenic and not odontogenic jaw cysts occupy the top spots after surgery of tooth extraction.

Unfortunately, the young doctors who have passed the primary specialization, but do not have enough clinical experience is not always consult with experienced colleagues about patients with this disease. To get necessary information from the literature is often difficult, as in textbooks and guidance for doctors, material on the classification, diagnosis, and treatment of jaw cysts usually taught or short, or contradictory and a monograph on this subject, have long been a rarity. After studying this question thoroughly, we, first of all, set a goal to give the most rational variant of the manual, which best set out a question of statistical classification methods for diagnosis and treatment of jaw cysts considering primarily the interests of practical dentistry.

CHAPTER I. MORPHOLOGY OF JAW CYSTS

Cyst (cysta; from greek cystis - blister) - pathological benign cavity formation, usually spherical form that consists of a closed connective tissue membrane and epithelial lining with liquid or semi-liquid content - waste product of the epithelial lining, which accumulates in the form of keratin, colloids and crystalloids (eg, cholesterol crystals).

The true cyst created inside one or another type of stratified squamous epithelium which is usually constructed by type of surface epithelium of the oral cavity, but on the upper jaw sometimes submitted by cylindrical ciliated epithelium type of the mucous of maxillary cavity. Pseudocyst has no epithelial lining. Spurious cysts can be simple and aneurismal.

It is important to remember that the differentiated epithelium normally in jaw bones is absent. Therefore, the treatment of cysts, all the epithelium must be removed, to avoid a recurrence.

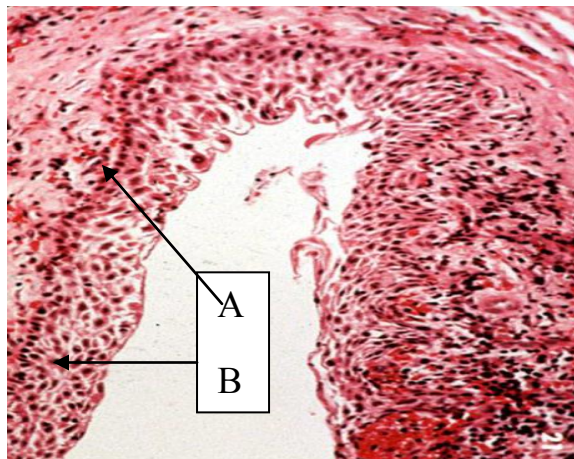


Figure 1.

Histological structure of the cyst membrane:

A - Connective-tissue membrane, B - epithelial lining

Accumulation of metabolic products of the epithelial lining leads to increasing of hydrostatic pressure in the cavity of the cyst. As a result of increasing pressure on the surrounding bone, is it osteolysis, leading to an increasing of pathological cavity size, and then deformation of the jaw.

Cysts are self-similar to a benign tumor disease. With benign tumors cysts are united with slow expansive growth. Distinctive features from benign tumors - lack of independent growth. The development of cysts stops after creating an outflow of its contents.

CHAPTER II. STATISTICS OF CYSTS FORMATION IN JAWS BONES

Radicular cysts occur according to Vasiliev (1950) at 94 - 96% Myroniuk (1965) - 91%; Solntsev-Kolesov (1982) - 84% of all cases of formation cysts in the jaws.

The tendency to reduce the number of radicular cysts associated primarily with improving the quality of diagnosis and differential diagnosis.

Notice that among the patients who enter the dental hospitals, patients with radicular cysts account for approximately 8%. About half of them (46%) - is sick of cysts of the jaws, which began to fester. And radicular cysts are more common on the upper (63%) and less often on the lower (34%), jaw, equally often localized on the right and the left sides (Tataryntsev, 1972).

Nearly equally often they appear in both men and women. The largest number of radicular cysts detected in age from 20 to 45 years. This is due to the fact that in this age period teeth are often affected caries process, complicated by inflammatory changes in the periapical tissues.

Follicular cysts are found according to Evdokimov, Vasilyev (1964), Ermolaev et al. (1972) - 4 - 6%. In most cases, follicular cysts developing in childhood and youth age during the eruption of permanent teeth (34% of patients 14 years old), and later, in 18-20 years, the development of follicular cysts observed in the area of wisdom teeth.

Periodontal cysts are found according to Solntsev-Kolesov (1981) - 1.5% of cases.

Cysts, containing a tooth, present only among children during alternating occlusion and according to Gogol (2006), constitute 5.95% of this age group.

Ceratocysts of jaws constitute from 5.4% to 17.4% of all odontogenic cysts. In 7 - 9% process has multiple character (Raubenheimer, 1993). Keratocystic jaws occur equally in both sexes - 50.8% in men and 49.2% women.

The most frequent localization of jaws ceratocysts is angle and mandibular branch - 64.3%. Ceratocysts of upper jaw are found only in 6.55% of patients studied (N.V.Chernigivska, 2009).

CHAPTER III. CLASSIFICATION OF JAW CYSTS

Studying in the literature question of classification of jaw cysts, we, first of all, set a goal to find the best option of classification, considering primarily interests of practical dentistry.

One of the first who classified the cysts was Limberg - Lviv (1939). The author have divided them into:

1. Cysts around the tooth
 - around the crown
 - apical
2. Traumatic cysts.
3. Cholesteatomas.
4. Incisal canal cysts.

In the classification of jaw cysts by Evdokimov (1964) and Kolesov (1964) allocated two types of cysts:

1. Radicular (root around) cysts.
2. Follicular (around crowns) cysts.

All three classifications are very simplified. They did not cover a variety of jaw cysts. And most importantly, the authors consider cysts as odontogenic tumors, not as separate nosological unit.

Another very successful classification of odontogenic tumors is morphological, considered by Ermolaev (1964). Author all odontogenic tumors divides into three main groups: epithelial, connective tissue, and mixed. Each of these groups has its subgroups.

I. Odontogenous formations of epithelial nature.

1. Odontogenous cysts of inflammatory origin:

- Radicular;
- Containing the teeth;
- Paradental.

2. Odontogenous cysts, which is a defect of the epithelium that forms teeth:

- Primary;
- Follicular;
- Cysts of eruption;
- Gingival.

3. Adamantynomas.

4. Odontogenous cancer.

II. Odontogenous formations of connective tissue nature.

1. Odontogenous fibromas.

2. Cementomas.

3. Odontogenous sarcoma.

III. Odontogenous formations of mixed nature (epithelial and of connective tissue).

1. Soft odontoma.
2. Solid odontoma.

The author was first who separated jaw cysts as an independent nosological unit. Controversial point of classification is that the cyst containing tooth author belongs to a group of cysts of inflammatory of origin through the fact that developing on a removable occlusion, where, along with the beginnings of permanent teeth are roots of periodontical primary teeth.

Paradental cyst author also refers to the first group, because it is formed near the 38 and 48 tooth when their eruption is complicated, but it is sometimes appear in the area of other teeth, with no signs of inflammation, which assigns it to the second group. And the most important that the classification considers only odontogenic cysts without not odontogenic.

From foreign authors, in these years, the most successful is the classification of cysts by Ferenczy (1967). Author investigated cysts in embryo and pathological ways as well as in aspect X-ray.

Author separating the radicular cyst on the apical (if it develops near the apex), apical-lateral (if it is formed in part near the top, and partly on the side of the root), lateral (if it is formed due to the high lateral branch root canal) . Besides radicular cysts may be under periosteum (localized most part under the periosteum and soft tissues, and a small portion in the bone) and traumatic (resulting from the death of the pulp, which occurred due to injury of the tooth).

The author separates paradental cyst, which may be formed along of the root wall (lateral paradental cyst) or near its apex (apical paradental cyst).

If the cyst is formed by the pathological proliferation of dental sac, that lines with the epithelium, surrounding the crown of tooth, it is called a central (if it is based around the crown) or lateral (if it develops from the lateral side of the

crown).Cysts that formed before eruption of the tooth, the author calls follicular cysts. Primary cyst in classification is called a simple follicular cyst.

From not odontogenic cysts, the author identifies nasal-mouth, slit, front or alveolar middle, posterior or palate, nasolabial and spherical.

This classification is still successfully used by many doctors, although very different from our own classification

Sort all together cysts tried classification of jaw cysts WHO (1971). It is divided on odontogenic cysts and not odontogenic:

A. Evolutionary epithelial cysts:

1. Odontogenic cysts:

- a) primary cyst;
- b) gingival cyst;
- c) cyst of eruption;
- d) follicular cyst.

2. Not odontogenic cysts:

- a) nasal-palatal canal cyst;
- b) globulomaxillar cyst;
- c) nasolabial cyst.

B. Epithelial inflammatory cysts: root cysts.

In the classification selected forms of cysts, which are rare – gingival, eruption cyst, but not paradental cyst.

Subsequently, the WHO classification (1971), according to Sabo (2005), seems to have changed and headings presented below:

A. Evolutionary epithelial cysts

1. Odontogenic cysts:

- Perinatal cyst;
- Gingival cyst of adults;
- Primary cyst;
- Cyst of eruption;
- Follicular cyst;
- Lateral periodontal cyst;
- Ceratocyst.

2. Non-odontogenic cysts:

- Incisive canal cyst;
- Median palatine cyst;
- Globulamaxillacyst;
- Median mandibular cyst;
- Nasolabial cyst.

B. Odontogenic inflammatory origin cyst:

- Radicular cyst;
- Residual cyst;
- Paradental cyst.

After the changes in classification are presented almost all types of epithelial odontogenic cysts and not odontogenic, but unfortunately absent false not epithelial cysts.

More detail can be called morphological classification of tumors and tumor-like formations of the jaws in the development, of which participated the working group: I.I. Yermolaev, V.V. Panikarovskii, A.I. Paches, B.D. Kabakov, V.M.Bentsyanov and S.J. Balsevich (1975). Cysts of the jaws are divided into:

I. Epithelial cyst.

1. Odontogenic cysts:

- a) primary cyst;
- b) eruption of cyst;
- c) paradental cyst;
- d) gingival cyst;
- e) cyst that contains tooth;
- e) follicular cyst;
- i) root (radicular) cyst

2. Not odontogenic cysts:

- a) Incisive canal cyst (nasal-palatine);
- b) globulamaxillar (fisural) cyst;
- c) holoatoma .

II. Not epithelial bone cyst:

- a) anevryzmal cysts;

- b) traumatic cysts;
- c) hemorrhagic cysts.

The classification presented all types of cysts. According to the morphological parameters and tissue nature of jaw cysts are divided into subgroups of epithelial and not epithelial genesis. Some types of cysts of the jaws closest to the defects of structures that forming a tooth. At the same time together with morphological designations in terms of this classification, there are also purely anatomical topographically clinical sign or representations that is not fully comply with the concept of histological classification, but at the same time simplifies its application and gives it meaning.

Today, the educational literature on surgical dentistry, classification of jaw cysts regarded in abbreviated form, or without reference to one's authorship and literary sources, or refer to the International histological classification.

Thus, among the modern classifications, we have found in the literature of recent years is the classification of Soloviev et al. (2004). Perhaps that this division of cysts on nosological units owned by the authors, since the reference to someone's authorship or literary source is missing.

Authors on the morphology and pathogenesis and localization distinguish the following types of odontogenic cysts:

I. Cysts that developing from the enamel organ or follicle.

1. Follicular cysts:

- Dental - odontogenic cyst surrounding the tooth that does not cut through (usually containing the crown of normally formed tooth);

- Eruption cyst - follicular cyst located around the crown, which erupt in children.

2. Gingival cyst - odontogenic cyst attached or free gums as a small swelling, which sometimes reminds mukotsel.

3. Primordial cyst - rather rare type of odontogenic cyst that has developed as a result of cystic degeneration or destruction of stellate epithelial of the enamel organ to calcification of enamel and dentin.

II. Cysts that developing from epithelial lamina that forms tooth (Malyasse islands) - radicular (root around) cysts.

1. Apical cyst - periodontal cyst that covers the top of the tooth root. This type of cyst is the result of necrosis of the pulp of the tooth with caries, tooth injury.

2. Lateral periodontal cyst, covers the lateral surface of the tooth root (usually found in the mandibular premolars), which is in the process of eruption.

3. The residual cyst that stayed or emerged after tooth extraction.

III. Cysts that developing from the enamel organ or Malyasse islands: odontogenic keratocyst - cyst containing keratin mass.

In the classification entered residual cyst, which many authors count as a consequence radicular cyst. A cyst that contains tooth united with follicular cyst and paradental belongs to the group of radicular cysts. Unfortunately, the classification is only present odontogenic cysts, not odontogenic cysts authors are not considered.

Timofeev (2010) divides cysts of the jaws as follows:

Depending on the histological structure:

- true;

- false.

Depending on the etiology:

- inborn;

- acquired.

Odontogenic origin:

- Radicular (apical, lateral, subperiosteal, residual)

- Follicular;

- Paradental;

- Epidermoid.

Not odontogenic origin:

- Nasal, palatine (incisive canal);

- globulo-maxillary (spherical-maxillary);

- Alveolar nasal (nasal-labial).

The classification is missing ceratocyst (primary cyst) cyst containing tooth and no nosological units of false cysts.

Not without its flaws and International histological classification of tumors MHKO (Malanchuk, Kopchak, 2008). The classification includes the following types of cysts:

A. Not epithelial cysts:

- anevrizmal;
- simple bone cyst.

B. Epithelial cyst of the evolutionary origin (malformation of the jaws and teeth rudiments).

Odontogenic:

- Follicular;
- Ceratocyst (primary);
- Cyst of eruption;
- Gingival.

Not odontogenic

- cyst of incisive canal;
- globulo-maxillar;
- pairalveolar (nasal-labial).

B. Epithelial cyst of inflammatory origin - radicular cysts:

- from milk tooth;
- from permanent tooth.

Analyzing the a large amount of literature, we concluded that there is no consensus on the classification of jaw cysts, although this problem was engaged a great number of authors. In our view, still the most appropriate classification of jaw cysts, today, is a classification of cysts, proposed a group of authors: I.I. Ermolaeva, V.V. Panikarovskii A.I Paches, B.D. Kabakov, V.M. Bentsyanova and S.J. Balsevich (1975).

Classification in the first place, and takes into consideration the interests of practical dentistry on the one hand and on the other hand, to some extent meets the needs of scientific medicine.

CHAPTER IV. ETHIOPATHOGENESIS, MECHANISM OF FORMATION AND CLINICAL SYMPTOMS OF DIFFERENT TYPES OF CYSTS.

RADICULAR (APICAL, BASAL, ROOT) CYST

Today the mechanism of formation cysts of inflammatory origin is associated with epithelial elements in the apical areas.

However, the origin of these inclusions is interpreted differently.

Astakhov et al. (1907) suggest that cysts forms from the remnants of Malyasse embryonic epithelial cells.

Kozyrev (1954) believes that Malyasse-Astakhov cells is nothing more than a endothelial cells of the vascular wall, that accidentally caught in the cross-section histological preparation.

Schuster (1908), Lukomsky (1927) argue that the epithelial cells in periodontal and bone are the result of growth and penetration into bone of deepest layers of the epithelium of the gums.

Gravitch (1956) considers the possibility of germination gums epithelium in apical pockets through the fistula canal.

Petrova (1972) presented experimental evidence of the possibility of metaplasia of the epithelial cells from the granulation tissue that develops due to chronic periodontitis.

Without the main thought on the mechanisms of origin of epithelial inclusions in the thickness of the bone, the majority of authors, however, solidary that cysts formation is influenced by the irritant action of chronic inflammation in the periodontium.

The mechanism of cyst formation is as follows:

1. Under the influence of mechanical or chemical irritant in periodont appears the inflammation.
2. Inflammation effect on epithelial cells in periodont that reproduce, forming a cavity. The first line of defense in the periapical area is the formation of granulomas. Granuloma - a highly vascularized tissue that contains infiltration of immunological cells such as lymphocytes, macrophages, plasma cells, and so on.
3. The cavity is filling with transudate, which creates pressure on the bone and increase the cavity.
4. Granuloma develops into a cystgranulome into the bone.
5. The cyst is gradually increasing.

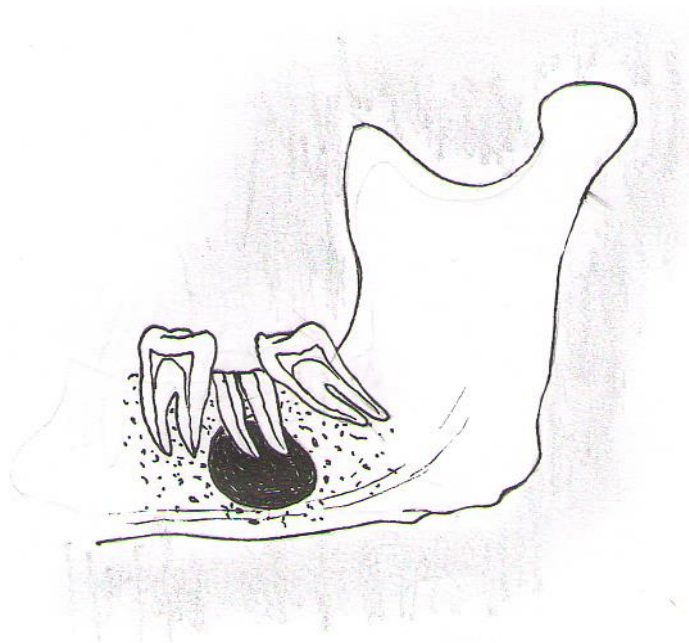


Figure 2.

Schematic image of the radicular cyst

The confirmation of the theory of the pathogenesis of inflammatory radicular cysts is researching of Bernadska and Kutcenko (1986). After studying in 40 patients fibrinolytic activity of the cyst membrane and adjacent bone tissue, they found that for chronic granulomatous periodontitis is characterized by increasing of fibrinolytic ability of the cyst membrane in 4.7 times while increasing at 26% of fibrinolytic activity of the adjacent bone. Based on these results the authors concluded that a significant role of fibrinolytic potential of tissue in the lesion focus in the pathogenesis of odontogenic cysts of the jaws. The dynamics of changes in fibrinolytic ability membrane and the surrounding bone tissue has prognostic value and opens the possibility of using of the pathogenetic treatment.

The clinical picture is determined by the size of the cyst, the presence or absence of complications such as suppuration or pathological fracture of the jaw.

The initial stage of development of the cyst is asymptomatic.

Complaints of patients with radicular cysts may be absent, and its detection - is often accidental finding in radiography of teeth during their treatment. In other cases, complaints are reduced to the presence of the fistula or deformation on alveolar process.

Pressing of neurovascular bundle on mandible can cause a a symptom of Vincent (paresthesia of the lower lip). Germination of cyst in the lower nasal passage is accompanied by difficulty in nasal breathing.

In compiling the history of patients with around the root odontogenic cysts usually indicate on an earlier endodontic treatment "causal" tooth and then marked reduction of pain. Some notes periodic exacerbations of the disease, which took place after the intraoral incision.

Typically, the diameter of the cysts varies from the size of a pea to the size of chicken eggs (0.5 to 5 cm).

The development and growth of cysts depends on the anatomic region in which it originated.

If the cyst is localized in the region lower incisors, canines and premolars, its development usually occurs in the vestibular direction, so that there are no significant external cortical layer of the bone of the jaw.

Developing in the area of the lower molars, where a layer of cortical bone material is almost the same on both sides, the cyst usually pushes them evenly, giving the body of the mandible specific shape. In this case, the cyst grows as back and forth, pressing on the spongy substance, which leads to its atrophy. Pushing the mandibular canal down the cyst grows together with neurovascular bundle, which is located in the channel.

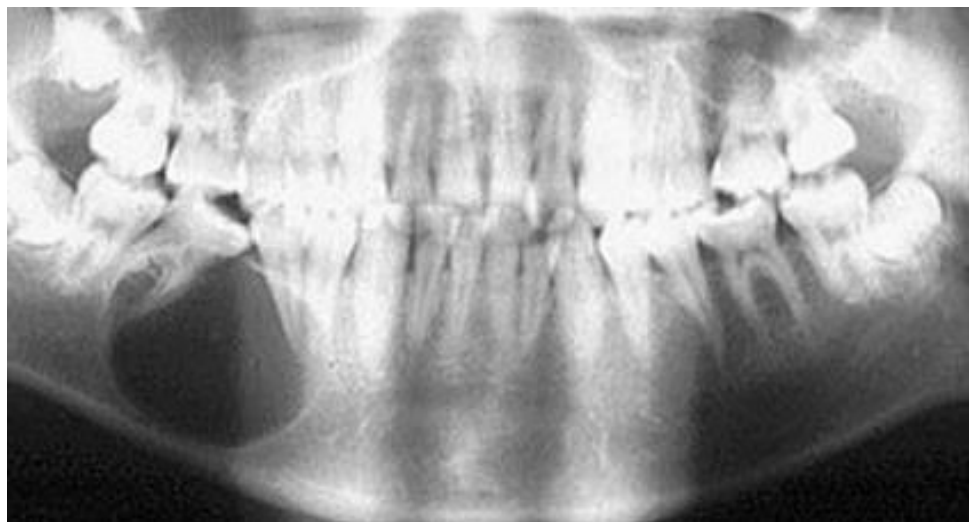

Figure 3.

The radicular cyst of the mandible on the right from 45 causative tooth is on panoramic radiograph. Roots of surrounding teeth diverge.

If there was a cyst near the root of the lower wisdom tooth, it is developing in the upper posterior direction, destroying the branch and the angle of jaw.

Cyst that develops on the upper teeth (except the lateral incisors) progresses in the vestibular direction. As for cysts, beginning from the second incisors, roots of which are tilted toward the palate, they gradually destroy the bone from the palate.

If maxillary bone is pneumatized well and in it grew roots of molars, the cystic membrane grows in the maxillary sinus, pushing her up in the middle. This gradually leads to atrophy of the bone within a few teeth and deforms the upper jaw.

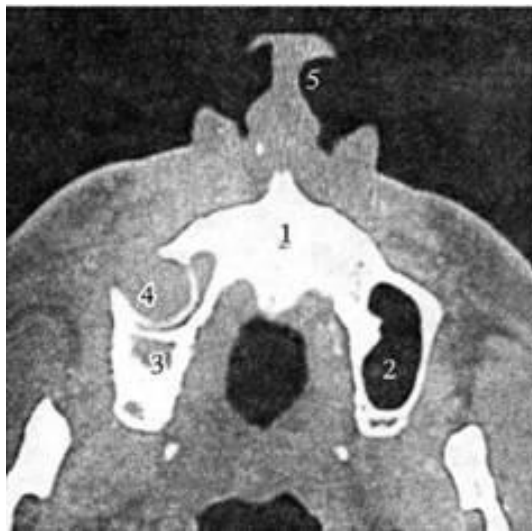

Figure 4.

Radicular cyst of the right maxilla from 15 tooth deforms wall of the maxillary sinus (computer tomography)

An objective examination determined by changing the configuration of the alveolar process or the body of jaw. In many ways it dependent on their location. Often people asymmetry may occur when the presence of cysts in the frontal division of the upper and lower jaws. During germination of cysts developing from central incisors of the upper jaw to the side of the nasal cavity,

can be found Gerber roller - protrusion of the lower nasal passagethat is revealed at rhinoscopy.

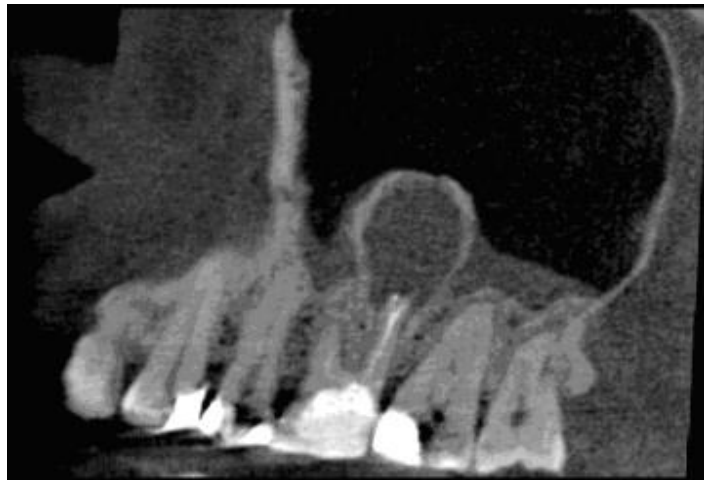


Figure 5.

Transversal section of maxilla at projection of palatal channel of 26 tooth.
Palatal and distal buccal roots are if cyst cavity.

At survey of the oral cavity is defined roundish protrusion of the anterior wall of the jaw in the transitional fold. The mucous membrane color is not changed.

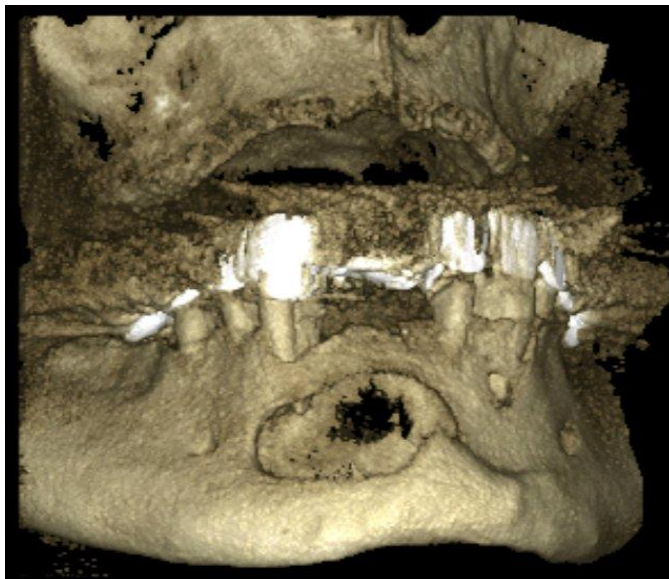


Figure 6.

Radicular cyst of the mandible from 33 till 43 teeth.

Palpation of deformation is painless, protrusion boundaries are clear. With the development of cysts from the tooth root, which facing to the palate (lateral incisor, second premolar, first molar), observed thinning and sometimes resorption of palatal plate of the upper jaw. On the palate is palpated restricted semicircular protrusion.

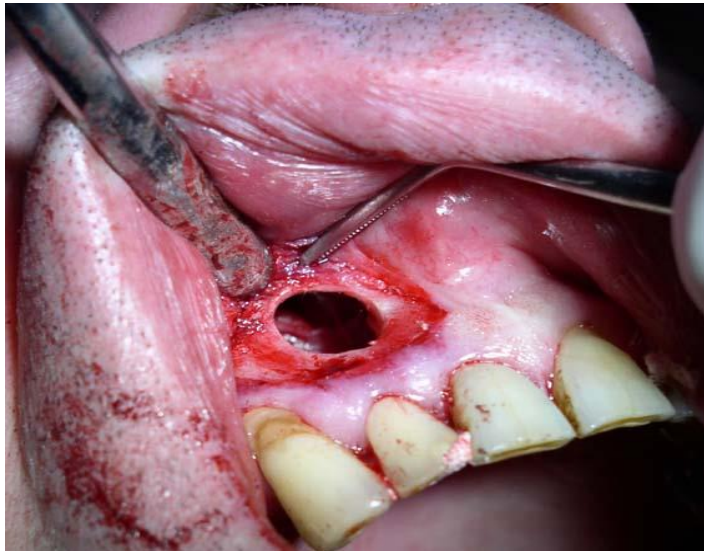

Figure 7.

Radicular cyst of the right maxilla.

Crown of the "cause" tooth changed in the color or destroyed by caries process. Probing of root canal tooth is painless. Percussion of tooth can cause discomfort, but usually is painless.

During the treatment of the tooth pulps extractor can get into outside apex of the root and through the root canal released clear, straw-yellow liquid. During the removing of the tooth this fluid released through the hole. Applying infraorbital probe for sensing, the doctor enters the cavity of the cyst.

DENTIGEROUS CYST

Dentigerous cyst – is a cyst from temporary tooth, in which cavity is the germ of the permanent tooth or a tooth that has emerged. Many authors refer to this cyst follicular cyst (Lapydus, 1928; Albanskaya, 1936 Agapov, 1953 Bernadskyy, 1983).

The mechanism of its occurrence at first is no different from the pathogenesis of radicular cysts. But then with a gradual increase of the cyst membrane covers and removes the germ of the permanent tooth, and the full inclusion of permanent tooth germ into the bone resulting in his death. It's also possible the including of impacted tooth to the cystic cavity from the cyst of permanent tooth.

Dentigerouscysts are only at children of deciduous teeth and no distal that V temporary tooth. It is often diagnosed between the ages of 7-10 years.

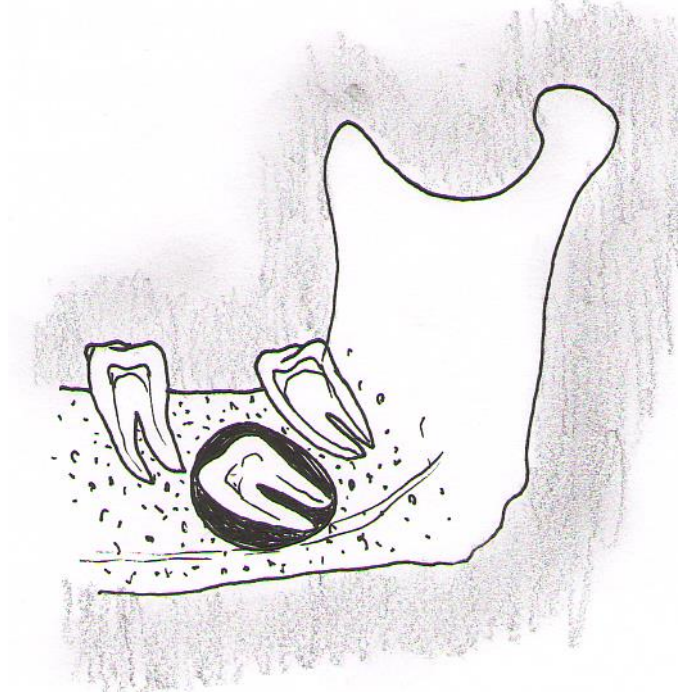

Figure 8.

Schematic image of the dentigerous cyst

The clinical course is the same as radicular and follicular cysts.

At the beginning of the formation of dentigerous cysts there are no complaints.

The deformation of the alveolar process of the jaw and body is gradual, painless. Palpation reveals a deformed jaw in tumor areas of thick consistency. When large amounts of cyst wall becomes thin and when you click on it flexes (symptom Runge-Dupuitren). The mucous membrane near the cyst is not changed in color.

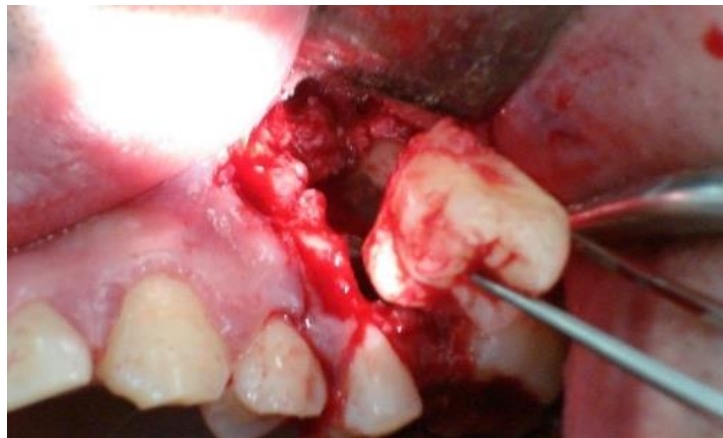

Figure 9.

Dentigerous cyst of the left maxilla.

Radiologically it is determined bone thinning smooth with clear boundaries. Permanent tooth follicle or impacted formed tooth is visible in its cavity.

Macroscopically it is determined a single-chamber cavity lining by membrane and containing yellowish transparent liquid with crystals of cholesterol.

Microscopically the cyst membrane is represented with a thin layer of connective tissue covered with stratified by squamous epithelium, 2-3 cells thick.

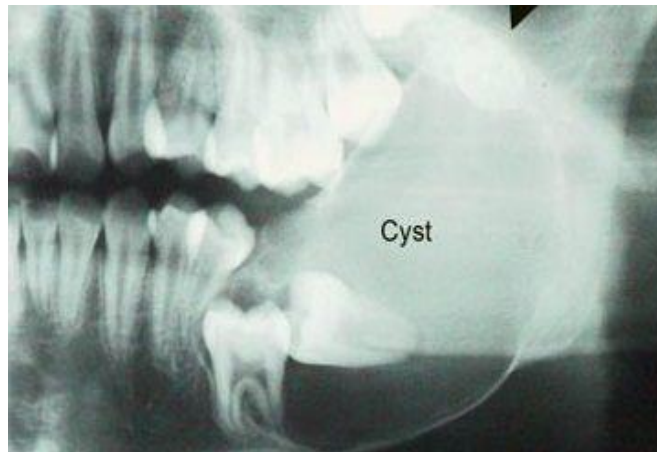

Figure 10.

Dentigerous *cyst* in the area of body and angle of the mandible is on radiograph.

Dentigerous cyst must be differentiated from ameloblastoma and primary odontogenic cyst.

Treatment consists of cystectomy with removal of impacted tooth or two-stage operation.

In some cases, especially in cysts that suppurate, it uses the method cystotomy.

For children often shown holding plastic surgery cystotomy because it enables the final development, movement and proper eruption of impacted tooth around which there was a cyst.

PARADENTAL (RETROMOLAR) CYST

Paradental cyst is an inflammatory cyst that develops on the side of the tooth root. Paradental cysts are usually localized in the angle of the mandible, immediately behind the lower wisdom tooth. The majority of authors associate its origin with chronic inflammation in paradental tissue that arises from the complicated eruption of wisdom teeth. This results to cystic conversion of inflammatory growths surface epithelium under the "hood" of the soft tissues of the erupted teeth.

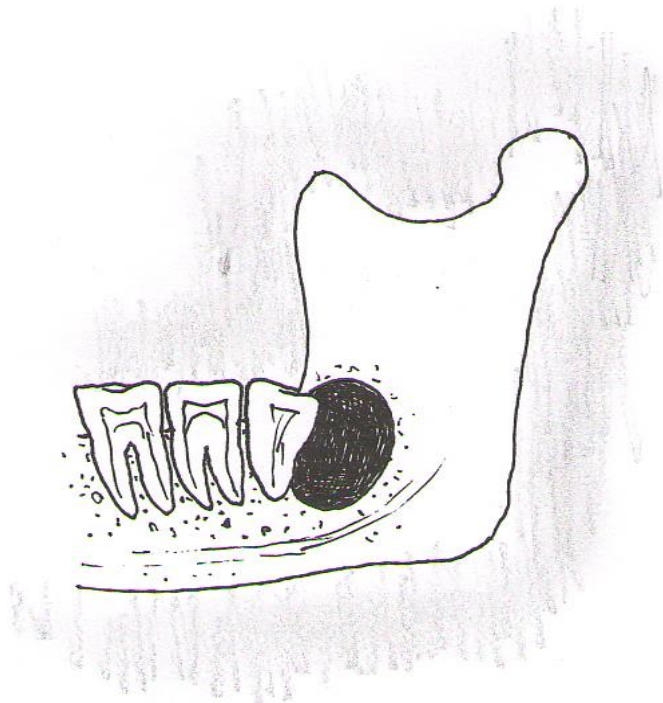


Figure 11.

Schematic image of the paradental cyst

Confirmation of this is that histologically paradental cyst has no different with radicular cysts.

However, in clinical and X-ray examination of a large number of people with the abnormal eruption of wisdom teeth Kanopkene (1966) never noticed that they have paradental cysts.

Clinical picture of paradental cyst has no characteristic features, except that it develops in the area of the lower wisdom tooth that has fully or partly erupted. Asymptomatic cyst grows so detect it in early stages is extremely difficult. At growth of cyst it appears as a small, limited and painless swelling in the area of the wisdom tooth.

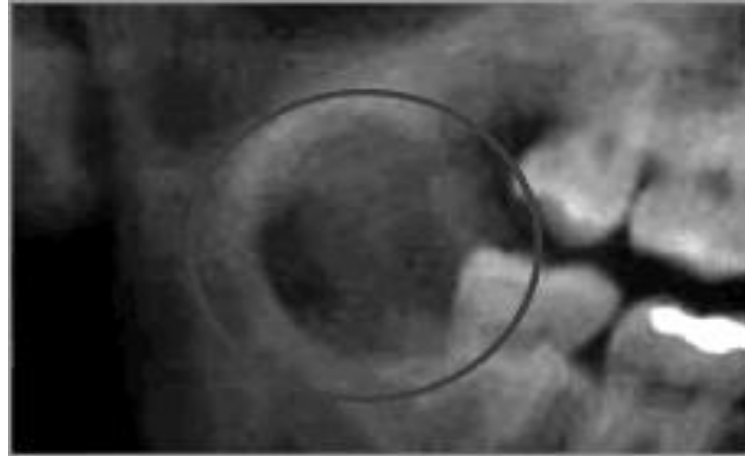


Figure 12.

Paradental cyst of the mandible angle is on radiograph.

Paradental cyst is diagnosed confirmed by X-ray examination.

Radiologically it defined area of dilution ovoid form that is distal to the impacted wisdom tooth.

Diagnosis is complicated when paradental cyst is residual.

Differential diagnosis is made with the other jaw cysts and cystic forms of tumors of the jaw bones.

Treatment – is remove of impacted tooth, cystectomy.

PRIMARY (KERATOCYST, PRIMORDIAL) CYST

Primary cyst arising from the remnants of tooth-constitutive plate as malformation, and is localized in the area of the angle and branches of the mandible. In this group of odontogenic cystic there is no direct anatomical and topographical relationship of the erupted teeth or dental germs. The nature of the microscopic structure and some clinical-radiological features of cysts make it possible to consider them as a malformation of odontogenic epithelium of supernumerary germ, because epithelium and other tissues of the tooth germ are spent on developing the cyst. This cyst has a thin fibrous wall; its inner surface is lined by squamous epithelium. As a result of parakeratosis its contents reminds cholesteatoma, and odontogenic epithelium is exhibited at the walls. Keratocysts can be mono-and multi-chamber; multiple cysts often multi-chamber. However, they are combined with other development defect and often recur. In the cavity of the cyst tooth is absent.

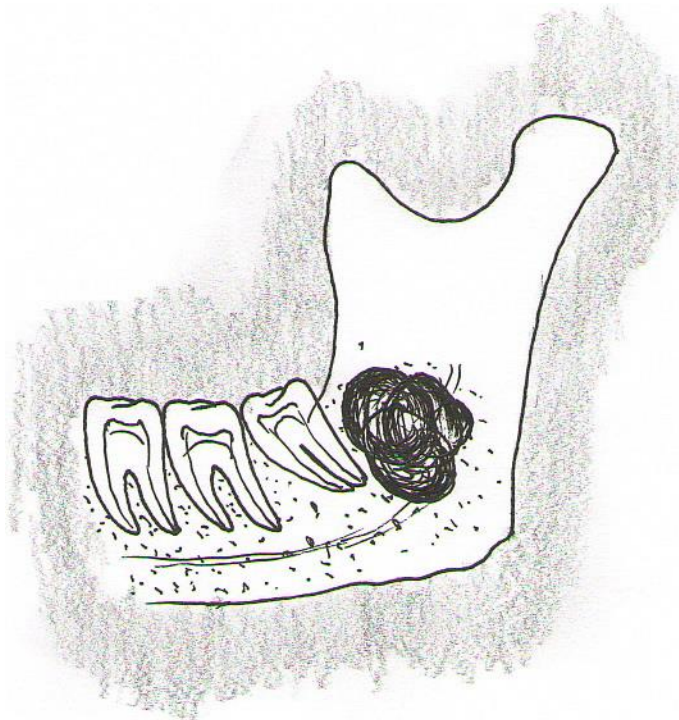


Figure 13.

Schematic image of the primary cyst

Ermolaev (1964) first identified it with the group of follicular cysts. McDonald et al (2003) divided keratocyst into two separate types:

1) primordial cyst - has fibrous wall that are sent by stratified squamous odontogenic non-keratinizing epithelium;

2) keratocyst - has homogeneous thin epithelial lining of 3-5 layers of cells with wrinkled surface, often with the presence of keratinized scales in the lumen of the cyst surrounded by a layer of basal cells.

This separation is made according to the histopathological study, but clinically and radiologically they look exactly the same. This separation has no effect to methods of treating (McDonald, Avery, 2003).

Clinically cyst begins quietly for a long time and is not shown because, apply to body, angle and branch of jaw and did not lead to severe deformity of the bone. Therefore, it is determined only when it reaches a large size.

Usually the complaints appear when the cyst is quite large. Patients indicate a jaw deformity and discomfort when chewing on the mobility of several teeth. At suppuration of cysts complaints coincide with complaints at inflammatory diseases of the jaws.

Slight painless bulging area in the jaws in the area of molars is revealed on examination. Some patients find bone due to the accession of inflammation, sometimes found incidentally during radiological examination about other diseases.

X-ray picture is characterized by a large dilution of bone with clear polycyclic contours; with irregular bone resorption creates an impression of multi-chamber. Often coronary and condylar processes are in process. Cortical plate becomes thinner and sometimes can be absent in some areas.

Final diagnosis can be set, based on a histological examination of biopsy material.

During the puncture is sometimes possible to obtain a dense mass of dirty-gray color with an unpleasant odor.

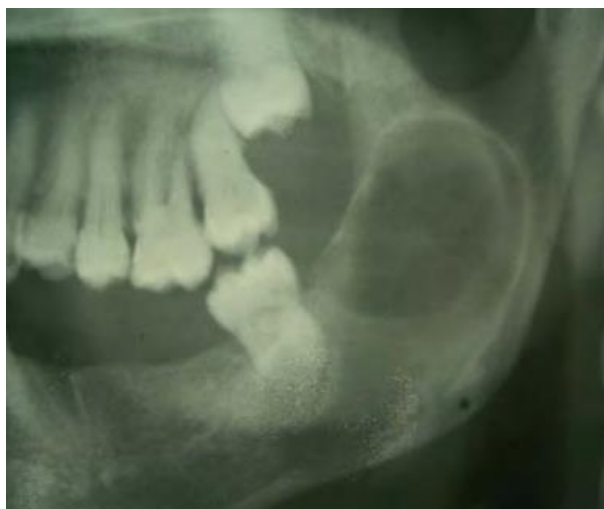

Figure 14.

Primary cyst of the angle and ramous of mandible is on radiograph.

In a biopsy, which can appear simultaneously and the first stage of surgical treatment can be determined macroscopically cavity coated protrusion is unable to bone mass and containing keratin. Histological examination of surgical specimens determined connective tissue thin capsule, which sent by stratified squamous epithelium with pronounced symptoms of keratinization. In epithelial lining ob keratocyst more mitosis are present, than in the epithelial layer of radicular cysts (Main, 1970; Toller, 1971).

Odontogenic keratocyst of jaws – is a frequent phenotypic of expression of the syndrome Horlin-Goltz (polysystemic disease that transmitted by autosomal dominant type and caused by mutations in 8.3-cm interval of the 9th chromosome), where they are in 65-75% of cases, and is the first manifestation of this syndrome.

To establish the diagnosis of Horlin-Goltz syndrome, it is necessary to differentiate it from hyperparathyroidism, non-syndromal cysts of the jaws, osteoblastoclastoma. It should be differentiated from ameloblastoma. At last there is a pronounced swelling of the jaw.

Treatment of primary cyst must be radical. There is no consensus about treatment keratocyst. Methods range from cystotomy to resection of the jaw. This is due to the large variety of clinical variants of keratocyst, and with the possibility of recurrence.

Chernihovsky (2009) recommends at small size of keratocyst (within one or two teeth) to conduct cystectomy in one stage, with optional dynamic observation for 3-5 years. Two-stage treatment is optimal for keratocysts that located in the projection of more than 3 teeth. After the first stage, the restoration of cystic tissue at the second stage - remove residual membrane of keratocyst.

FOLLICULAR CYSTS

The question of the genesis of follicular cysts isn't insufficiently defined. According to most authors, follicular cysts are the result of malformations dental-formed epithelium (cyst-like degeneration of the follicle tissue). This, due to the fact that in close connection with the actual follicular cysts is always normal or rudimentary, or supernumerary tooth completely or partially finished developing. This tooth is located deep in the jaw that is always found one that has not erupted.

At the same time, some authors (Lapydus, 1928; Albanskaya, 1936 Agapov, 1953 Bernadskiy, 1983) think that follicular cysts arise from inflammation in the apex of the roots of milky teeth when inflammation is near permanent tooth follicle. At the starting point of the process is disease of milky tooth, and the follicles of permanent teeth are captured in the process only then.

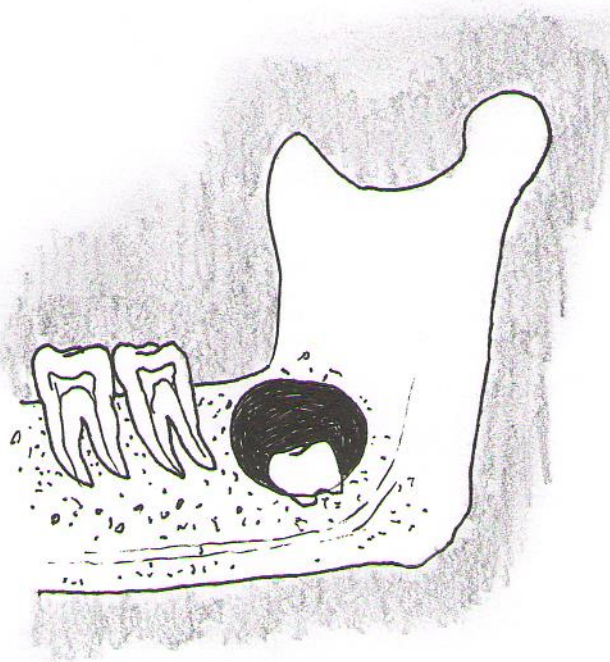


Figure 15.

Schematic image of the follicular cyst

The term "follicular cyst" should call the two groups of cysts.

The first group is characterized by signs of prolonged or intense chronic inflammation around the roots of milky, sometimes permanent erupted teeth. This inflammation is the cause of long-term chemical irritation of permanent tooth follicle.

Another group – is the properly follicular cyst, which is always the normal or supernumerary tooth that is fully or partially completed his formation and is located deep in the jaw.

The clinical picture of follicular cysts.

Simanovsky (1964) believes that follicular cysts are developed quite a long time, and the clinical course of this disease can be seen some stages.

I stage – is latent development of follicular cysts with absence of clinical symptoms. On examination it is revealed no permanent or of presents of milky tooth (radiography), which was delayed by the terms of change.

II stage – is the appearance of deformation of the alveolar process of the jaw or body through dense painless swelling. The duration of this stage is from several months to several years. It is in this stage may be a bone infection.

Follicular cysts are found much more frequently in children and adolescence. In adults, they sometimes can be diagnosed in the third decade of life.

Follicular cysts are localized usually near the third molar on the lower jaw, canines and third molar on the upper jaw. Sometimes follicular cysts may be located at the lower edge of the orbit, nose or maxillary sinus, completely filling it (Migunov, 1963).

Clinical features and diagnosis methods follicular cysts are often indistinguishable from those in radicular cyst and other cysts of the jaws.

At the beginning of the formation of follicular cysts patient has no complaints. When the cyst become large and there is a deformity of the jaw, the child or his parents point to it, as well as discomfort when chewing, the lack of proper tooth in dental arch, which in terms would have to erupt.

Local status at radicular or follicular cysts has common features. The deformation of the alveolar process of the jaw and body is gradual, painless. Palpation of deformed areas of jaw reveals neoplasme with thick consistency. When cyst has large size its wall (usually external) becomes thin and when you click on it bends, it is a symptom of Runge-Dupuitren - malleability cortical plate. The mucous membrane in the area of cyst is not changed in color.

According to the localization of the cyst thickening of the jaw occurs, often with deformation.

Radiologically bone thinning with clear smooth outside monocyst type and presence of impacted tooth which crown is turned into a cavity or cyst or adjacent to the wall are determined.

Also, at follicular cysts in its cavity on chest radiograph permanent tooth follicle may be visible.

Sometimes it can be two-chamber follicular cyst on radiograph; the cyst is divided by a partition into two cavities, each of which can sometimes be formed or rudimentary tooth.

Nykohosova (1973) observed follicular cyst, which occupied the body of the mandible from 36 to 46 teeth with the presence inside of four teeth in combination with 23 impacted teeth deep in the alveolar process of the cyst.

The composition of the liquid contents is the same in radicular and follicular cysts.

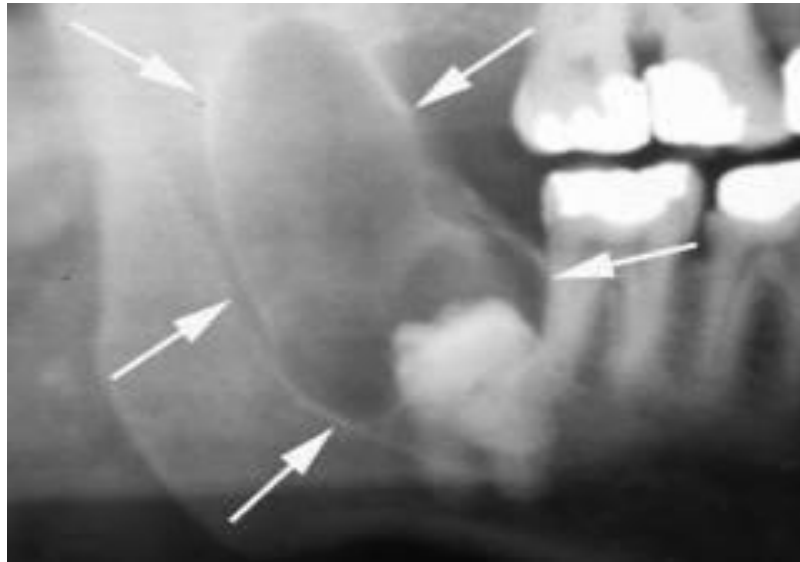


Figure 16

Follicular cyst of the angle and ramous of mandible is on radiograph.

Clear yellow opalescent liquid, with a touch of cholesterol crystals is determined in the puncture. In infected cysts there is contained turbid fluid, with lots of white blood cells.

Follicular cysts must be differentiated from cancer and sarcoma, abscess, cystic form of adamantinoma (ameloblastoma) and radicular cyst.

First three diseases can be differentiated according to anamnesis (rapid development, pain, cachexia, fever, etc.) and physical examination (presence of cancerous decay, the presence of pus at the opening of the abscess, receiving blood during puncture sarcoma, etc.). The cystic form of adamantynomy is difficult to distinguish from follicular cysts. This is due to the large number of similar clinical signs that have both diseases. Definitive diagnosis can be placed only after the previous histopathological investigation.

Different clinical signs of radicular and follicular cysts are: in the first case - the existence of a "causal" tooth in the dental arch that is affected by

caries; it changed in color, percussion may be painful; the second - the absence of permanent teeth in alveolar arch.

Treatment of follicular cysts is surgical. Volume of surgery should be planned individually and depends on the nature of the cyst, its location, the presence of suppuration, prospects of impacted tooth eruption, and the size of the cyst stage, lesions of jaws and the possibility of reparative osteogenesis.

Usually cystectomy is used with removal of impacted tooth or two-step operation. In follicular cysts with inflammatory origin equally well be used as cystectomy and cystotomy.

Method of two-stage cystectomy may be the treatment in patients with large follicular cysts in the mandible. Thus sometimes advisable prophylactic to impose preoperatively in dentitions tires Vasiliev (to prevent pathological fracture of the mandible) or make and attach dento-alveolar tires (capitalist) plastic type Phrihoph or Weber.

Plastic cystotomy is used for children because it provides the possibility of a final development, movement and proper impacted tooth eruption that developed a cyst. To provide a place where could erupt tooth, sometimes resort to orthodontic treatment in the postoperative period (making tires, spacers between two adjacent teeth and so on).

In adult patients, when there is no certainty that a tooth that is on the bottom of the cyst to take their place in the alignment, it is better to remove.

Cystectomy is usually done in adults. To accelerate reparative processes in place operation it is recommended to fill the bone defect that formed in the jaw by osteoplastic materials.

Experienced staff of our clinic shows that in large cysts (more than 2 cm in diameter) possible to remove cystic membrane without complications if the operation was not preceded by suppuration of the cyst contents.

The upper jaws proposed above operation (connection cyst cavity with the nasal cavity by Herbert, the connection of oral cysts of the maxillary sinus without establishing a connection to the inferior course by Iackes) do not apply because they are less rational than the above methods.

ERUPTION CYST

The appearance of cysts is associated with tooth eruption. It is occurred in childhood, often formed cyst in children older than 10 years.

Microscopically, the cyst shell is sent by non-keratinizing multilayered squamous epithelium and filled with serous or hemorrhagic fluid. The presence of blood in the contents of the cyst gives it a bluish-gray color.

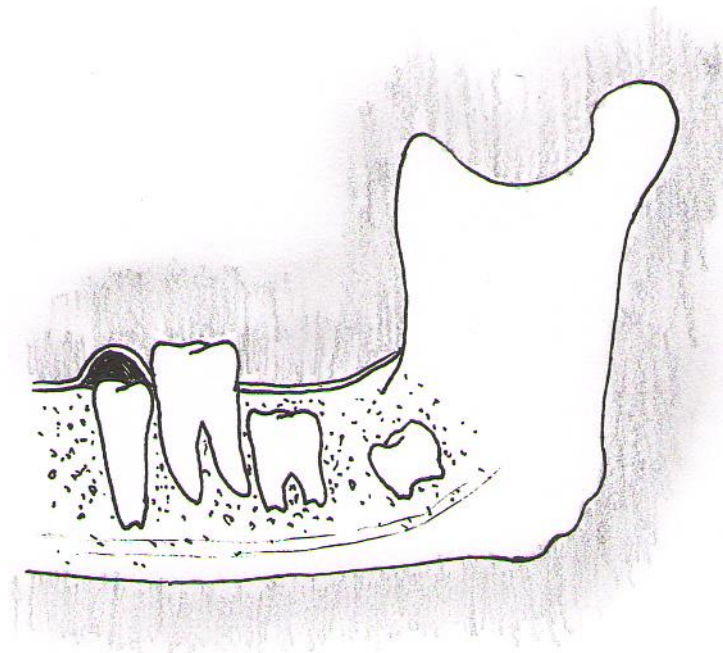


Figure 17.

Schematic image of the eruption cyst

The child complains on the presence of formation in alveolar process in place of the missing tooth (permanent or temporary).

Clinically: formation is rounded, soft, painless, and bluish in color, covered with intact mucosa. The tooth that is not erupted can be palpated.

Radiological destruction of bone is not defined.

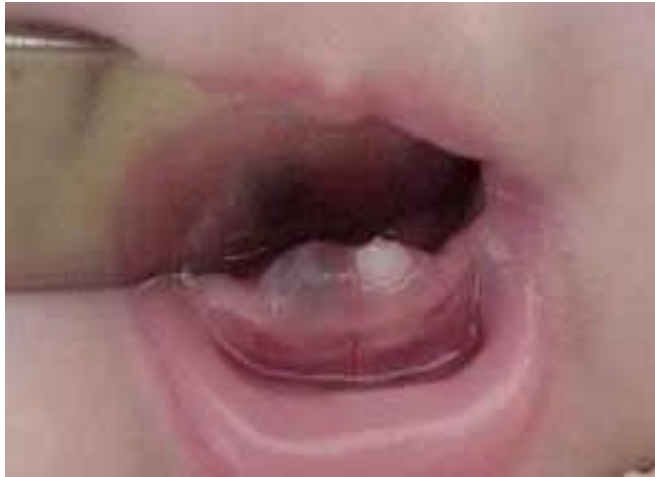

Figure 18.

The eruption cyst on the alveolar process of the mandible.

Surgical treatment is not required because the tooth that is erupted, breaking the wall of the cyst. However, when the eruption of the tooth is delay, it should do the incision (cystotomy) for drainage of the cyst that gives relief to patients.

GINGIVAL CYST

Gingival cyst ("Epstein pearl", "Serra iron") – is an extremely rare neoplasm with extracystous localization. The cyst develops in the gums of epithelial remnants of dental lamina.

It occurs mainly in children under the age of 5 months, in some cases, is found in adults. The mandible and maxilla are involved with the same frequency. Cyst grows slowly and expansively.

Objectively whitish, very dense spherical formation of the mucous membrane of the alveolar process of the jaws (in the field of gum ridge) or the midline palate (until his tongue), pearly shades are defined, they are asymptomatic.

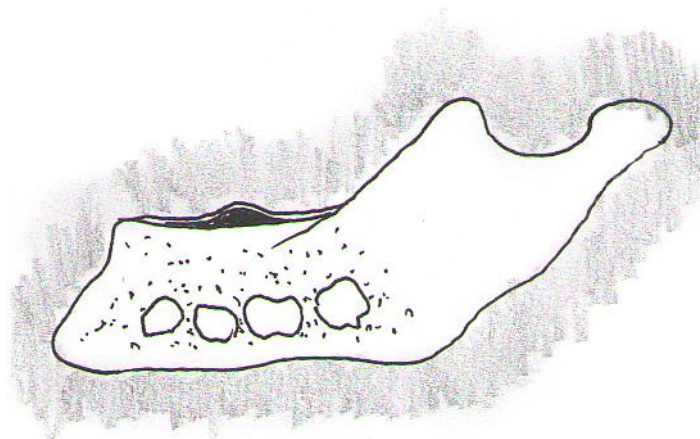


Figure 19.

Schematic image of the gingival cyst

Radiographic changes are not detected. Macroscopically gingival cyst appears as one or more small nodules with a diameter of 2 to 3 mm (rarely up to 1 cm) below the mucous membrane of the gums. In the context of the cavity may be absent, especially if lesions did not exceed 0.5 cm in diameter Real

relapses of tumors are rare, recurrence gingival cysts usually bind with multiple possible first character of the pathological process.

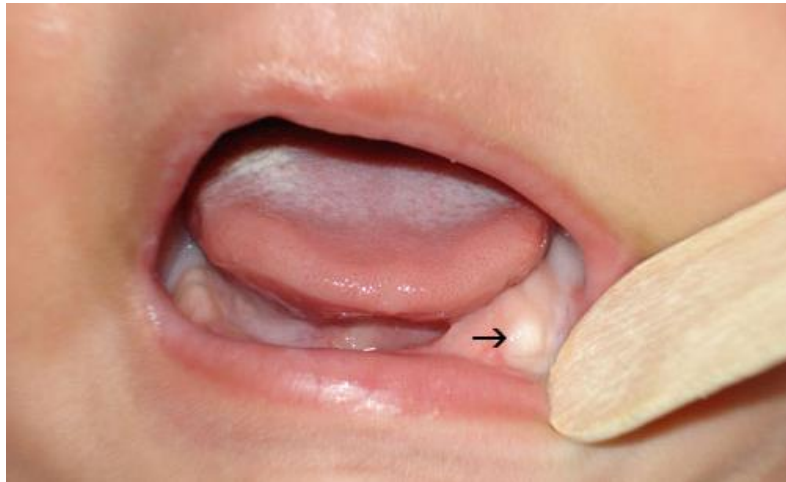

Figure 20.

The gingival cyst on the alveolar process of the mandible.

Under the microscope, it turns round cyst with a fibrous capsule, which is lined with stratified squamous, keratinizing epithelium. Sometimes the entire of cyst cavity is filled with thick horny masses.

Treatment is not required. They are prone to spontaneous disappearance.

RESIDUAL (REMAINING) CYST

Residual cyst occurs as a result of improper surgical removal of radicular cysts. These cysts remain after extraction of teeth because doctor didn't diagnosed it, or because the cystic membrane wasn't removed completely due cystectomy.

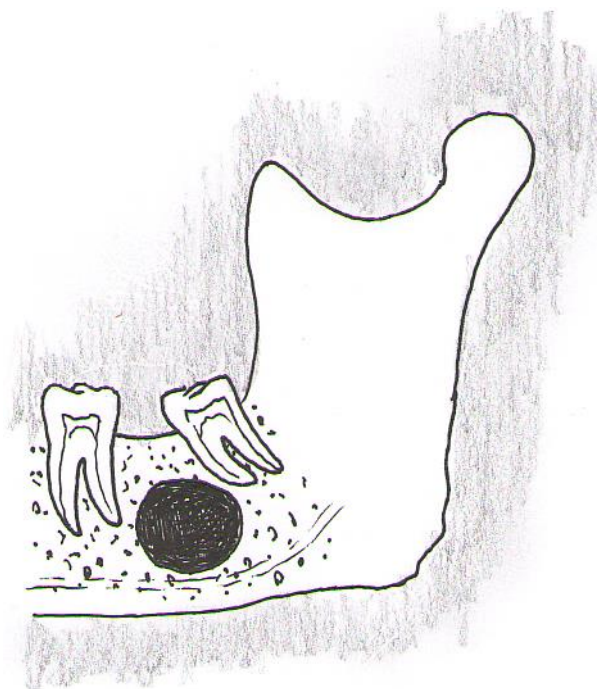


Figure 21.

Schematic image of the residual cyst

About 30% of radicular cysts are residual and remain after the removal or loss of teeth. On the origin of cysts in these cases indicate its localization close to the hole of the missing tooth (Ryabukhin, 1991).

Its clinical and histological features are identical to the radicular cyst.

These cysts gradually increase in size, deform the jaw. When they are supplicated become are clinically and roentgenographically visual.

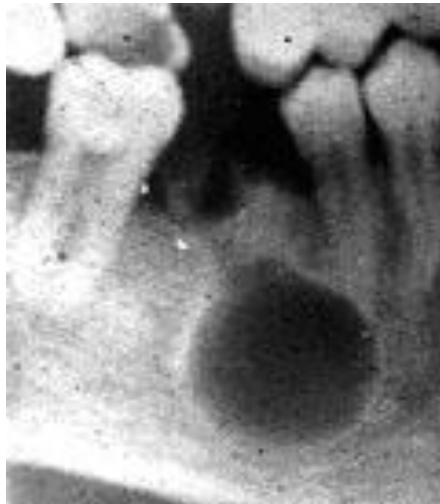

Figure 22.

Residual cyst of the body of mandible is on radiograph.

Radiologically this cyst appears as clearly delineated rounded enlightenment of bone, localized close to the extracted tooth socket.

CHOLESTEATOMA (EPIDERMAL CYSTS, "PEARLY TUMOR")

Cholesteatoma of jaw – is tumor-like formation, its capsule is lined by epidermis; its content looks like a mushy mass that includes horn weight and cholesterol crystals. 160-180 mg% cholesterol can be defined in punctate. This is due to the presence of cholesterol this tumor-like formation often has greasy or stearic shade that gave rise to its name (Muller, 1938).

Cholesteatomas of jaws can be two types:

- 1) like epidermal cyst that not contains the tooth;
- 2) like follicular cyst that surround the crown of the tooth (Kyandsky, 1938), which has not yet been erupted. Maxilla is most affected.

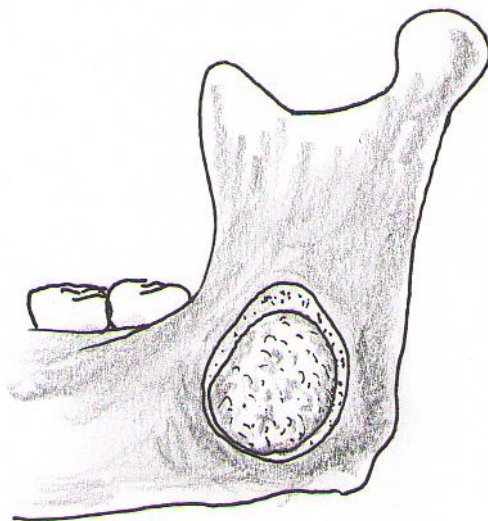


Figure 23.

Schematic image of the cholesteatoma

It is important to notice that pearl (pearl) shade mass is always inside of the cholesteatoma cavity, that has that disappears quickly after opening of cholesteatoma and shall enter greasy look. Pearl luster is caused by the presence

of concentric directed at each other particle disintegration of cell clusters of keratinized epithelium at cholesteatoma masses, therefore Cruvielhier (1829) called cholesteatoma as "pearly tumor".

The clinical picture of cholesteatoma of jaws is often generally similar to the clinical picture of jaw cysts, at least - cystic form of adamantinoma, which has a two-or three-chambered structure. Typically, an accurate diagnosis of cholesteatoma is established histologically or during surgery and is confirmed by histological examination of surgical specimens.

Treatment - Removal of cyst by cystectomy, less cystotomy.

CYST OF INCISIVE DUCT (NASAL-PALATAL)

Cyst of nasal-palatal duct (incisive foramen) is an epithelial non-odontogenic arises from epithelial remnants of nasal-palatal duct, that was formed during the embryonic period in nasal-palatal channel among the "cleft" cysts is often occurs. The incisive canal has two apertures in the nose and a palate. The channel can be double, like the letter "V" or part of a double, like the letter "Y".

According to the anatomical structure of the incisive canal cyst can be: central, unilateral and bilateral.

According to W. Petriell (1985) cysts can be found at 1% human.

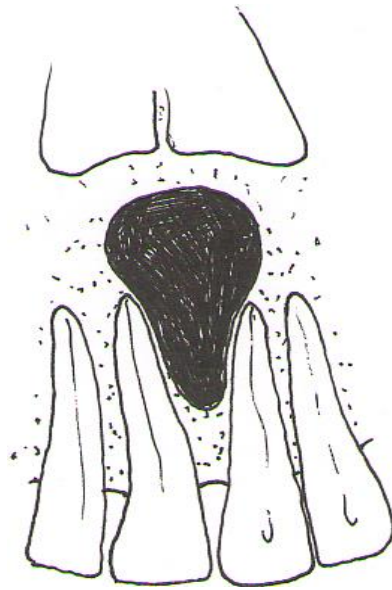


Figure 24.

Schematic image of the nasopalatine duct cyst

Microscopically the cyst membrane is lined by squamous epithelium bordering on oral stratified and blinking epithelium near the nose.

Cyst is located generally in the area of the alveolar arch near maxillary incisors, because that it could be diagnosed as radicular cyst. The cyst increases in size, and leads to resorption of palatal processes of the maxilla.

At examination of the oral cavity in the anterior part in the middle of the palate, round painless formation with clear boundaries is determined. "Recess" marked at palpation. Central incisor is usually intact, electroexcitability of pulp within normal limits. X-ray examination has crucial importance in the diagnosis of nasal-palatal cysts; it looks like round shape in the incisive foramen. Contours of periodontal gap of central incisors are preserved. Cysts can fester.

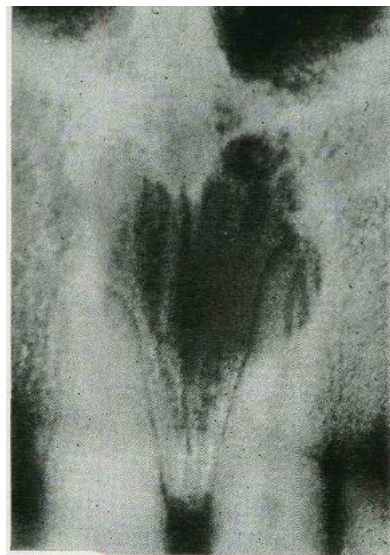


Figure 25.

Nasopalatine duct cyst is on radiograph.

At puncture, the cyst contents are yellowish liquid with crystals of cholesterol.

Surgical treatment (cystectomy). The operation is carried out with access at palatal surface of the alveolar arch of maxilla. With a significant detection of cysts on the eve of the mouth it is removed from the vestibular side of the alveolar arch of maxilla.

GLOBULE-MAXILLARY (INTERMAXILLAR) CYST

Globule-maxillary cyst of maxilla is localized on the line of locking of process of the upper jaw and the spherical portion of the medial nasal process. This cyst is seen in the anterior maxilla in the area between the lateral incisors and canine.

Globule-maxillary cyst is non odontogenic cyst of maxilla.

It is lined with flattened cylindrical, cubical epithelium. In the connective tissue sheath it may be signs of chronic inflammation.

Contains no cholesterol yellowish liquid (Roginskii, 1987).

Clinically it shows by wrong position of 2nd incisor or canine retention.

On radiographs it is usually determined by resorption of bone, its shape resembles an inverted pear with clear boundaries. Roots of 2nd incisor and canine can be draw apart, and the contours of periodontal gap are maintained.

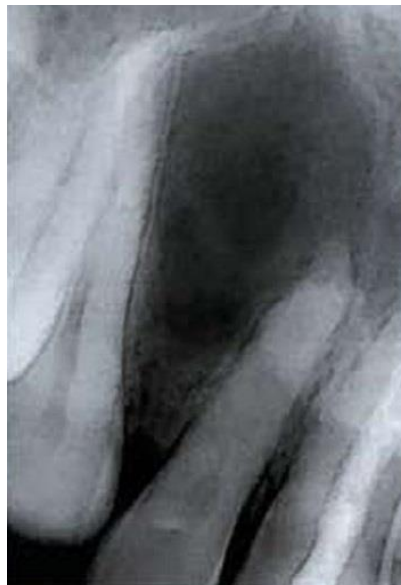

Figure 26.

The globule-maxillary cyst (the X-ray picture)

Globule-maxillary cyst is diagnosed hard. Often it can be mistakenly considered as follicular cyst of canine.

Treatment – is cystectomy. Cysts are removed by cystectomy access at vestibule of mouth.

NASOLABIAL (PARAALVEOLAR, NASAL-ALVEOLAR) CYST

Nasolabial cysts are rare, comprising about 0.3% of maxillary cysts. Nasolabial cyst is observed on alveolar process of the upper jaw, along with the base of nostrils. Histologically it is defined by cylindrical multilayered epithelium with goblet cells, squamous metaplasia.

Nasolabial cysts are found most often in female adults in the fourth to fifth decades of life. They commonly present as a localized painless swelling in the nasogenian sulcus and the nasal alar base.² Diagnostic tests include flexible nasofibrosocopy, computed tomography (CT) and magnetic resonance imaging (MRI). Treatment is surgical, usually cyst marsupialization or enucleation.^{2,4-10} The recurrence rate varies according to the technique, but it is generally low.

The aim of this paper was to assess a nasolabial cyst series to describe the clinical presentation, the diagnosis and the appropriate surgical techniques used in this disease.

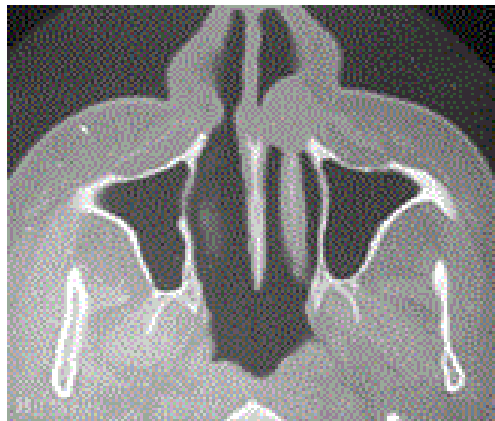


Figure 27.

The nasolabial cyst (the computed tomography)

Nasolabial cyst may develop from embryonic epithelial islands along the line of locking of maxilla process, lateral nasal process, and the spherical part of

the middle nasal bone. It is formed in the wings of the nose in the soft tissues, outside of the alveola during the transitional mucosa folds and lip tissue. With the expansive growth of the alveolar process on the part of the cheek or location of the lateral incisor, it can cause shallow depressions.

Clinically rounded formation, with clear boundaries is defined under wings of the nose, elastic consistency, movable, painless, skin, mucous membranes and bones are not fused.

Radiological nasolabial cyst is not defined; it can be detected only after introduction of contrast material into it.

Content of cysts is yellowish opalescent liquid.

Treatment – is cystectomy. These cysts are removed by cystectomy access vestibule of mouth.

ANEURISMAL CYST

Aneurismal bone cysts are non-epithelial cysts. They are usually in the area of intact teeth on the lower jaw in prepuberty and puberty age (Roginskiy, 1987).

The name "aneurismal" cyst means only one of the later symptoms of this disease - deformation ("inflation") of the mandible.

Aneurismal cysts were previously considered to osteoblastoclastomas.

According to some authors, the formation of bone cyst is the result of changes of giant-cell tumors (Elmslie, 1931, and others.) and can be a process of self-treatment of giant-cell tumors (Rusak, 1952; Geschickter, Copeland, 1949, et al.). Others believe that bone cyst is cystic variant or cystic phase of osteoblastoclastoma (Volkov, 1985).

In 1942, Jaffe and Lichtenstein identified aneurismal bone as an independent form of injury. By the time it was described under the names "giant-cell atypical or subperiosteal tumor", "ossifying hemangioma", "aneurismal giant-cell tumor". The term "aneurismal" describes the appearance of the bone ("inflation" in the area of lesions) and does not foresee the aneurysm itself. Jaffe argues bold of aneurismal cyst as follows.

Aneurismal cyst is a benign cystic lesion of bone, composed of blood-filled spaces separated by connective tissue septa containing fibroblasts, osteoclast-type giant cells and reactive woven bone. Fifty percent of aneurismal cysts arise in the long bones and 20% in the vertebral column. It accounts for 1.5% of the nonodontogenic, nonepithelial cysts of the mandible. It is found more frequently in the mandible than the maxilla (3:1) with preponderance for the body, ramus and angle of the mandible. It affects young persons under 20 years of age with no gender predilection.

Aneurismal cyst can be classified into three types. Conventional or vascular type (95%) manifests as a rapidly growing, expansive, destructive lesion causing cortical perforation and soft tissue invasion. The solid type (5%) may present as a small asymptomatic lesion first noticed as radiolucency on a routine radiograph or as a small swelling. A third form or mixed variant demonstrates features of both the vascular and solid types. It may be a transitory phase of the lesion because sudden activation or rapid enlargement of stable lesions has been reported.

Unlike giant cell tumor aneurismal bone cyst is not pulsing. Thus, it can't be equated with a pulsating giant tumor. In the long tubular bones is localized at the end of diaphysis and doesn't capture epiphysis. However, all these differences, especially for the jaw bone can't provide essential.

Neither one of a significant number of observations failed to detect ripples in the jaw bones of giant tumor and spread it on the condylar process. The diagnosis of this form of disease depends on the views of particular author (subperiosteal giant cell tumor, hemangioma, bone cyst, aneurismal bone cyst) (Vinogradov, 1973).

Clinically, at the beginning aneurismal cyst is asymptomatic. The first signs of the disease in almost half of patients are complaints of a toothache. In the other half of patients tumors are detected incidentally during radiography, which make in order to identify other pathology.

Deformation of the jaw in a spindle-shaped swelling of the bone is pronounced at palpation of pathological fireside. In most cases, some parts of the tumor are pliable at pressed. Thinned bone that covers the tumor has smooth, prominent, dome-like shape.

Aneurismal bone cysts are benign formations. Spontaneous cure of aneurismal bone cysts of jaw is not happened.

Radiological cyst is manifested as pockets of enlightenment in the jaw bone round or oval form, sometimes with more or less pronounced "porosity". Painting the bone defect is homogeneous and reminds odontogenic cyst or ameloblastoma of jaw. The radiological features of aneurismal cyst in the jaws are quite conflicting; the bone is expanded, appears cystic resembling a honeycomb or soap bubble and is eccentrically ballooned. There may be destruction or perforation of the cortex and a periosteal reaction may be evident. It may appear radiolucent, radiopaque or mixed. In our case, a unilocular radiolucency causing expansion of the cortical plates and thinning of the lower border of the mandible with root resorption of the involved teeth was present. The diagnosis based on radiographic appearance is impossible because there are other lesions having similar radiographic appearance, such as ameloblastoma, myxoma, central giant cell granuloma, odontogenic cysts or central hemangiomas of the bone.

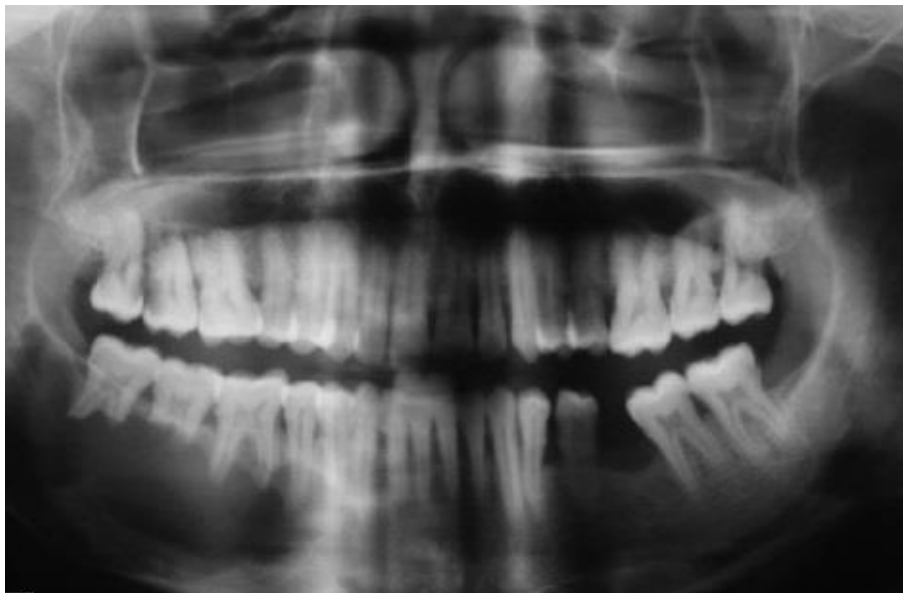


Figure 28.

The aneurismal cyst (orthopantomography)

Macroscopically single-chamber cyst with smooth walls is determined. The inner lining of cyst is smooth, shiny, sometimes with irregular appendages soft, brown tissue and blood clots. Cyst contains serous or blood fluid. Cortical layer in the cyst is thinned.

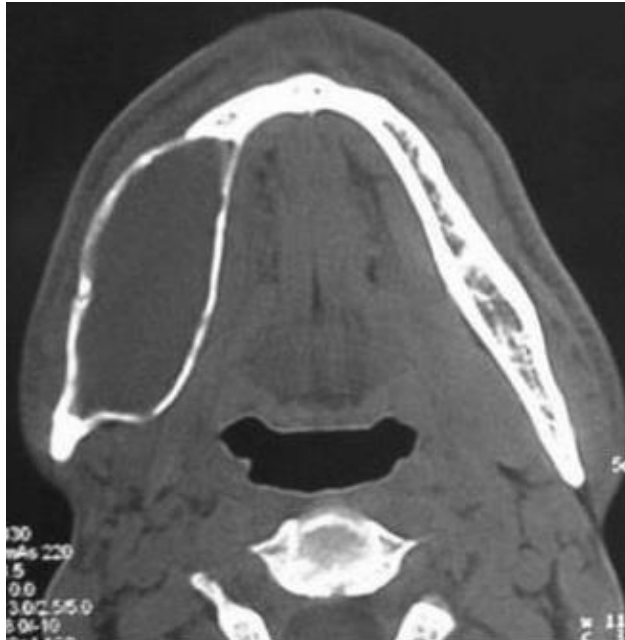


Figure 29.

The aneurismal cyst (the computed tomography)

Histologically, aneurismal cyst consists of many sinusoidal blood-filled spaces set in a fibrous stroma, with multinucleated giant cells and osteoid. Hemosiderin is present in variable amounts and there is evidence of osteoid and bone formation. This description is characteristic of the “classic or vascular” form. The histologic features in our case were consistent with the above-mentioned features. Solid form is the other histological type, which is a noncystic variant with solid gray-white tissue, hemorrhagic foci and abundant fibroblastic and fibrohistiocytic elements with osteoclast-like giant cells, osteoblastic differentiation areas with osteoid and calcifying fibromyxoid tissue. The mixed form demonstrates elements of both vascular and solid types. There

are manifest defects through which the fibrous wall of cyst borders the periosteum.

Numerous small and large cavities filled with connective tissue cells, with multiple giant polynuclear cells, erythrocytes, hemosiderin, and narrow ravines osteoid are revealed histological.

Diagnosis of aneurismal cysts of the jaw bones is complicated due to their similarity with pathological processes in the jaw bones, as ameloblastoma, odontogenic cyst, giant cell tumor, simple bone cyst. According to some sources, the relative frequency of diagnosis of disagreements amounted to 97.3%.

Surgical treatment is carried out (curettage of the cyst membrane) at this type of cyst. Treatment of aneurismal cyst is usually directed toward complete removal of the lesion. This may prove difficult at times since the lesions are often multilocular and may be divided by multiple bony septae. The treatment modalities are percutaneous sclerotherapy, diagnostic and therapeutic embolization, curettage, block resection and reconstruction, radiotherapy and systemic calcitonin therapy.

HEMORRHAGIC (SIMPLE BONE) CYST

In the literature, the tumor is described as youthful, hemorrhagic. Some authors call it traumatic. Some authors link the formation of simple bone cysts with bone trauma and intraosseous hemorrhage (hemorrhagic or traumatic cyst). Others believe that the formation of simple cysts caused by intensive growth of the skeleton at prepuberty and puberty age. During the growth of sponge bone does not have time to readjust and calcification form intraosseal cavity. A third group of researchers do not share the simple and aneurysmic cyst. The invalidity suggests about the distribution of youth and aneurismal bone cysts (Vinogradov, 1973; Yaroshevsky, 1977).

Cakes and al. (1978) analyzed a large number of clinical and laboratory data, concluded that the radiographic finding of cysts is not the basis for establishing a clinical diagnosis.

However, they consider authentic existence independent of bone disease in children, which is now designated as simple (youthful) cyst. Typical localization of youthful cysts is proximal metaphysis of shoulder and thigh (body of mandible - usually between canine and the ascending branch of the mandible).

Simple bone cyst occurs most of the time in the mandible with equal frequency in the body and ramus area. The margins can vary from smooth well-defined corticated to ill-defined. It is easier to identify the superior border of the lesion in the alveolar cortex than inferior border of the lesion. The lesion is oval resembling a cyst. It scallops between roots of involved teeth and causes sparring of the roots. Simple bone cyst is uniformly radiolucent and sometimes although it doesn't have septa, it can look as a multilocular lesion. This look is due to the propensity of the lesion to scallop endosteal surface of the outer cortex of the mandible.

Clinical picture of simple bone cysts is poor. Patients haven't severe deformation of the body of the mandible. The first symptom is pain in the intact teeth, localized in the cyst area.

Radiologically this is single-chamber area enlightenment without deformation and discontinuity of the cortical layer. The limits of cavity are unclear.

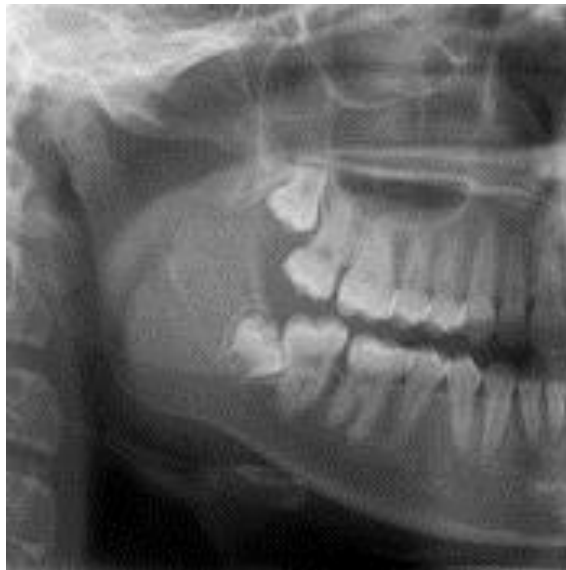

Figure 30.

The simple bone cyst (The X-ray picture)

Histologically, the cyst wall is formed by a layer of fibrous tissue, hemosiderin is in the cavity. It is believed that these cysts are formed at the site of hemorrhage after trauma. Simple bone cyst is not classified as a true cyst because the lesion contains no fluid and it lacks an epithelial lining. It is found to be empty or filled with serous or sanguineous fluid.

Vinogradov (1973) believes that this cyst should be diagnosed by comparing the clinical and radiological data, macro-and microscopic studies. In those cases where the tissue osteoblastoclastoma type is detected in walls of the cysts rightly diagnose osteoblastoclastoma or express such an assumption. The

presence of individual or clusters of osteoclasts is not itself a basis for diagnosis osteoblastoclastoma. If there is no tissue osteoblastoclastoma type, it should be simple to diagnose a cyst, but judged about its pathogenesis is difficult.

Pre-operative evaluation of the intralesional blood flow is still necessary because simple bone cysts pose a heavy bleeding risk in surgery. Bleeding may occur during biopsy or surgery because hemorrhagic cysts are aneurysms with numerous pools of blood. Treatment is surgical. The complete removal of the cyst membrane is necessary.

TRAUMATIC CYST

Traumatic cysts of the jaws are rare. They are not-epithelial cysts. These cysts are found in the lower jaw. In the initial stages of the progress of this disease are asymptomatic. These cysts are diagnosed accidentally. On radiographs they appear as clearly distinct cavity with sclerosed bony borders at the lateral part of body of the jaw, is not related to the teeth. The pathogenesis of these cysts is unknown. Histologically, the cyst has an epithelial lining. The bony walls of coated thin fibrous tissue containing with multinucleated giant cells and hemosiderin grain (Gubaidullin, Tsehelnik, 1990).

Traumatic bone cysts may be classified as unicameral, simple, solitary, hemorrhagic, or idiopathic. They are usually asymptomatic and appear on routine radiographies.

Traumatic cysts can be not filled with liquid contents or hemorrhagic fluid.

Some experts believe the result of intense bone growth of bone in which the bone sponge does not have time to regroup and form bone cavity. Similar cysts occur in the epiphysis of long bones. At the same time, it is believed that traumatic cysts result from bleeding in the central parts of the jaw. Hemorrhage into the thick spongy substance can lead to the formation of intraosseous cavity lining capsule of connective tissue, the formation of which involved endost.

Traumatic bone cysts are considered almost exclusively mandibular lesions, with a preference for the posterior areas (body and ramus) - although the symphysis may also be a site. They rarely may be present in the maxilla, although some studies have found a 25% incidence of cases in this bone. Possibly its almost exclusive location in the mandible is related to its pathogenesis; the trauma-hemorrhage theory may be an explanation because the

mandible, which has more cortical bone, repairs itself more slowly compared to the maxilla.

At purulence fistula may form, which is a way for the growing season of the epithelium of the mucous membrane of the gums deep into the jaw, followed by lining membrane of the cyst completely or, more often, in part. The pulp of the teeth that border with traumatic cysts of the jaws tends to remain viable.

Since material for histologic examination may be scant or non-existent, it is very often difficult for a definite histologic diagnosis to be achieved. Most of the histologic findings reveal fibrous connective tissue and normal bone. There is never any evidence of an epithelial lining. The lesion may exhibit areas of vascularity, fibrin, erythrocytes and occasional giant cells adjacent to the bone surface

The widely recommended treatment for traumatic cysts is surgical exploration followed by curettage of the bony walls. Removal of traumatic jaw cysts are performed by enucleation or cystotomy, depending on the size of the pathological formation. The surgical exploration serves as both a diagnostic manoeuvre and as definitive therapy by producing bleeding in the cavity. Haemorrhage in the cavity forms a clot which is eventually replaced by bone. It is believed that in some cases there may be a spontaneous resolution.

CHAPTER V. EXAMINATION AND PREPARATION OF THE PATIENT FOR OPERATION

X-ray examination.

Elements of X-ray examination of the upper jaw are:

- Contact dental radiographs;
- Orthopantomogram;
- Lateral roentgenogram of the upper jaw;
- A roentgenogram of the paranasal sinuses;
- A roentgenogram of the cranial bones in a straight projection.

For X-ray examination of the lower jaw are used:

- Contact dental radiographs;
- Orthopantomogram;
- Lateral roentgenogram of the lower jaw;
- A roentgenogram of the cranial bones in a straight projection.

At X-ray examination evaluated following parameters:

1. The degree of resorption of the alveolar process in the area of "causal" tooth root. In case of reducing of its height at 1/3 of the root, the operation with preserving of tooth is inappropriate.

2. Cyst size. It allows you to decide on the type of surgery (cystectomy or cystotomy).

3. Condition of the root canal of tooth. The quality and level of filling of a root canal of tooth, availability of denticle, additional branches from the main canal of the tooth root.

4. Availability of fracture of "causal" tooth root. The level of the fracture is the criterion for the decision to remove only the apical part or all tooth.

5. The relationship of cysts with the roots of adjacent teeth addresses the question about necessary of removal of tooth pulp of these teeth, or operation type cystotomy.

6. Complications of previously endodontic treatment. If you find these in some cases can make the tooth root apex resection and retrograde root seal.

At X-ray examination you can use fistulography (filling the cyst cavity through fistula by radiographic mass).

Computed tomography provides very valuable additional information:

- The state of the maxillary sinus;
- The level of "growing" of cyst in the maxillary sinus;
- The preservation of the main counterforts of the jaw.

These data allow to choose the best operative approach (from the hard palate, vestibule of the mouth).

Electroodontodiagnostic

Electroodontodiagnostic is used to determine the threshold of excitability of the pulp of the teeth that adjacent to the cyst.

At increasing of electroexcitability threshold of teeth adjacent to cysts than 60 mA it is recommended to do previous endodontic treatment.

Cytological examination

Cytological examination is important for the final decision on the tactics of the patient, and the amount and radical of surgery. It is necessary to send the patient to a specialized oncological hospital upon detection of tumor cells in punctate.

Endodontic preparation of the patient

The aim of endodontic treatment is root canal tooth fillings.

Regardless of the technique of used endodontic treatment should be sought to fill the root canal of the tooth to the root apex of the tooth.

The most frequent errors in endodontic treatment:

- Incomplete filling of channel - to eliminate this error before the operation attempt refilling of root canal of tooth;
- Timer of tool in the root canal of tooth - is an attempt to remove the instrument, the failure it is necessary to "get around" and refilled the channel;
- Perforation of the wall of the channel - at this complication the channel is filled to the root apex of tooth, closing the perforation by amalgam.

If unable to liquidate of earlier errors of endodontic treatment in the course of surgical treatment do root apex resection, preferably with retrograde filling of the tooth canal. When choosing a filling material for obturation of root canal, preferred zinc phosphate cements.

Prosthetic preparation of the patient

After endodontic treatment it is carried out the restoration of the anatomical shape of the tooth using fillings, inlays, crowns. These manipulations are carried out according to the rules described in the books and guidance of therapeutic and prosthetic dentistry.

CHAPTER VI. INSTRUMENTS AND MATERIALS THAT ARE USED IN SURGICAL TREATMENT OF JAW CYSTS

Once a patient is diagnosed, clinical and laboratory examinations are conducted, kind of operation is solved, dental surgeon must have the necessary tools and materials for surgical treatment.

There is no doubt that doctors in modern hospitals should use only single sheets, ranging from masks, rubber gloves and other things that most closely matches the rules of asepsis.

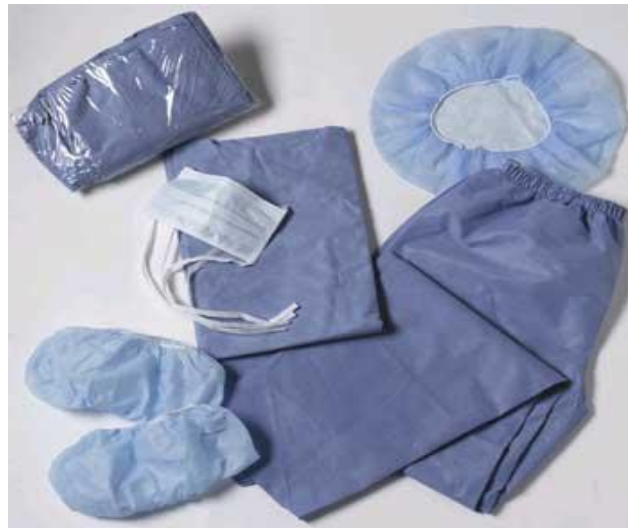

Figure 31.
Modern disposable ammunition of surgeon-stomatologists

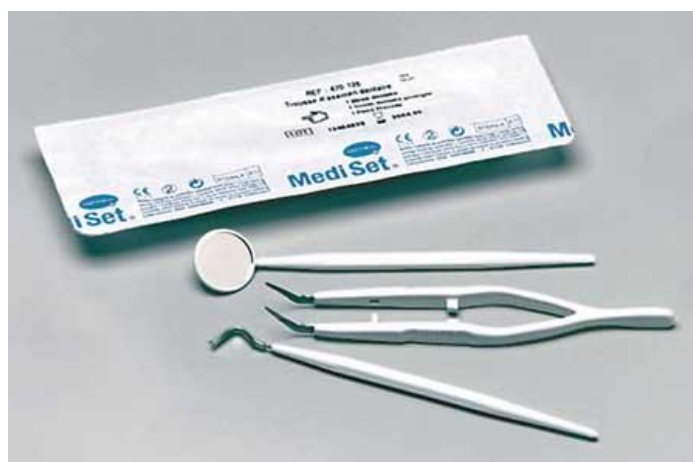

Figure 32.
Stomatological set of instruments for diagnosis

For diagnostic and therapeutic manipulations it is necessary to have a set of complementary of tools - diagnostic dental kit, puncture syringe, Volkmann's, Farabef's and Kocher-Langenbeck's hooks, a set of anatomical and surgical tweezers, surgical probes.

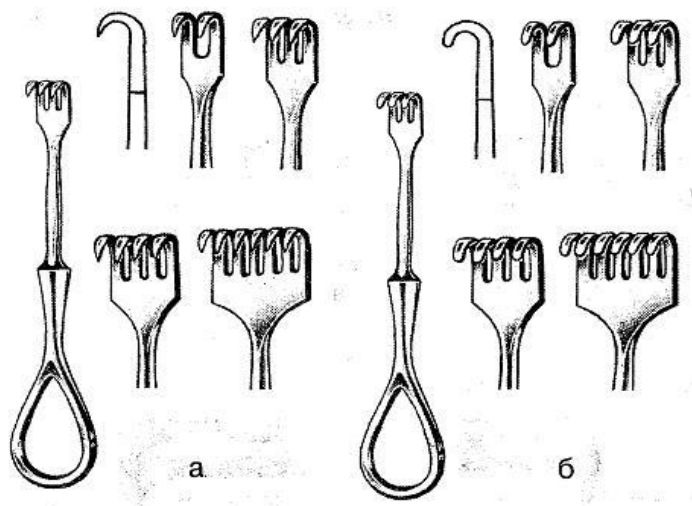


Figure 33.

Set of hooks by Farabef (a – spur toothed, b - bluntly toothed)



Figure 34.

Set of hooks by Farabef

For the injection of local anesthesia for removal of cysts of the jaws still widely used reusable syringe type "Record". At present, these syringes in outpatient dental practice are not used.

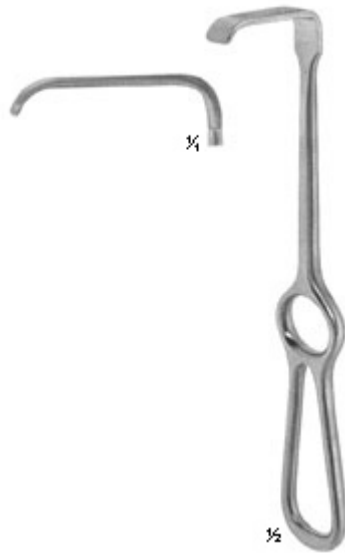


Figure 35.

Set of hooks by Kocher- Langenbeck



Figure 36.

Set of surgical and anatomical tweezers

Disposable syringe types "Luer", which are widely used now in the public dental institutions, have an advantage over multiple syringes due to the fact that they are sterilized at manufacture. But they are not suitable for use in the mouth,

which is much vascularized tissue, which often leads to complications such as vascular injury and the occurrence of hematomas.

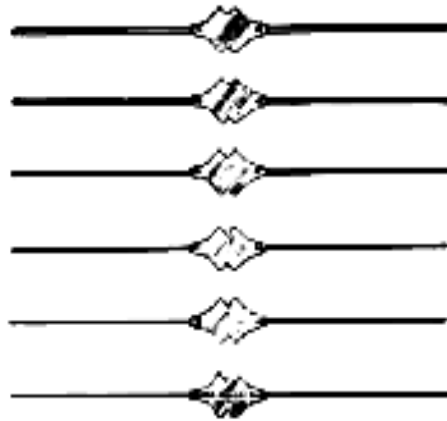


Figure 37.

Set of surgical probes

Syringe type "Carpula" decided disadvantages of syringe type "Record" and "Luer". These syringes are charged by special cylindrical ampoules ("cartridge", "carpula") that contain an anesthetic. This design ensures sterility, precise anesthetic and vasoconstrictor, sample useful at aspirating test.



Figure 38.

Reusable injector type "Record"



Figure 39.

Disposable injector type "Luer"

CARPULA – is a cylindrical disposable glass or plastic ampoule, with anesthetic solution, its volume is 1,7-2,2 ml. For ease of use on each karpuli contains information about the anesthetic that allows you to quickly and accurately select the desired drug as an anesthetic each has its indications and contraindications for use.

Needle for carpule syringe is a hollow tube with two working ends. Needle is stored in a protective plastic case.

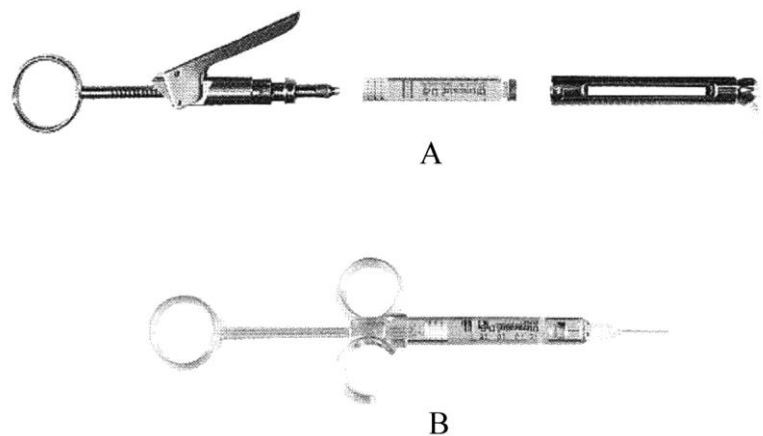


Figure 40.
Carpule injectors (a- iron; b- plastic)

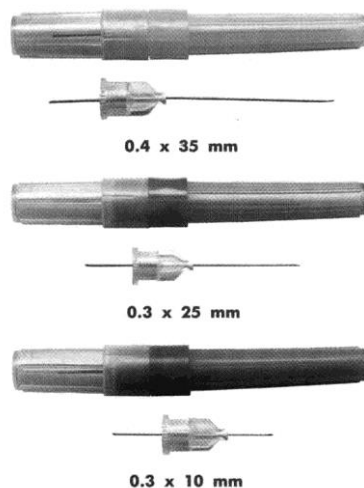


Figure 41.
External view of needle for carpule syringe

Bevels of these needles are not generally an angle of 45 degrees, but: 10 degrees (Long), 20 degrees (medium), 30 degrees (short), 70 degrees (very short). There are also needles with complex "triplicate" bevel. This needle easy manoeuvres with high capacity, easy pierces the soft tissue with minimal tenderness and traumatic.

Some needles ("Pointject", Japan) have marking (red dot) on the part of the bevel, which makes it easy to navigate at introduction of the needle during injection. Some companies cover the metal part of the needle by silicone, which prevents the formation of the copper combinations on surface of needle that occur during sampling of anesthetic from ampoules.

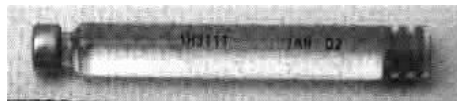


Figure 42.
External view of carpule

Choosing the right needle provides an effective local anesthesia with minimal pain and with minimal risk of complications. It is better, if possible, to work with needles of one company that allows you to take the right needle in seconds.

Some stomatologists often have difficulties when dealing with needles that marked the American system of measurement.

The American standard needle has labeling system of lengths and diameters, they also have a other diameter of the cone, that is not prevents their use in carpul syringes of European standards and it needs a special adapter.

In 1997, company "MILESTONE SCIENTIFIC" (USA) proposed automated computerized injector "WAND". Structurally, it consists of a block that has the electronic indicator control of cartridge for standard carpul, capillary

successor with a single needle, which the authors called "magic bullet" and the launcher button, which is enabled by using the pedals.

The advantages of this new injector are: lack of patient fear of injection; anesthetic served in tissue at quantity dosage and at the same rate, with constant pressure. In our country this computer syringe has not found its widespread yet due to its high market value.

For surgical intervention it is necessary to have a set of scalpels.

For making medical scalpels use stainless steel. Disposable scalpels do not need high corrosion resistance because they are made of hardened chrome steel for cold forming.

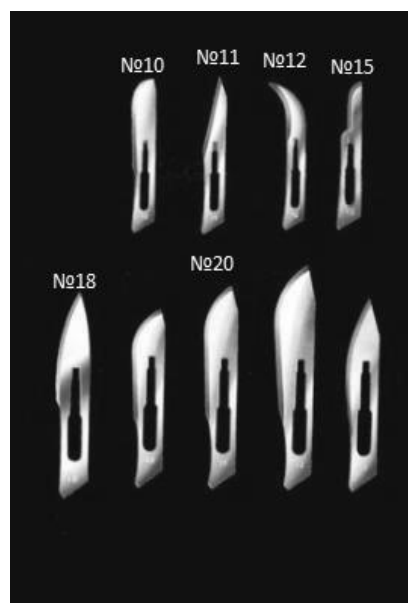


Figure 43

Set of different types of scalpel and disposable blades

Reusable scalpels are differed on high content of chromium (9518), or more complex doping (H12MF).

Scalpel blades for ophthalmic operations, which are also used by dental surgeon, usually made of ceramic or leukosapphire, stelits with thick diamond coating. Because of the high cost, they are forced reusable.

Modern scalpels are more frequently collapsible - permanent removable handle and mounted blade that can't be reface.

By appointment scalpels are classified as aculeate (use them to make deep but not wide cuts), abdomen (use them to make long and wide but not deep cuts), sickle (used to perform cuts in tight spaces).

It is necessary to have also several kinds of eye and other scissors.



Figure 44

Set of different types of scissors

Raspatory is designed to separate the periosteum from the bone using sphenoid cutting edge of tools. Separation of periosteum of the bone is a stage of operations cystotomy and cystectomy.

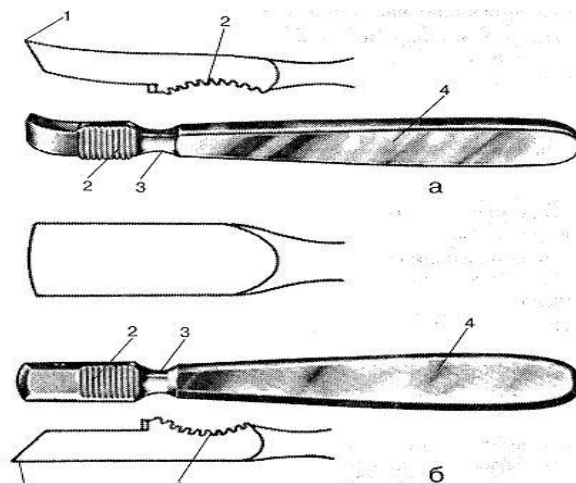


Figure 45

Principal construct of surgical raspatory (a — Farabeth's covered raspatory; b — Farabeth's straight raspatory).

To work with the bone doctor must have bone clippers, looped spoons, set of dental tools to removing teeth, nozzle for a drill with a set of burs and friezes.



Figure 46
Set of spoons for curettage

Choosing of needle-holders is an important aspect of quality of operation.

Today there are more than 30 models of needle-holder, different design and field of use, which provide cross-linking of tissues under different conditions. The main ones are Hehar's, Mathieu's, Trojanov's, Barraquer's and Kodivilly's needle-holders.

Hehar's needle-holder – is classic straight needle holder. It has a different length and width of the pen, and different notch on branshah. Hehar's needle-holder is often used with the hilt of different lengths.

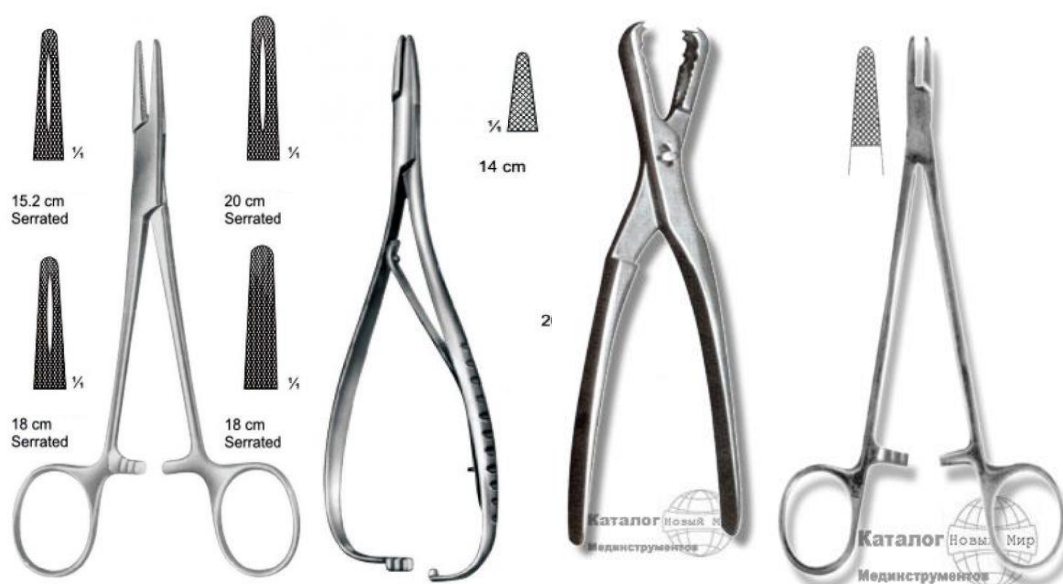


Figure 47.
Needle-holders by Hehar, Matiu, Barracer, Troyanov

Barraquer's needle holder is used in ophthalmic microsurgery. Hemispherical recesses are at the ends of the inner surfaces holders, so the needle is held at any angle to the axis.

Zand's needle holder is used for the maintenance of eye surgical needles when suturing. It is a combination of tweezers with a clip, and one holder tool for them overall.

Langenbeck's needle holder – is a needle holder with lead plates on the job lips, providing more reliable fixation of the needle.

Mathieu's needle holder is used for holding the surgical needle when you apply the seam. It is equipped with springy handlebar lock that is opened during the subsequent compression handle.

Trojanov needle holder is used for maintenance of surgical needles at suturing. Fixing lock located on the end of the handle, so undoing it done by V finger.

Trojanov's and Mathieu's needle holders are so designed handle lock which the compression fingers.

Locking tool for this rests on the palm, which is not impossible and even damage to the hands of the surgeon surgical gloves. These deficiencies make it difficult to use in surgery of the needle holder.

Thus, the choice of needle holder is largely driven by the size of the needle and the features of the intervention. What delicate and technically difficult operation, the more sophisticated needle holder should be. The smaller the needle, the smaller should be in quotes needle holder. Needle holder continued the surgeon's hands, so quality needle holder will increase the chances of a successful outcome of the operation and reduce the likelihood of complications.

Besides the above listed for surgery must have dressing (gauze balls, napkins) antiseptic turundas (iodoform, xeroform), suture and surgical needles material for reparative osteogenesis local anesthetics. On the latest materials E acquaint you more detail in separate sections of this manual.

CHAPTER VIII. CHOICE OF SUTURE MATERIAL IN SURGICAL TREATMENT OF JAW CYSTS

Today, the commercial market of medical devices offers a large number of suture materials. However, rare manufacturing companies pay attention to the specifics of what is presented to suture materials in stomatology.

Based on the experience of our department, we have attempted to define the main provisions in this regard.

No need to argue that today it is advisable to use only atraumatic suture material (than needle and thread are combined), its main advantage is minimal traumatization of tissues. Another positive point is the lack of time spent for selecting needles, which corresponds to the diameter of the thread, the need to attach a thread to the needle, non-permanent use, the uselessness of repeated sterilization and needle grinding.

Most famous manufacturers of suture material offer yarns generally of good quality, but the texture of the needles varies considerably, though, that proper suturing and favorable flow of the healing process largely depends on the needle used by a surgeon.

The quality of surgical needles is determined by its strength (ability to resist to deformation) with a minimum thickness, sharpness, hardness (the ability to resist bending), ductility (ability to resist a fracture), and sterile immunity to corrosion, resistance in needle-holder.

For the manufacture of surgical needles it used different brands of stainless steel. Usually it used steel stamps series 300 or 400.

For atraumatic suture material of different manufacturers, you should always focus primarily on knowledge of anatomy and needle design. This helps the surgeon to quickly select a suture material with adequate needle. Talking

about the anatomy of the needle, we primarily mean the edges, and place of the body of the thread.

Surgical needles in shape divided into: pricking; cutting; back-cutting; piercing-cutting (taperkat); lanceolate; blunt-pointed.

Pricking needles commonly are used for soft tissue (blood vessels), where cutting needle can cause unnecessary injury. These needles normally used for applying the anastomosis, when connected of homogeneous soft tissue (muscles, fascia, mucous membranes, etc.). Body of needle is round, flattened in the middle for better capturing in needle-holders. Conical, very smooth needle tip facilitates penetration into the tissue.

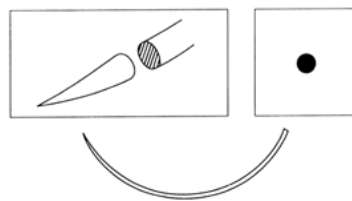


Figure 48.
Pricking needle

Cutting needles have three sharp edges that provide free penetration of the needle through solid tissue. It is used for closure of thick tissues, skin.

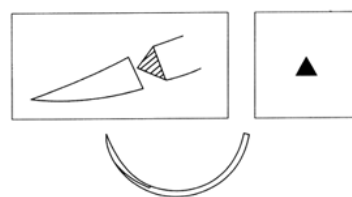


Figure 49.
Cutting needle

Back-cutting needles (reversible) have a triangular section on the whole over with an outer cutting edge. By the third cutting edge needle acquires increased strength in the tip and easier pierces the hard tissue. These needles are

preferred for node seam undergoes constant tension. Due to the fact that the flat base of the needle facing the wound, after tightening of the suture it is less likely to cut it. It is used for closure of thick tissues, skin.

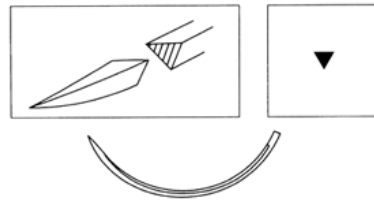


Figure 50.
Reverse needle

Reversible cutting needle is 40% stronger than standard cutting and working with her surgeon can make more effort to match the edges of the wound without fear cut flap.

Pricking-cutting needle ("taperkat") is round in section, with cutting tip. These needles have been created in an attempt to combine the advantages of pricking and cutting needles. The cutting tip is obtained by turning the tapered needle tip. By reducing the channel that forms in tissues compared with the cutting needle is a needle shape can significantly reduce the traumatization of tissues. It is used for hard tissue (aponeurosis, vessel with calcificates etc.).

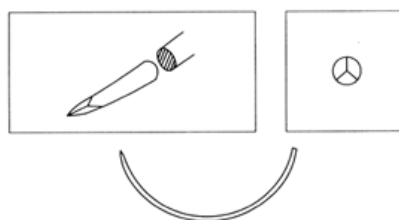


Figure 51.
Pricking-cutting needle

Trapezoidal needle (lanceolate) have flattened body of the needle with two cutting sides. This needle penetrates between the thin layers of tissue without damaging them. It is used in ophthalmology and microsurgery.

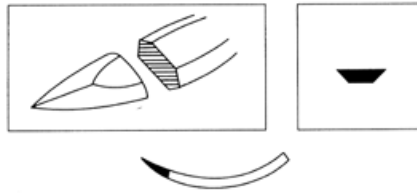


Figure 52.
Lanceolate needle

Needles with blunt tip are round in section, with smooth (blunt) tip. The blunt tip ensures the preservation of blood vessels and tendons in the firmware. They are used in operations on parenchymatous organs, cervix, liver, etc.

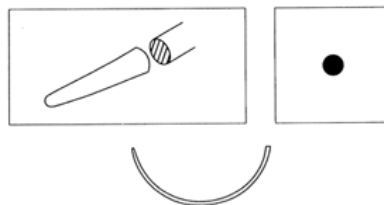


Figure 53.
Needle with a seared tip

All needles are subjected to sharpening giving them the necessary geometry time. In the manufacture of some needles it is made additional sharpening. Most sharp needles are used in plastic surgery and ophthalmology. Needles are not amenable to additional sharpening, used in suturing tissue, which is ideal sharpness is not a critical parameter.

In the manufacture of needles from mild steel firms have to reinforce the edge using a larger view.

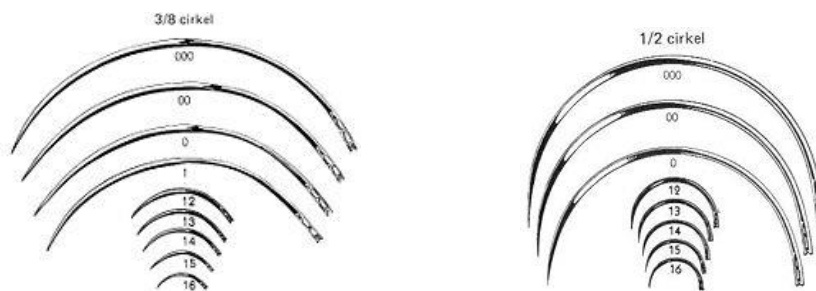


Figure 54.
Concavity measures of surgical needles

Surgical needles whenever concavity divided into: straight and curved.

Needles also vary in the extent of concavity (denoted by number fraction of the circle) and are: straight, 1/4 circle, 3/8 circle, 1/2 circle and 5/8 circle. To perform surgical manipulations in the mouth it is recommended the use of needles with extent of concavity 3/8 and 1/2 circle.

To attach the needle thread to use multiple methods that differ in degree of complexity, high cost of production and the strength of adhesion.

The most common (easiest and cheapest) way is production of channel on blunt edge of the needle, placing it in the thread and clips the threads in the channel. The application of such techniques can't achieve a strong attachment to thread the needle. Another way is drilling of holes in the blunt edge of the needle by diamond forests. Both methods are used for the manufacture of needles from relatively mild steel. The most expensive, but also accurate and reliable method of attaching a thread to the needle is the method of production of holes to thread by laser drilling.

Good are those manufacturers of suture material that each filament diameter is selected appropriately sized needle. Maximum matching of thread and needle sizes make minimizes of trauma of inflicted tissue during suturing of the wound edges.

Unfortunately, there are companies that for one needle diameter use a number of different sizes of thread; such diameter of thread as 5/0, 4/0 and 3/0 is fixed to the needle diameter of 0.65 mm.

Regarding the choice of threads then there is no need to dwell on the peculiarities of their production for several reasons. First, a variety of materials and methods are used for the manufacture of threads too big. Second, the quality of the threads of known companies is always implicitly high.

The structure of threads, modern suture materials are divided into: monofilament (filament, consisting of a single coherent fiber) and polyfilament (a lot of fibers). Polyfilament thread can be twisted and braided. These threads can be with coated and without it. Polyfilament thread without cover has peel effect. In case of stretch of this thread through the tissues due to its rough, uneven surface, it cuts through and injures tissue. This leads to greater tissue damage and bleeding to most of the puncture. This thread barely extends through the tissues. To avoid this effect, polyfilament threads are covered by a special coating that provides a smooth surface string. These threads are called combined. Polyfilament thread has so-called cankered effect. This is when between fibers braided or twisted yarns are micropores that are filled by tissue fluid in finding this thread in the wound. If the wound is infected, then microorganisms can displace to a healthy, uninfected part of the tissue, on micropores, causing inflammation there.

So, mono-and polyfilament threads have positive and negative qualities.

Woven threads are stronger for rupture; they retain high strength at the knot. Monofilament becomes less strong in the area of knot. Polyfilament threads are used at endoscopic operations. This is due to the fact that endosurgeons used mainly intracorporal ways of knotting, which involves tying threads with tools. However, monofilament in place of pressure may lose strength and tear.

Manipulation properties of threads are elasticity and flexibility. Elasticity is one of the main parameters of the thread. Manipulate by stiff filaments is harder for surgeon, that make more tissue damage. Tough thread, with increased memory, balls going into the wound, creating additional difficulties surgeon in a small operating field.

Polyfilament thread is much softer, more elastic, has less memory. Braided thread is knitted at fewer knots. Monofilament strikes easier through the tissues. During extraction of it from the wound, it does not grow to tissues and easily extracted. Braided thread adheres to tissue for 5-6 days, so it is very difficult to extract it.

Strength of knot connected with surface properties of filaments. Generally, surface of the thread is smoother, the sooner preparing a knot in it. Therefore, the monofilament strands bind more knots. One of the items to the current requirements of suture material – is minimum number of knots required for its reliability. Every extra knot is a foreign material. The smaller number of knots makes less inflammatory tissue reaction.

Biocompatibility and inertia – are the ability of thread to cause tissue inflammation. Monofilaments have less irritating effect. For all things being equal, polyfilament thread will cause greater inflammation of tissue monofilament.

Decaying effect – is the ability of a thread to absorb the contents of the wound. As we already know, polyfilament threads have this effect, but monofilaments don't. Therefore, monofilament doesn't support the inflammatory process in infected wounds.

By capacity for biodegradation (resorption in the body) sutures are divided into: that resolves conventionally, absorbed and not absorbed.

Materials that resolve include are: catgut, absorbable synthetic filament.

Catgut suture simple and chrome – is a material of natural origin with serous or tissue of small ruminants. In filaments that dissolve, there are two characteristics in terms of dispersal. These are: biological durability or support

tissues - a period when the thread is biodegradable in the body and still retains 10-20% of its original strength. The term of complete resorption – is the time it takes absorbable thread to completely dissolve in the body. Biological durability of plain catgut is 7-10 days; chrome – 15-20 days. The term of complete resorption of simple catgut is 50-70 days, chrome – is 90-100 days. These terms are very relative, because the resolution of catgut in the human body is its cleavage by cellular proteolytic enzymes. Therefore, the rate of resorption of catgut depends on the human condition and the state of health of the animal, which was made catgut thread. Often there are cases where the suture is not resolve for six months and later.

Artificial resolve materials are threads from polyglycol polydyaxone and polyglykapon acids. They are different in structure: mono and polyfilament, in terms of deterrence tissue and full-term of resorption. All firms producing surgical suture materials do it with the same polymers. Therefore, the classification is based on synthetic strings that resolve, we will deter their terms of tissues and full-term resorption.

Synthetic filament with short term of resorption - is woven from threads polyglycolen acid. Biological durability of these threads like simple catgut is 7-10 days, full-term resolution for 40-45 days. These threads are used in general surgery, pediatric surgery, plastic surgery, urology and any other surgery where tissues form scar for 7-10 days. The advantage of these threads is their small term of resolution (40-45 days). It's a pretty short time to these threads are not formed urinary or biliary stones, they are very good for intradermal cosmetic seam resolves, the patient does not need to go back to the surgeon to remove the threads.

Synthetic filament with medium term of resorption can be braided and monofilament. This group of threads is more likely to use in surgery, because

the terms of the support tissues they make up 21-28 days - this is the period during which the scar forms in most human tissues. Then there is no need for wires and they dissolve over 60-90 days, leaving no trace of the body. These threads are used in various fields of surgery. The group with medium term of resorption includes monofilament from polyglykapon. Term of tissues containment in these threads is 18-21 days, complete resorption occurs due 90-120 days. These threads can be used in any surgery. Their drawback - at worst manipulative properties than the woven threads absorbable - they need to knit more knots.

The third group of synthetic filament is threads with long dispersal of polydyaxanone. Term of maintenance of tissues is about 40-50 days. Complete resorption is for 180-210 days. These threads are used in general thoracic surgery, traumatology, in maxillofacial and oncosurgery, as well as any other surgery that require string that resolves to support the tissues with long scar formation: cartilage tissues, aponeurosis, fascia and tendon.

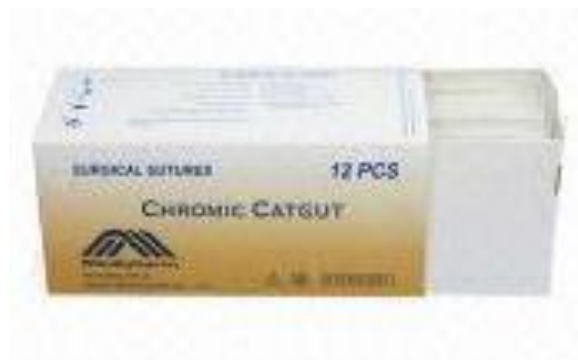

Figure 55.
Catgut

Recently catgut is replaced by synthetic resorbable strings everywhere. Catgut thread is most reactogenic of all strands - the only thread which describes the reaction of anaphylaxis. Using of catgut filaments can be considered as extraneous tissue transplant operation because it is made with a foreign protein. Experimental studies have shown that at wounds suturing by catgut is enough to enter 100 staphylococcus microbes to get a purulence (usually normally require

one hundred thousand). Catgut thread even in the absence of microbes can cause aseptic necrosis of the tissues. Formerly referred to the unpredictable timing of loss of strength resorption catgut, moreover, if we compare the same thread diameter, the strength of catgut less than synthetic fibers. Catgut, while in the wound, it causes irritation, inflammation, resulting its longer healing. The tissue that is sutured by synthetic dissolves thread heals faster. It has long been observed that once the surgical department goes to work with synthetic filament (but not catgut), the rate of postoperative complications is reduced. All of the above indicate that in modern surgery is no indication for the use catgut. At the same time, some surgeons continue to use it and find catgut as satisfactory suture material. Primarily, this is due to the habit of surgeons lack experience of using synthetic strings that resolve.

The group of threads that conditionally dissolve includes: silk; polyamide or nylon; polyurethanes.

Silk in its physical properties is considered the gold standard in surgery. It is soft, flexible, and durable, knit allows two knots. However, due to the fact that it refers to materials of natural origin, it is comparable only with catgut in its chemical properties and silk in inflammatory reaction only slightly less pronounced than on the suture. Silk also cause aseptic inflammation, including the formation of necrosis. When using silk thread in the experiment, it was pretty 10-staphylococcus microbes that cause suppurating wounds. Silk has expressed sorption properties and rotting, so it can serve as a guide and a reservoir of bacteria in the wound. Located in the human body, silk resolves within 6-12 months, making it impossible to use it with prosthetics, in connection with what is recommended to replace the silk thread by other material.

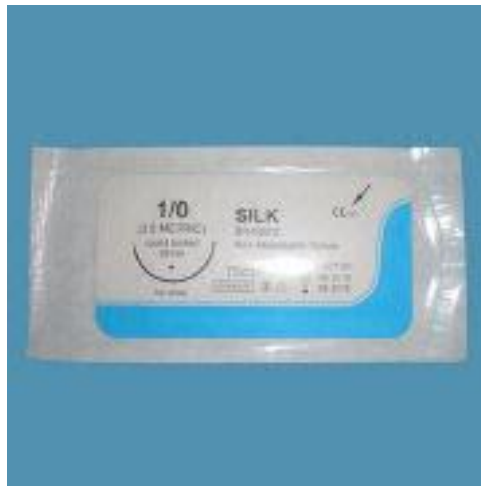

Figure 56.
Silk

Group **polyamide (nylon)** absorbed in the body within 2-5 years. Polyamides - are historically the first synthetic suture material, chemically are inappropriate for surgical suture. These threads the most reactogenic from all artificial synthetic fibers, and the reaction is in the nature of delayed tissue inflammation and lasts the entire time that the thread is in the tissues.

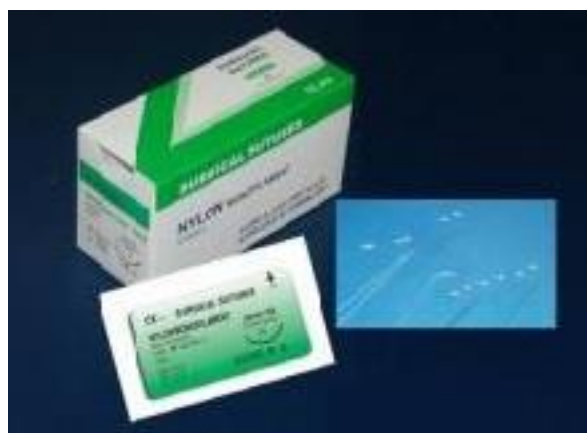

Figure 57.
Nylon suture material

First, polyamide or nylon, made with a twist then braided and monofilament threads. As the inflammatory response of tissues to these threads, they are arranged as follows: the smallest reaction to monofilament filaments over to woven, even more twisted. Polyamide, used in surgical practice, the

most common monofilament thread; should also be noted that the lowest value of these threads. These threads often are used for intradermal, removable not absorbable suture for stitching of blood vessels, bronchus, tendons, aponeurosis, using in ophthalmology.

Polyurethane air - the last of a group of polymer materials conventionally resolve. Of all the monofilaments it has the best manipulation properties. It is very flexible, has virtually no memory strings, easy to work with him in the wound. This is the only monofilament, which can bind three nodes. Unlike polyamides is not supported in wound inflammation.

The third group – is a thread that is not absorbable: polyester; polypropylene (polyolefins); group of fluorocarbon materials; steel; titanium.

Polyester thread is more inert than polyamides, cause less tissue reaction. Threads are mainly woven and extremely durable. While the use of threads in surgery is more limited, they disappear from the arsenal of surgeons. This is due to both the advent of synthetic absorbable threads, and the fact that of all the properties except polyesters lose strength polypropylene. Now polyesters used in 2 cases: when you need to sew the tissues for a long time after the operation are under tension and thus need the most robust and reliable thread; in cases where the thread that does not resolve, you need at endosurgery.

These threads are used in cardiac surgery, traumatology, orthopedics, general surgery and any other surgery that require strong thread that does not resolve.

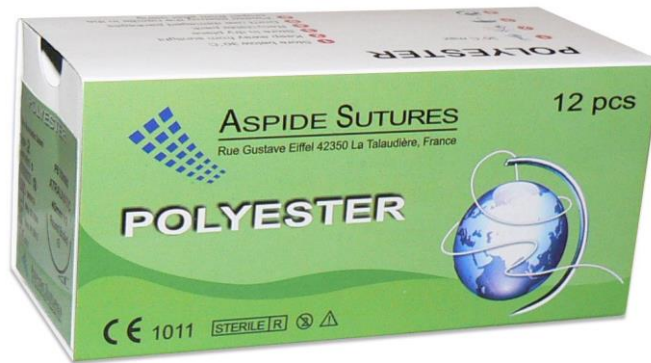


Figure 58.
Polyester suture material

The second group is **polypropylene (polyolefins)**. This material is available only in the form of monofilaments. Of all the above-mentioned polymers, these threads are inert to most tissues, the response of tissues to polypropylenes almost nonexistent, so they can be used in infected tissues or not to remove, if the wound became purulent. Also they are used in cases where even minimal inflammatory reaction is undesirable, and in patients with a predisposition to formation of celloid scar.

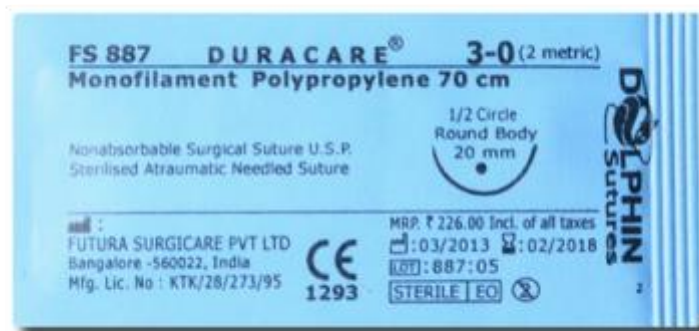

Figure 59.
Polypropylene suture material

Applying these threads never leads to the formation of ligature fistulas. Threads in this group have only two shortcomings: they are not dissolvable and

have the worst manipulation properties than woven threads; they knotted by a large number of knots.

The third group of not dissolve threads includes **fluoropolymers**. This is latest research of all firms in the polymers of which make surgical suture material. Scientists have been observed if the polymer is added fluor-connect component; the material acquires great strength, becoming more flexible, more elastic. These threads have the same properties and are used in the same operations, where a group of filaments of polypropylene. The only difference is that the threads are softer, more elastic; you can knit it by a smaller number of knots.

The last group of not biodegradable threads material is **steel and titanium**. Steel can be in the form of monofilament and wickerwork. Steel monofilament is used in general surgery, traumatology and orthopedics, woven in cardiac surgery for manufacturing an electrode for temporary pacing.

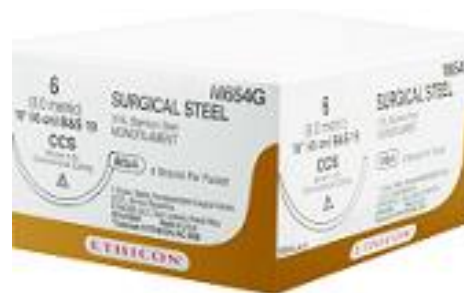

Figure 60.
Surgical steel

One of the most important parameters of a thread is its size (diameter), which is measured by the number of zeros. The more zeroes, the finer the thread. Rule surgeon says: "It is necessary to use the smallest diameter of the thread that can adequately support tissue that has not yet healed".

So today in practice dental surgeon should be guided in choosing of type of suture material, not by their personal preferences and thoughts, cheap material, and based on the indications for its use, most of his positive qualities, minimum - negative.

CHAPTER VII. CHOICE OF ANESTHESIA IN SURGICAL TREATMENT OF JAW CYSTS

Choosing of local anesthetic.

All variety of modern local anesthetics fits into the two major groups: ether and amide.

Local anesthetics ether type. Previously for injectable anesthesia only were used drugs of this group - cocaine, dicaine, Novocaine. Due to their high toxicity and the advent of less toxic drugs currently in carpule anesthesia they found their use.

Local anesthetics amide type.

TRIMEKAYINE (Trimecaine) - derivative of hydrochloride 2, 4, 6 - trimethylacetate anilid diethylaminoacetic acid. Synonyms are Mesdicaine, Mesocaine.

This drug is not used in carpule anesthesia, but is widely used in dental clinics in Ukraine and CIS countries for terminal anesthesia by conventional syringe.

LIDOCAINE is amid of aromatic amine. Derivative of hydrochloride 2.6.-N, N-diethylaminoacetanilid. Synonyms are Alocaine, Anestacon, Anestecaine, Astrocaine, Acetoxyline, Dollicaine, Dulcicaine, Xycaine, Xylesin, Xylestesin, Xylocard, Xylocoton, Xylodont, Xylocaine, Xylonor, Xyloton, Xylotox, Xylocitin, Leostesin, Lignocaine, Lignom, Lignospan, Lidestesin, Lidocard, Lidocoton, Maricaine, Nylicaine, Octocaine,

Pressicaine, Rapicaine, Remicaine, Solcain, Stericaine, Utilicaine, Fastocaine, Esracaine.

Lidocaine is first amide anesthetic that was used at stomatology and today is the most useful. The effect of anesthesia is 3-4 times more than novocaine, but toxicity is twice higher. Rapidly absorbed, slowly decomposes, a longer time of anesthesia than novocaine (up to 60-120 min.). Anesthesia occurs within 2-3 minutes.

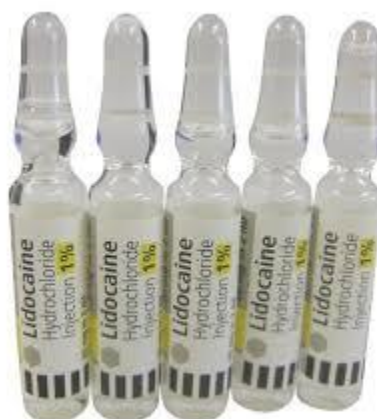

Figure 61.
Lidocaine

Pashchuk (1987) considered that lidocaine metabolized in the liver and only 17% of it is excreted unchanged in the urine (10%) and bile (7%). In addition to the anesthetic effect of the drug has a pronounced antiarrhythmic effect, as also used in cardiology. When topically applied medication expands the blood vessels. Lidocaine is not para-aminobenzoic acid antimetabolites so it compatible with sulfonamides. If overdose it lead to pale skin, nausea, vomiting, trembling muscles, lowers blood pressure. At lidocaine intoxication (if a quick introduction to the vascular bed) it is possible such complications as hypotension, vascular collapse, depression of the respiratory center, convulsions. Sometimes it is possible impairment, allergic reactions. Contraindication to the use of this drug is heavy gravis of myasthenia. The drug is used with caution in failure of the cardiovascular system, liver and kidneys. It is not recommended to

combine it with β -blockers, as this may develop bradycardia, hypotension, bronchospasm.

MEPIVACAINE – is derived amides of aromatic amines (anilids) - hydrochloride of dimethylanilid N-methyl-pepycol acid. Synonyms are Isocaine, Carbocaine, Meaverin, Mepivastesin, Mepicoton, Polocaine, Scandicaine, Scandonest.

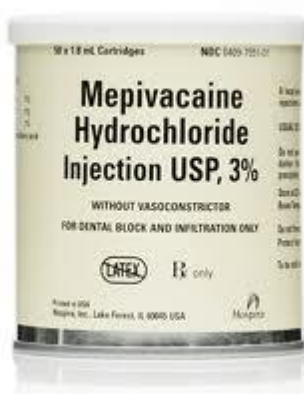

Figure 62.
Mepivacaine

For the anesthetic efficacy it 4 times dominated on novocaine, but mepivacaine 1.5 - 2 times more toxic than it. For efficacy and toxicity approximately equals to lidocaine, but much less than it dilates blood vessels. Anesthesia occurs within 2-3 minutes, duration of 60-120 minutes. Mepivacaine – is anesthetic substance that has a strong tropism for nervous tissue and provides a minimum quantity sufficient analgesic effect. It doesn't stimulate the cardiovascular system that can be used at patients with severe cardiovascular disease.

PRILOCAINE – is amide type anesthetic (a derivative toluidyn) close in chemical structure to lidocaine. Synonyms are Xylonest, Prolitocaine, Citonest.



Figure 63.
Prilocaine

The drug is 1.5 times more toxic by procaine, but the anesthetic effect is 4 times higher. Anesthesia occurs within 2-3 minutes after introduction; duration of 60-120 minutes.

A comparison of the pharmacological properties of prilocaine and lidocaine Konietrke and Cooh (1985) found that prilocaine can cause methemoglobinemia, while lidocaine is more cerebral and cardiocirculatory toxicity.

The drug is practically not dilates blood vessels, so it is usually used without vasoconstrictor.

Prilocaine should not be used during anesthesia in children, pregnant women, the elderly and in patients with liver disease.

ARTICAINE – is amide type anesthetic derived tiofenov series. Synonyms are Alphacame, Carticaine, Septanest, Ubistesin, Ultracaine.

The degree of vasodilatory activity of articaine is equivalents to mepivacaine and prilocaine. Drug toxicity is 1.5 times greater than novocaine, but it is 5 times stronger. Anesthesia occurs within 0.5-2 minutes and lasts longer than 60-180 minutes.

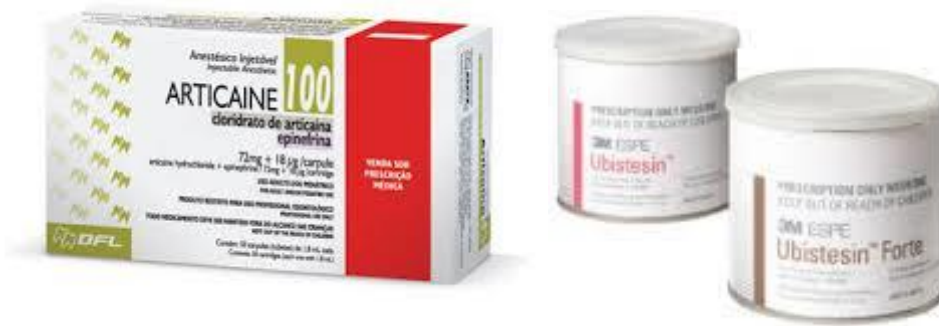

Figure 64.
Articaïne

At compared with lidocaine appears that the analgesic effect of 2% articaïne solution lasted 126 minutes and 2% lidocaine solution lasted only 106 minutes (Heudobin, Mattiba, 1974). The authors noted a lower toxicity of articaïne. According to Ebert (1974), comparing the actions articaïne and mepivacaine at terminal anesthesia and found that 1% articaïne solution has a shorter latency period and significantly longer duration of anesthesia than a 1% mepivacaine solution.

A high percentage of protein binding allows you to keep 95% of the articaïn introduction in circulating in the bloodstream bound inactive state. This figure suggests a low toxicity and its high analgesic efficacy. Relatively low toxicity enables extended use of 4% solution of anesthetic, causing an even greater effect of anesthesia. This advantages allows to used articaïne in children, pregnant women, elderly patients. (Shuhaylov et al., 1996).

Compared to other local anesthetics best performance of plasma clearance has articaïne. The drug is excreted from the body at a speed of 4 mg/min, which is 4 times faster than lidocaine or mepivacaine.

High clearance defines low risk of toxic reactions. The half-life or half-life period of articaïne – is 21.9 min, which is 4-5 times less than that of lidocaine, prilocaine, mepivacaine.

Articaine has excellent diffusion properties, its separation factor higher than lidocaine, bupivacaine and prilocain (123.0 units. against 10.0, 6.9, 83.2 units) (Casanovas et all., 1982).

These data indicate a high degree of diffusion through biological membranes, due to the structural features of articaine molecule (Lemay et all., 1984). Thus, according to Zorian and Anisimov (1995) articaine medications can provide anesthesia of palate after vestibular terminal anesthesia in the maxilla and pulp anesthesia after the same anesthesia in the mandible. Schulte (1989) suggests reducing the use of regional anesthesia with this drug and widely used of terminal anesthesia.

According Dudkiewiez et all. (1987), anesthesia by articaine in any case did not require its re-introduction.

According Rahu (1999), who between 1976 p. to 1995, p. had made more than 800 million injections by articaine incidental effects amounted to 1 400 000 patients. In general they weren't associated with the articaine and were specific to the action of adrenaline on the cardiovascular system. Only 10 patients occurred allergy to the drug, indicating a slight possibility of allergic reactions.

BUPIVACAINE – derivatives of aromatic amides are butyl analogue of mepivacaine. Synonyms are Duracaine, Carbostesin, Magcaine, Narcain, Svedocain, Sensorcaine.

The drug is still not widespread use in our country. Despite the high toxicity, is considered one of the safest of local anesthetics. Unlike novocaine that splits by pseudoholinesterase at blood serum, metabolizes in the liver. Anesthetic activity of bupivacaine at 6-16 times the novocaine, but it is 7-8 times more toxic. Use 0.25%, 0.5% and 0.75% of solution of 25 to 60 ml (total

dose less than 75 mg). Anesthesia occurs within 4-10 minutes after injection, reaching a peak after 15-35 minutes and lasts for more than 240 minutes.



Figure 65.

Bupivacaine

According Egorova (1985), the duration of infiltration anesthesia by bupivacaine is 12 hours, with conduction block - more than 13 hours.

There may be instances of generalized toxic reaction that manifested seizures, due to exposure of the drug in the vascular bed (Moore et Cooli, 1978).

Overdose causes cardiac abnormalities. It is used mainly in hospitals maxillofacial surgery, where he continued action provides postoperative analgesia.

AETHYDOCAINE – is a local anesthetic, similar in structure and chemical properties to lidocaine, its lipophilic homologue. Synonym is Duranest.

According Lond et al. (1974), it dominates lidocaine on the strength and duration of anesthetic action. The author used the drug for intercostal nerve

blockade in a 0.25-0.5% solution in an amount of 30-60 ml. Anesthesia occurs within 6-9 minutes and lasts up to 790 minutes.

Bridenbaugh et al. (1974), comparing the effect of a 1% aethydocaine solution with 2% lidocaine solution during epidural anesthesia, found that pain occurs simultaneously, but its duration at the injection aethydocaine up to 6 hours, and lidocaine - 4 hours.

Niesel et al. (1974) noted a close relationship aethydocaine plasma proteins than lidocaine (94% vs. 55%).

Paradis and Fournier (1975), comparing aethydocaine and lidocaine in the degree of achieving the same level of anesthesia, noted that aethydocaine it occurs within 5 minutes, while lidocaine - in 13.4 minutes. Duration of anesthesia by aethydocaine is much greater than lidocaine.

For the prevention of intoxication (during epidural anesthesia) Tucker et al. (1977) recommended a combination of lidocaine with aethydocaine the following procedure - 20 ml of 2% lidocaine solution and 20 ml of 1% aethydocaine solution.

The main disadvantage of the drug is increased bleeding during operation due to the fact that it expands the blood vessels. To avoid this, it is best to use with vasoconstrictor.

A positive aspect of drug use is a significant duration of its action in the postoperative period. In terms of analgesic options it is close to bupivacaine. Despite the high toxicity, is considered one of the safest.

HOSTACAINE – is hydrochloride parabutilamin of acetic acid. Synonyms are Butanalycain, Butacetolud.

Used for terminal anesthesia in a 0.5% solution of up to 120 ml of 1% solution in accordance fewer. The drug was well tolerated by tissues. Anesthesia occurs rapidly, immediately after infiltration can be carried out the operation. This is due to its high diffuse property. With this bound is also more rapid expiration anesthetic. It is therefore necessary to apply vasoconstrictor drugs (1 drop of 0.1% solution of epinephrine in 10 ml of hostacaine solution). Anesthetic action while continues to 80 minutes. Repeated injections are safe.

The clinical substantiation of choice of anesthetic drug and method of local anesthesia in the surgical treatment of cysts of the jaws.

The choice of local anesthetic and modern anesthetics in surgical treatment of jaws cysts depends on the duration of operation, the presence or absence of inflammation, the patient's age, the presence of his common diseases and their allergy status.

Duration of anesthesia is related to the complexity and duration of operation and the duration of the anesthetic should always be longer than the actual intervention. Vasoconstrictor drugs help to increase the duration of anesthesia.

Principle - "the time of the anesthetic increases with dose" is losing its relevance with the advent of modern anesthetics, as with dosage 1,7-1,8 ml, they cause a more powerful and lasting effect than 5,0-10 ml solution of Novocaine or trimecaine.

Choosing a potent local anesthetic, remember that it is more toxic, and, in addition, will stipulate a longer paresthesia of soft tissues that cause discomfort phenomenon at the patient.

Reducing the percentage of local anesthetic by vasoconstrictor added to it in some way solve the problem of toxicity. The solution can also serve as anesthetics using medium strength and duration of action of the vasoconstrictor that increases their future actions. But keep in mind that increasing of concentrations of anesthetics to 3 - 4% (3% mepivacaine 3% lidocaine, 4% articaine) not containing vasoconstrictor much inferior to today composition: 2% local anesthetic with vasoconstrictor in the ratio of 1:100,000 (1:200,000).

Preparations of medium strength and duration with vasoconstrictor are used in uncomplicated and atypical extraction of teeth, at remove a few teeth at

the same time, root apex resection, hemisection, amputation of root, replantation, crown-radicular separation, cystotomy and cystectomy, alveolectomy, sinusotomy, curettage, gingivotomy, gingivectomy, flap operation in the treatment of periodontitis, at the opening of abscesses, and others.

Using a local anesthetic with vasoconstrictor is contraindicated in patients with hyperthyroidism, malignant hypertension, myocardial infarction, which was moved less than two months ago, unstable stenocardia, ventricular tachycardia, polymorphic ventricular arrhythmia, atrioventricular blockade, acute pulmonary edema and acute form of diabetes. You can't combine this anesthesia with tranquilizers and neuroleptics. In this case it is better to use the same local anesthetic concentration of 3-4% without vasoconstrictor, if the drug has no contraindications.

During pregnancy and breastfeeding of infants should be remembered that local tools easily pass the placental barrier in the free ionized form, as well as other molecules, the molecular weight of less than 600 units. At pregnancy is the preferred anesthetic with a pronounced coupling to protein and low liposoluble.

Studies show that during pregnancy the drugs of choice are the drugs of Articaine in which the percentage of protein binding is 95%, while in mepivacaine - 78%, and lidocaine - 64%. Articaine also has the advantage at liposoluble - 17 units versus 19.3 and 46.4 in mepivacaine-lidocaine.

Due to the risk of maternal and fetal methemoglobinemia, prilokayin use is prohibited for pregnant women.

Using drugs lidocaine and its analogs for local anesthesia, always should remember that it is contraindicated in patients with hepatic impairment (cirrhosis, porphyria), with atrioventricular conduction disturbances, uncontrolled epileptic treatment. Lidocaine is used with caution in patients who are treated with anticoagulants. There is the fact that lidocaine should not be

used in athletes due to the fact that the drug contains active substances that cause a positive reaction doping control.

Local anesthetic mepivacaine and its analogues are very similar to lidocaine for pharmacological properties. Contraindications to its use are severe myasthenia gravis, low plasma cholinesterase, severe liver dysfunction.

Prilocaine and its analogues are less toxic than lidocaine and mepivacaine, but found that it causes methemoglobinemia in a while lidocaine has a more cerebral cardiovascular toxicity.

Drugs of articaine are contraindicated for children under 4 years old, and patients with severe cardiovascular disease. In addition to patients aged 70 dosages should be reduced by one-third and two times at the age of 80 years. This is due to the fact that with age, hepatic, cardiac, respiratory and renal function decline.

To avoid errors and complications in the selection and use of a local anesthetic, first of all it is necessary to examine the sources of information in its properties and contraindications to interview the patient about the presence of a comorbidity and allergic status.

The choosing of similar solutions of local anesthetics that are manufactured by different companies, it is determined by the physician, his habits and sympathies. So, analogs of articaine are ultracaine (company Hoechst), septanest (Septodont) and ubistezin (ESPE).

We did comparative analysis of the above drugs of articaine in depth, time of occurrence and duration of anesthesia at 75 volunteers. For objectivity of study all drugs were coded and applied the principle of "placebo". The study found no significant benefits of drugs one company from another. We concluded that the success of anesthesia in most cases depends not only on the properties of the local anesthetic, but on the technique of local anesthesia physician

ownership, mental and emotional condition of patients, individual anatomic and topographic features of the structure of the maxillofacial area, the presence or absence of signs of inflammation at the site of surgery.

The use of local anesthetics should be tailored to the individual maximum dose. Usually it is calculated in accordance with the body weight of the patient. Surgeon-stomatologists must provide the maximum possible analgesic effect using a minimal amount of anesthetic.

German Dental Association in this regard recommends using a dose that did not exceed 50% of the maximum value of the toxic dose.

These values are not absolute and are based on data from experiments and tests of statistical research. However, given the differences in the physiology of the organism and the patient's health, toxic reactions can occur when using non-toxic doses. In cases where during operation it is necessary in the amount of local anesthetic, which exceeds 50% of the maximum dose, you should be able to provide emergency care to a patient, which includes the possibility of intravenous injection, inhalation of oxygen, and assisted mechanical ventilation, etc.

Ball (2000) recommends to determine the maximum dose of anesthetic approximately as rule "for every 10 kg of weight you can use 1 carpule of drug". In children, the dose is reduced twice.

CHAPTER IX. SELECTION OF MATERIALS FOR REPARATIVE OSTEOGENESIS IN SURGICAL TREATMENT OF JAW CYSTS

Due to the advent of a large number of different osteogenic materials and the lack of a sufficient number of independent information about them, the surgeons-stomatologists have the problem of choosing of required material for each specific clinical situation at the treatment of cysts of the jaws.

All materials for the restoration of bone tissue origin are divided into:

1. Autogenic(donor is the patient)
2. Allogeneic (donor is another person)
3. Xenogeneic (donor is an animal, but not human)
4. Alloplastics (synthetic, including those derived from natural minerals)

According to the classification (Edward, Cohen, 1988), that was compiled on the basis of the severity of the inductive potential to replace bone tissue all materials can be divided into osteoinductive, osteoconductive, osteoneutral and materials for directed tissue regeneration. This classification was completed in the relevant sections of the new modern drugs (Ostrovsky, 2011), which recently appeared in the stomatological market. This author took some materials that are not biodegradable to a group of osteoconductive implants, despite the fact that at the original classification, they are osteoneutraln implants.

I. OSTEOINDUCTIVE IMPLANTS.

Osteoinduction (Urist and McLean, 1952) – is the ability of a material to cause osteogenesis, cementogenesis and growth of periodontal ligament.

A. autografts

1. Extraoral - ilium, rib

a. Fresh

b. Frozen

2. Intraoral

a. Bone clot - a mixture of bone

b. Tubers

c. Zones of extraction

d. Mental area

e. The body and the mandibular branch

B. Alloimplants

1. Alloimplantat of demineralized lyophilized bone (ADLB)

2. Alloimplantat of lyophilized bone (ALB)

In the process of demineralization and bone degreasing collagen matrix and inductive proteins are released (bone morphogenetic protein (BMP)) that induce osteogenesis. The degree of severity of osteoinductive potential may depend on the characteristics of the process used to produce the material. For example, use of ethylene oxide reduces osteoinductive effect compared to the process of ensuring sterility using aseptic manufacturing technology (Sogal co-authors, 1997).

It is important to remember that ADLB has more potential of induction than intraoral material, but smaller than the graft from the ilium bone (Bowers

co-authors, 1985). However, autograft from iliac crest is not recommended to use in the vicinity of the roots, in connection with a possible resorption of them.

II. OSTEOCONDUCTIVE IMPLANTS.

Osteoconduction (Urist co-authors, 1958) – is the ability of a material to play the role of a passive matrix for new bone.

A. Allogenic implants

1. Organic matrix

a. Alloimplant of lyophilized bone (ALB)

b. Alloimplant of demineralized lyophilized bone (ADLB)

2. Inorganic matrix

a. Porous hydroxyapatite (Osteomin)

B. Alloplastic implants

1. Porous hydroxyapatite (Ostegraf/LD, Alhypor)

2. Porous hydroxyapatite (Ostegraf/D, PermaRydzh, Interpor)

3. Biologically active glass (PerioHlas, BioHran)

4. HTR - polymer

5. Calcium sulfite (Kapset)

S. Xenimplants

1. Porous hydroxyapatite (Osteograp/N, Bio-Oss)

III. OSTEONEUTRAL IMPLANTS.

Completely inert implants are only used to fill the space. Froum et al (1982) described them as biocompatible foreign bodies in the thick of tissues that are not support for new bone.

A. Alloplastic materials

1. Absorbable - Beta tricalcium phosphate
2. Not absorbable - durapatit, not-porous hydroxyapatite (Interpor, PermaRydzh, Osteograf/D), NTR-polymer
3. Metallic – dental implants, fixing screws and plates used in maxillofacial surgery

IV. DIRECTED TISSUE REGENERATION.

(Ellegaard and co-authors, 1976) – is the ability of a material to prevent apical epithelial proliferation.

A. That is not biodegradable (Gore-Tex, Tefhen)

B. That is absorbable

1. Natural

- a. collagen (Bio-Hyde, Bio-Mend)
- b. demineralized freeze-dried laminated bone (Lambon)

2. Synthetic

- a. calcium sulfat (Kapset)
- b. polymeric (Atrysorb, Epi-Hyde, Rezolut, Vikril mesh)

As seen from the classification ADLB and ALB have inductive and conductive properties simultaneously. At the same time we should not think that drugs are in the same group can be used in similar clinical situations. As much for the indications for use of a particular drug affects is not the origin, but is material absorbable, or not, and the mechanism of resorption.

Materials such as Interpor, PermaRydzh, NTR-polymer Osteograf/D, referred to osteoconductive and osteoneutral implants, because their surface has osteoconductive properties, while they themselves are largely to fill the space.

Special attention should be given to material made from hydroxyapatite. They include quite a number of domestic and foreign products. These materials can be divided into three groups:

- 1) Natural (animal origin, such as Osteograf/N and Bio-Oss) that is resolved by cellular resorption, in other words, only when by the patient's own bone replaced;

- 2) Synthetic absorbable (Osteograf/LD, osteogenic, Hydroxiapol, Alhypor). They absorbable in tissue fluids, regardless of the degree of filling of bone defects of patient;

- 3) Synthetic non-absorbable (Osteograf/D, PermaRidg, Interpor).

Taken into account mechanisms for dispersal indications for use are determined.

Natural hydroxyapatites are obtained from bones of cattle. Such hydroxyapatites are preferred for use in periodontics and maxillofacial surgery by reason of resorption of the material. There are two main ways of obtaining of inorganic bone matrix, but rather the removal of proteins and other organic

substances from animal bones. In one of them, (Osteograf/N) it is achieved by use a high-temperature water. In otherwise (Bio-Oss) – by using of relatively low temperatures and chemical solvents.

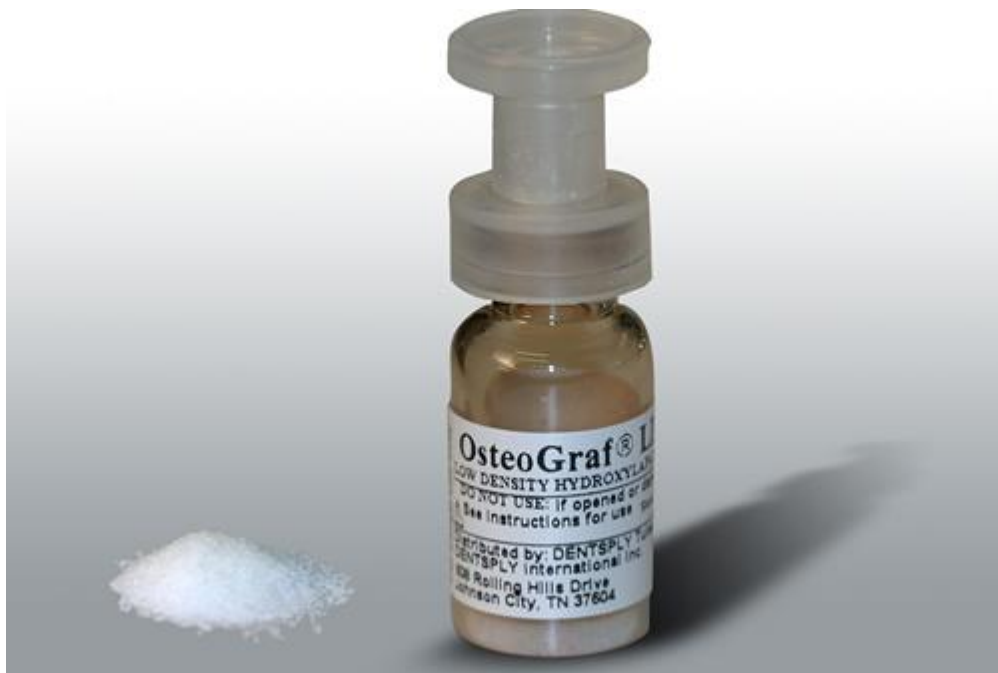

Figure 66.
Osteograf/N



Figure 67.
Bio-Oss

The first method is slightly better because unlike the other allows you to remove 100% of protein and get the only material of animal origin, which fully meets the ASTM F1581-95 "Structure of inorganic bone substitutes for use in surgery." The presence of residual proteins in the material obtained with

relatively low temperatures, is a substrate for allergic reactions and prevents the attachment of osteogenic cells to the surface of hydroxyapatite crystals (Sogal et al., 1998). In addition, Bio-Oss offered in the U.S. market, is obtained from American cows.

Synthetic resorb materials are intended as a low-cost replacement of natural hydroxyapatites. However, due to the characteristics of resorption indications for their use are limited to defects of the two or three sides, situations where there is a high probability of rapid regeneration of bone adjacent to the defect sites.

Synthetic hydroxyapatite, which is not absorbed, has only two indications for use: 1) filling defects and alveolas after tooth removal when no longer provides for the installation of dental implants. That is, synthetic hydroxyapatite helps to maintain bone morphology in order to provide support for the denture and prevents defects; 2) as PermaRydg material placed on the surface of the ridge and serves as support for dentures if any significant atrophy of the alveolar ridge of the mandible.

The easy-graft is bioresorbable material, completely synthetic bone graft substitutes for bone defects. They consist of two components: Granules and BioLinker. When combining these two components, the easy-graft material becomes a putty-like biomaterial and can be applied directly from the syringe into the bone defect. In contact with body fluids such as blood or saliva the material hardens within minutes and forms a stable, porous bone substitute material. Due to the porosity of the material, the absorption of blood is possible and thus positively influences the healing process.



Figure 68.
The easy graft

The synthetic bone grafting material Cerasorb supports the structure of the patient's own bone, is fully resorbed, while new bone is formed. It is an alternative to cancellous bone due to its chemical and biological properties which ensure physiological defect repair. With Cerasorb a second stressful procedure for harvesting cancellous bone can frequently be avoided. In the course of patient information potential risks of infection and allergy associated with materials of biological origin need not be addressed.

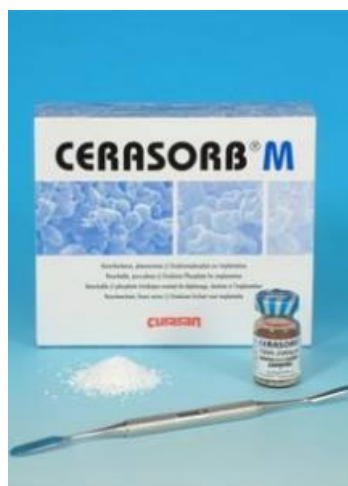

Figure 69.
Cerasorb

The calcium sulfate (Kapset) is osteoconductive material and textile materials for direct regeneration. This is due to the fact that calcium sulfate is a special ultra-pure surgical plaster and thus it can be used for both filling defects (mixed with hydroxyapatite, or demineralized lyophilized bone) as well as

membrane, causing divorced pasty state to calcium sulfate over the defect, then the material hardens quickly. Thus Kapset is a source of calcium for the new bone formed and prevents migration of particles of hydroxyapatite ADLK or field defect. Fill only one defective calcium sulfate can't be. In addition, Kapset is one of the few membrane, opening them in the process of wound healing is not an indication for removal of the material. Moreover, when we use Kapset the complete matching of flaps by suturing wounds is desirable but not required.

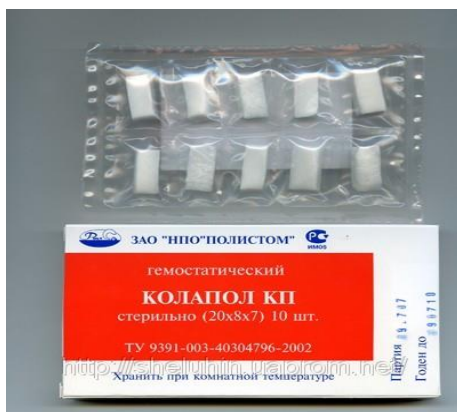

Figure 70.
The calcium sulfate

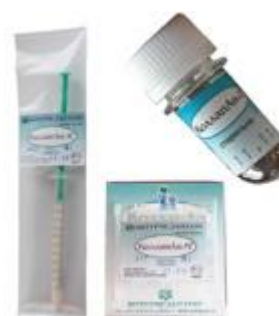Often collagen is added to materials made from hydroxyapatite. Since all currently used collagen is of animal origin, some drugs (Colapan and Colapol) are a combination of xenogenic or aloplastic materials (hydroxyapatite) and collagen. Colapan, Colapol and their variety is only known to the materials that are a combination of synthetic hydroxyapatite and collagen. It is believed that collagen has the ability to attract osteogenic cells and promotes their attachment to the surface of hydroxyapatite.

Almost a third of the mass of vertebrate proteins accounts for the share of collagen. Quantitatively collagen predominates over all other proteins (6% of body weight). Collagenous connective tissue composed of fibers composed of collagen fibrils. This filament is organized differently depending on the biological function of connective tissue. Fibrils composed of polypeptide subunits (tropocollagen), which is concluded in a parallel beam type "head to

tail". It is necessary to clearly distinguish between the concept of "collagen fibers" and "collagen". Collagen fiber is heterogeneous formation and contains in addition to the protein collagen, and other chemical components. Molecule of tropocollagen - this is the protein collagen.



Colapol



Colapan

Figure 71.

Now we know at least 13 types of collagen. The most common are first five collagen types. Related to bone collagen I and to a much lesser extent V types. It is known that type I collagen is also a member of the tendons and bones. However, collagen type I bone differs in chemical composition.

We know that not all collagen attracts osteogenic cells, and only a small portion of its molecules. Scientists SeraMed Company (USA) was able to determine the sequence of 15 amino acids constituting the peptide that facilitates migration of osteoblast precursors (Jing Jing Qian, 1996). This peptide, called P-15, was able to synthesize in the laboratory and apply it to the surface of particles of natural hydroxyapatite. Ready drug called "PepGen P-15" and its future in dental practice seems extremely promising.

Another interesting material that has appeared recently is Endoheyn which is the enamel matrix proteins, repairing cement root and periodontal communication, which in turn promotes regeneration of alveolar bone.

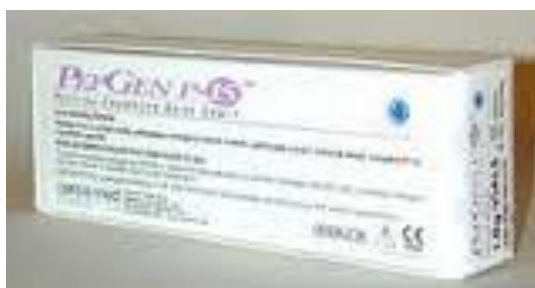

Figure 72.
PepGen P-15

Demineralised freeze-dried laminated bone (Lambon) – is membrane for directional tissue regeneration, which also owns osteoinductive and osteoconductive properties. The only disadvantage is the relative high cost of the material.

Bone morphogenetic protein - 2 (BMP-2). The clinical trials of BMP-2 is not yet completed, but the available results show outstanding performance of this material. Rather, the drug will be soon available on the stomatological market.



Figure 73.
Bone morphogenetic protein – 2

Summarizing all the above said, the most effective materials for restoration of lost bone are currently the autologous and allogenic bone. Many aloplastic materials that available on the market today, help to stabilize the clot and prevent shrinkage of tissues. But it is still debated their ability to stimulate the formation of new bone.

Marketing.

Competition in the market causes companies to resort to such methods of promotion of drugs that can provide the required level of sales. These methods are basically honest, but not always correct. To avoid downloading unnecessary information practitioners give only a few specific examples:

A. Inorganic bone matrix derived from animal material means natural hydroxyapatite, which hold back some producers to allocate their preparation of a series of hydroxyapatite and give it a different status.

B. If contraindications or side effects not detected, this does not mean that they are not. In any textbook on pharmacology states that there are no medications without side effects. Contraindications and side effects do not necessarily reveal their possible fate with sufficient confidence to assume (eg, the use of products containing antibiotics, organic matter (collagen) can not deny the possibility of allergic reactions, however, allergic reactions can occur on almost any -material). To his credit, foreign manufacturers - the instructions for use, they always point to the possibility of even the most incredible side effects (perhaps because they have a legal responsibility to provide complete and objective information about their products).

C. Publication of colorful brochures (of course, necessary and informative), but diverts attention from medical instructions are attached to each product. However, it is in the instructions the manufacturer provides complete and accurate information, so it cannot be ignored in any case.

D. In advertising materials based on hydroxyapatite manufacturing companies often appeal to transfer the danger of infectious diseases using

ADLK. And at the same time combined with collagen-hydroxyapatite (including cadaveric origin).

E. It is extremely critical to treat these studies presented in brochures, pamphlets different companies often give information about the diametrically opposite effect of the same material. Although due to the lack of reliable scientific data in local dental periodical publications Russian dentist more often nowhere to draw at least some information that deserves attention. However, the problems of our publications below.

F. Information on the benefits of using a particular drug or material must draw from independent sources.

A few words about domestic materials cadaveric origin. It is possible that all the preparation, fencing, demineralization, degreasing, sterilization carried out in accordance with all requirements. But the lack of clear laws regarding organ donation, sufficient material base and businesses (such as banks tissues, often non-profit organizations with enormous financial opportunities and a strong research base) make difficult undertaken to ensure quality control, which is a crucial criterion in today's health (and only) production.

Each batch produced abroad cadaveric material origin accompanied by an official document stating the following parameters: age, donor cause of death (usually trauma), the results are tested for syphilis, HIV (including HIV-1 DNA), hepatitis B, and hepatitis C virus T-cell lymphoma Rights (VTLCH-1) (of course all negative), the social behavior of the patient (if suspected of belonging to a group of social risk patient is automatically excluded from the application of the donation), the name of the laboratory transfer standard tests, doctor name responsible for the tests.

In the preparation of the manual, we examined the large number of foreign and domestic literature, and concluded that the vast majority of the articles cannot be considered in any way objective, and often there are reports of clinical cases, or is an advertisement.

In this regard, it should be very carefully and critically relate to the whole of received information. In fact, the total lack of work that meet the standards of current medical literature, as it may seem, it eliminates the need for a dental surgeon in the ability to critically interpret articles published in dental journals. Since not everyone finds appropriate to spend time and energy just to increase their knowledge in this area.

CHAPTER X CHOICE OF SURGICAL METHODS AT TREATING THE JAW CYSTS

Methods that remove the cyst agents that destroy of tissue (iodine tincture, silver nitrate, acids and caustic alkalis) are unsuccessful and now clinical research in this area is completely stopped.

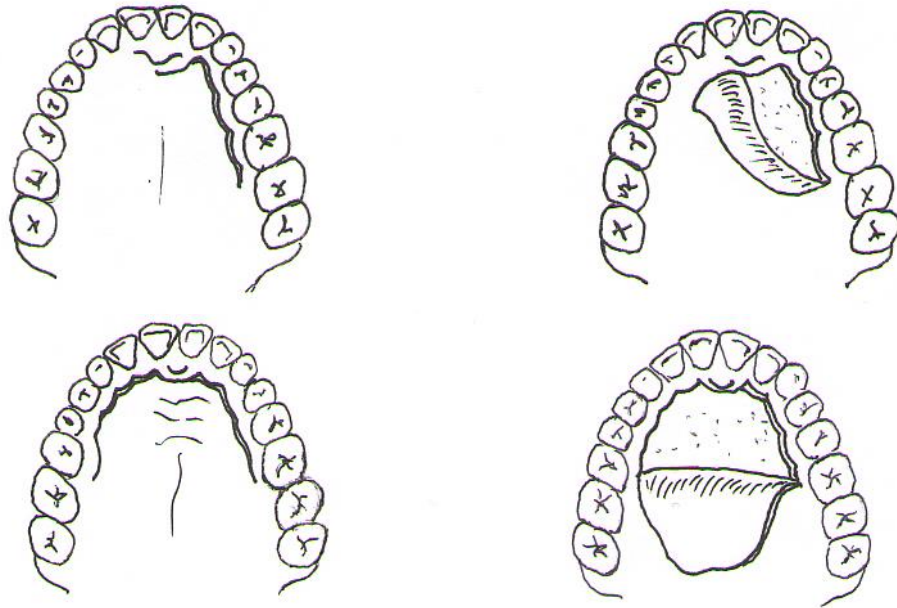


Figure 74.

Scheme of incisions at surgical treatment of maxillar cysts at palatal access.

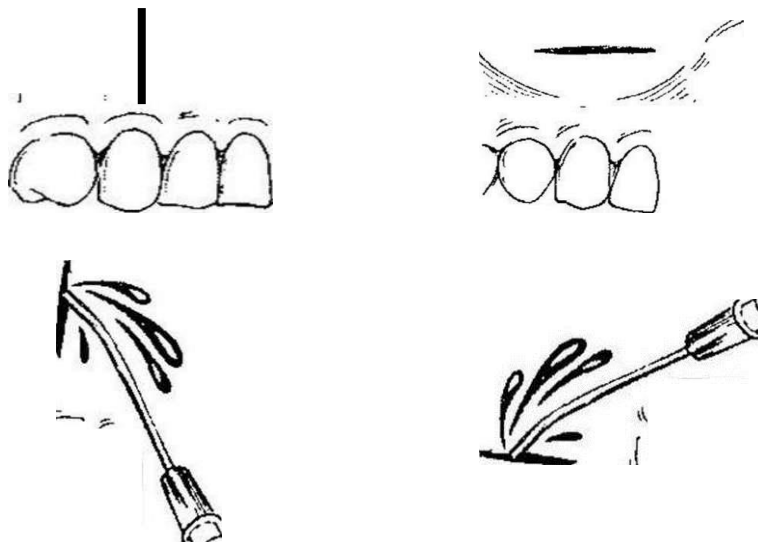


Figure 75.

Vertical and horizontal incisions at suppurate cysts

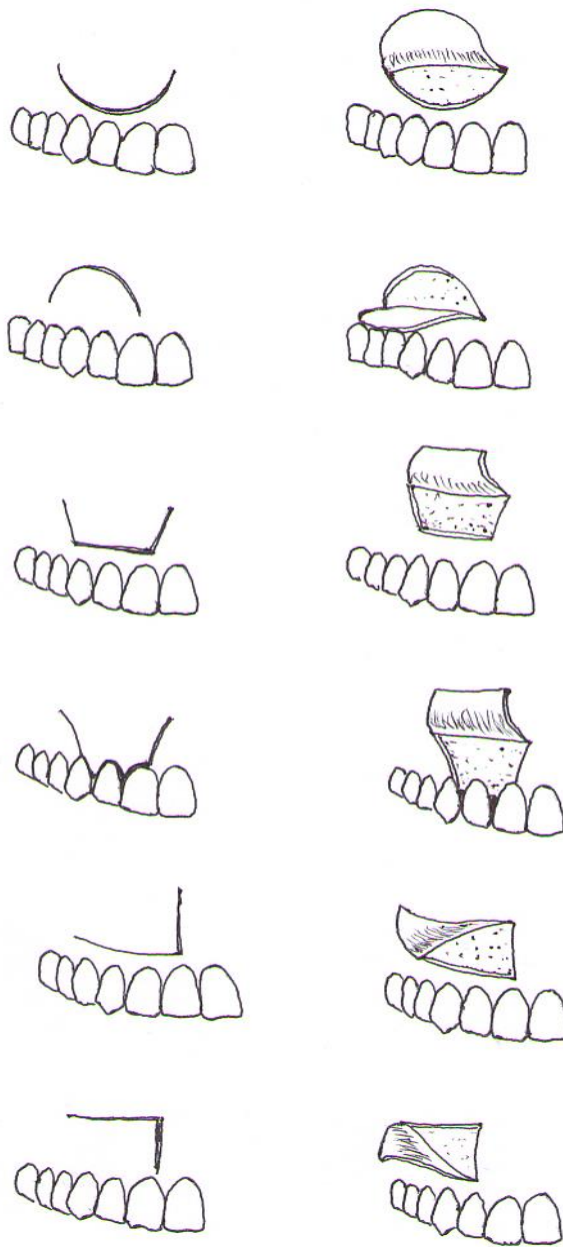


Figure 76.

Incisions for formation of mucous-periosteal flap at cystotomy and cystectomy (oviform, oviform at cystotomy with preserving of tooth, trapezoidal, trapezoidal to the necks of the teeth, L - shaped, L - shaped at cystotomy with preserving of tooth,)

Sometimes small radicular cysts can be extracted together with roots during tooth extraction.

In case of separation of cyst from the root it is possible to do scraping of alveola by spoon.

Treatment of jaws cysts can be only surgical.

Two basic types of operations are conducted: cystotomy and cystectomy. These methods were developed and described in 1892 and 1910 by surgeon Partsch and called – Partsch I and Partsch II.

Cystotomy, known as Partsch I, was offered much earlier by french surgeon Dupuitren. Partsch only made detailed description of this method. Therefore, cystotomy should be called like operation by Dupuitren-Partsch.

Cystectomy (PARTSCH - II)

Method of operation involves the removal of all epithelial and connective tissue membrane of cyst cavity.

First method of cystectomy was operation of Bramant, which provides formation of mucoperiosteal flap, leg of which is addressed to the transitional fold, removing of deformed and thinned bones and all shells of cysts and placing of flap in the bone cavity. This method has no risk of recurrence because the periosteum flap not adjacents to the membrane of cyst, but to the bone.

Partsch changed this classic technique (operation Partch II). He formed mucoperiosteal flap projection in the largest protrusion of bone, separate it up on the upper jaw, and down on the lower jaw; extract deformed bone and cyst membrane. Then a cut mucoperiosteal flap is not placed into the bone cavity and fixing by seams on the original site. The cavity of the cyst at the same time filled with a blood clot or sealed by different osteotropic substances.

Indications:

1. Cyst, which is a malformation of odontogenic epithelium.
2. Cysts of small size in the area of 1-2 teeth.
3. Cyst in the maxilla, which grows in the maxillary sinus or pushes it, without signs of inflammation.
4. Jaw cysts in areas that don't have teeth, while maintaining bone walls in the edge of the mandible, floor of the nose.
5. Follicular cyst when permanent tooth follicle is lost (changed color that is not natural shine of the crown, the tooth is soft, which is determined by the operation), often is the case with festering cyst.

Surgical technique:

The operation is performed under conductive and infiltration anesthesia.

In the vestibular surface of the alveolar process of the jaw mucosa is cut to the bone semi-ovoid or trapezoidal shape, mucoperiosteal flap is cut out with the base turning the side of the transitional fold. End of the flap in case of the presence of teeth should not be up to the gingival margin at 0.5-0.7 cm, while removing a tooth section passing through its hole. If the cyst is located close to the dental cervix at the gum edge flap include a gingival papilla. The magnitude of the flap should be more than cyst: it should be overlaps than the future bone defect, and the line of stitches not coincide with it.

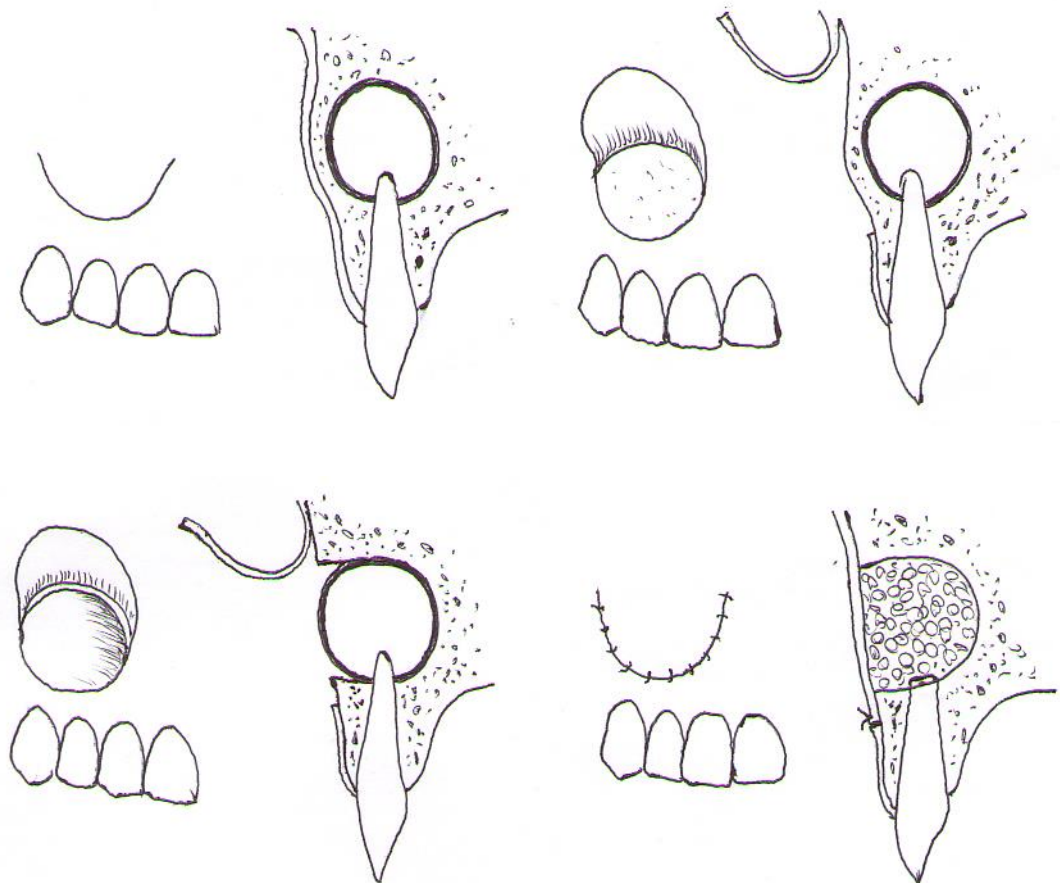


Figure 77.

Stages of cystectomy

Mucoperiosteal flap is striped from the bone by rugine, using gauze. The tampon is subsumed under rugine and then skeletoned the bone in the area of cyst. In the absence of bone it needed care when do stripe of the periosteum membrane from the cyst. Separated flap is hold by hooks or ligatures.

Over the cyst in projection of causal tooth apex using trepan drill it does holes around the perimeter of the future defect and connect them together. The bone plate round shape is removed, anterior wall of the cyst is open.

Size of the bone defect should enable examination of the cyst and root apex resection develops. With rugine, angular elevator and surgical tablespoons peeled cyst membrane that easily goes from proper bone, but kept in touch with the causal root of the tooth. To isolate membrane saw off the tip of the root to the surrounding bone and bone with root extract.

After resection of the root apex destroy of shells of cyst prevent the recurrence of the cyst.

However, if the cyst is located close to the neck of the causative tooth preservation latter impractical because after resection of the root apex and stump not withstand load quickly growth. Multi-root tooth usually can't be save (due to obstruction of channels), and it is removed. Or, if the cyst comes from one of roots possible of the operation of cystectomy root amputation or hemysection of tooth.

After resection of the root apex, when viewed from the stump is necessary to determine the presence of cement in the root canal, in it absence it is necessary to do retrograde filling by amalgam or special cements (ProRoot MTA). This action prevents inflammatory of bone wound as a result of infection from the root canal.

After removal of the cyst membrane roots of adjacent teeth that was prepared earlier and exposed, should be also resected.

After removing the bone and bone cutters smoothing edges and roots to the level of surrounding bony walls, the cavity was washed with hydrogen peroxide. Then conduct an audit of the bone cavity filling material is removed pieces that left over. The cavity is filled with a blood clot, which is a reliable biological factors in wound healing.

Today, some surgeons fill the cavity by bloody hemostatic sponge and injected streptocide or dry powder antibiotic.

Modern technology allows improve cystectomy procedure.

To activation of osteogenesis bone cavity appropriately is filling by biocomposit osteoplastic materials.

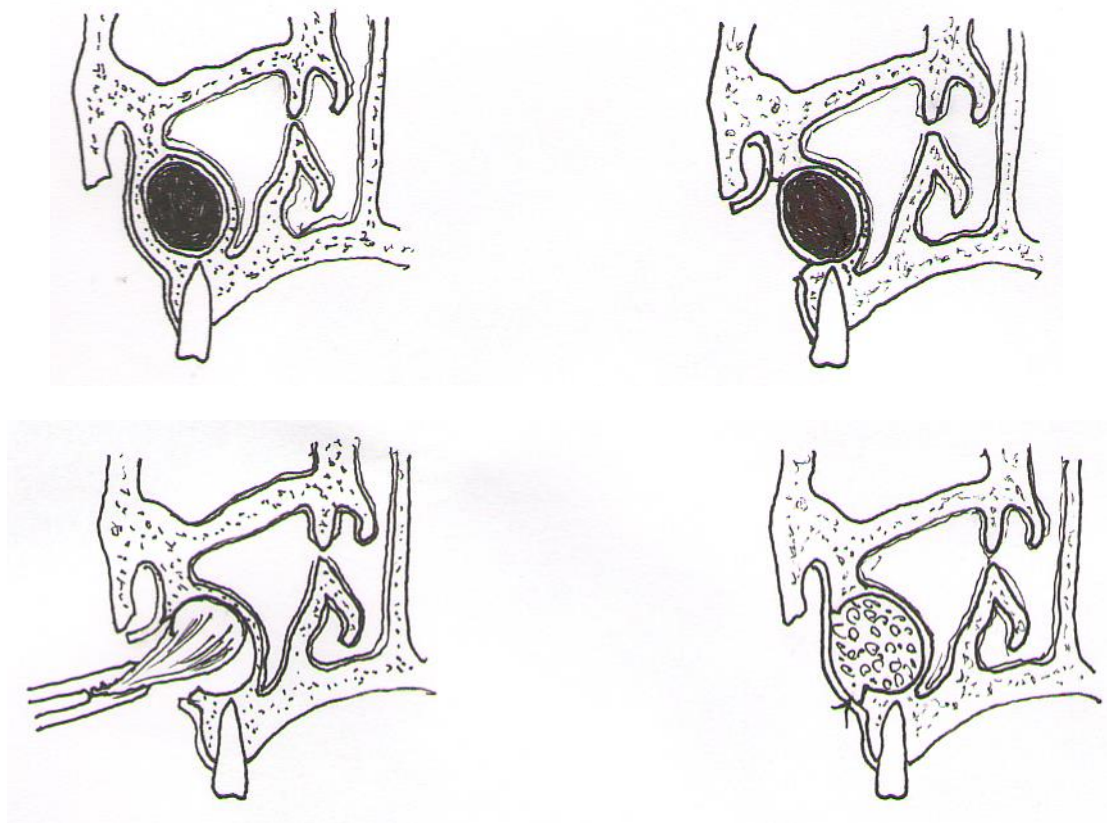


Figure 78.

Stages of cystectomy with direct reparative osteogenesis

Biocomposit material which fills the bone cavity prevents early complications. This is due to the lack of a blood clot, which significantly reduces the transmission cavity.

Biocomposit material filling the cavity of the cyst, promote restoration of form and function of the jaw by speeding up regeneration.

After filling the cavity flap laid in place, the wound edges is closed by knotted sutures of catgut, sometimes with silk.

In case of flap reduction it should be mobilized by the linear section of the periosteum at the base.

Externally pressing bandage - "mouse" to restrain the cheeks and lips and creating peace postoperative area not less than 4-5 days.

Assign pain relievers, antihistamines, according to conduct anti-inflammatory therapy.

The patient is unable to work for 6-7 days. Healing occurs through the bone cavity by blood clot, as after tooth extraction.

In the presence of large cavities required radiographic examination for a long time (up to 1-2 years).

If infected blood clot develops inflammation. It is necessary to create a flow of fluid between the seams or do the puncture of cavity out of line and wash it seems by antiseptic solutions. Daily washing for 3-4 days often interrupt inflammation. At long festering wound edges during diluted, washed it, injected into the cavity by loosely iodoform swab, putting a flap inside. As granulating wounds (2-3 weeks) swab is displaced, it gradually are cut and removed.

The negative sides of cystectomy include:

- 1) It is necessary to resort to more advanced filling of teeth;
- 2) The risk of perforation of the mucous membrane of the nasal passages in cysts of the upper front teeth;
- 3) The possibility of opening the maxillary cavity in cysts in molars and maxillary premolars;
- 4) Exposure of the inferior alveolar nerve damage and homonymous artery and vein for large cysts body of the mandible, which often leads to severe bleeding and prolonged paresthesia in chin area.
- 5) Operation cystectomy requires complete removal of the cystic sac, leaving at least a small trace of it leads to recurrence of the cyst.

Cystotomy (PARTSCH - I) - involves the removing of only the front wall of the cyst. At that cyst becomes a cavity that communicates with the oral cavity.

The cyst wall is dissected for the purpose of evacuation of its contents. This operation produces at emergence indications, at acute purulent inflammation.

Indications:

1. Cyst, when 3 and more intact teeth are projected into the cavity on the radiograph, at the root of teeth periodontal crack is not defined;
2. Big size of cyst when bone walls of the maxillary sinus, nasal passage floor are destroyed;
3. Cyst in children in which the operation can save the follicles of permanent teeth
4. Patients with severe concomitant diseases;
5. Larger cysts of the mandible with a sharp thinning of bases jaw (bone thickness is less than 0.5 cm);
6. Follicular cyst;
7. Patients elderly and senile age.

Surgical technique.

Preoperative preparation of teeth for cystotomy unlike cystectomy affects only the causative tooth, while others, though involved in the area of cysts after surgery still cover by its shell.

The operation is carried out under local anesthesia. Semi-oviform mucoperiosteal flap is cut out, its size should be less than the future bone defect. While maintaining the causal tooth base of flap can be (which is preferable) turn to the gingival margin to closing of stump resected root.

After exposure of the bone wall near the cyst trepanation hole are made, the size of which shall not be less than the diameter of the cyst, because the process of healing is a narrowing of the bone defect.

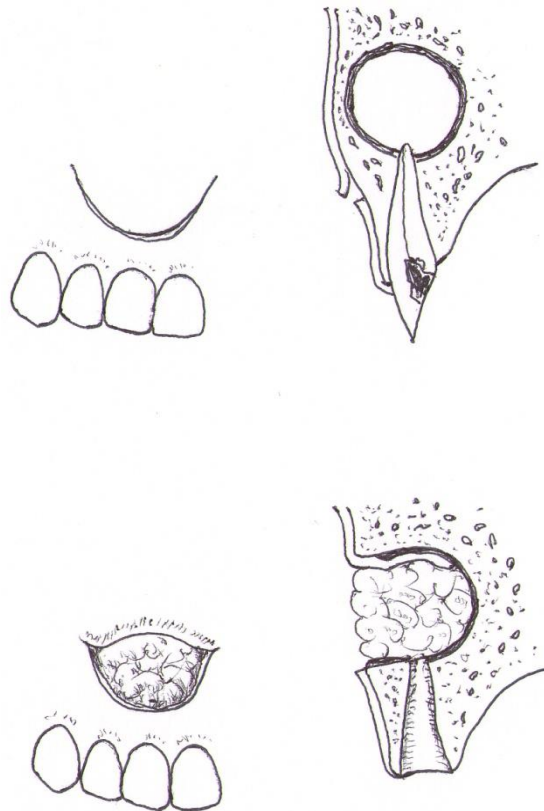


Figure 79.
Stages of cystotomy

For large cysts that localized at jaw branch, size of bone defect shall be sufficient to maintain communication with the oral cavity. Cystic cavity is washed; mucoperiosteal flap is turned directly into the front of the cavity and holded by iodoform gauze. Some authors fix screwed flap to shell cysts by

seams, cystic binder used and the wall to the edge of the wound of the mucous membrane of the mouth vestibule.

Cystotomy from the palatine in cases of bone defect is to remove mucoperiosteal flap like diameter of the cyst; sometimes in a cavity swab is leaved.

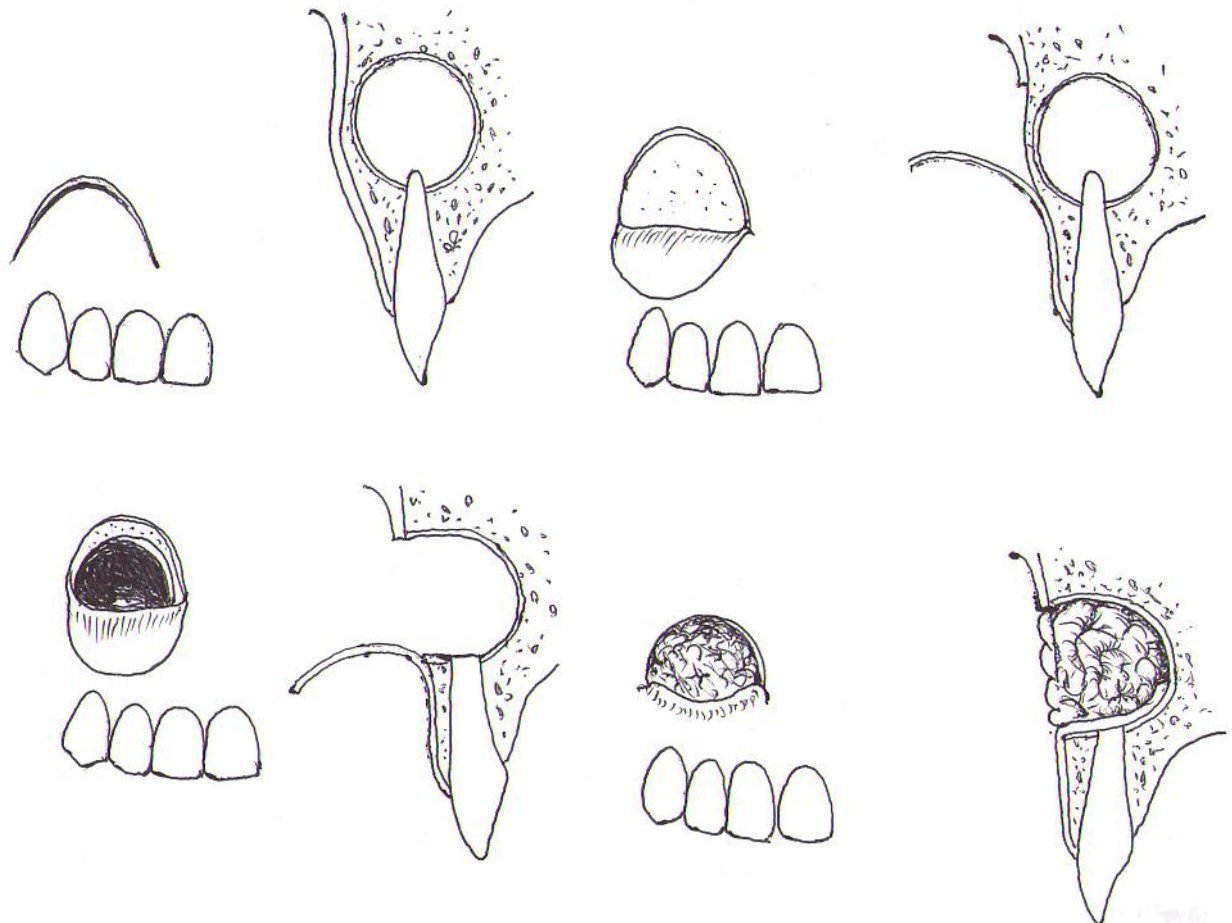


Figure 80.

Stages of operation cystotomy with preservation of tooth

After 6-8 days after operation produce change of iodoform tampon, so far it slime and begins rejected. This change is carried out to 3, at least 4 times. Wound edges usually became epithelized and formed an additional cavity that communicates with the vestibule and the oral cavity to the end of the 3rd week. Patient wash it with antiseptic solutions by himself. In some cases, it is

necessary to do the obturator of self-curing plastic. Otherwise, overgrowth of bone and mucosa around the edge of the hole will lead to the closure notice. Obturator, with the growth of bone cutter grind off, not decreases its diameter. Healing time, especially at big postoperative cavities can be to 1.5-2 years. Working capacity of patients after surgery disturbed by an average of 5-6 days.

At cystotomy that held in radicular cysts from temporary teeth, the tooth is removed, the roots of which are located in the cavity of the cyst, the latter is emptied through the hole in the alveolar process. "Window" into the cavity of the cyst we do through the hole of the removed tooth. It allows to provide for the eruption of permanent teeth. After emptying of the cyst its cavity is closed by iodoform gauze. First, it is changed after 3 days, and then - one day a week until the cyst cavity became epithelized and permanent tooth is erupted.

The positive sides of this intervention are its minimal trauma and create optimal conditions for the eruption of permanent teeth in the correct position, in the dental arch.

The negative side of cystotomy is necessity of prolonged postoperative care of the open cavity of the cyst (sometimes up to several months) until it has acquired a flattened shape.

Oronazal cystectomy

The essence of the intervention is to connect the maxillary sinus with the cyst cavity and formation of single cavity that connect with the lower nasal passage.

Indications:

1. Missing teeth within the cyst.
2. Incorporate of 1-2 teeth in the area of cyst.

Oronazal cystotomy.

Indications:

1. Presence of a large number of intact teeth that inverse into the cyst cavity;
2. Presence of comorbidities.

Surgical technique.

The operation is performed under local anesthesia. Incision of tissue to bone produce 0.5 cm below the transition fold from the second incisor to the second or third molars. In case of simultaneous removal of the causative tooth trapezoid incision passes through the socket of the tooth.

Anterior wall of the maxilla is divided and the bone is skelated. At oronazal cystectomy it should remove all shell of cysts, make resection of sealed roots apexes, connect the cavity with the maxillary sinus, remove bone jumper between them. Only polypous changed parts of the mucosa are removed from

sinus, creating anastomosis with inferior nasal passage. After do the sutures of the wound from oral side. As a result of the operation the lower part of the cavity detected with bare bony walls, which are then granulated, scars and partially epithelized.

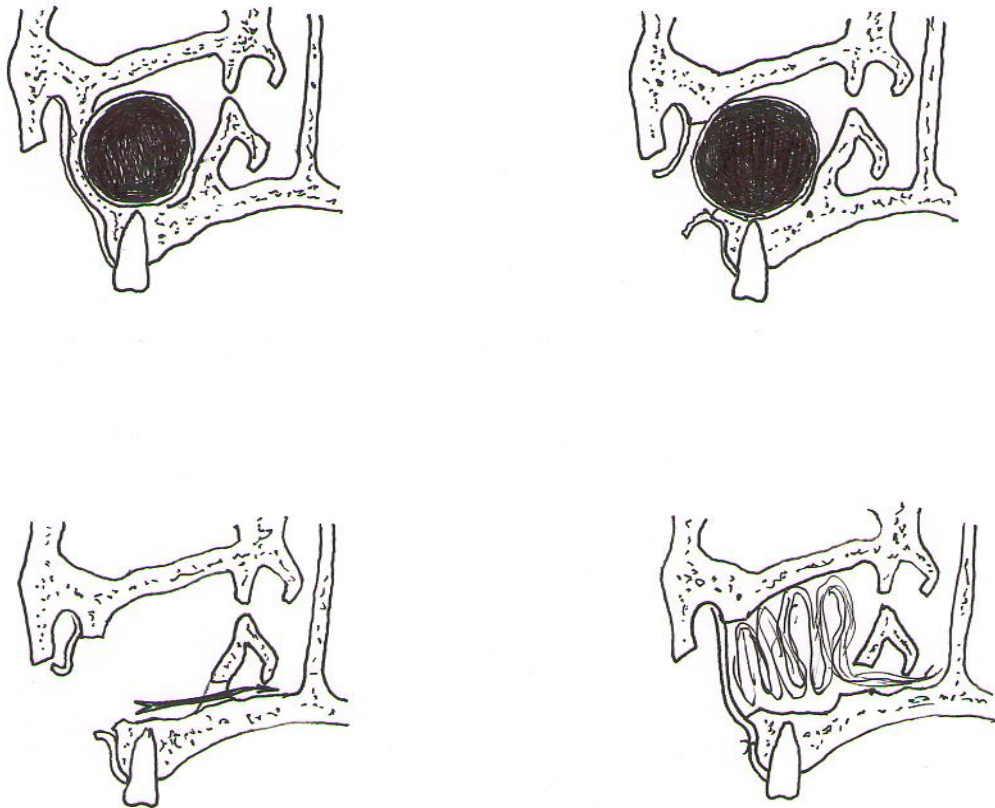


Figure 81.

Stages of oronasal cystectomy

As usual cystectomy, oronasal cystectomy is radical surgery and more traumatic than oronasal cystotomy.

At oronasal cystotomy it is necessary to remove only the front and upper shell of the cyst; do not make resection of the roots apexes of intact teeth. As a result oronasal cystotomy lower part of the cavity becomes fast epithelized.

Plastic cystectomy

The shell of the cyst is removed completely, but the wound is not sutured and a forming cavity is tamponed by iodoform gauze.

Indications:

1. Decaying cyst, without warranty of primary wound healing;
2. It may be the result of cystectomy that is complicated by suppuration.

Two-stage operation

Stage 1 – is decompression surgery.

For a long period creates it make the combination with oral cavity like cystotomy sufficient for making the outflow of cystic cavity, but not large diameter.

Second stage – is cystectomy. It produced an average after 1-1.5 years.

Indications:

1. Larger cysts that are defect tooth forming epithelium (toothcontain and keratocyst) capable to recurrence and degeneration;
2. Radicular cyst of the upper jaw, accompanied by destruction of bone floor of the nasal cavity;
3. Radicular cyst of the mandible, occupying its body and branches.

Benefits of operations:

1. It is not traumatic.
2. It is possible to do at polyclinic

3. Possible to keep shape and size of the jaw, despite the prevalence of lesions,

4. Leads to complete recovery of the patient.

CHAPTER XI. COMPLICATIONS ARISING IN SURGICAL TREATMENT OF JAW CYSTS

Complications during surgery.

1. Bleeding that life-threatening for patient. Bleeding from the soft tissues are stop by tamponade by gauze pad. In case of injury of the lower alveolar artery tamponade of mandibular canal is carried.

2. Perforation of the maxillary sinus floor. In this case, the cystsinusotomy is followed by careful suturing of wounds of the soft tissues.

3. Fracture of the jaw. In order to prevent this complication before surgery should impose the individual wire. In case of fracture splinting is necessary to develop jaws and ensure complete drainage of the cyst cavity. Antibiotic therapy. Complete extirpation of a cyst is developed after consolidation of jaw fragments.

Postoperative complications.

1. The inflammatory reaction. After cystectomy in case of violation of the recommendations by patient (receiving antibiotics) it may be suppurating of wound. In this case, is necessary to remove the seams, wash the bone cavity and put enter iodoform turundas. Then carrying of the wound like cystotomy.

2. Paresthesia is a result of nerve damage. In postoperative period, the patient notes numbness in the area of innervation of the corresponding nerve. Treatment: used physiological and vitamins therapy.

3. Oroantral or oronazal anastomosis. To prevent this it is the necessary to do tight suturing of the edges of the wound, patient should compliance the guidelines (do not sneeze, do not smoke).

REFERENCES

1. Absi E.G., Sim R.L. Odontogenic keratocyst involving the maxillary sinus: report of two cases. *Dentomaxillofac Radiol* 1994; 23:226-229.
2. Agaram N.P., Collins B.M., Barnes L., Lomago D., Aldeeb D., Swalsky P., Finkelstein S., Hunt J.L. Molecular analysis to demonstrate that odontogenic keratocysts are neoplastic. *Arch. Pathol. Lab. Med.* 2004; 128: 313-317.
3. Ahlfors E., Larsson A., Sjogren S. The odontogenic keratocyst: a benign cystic tumor? *J Oral Maxillofac Surg.* 1984 Jan; 42(1): 10-9.
4. Anand V.K., Arrowood J.P.Jr., Krolls S.O. Malignant potential of the odontogenic keratocyst. *Otolaryngol. Head Neck. Surg.* 1994; 111: 124-9.
5. Anneroth G., el-Hajj G. Odontogenic keratocysts-a retrospective clinical and histologic study. *Int. J. Oral. Maxillofac. Surg.* 1996 Apr; 25(2): 124-9.
6. August M., Faquin W.C., Troulis M.J., Kaban L.B. Dedifferentiation of odontogenic keratocyst epithelium after cyst decompression. *J. Oral. Maxillofac. Surg.* 2003 Jun; 61(6): 678-83; discussion 683-4.
7. Bataineh A.B., al Qudah M. Treatment of mandibular odontogenic keratocysts. *Oral. Surg. Oral. Med. Oral. Pathol. Oral. Radiol. Endod.* 1998; 86: 42-7.
8. Barreto D.C., Gomez R.S., Bale A.E., Boson W.L., De Marco L. PTCH gene mutations in odontogenic keratocysts. *J. Dent. Res.* 2000; 79:1418-1422.
9. Barreto D.C., De Marco L., Castro W.H., Gomez R.S. Glandular odontogenic cyst: absence of PTCH gene mutation. *J. Oral. Pathol. Med.* 2001; 30: 125-128.
10. Barreto D.C., Bale A.E., De Marco L., Gomez R.S. Immunolocalization of PTCH protein in odontogenic cysts and tumors. *J. Dent. Res.* 2002; 81: 757-760.

11. Blanas N., Freund B., Schwartz M., Furst I.M. Systematic review of the treatment and prognosis of the odontogenic keratocyst. *Oral. Surg. Oral. Med. Oral. Pathol. Oral. Radiol. Endod.* 2000; 90: 553-8.
12. Bornstein M.M., Filippi A., Altermatt H.J., Lambrecht J.T., Buser D. The odontogenic keratocyst—odontogenic cyst or benign tumor? *Schweiz Monatsschr Zahnmed.* 2005; 115(2): 110-28.
13. Brannon R.B. The odontogenic keratocyst: a clinicopathologic study of 312 cases. Part I. Clinical features. *Oral. Surg. Oral. Med. Oral. Pathol.* 1976 Jul; 42 (1): 54-72.
14. Brannon R.B. The odontogenic keratocyst: a clinicopathologic study of 312 cases. Part II. Histologic features. *Oral. Surg. Oral. Med. Oral. Pathol.* 1977 Feb; 43(2): 233-55.
15. Browne R.M. The odontogenic keratocyst: clinical aspects. *Br. Dent. J.* 1970; 128(5): 225-31.
16. Brondum N., Jensen VJ. Recurrence of keratocysts and decompression treatment. A long-term follow-up of forty-four cases. *Oral. Surg.* 2000 Mar; 3: 35-40.
17. Browne R.M. The odontogenic keratocyst: histologic features and their correlation with clinical behavior. *Br. Dent. J.* 1971; 131: 249-59.
18. Chen S.Y., Miller A.S. Ultrastructure of the keratinizing and calcifying odontogenic cyst. *Oral. Surg. Oral. Med. Oral. Pathol.* 1975 May; 39(5): 769-80.
19. Chow H.T. Odontogenic keratocyst: a clinical experience in Singapore. *Oral. Surg. Oral. Med. Oral. Pathol. Oral. Radiol. Endod.* 1998; 86: 573-7.
20. Cohen M.M Jr. Nevroid basal cell carcinoma syndrome: molecular biology and new hypotheses. *Int. J. Oral. Maxillofac. Surg.* 1999; 28:216-23.
21. Eyre J., Zakrzewska J.M. The conservative management of large odontogenic keratocyst. *Br. J. Oral. Maxillofac. Surg.* 1985; 23:195-203.

22. Fantasia J.E. Lateral periodontal cyst: an analysis of forty-six cases. *Oral. Surg. Oral. Med. Oral. Pathol.* 1979; 48:237-43.
23. Farndon P. A., Del Mastro R.G., Evans D.G., Kilpatrick M.W. Location of gene for Gorlin syndrome. *Lancet.* 1992; 339: 581-2.
24. Forssell K., Sorvari T.E., Oksala E. A clinical and radiographic study of odontogenic keratocysts in jaws. *Proc. Finn. Dent. Soc.* 1974; 70: 121—34.
25. Forssell K., Forssell H., Kahnberg K.E. Recurrence of keratocysts: a long-term follow-up study. *Int. J. Oral. Maxillofac. Surg.* 1988; 17:25-8.
26. Garlock J.A., Pringle G.A., Hicks M.L. The odontogenic keratocyst: a potential endodontic misdiagnosis. *Oral. Surg. Oral. Med. Oral. Pathol. Oral. Radiol. Endod.* 1998; 85:452-6.
27. Giardina C., Caniglia D.M., Lettini T., Valente T., Poliseno G., Tantimonaco L., Favia G. Morphometric discrimination between syndromic and nonsyndromic keratocysts. *Anal. Quant. Cytol. Hystol.* 2001; 23: 373-380.
28. Gonzalez-Alva P., Tanaka A., Oku Y., Yoshizawa D., Itoh S., Sakashita H., Ide F., Tajima Y., Kusama K. Keratocystic odontogenic tumor: a retrospective study of 183 cases. *J. Oral. Sci.* 2008; 50:205-212.
29. Gorlin R.J., Goltz R.W. Multiple nevoid basal cell epithelioma, jaw cysts and bifid rib: a syndrome. *N. Engl. J. Med.* 1960; 262: 908-12.
30. Giinhan O., Yildiz E., Karslioglu Y., Aydintug Y., Dogan N., Celasun B. Nuclear morphometric features of epithelial cells lining keratocysts. *Anal. Quant. Cytol. Hystol.* 2003; 25: 85-89.
31. Hamamoto Y., Nakajima T., Ozawa H. Ultrastructural and histochemical study on the morphogenesis of epithelial rests of Malassez. *Arch. Histol. Cytol.* 1989; 52: 61-7Q.
32. Haring J.I., Van Dis M.L. Odontogenic keratocysts: a clinical, radiographic, and histopathologic study. *Oral. Surg. Oral. Med. Oral. Pathol.* 1988 Jul; 66(1): 145-53.
33. Hayashi K., Tozaki M., Yoshida N., Fukuda K., Tanabe H. Dynamic multislice helical CT of ameloblastoma and odontogenic keratocyst: correlation

between contrast enhancement and angiogenesis. *J. Comput. Assist. Tomogr.* 2002; 26: 922-6.

34. Hennis H.L. 3rd, Stewart W.C., Neville B., O'Connor K.F., Apple DJ. Carcinoma arising in an odontogenic keratocyst with orbital invasion. *Doc. Ophthalmol.* 1991; 77(1): 73-9.

35. Hodgkinson D.J., Woods J.E. Dahlin D.C., Tolman D.E. Keratocysts of the jaw: clinicopathologic study of 79 patients. *Cancer.* 1978; 41: 803-13.

36. Ide F., Shimoyama T., Horie N. Peripheral odontogenic keratocysts: a report of 2 cases. *J. Periodontal.* 2002; 73(9): 1079-81.

37. International Histological Classification of Tumors №3. Histological Typing of Odontogenic Tumors Jaw Cyst and Allied Lesions. Geneva: WHO 2005.

38. International Histological Classification of Tumors №5. Histological Typing of Odontogenic Tumors Jaw Cyst and Allied Lesions. Geneva: WHO 1971.

39. Kakarantza-Angelopoulou E., Nicolatou O. Odontogenic keratocysts: clinicopathologic study of 87 cases. *J. Oral. Maxillofac. Surg.* 1990; 48: 593-9.

40. Kaplan I., Anavi Y., Hirshberg A. Glandular odontogenic cyst: a challenge in diagnosis and treatment. *Oral. Dis.* 2008 Jan 31; 62(1): 651-5.

41. Kaplan I., Gal G., Anavi Y., Manor R., Calderon S. Glandular odontogenic cyst: treatment and recurrence. *J. Oral. Maxillofac. Surg.* 2005 Apr; 63(4): 435-41.

42. Kim S.G., Yang B.E., Oh S.H., Min S.K., Hong S.P., Choi J.Y. The differential expression pattern of BMP-4 between the dentigerous cyst and the odontogenic keratocyst. *J. Oral. Pathol. Med.* 2005 Mar; 34(3): 178-83.

43. Kolar Z., Geierova M., Bouchal J., Pazdera J., Zboril V., Tvrdy P. Immunohistochemical analysis of the biological potential of odontogenic keratocysts. *J. Oral. Pathol. Med.* 2006 Feb; 35(2): 75-80.

44. Kubota Y., Nitta S., Oka S., Nakagawa S., Ninomiya T., Shirasuna K. Discrimination of ameloblastomas from odontogenic keratocysts by cytokine

levels and gelatinase species of the intracystic fluids. *J. Oral. Pathol. Med.* 2001; 30:421-427.

45. Kubota Y., Oka S., Nakagawa S., Shirasuna K. Interleukin-1 α enhances type I collagen-induced activation of matrix metalloproteinase-2 in odontogenic keratocyst fibroblasts. *J. Dent. Res.* 2002; 81:23-27.

46. Lehrman B J., Mayer D.P., Tidwell O.F., Brooks M.L. Computed tomography of odontogenic keratocysts. *Comput. Med. Imaging Graph.* 1991; 15:365-8.

47. Li T.J., Browne R.M., Prime S.S., Paterson I.C., Matthews J.B. p53 expression in odontogenic keratocyst epithelium. *J. Oral. Pathol. Med.* 1996 May; 25(5): 249-55.

48. Lo Muzio L., Nocini P.F., Savoia A., Consolo U., Procaccini M., Zelante L., et al. Nevroid basal cell carcinoma syndrome. Clinical findings in 37 Italian affected individuals. *Clin. Genet.* 1999; 55: 34-40.

49. MacDonald-Jankowski D.S. The involvement of the maxillary antrum by odontogenic keratocysts. *Clin. Radiol.* 1992; 45:31-3.

50. Madras J., Lapointe H. Keratocystic odontogenic tumour: reclassification of the odontogenic keratocyst from cyst to tumour. *Tex. Dent. J.* 2008 May; 125(5): 446-54.

51. Magnusson B.C. Odontogenic keratocysts: a clinical and histological study with special reference to enzyme histochemistry. *J. Oral. Pathol.* 1978; 7: 8-18.

52. Marzella M.L., Poon C.Y., Peck R. Odontogenic keratocyst of the maxilla presenting as periodontal abscess. *Singapore Dent. J.* 2000; 23:45-8.

53. Maurette P.E., Jorge J., de Moraes M. Conservative treatment protocol of odontogenic keratocyst: a preliminary study. *J. Oral. Maxillofac. Surg.* 2006 Mar; 64(3): 379-83.

54. McClatchey K., Batsakis J.G., Hybels R., Van Wieren C.R. Odontogenic keratocysts and nevroid basal cell carcinoma syndrome. *Arch. Otolaryngol.* 1975 Oct; 101(10): 613-6.

55. Meara J.G., Li K.K., Shah S.S., Cunningham MJ. Odontogenic keratocysts in the pediatric population. *Arch. Otolaryngol. Head. Neck. Surg.* 1996; 122: 725-8.
56. Meara J.G., Shall S., Li K.K., Cunningham M.J. The odontogenic keratocyst: a 20-year clinicopathologic review. *Laryngoscope.* 1998 Feb; 108(2):280-3.
57. Meara J.G, Pilch B.Z., Shah S.S., Cunningham MJ. Cytokeratin expression in the odontogenic keratocyst. *J. Oral. Maxillofac. Surg.* 2000; 58: 862-865
58. Mohammad Ali, Ronald A., Baughman A. Maxillary odontogenic keratocyst. A common and serious clinical misdiagnosis. *J. Dentistry & medicine. JADA, Vol. 134, July 2003; 877-883.*
59. Morgan T.A., Burton C.C., Qian F. A retrospective review of treatment of the odontogenic keratocyst. *J. Oral. Maxillofac. Surg.* 2005; 63: 635-639.
60. Mozaffari E., Marmor D.S., Alawi F. Odontogenic keratocyst with a misleading clinical and radiologic appearance. *Quintessence Int.* 2007 Nov-Dec; 38(10): 837-41.
61. Neville B.W., Mishkin D.J., Traynham R.T. The laterally positioned odontogenic keratocyst. a case report. *J. Periodontal.* 1984; 55:98-102.
62. Neville B.W., Damm D.D., Brock T. Odontogenic keratocysts of the midline maxillary region. *J. Oral. Maxillofac. Surg.* 1997; 55:340-4.
63. Ninomiya T., Kubota Y., Koji T., Shirasuna K. Marsupialization inhibits interleukin-1« expression and epithelial cell proliferation in odontogenic keratocysts. *J. Oral. Pathol. Med.* 2002; 31: 526-533.
64. Nohl F.S., Gulabivala K. Odontogenic keratocyst as periradicular radiolucency in the anterior mandible: two case reports. *Oral. Surg. Oral. Med. Oral. Pathol. Oral. Radiol. Endod.* 1996; 81:103-9.

65. Oda D, Rivera V, Ghanee N, Kenny EA, Dawson KH: Odontogenic keratocyst: the northwestern USA experience. *J Contemp Dent Pract* 2000,1: 60-74.
66. Ohki K., Kumamoto H., Ichinohasama R., Sato T., Takahashi N., Ooya K. PTC gene mutations and expression of SHH, PTC, SMO, and GLI-1 in odontogenic keratocysts. *Int. J. Oral. Maxillofac. Surg.* 2004; 33: 584-592.
67. Olson R.E., Thomsen S., Lin L.M. Odontogenic keratocyst treated by the Partsch operation and delayed enucleation: report of case. *J. Am. Dent. Assoc.* 1977Feb;94(2): 321-5.
68. Payne T.F. An analysis of the clinical and histopathologic parameters of the odontogenic keratocyst. *Oral. Surg. Oral. Med. Oral. Pathol.* 1972; 33: 538-46.
69. Panders A.K., Hadders H.N. Solitary keratocysts of the jaws. *J. Oral. Surg.* 1969; 27: 931-8.
70. Piattelli A., Fioroni M., Rubini C. Differentiation of odontogenic keratocysts from other odontogenic cysts by the expression of bcl-2 immunoreactivity. *Oral. Oncol.* 1998 Sep; 34 (5): 404-7.
71. Pindborg JJ., Hansen J. Studies on odontogenic cyst epithelium: clinical and roentgenologic aspects of odontogenic keratocysts. *Acta Pathol. Microbiol. Scand.* 1963; 58: 283-94.
72. Pogrel M.A., Jordan R.C. Marsupialization as a definitive treatment for the odontogenic keratocyst. *J. Oral. Maxillofac. Surg.* 2007 Feb; 65(2): 362-3.
73. Philipsen H.P. Om keratocyster (kolesteratomer) and kaeberne. *Tandlaegegebladet* 1956; 60: 963-81.
74. Philipsen H.P. Keratocystic odontogenic tumour. In *World Health Organization classification of tumors. Pathology and genetics of head and neck tumors*, Barnes L., Everson J.W., Reichart P., Sidransky D. (Eds.). 2005; pp. 306-307, IARC Press, Lyon.

75. Radden B.G., Reade P.C. Odontogenic keratocysts: a review and clinicopathological study of 368 odontogenic cysts. *Aust. Dent. J.* 1973; 18:218-25.

76. Richter M., Fiore-Donno G., Kuffner R. Odontogenic keratocysts. *SSO Schweiz Monatsschr Zahnheilkd.* 1975 May; 85(5): 487-506.

77. Rippin, J.W., Woolgar, J.A. The odontogenic keratocyst in BCNS and non-syndrome patients. *Investigative Pathology of Odontogenic Cysts.* CRC Press, Boca Raton; 1991. pp. 211-232.

78. Rud J., Pindborg J J. Odontogenic keratocysts: a follow-up study of 21 cases. *J. Oral. Surg.* 1969; 27:323-30.

79. Schmidt B.L., Pogrel M.A. The use of enucleation and liquid nitrogen cryotherapy in the management of odontogenic keratocysts. *J. Oral. Maxillofac. Surg.* 2001; 59: 720-5.

80. Shear M. Developmental odontogenic cysts: an update. *J. Oral. Pathol. Med.* 1994; 23:1-11.

81. Shear M. The aggressive nature of the odontogenic keratocyst: is it a benign cystic neoplasm? Part 1. Clinical and early experimental evidence of aggressive behaviour. *Oral. Oncol.* 2002; 38:219-226

82. Shear M. The aggressive nature of the odontogenic keratocyst: is it a benign cystic neoplasm? Part 2. Proliferation and genetic studies. *Oral. Oncol.* 2002 Jun; 38(4): 323-31.

83. Shear M. The aggressive nature of the odontogenic keratocyst: is it a benign cystic neoplasm? Part 3. Immunocytochemistry of cytokeratin and other epithelial cell markers. *Oral. Oncol.* 2002 Jul; 38(5): 407-15.

84. Stajcic Z., Paljm A. Keratinization of radicular cyst epithelial lining or occurrence of odontogenic keratocyst in the periapical region? *Int. J. Oral. Maxillofac. Surg.* 1987; 16: 593-5.

85. Stoelinga P.J.W. The treatment of odontogenic keratocysts by excision of the overlying, attached mucosa, enucleation, and treatment of the bony defect

with Carnoy solution. *Oral. Surg. Oral. Med. Oral. Pathol. Oral. Radiol.* 2005 Oct; 94(4): 232-44.

86. Stoelinga P.J.W. Long-term follow-up on keratocysts treated according to a defined protocol. *Int. J. Oral. Maxillofac. Surg.* 2001; 30:14-25.

87. Stoll C., Stollenwerk C., Riediger D., Mittermayer C., Alfer J. Cytokeratin expression patterns for distinction of odontogenic keratocysts from dentigerous and radicular cysts. *J. Oral. Pathol. Med.* 2005 Oct; 34(9): 558-64.

88. Takeda Y., Kuroda M., Kuroda M., Suzuki A., Fujioka Y. Melanocytes in odontogenic keratocyst. *Act. Pathol. J.* 1985 Jul; 35(4): 899-903.

89. Tan Z.Z., Liu B., Wei J.X., Zou H., Zhao Y.F. Effects of mandibular odontogenic keratocyst surgery and removable partial prostheses on masticatory performance. *J. Prosthet. Dent.* 2007 Feb; 97(2): 107-11.

90. Tosios K.I., Kakarantza-Angelopoulou E., Kapranos N. Immunohistochemical study of bcl-2 protein, Ki-67 antigen and p53 protein in epithelium of glandular odontogenic cysts and dentigerous cysts. *J. Oral. Pathol. Med.* 2000 Mar; 29(3): 139-44.

91. Tucker W.M., Pleasants J.E., MacComb W.S. Decompression and secondary enucleation of a mandibular cyst: report of a case. *J. Oral. Surg.* 1972; 30: 669-73.

92. Vedtofte P., Praetorius F. Recurrence of the odontogenic keratocysts in relation to clinical and histological features: a 20-year follow-up study of 72 patients. *Int. J. Oral. Surg.* 1979; 8:412-20.

93. Voorsmit R.A., Stoelinga P.J., Van Haelst UJ. The management of keratocysts. *J. Maxillofac. Surg.* 1981; 9: 228-36.

94. Webb D.J., Brockbank J. Treatment of the odontogenic keratocyst by combined enucleation and cryosurgery. *Int. J. Oral. Surg.* 1984 Dec; 13(6): 506-10.

95. Wetmore S J., Billie J.D., Howe A., Wetzel W. Odontogenic keratocyst: diagnosis and treatment. *Otolaryngol. Head. Neck. Surg.* 1983; 91:167-72.

96. Woolgar J. A., Rippin J.W., Browne R.M. A comparative study of the clinical and histological features of recurrent and non-recurrent odontogenic keratocysts. *J. Oral. Pathol.* 1987; 16:124-24.

97. Wright B.A., Wysocki G.P., Larder T.C. Odontogenic keratocysts presenting as periapical disease. *Oral. Surg. Oral. Med. Oral. Pathol.* 1983; 56:425-9.

98. Wright J.M. The odontogenic keratocyst: orthokeratinized variant. *Oral. Surg. Oral. Med. Oral. Pathol.* 1981 Jun; 51(6): 609-18.

99. Yoshiura K., Higuchi Y., Ariji Y., Shinohara M., Yuasa K., Nakayama E., Ban S., Kanda S. Increased attenuation in odontogenic keratocysts with computed tomography: a new finding. *Dentomaxillofac. Radiol.* 1994 Aug; 23(3): 138-42.

100. Yoshiura K., Higuchi Y., Araki K., Shinohara M., Kawazu T., Yuasa K., Tabata O., Kanda S. Morphologic analysis of odontogenic cysts with computed tomography. *Oral. Surg. Oral. Med. Oral. Pathol. Oral. Radiol. Endod.* 1997 Jun; 83(6): 712-8.

101. Zachriades N., Papanicolaou S., Triantafyllou D. Odontogenic keratocysts: review of the literature and report of sixteen cases. *J. Oral. Maxillofac. Surg.* 1985; 43: 177-82.

102. Zhang L., Sun Z.J., Zhao Y.F., Bian Z., Fan M.W., Chen Z. Inhibition of SHH signaling pathway: Molecular treatment strategy of odontogenic keratocyst. *Med. Hypotheses.* 2006; 67(5): 1242-4.