

## MORPHOLOGICAL AND IMMUNOHISTOCHEMICAL CHARACTERISTICS OF HUMAN TRIGEMINAL GANGLION NEURONS IN THE PRENATAL PERIOD OF DEVELOPMENT

### CHARAKTERYSTYKA MORFOLOGICZNA I IMMUNOHISTOCHEMICZNA LUDZKICH NEURONÓW ZWOJU TRÓJDZIELNEGO W OKRESIE ROZWOJU PRENATALNEGO

Ivan I. Starchenko, Yulia N. Vitko, Oleksii K. Prylutskyi, Sergii O. Bilokon, Nataliia I. Vynnyk

HIGHER STATE EDUCATIONAL ESTABLISHMENT OF UKRAINE "UKRAINIAN MEDICAL STOMATOLOGICAL ACADEMY", POLTAVA, UKRAINE

#### ABSTRACT

**Introduction:** Data related to the amount, size and morphological characteristics of cell elements of sensory ganglia at different stages of prenatal development has not been fully elucidated in recent scientific publications. At the same time publications considering the study of cell structure of trigeminal ganglion in the postnatal period confirm heterogeneity of its neurons.

**The aim** of the research was to study morphological and immunohistochemical characteristics of human trigeminal ganglion neurons at 12-14 weeks of prenatal development.

**Material and Methods:** The study was made on 24 trigeminal ganglions of 12 human fetuses at 12 to 14 weeks of prenatal development after abortion made on social and medical indications.

**Results:** At the studied period of the intrauterine development nerve cells of the trigeminal ganglion significantly differed in size, tinctorial properties and degree of argentophilia of the perikaryon. At the same time, the number of small nerve cells with an average diameter of less than 15  $\mu\text{m}$  prevailed.

Immunohistochemical study allowed detecting the apparent Bcl-2 expression in the overwhelming number of small neurons; the expression of this marker has been observed in 50% of cells of the medium-sized neurons. No Bcl-2 expression has been found in most of the large neurons. Almost all the neurons, regardless of the size, showed moderate Ki-67 expression, protein S-100. VEGF expression has also occurred in the vast majority of the nerve cells of all size groups.

**Conclusions:** 1. Human trigeminal ganglion neurons both at 12-14 weeks of prenatal development and in postnatal period are represented by heterogeneous population. 2. Polymorphism of trigeminal ganglion neurons has been found by all applied techniques. 3. Detected polymorphism is the evidence of processes of maturation and differentiation of neurons in human trigeminal ganglion at 12-14 weeks of prenatal development.

**KEY WORDS:** trigeminal ganglion, neurons, prenatal development.

Wiad Lek 2017, 70, 3, cz. II, 561-565

#### INTRODUCTION

Data related to the amount, size and morphological characteristics of cell elements of sensory ganglia at different stages of prenatal development has not been fully elucidated in recent scientific publications. At the same time publications considering the study of cell structure of trigeminal ganglion in the postnatal period confirm heterogeneity of its neurons. Thus Komer [1], on the basis of the analysis of silver-impregnated specimens suggested dividing trigeminal ganglion neurons into four groups; while studying the tissue specimens of human trigeminal ganglion, stained in hematoxylin-eosin and azan D. Krastev, et al. [2] divided all neurons of trigeminal ganglion into seven groups on the basis of the set of morphological properties. It was also hypothesized about the functional heterogeneity of neurons with various morphological characteristics [3].

Some publications [4] show that differentiation of trigeminal ganglion neurons into various morphofunctional classes in birds and mammals originates early

in the prenatal period. At the same time it is noted that maturation of diverse types of neurons occurs nonsimultaneously; however this issue remains to be understood to date.

#### THE AIM

The aim of the research was to study morphological and immunohistochemical characteristics of human trigeminal ganglion neurons at 12-14 weeks of prenatal development.

#### MATERIAL AND METHODS

The study was made on 24 trigeminal ganglions of 12 human fetuses at 12 to 14 weeks of prenatal development after abortion made on social and medical indications. Ethics and legal issues of the study have been resolved under existing international conventions and Ukrainian legislation, as well as bioethical principles, the Law of Ukraine "On transplantation of organs and other anatomical materials", issued on 16.07.1999, No. 1007-XV. In

compliance with the abovementioned legal documents in every case sampling of objects for morphological study met the standing procedure for the collection, transportation and follow-up storage.

With the purpose of obtaining the images of microscopic structure of trigeminal ganglion and conducting a subsequent immunohistochemical analysis part of trigeminal ganglions was fixed in 10% neutral formalin during 24 hrs. After dehydration in spirits of the ascending densities the specimens were embedded into paraffin according to conventional technique with subsequent preparation of histological 5-7  $\mu$  sections, stained with hematoxylin and eosin [5,6].

For detailed analysis of cell structure, after previous examination of them on hystotopographical preparations [7], semi-thin sections were prepared from some pre-studied at the macro- and microscopic levels trigeminal ganglions according to the in-house method [8] and stained by polychrome technique. Some part of the total amount of specimens of trigeminal ganglions was impregnated with silver nitrate with subsequent embedding into EPON-812, preparation of semi-thin sections and finish staining of individual sections by Mallory technique [9,10].

Immunohistochemical analysis has been carried out using the "DAKO" (Denmark), Ready-to-Use monoclonal antibodies (MCAB). Phenotypic features of trigeminal ganglion neurons were studied by evaluating the level of expression of Ki-67 protein as a generic marker of the proliferative activity, vascular endothelial growth factor (VEGF), a Bcl-2 apoptosis regulator and S-100 protein.

## RESULTS AND DISCUSSION

On the specimens stained with hematoxylin and eosin the majority of neurons were round and oval-shaped, seldom polygonal with one nucleus, containing 1-2 nucleoli. It should be noted that polygonal irregular shape of individual neurons is, probably, in our opinion, caused by inevitable postmortem changes and deformation in the process of fixation and dehydration. Apparently, it is for this reason that some researchers, who have studied the cells of human sensory ganglions, describe a significant diversity of shapes of karyoplasms in neurons, which is much less pronounced in the ganglions of laboratory animals.

Our previous studies of metric characteristics of cell elements of human trigeminal ganglion enabled to divide the neurons of the latter into three groups, depending on the mean diameter: small (up to 15  $\mu$ ), medium-sized (15 to 20  $\mu$ ) and large (over 20  $\mu$ ). At the same time it should be noted that proportion of small neurons visibly predominated in the studied period of prenatal development [11]. The perikaryon of the latter was round-shaped or had irregular shape with relatively large nucleus, occupying major part of cytoplasm volume.

The nucleus/cytoplasm ratio in the medium-sized neurons shifted to cytoplasm side, as compared with abovementioned neurons. In this way the population of neurons was heterogeneous in this size group. Round, oval and

irregular polygonal-shaped neurons have been found there in equal parts. All three types of cells had centric nuclei, occupying approximately half of the perikaryon, containing 1-2 medium-sized hyperchromic nucleoli.

Round to oval-shaped perikaryon was the most typical in large neurons. Among them the predominant number of cells with relatively pale nuclei, as well as few neurons with dark hyperchromatic nuclei has been distinguished. At the same time it should be noted that no evidence of mitotic activity of neurons has been detected during each observations. Consequently, we hypothesize that at this stage no multiplication of neurons occurs, but only its maturation and differentiation. Small neurons with karyoplasm of indistinct color and shape should be considered the least differentiated cell bodies in the population.

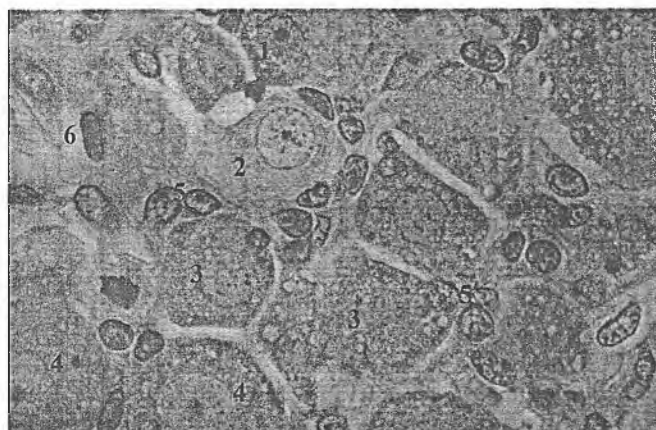
Fewer amounts of neurons with dark nuclei have been found among large and medium-sized cells. At the same time tinctorial properties of the cytoplasm enables to distinguish dark and light neurons among them.

The analysis of the semi-thin sections stained by polychromatic technique and impregnated with silver nitrate provided with more detailed view on structural organization of trigeminal ganglion neurons at 12-14 weeks of prenatal development. Thus semi-thin sections showed that the shape of the majority of neurons was round to ovoid and only few cells were characterized by the irregular polygonal shape of the perikaryon. All observations showed that on the semi-thin sections neurons had more regular and even boundaries, as compared with paraffin sections stained with hematoxylin and eosin that confirms indirectly our hypothesis about the considerable deformation of neurons during the preparation of micro specimens according to conventional techniques.

On the semi-thin sections neurons with different stain intensity of cytoplasm, from moderately basophilic in light neurons to highly pronounced basophilia in dark ones, are clearly distinguished. Maximum possible magnification of the light microscope shows that the cytoplasm of neurons has heterogeneous structure due to presence of clear vesicle-like inclusions and lumpy bodies with intensive basophilia. Apparently, the lumpy basophilic body is represented by the cytoplasm areas, rich in flattened cisterns of granular endoplasmic reticulum, containing numerous ribosomes, called Nissl substance (Fig.1).


It is possible that vesicular inclusions are also represented by the bioplasts, which are hardly to be identified at the optical light level. It should be taken into account that the formation of such structures occurs during the fixation and preparation of the microspecimens.

At the same time, during electron microscopic analysis of trigeminal ganglion neurons some publications considered similar structures as the formations close to granules of adrenaline and noradrenaline according to the set of morphological properties [12,13,14]. It is noteworthy that in most neurons the described vesicular structures are located relatively evenly in the cytoplasm, and visualized the most distinctly in large neurons with dark cytoplasm whereas in the light neurons they were practically not observed.



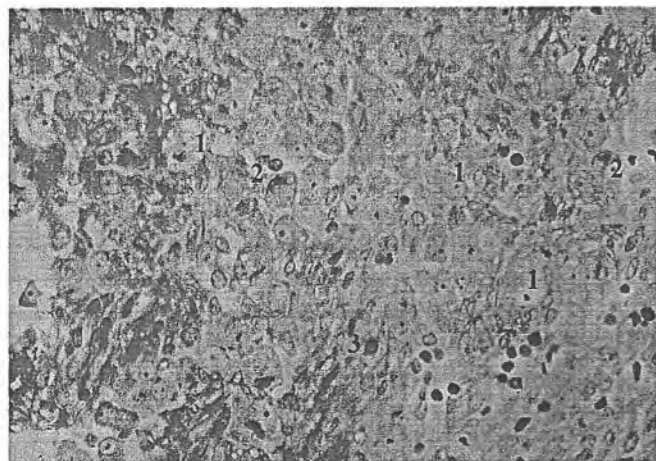
**Fig.1.** Cell elements of human trigeminal ganglion at 12-14 weeks of prenatal development. Polychrome stain. x 900.

1 – small neuron with hyperchromatic cytoplasm and fuchsinophil nuclei; 2 – medium-sized neuron with clear nucleus and clear cytoplasm; 3 – medium-sized neurons with vesicular inclusions in cytoplasm; 4 – large neurons with vesicular inclusions in cytoplasm; 5 – mantle cells; 6 – fibroblasts.



**Fig. 2.** Internal structure of human trigeminal ganglion at 12-14 weeks of prenatal development. Semi-thin section. Silver impregnation. x 900.

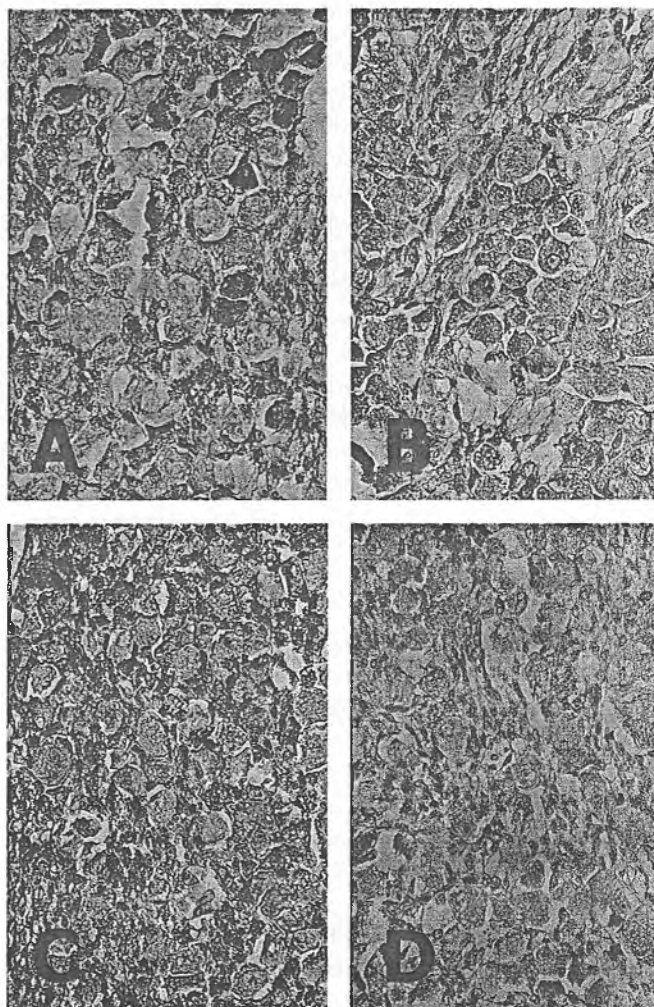
1 – neuron with moderate argentophilia of perikaryon; 2 – neuron with intensive argentophilia of perikaryon; 3 – argentophilic granules in the perikaryons of neurons; 4 – nerve-cell processes; 5 – bifurcation of nerve-cell processes; 6 – funiculi; 7 – hollow spaces in neuron nuclei's places.



**Fig. 3.** Internal structure of human trigeminal ganglion at 12-14 weeks of prenatal development. Semi-thin section. Silver impregnation with finish Mallory's stain. x 400.

1 – neurons with poor argentophilia and moderate basophilia of cytoplasm; 2 – neurons with argentophilic inclusions in the perikaryon; 3 – funiculi.

On the semi-thin sections nuclei of neurons were mainly round-shaped with one, seldom two, nucleoli and visibly differed in stain intensity. Thus, in some magnification it is possible to identify three types of nuclei on the basis of this feature on the semi-thin sections, stained by polychrome technique. Nuclei with indistinct fuchsinophilia were found the most frequently and were typical for large and medium-sized neurons with hyperchromatic cytoplasm. Light nuclei were found less frequently in contrast to nuclei mentioned above and were identified in the neurons of all size groups, cytoplasm of which had poor tinctorial properties. Basophilic nuclei were seldom found, too, mainly in small neuron with hyperchromatic cytoplasm (Fig.1).



**Fig.4.** Immunohistochemical study of human trigeminal ganglion neurons at 12-14 weeks of prenatal development. x 600

a – reaction of monoclonal antibodies to Bcl-2; b – reaction of monoclonal antibodies to Ki-67; c – reaction of monoclonal antibodies to S-100; d – reaction of monoclonal antibodies to VEGF.

It should be noted that both on regular histological sections and semi-thin sections stained by polychrome technique no lipofuscin pigment has been found in the karyoplasm of neurons of all types, presence of which is very typical for sensory ganglions neurons at the postnatal period of development, especially in elderly and senior people [15].

Another picture has been observed on the semi-thin section, impregnated with silver nitrate. This technique showed that almost all neurons were round-shaped or ovoid with even distinct borders. At the same time neurons with irregular polygonal shape were practically not found. The distinctive characteristic of impregnated semi-thin sections without additional staining is the possibility of selective detection on the specimens of processes of individual neurons, enabling us to expand the previous data. During all observations we succeeded in visualization of one process, branching from the neurocyton with its subsequent division into two thinner branches in the distance corresponding from half to two-three perikaryon diameters. The latter bifurcated at an acute angle and seldom at the right angle (Fig.2.).

The branches, originated after mitosis of the nerve-cell process, represented by axon and dendron, respectively, were wavy and formed rather dense net due to chaotic twisting with processes of adjacent neurons.

Therefore, on the basis of the abovementioned facts, all neurons of trigeminal ganglion at 12-14 weeks of prenatal development should be considered as pseudounipolar and scattered reports about the presence of bipolar and multipolar neurons in trigeminal ganglion at later stages of prenatal development and postnatal period are apparently connected with certain difficulties in the interpretation of complex spatial relationship between the neurocytons and their processes.

Interestingly, during the major observations nuclei of neurons are not impregnated with silver, and, consequently without additional staining they look like optically empty oval or round-shaped cavities. In additional staining of impregnated semi-thin sections by Mallory technique the nuclei become distinct without any visible morphological difference from the similar ones on the polychrome stained semi-thin sections.

Due to varying argentophilia of cytoplasm, some neurons on the specimens, impregnated with silver nitrate have visible differences, and, therefore, in certain magnification it is possible to divide them into three groups on the basis of such property. Neurons with moderate argentophilic cytoplasm are assigned to Group I, which is the most numerous. Due to relatively equal distribution of silver, the cytoplasm of such neurons has the homogeneous brownish golden appearance. Basically, such neurons are large and medium-sized.

The distinctive characteristic of neurons of Group II is the intensive argentophilia of cytoplasm due to which the latter is characterized by the homogeneous brownish golden appearance. Neurons of such type have been found in all size groups; however, the most numerous

populations of them have been detected among small neurons. Inhomogeneous impregnation of cytoplasm is typical for neurons of Group III, due to which compactly arranged dark brown granules have been found in cytoplasm, mainly in the perinuclear space, against the yellowish-golden background. Similar neurons have been also found in all size categories.

More colorful picture, showing the tinctorial properties of neurons' perikaryons, has been observed on the silver-impregnated semi-thin sections with additional staining of the latter by Mallory technique (Fig. 3).

In this case, neurons with cytoplasm stained light blue have been found the most frequently. Most probably, karyoplasm of such neurons has very poor argentophilic properties and moderate basophilia. A significant amount of neurons whose basophilic cytoplasm contains argentophilic inclusions, amount of which can vary within the wide range, have been found, too. In addition the latter can have both relatively homogeneous diffuse distribution of argentophilic substance in all volume of perikaryon and concentrate in the form of dark brown granules in the perinuclear area.

Scattered neurons with cytoplasm, colored dark brown due to high argentophilia and with no visible basophilic staining have been found (Fig.3).

Immunohistochemical study of human trigeminal ganglion neurons at 12-14 weeks of prenatal development enabled detection of manifested intracellular Bcl-2 expression, with relatively equal distribution in karyoplasm, in the overwhelming majority of small neurons, whereas the intensity of expression was evidently poorer in the medium-sized neurons and was detected in approximately 50% of neurons.

Almost all neurons regardless of their size showed moderate Ki-67 expression, characterized by the homogenous staining of cytoplasm. Similarly, moderate to prominent expression of S-100 protein was typical for neurons of all size groups at the studied period of prenatal development. VEGF expression was also detected in the overwhelming majority of neurons of all size groups and was irregular with poor and moderate manifestation in approximately the same number of neurons (Fig.4).

## CONCLUSIONS

1. Human trigeminal ganglion neurons both at 12-14 weeks of prenatal development and in postnatal period are represented by heterogeneous population with significant difference in shape, size, tinctorial properties of nucleus and cytoplasm.
2. Polymorphism of trigeminal ganglion neurons has been found by all applied techniques. In addition, the analysis of the semi-thin sections, silver nitrate-impregnated specimens and application of immunohistochemical studies enables detection of more amounts of neurons' subpopulations than in conventional methods of study.
3. Detected polymorphism is the evidence of processes of maturation and differentiation of neurons in human trigeminal ganglion at 12-14 weeks of prenatal development.



## REFERENCES

1. F. Komer, Z. Mikrosk: Variationsstatistische Untersuchungen über die Grosse der Eama und der Kernkörperchen menschlicher Nervensellen. *Anat. Porsch.* 1937, 4, 81–115.
2. D. Krastev, D. Palof, A. Hinova-Pavlova et al. Light-microscopic structure of trigeminal ganglion in humans. *Journal of IMAB – Annual Proceeding (Scientific Papers)* 2007, 14, 1, 111–115.
3. Lang J, Reiter U.: Über den Verlauf der Hirnnerven in der Seitenwand des Sinus cavernosus. *Neurochirurgia* 1984, 27, 93–97.
4. G. C. Gaik, A. I. Farbman: The chicken trigeminal ganglion. I. An anatomical analysis of the neuron types in the adult. *J. Morphol.* 1973, 141, 43–56.
5. Korzhevskii D.E. Basics of histologic techniques. / D.E. Korzhevskii, A.V. Giljarov. – SPb.: SpetsLit, 2010. – 95p.
6. Bagrii M.M., Dibrova V.A., Popadynets O.G., Gryshuk M.I. Methods of morphological researches. Vinnytsja: Nova knyga; 2016. – 328p.
7. Kostilenko YP, Boiko IV, Starchenko II, Prilutskii AK: A method for making histological preparations equivalent to semithin sections with large examination areas for multipurpose morphological studies. *Neuroscience and behavioural physiology* 2008, Nov; 38(9): 897-9.
8. Bilokon S.O., Vitko Yu.M., Tkachenko P.I. et al. Optimize the study of the structural elements of biological tissues in the hystotopographic thin sections. *Molodoj uchjonyi*; 2014; 15(74): 134-137p.
9. Kostilenko Yu.P., Eroshenko G.A., Starchenko I.I., Erjomina N.F. Determine the elements of the peripheral nervous system on semithin sections using silver nitrate impregnation. *Naukovyi visnyk Uzhgorodskogo universytetu. Serija medycyna*; 2000; 11: 52-62p.
10. Zhutaev I.A.: Method of impregnation of sections glued onto glass [IKmetodike impregnatsii nakleennykh na stekla srezov.]. *Arkhiv patologii* 1969, 31, 6, p32
11. Vitko Yu.N. Morphometric characteristic of neurocytes of human trigeminal ganglion on different stages of natal development. *Visnyk problem biologii i medycyny* 2016; 2-1: 368-371.
12. Krastev D.: Electronmicroscopical investigation of the small neurons in trigeminal ganglion. *Journal of IMAB – Annual Proceeding (Scientific Papers)* 2007, 14, 1, 27–29.
13. Krastev D.: Trigeminal ganglion – electronmicroscopy of large light pseudounipolar neurons. *Journal of IMAB – Annual Proceeding (Scientific Papers)* 2007, 14, 1, 30–32.
14. Sangiacomo C. O., Panetta V.: Electron microscop observation on the superior cervical ganglion of a newborn rat. I. Nerve cells. *La Rincera scientifica* 1969, 39, 4, 448–454.
15. Nikiforov A.G., Starchenko I.I., Chernjak V.V. Comparative characteristics of the cellular composition of human spinal units in the young and elderly. Scientific and practical edition: Publishing Center of The International Scientific Association "Science & Genesis", Prague, Czech Republic, 2015, Volume 1, p. 98-101.

## ADDRESS FOR CORRESPONDENCE

Ivan Starchenko

23 Shevchenko Str., 36011 Poltava, Ukraine

tel.: +380976471120

e-mail.: stardoc@i.ua

Received: 20.01.2017

Accepted: 18.05.2017