

VETERINARSKI ARHIV 84 (2), 199-204, 2014

## Congenital nephroblastoma in a Holstein-Friesian fetus - case report

**Rajamanickam Madheswaran<sup>1\*</sup>, Mahakrishnan Palanisamy<sup>2</sup>,  
Sakthivel Manokaran<sup>2</sup>, Soundarapandian Sivaseelan<sup>1</sup>,  
Gurusamypalayam A. Balasubramaniam<sup>1</sup>, Govindarajan Vijayakumar<sup>3</sup>,  
Mani Selvaraju<sup>4</sup>, and Royappan E. Napoleon<sup>2</sup>**

<sup>1</sup>*Department of Veterinary Pathology, Veterinary College and Research Institute, Namakkal, Tamil Nadu, India*

<sup>2</sup>*Department of Animal Reproduction, Gynecology and Obstetrics, Veterinary College and Research Institute, Namakkal, Tamil Nadu, India*

<sup>3</sup>*Department of Veterinary Clinical Medicine, Ethics and Jurisprudence, Veterinary College and Research Institute, Namakkal, Tamil Nadu, India*

<sup>4</sup>*Department of Clinics, Veterinary College and Research Institute, Namakkal, Tamil Nadu, India*

---

**MADHESWARAN, R., M. PALANISAMY, S. MANOKARAN, S. SIVASEELAN, G. A. BALASUBRAMANIAM, G. VIJAYAKUMAR, M. SELVARAJU, R. E. NAPOLEAN: Congenital nephroblastoma in a Holstein-Friesian fetus. Vet. arhiv 84, 199-204, 2014.**

### ABSTRACT

A seven-year-old Holstein-Friesian cow was brought to the hospital with signs of dystocia in the eighth month of gestation. The dystocia was relieved and a dead male fetus removed. The fetus had a significantly distended abdomen. At necropsy, the fetus showed a very large, round and well encapsulated extra renal mass in the abdominal cavity. The cut surfaces of the mass showed a white, cauliflower-like growth with red surfaces. The lobules were spongy and distinctly demarcated by fat and hemorrhages. Microscopic examination of the tissue sections revealed blastemal, epithelial and mesenchymal elements. These cells were round to oval in shape with scanty cytoplasm. The nuclei were spherical, sometimes vesicular and hyperchromatic. The epithelial structures resembled the development of tubulo-glomerulogenesis. The mesenchymal cells were polyhedral in shape, found between the tubules. The gross and microscopic features of the tissue sections were consistent with a diagnosis of nephroblastoma.

**Key words:** Holstein-Friesian fetus, nephroblastoma, gross pathology, histopathology

---

\*Corresponding author:

R. Madheswaran, Assistant Professor, Department of Veterinary Pathology, Veterinary College and Research Institute, Namakkal - 637 002, Tamil Nadu, India. Mobile: +91 94 88 585 638; E-mail: [rmadheswaran2003@gmail.com](mailto:rmadheswaran2003@gmail.com)

### Introduction

The fetal kidneys are formed by the development of nephron from fetal metanephric blastema. Nephroblastoma is a congenital neoplasm arising from metanephric blastema during pre- or post-natal life (MOULTON, 1961; KIRKBRIDE and BICKNELL, 1972; MEUTEN, 2002; DEVI et al., 2011). This tumor is a combination of embryonic renal tissue with myxomatous mesenchyme in various amounts (MEUTEN, 2002). It is characterized by the presence of great structural and histological diversity including blastemal, epithelial and stromal cells (KIRKBRIDE and BICKNELL, 1972; MURPHY et al., 1994; ZOLLER et al., 2008). Nephroblastomas are organoid teratomas (KIRKBRIDE and BICKNELL, 1972) clinically evident as abnormal, intra-abdominal masses (ZOLLER et al., 2008).

Nephroblastomas are common in swine and chickens, but has rarely been reported in dogs, sheep and cattle (SULLIVAN and ANDERSON, 1959; MOULTON, 1961; SRIVASTAVA et al., 1989; MAXIE, 1993; HEADLEY et al., 2006; NEWMAN et al., 2007). The literature on nephroblastoma in bovine fetuses is meager (KIRKBRIDE and BICKNELL, 1972; DEVI et al., 2011). No reports of congenital nephroblastoma in Holstein-Friesian fetus were found when major databases were accessed, hence this report describes the gross and histology findings of nephroblastoma in a Holstein-Friesian fetus.

### Case report

A seven-year-old Holstein-Friesian cow was brought to Hospital Campus, Veterinary College and Research Institute, Namakkal, India. The animal was pregnant for the third time and showing clinical signs of dystocia in the eighth month of gestation. The water bag ruptured a day before the animal brought to the hospital. Dystocia was relieved after careful obstetrical examination and a dead male fetus removed by forced traction. The fetus had a significantly distended abdomen.

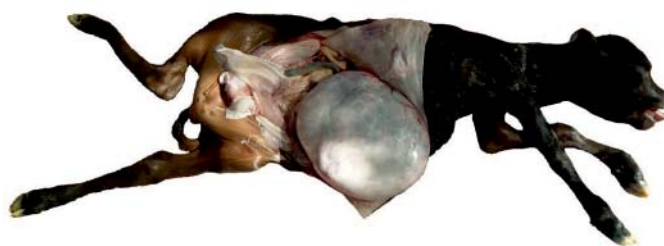

Fig. 1. Holstein-Friesian fetus showing a huge rounded mass in the abdominal cavity.

At necropsy, the fetus showed a very large, round and well encapsulated extra renal mass (40 × 33 cm) in the abdominal cavity (Fig. 1). The abdominal cavity also contained about 5 litres of amber-coloured fluid. The weight of the mass was 3.8 kg and thickness of the capsule 1.3 cm. The capsule was grayish-white in colour. The cut surfaces of the mass resembled a white, cauliflower-like growth with red surfaces (Fig. 2). The lobules were spongy and distinctly demarcated by fat and hemorrhages. The kidneys and other visceral organs observed were normal. Representative pieces of the tissues from the mass were collected, fixed in 10% formalin solution, and routinely processed for histopathology.

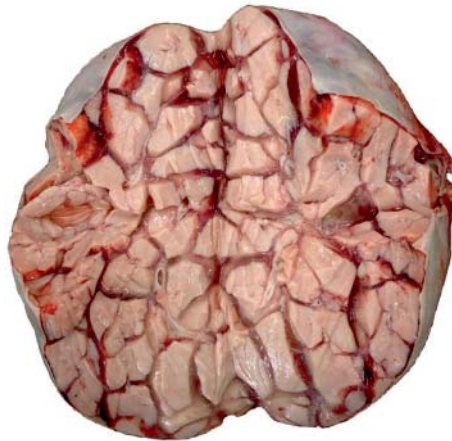

Fig. 2. Cut surfaces of the mass showing white cauliflower-like growth with red surfaces

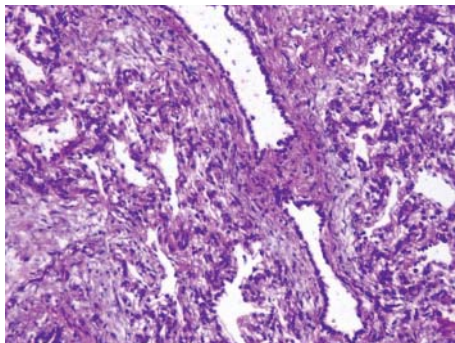


Fig. 3. Microscopic examination of the mass comprising blastemal, epithelial and mesenchymal elements. H&E; ×200.

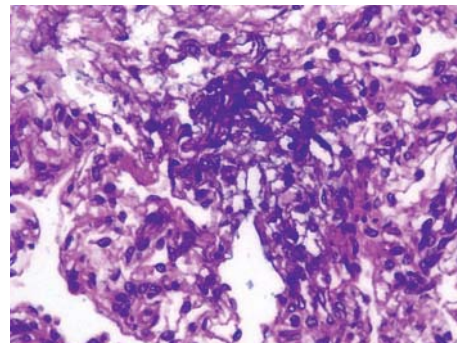


Fig. 4. Microscopically, epithelial cell structures appeared to be the early stage of tubulo-glomerulogenesis. H&E; ×400.

Microscopic examination of the tissue sections revealed blastemal, epithelial and mesenchymal elements (Fig. 3). The blastemal cells were differentiated to form dense, irregular masses, clusters and nests. These cells were round to oval in shape with scanty cytoplasm. The nuclei were spherical, sometimes vesicular and hyperchromatic, containing finely granular chromatin with multiple nucleoli and mitotic figures. The blastemal cells were arranged into glomeruloid and tubular structures lined by flattened epithelium. Some tubules were dilated with eosinophilic fluid and cell debris. Abortive tubules were noticed in most of the tissue sections. The epithelial cell structures appeared to be the early stages of tubulo-glomerulogenesis (Fig. 4). The mesenchymal cells were polyhedral in shape, found between tubules. Inflammatory reaction was absent. Gross and microscopical examination of other organs ruled out metastasis.

### Discussion

Nephrogenic blastema differentiates to form nephrons and supporting connective tissues. A nephroblastoma consists of all component tissues of the kidney arising from blastema. It arises as a result of the failure of the metanephric blastema to undergo normal differentiation. Blastemal cells which differentiate to form abortive tubules and glomeruloid structures have been corroborated in earlier findings (SEELY, 2004).

Gross and microscopical examination confirmed the mass as congenital nephroblastoma. Histopathologically, the tumor was characterized by the presence of undifferentiated blastemal, epithelial and mesenchymal elements. This triphasic growth pattern is the hallmark of nephroblastoma, and the case resembled earlier reports in human and animals (NEWMAN et al., 2007; RASO et al., 1994). It is also a criterion in distinguishing malignant nephroblastoma from benign (SINGH et al., 2005). The predominant mesenchymal tissues, sparse epithelial elements and distribution of tubules in the connective tissues observed in this case were in agreement with reported findings (KIRKBRIDE and BICKNELL, 1972).

The literature reports that nephroblastoma mostly replaces renal parenchyma at varying degrees (BASKIN and PAOLI, 1977; MADHESWARAN et al., 2009), but this was not true in the present case, where the tumor had developed in the extra renal region. Similar observations have been reported earlier only in dogs (NEWMAN et al., 2007). Though the lungs have been reported as the preferential site for metastasis (RASO et al., 1994; SINGH et al., 2005; ZOLLER et al., 2008), no histological evidence was found to document this. Nor did parallel findings explain the presence of amber-coloured fluid in the abdominal cavity. Congenital nephroblastoma developed during prenatal life in the present case was in agreement with reported findings (KIRKBRIDE and BICKNELL, 1972; DEVI et al., 2011). However, in most of the literature, development of nephroblastoma after birth has been noted.

The exact cause of the development of nephroblastoma was not clearly established (ZOLLER et al., 2008). The cause of nephroblastoma in humans is the loss of function of tumor suppressor genes (BROWN and MALIK, 2001) like WT1, but such an investigation was not attempted. To the author's knowledge, this is the first report of congenital nephroblastoma in a Holstein-Friesian fetus of this age.

### References

- BASKIN, G. B., A. D. PAOLI (1977): Primary renal neoplasms of the dog. *Vet. Pathol.* 14, 591-605.
- BROWN, K. W., K. T. MALIK (2001): The molecular biology of Wilms' tumor. *Exp. Rev. Mol. Med.* 3, 1-16.
- DEVI, V. R., G. VEERAIAH, K. YEDUKONDALU, S. K. BEGUM, P. ANNAPURNA, P. SUNITHA, M. A. DEVI (2011): Congenital Nephroblastoma in a Buffalo Calf. *Braz. J. Vet. Pathol.* 4, 225-226.
- HEADLEY, S. A., J. P. SAUT, P. C. MAIORKA (2006): Nephroblastoma in an adult sheep. *Vet. Rec.* 159, 850-852.
- KIRKBRIDE, C. A., E. J. BICKNELL (1972): Nephroblastoma in a bovine fetus. *Vet. Pathol.* 9, 96-98.
- MADHESWARAN, R., P. KALAISELVAN, K. Y. MATHUR, P. D. SHELAR, J. J. BHELONDE, V. V. PANDE, V. UDUPA, V. M. SHINGATGERI (2009). Nephroblastoma in an 11-week old male Wistar rat with unaltered haematological and plasma biochemical parameters. *Braz. J. Vet. Pathol.* 2, 62-63.
- MAXIE, M. G. (1993): The urinary system. In: *The Pathology of Domestic animals.* (Jubb, K. V. F., P. C. Kennedy, N. Palmer, Eds.), 4<sup>th</sup> ed., 2, 518-522.
- MEUTEN, D. J. (2002): Tumors of the urinary system. In: *Tumors of Domestic Animals.* (Meuten, D. J. Ed.), 4<sup>th</sup> ed., 509-546.
- MOULTON, J. E. (1961): *Tumors in domestic animals.* University of California Press, Berkley.
- MURPHY, W. M., J. B. BECKWITH, G. M. FARROW (1994): *Tumors of the Kidney, Bladder and Related Urinary Structures.* Armed Forces Institute of Pathology, Washington, DC. 11, 12-55.
- NEWMAN, S. J., A. W. CONFER, R. J. PANCIERA (2007): Urinary system. In: *Pathologic Basis of Disease.* (McGavin, M. D., J. F. Zachary, Eds.) 4<sup>th</sup> ed., 613-692.
- RASO, E., J. TIMAR, S. PAKU, K. LAPIS (1994): Metastasizing rat nephroblastoma. A rodent Wilm's tumour model. *Carcinogenesis* 15, 1243-1249.
- SEELY, J. C. (2004): Renal mesenchymal cell tumor vs nephroblastoma: Revisited. *J. Toxicol. Pathol.* 17, 131-136.
- SINGH, B. P., J. C. PATTERSON-KANE, S. P. REDROBE, J. L. CHAPMAN (2005): Intrarenal pelvic nephroblastoma in a meerkat (*Suricata suricatta*). *J. Vet. Diagn. Invest.* 17, 623-625.
- SRIVASTAVA, A. K., D. N. SHARMA, J. N. DWIVEDI (1989): Nephroblastoma in a calf. *Vet. Rec.* 125, 245-246.

SULLIVAN, D. J., W. A. ANDERSON (1959): Embryonal nephroma in swine. *Am. J. Vet. Res.* 20, 324-332.

ZOLLER, M., K. M. RENSING, A. FAHRION, F. J. KAUP (2008): Malignant nephroblastoma in a common marmoset (*Callithrix jacchus*). *Vet. Pathol.* 45, 80-84.

Received: 22 January 2013

Accepted: 19 December 2013

---

**MADHESWARAN, R., M. PALANISAMY, S. MANOKARAN, S. SIVASEELAN, G. A. BALASUBRAMANIAM, G. VIJAYAKUMAR, M. SELVARAJU, R. E. NAPOLEAN: Kongenitalni nefroblastom ploda holštajnsko-frizijske pasmine. *Vet. arhiv* 84, 199-204, 2014.**

**SAŽETAK**

Krava holštajnsko-frizijske pasmine u dobi od sedam godina i osmom mjesecu steonosti dopremljena je na bolnički pregled sa znakovima distocije. Pri teškom teljenju uklonjen je uginuli muški plod. Plod je imao znatno povećan trbuh. Pri razudbi je ustanovljeno da je imao vrlo veliku, okruglu i dobro učahurenu tvorevinu oko bubrega u trbušnoj šupljini. Tvorevina je nalikovala na cvjetaču bjelkaste boje s crvenkastom površinom. Lobuli su bili spužvasti i jasno razgraničeni masnim tkivom s nalazom krvarenja. Mikroskopskom pretragom ustanovljene su primitivne epitelne i mezenhimne stanice. One su bile okrugle do jajolike s malo citoplazme. Jezgre su im bile okrugle, mjestimično mjehuričaste i hiperkromatske. Epitelna građa podsjećala je na tubuloglomerulogenezu. Mezenhimne stanice bile su višestaničnog oblika, smještene između tubula. Makroskopski i mikroskopski nalaz na prerezu tkiva ukazivao je na nefroblastom

**Ključne riječi:** holštajnsko-frizijska pasmina, plod, nefroblastom, patoanatomski i patohistološki nalaz

---