

A Validity of Ultrasound Subdivision of Risser Grade 4 in Assessment of Skeletal Maturity

Hrvoje Pitlović¹, Savo Jovanović², Vlatka Pitlović³, Gordan Šarić⁴ and Tomislav Crnković⁵

¹ General Hospital »dr. Josip Benčević«, Department of Orthopaedic Surgery, Slavonski Brod, Croatia

² University of »Josip Juraj Strossmayer«, School of Medicine, Osijek, Croatia

³ General Hospital »dr. Josip Benčević«, Department of Surgery, Slavonski Brod, Croatia

⁴ University of »Josip Juraj Strossmayer«, School of Medicine, Department of Radiology, Osijek, Croatia

⁵ General Hospital Požega, Department of Orthopaedic Surgery, Požega, Croatia

ABSTRACT

In the treatment of adolescent idiopathic scoliosis, one of the most frequently used technique to determine skeletal maturity is the method described by Risser. The ossification of iliac apophysis progresses from ventral to caudal through the four zones and the fusion of the iliac apophysis to the iliac crest (Risser grade 5) indicated vertebral growth completion, therefore the termination of scoliotic deformity progression. The main disadvantages of Risser method are exposure to radiation and the questionable reliability, so there are efforts to examine iliac apophysis by ultrasound. There is also no resolute recommendation when to discontinue brace treatment of scoliosis. Using ultrasound, in this study, we subdivided Risser grade 4 to grade 4a and 4b, according to the amount of cartilage left unossified, in order to make clear when is safe to end brace treatment. We measured increase in height, during six month period, for 92 healthy children, who were classified by ultrasound in Risser 4a or 4b group. There was significantly larger increase in height for group 4a ($p < 0.001$). For girls, we also noted time past from menarche as sign of biological maturity. Girls from group Risser 4b got menarche 2.74 years before they were examined while group Risser 4a got menarche only 1.57 years before ($p < 0.001$). Subdivision of Risser 4 grade by ultrasound is promising method in determining end of brace treatment for scoliosis.

Key words: iliac crest apophysis, Risser grade, skeletal maturity, ultrasound assessment

Introduction

The assessment of skeletal maturity is of great importance in treating disorders as diverse as scoliosis and kyphosis, slipped capital femoral epiphysis, potentially limb length inequality, adolescent Blount disease and some fractures in children¹⁻⁴.

In the treatment of adolescent idiopathic scoliosis, one of the most frequently used technique to determine skeletal maturity is the method described by Risser (Figure 1)⁵. He demonstrated that ossification of iliac apophysis progresses from ventral to caudal through the four zones and the fusion of the iliac apophysis to the iliac crest (Risser grade 5) indicated vertebral growth completion, therefore the termination of scoliotic deformity progression.

Despite many critics, due to the simplicity and accessibility in X-rays of the spine, determination of Risser

grade is a part of every therapeutic strategy for idiopathic scoliosis. With a Cobb angle and age of menarche in girls, it helps to decide whether and when to start brace treatment, when to stop using brace and when to perform surgery⁴.

The main disadvantages of Risser method are exposure to radiation and the questionable reliability of the method⁶⁻⁸.

To avoid radiation and increased reliability of Risser method, in several recent works, examiners used ultrasound to determine the Risser grade^{9,10}. There is very good agreement in Risser grading between radiographic and ultrasound evaluation.

There is no resolute recommendation when to discontinue brace treatment of scoliosis.

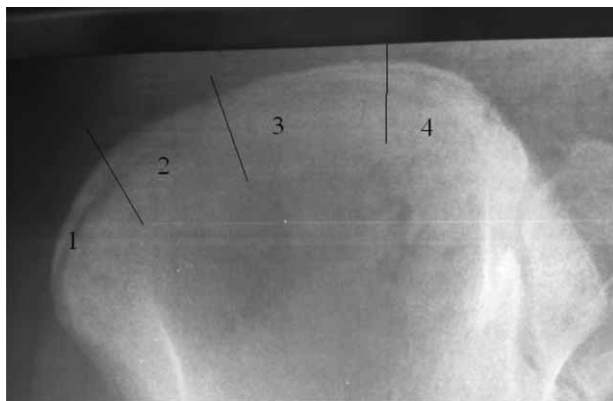


Fig. 1. Risser stage 4. The iliac crest is divided into the four parts. Apophysis developed from anterior to posterior or moving from stage 1 to stage 4. Stage 0 is when the apophysis has not appeared, and stage 5 when apophysis has fused to iliac crest.

Duration of Risser grade 4 can be a long period and iliac apophysis may fuse as late as age 22 or 23, and sometimes, it never fuses¹¹. It would be futile, if not naive, to wait until the iliac crest is completely ossified (Risser grade 5) before stop wearing orthosis. On the other hand, some authors warn that there is, especially in boys, remarkable spinal growth during Risser grade 4 and so the progression of curve is not unusual^{12,13}.

Using three-dimensional ultrasound images we sub-classified Risser grade 4 according to the level of skeletal maturation of iliac apophysis in order to make compliance about opposite attitudes when to discontinue brace treatment of scoliosis.

Subjects and Methods

392 healthy school children, age from 10 to 18, were enrolled in this prospective clinical study. During first visit body height and sitting height were determined by stadiometer. We calculated the chronological age of the subjects with the help of date of birth and expressed it as a number with one decimal place (eg. for a child at the age of 11 years and 6 months chronological age is 11.5). For girls who had experienced menarche we calculated years that past from menarche and expressed it as a number with one decimal place (eg. if girl had menarche 6 months ago time past menarche was 0.5).

We made ultrasound examination of iliac bone in manner described in other papers, in all subjects, in order to determinate Risser grade^{9,10}.

TABLE 1
THE MAIN CHARACTERISTICS OF THE PARTICIPANTS OF THE STUDY

	Male (N=50)	Female (N=92)
Age	15.81±1.03	14.84±1.32
Initial height	179.7±6.38	165.54±6.11
Initial sitting height	91.46±3.16	86.18±2.96

The total of 142 subjects (50 male and 92 female) who were categorized as Risser grade 4 were included in the study. The main characteristics of the sample are shown in Table 1.

According to following principles we further classified Risser 4 group in Risser 4a and 4b:

- in transverse sonogram of iliac bone, if there is 2 mm or more of cartilage between iliac apophysis and iliac wing it was classified as 4a (Figure 2)
- in transverse sonogram of iliac bone, if there is less than 2 mm of cartilage between iliac apophysis and iliac wing it was classified as 4b (Figure 3)

After 6 months there were 92 children for follow up. We repeated height measurements and calculated increase in height and sitting height.

Results

To test the hypothesis whether it is justifiable to divide the subjects with Risser grade 4 into two groups, Risser 4a and Risser 4b, the total of 142 subjects (50 male and 92 female) were distributed into two subsamples according to the ultrasound criteria as described in Methods section. Those subgroups consisted of 72 subjects (27 male and 45 female) who were categorized as Risser 4a and 70 subjects (23 male and 47 female) categorized as Risser 4b.

Before any other data analysis, first we wanted to test for possible correlation between the category Risser 4a and Risser 4b and gender. Spearman rank order correlation, as well as Hi-square test showed that there was no influence of gender on categorizing the subjects into Risser 4a or Risser 4b group (Spearman $r = -0.04$, $\chi^2 = 0.34$, $p = 0.563$), so we could proceed with the study.

After six months the number of subjects that were tested initially and finally after six months comprised to 92 subjects (41 male and 51 female). Student t-test for independent samples was used in order to search for differences in height and sitting height at the beginning of the study. Results showed that there were no differences between the groups in those variables (Table 2).

Interestingly, when we tested for differences in height and sitting height as well for difference in those variables at the beginning of the study and we found much larger increase in height and sitting height in group 4a then in group 4b (Table 3). The largest difference between the groups was in increase of overall height ($p < 0.001$).

We also wanted to test difference between the Risser 4a and Risser 4b in appearance of the menarche in relation to the Risser grade at initial testing. Ninety-two female from the total sample were divided into Risser 4a (N=45) and Risser 4b (N=47) and the years that past from menarche were recorded. As we observed that the Spearman r showed strong correlation between Risser grade 4a or 4b with the number of months passed since menarche (Spearman $r = -0.498$; $p > 0.05$) we proceeded with the Student t test for independent sample; Risser 4a or 4b being the grouping variable. Even though there

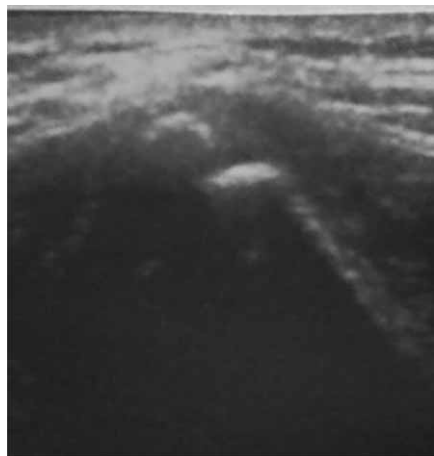


Fig. 2. Risser 4a grade: in transverse sonogram of iliac bone, there is 2 mm or more cartilage between iliac apophysis and iliac wing.

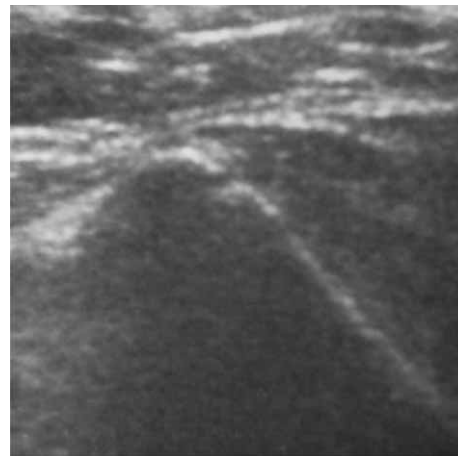


Fig. 3. Risser 4b grade: in transverse sonogram of iliac bone, there is less than 2 mm of cartilage between iliac apophysis and iliac wing.

was no statistically significant difference in mean menarche age (12.6 ± 1.07 vs. 12.71 ± 0.95 ; $p=0.637$) there was a significant difference between the groups in number of years which past since menarche (Table 4).

Group Risser 4b got menarche 2.74 years before they were examined while Group Risser 4a got menarche only 1.57 years before ($p<0.001$, Table 4.). Obviously the girls in Group Risser 4b are distinctively biologically older and they distinguish from the girls in the Group Risser 4a in that variable.

According to the results we could conclude that statistically there is a significant difference between the groups

Risser 4a and Risser 4b and if we observe those subjects in regard to the increase in height over six months and appearance of menarche, the subsample Risser 4a and 4b do not pertain to the same cohort.

Discussion and Conclusion

In determining skeletal maturity, Risser method is very popular among orthopaedic surgeons. Almost every guideline for treating idiopathic scoliosis respects Risser grade in decision weather and when to start brace treat-

TABLE 2
DIFFERENCES IN HEIGHT AND SITTING HEIGHT AT THE BEGINNING OF THE STUDY

	\bar{X} 4a	\bar{X} 4b	SD 4a	SD 4b	F-ratio	t-value	p
Sitting height at 0 months	88.94	88.00	3.88	4.11	1.123	1.089	0.279
Height at 0 months	174.61	171.10	8.26	9.18	1.234	1.857	0.067

SD – standard deviaton

TABLE 3
INCREASE IN HEIGHT AND SITTING HEIGHT AFTER 6 MONTHS FOR RISSER GROUP 4A AND 4B

	\bar{X} 4a	\bar{X} 4b	SD 4a	SD 4b	F-ratio	t-value	p
Sitting height at 6 months	90.18	88.75	4.22	4.34	1.058	1.556	0.123
Increase in sitting height	1.24	0.75	1.35	0.72	3.541	2.290	0.024
Height at 6 months	176.24	172.09	8.59	9.50	1.223	2.123	0.037
Increase in height	1.63	0.99	0.76	0.84	1.213	3.728	0.000

TABLE 4
DIFFERENCES BETWEEN THE RISSER 4A AND RISSER 4B IN APPEARANCE OF THE MENARCHE

	\bar{X} 4a	\bar{X} 4b	SD 4a	SD 4b	F-ratio	t-value	p
Age at menache (years)	12.60	12.71	1.07	0.95	1.273	-0.474	0.637
Menarche before Risser 4 (years)	1.57	2.74	0.92	1.14	1.532	5.341	0.000

TABLE 5
CESSATION OF GROWTH IN CHILDREN GROUP RISSER 4a
AND RISSER 4b

	Six month growth ≤ 1 cm	Six month growth < 1 cm (cessation of growth)
Risser 4a	31	4
Risser 4b	29	28

ment. For idiopathic scoliosis in children Risser up to grade 3 and for girls up to a year after menarche brace should be prescribed⁴.

Many limitations of Risser method, such as very variable (from fair to excellent) interobserver and intraobserver reproducibility was noted^{6,7}. Another limitation is the high frequency of anomalous iliac apophysis development. Risser reported that 10% of all patients have short excursions of ossification⁵. Zaoussis and James and Shuren et al. noted 40 and 41% rates of anomalous development (fragmented ossification, short excursion, posterior ossification, ossification progression from the posteromedial to the anteromedial position)^{6,8}. Repeated X-ray exposure in the follow-up examinations of scoliosis patients may increase the risk of cancer¹⁴.

Although new X-ray machines are available to illustrate the Risser sign with a radiation of 9–10% compared to a standard radiation dose, there are efforts to examine iliac apophysis by ultrasound. According to Thaler et al. and Torlak et al. there is very good agreement in Risser grading between radiographic and ultrasound evaluation^{9,10}.

There are good recommendations when to start scoliosis treatment, but more obscure is when to discontinue brace treatment⁴. Weaning of the brace is usually recommended in Risser grade 4 because growth is insignificant and risk for progression of the curve is minimal^{8,15}. However, Hoppenfeld illustrated that 75.2% of children had further growth after Risser grade 4¹⁶. The mean growth was 1.75 cm in the girls and 2.46 cm in the boys (0.5–8.9 cm) and no growth occurred after apophysis fusion (Risser grade 5).

Little et al. proved that 11% of the girls had their maximum point of curve progression after the Risser

grade 4¹². This percentage is even greater in boys, so Song et al. recommended that idiopathic scoliosis should be followed to Risser stage 5, regardless of age, as there remains a substantial risk for late progression¹³.

The three-dimensional features of ultrasound images impose an idea to make subclassification of Risser grade 4 according to the level of skeletal maturation of iliac apophysis, in order to make clear when to discontinue brace treatment of scoliosis. Our study involved the greatest number of children, published yet, in which Risser grade was examined by ultrasound. Analysing iliac apophysis in a posterior part, children with Risser grade 4 differs in amount of cartilage and bone. Children with less amount of cartilage were expected to have lower growth potential. We proved that in present study. There was statistically significant difference in increase in height and sitting height between Risser 4a and 4b group. If we define cessation of growth as increase in height of less than two centimeters per year, in six month period, growth velocity of less than one centimeter means that child have stopped growing¹⁷.

In our study mean growth for Risser 4b is 0.99 cm. In that group we can conclude with lot of caution that they have stopped growing.

From Table 5 it is obvious that half of children Risser 4b still grow and almost all children from Risser 4a have increased in height. In extension of the study we will try to move a point of division of Risser 4a and 4b to 1.5 or 1 mm in order to have less or neither growth in 4b group. It would be also important to test progression of scoliotic curve in the light of this new classification.

Menarche, as a sign of biological maturity, proved to be a reasonable landmark for predicting curve progression in many studies^{4,8,12,15}. Scoliotic curves are highly unlikely to progress maximally more than two years after menarche.

In our study girls from Risser 4b group got menarche 2.74 years before they were examined while Group Risser 4a got menarche only 1.57 years before. Obviously the girls in group Risser 4b are distinctively biologically older than girls in group Risser 4a.

Subdivision of Risser 4 grade by ultrasound is promising method in determining end of brace treatment for scoliosis.

REFERENCES

- SANDERS JO, BROWNE RH, MCCONNELL SJ, MARGRAF SA, COONEY TE, FINEGOLD DN, *J Bone Joint Surg Am*, 89 (2007) 14. — 2. LITTLE DG, SONG KM, KATZ D, *J Bone Joint Surg Am*, 82 (2000) 685. — 3. STASIKELIS PJ, SULLIVAN CM, PHILLIPS WA, *J Bone Joint Surg Am*, 78 (1996) 1149. — 4. HEFTI F, *Pediatric Orthopedics in Practice*, Springer Verlag Berlin-Heidelberg, 2007. — 5. RISSER J, *Clin Orthop Relat Res*, 11 (1958) 111. — 6. SHUREN NKJ, EMANS J, RAND F, *Spine*, 17 (1991) 359. HOPPENFELD SLB, MURTHY V, ZUN G, *Spine*, 29(2003) 47. — 7. REEM J, CARNEY J, STANLEY M, *Skeletal Radiol*, 38 (2009) 371. — 8. ZAOUSSIS AL, JAMES J, *J Bone Joint Surg Br*, 40 (1958) 442. — 9. THALER M, KAUFMANN G, STEINGRUBER I, *Eur*

- Spine J*, 17 (2008) 1251. — 10. TORLAK G, KITER E, OTO M, AKMAN A, *Spine (Phila Pa 1976)*, 37 (2012) 316. — 11. DIMEGLIO A, *J Pediatr Orthop*, 21 (2001) 549. — 12. LITTLE DG, SONG KM, KATZ D, HERRING JA, *J Bone Joint Surg Am*, 82 (2000) 685. — 13. SONG KM, LITTLE DG, *J Pediatr Orthop*, 20 (2000) 286. — 14. RONCKERS CM, DOODY MM, LONSTEIN JE, *Cancer Epidemiol Biomarkers Prev*, 17 (2008) 605. — 15. LONSTEIN J, *J Bone Joint Surg Am*, 66 (1984) 1061. — 16. HOPPENFELD SLB, MURTHY V, ZUN G, *Spine*, 29 (2003) 47. — 17. BUCKLER JMH, *A Longitudinal Study of Adolescent Growth*, Springer London, 1990.

H. Pitlović

Department of Orthopaedic Surgery, General Hospital »dr. Josip Benčević«, A. Štampara 42, 35000 Slavonski Brod, Croatia

e-mail: hrpitlovic@gmail.com

OPRAVDANOST ULTRAZVUČNE PODJELE RISSER 4 STUPNJA ZA PROCJENU KOŠTANE ZRELOSTI

S A Ž E T A K

U liječenju adolescentne idiopatske skolioze, jedna od najčešće korištenih tehnika za određivanje koštane zrelosti je metoda koju je opisao Risser. Okoštavanje apofize crijevne kosti napreduje od prijeda prema strage kroz četiri zone, a srastanje apofize sa grebenom crijevne kosti (Risser stupanj 5) znači prestanak rasta kralješnice, a tako i kraj progresije skolioze. Glavni nedostaci Risserove metode su izloženost ionizirajućem zračenju i upitna pouzdanost metode, pa se zbog toga istražuje učinkovitost ultrazvuka u procjeni okoštavanja ilijakalne apofize. Osim toga, još uvijek nema stroge preporuke kada prekinuti liječenje skolioze ortozom. Kako bismo razjasnili kada je sigurno završiti liječenje ortozom, u ovoj studiji smo, pomoću ultrazvuka podijelili Risser stupanj 4 na stupanj 4a i 4b, ovisno o količini hrskavice koja još nije okoštala u stražnjem dijelu grebena crijevne kosti. Tijekom šest mjeseci mjerili smo rast u visinu, za 92 zdrave djece, koji su razvrstani ultrazvukom u Risser 4a ili 4b skupinu. Rast je bio značajniji u skupini 4a ($p < 0,001$). Za djevojke smo bilježili vrijeme proteko od prve menstruacije. Djevojke iz skupine Risser 4b su imale menarhu prosječno 2,74 godina prije testiranja, dok su djevojke iz skupine 4a imale menarhu tek prosječno 1,57 godina prije testiranja ($p < 0,001$). Podjela Risser 4 stupnja ultrazvukom na Risser 4a i 4 b stupanj je obećavajuća metoda za određivanju prestanka liječenja skolioze ortozom.