

Complex Regional Pain Syndrome Type I after Diphtheria-Tetanus (Di-Te) Vaccination

Ervina Bilić¹, Ernest Bilić², Marija Žagar¹, Denis Čerimagić³ and Davorka Vranješ¹

¹ University of Zagreb, University Hospital Center, Department of Neurology, Zagreb, Croatia

² University of Zagreb, University Hospital Center, Department of Pediatrics, Zagreb, Croatia

³ General Hospital, Department of Neurology, Dubrovnik, Croatia

ABSTRACT

Complex regional pain syndrome type I (CRPS I) is a disorder of one or more extremities characterized by pain, abnormal sensitivity (allodynia), swelling, limited range of motion, vasomotor instability, fatigue and emotional distress. The symptoms may be aggravated by even minor activity or weather change. It is usually provoked by injury, surgery or injection but in a small proportion of patients CRPS I develops without a clear causative event. There are several literature reports on CRPS after rubella and hepatitis B vaccination. We present a case of CRPS I affecting the left arm after diphtheria and tetanus (Di-Te) vaccination in the left deltoid muscle in a young girl having experienced profound emotional stress before the vaccination procedure. History data on previous minor trauma at the site of vaccination or emotional stress may necessitate temporary vaccination delay due to their proneness to impaired local or systemic immune response and CRPS as a complication of vaccination. If a child or an adult has prominent swelling and severe pain after vaccination, the diagnosis of CRPS I should be considered and if confirmed, the multidisciplinary treatment should start as soon as possible.

Key words: complex regional pain syndrome, diphtheria, tetanus, vaccination, adverse effects

Introduction

Complex regional pain syndrome type I (CRPS I) is a disorder of one or more extremities characterized by pain, abnormal sensitivity (allodynia), swelling, limited range of motion, vasomotor instability, fatigue and emotional distress^{1,2}. CRPS may develop following fractures, limb trauma, infections, soft tissue contusion, tendon ruptures, myocardial infarction, lesions of central and peripheral nervous system, but spontaneous onsets have been also described³⁻⁵. Emotional stress may be an important contributor for CRPS development⁶⁻⁹. The diagnosis is based on clinical parameters, as there is no pathognomonic laboratory test for CRPS I³. The pathogenesis of CRPS I is unclear and treatment is usually multidisciplinary combining conservative treatment including pharmacotherapy, physical management or psychological approach^{8,9}. Interventional therapies such as nerve blockade, sympathetic block, spinal cord and peripheral nerve stimulation, implantable spinal medication pumps, and chemical or surgical sympathectomy are still controversial issues but may be helpful¹⁰. There are

several case reports of CRPS I following immunization with different vaccines, but we found no report of CRPS I development after diphtheria tetanus (Di-Te) vaccination^{8,11,12}. We present a case of CRPS I affecting the left arm after Di-Te vaccination in the left deltoid muscle in a young girl having experienced profound emotional stress before the vaccination procedure. She described her emotional and physical status before the vaccination as 'exhausted and tired'. The patient also reported sleep disturbance and was worried about her family subsistence and her own future. The possible sharing mechanism in all reported cases of CRPS I after immunization is minor trauma during vaccination. Emotional distress is part of the full clinical presentation of CRPS I. Our patient had signs of depression, anxiety and sleep disorder before vaccination. The emotional state, living conditions (social and economic), physical and emotional stress may have also contributed to CRPS I development. Complete clinical presentation of CRPS I is not frequently reported as a possible complication following vaccination. It is pos-

sible that milder forms of CRPS I may be more frequently present but overlooked. If a child or an adult has prominent swelling and severe pain after vaccination, the diagnosis of CRPS I should be considered and if confirmed, the multidisciplinary treatment should start as soon as possible.

Case Report

The 18-year-old girl received Di-Te vaccination in the left deltoid muscle on March 13, 2008. Her past history did not disclose any previous trauma of the shoulder or arm, serious disease or atypical reaction to vaccine. She reported allergy to dust and maggot. Medical history revealed obstructive bronchitis until age 6 and a recent history of laryngitis treated with antibiotics three weeks before admission (azithromycin and amoxicillin with clavulanic acid). For a year before the vaccination she was exposed to severe emotional stress caused by poor social and economic condition in her family and suffered from sleep disorder.

Only fifteen minutes after vaccine injection, she developed swelling of the entire left arm, discoloration of the skin with limited range of motion of the arm and fingers (Figure 1). During the next few hours, she suffered from severe pain in her left shoulder and forearm, subsequently involving the whole left arm. The range of motion was seriously reduced, and at the end of the same day she could only move her fingers. At the time of admission to Department of Neuromuscular Disorders, the patient was not able to move her left arm, the swelling was severe and regional pain was graded as 10/10 points on the pain visual assessment scale. Physical examination showed discoloration of the skin with slow capillary refill. The skin was unremarkable at the site of vaccine injection. Sensation of the arm was normal and there was no paresthesia or hyperesthesia. All laboratory parameters were normal (erythrocyte sedimentation rate, hemoglobin, white blood cell count, biochemistry parameters, thyroid hormones, immunological parameters) and

neuroimaging of the head, cervical spine and brachial plexus revealed no pathologic findings. X-rays and nerve conduction velocity (NCV) showed no pathologic changes. The patient had previously responded modestly to non-steroidal antirheumatics and steroid therapy, so we decided to administer additional analgesia with opioid drugs, pregabalin and antidepressants. Upon psychiatric examination, psychotherapy and pharmacotherapy were recommended because of the emotional distress and family problems. During the 4-week hospital stay, the patient also underwent physical therapy. Towards the end of hospital stay, all therapeutic approaches yielded encouraging results, the pain subsided, the range of motion was less restricted, the swelling was remarkably reduced, and the patient was optimistic and free from sleep disturbance (Figure 2). After one year, the patient still suffered less severe pain, there was no swelling, and her psychological status was significantly improved. The functional status of the arm was not fully satisfactory, as there some restriction in the range of motion persisted.

Discussion and Conclusion

Di-Te vaccine is composed of diphtheria and tetanus toxoid with additional agents, i.e. aluminum phosphate, thiomersalate (preservative), formaldehyde and water. The term CRPS describes primary clinical characteristics of the disease without defined pathogenesis of the syndrome. Two forms of CRPS have been defined: type I, previously called reflex sympathetic dystrophy (RSD) and type II, previously called causalgia⁹. The diagnosis of CRPS I is based exclusively on clinical parameters as there is no typical laboratory parameter characteristic of CRPS I¹³.

It is very important to find out whether a patient with regional pain and swelling has other clinical parameters for CRPS I diagnosis. The leading clinical signs for CRPS I are severe regional pain, allodynia, motor dysfunction, emotional distress, vasomotor instability and skin color changes^{8,9}. The pathogenesis of CRPS has not yet been

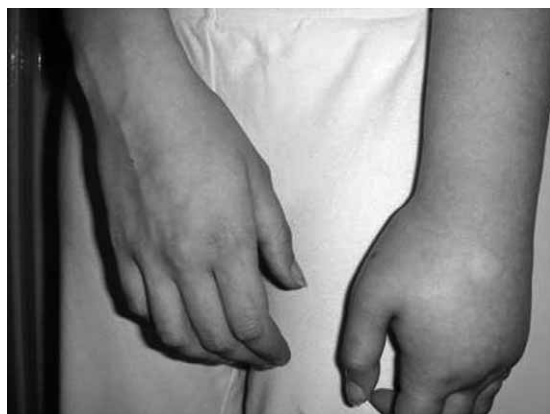

Fig. 1. Fifteen minutes after vaccine injection swelling of the arm, discoloration of the skin with limited range of motion of the arm and fingers was observed.

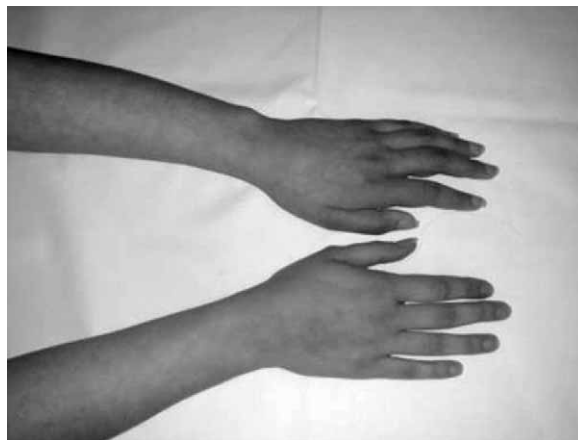


Fig. 2. The swelling of the arm was remarkably reduced after four weeks.

clarified and the view of CRPS indicates that the disorder is not caused by just one system or just one mechanism (e.g., sympathetic afferent coupling, adrenoreceptor disease, peripheral inflammation, hypoxia, psychogenicity)^{14,15}.

In this case report, we present a young girl with CRPS I affecting the left arm after Di-Te vaccination in left deltoid muscle, probably caused by minor trauma on needle insertion. It is known that CRPS I may be caused by cumulative trauma, repetitive injury, or even minor trauma. The severity of physical injury is not related to the risk of CRPS¹⁶. The risk of CRPS may depend on susceptibility for exaggeration of the underlying disease mechanism. This is supported by the observation of abnormal neuroinflammatory responses to triggers in the unaffected limbs of CRPS patients, such as increased NO release from peripheral monocytes upon stimulation with cytokines¹⁷ and enhanced axon-reflex vasodilatation upon electrical C-fiber stimulation¹⁸. These were found in unaffected limbs, suggesting that abnormal responses are innate and do not evolve from the CRPS itself.

Neural activity in postganglionic noradrenergic fibers supplying blood vessels induces the release of norepinephrine and possibly other substances, thus causing vasoconstriction. Excitation of primary afferent fibers causes vasodilatation in precapillary arterioles and plasma extravasation in postcapillary venules by the release of substance P and other vasoactive compounds¹⁴. Some of these effects may be mediated by non-neuronal cells such as mast cells and macrophages (by direct effect or *via* cytokines, i.e. TNF alfa, IL-6, IL-1, tryptase). Macrophages act as antigen presenting cells and can be activated by danger/alarm signals from injured cells, such as

those exposed to pathogens, toxins and mechanical damage¹⁹.

We found only few reports on CRPS I triggered by vaccination with various vaccines. All reported cases of CRPS I after vaccination refer to healthy girls developing CRPS I after needle vaccination on regular recommended immunization^{8,12}. Previous lesion of the tissue injected for vaccination or tissue cell damage by viral infection, along with additional irritation induced by vaccination, may lead to strong macrophage stimulation and consequentially to the effect described above. In other words, even a minor trauma such as blow sustained on physical exercise preceding vaccination may trigger CRPS in susceptible individuals. Therefore, prior to vaccination each individual should be asked about the possible previous, even minimal trauma in the body area to be injected. It is of utmost importance in children active in sports and in preschool children. Our patient was in deep emotional stress before vaccination, which should be taken in consideration for the possible role of emotional stress in modifying normal immune response and in the pathogenesis of CRPS I.

The pathogenesis of CRPS is multifactorial, and several mediators of different disease mechanisms are involved in this complex disorder¹⁵. In this case report, we tried to elucidate some of the possible triggers for CRPS onset following Di-Te vaccination and the impact of previous emotional stress on CRPS development. History data on previous minor trauma at the site of vaccination (in particular in preschool children and athletes) or emotional stress may necessitate temporary vaccination delay due to their proneness to impaired local or systemic immune response and CRPS as a complication of vaccination.

REFERENCES

- MUÑOZ-GOMEZ J, COLLADO A, GRATACÓS J, CAMPISTOL JM, LOMEÑA F, LLENA J, ANDREU J, *Arthritis Rheum*, 34 (1991) 625. — 2. STANTON-HICKS M, JANIG W, HASSENBUSCH S, HADDOX JD, BOAS R, WILSON P, *Pain*, 63 (1995) 127. — 3. DIJKSTRA PU, GROOTHOFF JW, TEN DUIS HJ, GEERTZEN JH, *Eur J Pain*, 7 (2003) 457. — 4. STRAKOWSKI JA, WIAND JW, JOHNSON EW, *Upper limb musculoskeletal pain syndromes*. In: BRADDOM RL (Ed) *Physical medicine and rehabilitation*. 2nd ed. (WB. Saunders Company, Philadelphia, 2000). — 5. DE ROOLJ AM, PEREZ RS, HUYGEN FJ, ELJS FV, KLEEF MV, BAUER MC, van HILTEN JJ, MARINUS J, *Eur J Pain*, 14 (2010) 510. — 6. CIMAZ R, MATUCCI-CERINIC M, ZULIAN F, *J Child Neurol*, 14 (1999) 363. — 7. GEERTZEN JH, de BRUIJN H, de BRUIJN-KOFMAN AT, ARENDZEN JH, *Med Rehabil*, 75 (1994) 442. — 8. JASTANIAH WA, DOBSON S, LUGSDIN JG, PETTY RE, *J Pediatr*, 143 (2003) 802. — 9. LITTLEJOHN G, *Nat Clin Pract Rheumatol*, 3 (2007) 504. — 10. HSU ES, *Am J Ther*, 16 (2009) 147. — 11. KIMMEL SR, *Clin Fam Pract*, 2 (2000) 369. — 12. GENÇ H, KARAGOZ A, SARACOGLU M, SERT E, ERDEM HR, *Eur J Pain*, 9 (2005) 517. — 13. HARDEN RN, BRUEHL S, STANTON-HICKS M, WILSON PR, *Pain Med*, 8 (2007) 326. — 14. JANIG W, BARON R, *Lancet Neurol*, 2 (2003) 687. — 15. DE MOS M, STURKENBOOM MC, HUYGEN FJ, *Pain Pract*, 9 (2009) 86. — 16. RAUIS AL, *Acta Orthop Belg*, 65 (1999) 86. — 17. HARTRICK CT, *Neurosci Lett*, 323 (2002) 75. — 18. LEIS S, WEBER M, SCHMELZ M, BIRKLEIN F, *Neurosci Lett*, 359 (2004) 163. — 19. MATZINGER P, *Science*, 296 (2002) 301.

D. Čerimagić

Department of Neurology, General Hospital, Roka Mišetića 2, 20000 Dubrovnik, Croatia
e-mail: deniscerimagic@yahoo.com

KOMPLEKSNI REGIONALNI BOLNI SINDROM TIP I NAKON CIJEPLJENJA PROTIV DIFTERIJE I TETANUSA (DI-TE)

S A Ž E T A K

Kompleksni regionalni bolni sindrom tip I (CRPS I) je poremećaj koji zahvaća jedan ili više ekstremiteta, a karakterizira se bolovima, smetnjama osjeta (alodinija), oticanjem, ograničenim opsegom kretnji, vazomotornom nestabilnošću, umorom i emocionalnim distresom. Do pogoršanja ovih simptoma mogu dovesti fizička aktivnost ili promjena vremenskih prilika. Pojavu ovog sindroma najčešće uzrokuje ozljeda, kirurški zahvat ili injekcija, a u manjem broju slučajeva uzrok ostaje nepoznat. U literaturi je opisano nekoliko slučajeva pojave CRPS-a nakon cijepljenja protiv ru-beole i hepatitisa B. Prikazujemo slučaj pojave CRPS-a tip I na lijevoj ruci, nakon cijepljenja protiv difterije i tetanusa (Di-Te) u području lijevog deltoidnog mišića, kod djevojčice koja je prije cijepljenja bila pod dubokim emocionalnim stresom. Anamnestički podaci o ranijoj, čak i minimalnoj traumi u području u kojem se planira aplicirati cjepivo ili podatak o emocionalnom stresu mogu biti razlog odgode cijepljenja, kako bi se izbjegli lokalni i sustavni imunološki odgovori te CRPS kao moguća komplikacija cijepljenja. Ukoliko dijete ili odrasli pacijent ima izražen edem ekstremiteta te intenzivnu bol nakon cijepljenja, mora se razmotriti dijagnoza CRPS-a, a ukoliko se ista potvrdi potrebno je što prije započeti s multidisciplinarnim liječenjem.