

*Pre-publication version of paper accepted for publication in Clinical Radiology on 22<sup>nd</sup> February 2019*

# The imaging modality of choice for patients with a suspected scaphoid fracture who have normal initial radiographs: a UK-wide national audit.

M.H. Chunara <sup>a</sup>, C.M. McLeavy <sup>a</sup>, V Kesavanarayanan <sup>a</sup>, D Paton <sup>b</sup> & A Ganguly <sup>a, c</sup>.

<sup>a</sup> *Department of Radiology, Warrington Hospital, Lovely Lane, Warrington, WA5 1QG.*

<sup>b</sup> *Nottingham University Business School, Jubilee Campus, Nottingham, NG8 1BB*

<sup>c</sup> *Guarantor and correspondent: A. Ganguly, Department of Radiology, Warrington Hospital, Lovely Lane, Warrington, WA5 1QG. Tel.: 01925635911. E-mail address: akash.ganguly@nhs.net (A. Ganguly).*

# Abstract

**BACKGROUND:** The prevalence of scaphoid fractures in the young and active patient population is high. Initial suspicion relies on the combination of a clinical examination and scaphoid series. Both of these are imperfect and often result in premature wrist immobilisation, itself associated with significant lifestyle and socioeconomic implications. MRI has been shown to be an effective modality for the investigation of radiographically-occult scaphoid fractures, yet there remains a stark inconsistency in the modality of choice both in the UK and internationally.

**METHODS:** A survey monkey questionnaire was sent to 140 eligible NHS trusts derived from the NHS England database following exclusion of all non-acute and specialist centres. Four questions were asked regarding the provision of MRI for radiographically-occult scaphoid injuries, time-to-MRI, number of MRI scanners in the trust and any alternative imaging offered.

**RESULTS:** Responses were received from 74 trusts (53%). Thirty-eight offered MRI as a first-line test in plain-film occult scaphoid injury, 25 preferred CT and 11 opted for repeat plain radiographs. Of the 38 trusts who offered MRI, 26 were able to offer this within 1 week; the remainder provided it within 2 weeks. No trends were identified based on the size of the hospital or its geographical location. Statistical analysis of the data using logit regression, Pearson correlation coefficients and a negative binomial regression revealed no statistically significant relationship between the number of MRI scanners in the department and the ability to provide an MRI, nor between the numbers of MRI scanners and the time-to-MRI.

**CONCLUSIONS:** There remains a clear disparity, in the UK, in the modality of choice for plain film occult scaphoid injuries. MRI has been consistently recognised in the literature to be a highly-specific, highly-sensitive and cost-effective tool, yet only 51% of trusts who responded provide this service in the UK. Given the patient demographic affected and the resultant loss of working hours from overzealous wrist immobilisation, MRI should be considered as the first-line imaging modality of choice in plain-film occult scaphoid injury, if not a first-line test for acute wrist trauma.

# Introduction

Injury to the carpus is common, particularly amongst the young and active patient population.<sup>1</sup> Of the eight bones that comprise the carpus, the scaphoid is the most commonly injured, accounting for over 90% of all carpal bone fractures.<sup>2</sup>

The current practice in emergency departments in the United Kingdom for the initial evaluation of a scaphoid fracture relies on the use of plain radiographs of the wrist, with dedicated scaphoid views, collectively referred to as a scaphoid series. The negative predictive value of this examination was evaluated by Dorsay et al and returned a weighted average of 74%, meaning that 1 in 4 patients with a normal x-ray will be falsely reassured.<sup>3</sup>

Given the predominantly young patient population, ongoing strain with continued use of the wrist leads to an unacceptable increased risk of complications from untimely treatment. These include avascular necrosis and various forms of malunion, the most severe of which is pseudoarthrosis. This has long been recognised due to the tenuous vascular supply to the scaphoid bone which involves retrograde filling of the proximal pole.

In light of the aforementioned risks, patients with a radiographically-occult scaphoid fracture on the initial scaphoid series, but with a continued high clinical suspicion for a fracture, are offered treatment with a Colles cast or wrist splint and referred for further imaging.<sup>2</sup>

Repeat radiographic imaging at 10-14 days following the injury is still used in many centres in the UK and internationally, relying on the fact that increased resorption at the fracture cleft makes the diagnosis of a scaphoid fracture more conspicuous with time. However,

approximately 5-10% of patients with a clinically-suspected scaphoid injury do not actually transpire to have one, so are needlessly overtreated, suffering a loss of productivity as a result.<sup>1,4</sup>

It is thus crucial that patients are diagnosed and treated correctly and in a timely manner. A variety of imaging modalities including nuclear bone scintigraphy, CT and MRI have been employed as second-line tests in an attempt to improve the accuracy of radiographically-occult scaphoid fracture detection. Current research however confirms that there remains a striking inconsistency in the imaging modality of choice internationally.<sup>5,6,7</sup>

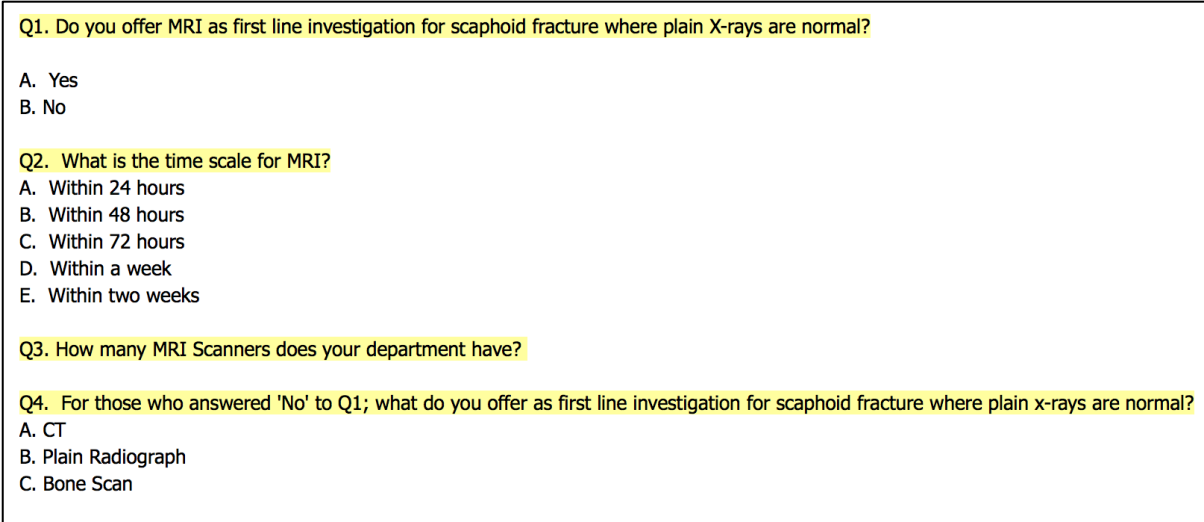
The aim of this national audit was to assess the current practice of scaphoid fracture imaging (where initial scaphoid x-rays are normal) in the United Kingdom, in the midst of inconsistency in the literature and a reasonable directive from most national guidance suggesting a shift towards MRI. In addition, we will review the current literature on scaphoid fracture imaging.

## Materials and Methods

A list of all NHS trusts in the UK was obtained from NHS England. Specialist paediatric, cardiothoracic, mental health, maternity, community and ambulance-specific trusts were excluded.

The email address of the clinical director of radiology or lead musculoskeletal radiologist for each eligible trust was identified either from the trust website or direct telephone contact with the radiology department secretaries.

A Survey Monkey questionnaire was sent to each trust containing four multiple choice questions related to the management of plain film occult scaphoid fractures (Fig 1). A time frame of two months was allowed for response. Those trusts who did not respond were then contacted directly by A Ganguly via an email with the questions attached.



Q1. Do you offer MRI as first line investigation for scaphoid fracture where plain X-rays are normal?

- A. Yes
- B. No

Q2. What is the time scale for MRI?

- A. Within 24 hours
- B. Within 48 hours
- C. Within 72 hours
- D. Within a week
- E. Within two weeks

Q3. How many MRI Scanners does your department have?

Q4. For those who answered 'No' to Q1; what do you offer as first line investigation for scaphoid fracture where plain x-rays are normal?

- A. CT
- B. Plain Radiograph
- C. Bone Scan

Fig 1: Screen shot of the questionnaire sent to trusts. One option could be selected for each question with a free text box for any additional comments related to the question.

Data was collected relating to whether MRI was offered as a first-line test in plain radiograph occult scaphoid injuries, the time scale to MRI being performed, any alternative imaging offered and the number of MRI scanners in the trust.

# Results

After exclusion of the ineligible trusts described above, a total of 140 trusts were identified within the UK for inclusion in the study. Responses were received from 74 of the 140 trusts contacted (53%). Of these 74, 38 offer MRI as a first-line (51%) with 36 offering an alternative imaging modality (49%). Of the 38 trusts who offer MRI as a first line investigation, 26 aim to perform the MRI within 1 week with the remaining 12 aiming to scan within 2 weeks. Of the 36 trusts who offer an alternative imaging modality, 25 opted for CT with 11 offering a repeat plain radiograph as the first-line investigation. One trust does still offer nuclear bone scintigraphy although recognise that this is performed on very few patients and they prefer to use CT as their first-line investigation.

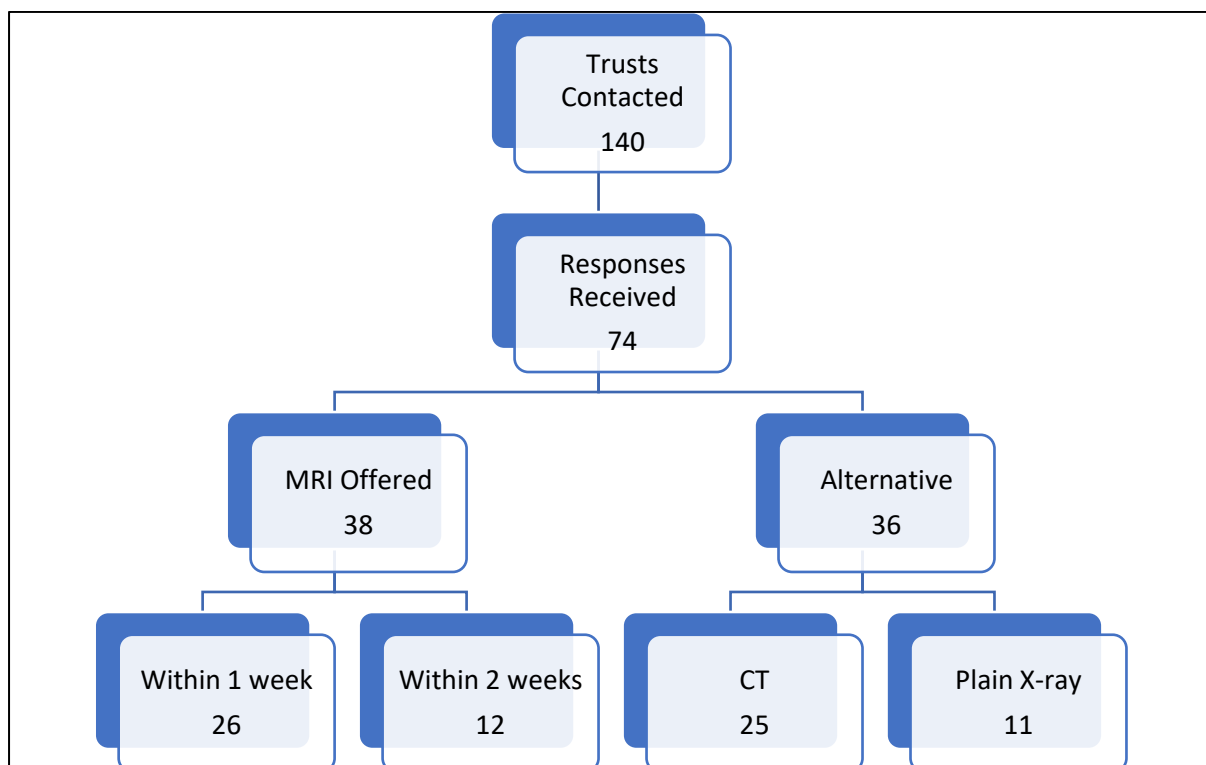


Fig 2: Flow chart demonstrating a summary of the responses received from the questions asked in Fig 1.

The results were split into responses from district general hospitals and teaching trust. No pattern of variability could be found between these groups with 49% of teaching trusts and 48% of district general hospitals offering MRI as a first-line investigation.

Finally, the results were organised geographically with no pattern of geographical variability being identified with 51% of southern trusts and 48% of northern trusts offering MRI as a first-line investigation. The decision to classify a trust as northern or southern was achieved by drawing an arbitrarily placed horizontal line over a map of the UK at the level of Leicester (the authors acknowledge that this is a heavily debated subject however the line had to be drawn somewhere).

<b>Number of MRI Scanners</b>	<b>Trusts</b>
One	19
Two	17
Three	22
More	14
No response	2

Fig 3: Table demonstrating the number of MRI scanners in the trusts who responded to the survey.

### **Statistical Evaluation:**

The responses were also evaluated statistically to address two hypothetical questions; firstly, whether there was a relationship between the number of MRI scanners at the Trust and offering MRI as first-line investigation, and secondly, whether there was a relationship between the number of MRI scanners and how soon MRI was offered. To address the first question, a Logit



regression analysis was performed between trusts that ‘offered MRI as first-line’ and trusts that ‘did not offer MRI as first-line’ investigation with number of scanners as the independent variable. The logistic regression coefficient was 0.0193 with a standard error of 0.1105, which gave a p-value of 0.8614; odds ratio was 1.0195 (95% CI 0.8210 – 1.2659) This meant that greater number of scanners in a trust was associated with a higher probability of an MRI being offered, however the effect was very small and, far from being statistically significant. In other words, there was no evidence that the number of scanners had any effect on whether or not an MRI scan was offered as first-line investigation.

To answer the second question, Pearson correlation coefficient was calculated between number of MRI scanners and time-to-MRI. The Pearson correlation coefficient was 0.1664 which meant a modest, positive association between the number of scanners and the time-to-MRI; however, the p-value was 0.327 (95% CI -0.1666 to 0.4654) meaning that the correlation was not statistically significant. A negative binomial regression analysis performed to answer the same question showed a p-value of 0.229, corroborating the lack of statistical significance indicated by the Pearson correlation test. In other words, again, there was no evidence that the number of scanners had an effect on timing of MRI.

In summary, our survey had a response rate of 53% with 51% offering MRI as a first-line investigation for radiographically-occult scaphoid fractures and 49% offering an alternative modality. No pattern could be identified within the results to suggest why there is variability between the first line investigation of choice in suspected scaphoid fractures within UK trusts. In other words, there was no evidence that the number of scanners had any effect on whether or not an MRI scan was offered as first-line investigation; nor did it have any effect on the timing of such MRI.



# Discussion

Scaphoid fractures are not only common, but typically present in a patient demographic who, with incorrect treatment, suffer significant morbidity and loss of productivity.<sup>8,9</sup> This is due to a spectrum of outcomes from accelerated osteoarthritic changes secondary to delayed treatment, to lost working hours for the self-employed – the end result of needless wrist immobilisation.

We performed this national, UK-wide audit to assess whether there has been any progress in determining the modality of choice for patients with radiographically-occult scaphoid fractures. The results of our national audit reaffirm the inconsistency in the imaging modality of choice for patients with a plain x-ray occult scaphoid fracture, with 51% preferring MRI, 34% utilising CT and 15% relying purely on repeat radiographs. Perhaps surprisingly, nuclear bone scintigraphy was not used by any of the respondents as the preferred first-line modality for radiograph-negative scaphoid fracture evaluation.

It has long been known that the sensitivity of the clinical examination is high with most studies reporting sensitivity figures approaching 100%.<sup>2,8</sup> Conversely however, the specificity of the clinical examination for a scaphoid fracture is poor. Tenderness over the anatomical snuffbox has a specificity of just 9%, over the scaphoid tubercle – 30% and on longitudinal thumb compression – 48%.<sup>8</sup> Even when all three findings are evaluated for together, the combined overall specificity still only reaches 74%. Even less reassuring however, is the positive predictive value of the clinical examination, which ranged between 13% and 69% - with a weighted average of 21% - in an American hospital over a 6-year interval.<sup>3</sup>

As an imaging modality for radiographically-negative scaphoid fractures, MRI has been shown to be a cost-effective, highly-sensitive and highly-specific test.<sup>2-9</sup> Brydie et al evaluated 195 patients in a UK hospital with a high clinical suspicion for acute wrist trauma and who had a negative initial scaphoid series.<sup>10</sup> Early MRI detected 74 fractures (37 scaphoid fractures and 37 non-scaphoid fractures including other bones in the carpus and distal radius) and 119 patients with no fracture. The study concluded that the management of 180 patients, that is 92% of the total cohort, was altered as a result of early MRI scanning. In a similar study by Kumar et al, 22 patients were evaluated with an early MRI at an Australian major referral emergency department.<sup>11</sup> Of the 22 patients referred, 9 had evidence of wrist bone fractures (including the scaphoid [6], distal radius [2] and hamate [1]) with no fracture demonstrated in the remaining 13 patients. Of these 13 patients, a repeat clinic review at 10 days permitted discharge of 5 patients with no ongoing clinical concerns. The remaining 8 went on to have a repeat MRI which confirmed no fracture. Overall the sensitivity and specificity for early MRI scanning in this study was 100%. A larger scale study in a UK hospital by Khalid et al assessed 611 patients with a clinically-suspected scaphoid fracture and negative initial radiographs.<sup>2,13</sup> MRI revealed 272 cases with bony injuries including scaphoid fractures, 23 patients with soft tissue injuries, 47 patients with incidental pathologies and 269 patients with no pathology demonstrated.<sup>2</sup> More recent studies from 2017 also show comparable results, as demonstrated by Prasad et al.<sup>12</sup>

In patients for whom MRI is not suitable, the options of CT and nuclear bone scintigraphy (NBS) can be utilised.

NBS has a very high sensitivity and negative predictive value for scaphoid fractures with most studies reporting figures reaching 100% for both parameters.<sup>2,14-18</sup> However, the specificity and

positive predictive value for scaphoid fractures is poor as it often struggles to differentiate true fractures from bone oedema, soft tissue injury and inflammatory arthropathies.<sup>4</sup> In addition, NBS is infrequently used on an emergent basis given the complex nature of the study and availability of the radionuclide, which results in patients requiring a cast or wrist splint for at least a short period of time.<sup>3</sup> This precludes its routine use for scaphoid fracture evaluation in modern day emergency departments.

CT is the preferred modality for scaphoid fracture detection if MRI is not suitable. Whilst being marginally less sensitive than NBS, it maintains a high specificity and accuracy owing to the enhanced bone reconstructions which provide superior cortical and trabecular resolution.<sup>19</sup>

Two published reviews of the three modalities described above (MRI, NBS and CT) are currently available with the study by Yin et al representing the latest Cochrane review.<sup>2,4</sup> Yin et al evaluated 15 studies on NBS with a total of 1102 patients, 10 studies on MRI with a total of 513 patients and 6 studies on CT with a total of 211 patients.<sup>4</sup> The specificity, sensitivity and logarithmic diagnostic odds ratio for NBS was 97%, 89% and 4.78, for MRI the results were 96%, 99% and 6.6 and for CT the results were 93%, 99% and 6.11 respectively. Ring et al showed comparative results in their published review.<sup>20</sup>

Though the reviews above have some limitations, including the lack of randomisation and generally small cohort populations, the results from extensive publications on this subject matter to date highlights MRI as the superior imaging modality for investigating radiographically-occult scaphoid fractures. Of course, MRI has the added benefit of being able to detect non-scaphoid-related pathology and is also capable of scanning through a cast, if in

situ at the time of the examination.<sup>3</sup> Nonetheless, there will be patients for whom MRI is not suitable or available, and for these patients, CT is the next best modality of choice.

This is largely in line with national and international guidance provided by the Royal College of Emergency Medicine (RCEM), American College of Radiology (ACR, Appropriateness Criteria), Royal College of Radiology (RCR, iRefer), National Institute for Health and Care Excellence (NICE) and the orthopaedic/radiology literature.<sup>2,4,21,22,23,27</sup>

**RCEM (2013):** *“MRI appears to have the best diagnostic performance ... CT scanning is a reasonable alternative if MRI is not possible or contraindicated”*.<sup>2</sup>

**ACR (2013):** *“MRI is the study of choice. For patients with contraindications to MRI, CT is preferred to scintigraphy”*.<sup>21</sup>

**RCR:** *“MRI is accurate and cost-effective. Low-dose CT is an alternative”*.<sup>22</sup>

**NICE (2016):** *“Consider MRI for first-line imaging in people with suspected scaphoid fractures following a thorough clinical examination”*.<sup>23</sup>

**Radiology literature - Yin et al (2009):** *“Based on the current evidence, MRI is highly accurate for confirming and excluding the diagnosis of scaphoid fractures and might be used as the first choice in a patient with a suspected scaphoid fracture”*.<sup>4</sup>

**Orthopaedic literature – Adams et al (2017):** *“If there is clinical suspicion for a fracture, one should obtain an MRI scan, which has the highest sensitivity and specificity for diagnosis”*.<sup>27</sup>

The accessibility of MRI and its cost-implications are often put forward as limiting factors precluding its use early in scaphoid fracture detection. A comprehensive study by Dorsay et al however revealed promising results.<sup>3</sup> They evaluated a number of patients admitted through

the emergency department with acute wrist trauma and compared the costs associated with a screening MRI using a fast image acquisition protocol (10 minutes actual scan time; coronal T1 and fat-saturated T2-weighted images) and traditional management. Their results consistently demonstrated that early MRI is a cost-effective method for scaphoid fracture detection; in those in whom the test was negative, the avoidance of costs associated with orthopaedic consult in the emergency department and at follow-up, multiple scaphoid radiographs and premature limb casting offered significant cost savings. Moreover, early screening MRI was performed at a reduced cost of \$770 USD, compared with the routine MRI wrist study that was often requested during repeated clinic attendances, which was performed at a cost of \$1256 USD.

Hansen et al provided similarly impressive cost-analysis data showing that subacute MRI in patients with suspected scaphoid fractures but normal initial radiographs increased the in-hospital costs by 151 EUR but reduced non-hospital costs (immobilisation time and sick leave) by 2869 EUR, once again demonstrating significant cost savings.<sup>24,25</sup>

Raby compared early versus late MRI scanning in patients with a negative scaphoid series using a dedicated 0.2 tesla extremity scanner in a Scotland hospital at a cost of just £50 per examination.<sup>26</sup> He identified that early MRI scanning altered patient management in 89% of cases, versus 69% of patients in whom the MRI scan was delayed. Moreover, there were much fewer cases referred for MRI evaluation than expected, with no significant increase in the number of examinations requested following provision of the early MRI service. Concluding, he described that overall costs changed very little when compared to standard practice for the significant patient benefits that were incurred.

With the availability of relatively cheap extremity MRI scanners in the United Kingdom, the role of early MRI scanning should be recognised not only for its long-term overall cost-savings, but also for the ease of patient imaging. Limited field extremity scanners permit the elderly and infirm to be scanned in a supine position with the arm held abducted, a population who would otherwise struggle to adopt the prone position required in a non-dedicated scanner.<sup>26</sup>

But how soon should patients be scanned? Early scanning of course allows patients with no significant pathology to be discharged with the resultant cost benefits to the hospital and society but adds strain to an already pressurised and constrained imaging directorate. A study by Langhoff et al described that most scaphoid fractures developed healing-related complications when treatment was delayed by 4 weeks, with no significant risk in the first 4 weeks following trauma.<sup>27</sup> As our results demonstrated, of the trusts that offer MRI as a first-line test in radiograph-negative scaphoid fractures, 100% are able to offer it within 2 weeks.

In conclusion, our study demonstrates that whilst MRI is a preferred imaging modality amongst UK trusts (51%), there remains inconsistency in the imaging requested for patients with radiographically occult scaphoid fractures. Time-to-MRI is not influenced, based on UK data, by the number of MRI scanners in a department, or by the size of the hospital.

Given the wealth of evidence in favour of early MRI scanning, long-term cost-savings, advent of cheap extremity scanners with rapid acquisition times and the added socioeconomic benefit of avoiding hasty casting, MRI should be the investigation of choice for all acute hospitals in the United Kingdom, either as a first-line test for patients with a suspected scaphoid fracture, or for those in whom the initial scaphoid x-rays are normal.



# References

1. Kaewlai R, Avery L, Asrani A, Abujudeh H, Sacknoff R, Novelline R. Multidetector CT of Carpal Injuries: Anatomy, Fractures, and Fracture-Dislocations. *RadioGraphics*. 2008;28(6):1771-1784.
2. Benger J, Machin E, Blackham J. GEMNet guideline: Management of Suspected Scaphoid Fractures in the Emergency Department [Internet]. RCEM Guidance. 2013 [cited 2 June 2018]. Available from: [https://www.rcem.ac.uk/docs/College%20Guidelines/5z25.%20Suspected%20Scaphoid%20Fractures-%20\(Flowchart\)%20\(Sept%202013\).pdf](https://www.rcem.ac.uk/docs/College%20Guidelines/5z25.%20Suspected%20Scaphoid%20Fractures-%20(Flowchart)%20(Sept%202013).pdf)
3. Dorsay T, Major N, Helms C. Cost-Effectiveness of Immediate MR Imaging Versus Traditional Follow-Up for Revealing Radiographically Occult Scaphoid Fractures. *American Journal of Roentgenology*. 2001;177(6):1257-1263.
4. Yin Z, Zhang J, Kan S, Wang X. Diagnosing Suspected Scaphoid Fractures: A Systematic Review and Meta-analysis. *Clinical Orthopaedics and Related Research*®. 2009;468(3):723-734.
5. Foex B. Magnetic resonance imaging or bone scintigraphy in the diagnosis of plain x ray occult scaphoid fractures. *Emergency Medicine Journal*. 2005;22(6):434-435.

6. Tiel-van Buul M, Roolker W, Broekhuizen A, Van Beek E. The diagnostic management of suspected scaphoid fracture. *Injury*. 1997;28(1):1-8.
7. Groves A, Kayani I, Syed R, Hutton B, Bearcroft P, Dixon A et al. An International Survey of Hospital Practice in the Imaging of Acute Scaphoid Trauma. *American Journal of Roentgenology*. 2006;187(6):1453-1456.
8. PARVIZI J, WAYMAN J, KELLY P, MORAN C. Combining the Clinical Signs Improves Diagnosis of Scaphoid Fractures. *Journal of Hand Surgery*. 1998;23(3):324-327.
9. Steinmann S, Adams J. Scaphoid fractures and nonunions: diagnosis and treatment. *Journal of Orthopaedic Science*. 2006;11(4):424-431.
10. Brydie A, Raby N. Early MRI in the management of clinical scaphoid fracture. *The British Journal of Radiology*. 2003;76(905):296-300.
11. Kumar S, O'Connor A, Despois M, Galloway H. Use of early magnetic resonance imaging in the diagnosis of occult scaphoid fractures: the CAST Study (Canberra Area Scaphoid Trial). *The New Zealand medical journal*. 2005;118(1209).
12. Prasad C, Pyadala N. The Role of Radiology in Diagnosis and Management of Scaphoid Fracture. *IAIM*. 2017;4(6):175-180.
13. Khalid M, Jummani Z, Kanagaraj K, Hussain A, Robinson D, Walker R. Role of MRI in the diagnosis of clinically suspected scaphoid fracture: analysis of

- 611 consecutive cases and literature review. *Emergency Medicine Journal*. 2010;27(4):266-269.
14. STORDAHL A, SCHJØTH A, WOXHOLT G, FJERMEROS H. Bone Scanning of Fractures of the Scaphoid. *Journal of Hand Surgery*. 1984;9(2):189-190.
15. WAIZENEGGER M, WASTIE M, BARTON N, DAVIS T. Scintigraphy in the Evaluation of the “Clinical” Scaphoid Fracture. *Journal of Hand Surgery*. 1994;19(6):750-753.
16. Akdemir Ü, Atasever T, Sipahioğlu S, Türkölmez Ş, Kazimoğlu C, Şener E. Value of bone scintigraphy in patients with carpal trauma. *Annals of Nuclear Medicine*. 2004;18(6):495-499.
17. Young M, Lowry J, Laird J, Ferguson W. <sup>99</sup>Tcm-MDP bone scanning of injuries of the carpal scaphoid. *Injury*. 1988;19(1):14-17.
18. Jørgensen T, Andresen J, Thommesen P, Hansen H. Scanning and Radiology of the Carpal Scaphoid Bone. *Acta Orthopaedica Scandinavica*. 1979;50(6):663-665.
19. Tiel-van Buul M, van Beek E, Dijkstra P, Bakker A, Broekhuizen T, van Royen E. Significance of a hot spot on the bone scan after carpal injury — evaluation by computed tomography. *European Journal of Nuclear Medicine*. 1993;20(2):159-164.

20. Ring D, Lozano-Calderón S. Imaging for Suspected Scaphoid Fracture. *The Journal of Hand Surgery*. 2008;33(6):954-957.
21. Bruno M, Weissman B, Kransdorf M, Adler R, Appel M, Beaman F et al. Acute hand and wrist trauma [Internet]. ACR Appropriateness Criteria®. [cited 3 June 2018]. Available from:  
<https://acsearch.acr.org/docs/69418/Narrative/>
22. Wrist injury: suspected scaphoid fracture [Internet]. iRefer Guidelines. [cited 3 June 2018]. Available from: <https://www.irefer.org.uk/guidelines>
23. National Institute for Health and Care Excellence. (2016). *Fractures (non-complex): assessment and management / Guidance and guidelines / NICE*. [online] Available at:  
<https://www.nice.org.uk/guidance/ng38/chapter/Recommendations#acute-stage-assessment-and-diagnostic-imaging> [Accessed 10 Jun. 2018].
24. HANSEN, T., PETERSEN, R., BARCKMAN, J., UHRE, P. and LARSEN, K. (2009). Cost-effectiveness of MRI in managing suspected scaphoid fractures. *Journal of Hand Surgery (European Volume)*, 34(5), pp.627-630.
25. Tibrewal, S., Jayakumar, P., Vaidya, S. and Ang, S. (2011). Role of MRI in the diagnosis and management of patients with clinical scaphoid fracture. *International Orthopaedics*, 36(1), pp.107-110.

26. Raby, N. (2001). Magnetic Resonance Imaging of Suspected Scaphoid Fractures Using a Low Field Dedicated Extremity MR System. *Clinical Radiology*, 56(4), pp.316-320.
27. LANGHOFF, O. and ANDERSEN, J. (1988). Consequences of late immobilization of scaphoid fracture. *The Journal of Hand Surgery: Journal of the British Society for Surgery of the Hand*, 13(1), pp.77-79.
28. Adam, J. and Woodruff, M. (2017). Acute scaphoid fractures and non-unions. *Orthopaedics and Trauma*, 31(4), pp.257-265.