

# Cognitive decline and white matter changes in mesial temporal lobe epilepsy

Shang-wen Xu, MD<sup>a</sup>, Ji-hui Xi, MM<sup>a</sup>, Chen Lin, PhD<sup>b</sup>, Xiao-yang Wang, BE<sup>a</sup>, Li-yuan Fu, ME<sup>a</sup>, Stephen Francis Kralik, MD<sup>c</sup>, Zi-qian Chen, MD<sup>a,\*</sup>

## Abstract

Noninvasive imaging plays a pivotal role in assessing the brain structural and functional changes in presurgical mesial temporal lobe epilepsy (MTLE) patients. Our goal was to study the relationship between the changes of cerebral white matter (WM) and cognitive functions in MTLE patients.

Voxel-based morphometry (VBM) and tract-based spatial statistics (TBSS) MRI were performed on 24 right-handed MTLE patients (12 with left MTLE and 12 with right MTLE) and 12 matching healthy controls. Gray matter (GM), WM, and whole brain (WB) volumes were measured with VBM while fractional anisotropy (FA), mean diffusivity (MD), axial diffusivity (AD), and radial diffusivity (RD) were measured with TBSS. All patients and controls also underwent Montreal Cognitive Assessment (MoCA) before MRI.

WM volume and the ratio of WM volume versus WB volume were significantly lower in MTLE patients compared with controls. WM volume in MTLE patients had a positive correlation with MoCA score ( $r = 0.71$ ,  $P < .001$ ) and a negative correlation with the duration of epilepsy ( $r = -0.693$ ,  $P < .001$ ). Volumetric differences were mainly located in the corpus callosum, uncinate fasciculus, inferior longitudinal fasciculus, and superior longitudinal fasciculus. FA of both left MTLE and right MTLE groups was significantly decreased, while MD, AD, and RD were significantly increased. Most left MTLE patients showed bilateral WM fiber tract changes versus ipsilateral changes for right MTLE patients.

Changes in DTI parameters and WM volume were found in MTLE patients and more ipsilateral changes were seen with right-sided MTLE. Cognitive changes of MTLE patients were found to be correlated with the changes in WM structure. These findings not only provide useful information for lateralization of the seizure focus but can also be used to explain functional connectivity disorders which may be an important physiological basis for cognitive changes in patients with MTLE.

**Abbreviations:** AD = axial diffusivity, FA = fractional anisotropy, GM = gray matter, MD = mean diffusivity, MoCA = Montreal Cognitive Assessment, MTLE = mesial temporal lobe epilepsy, RD = radial diffusivity, TBSS = tract-based spatial statistics, VBM = voxel-based morphometry, WB = whole brain, WM = white matter.

**Keywords:** mesial temporal lobe epilepsy, tract-based spatial statistics, voxel-based morphometry

## 1. Introduction

Epilepsy is a reoccurring chronic neurological disease caused by a variety of etiologies. There are more than 9 million epilepsy patients in China, of which, 20% to 30% are drug-resistant temporal lobe epilepsy. Mesial temporal lobe epilepsy (MTLE),

caused by mesial temporal lobe sclerosis, is the most common intractable epilepsy in adults.<sup>[1]</sup> Repeated abnormal electrical discharges in the brain of MTLE patients can cause microstructural damages in WM fiber tracts, resulting in brain connectivity disorders and central nervous system dysfunction.<sup>[2,3]</sup> With the progression of disease, the cognitive function of MTLE patients, such as language, perception, emotion, attention and memory, may also decline, even to a degree that it can impact personality and other high level social ability.

Although MTLE patients have severe clinical symptoms and imaging can identify mesial temporal sclerosis, for the majority of MTLE patients, conventional MRI sequences do not show obvious abnormalities in the remainder of the brain parenchyma.<sup>[4]</sup> Therefore, more sensitive MRI methods, such as diffusion tensor imaging, are needed to noninvasively detect and exam microstructural changes in the brain of MTLE patients.<sup>[5]</sup> In recent years, advanced MRI methods have been used to assess the brain structural and functional changes of epilepsy patients.<sup>[6–8]</sup> A recent meta-analysis of DTI studies in MTLE patients revealed significant, widespread microstructural changes across the majority of WM regions, with the most obvious deficits occurring in regions closely connected to the temporal WM, including the arcuate fasciculus, uncinate fasciculus, and inferior longitudinal fasciculus.<sup>[9]</sup> However, most studies reported in the literature are for unilateral MTLE.<sup>[6,10]</sup> A very limited number of studies have compared the difference between left and right MTLE and some of them are only based on clinical

Editor: Devrimsel Harika Ertem.

Funding: The project was supported by the Key Program of Fujian Province Science and Development Foundation (Grant No. 2009Y0037).

The authors have no conflicts of interest to disclose.

Supplemental Digital Content is available for this article.

<sup>a</sup> Department of Medical Imaging, Fuzhou General Hospital, Xi'erhuan Beilu, Fuzhou, Fujian, PR China, <sup>b</sup> DABR Department of Radiology Mayo Clinic,

<sup>c</sup> Department of Radiology and Imaging Science, Indiana University School of Medicine, Indianapolis, IN.

\* Correspondence: Zi-qian Chen, Department of Medical Imaging, Fuzhou General Hospital, Xi'erhuan Beilu, Fuzhou, Fujian 350025, PR China (e-mail: czqfz1108@163.com).

Copyright © 2018 the Author(s). Published by Wolters Kluwer Health, Inc. This is an open access article distributed under the terms of the Creative Commons Attribution-Non Commercial License 4.0 (CCBY-NC), where it is permissible to download, share, remix, transform, and buildup the work provided it is properly cited. The work cannot be used commercially without permission from the journal.

Medicine (2018) 97:33(e11803)

Received: 3 January 2018 / Accepted: 16 July 2018

<http://dx.doi.org/10.1097/MD.00000000000011803>

diagnosis and EEG results without surgical or pathological confirmation.<sup>[11]</sup>

New MRI techniques that are sensitive to the minor volume and diffusion changes in the WM resulting from microstructural changes have become available. Voxel-based morphometry (VBM) uses statistical parametric mapping (SPM) to detect small and focal differences in the brain and the spatial location of such differences. For each voxel in a three-dimensional volume, the differences in gray matter (GM), WM, and cerebrospinal fluid (CSF) are evaluated respectively. Such information is helpful for the detection and localization of small changes to the brain.<sup>[12]</sup> VBM has been widely used in the study of normal brain development, as well as neurological and metabolic diseases such as Alzheimer's disease,<sup>[13]</sup> migraine,<sup>[14]</sup> language disorder,<sup>[15]</sup> autism,<sup>[16]</sup> depressive disorder,<sup>[17]</sup> and so on. DTI is a noninvasive imaging technique that can reveal the three-dimensional morphology of WM fiber tracts *in vivo*.<sup>[18–20]</sup> DTI can quantitatively measure the structural integrity of WM by measuring the parameters of diffusion process. DTI data analysis methods include: region of interest (ROI) measurement, voxel-based analysis (VBA), DTT, tract-based spatial statistics (TBSS), etc. TBSS has been widely used in the study of WM structure in the development of normal brain as well as in many diseases or pathological conditions, such as Alzheimer's disease,<sup>[21,22]</sup> chronic musculoskeletal pain,<sup>[23]</sup> schizophrenia,<sup>[24–26]</sup> and so on. TBSS was reported capable of automatically analyzing WM tracts in the whole brain (WB) and was found to be more accurate than VBM in locating areas of difference.<sup>[27,28]</sup> Abnormal DTI parameters were not confined to the temporal lobe in MTLE patients. The abnormalities could be outside of temporal lobe, especially in the WM with bilateral distribution, suggesting that the effect of MTLE is distributed throughout the brain.<sup>[20,29,30]</sup> This is due to the abnormal discharge in one side of the brain also affects the opposite side connected through WM fiber tracts. It not only causes neuronal abnormalities locally and in adjacent areas, but also structural changes in contralateral brain tissue.<sup>[31]</sup> Overall, VBM and DTI allow better understanding of the neuropathological mechanisms and their relationship with clinical manifestations. These new imaging methods not only can provide information for the diagnosis of MTLE, but also can be helpful in the lateralization and localization of epileptogenic foci.

In this study, we used VBM to measure GM, WM and WB volumes and TBSS to measure WM fractional anisotropy (FA), mean diffusivity (MD), axial diffusivity (AD), and radial diffusivity (RD) in MTLE patients in order to study their relationships with the cognitive function.

## 2. Methods

This study was approved by the Hospital Ethics Committee and written informed consent was obtained from all subjects.

### 2.1. Patients

**Control group:** The inclusion criteria for the patient group were: unilateral temporal lobe origin as indicated by seizure characteristics (complex partial seizure) and by EEG during the episodes of seizure; confirmation of mild hippocampal sclerosis by postsurgical pathology; duration of epilepsy  $\geq 2$  year and at least 2 different, appropriate antiepileptic drugs treatment was ineffective based on Engel classification of epilepsy efficacy assessment;<sup>[32]</sup> preoperative MRI including volumetric imaging and

DTI. The final determination of epilepsy laterality and location was based on comprehensive preoperative clinical evaluation, postoperative pathology, and the outcomes of surgical intervention. The exclusion criteria for the patient group were: history of head trauma, mental disorder or family history of psychosis and alcoholism; diabetes,<sup>[33]</sup> cardio-cerebrovascular disease,<sup>[34]</sup> and other serious systemic diseases which have been reported to affect the cerebral WM.

During the period of January 2014 to January 2015, 24 patients who met the above criteria were enrolled. Among the 24 MTLE patients, 12 of them had left MTLE (LMTLE) and the remaining 12 had right MTLE (RMTLE).

**Control group:** The inclusion criteria for the healthy control group were: no history of neurosurgery and psychosis and other neurological diseases, no abnormal liver and kidney function; no history of diabetes; and no abnormal imaging finding.

### 2.2. Cognitive assessment and MRI examination

One hour before the MRI examination, subjects were tested for cognition using the Montreal Cognitive Assessment (MoCA), which is a widely used screening tool assessing multiple cognitive domains including short-term memory; visuospatial ability; executive function; verbal abstraction; attention, concentration and working memory; language ability and orientation to time and place.<sup>[35]</sup> All MRI examinations were performed on a 3.0T scanner (Siemens MAGNETOM Tim Trio, Erlangen, Germany) with a 12-channel phased array head coil. Subjects were instructed to remain still in supine position with eyes closed during MRI. A foam pad was used for head support and stabilization and cottons balls were placed in the ears for noise reduction.

All subjects underwent T2-weighted FSE and FLAIR scans to rule out other brain lesions. A 3D magnetization prepared rapid acquisition gradient echo (3D MP-RAGE) sequence was used to acquire sagittal T1-weighted images for VBM analysis. The imaging parameters were: TR/TE=1900 ms/2.5 ms, FOV=256 mm  $\times$  256 mm, slice thickness=1.0 mm, slice gap=0 mm, number of slices=160, flip angle=9°, matrix=256  $\times$  256, averages=1, voxel size=1 mm  $\times$  1 mm  $\times$  1 mm. For DTI, a single-shot diffusion weighted echo planner imaging (SS-DW-EPI) sequence was used. The scanning parameters were: TR/TE=6100 ms/93 ms, FOV=240 mm  $\times$  240 mm, matrix=128  $\times$  128, slice thickness=3.0 mm, slice gap=0.0 mm, averages=4, b=0 and 1000 s/mm<sup>2</sup> and number of diffusion encoding directions=30. The scanning time was 12:54.

### 2.3. Image processing and quantification

3D T1 weighted morphological brain images were first registered with the standard template and then segmented using the IBASPM tool in the SPM software package SPM8 (SPM, <http://www.fil.ion.ucl.ac.uk/spm>) based on MATLAB 2009a (MathWorks, Natick, MA) in order to calculate WB volume, GM volume, WM volume and the ratios of WM/WB, GM/WB, and GM/WM. Using FSL 5.0.7 software (<http://www.fmrib.ox.ac.uk/fsl/>), diffusion weighted images were corrected for head motion and distortions by registering them to the b=0 images with an affine transformation, and the nonbrain structures were removed by the BET tools using b=0 images as reference. The FA, MD, AD, and RD values were calculated using the DTIFIT tool in FSL based on the method proposed by Stejskal and Tanner.<sup>[36]</sup> Then, a mean FA images was generated to produce a mean skeleton

**Table 1**  
**Demographic and clinical informationa.**

	Sex (M/F)	Age, years (mean ± SD)	Education level, years (mean ± SD)	Duration of disease (yr) (mean ± SD)
LMTLE	5/7	15–45 (28.83 ± 9.89)	5–15 (10.33 ± 2.64)	2–20 (9.63 ± 4.24)
RMTLE	7/5	22–42 (29.75 ± 5.88)	4–15 (10.25 ± 3.89)	1–16 (8.50 ± 3.85)
Control Group	5/7	23–43 (28.25 ± 7.24)	3–18 (12.75 ± 4.61)	

LMTLE=left mesial temporal lobe epilepsy, RMTLE=right mesial temporal lobe epilepsy.

with FA threshold set to 0.2,<sup>[27]</sup> which represented the centroids of all tracts common to the group, each subject’s aligned FA data were projected onto the skeleton, and tract-based spatial statistics (TBSS) were used to voxel-wise cross-subject statistical analysis. Nonparametric inference testing was conducted using the “randomize” tool in FSL with 500 permutations. For the multiple comparison corrections, the threshold-free cluster enhancement (TFCE) with FWE ( $P < .05$ ) was employed. The spatial locations of the various brain regions were expressed in MNI (Montreal Neurological Institute) coordinates. Finally, the TBSS results of the 4 diffusion anisotropy parameters were mapped to the standard WM fiber tract atlas produced by Johns Hopkins University (JHU White-Matter Tractography Atlas) for accurate localization of the abnormal WM fiber tracts.

**2.4. Statistical analysis**

Statistical analysis was performed using SPSS 17.0 software (SPSS Inc, Chicago, Illinois).  $P < .05$  was considered statistically significant. The differences of gender, age, duration of disease, and level of education were compared between the 2 groups using One-Way ANOVA and chi-square test. Two independent sample *t*-tests were used to compare the quantitative parameters of WB, GM, and WM volumes between the MTLE and the control group, and the parameters of DTI on fiber skeleton images between RMTLE, LMTLE, and control group, respectively. Bivariate correlation analysis was used to analyze the correlation between WM volumes and cognitive function assessment as well as the duration of disease.

**3. Results**

**3.1. Demographics**

Characteristics of all subjects were summarized in Table 1. There was no significant difference in gender ( $\chi^2 = 0.892, P = .640$ ), age ( $F = 0.111, P = .895$ ) and educational level ( $F = 1.673, P = .203$ ) between the patient groups and the control group.

**3.2. MoCA score**

MoCA scores in the MTLE group were lower compared with the control group as shown in Table 2. There were significant differences ( $P < .05$ ) in visuospatial and executive function, naming, memory, abstraction, and total score.

**3.3. WM volume**

There was a reduction in WB, GM, and WM volumes in the MTLE group compared with the control group as shown in Table 3. However, only WM volume and WM/WB ratio differences were statistical significant ( $P < .05$ ).

**3.4. Relationship between WM volume, MoCA scores, and duration of disease**

Pearson correlation analysis showed a positive correlation ( $r = 0.71, P < .001$ ) between WM volume and total MoCA score for the MTLE group (Fig. 1) and a negative correlation ( $r = -0.693, P < .001$ ) between WM volume and the duration of epilepsy (Fig. 2).

**3.5. Differences in FA**

Compared to the control group, WM tracts with decreased FA were predominantly bilateral in the LMTLE group versus more ipsilateral in the RMTLE group (Fig. 3). WM tracts with statistically significant reduction of FA are listed in Tables 4 and 5. No WM tract was found to have elevated FA in the patient group.

**3.6. Differences in MD**

Compared to the control group, WM areas with increased MD in the LMTLE group were predominantly bilateral while areas with increased MD in the RMTLE group were predominantly in the ipsilateral hemisphere (see Figure I, Supplemental Content, <http://links.lww.com/MD/C395>, which shows the maps of statistical difference of MD values). WM tracts with statistically significant increase of MD are listed (see Table I, Supplemental Content, <http://links.lww.com/MD/C395>, which illustrates the brain regions where MD in the LMTLE group was different from the control group; see Table II, Supplemental Content, <http://links.lww.com/MD/C395>, which illustrates the brain regions where MD in the RMTLE group was different from the control group). Compared with the control group, none of the WM tracts had reduced MD in the patient group.

**Table 2**  
**Comparison of MoCA scores between MTLE group and control group<sup>†</sup>.**

	MTLE group	Control group	t-value	P-value
Visuospatial and executive function	3.04 ± 1.16	4.92 ± 0.29	-5.477	<.001*
Naming	1.54 ± 0.72	2.75 ± 0.45	-5.287	<.001*
Memory	1.63 ± 0.65	3.92 ± 0.67	-9.911	<.001*
Attention	4.33 ± 1.46	5.25 ± 0.87	-1.992	.054
Language	1.33 ± 0.64	1.75 ± 0.62	-1.865	.071
Abstraction	0.96 ± 0.36	1.67 ± 0.49	-4.926	<.001*
Orientation	5.63 ± 0.58	5.83 ± 0.39	-1.127	.268
Total	19.29 ± 2.29	26.50 ± 0.68	-10.822	<.001*

MoCA=Montreal Cognitive Assessment, MTLE=mesial temporal lobe epilepsy.

\*Indicates  $P < .05$ .

† Data are presented as mean ± SD.

**Table 3**

**Comparison of WB, GM, WM, and CSF volumes and their ratios between MTLE group and control group<sup>†</sup>.**

Volume, cm <sup>3</sup>	MTLE group	Control group	t-value	P-value
WB	1683.86 ± 110.21	1724.56 ± 187.18	-0.879	.385
GM	686.61 ± 99.13	728.11 ± 97.59	-1.399	.169
WM	501.09 ± 25.78	553.13 ± 72.67	-3.166	.003*
CSF	496.16 ± 130.99	443.32 ± 139.14	2.517	.202
Ratio	MTLE group	Control group	t-value	P-value
GM/WB	0.41 ± 0.06	0.42 ± 0.05	-0.908	.369
WM/WB	0.30 ± 0.02	0.32 ± 0.03	-2.807	.008*
GM/WM	1.37 ± 0.19	1.35 ± 0.14	0.369	.714

CSF=cerebrospinal fluid, GM=gray matter, MTLE=mesial temporal lobe epilepsy, WB=whole brain, WM=white matter.

\* Indicates  $P < .05$ .

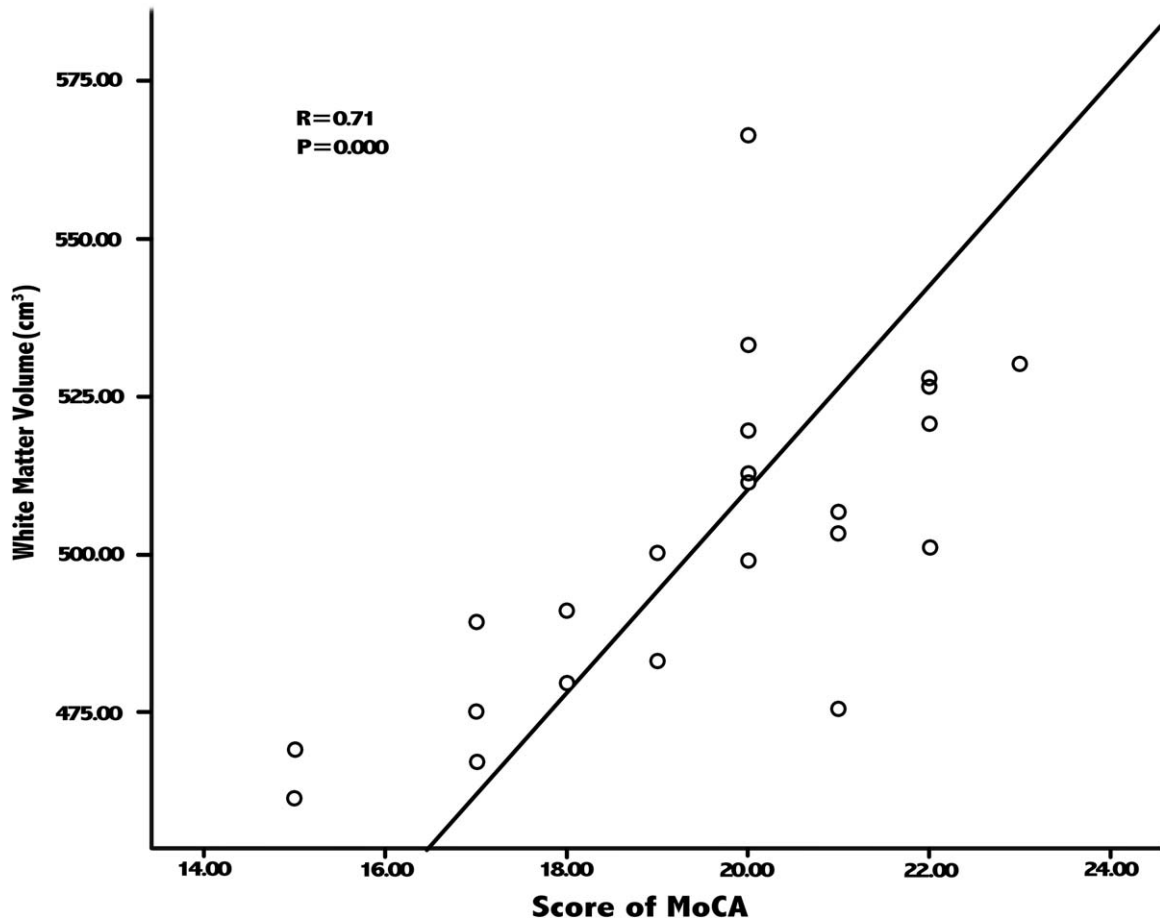
<sup>†</sup> Data are presented as mean ± SD.

**3.7. Differences in AD**

Compared to the control group, the areas with increased AD were smaller in the patient group. The areas with increased AD were mostly ipsilateral side for the LMTLE group, whereas all areas were ipsilateral for the RMTLE group (see Figure II, Supplemental Content, <http://links.lww.com/MD/C395>, which shows the maps of statistical difference of AD values). As shown in Supplemental Table III and IV (see Table III, Supplemental Content, <http://links.lww.com/MD/C395>, which illustrates the brain regions where AD in the LMTLE group was different from the control group; see Table IV, Supplemental Content, [\[links.lww.com/MD/C395\]\(http://links.lww.com/MD/C395\), which illustrates the brain regions where AD in the RMTLE group was different from the control group\), none of the WM tracts with AD reduction were found in the patient group.](http://</a></p>
</div>
<div data-bbox=)

**3.8. Differences in RD**

Compared with the control group, increased RD in the LMTLE group was bilateral while increased RD in the RMTLE group was mostly in the right side (see Figure III, Supplemental Content, <http://links.lww.com/MD/C395>, which shows the maps of statistical difference of RD values). WM regions with statistically significant



**Figure 1.** Scatter plot of white matter volume versus MoCA score. MoCA=Montreal Cognitive Assessment.

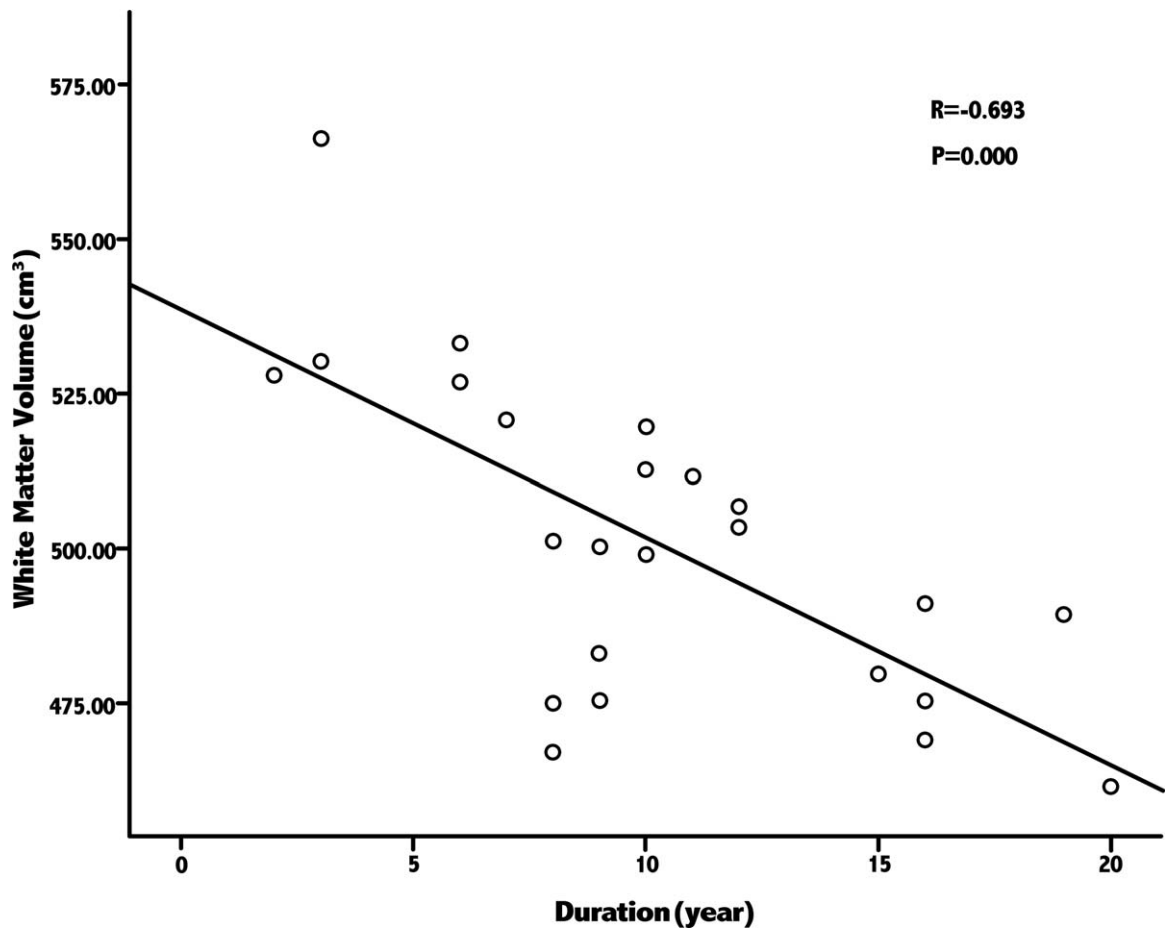


Figure 2. Scatter plot of WM volume versus the duration of epilepsy. WM=white matter.

RD difference are listed in Table 10 and Table 11 (see Table V, Supplemental Content, <http://links.lww.com/MD/C395>, which illustrates the brain regions where RD in the LMTLE group was different from the control group; see Table VI, Supplemental

Content, <http://links.lww.com/MD/C395>, which illustrates the brain regions where RD in the RMTLE group was different from the control group). Compared with the control group, no WM tract had reduced RD in the patient group.

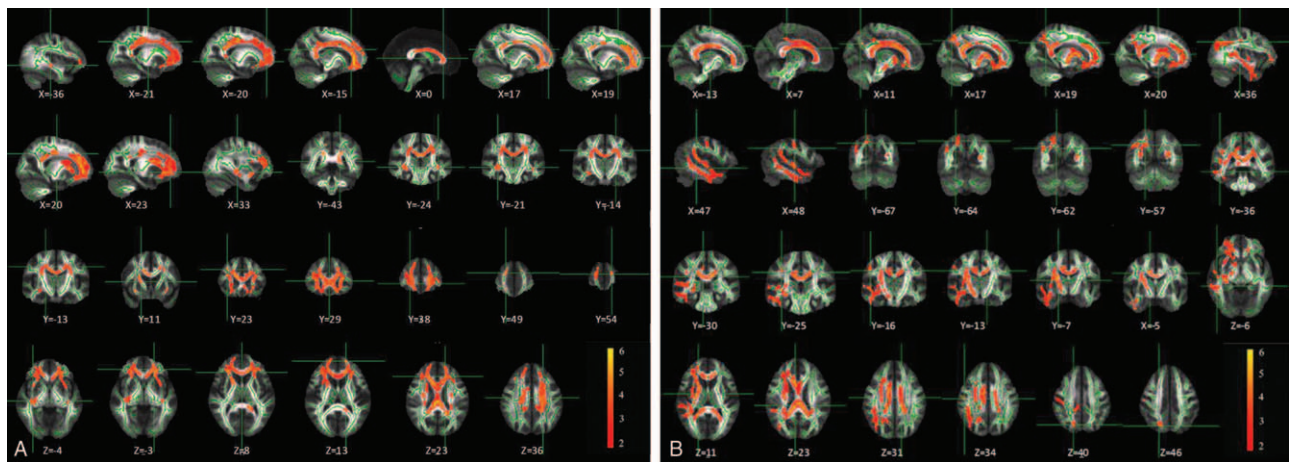


Figure 3. Maps of statistical difference of FA values. The 2 maps show significant lower FA values that are marked in red-yellow for the comparison between the LMTLE and the control groups (left), and between the RMTLE and the control groups (right). The white matter fiber skeleton is marked in green and the brighter areas in the color scale represent greater difference. FA=fractional anisotropy, LMTLE=left mesial temporal lobe epilepsy, RMTLE=right mesial temporal lobe epilepsy.

**Table 4**

The brain regions where FA in the LMTLE group was different from the control group.

MNI coordinates			Volume, mm <sup>3</sup>	Brain hemisphere	White matter tract	FA		P value
X	Y	Z				LMTLE group	Control group	
0	29	8	11,828	—	Forceps minor	0.76 ± 0.03	0.87 ± 0.11	.012
-15	54	13	3365	Left	Forceps minor	0.50 ± 0.05	0.57 ± 0.06	.041
71	180	82	1898	Left	Forceps minor	0.60 ± 0.04	0.69 ± 0.05	.023
-16	-43	9	285	Left	Forceps major	0.62 ± 0.04	0.77 ± 0.09	.032
-36	-24	-3	85	Left	Inferior longitudinal fasciculus	0.20 ± 0.06	0.28 ± 0.07	.041
33	-21	4	182	Left	Inferior longitudinal fasciculus	0.24 ± 0.07	0.30 ± 0.07	.033
-21	-14	36	680	Left	Corticospinal tract	0.28 ± 0.05	0.38 ± 0.06	.016
20	-13	36	240	Left	Corticospinal tract	0.34 ± 0.10	0.41 ± 0.12	.042
-20	38	-3	578	Left	Uncinate fasciulus	0.31 ± 0.02	0.41 ± 0.05	.039
23	38	-3	326	Left	Uncinate fasciulus	0.27 ± 0.03	0.39 ± 0.04	.027
-36	-24	-3	73	Left	Inferior ronto-occipital fasciculus	0.21 ± 0.03	0.28 ± 0.08	.040
33	-21	-4	89	Left	Inferior ronto-occipital fasciculus	0.26 ± 0.04	0.37 ± 0.02	.014
19	11	9	92	Left	Anterior thalamic radiation	0.47 ± 0.06	0.57 ± 0.03	.012
-15	29	23	1835	Left	Cingulum	0.32 ± 0.10	0.41 ± 0.04	.025

FA=fractional anisotropy, LMTLE=left mesial temporal lobe epilepsy, MNI=Montreal Neurological Institute.

#### 4. Discussion

##### 4.1. WM structural changes demonstrated by MRI

In this study, MTLE patients were divided into LMTLE and RMTLE subgroups. Their WM tract microstructures were analyzed and compared with the normal control group separately, avoiding the error caused by left-right mixing or the bias caused by left-right inversion. The results are thus more accurate and reliable. Our study found that WM tract changes were different in LMTLE and RMTLE groups. LMTLE patients had bilateral changes of decreased FA, increased MD and increased RD in WM tracts while RMTLE patients had mostly ipsilateral changes. However, the regions of increased AD were mainly in the left side for the LMTLE group, but were concentrated in the right side for the RMTLE group. Similar findings were made in other studies.<sup>[9,10,37]</sup> The study by Besson et al<sup>[38]</sup> of 39 temporal lobe epilepsy (TLE) patients (36 of them were right-handed) also showed that the left TLE had more extensive WM connectivity decrease. Such asymmetrical change in WM structure of left and right TLE patients may be related to the asymmetry of brain structure and function. Some of the functional areas in the left hemisphere are more developed in the right-handed persons, but, in the event of dysfunction, its impact may be greater as well.

##### 4.2. The relationship between WM structural change and cognitive function change in MTLE

We found that WM tract changes in MTLE patients were mainly located in the corpus callosum, uncinate fasciculus, superior longitudinal fasciculus, cingulum, anterior thalamic radiation, inferior frontal-occipital fasciculus and corticospinal tract. WM volume was positively correlated with MoCA, but negatively correlated with the duration of disease. Chronic and repeated seizures could lead to more severe damage in WM than in GM. The decrease of FA and increase of MD suggested that the extensive microstructure change in the WM may cause macroscopic atrophy and reduction of WM volume, leading to a decrease in the intratemporal lobe and inter hemisphere connectivity. This may be an important reason for the decline of cognitive functions in MTLE patient. Such decline was more remarkable for visuospatial and executive function as well as naming, memory and abstraction functions.

The corpus callosum is an important WM fiber connecting the left and right cerebral hemispheres. The splenium of corpus callosum transmits somatosensory information between the parietal lobes of the 2 hemispheres of the brain and transmits visual information between the occipital lobes.<sup>[39]</sup> The posterior cingulum is considered an important neural structure for memory and an important component of cholinergic system. Uncinate

**Table 5**

The brain regions where FA in the RMTLE group was different from the control group.

MNI coordinates			Volume mm <sup>3</sup>	Brain Hemisphere	white matter tract	FA value		P value
X	Y	Z				RMTLE group	Control group	
0	29	22	4868	—	Forceps minor	0.69 ± 0.10	0.81 ± 0.04	.018
0	-25	23	6224	—	Forceps major	0.60 ± 0.03	0.50 ± 0.08	.037
19	-57	33	288	Left	Forceps major	0.51 ± 0.05	0.59 ± 0.03	.020
11	-5	31	4982	Left	Corpus callosum body	0.58 ± 0.04	0.77 ± 0.11	.014
-13	-13	31	3362	Left	Corpus callosum body	0.67 ± 0.03	0.75 ± 0.10	.046
48	-7	11	638	Left	Uncinate fasciulus	0.21 ± 0.07	0.32 ± 0.07	.023
36	-25	34	195	Left	Superior longitudinal fasciculus	0.28 ± 0.05	0.39 ± 0.06	.037
47	-36	6	160	Left	Inferior longitudinal fasciculus	0.24 ± 0.04	0.39 ± 0.05	.031
17	-67	40	90	Left	Cingulum	0.30 ± 0.11	0.42 ± 0.04	.016
20	-64	46	106	Left	Anterior thalamic radiation	0.43 ± 0.07	0.58 ± 0.09	.018

FA=fractional anisotropy, RMTLE=right mesial temporal lobe epilepsy.

fasciculus plays an important role in the formation and reproduction of situational memory. It is an important pathway for TLE to spread from the temporal lobe to the frontal lobe.<sup>[40]</sup> Our results shows that, other than the bilateral increase of uncinate fasciculus FA in LMTLE group, there were ipsilateral changes of uncinate fasciculus FA in RMTLE patients and the uncinate fasciculus MD, AD and RD in both RMTLE and LMTLE groups. Therefore, abnormal DTI parameters in ipsilateral uncinate fasciculus may be a characteristic change of MTLE, which may be of value in localization of MTLE. Other studies have shown that a decrease of FA in left uncinate fasciculus in patients with left TLE implies a disruption of WM integrity of left uncinate fasciculus, which is closely related to patient's decline of executive function.<sup>[41]</sup>

There are multiple reasons for the decline of cognitive function in patients with epilepsy.<sup>[42]</sup> In addition to structural damage, other factors include time of onset, duration, seizure frequency, severity and duration, and even the use of antiepileptic drugs. Some believe that seizure duration has more impact on the cognitive function than its frequency.<sup>[43]</sup> Hermann et al<sup>[44]</sup> found that the younger age of onset, the less WM volume is present in the TLE patient which may result in more obvious cognitive dysfunction. In this study, GM and WM volumes of MTLE group appeared to be reduced when compared with the normal group. However, statistical analysis shows that only the differences in WM volume and WM/whole brain ratio are statistically significant. This is likely due to the reduction in WM volume was more dramatic, but the reduction in GM volume was relatively less and not statistically significant. Also, we consider whole brain as WM+GM+CSF,<sup>[45]</sup> instead of whole brain as WM+GM. Therefore, even though WM volume and GM volume were reduced, CSF volume might have increased, causing the difference in whole brain volume to be statistically insignificant. Compared with the normal population of the same age and education level, there are varying degrees of cognitive dysfunction and behavioral abnormalities in epilepsy patients.<sup>[46]</sup> By studying the relationship between WM damage and cognitive function, Riley *et al* found that the WM areas with the most negative impact are ipsilateral anterior and mesial temporal lobe, cerebellar hemisphere and contralateral parietal WM.<sup>[47]</sup>

Our TBSS results showed that FA, MD, AD, and RD of association fibers, commissural fibers, and projection fibers had different degrees of abnormal change in MTLE patients. These changes will inevitably lead to brain connectivity disorders, thereby affecting the execution of instructions which requires neural network or system coordination and finally manifested as cognitive decline. Therefore, changes in the brain structure of patients with MTLE leading to functional connectivity disorders may be an important physiological basis for cognitive changes in patients with MTLE.

#### 4.3. Limitations

There are a few limitations of this study. First, since the inclusion and exclusion criteria were rigorous and the patient group had to be verified by postsurgical histology, the sample size was relatively small, which may result in some of bias in the results. Secondly, the difference in the individual dosing of antiepileptic medication for the MTLE group was not taken into account which may have uncertain effect on the results. Finally, although a wide range of WM microstructure abnormalities and DTI parameter abnormalities were found in the ipsilateral uncinate

fasciculus which may be useful for the diagnosis of MTLE, confirmation by studies with larger sample size is needed.

## 5. Conclusions

In summary, there was a significant reduction of WM volumes compared with GM volumes in the MTLE patients, and the cognitive dysfunction in MTLE patients was found to be closely related to the WM structure changes. More ipsilateral DTI changes are found with right-sided MTLE.

## Author contributions

**Data curation:** Jihui Xi.

**Formal analysis:** Xiaoyang Wang.

**Project administration:** Ziqian Chen.

**Software:** Liyuan Fu.

**Writing – original draft:** Shang-wen Xu.

**Writing – review & editing:** Chen Lin, Stephen F. Kralik.

Shang-wen Xu: 0000-0002-8273-5865

## References

- [1] Liu M, Bernhardt BC, Hong S-J, et al. The superficial white matter in temporal lobe epilepsy: a key link between structural and functional network disruptions. *Brain* 2016;139:2431–40.
- [2] Liao W, Zhang Z, Pan Z, et al. Default mode network abnormalities in mesial temporal lobe epilepsy: a study combining fMRI and DTI. *Hum Brain Mapp* 2011;32:883–95.
- [3] Yu A, Li K, Li L, et al. Whole-brain voxel-based morphometry of white matter in medial temporal lobe epilepsy. *Eur J Radiol* 2008;65:86–90.
- [4] Khan AR, Goubran M, de Ribaupierre S, et al. Quantitative relaxometry and diffusion MRI for lateralization in MTS and non-MTS temporal lobe epilepsy. *Epilepsy Res* 2014;108:506–16.
- [5] Correa DG, Ventura N, Zimmermann N, et al. Evaluation of deep gray matter volume, cortical thickness and white matter integrity in patients with typical absence epilepsy: a study using voxelwise-based techniques. *Neuroradiology* 2017;59:237–45.
- [6] Li J, Chen X, Ye W, et al. Alteration of the alertness-related network in patients with right temporal lobe epilepsy: A resting state fMRI study. *Epilepsy Res* 2016;127:252–9.
- [7] Toller G, Adhimoalam B, Rankin KP, et al. Right fronto-limbic atrophy is associated with reduced empathy in refractory unilateral mesial temporal lobe epilepsy. *Neuropsychologia* 2015;78:80–7.
- [8] Liu F, Wang Y, Li M, et al. Dynamic functional network connectivity in idiopathic generalized epilepsy with generalized tonic-clonic seizure. *Hum Brain Mapp* 2017;38:957–73.
- [9] Otte WM, van Eijsden P, Sander JW, et al. A meta-analysis of white matter changes in temporal lobe epilepsy as studied with diffusion tensor imaging. *Epilepsia* 2012;53:659–67.
- [10] Govindan RM, Makki MI, Sundaram SK, et al. Diffusion tensor analysis of temporal and extra-temporal lobe tracts in temporal lobe epilepsy. *Epilepsy Res* 2008;80:30–41.
- [11] Coan AC, Campos BM, Beltramini GC, et al. Distinct functional and structural MRI abnormalities in mesial temporal lobe epilepsy with and without hippocampal sclerosis. *Epilepsia* 2014;55:1187–96.
- [12] Ashburner J, Friston KJ. Voxel-based morphometry—the methods. *Neuroimage* 2000;11:805–21.
- [13] Son JH, Han DH, Min KJ, et al. Correlation between gray matter volume in the temporal lobe and depressive symptoms in patients with Alzheimer's disease. *Neurosci Lett* 2013;548:15–20.
- [14] Valfre W, Rainero I, Bergui M, et al. Voxel-based morphometry reveals gray matter abnormalities in migraine. *Headache* 2008;48:109–17.
- [15] Lu C, Peng D, Chen C, et al. Altered effective connectivity and anomalous anatomy in the basal ganglia-thalamocortical circuit of stuttering speakers. *Cortex* 2010;46:49–67.
- [16] Ecker C, Rocha-Rego V, Johnston P, et al. Investigating the predictive value of whole-brain structural MR scans in autism: a pattern classification approach. *Neuroimage* 2010;49:44–56.
- [17] Liu F, Guo W, Yu D, et al. Classification of different therapeutic responses of major depressive disorder with multivariate pattern analysis method based on structural MR scans. *PLoS One* 2012;7:e40968.

- [18] Edden RA, Jones DK. Spatial and orientational heterogeneity in the statistical sensitivity of skeleton-based analyses of diffusion tensor MR imaging data. *J Neurosci Methods* 2011;201:213–9.
- [19] Chen Z, Ni P, Zhang J, et al. Evaluating ischemic stroke with diffusion tensor imaging. *Neurol Res* 2008;30:720–6.
- [20] Li H, Xue Z, Dulay MF, et al. Fractional anisotropy asymmetry and the side of seizure origin for partial onset-temporal lobe epilepsy. *Comput Med Imaging Graph* 2014;38:481–9.
- [21] Canu E, Agosta F, Spinelli EG, et al. White matter microstructural damage in Alzheimer's disease at different ages of onset. *Neurobiol Aging* 2013;34:2331–40.
- [22] Shu N, Wang Z, Qi Z, et al. Multiple diffusion indices reveals white matter degeneration in Alzheimer's disease and mild cognitive impairment: a tract-based spatial statistics study. *J Alzheimer's Dis* 2011;26:275–85.
- [23] Lieberman G, Shpaner M, Watts R, et al. White matter involvement in chronic musculoskeletal pain. *J Pain* 2014;15:1110–9.
- [24] Nickl-Jockschat T, Stocker T, Markov V, et al. The impact of a Dysbindin schizophrenia susceptibility variant on fiber tract integrity in healthy individuals: a TBSS-based diffusion tensor imaging study. *Neuroimage* 2012;60:847–53.
- [25] Liu X, Lai Y, Wang X, et al. Reduced white matter integrity and cognitive deficit in never-medicated chronic schizophrenia: a diffusion tensor study using TBSS. *Behav Brain Res* 2013;252:157–63.
- [26] Guo W, Liu F, Liu Z, et al. Right lateralized white matter abnormalities in first-episode, drug-naive paranoid schizophrenia. *Neurosci Lett* 2012;531:5–9.
- [27] Smith SM, Jenkinson M, Johansen-Berg H, et al. Tract-based spatial statistics: voxelwise analysis of multi-subject diffusion data. *Neuroimage* 2006;31:1487–505.
- [28] Afzali M, Soltanian-Zadeh H, Elisevich KV. Tract based spatial statistical analysis and voxel based morphometry of diffusion indices in temporal lobe epilepsy. *Comput Biol Med* 2011;41:1082–91.
- [29] Liacu D, Idy-Peretti I, Ducreux D, et al. Diffusion tensor imaging tractography parameters of limbic system bundles in temporal lobe epilepsy patients. *J Magn Reson Imaging* 2012;36:561–8.
- [30] Arfanakis K, Hermann BP, Rogers BP, et al. Diffusion tensor MRI in temporal lobe epilepsy. *Magn Reson Imaging* 2002;20:511–9.
- [31] Gross DW, Concha L, Beaulieu C. Extratemporal white matter abnormalities in mesial temporal lobe epilepsy demonstrated with diffusion tensor imaging. *Epilepsia* 2006;47:1360–3.
- [32] Engel J. Surgery for seizures. *N Engl J Med* 1996;334:647–53.
- [33] van Bloemendaal L, Ijzerman RG, Ten Kulve JS, et al. Alterations in white matter volume and integrity in obesity and type 2 diabetes. *Metab Brain Dis* 2016;31:621–9.
- [34] Purkayastha S, Fadar O, Mehregan A, et al. Impaired cerebrovascular hemodynamics are associated with cerebral white matter damage. *J Cereb Blood Flow Metab* 2014;34:228–34.
- [35] Nasreddine ZS, Phillips NA, Bédirian Vr, et al. The Montreal Cognitive Assessment, MoCA: a brief screening tool for mild cognitive impairment. *J Am Geriatr Soc* 2005;53:695–9.
- [36] Stejskal EO, Tanner JE. Self-diffusion measurement: spin-echo in presence of time dependent field gradient. *J Chem Phys* 1965;42:288–92.
- [37] Ahmadi ME, Hagler DJ Jr, McDonald CR, et al. Side matters: diffusion tensor imaging tractography in left and right temporal lobe epilepsy. *AJNR Am J Neuroradiol* 2009;30:1740–7.
- [38] Besson P, Dinkelacker V, Valabregue R, et al. Structural connectivity differences in left and right temporal lobe epilepsy. *NeuroImage* 2014;100:135–44.
- [39] Hofer S, Frahm J. Topography of the human corpus callosum revisited—comprehensive fiber tractography using diffusion tensor magnetic resonance imaging. *NeuroImage* 2006;32:989–94.
- [40] Diehl B, Busch RM, Duncan JS, et al. Abnormalities in diffusion tensor imaging of the uncinate fasciculus relate to reduced memory in temporal lobe epilepsy. *Epilepsia* 2008;49:1409–18.
- [41] Diao L, Yu H, Zheng J, et al. Abnormalities of the uncinate fasciculus correlate with executive dysfunction in patients with left temporal lobe epilepsy. *Magn Reson Imaging* 2015;33:544–50.
- [42] Li Z, Chen Z. Research progress in the fMRI imaging of cognitive impairment of temporal lobe epilepsy. *Med Recapitulate* 2013;19:1622–4.
- [43] Smith ML, Elliott IM, Lach L. Cognitive skills in children with intractable epilepsy: comparison of surgical and nonsurgical candidates. *Epilepsia* 2002;43:631–7.
- [44] Hermann B, Seidenberg M, Bell B, et al. The neurodevelopmental impact of childhood-onset temporal lobe epilepsy on brain structure and function. *Epilepsia* 2002;43:1062–71.
- [45] Stricker NH, Schweinsburg BC, Delano-Wood L, et al. Decreased white matter integrity in late-myelinating fiber pathways in Alzheimer's disease supports retrogenesis. *Neuroimage* 2009;45:10–6.
- [46] Meador KJ. Cognitive outcomes and predictive factors in epilepsy. *Neurology* 2002;58:s21–6.
- [47] Riley JD, Franklin DL, Choi V, et al. Altered white matter integrity in temporal lobe epilepsy: association with cognitive and clinical profiles. *Epilepsia* 2010;51:536–45.