

# A case report of hepatopulmonary syndrome in hereditary hemorrhagic telangiectasia (HHT)

## Not all right-to-left shunting in HHT is due to pulmonary arteriovenous malformations

Sheila Krishnan, DO<sup>a</sup>, Tim Lahm, MD<sup>a,b,\*</sup>

### Abstract

**Rationale:** Hereditary hemorrhagic telangiectasia (HHT) is an autosomal dominant disorder characterized by abnormal vessel growth that results in telangiectasias and arteriovenous malformations (AVMs) in the skin, mucosa, and viscera. Up to 30% of patients with HHT exhibit pulmonary AVMs (PAVMs), clinically manifesting as right-to-left shunting and hypoxemia.

**Patient Concerns:** We report an unusual and novel case of a patient with HHT who lacked clinical sequelae of portal hypertension but presented to clinic with hypoxemia without dyspnea.

**Diagnoses:** Diagnostic workup revealed noncardiac right-to-left shunting due to hepatopulmonary syndrome (HPS) from HHT-induced portal hypertension rather than PAVMs. The diagnosis was confirmed by the absence of PAVMs on chest computed tomography and evidence of elevated portal pressures as noted by the presence of small esophageal varices on upper endoscopy and histologic findings on liver biopsy.

**Intervention:** Due to the patient's mild symptoms, no further intervention was required. He was closely followed up in the outpatient setting for changes in symptoms and underwent annual screening for development of PAVMs.

**Outcomes:** The patient continues to do well clinically. He has not experienced worsening hypoxemia or dyspnea and has not developed PAVMs.

**Lessons:** Given that management of hypoxemia in HPS drastically differs from that of hypoxemia due to PAVMs, this case demonstrates the importance of evaluating HHT patients for HPS if they exhibit impaired oxygenation and noncardiac right-to-left shunting in the setting of hepatic arteriovenous shunting.

**Abbreviations:** A-a gradient = alveolar-arterial gradient, AVM = arteriovenous malformation, BNP = B-type natriuretic peptide, CT = computed tomogram, HHT = hereditary hemorrhagic telangiectasia, HPS = hepatopulmonary syndrome, PAVM = pulmonary arteriovenous malformation, RV = right ventricular.

**Keywords:** alveolar-arterial gradient, hepatopulmonary syndrome, hereditary hemorrhagic telangiectasia, pulmonary arteriovenous malformation, pulmonary circulation

## 1. Introduction

Hepatopulmonary syndrome (HPS), a syndrome characterized by hypoxemia resulting from diffusion impairment due to intrapulmonary dilations, is a well-recognized complication of portal hypertension and most commonly occurs in the context of liver cirrhosis.<sup>[1]</sup> Less commonly, HPS may also occur in the

setting of noncirrhotic portal hypertension. We describe for the first time a case of HPS arising as a consequence of hereditary hemorrhagic telangiectasia (HHT), a multisystem disorder characterized by telangiectasias, arteriovenous malformations (AVMs), and recurrent nosebleeds. The patient developed AVMs in the liver, leading to noncirrhotic portal hypertension and HPS.

Editor: N/A.

Conflict of interest: TL has served as a consultant for Gilead and Actelion and serves on the speaker bureau for Bayer.

<sup>a</sup>Division of Pulmonary, Critical Care, Sleep and Occupational Medicine, Indiana University School of Medicine, <sup>b</sup>Richard L. Roudebush VA Medical Center; Indianapolis, IN.

\* Correspondence: Tim Lahm, Walther Hall, C400, 980 W. Walnut St, Indianapolis, IN 46202 (e-mail: [tlahm@iu.edu](mailto:tlahm@iu.edu)).

Copyright © 2018 the Author(s). Published by Wolters Kluwer Health, Inc. This is an open access article distributed under the terms of the Creative Commons Attribution-Non Commercial-No Derivatives License 4.0 (CCBY-NC-ND), where it is permissible to download and share the work provided it is properly cited. The work cannot be changed in any way or used commercially without permission from the journal.

Medicine (2018) 97:32(e11513)

Received: 2 April 2018 / Accepted: 20 June 2018

<http://dx.doi.org/10.1097/MD.00000000000011513>

## 2. Informed consent

Given that this is a case report, an ethics committee approval was not required. We did not use patient identifiers and maintained the anonymity of our patient. The patient verbally consented to have this case reported.

## 3. Case description

A 60-year-old male with a history of newly diagnosed HHT presented for evaluation of right-to-left shunting seen on screening bubble contrast echocardiogram. The diagnosis of HHT was discovered incidentally a few months prior (Fig. 1). At that time, he underwent hemicolecotomy and chemotherapy for colon cancer and developed persistent abdominal pain and fevers post-chemotherapy. An extensive workup was performed,

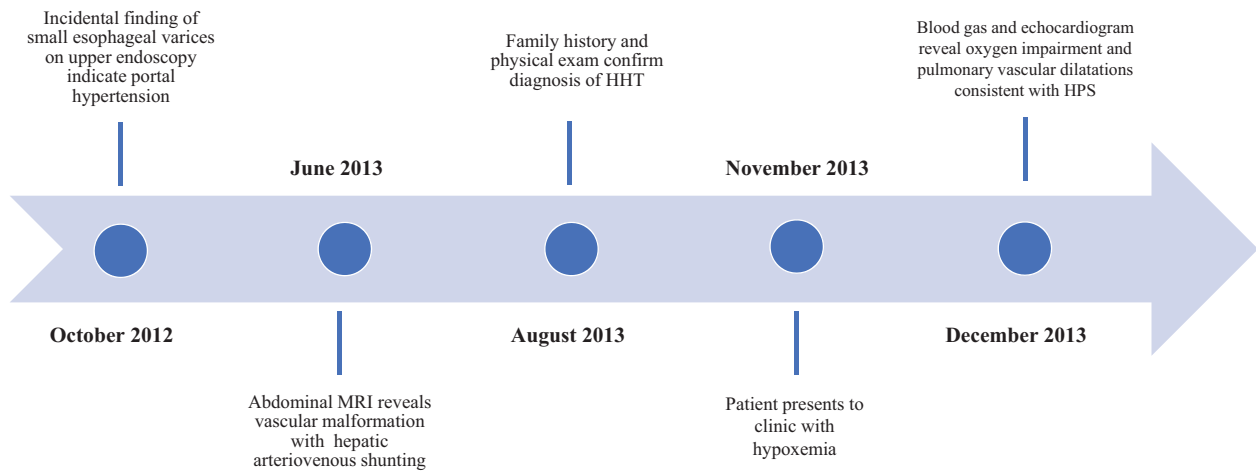


Figure 1. Timeline of patient presentation and diagnosis.

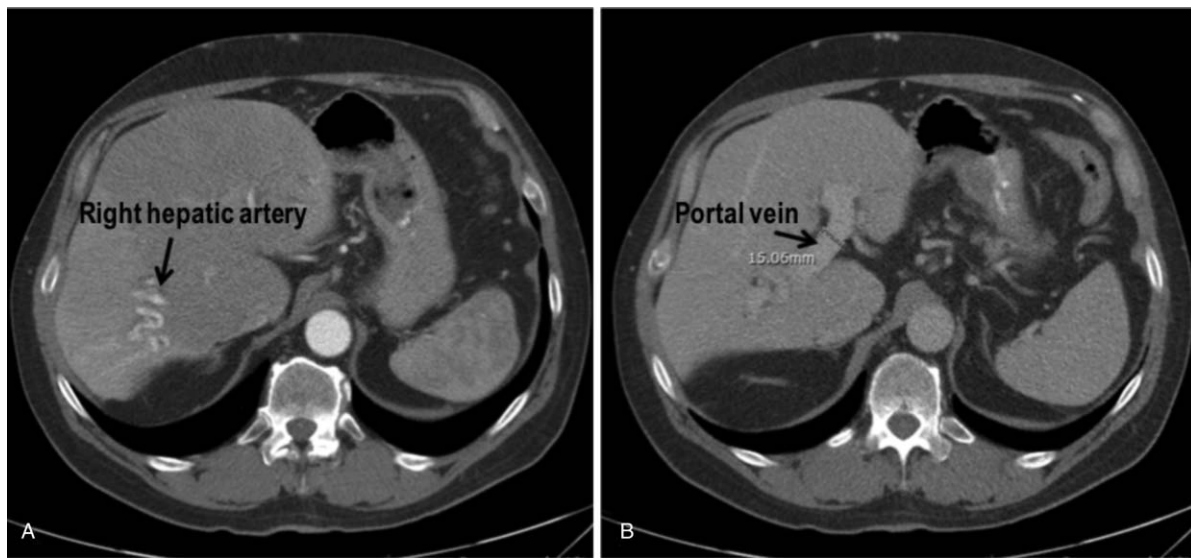


Figure 2. Magnetic resonance imaging of the abdomen demonstrating hepatic artery to portal vein shunting. (A) Irregular liver density and enlarged branches of right hepatic artery. (B) Enlarged portal vein and atrophy of right lobe of liver.

including an upper endoscopy, which demonstrated small esophageal varices. To further evaluate the etiology of the varices, magnetic resonance imaging of the abdomen was performed; this revealed mild splenomegaly, multiple hepatic AVMs with significant abnormal hepatic artery to portal venous shunting (Fig. 2A), and atrophy of the right lobe of the liver (Fig. 2B). A liver biopsy was subsequently performed and revealed focal sinusoidal dilation with nodular regenerative changes and ectopic portal vein branches without any evidence of fibrosis, consistent with noncirrhotic portal hypertension from hepatic AVMs. A more extensive review of his medical history revealed that he and several first-degree family members had a history of recurrent epistaxis. In addition, he also had physical examination findings of facial telangiectasias. Based on these criteria, a definite diagnosis of HHT was made according to Curaçao criteria (Table 1).<sup>[2]</sup> Genetic sequencing testing for *ENG*, *ACVRL1*, and *SMAD4* was negative and deletion/duplication testing for *ENG* and *ACVRL1* was negative as well.

At the time of evaluation, the patient had no symptoms of dyspnea, exercise intolerance, or hemoptysis. He also denied any neurologic symptoms. His vital signs were as follows: temperature of 98.2F, blood pressure of 163/97 mm Hg, heart rate of 70/min, and oxygen saturation of 93% on room air. Physical

Table 1

Curaçao diagnostic criteria for HHT.

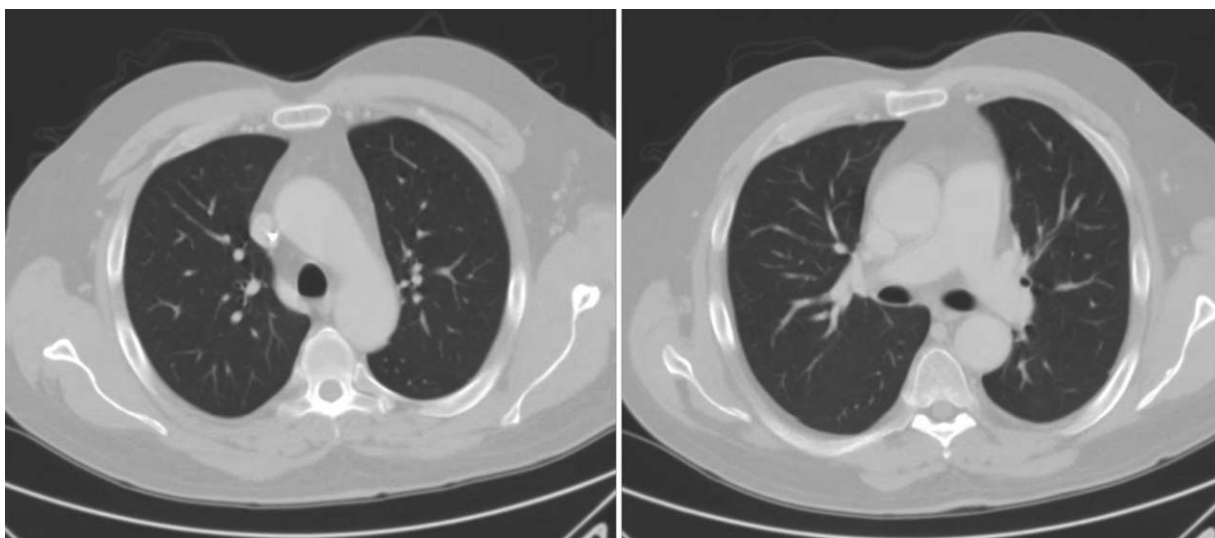
1. Epistaxis*	Recurrent spontaneous nosebleeds
2. Telangiectasias*	Multiple, at characteristic sites: lips, oral cavity, nose, fingers
3. Vascular malformations*	GI, pulmonary, hepatic, cerebral, spinal
4. Family history†	First degree relative with HHT

Definite diagnosis: 3 criteria present. Possible diagnosis: 2 criteria present. Unlikely diagnosis: less than 2 criteria present.

HHT = hereditary hemorrhagic telangiectasia.

\*Criteria that our patient met.

†Unclear if our patient met this criteria.



**Figure 3.** Noncontrasted computed tomography scan of the chest showing absence of pulmonary arteriovenous malformations and normal lung parenchyma.

examination revealed a healthy appearing male in no distress. Head and neck exam were significant for telangiectasias on his nose, while no telangiectasias were present on his lips or in the oral cavity. Examination of the heart, lungs, and neurologic system were normal. An echocardiogram with bubble study was performed to evaluate for pulmonary AVMs. This revealed a small noncardiac right-to-left shunt. Other echocardiographic findings included a normal left ventricular systolic and diastolic function and normal right atrial and right ventricular (RV) size. RV systolic function and estimated RV systolic pressure were normal. The presence of pulmonary AVMs was ruled out through multiple contrasted chest computed tomograms (CTs). In addition, chest CTs did not provide any evidence of parenchymal or airway disease (Fig. 3). Pulmonary function testing revealed normal spirometry and lung volumes. Lung perfusion scanning and B-type natriuretic peptide (BNP) level were normal. Due to known portal hypertension from hepatic AVMs and oximetry of 93% on room air, an arterial blood gas was ordered. This revealed an elevated alveolar-arterial (A-a) gradient of 18 mm Hg which was later repeated and revealed a gradient of 38 mm Hg (expected A-a gradient for his age was 15 mm Hg). Given the triad of portal hypertension, right-to-left shunt, and increased A-a gradient (Table 2), a diagnosis of hepatopulmonary syndrome (HPS) was made.<sup>[3]</sup>

**4. Discussion**

HHT is an autosomal dominant disorder characterized by abnormal vessel growth that results in telangiectasias and AVMs

in the skin, mucosa, and viscera. Patients with HHT can have AVMs in the pulmonary, cerebral, gastrointestinal, and hepatic vasculature. The risk for pulmonary AVMs is as high as 30%.<sup>[4,5]</sup> While all patients with HHT should be screened for pulmonary AVMs, in this report we highlight the importance of considering other, less common pulmonary complications in HHT patients. Our patient most likely developed portal hypertension because of hepatic AVMs, which put him at risk for HPS as well as portopulmonary hypertension. The latter, however, was ruled out by echocardiography and BNP level measurement, both of which were normal. In addition, pulmonary hypertension would be unlikely to cause noncardiac right to left shunting. The patient was noted to have an increased A-a gradient on 2 separate occasions. This finding, combined with exclusion of parenchymal pulmonary and airway pathologies by chest CT and pulmonary function testing, makes the diagnosis of HPS in this patient robust and reproducible. To the best of our knowledge, this is the first report of HPS in a patient with HHT.

The urgency in identifying pulmonary AVMs derives from the potential for detrimental events due to direct communication of venous blood into the systemic circulation; these include cerebrovascular accidents from paradoxical emboli, septic emboli, and brain abscesses. Regardless of symptoms, embolization of the feeding vessel should be attempted.<sup>[6-8]</sup> While the presence of pulmonary AVMs requires an aggressive management approach, other pulmonary pathology should be pursued when appropriate. Hepatic AVMs, if draining into the portal vein, can cause significant noncirrhotic portal hypertension, as was the case in our patient.<sup>[9,10]</sup> This puts patients at risk for

<b>Table 2</b>	
<b>Clinical criteria for hepatopulmonary syndrome.</b>	
<b>Clinical criteria</b>	<b>Features present in this patient</b>
Portal hypertension	Noncirrhotic portal hypertension evidenced by esophageal varices, splenomegaly, and liver biopsy findings
Oxygenation defect: partial pressure of oxygen < 80mm Hg or A-a gradient ≥ 15mm Hg while breathing ambient air	Oxygen saturation 93% on room air; initial A-a gradient of 18 mm Hg and repeat gradient of 35 mm Hg
Pulmonary vascular dilatation	Noncardiac right to left shunting seen on contrasted echocardiography

A-a gradient = alveolar-arterial gradient.

diseases associated with this condition, such as HPS, which manifests as hypoxemia and/or increased A-a gradient (as noted in our patient, explaining the right-to-left shunting noted on echocardiogram). Though the pathogenesis of HPS is poorly understood, commonly accepted mechanisms include intrapulmonary dilated vascular abnormalities, diffusion-perfusion imbalance, and hyperdynamic circulation of the pulmonary bed.<sup>[1,11]</sup> Experimental studies implicate an increase in vasoactive substances as a result of portal hypertension as a potential cause of HPS.<sup>[12,13]</sup> A recent study indicated that polymorphisms in genes involved in the regulation of angiogenesis may be associated with HPS development.<sup>[14]</sup> Of note, one of the candidate genes was *ENG*, mutations of which are associated with HHT development.<sup>[15]</sup> However, our patient did not exhibit any mutations in *ENG*. The observation that genetic abnormalities in genes involved in the regulation of angiogenesis represent potential risk factors for HPS development, and the fact that HHT is due to abnormal blood vessel development suggest that there may be a common link between HPS and HHT. This needs further evaluation in future studies.

Due to our patient's lack of subjective symptoms, mild hypoxemia, and the absence of pulmonary AVMs on CT imaging, no specific interventions were made. He is currently being observed, with annual screenings for new symptoms, worsening hypoxemia, and pulmonary AVMs.

## 5. Conclusion

This novel case emphasizes that while suspicion for pulmonary AVMs should be high in HHT patients with right to left shunting and hypoxemia or increased A-a gradient, HPS from portal hypertension should be considered in the differential diagnosis if the patient exhibits signs of impaired oxygenation and has clinical findings or data consistent with portal hypertension.

## Author contributions

**Conceptualization:** Sheila Krishnan and Tim Lahm.

**Writing – original draft:** Sheila Krishnan.

**Writing – review & editing:** Tim Lahm.

## References

- [1] Kaymakoglu S, Kahraman T, Kudat H, et al. Hepatopulmonary syndrome in noncirrhotic portal hypertensive patients. *Dig Dis Sci* 2003;48:556–60.
- [2] Shovlin CL, Guttmacher AE, Buscarini E, et al. Diagnostic criteria for hereditary hemorrhagic telangiectasia (Rendu–Osler–Weber syndrome). *Am J Med Genet* 2000;91:66–7.
- [3] Rodriguez-Roisin R, Krowka MJ. Hepatopulmonary syndrome—a liver-induced lung vascular disorder. *N Engl J Med* 2008;358:2378–87.
- [4] Cottin V, Dupuis-Girod S, Lesca G, et al. Pulmonary vascular manifestations of hereditary hemorrhagic telangiectasia (Rendu–Osler disease). *Respiration* 2007;74:361–78.
- [5] Cottin V, Plauchu H, Bayle JY, et al. Pulmonary arteriovenous malformations in patients with hereditary hemorrhagic telangiectasia. *Am J Respir Crit Care Med* 2004;169:994–1000.
- [6] Todo K, Moriwaki H, Higashi M, et al. A small pulmonary arteriovenous malformation as a cause of recurrent brain embolism. *AJNR Am J Neuroradiol* 2004;25:428–30.
- [7] Trerotola SO, Pyeritz RE. PAVM embolization: an update. *AJR Am J Roentgenol* 2010;195:837–45.
- [8] Trerotola SO, Pyeritz RE, Bernhardt BA. Outpatient single-session pulmonary arteriovenous malformation embolization. *J Vasc Interv Radiol* 2009;20:1287–91.
- [9] Garcia-Tsao G. Liver involvement in hereditary hemorrhagic telangiectasia (HHT). *J Hepatol* 2007;46:499–507.
- [10] Khalid SK, Garcia-Tsao G. Hepatic vascular malformations in hereditary hemorrhagic telangiectasia. *Semin Liver Dis* 2008;28:247–58.
- [11] Lange PA, Stoller JK. The hepatopulmonary syndrome. *Ann Intern Med* 1995;122:521–9.
- [12] Fallon MB, Abrams GA, McGrath JW, et al. Common bile duct ligation in the rat: a model of intrapulmonary vasodilatation and hepatopulmonary syndrome. *Am J Physiol* 1997;272(4 pt 1):G779–84.
- [13] Zhang M, Luo B, Chen SJ, et al. Endothelin-1 stimulation of endothelial nitric oxide synthase in the pathogenesis of hepatopulmonary syndrome. *Am J Physiol* 1999;277(5 pt 1):G944–52.
- [14] Roberts KE, Kawut SM, Krowka MJ, et al. Genetic risk factors for hepatopulmonary syndrome in patients with advanced liver disease. *Gastroenterology* 2010;139:130–9. e24.
- [15] McAllister KA, Grogg KM, Johnson DW, et al. Endoglin, a TGF-beta binding protein of endothelial cells, is the gene for hereditary haemorrhagic telangiectasia type 1. *Nat Genet* 1994;8:345–51.