



NIH PUBLIC ACCESS

Author Manuscript

Gastrointest Endosc. Author manuscript; available in PMC 2016 February 01.

Published in final edited form as:

Gastrointest Endosc. 2015 February ; 81(2): 380–388. doi:10.1016/j.gie.2014.08.005.

Performance characteristics of EUS for locoregional evaluation of ampullary lesions

Wiriyaporn Ridditid, MD^{1,2}, Suzette E. Schmidt, BSN¹, Mohammad A. Al-Haddad, MD¹, Julia LeBlanc, MD¹, John M. DeWitt, MD¹, Lee McHenry, MD¹, Evan L. Fogel, MD¹, James L. Watkins, MD¹, Glen A. Lehman, MD¹, Stuart Sherman, MD¹, and Gregory A. Coté, MD, MS³

¹ Indiana University School of Medicine, Indianapolis, Indiana, USA ² Chulalongkorn University, King Chulalongkorn Memorial Hospital, Thai Red Cross Society, Bangkok, Thailand ³ Medical University of South Carolina, Charleston, South Carolina, USA.

Abstract

Background—The accuracy of EUS in the locoregional assessment of ampullary lesions is unclear.

Objectives—To compare EUS with ERCP and surgical pathology for the evaluation of intraductal extension and local staging of ampullary lesions.

Design—Retrospective cohort study.

Setting—Tertiary-care referral center.

Patients—All patients who underwent EUS primarily for the evaluation of an ampullary lesion between 1998 and 2012.

Intervention—EUS.

Main Outcome Measurements—Comparison of EUS sensitivity/specificity for intraductal and local extension with ERCP and surgical pathology by using the area under the receiver-operating characteristic (AUROC) curves and outcomes of the subgroup referred for endoscopic papillectomy.

Results—We identified 119 patients who underwent EUS for an ampullary lesion, of whom 99 (83%) had an adenoma or adenocarcinoma. Compared with ERCP (n = 90), the sensitivity/specificity of EUS for any intraductal extension was 56%/97% (AUROC = 0.77; 95% confidence interval [CI], 0.64-0.89). However, when using surgical pathology as the reference (n = 102), the sensitivity/specificity of EUS (80%/93%; AUROC = 0.87; 95% CI, 0.76-0.97) and ERCP (83%/93%; AUROC = 0.88; 95% CI, 0.77-0.99) were comparable. The overall accuracy of EUS for

Copyright © 2015 by the American Society for Gastrointestinal Endoscopy

Reprint requests: Gregory A. Coté, MD, MS, Medical University of South Carolina, 25 Courtenay Drive, ART 7100A, MSC 290, Charleston, SC 29425.

DISCLOSURE: All authors disclosed no financial relationships relevant to this article.

Presented at the annual meeting of Digestive Disease Week, May 3-6, 2014, Chicago, Illinois, USA (*Gastrointest Endosc* 2014;79:AB448).

local staging was 90%. Of 58 patients referred for endoscopic papillectomy, complete resection was achieved in 53 (91%); in those having intraductal extension by EUS or ERCP, complete resection was achieved in 4 of 5 (80%) and 4 of 7 (57%), respectively.

Limitation—Retrospective design.

Conclusions—EUS and ERCP perform similarly in evaluating intraductal extension of ampullary adenomas. Additionally, EUS is accurate in T-staging ampullary adenocarcinomas. Future prospective studies should evaluate whether EUS can identify characteristics of ampullary lesions that appropriately direct patients to endoscopic or surgical resection. (*Gastrointest Endosc* 2015;81:380-8.)

The diagnostic approach to suspected ampullary tumors remains controversial. For ampullary adenomas, endoscopic resection is preferred over surgery given its lower morbidity.¹ However, some patients will undergo incomplete endoscopic resection in the setting of occult adeno-carcinoma, often caused by invasion of the duodenum, pancreas/ pancreatic duct (PD), or bile duct (BD).²⁻⁴ A previous prospective study of 106 patients with a benign tumor of the major or minor papilla treated endoscopically reported intraductal extension significantly reduced the likelihood of complete endoscopic resection from 83% to 46% ($P < .001$).³ In our recent cohort study of individuals undergoing endoscopic papillectomy, patients with incomplete resection had a significantly higher rate of intraductal extension (as defined by ERCP) than those with complete resection (31.3% vs 9.0%; $P = .0002$).² EUS is a less-invasive alternative to ERCP for the local staging of ampullary lesions. Although intraductal extension is not an absolute contraindication to endoscopic resection, EUS findings of intraductal extension or duodenal/pancreas invasion may triage patients to nonendoscopic treatment modalities and minimize the likelihood of incomplete endoscopic resection.⁵⁻⁹

Because of a paucity of evidence, the American Society for Gastrointestinal Endoscopy guideline recommends using EUS on a case-by-case basis in the workup of ampullary lesions.⁹ In a prospective trial of patients with ampullary lesions ($n = 40$), surgical resection was avoided in 10 patients (25%) who underwent EUS and intraductal US.⁵ Of those referred for endoscopic papillectomy ($n = 10$), all (7 with adenoma and 3 with adenocarcinoma limited to the mucosal layer) underwent successful endoscopic resection. Although several studies showed the reliability of EUS for T staging of ampullary neoplasms, these were limited by small sample size, heterogeneity of study design (combining both duodenal and ampullary lesions), or limited comparative analysis of intraductal extension with ERCP and surgical pathology.^{5,8,10}

Our primary objective was to compare EUS with ERCP and surgical pathology for the locoregional evaluation of ampullary lesions. Specifically, we measured the rates of intraductal extension and local tissue invasion by using surgical pathology as the reference standard. The secondary objectives were to describe the impact of intraductal extension (defined by EUS, ERCP, or both) on endoscopic resectability and the performance characteristics of EUS-FNA in this setting. Although there are subtle histopathological differences between a lesion arising from the duodenal aspect of the major papilla and one

arising from within the ampulla, we use the terms ampulla and papilla interchangeably and papillectomy to describe the endoscopic resection technique.

METHODS

Study population

By using an endoscopy database (ProVationMD; Wolters Kluwer Health, Philadelphia, Pa), we identified all patients who were referred for EUS to evaluate a known or suspected ampullary lesion (a previous biopsy suggesting adenoma/adenocarcinoma) between January 1998 and December 2012. Patients who had a previous ERCP with or without biliary stent placement were excluded from the study. Lesions were categorized as adenomatous (ranging from adenoma to adenocarcinoma) and nonadenomatous. We abstracted medical records for relevant demographic and clinical data, including the following lesion characteristics: intraductal (BD or PD) extension, local tissue (duodenum, pancreas, other) invasion, and size (by endoscopy, EUS, and surgical pathology). We describe each patient's management after EUS, including endoscopic or surgical resection and medical treatment. The accuracy of tumor staging, intraductal extension, and histo-logical features were evaluated by using surgical pathology as the reference standard. Our local institutional review board approved the study protocol before the collection of data.

EUS examination

All EUS examinations were performed before deciding to proceed with endoscopic or surgical resection (or neither). All patients underwent EUS with the absence of an overlying biliary stent. The indications for EUS included characterizing the tumor, locoregional staging (the assessment of intraductal extension and local tissue invasion), and/or obtaining a tissue diagnosis. All EUS procedures were performed by 1 of 6 experienced endosonographers (J.L., S.S., J.D., M.A., L.M., or G.C.) and ERCP by 1 of 6 experienced providers in ERCP (S.S., E.F., L.M., G.C., J.W., or G.L.), 3 of whom also performed EUS. During the examination, EUS was routinely completed to assess (1) tumor depth, (2) invasion into local structures (duodenum and/ or pancreas), (3) intraductal extension (BD, PD, or both), and (4) involvement of regional lymph nodes (LNs). The decisions to perform CT or magnetic resonance imaging before EUS or to perform FNA during the procedure were left to the discretion of the treating physician. EUS was performed by using radial echoendoscopes (GFUM20, GF-UM130, or GF-UM160; Olympus America, Inc, Center Valley, Pa) and/or linear echoendoscopes (32UA or 32 UX; Pentax Medical Co, Montvale, NJ or GF-UC30P or GF-UC140P; Olympus America, Inc). In some cases, FNA was performed by using a 19- or 22-gauge needle (Cook Endoscopy, Winston-Salem, NC) with the presence of on-site cytopathology.

Post-EUS management

After EUS, a therapeutic decision to proceed with endoscopic or surgical resection or to refer to medical oncology was made by the treating physician/endosonographer. Pre-resection sampling histopathology (mucosal biopsies) was performed at the discretion of the referring physician/endoscopist. Indications influencing the decision to proceed with ERCP included 1 or more of the following: (1) ampullary lesions without invasion of the

muscularis propria and considered potentially amenable to endoscopic papillectomy, (2) patients planned for surgical removal who had elevated bilirubin and/or alkaline phosphatase levels necessitating preoperative biliary drainage, or (3) poor surgical candidates requiring palliative biliary stent placement. During ERCP, performing endoscopic papillectomy was determined based on underlying medical comorbidities and the following lesion characteristics: (1) no or limited (<1 cm) intraductal extension, (2) no invasion of the muscularis propria, (3) no lymph node involvement, and (4) no distant metastasis. Endoscopic removal was performed by using a side-viewing duodeno-scope with a therapeutic (4.2 mm) working channel (Olympus Optical Co, Tokyo, Japan). At the time of endoscopic resection, intraductal extension (BD, PD, or both) was also assessed. When feasible, the lesion was resected en bloc by using an electrocautery snare with alternating cut/coagulation current (ERBO-TOM 200 HF; ERBE USA, Marietta, Ga).² Otherwise, a piecemeal resection technique was used.¹¹ If residual adenomatous tissue was suspected after resection, the endoscopist attempted to ablate it by using electrocautery or argon plasma coagulation.

For patients who did not meet the indications for endoscopic papillectomy, they were referred for surgical or medical oncology consultation as appropriate. For those proceeding to resection (surgical or endoscopic), the procedure occurred on the same day or within 2 weeks of the diagnostic EUS.

Definitions

At the time of EUS, an ampullary tumor was identified as an iso- or hypoechoic mass emerging from the ampulla of Vater. Locoregional staging included the evaluation of intraductal extension and local tissue invasion. Intraductal extension was defined as a discrete lesion in the BD (Fig. 1) or PD arising from the primary tumor. Local tissue invasion was described with the TNM classification system: no evidence of primary tumor (T0), carcinoma in situ (Tis), limited to the ampulla of Vater or sphincter of Oddi (T1), invasion of the duodenal muscularis propria/duodenal wall (T2), invasion of the pancreas (T3), invasion of the peripancreatic soft tissues or other adjacent organs or structures other than the pancreas (T4).¹² Because the American Society for Gastrointestinal Endoscopy guideline (2006) recommended performing ERCP with both BD and PD evaluation at the time of endoscopic resection to assess for evidence of extension into either ductal system,⁹ we compared EUS with ERCP by using ERCP as the reference standard for the evaluation of intraductal extension. During cholangiopancreatography (balloon-occluded technique), intraductal extension was defined by extension of a polypoid-filling defect into the BD or PD or tumor protruding from the ductal orifice with impaired contrast flow through the duodenal lumen (Fig. 2). For patients undergoing EUSFNA of the primary lesion, cytopathology was reported as adenoma, atypia, adenocarcinoma, or normal duodenal tissue. For those having EUS-FNA of a regional LN, cyto-pathology was reported as reactive LN or metastatic adenocarcinoma.

Preoperative evaluations by EUS and ERCP were compared with surgical pathology, which was the reference standard. Final surgical pathology included adenoma, advanced adenoma (defined as tubulovillous adenoma, villous adenoma, or adenoma with high-grade

dysplasia), adenocarcinoma, and all others. Of those undergoing endoscopic papillectomy of an ampullary adenoma, we assumed no intraductal extension if the lesion was completely removed with a negative margin reported by surgical pathology and no ductal extension identified during cholangiography. Moreover, we defined complete resection as a patient who underwent at least 1 surveillance endoscopy with no endoscopic evidence of residual adenoma. For patients who underwent surgical resection, intraductal extension was defined by its presence on surgical pathology. We defined complete surgical resection as a patient who underwent surgical removal with a negative tumor margin on histopathology.

Statistical analysis

We compared the performance characteristics (sensitivity/specificity) of EUS for intraductal (BD, PD, or both) and local staging with ERCP and surgical pathology (reference standard) by using area under the receiver-operating characteristic (AUROC) curves with 95% confidence intervals (CIs). We also analyzed outcomes from the subgroup referred for endoscopic papillectomy. Variables are presented as actual numbers and proportions. Statistical analyses were performed by using Stata version 11.2 (StataCorp LP, College Station, Tex).

RESULTS

Patient characteristics

During the 15-year study period, we identified 119 patients (59 female; mean age, 67.1 ± 14.5 years) who underwent EUS primarily for the evaluation of an ampullary lesion (Fig. 3). ERCP was performed in 90 patients (76%). Clinical presentations included incidental findings ($n = 36$; 30%), screening for familial adenomatous polyposis ($n = 8$; 7%), elevated liver or pancreas chemistries ($n = 15$; 13%), and overt symptoms (acute pancreatitis, abdominal pain, or jaundice) ($n = 60$; 50%). By endoscopy, EUS, and pathology, median lesion size was 20 mm (range 10-60 mm), 18 mm (range 8-50 mm), and 18 mm (range 4-78 mm), respectively. Based on histopathology, 20 (17%) were nonadenomatous. The remaining ($n = 99$) included adenoma ($n = 31$; 26%), advanced adenoma ($n = 33$; 28%), and adenocarcinoma ($n = 35$; 29%). Of those with an adenomatous lesion, 6 were lost to follow-up after EUS.

Therapeutic management after EUS

After EUS, a total of the 113 patients with ampullary tumors underwent surgery ($n = 39$), endoscopic papillectomy ($n = 58$), systemic therapy ($n = 5$), or endoscopic surveillance/no follow-up ($n = 11$) (Fig. 3). All patients with adenoma/adenocarcinoma who underwent surgery ($n = 36$) had a negative tumor margin, 28 (78%) had no intraductal extension, and 8 (22%) had intraductal extension. Endoscopic papillectomy was performed in 48 adenomatous lesions (48%) and 10 nonadenomatous lesions (50%).

EUS for the assessment of intraductal extension

In the subgroup of individuals who underwent ERCP ($n = 90$), we compared detection rates of intraductal extension when using EUS and ERCP (Table 1). With ERCP as the reference, the sensitivity, specificity, and accuracy of EUS for any intraductal extension were 56%,

97%, and 90%, respectively (AUROC = 0.77; 95% CI, 0.64-0.89). The majority of discordance was in BD extension seen on ERCP but not on EUS (6/12); however, in those having no EUS but only ERCP evidence of BD extension (n = 6), surgical pathology of the resected specimen and EUS agreed on no BD extension in 4 of 6.

In the subgroup of individuals who underwent endoscopic (n = 58) or surgical (n = 39) resection, we compared EUS and ERCP with surgical pathology for intraductal extension (Tables 2 and 3). With surgical pathology as the reference (n = 81), the sensitivity, specificity, and accuracy of ERCP for any intraductal extension were 83%, 93%, and 84%, respectively (AUROC = 0.88; 95% CI, 0.77-0.99) (Table 2). Comparable to ERCP, the sensitivity, specificity, and accuracy of EUS (n = 102) for intraductal extension were 80%, 93%, and 91%, respectively (AUROC = 0.87; 95% CI, 0.76-0.97) (Table 3). Intraductal extension was incorrectly classified in 13 of 81 patients by ERCP and in 9 of 102 patients by EUS.

Based on the type of echoendoscopes, EUS was performed by using a radial alone in 92 patients, linear alone in 21, and both in 6. When surgical pathology was used as the reference, the accuracy of radial and linear echoendoscopes was comparable. The accuracy of using a radial echoendoscope (n = 75) was 8 of 10 (80%) and 62 of 65 (95%) in classifying the presence and absence of intraductal extension, respectively. The accuracy of using a linear echoendoscope (n = 21) was 4 of 4 (100%) and 16 of 17 (94%) in determining the presence and absence of intraductal extension, respectively. Intraductal extension was incorrectly identified in 5 of 75 by radial echoendoscopes and in 1 of 21 by linear echoendoscopes.

EUS for the assessment of local tissue invasion

For the assessment of local tissue invasion, the overall accuracy of EUS was 90% by using surgical pathology as the reference standard (Table 4). The accuracy of EUS was 98%, 78%, 80%, and 78% in identifying patients with T1, T2, T3, and T4 stages, respectively. Of lesions confined to the ampulla (n = 66), EUS incorrectly described invasion of the pancreas in 1. In all others (n = 34), 7 patients having invasion of the duodenal wall (n = 4), pancreas (n = 1), and other structures (n = 2) found in the surgical specimens were missed by EUS; 1 patient was triaged inappropriately to endoscopic removal, whereas 6 patients were triaged correctly to surgery because of adenocarcinoma found in the biopsy specimen (n = 4) and positive cytology for malignancy (n = 2).

Outcomes of endoscopic papillectomy after EUS examination

Of 90 patients proceeding to ERCP after EUS, endoscopic papillectomy was performed in 58; preoperative biliary drainage was performed in 27 and palliative drainage in 5. In those undergoing endoscopic papillectomy (n = 58), jaundice was present in 5 (9%). Other presentations included incidental findings (n = 25; 43%), familial adenomatous polyposis screening (n = 3; 5%), abnormal laboratory test results (n = 6; 10%), and overt symptoms (n = 24; 41%). By endoscopy, EUS, and pathology, the median size of these lesions was 15 mm (range 10-50 mm), 16 mm (range 9-50 mm), and 15 mm (6-50 mm), respectively. Based on surgical pathology of the resected specimens, 10 were found to have a

nonadenomatous lesion (despite a previous biopsy specimen suggesting adenoma; these samples were not reviewed by histopathology at our institution before endoscopic papillectomy); carcinoid tumor (n = 1), ectopic gastric mucosa (n = 1), fibro-muscular dysplasia (n = 1), hyperplastic polyp (n = 2), normal duodenal mucosa (n = 2), and chronic inflammation (n = 3). No intraductal invasion was identified in nonadenomatous lesions. The remaining included adenoma (n = 25; 43%), advanced adenoma (n = 21; 36%), and adenocarcinoma (n = 2; 3%). We identified intraductal extension by EUS in 5 (9%) by ERCP in 7 (12%). EUS and ERCP agreed on no intraductal extension in 50 and intraductal involvement in 5. There were 3 discordant cases, with intraductal extension seen by EUS only in 1 and ERCP only in 2; complete endoscopic resection was achieved in 2 of these 3 cases.

Complete endoscopic resection with a negative surveillance endoscopy occurred in 53 of 58 (91%); in those having intraductal extension suggested by EUS and ERCP, complete resection was achieved in 4 of 5 (80%) and 4 of 7 (57%), respectively. Two patients with incomplete resection were found to have intraductal invasion at ERCP (confirmed by surgical specimens), which were missed by EUS. In the remaining 3 cases (advanced adenoma [n = 2] and adenocarcinoma [n = 1]), EUS underestimated duodenal muscularis propria invasion that was proved by surgical pathology.

EUS-FNA in a cohort of individuals with ampullary adenocarcinoma

A total of 20 patients underwent FNA at the time of EUS. Of those, 16 underwent FNA of the ampullary lesion and 4 of a regional LN. Of those having FNA performed of the primary lesion, 4 were ultimately proved to have nonadenomatous lesions; EUS-FNA confirmed carcinoid in 1 and true negative (no malignancy or adenoma) in 3. The remaining included adenoma (n = 2), advanced adenoma (n = 3), and adenocarcinoma (n = 7) based on surgical pathology. EUS-FNA confirmed adenocarcinoma in 6 of 7 (86%) and adenoma/advanced adenoma in 1 of 5 (20%). Of those undergoing EUS-FNA of a regional LN, 3 were described as reactive LNs and 1 was reported as metastatic adenocarcinoma; all had adenocarcinoma with LN involvement (n = 2) and no LN involvement (n = 2) confirmed by surgical pathology.

DISCUSSION

Local staging of ampullary lesions when using EUS

Because of its lower morbidity compared with surgery, endoscopic papillectomy is the preferred technique for resection of precancerous lesions of the ampulla.¹ Before endoscopic resection, recognition of adenocarcinoma (often missed with forceps biopsies of the ampulla), duodenal wall invasion, or extension of adenomatous tissue into the bile or pancreatic duct may influence the endoscopist's decision to proceed with endoscopic papillectomy. Given the inherent risks of ERCP and endoscopic papillectomy, incomplete endoscopic resection should be minimized. Therefore, accurate local staging of ampullary lesions is essential for the appropriate triage of patients to endoscopic or surgical resection. Previous studies showed that EUS is superior to transabdominal US, CT, and magnetic resonance imaging in assessing the T stage of ampullary lesions.¹³⁻¹⁹ In a recent meta-

analysis that included 14 studies and 422 patients, the pooled sensitivity/specificity of EUS for diagnosing T1-stage tumor was 77%/78%.²⁰ In our cohort (n = 119) of individuals being referred for consideration of endoscopic papillectomy, we observed an overall accuracy of 90% compared with surgical pathology. This higher rate may be attributed to the absence of an overlying biliary stent. Because EUS is operator dependent, the accuracy may be superior when performed by higher volume endosonographers. The greatest accuracy of EUS was in identifying patients with T1 disease (98%). For T2, T3, and T4 lesions, the diagnostic accuracy decreased to 78%, 80%, and 78%, respectively.

Intraductal extension (<1 cm) of ampullary lesions

Although not a contraindication to endoscopic resection, intraductal extension is a significant risk factor for incomplete endoscopic resection (odds ratio 0.29, $P = .01$).² A smaller Japanese series that included patients referred for surgery (n = 30) and endoscopic papillectomy (n = 10) reported high agreement with surgical pathology for bile (88%) and pancreatic (90%) duct extension when using EUS and 90% with intraductal US.⁵ In our cohort, EUS had 90% accuracy compared with ERCP for the assessment of intraductal extension of ampullary tumors. Compared with surgical pathology (n = 102), EUS and ERCP had comparable agreement for the evaluation of intraductal extension (91% and 84%). Of those having an incorrect diagnosis by ERCP (13/81) and EUS (9/102), ERCP was more likely to overstage intraductal extension than EUS (11/81, 13% vs 6/102, 6%).

What is the clinical significance of identifying intraductal extension when using EUS? We anecdotally observed a higher rate of complete endoscopic resection (91%) in the current series compared with our recent analysis (73%) that included all individuals undergoing endoscopic papillectomy, 39% of whom had undergone EUS before resection.² Of 182 patients undergoing endoscopic papillectomy for ampullary lesions in our previous study, 111 proceeded directly to ERCP without EUS; 70% had complete resection.² Patients with lesions deemed unresectable at the time of EUS or ERCP because of extensive (>1 cm) intraductal extension, invasion of the duodenal submucosa, or lymph node invasion were excluded from our previous study.² In a limited number of patients undergoing EUS before endoscopic papillectomy (n = 71) in this study, EUS was performed at similar frequencies in both the complete and incomplete endoscopic resection group (40% vs 35%; $P = .55$). However, patients with incomplete resection had a significantly higher rate of intraductal extension as defined by ERCP in this cohort (31% vs 9%, $P = .0002$); if a subgroup of these individuals had not undergone endoscopic papillectomy based on the finding of intraductal extension by EUS, then the complete resection rate may have been higher. Of 5 patients having incomplete resection in the current study, intraductal extension was detected in 2, both of which were missed by EUS. On the other hand, among 19 individuals with intraductal extension by EUS, 5 of 19 proceeded to endoscopic resection and 12 of 19 to surgical resection (1/19 underwent systemic chemotherapy and 1/19 had endoscopic surveillance with no intervention), with a complete endoscopic resection rate of 80%. Based on our results, it may be reasonable to consider strengthening society guidelines that currently recommend EUS on a case-by-case basis in the workup of ampullary lesions. Although this study is limited by its retrospective design, EUS may have appropriately triaged some or all patients referred for surgical resection, thereby improving the observed

complete endoscopic resection rate (91%). Given its safety profile and relatively low cost, especially when performed in the same setting as ERCP, EUS may reduce the need for diagnostic ERCP and the incidence of incomplete endoscopic resection. Although endoscopic papillectomy may be feasible in cases with intraductal growth, the rate of complete resection is lower.³

After EUS, 15 patients underwent successful surgical resection without ERCP because of adenocarcinoma found in the biopsy specimen (n = 3), intraductal extension (n = 2), and invasion of duodenal wall (n = 7)/pancreas (n = 3) with intraductal extension. The remaining 3 patients with incomplete endoscopic resection in this cohort had invasion of the duodenal muscularis propria, all which were missed by EUS. In previous series, EUS understaged invasion of the duodenal muscularis propria, ranging from 8% to 15%.^{5,10} Our observations suggest that EUS is more likely to understage ampullary lesions, perhaps due to missing focal invasion of the muscularis propria that is only identified by histopathological analysis of the resected specimen.

In addition, 10 patients undergoing endoscopic papillectomy in our study were found to have a nonadenomatous lesion based on surgical pathology of the resected specimen despite a previous biopsy specimen suggesting adenoma. However, those previous histopathology results were not re-reviewed at our institution before endoscopic removal. This suggests the need for re-reviewing histopathology results at a tertiary center before making a therapeutic decision.

EUS-FNA of ampullary lesions

The performance characteristics of EUS-FNA of periampullary cancers are well established^{21,22}; there are limited data analyzing the sensitivity/specificity of EUS-FNA in cohorts of ampullary lesions that include adenomas. In a study of 35 ampullary lesions, 13 of which were adenocarcinoma, the diagnostic accuracy was 89%.²³ In our cohort that included 20 patients who underwent EUS-FNA of an ampullary lesion (n = 16) or regional LN (n = 4), the accuracy of EUS-FNA for diagnosing adenocarcinoma was 86% (n = 6); on the other hand, the accuracy of diagnosing adenoma/advanced adenoma was only 20% (n = 1) in a limited number of cases. However, discerning adenoma from high-grade dysplasia is very difficult based on cytology alone.

Limitations

Our study is limited by its retrospective design and lack of predefined criteria for proceeding from EUS to endoscopic or surgical resection. The endoscopists used evidence of either limited (<1 cm) intraductal extension or no intraductal extension as an indication for endoscopic removal during the study period; this may lead to inconsistent criteria for surgical referral and influence treatment outcome of endoscopic resection. Although the exact length of intraductal extension was not documented, the extent of intraductal involvement was between subcentimeter to a maximum length of approximately 1 cm. These data represent a subset of ampullary tumors seen at our institution as some proceed directly to ERCP without EUS. Nevertheless, our high rate of complete endoscopic resection (91%) compared with that of historical series suggests that EUS may have appropriately

triaged a subgroup of patients to nonendoscopic treatment modalities, thereby avoiding the risks of ERCP and endoscopic papillectomy.

Summary

In conclusion, EUS has good agreement with ERCP and surgical pathology for the assessment of intraductal extension and local staging of ampullary lesions. In selected cases of local tissue invasion or intraductal extension identified by EUS, ERCP and attempts at endoscopic resection may be avoidable. Future studies should compare alternative imaging modalities such as EUS, intraductal US, and cholangioscopy, for assessing intraductal extension, as its presence significantly reduces the likelihood of complete endoscopic resection. Furthermore, our analysis suggests the need for a prospective, comparative effectiveness study to further evaluate the impact of EUS on minimizing ERCP and incomplete endoscopic resection of ampullary lesions.

Abbreviations

AUROC	area under the receiver-operating characteristic
DB	bile duct
CI	confidence interval
LN	lymph node
PD	pancreatic duct

REFERENCES

1. Ceppa EP, Burbridge RA, Rialon KL, et al. Endoscopic versus surgical ampullectomy: an algorithm to treat disease of the ampulla of Vater. *Ann Surg.* 2013; 257:315–22. [PubMed: 23059497]
2. Ridditid W, Tan D, Schmidt SE, et al. Endoscopic papillectomy: risk factors for incomplete resection and recurrence during long-term follow-up. *Gastrointest Endosc.* 2014; 79:289–96. [PubMed: 24094466]
3. Bohnacker S, Seitz U, Nguyen D, et al. Endoscopic resection of benign tumors of the duodenal papilla without and with intraductal growth. *Gastrointest Endosc.* 2005; 62:551–60. [PubMed: 16185970]
4. Boix J, Lorenzo-Zuniga V, Moreno de Vega V, et al. Endoscopic resection of ampullary tumors: 12-year review of 21 cases. *Surg Endosc.* 2009; 23:45–9. [PubMed: 18398649]
5. Ito K, Fujita N, Noda Y, et al. Preoperative evaluation of ampullary neoplasm with EUS and transpapillary intraductal US: a prospective and histopathologically controlled study. *Gastrointest Endosc.* 2007; 66:740–7. [PubMed: 17905017]
6. Roberts KJ, McCulloch N, Sutcliffe R, et al. Endoscopic ultrasound assessment of lesions of the ampulla of Vater is of particular value in low-grade dysplasia. *HPB (Oxford).* 2013; 15:18–23. [PubMed: 23216775]
7. Castillo C. Endoscopic ultrasound in the papilla and the periampullary region. *World J Gastrointest Endosc.* 2010; 2:278–87. [PubMed: 21160627]
8. Wee E, Lakhtakia S, Gupta R, et al. The diagnostic accuracy and strength of agreement between endoscopic ultrasound and histopathology in the staging of ampullary tumors. *Indian J Gastroenterol.* 2012; 31:324–32. [PubMed: 22996048]
9. Adler DG, Qureshi W, Davila R, et al. The role of endoscopy in ampullary and duodenal adenomas. *Gastrointest Endosc.* 2006; 64:849–54. [PubMed: 17140885]

10. Azih LC, Broussard BL, Phadnis MA, et al. Endoscopic ultrasound evaluation in the surgical treatment of duodenal and peri-ampullary adenomas. *World J Gastroenterol.* 2013; 19:511–5. [PubMed: 23382629]
11. Binmoeller KF, Boaventura S, Ramsperger K, et al. Endoscopic snare excision of benign adenomas of the papilla of Vater. *Gastrointest Endosc.* 1993; 39:127–31. [PubMed: 8495831]
12. Edge, S. *AJCC cancer staging manual.* Springer-Verlag; New York (NY): 2009.
13. Chen CH, Tseng LJ, Yang CC, et al. The accuracy of endoscopic ultra-sound, endoscopic retrograde cholangiopancreatography, computed tomography, and transabdominal ultrasound in the detection and staging of primary ampullary tumors. *Hepatogastroenterology.* 2001; 48:1750–3. [PubMed: 11813616]
14. Artifon EL, Couto D Jr, Sakai P, et al. Prospective evaluation of EUS versus CT scan for staging of ampullary cancer. *Gastrointest Endosc.* 2009; 70:290–6. [PubMed: 19523619]
15. Cannon ME, Carpenter SL, Elta GH, et al. EUS compared with CT, magnetic resonance imaging, and angiography and the influence of biliary stenting on staging accuracy of ampullary neoplasms. *Gastrointest Endosc.* 1999; 50:27–33. [PubMed: 10385718]
16. Chen CH, Tseng LJ, Yang CC. Preoperative evaluation of periampullary tumors by endoscopic sonography, transabdominal sonography, and computed tomography. *J Clin Ultrasound.* 2001; 29:313–21. [PubMed: 11424095]
17. Manta R, Conigliaro R, Castellani D, et al. Linear endoscopic ultrasonography vs magnetic resonance imaging in ampullary tumors. *World J Gastroenterol.* 2010; 16:5592–7. [PubMed: 21105192]
18. Chen CH, Yang CC, Yeh YH, et al. Reappraisal of endosonography of ampullary tumors: correlation with transabdominal sonography, CT, and MRI. *J Clin Ultrasound.* 2009; 37:18–25. [PubMed: 18726967]
19. Skordilis P, Mouzas IA, Dimoulios PD, et al. Is endosonography an effective method for detection and local staging of the ampullary carcinoma? A prospective study. *BMC Surg.* 2002; 2:1. [PubMed: 11914153]
20. Trikudanathan G, Njei B, Attam R, et al. Staging accuracy of ampullary tumors by endoscopic ultrasound: meta-analysis and systematic review. *Dig Endosc.* Epub 2014 Feb 17.
21. Ross WA, Wasan SM, Evans DB, et al. Combined EUS with FNA and ERCP for the evaluation of patients with obstructive jaundice from presumed pancreatic malignancy. *Gastrointest Endosc.* 2008; 68:461–6. [PubMed: 18384788]
22. Shin HJ, Lahoti S, Sneige N. Endoscopic ultrasound-guided fine-needle aspiration in 179 cases: the M. D. Anderson Cancer Center experience. *Cancer.* 2002; 96:174–80. [PubMed: 12115306]
23. Defrain C, Chang CY, Srikureja W, et al. Cytologic features and diagnostic pitfalls of primary ampullary tumors by endoscopic ultrasound-guided fine-needle aspiration biopsy. *Cancer.* 2005; 105:289–97. [PubMed: 15986397]

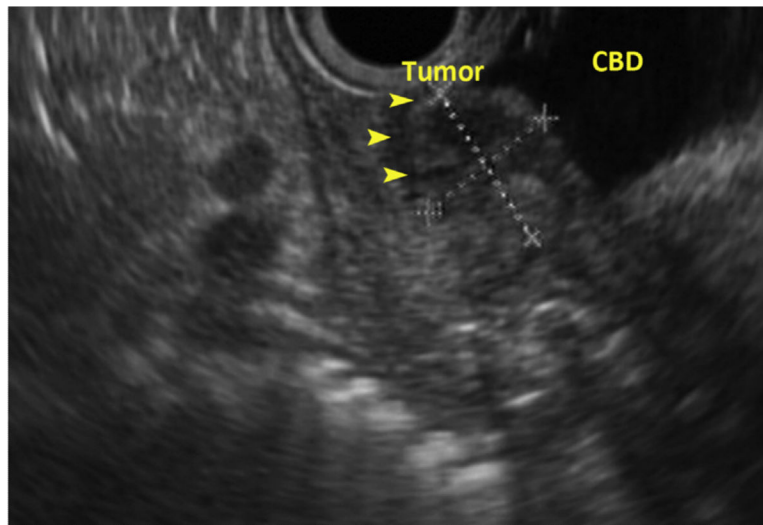


Figure 1. Intraductal extension (*arrowheads*) of ampullary adenocarcinoma by EUS. *CBD*, common bile duct.

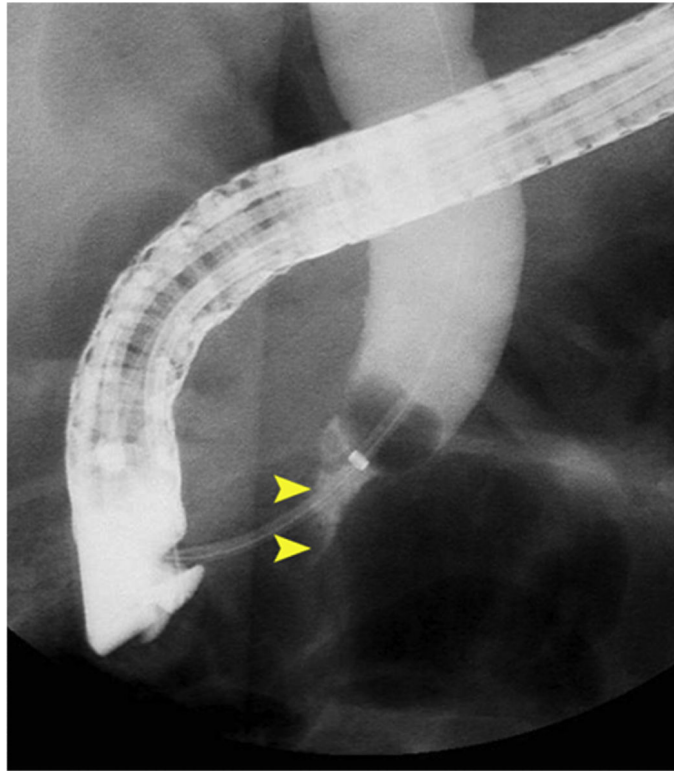


Figure 2. Distal bile duct stricture (*arrowheads*) secondary to intraductal extension of ampullary lesion by ERCP.

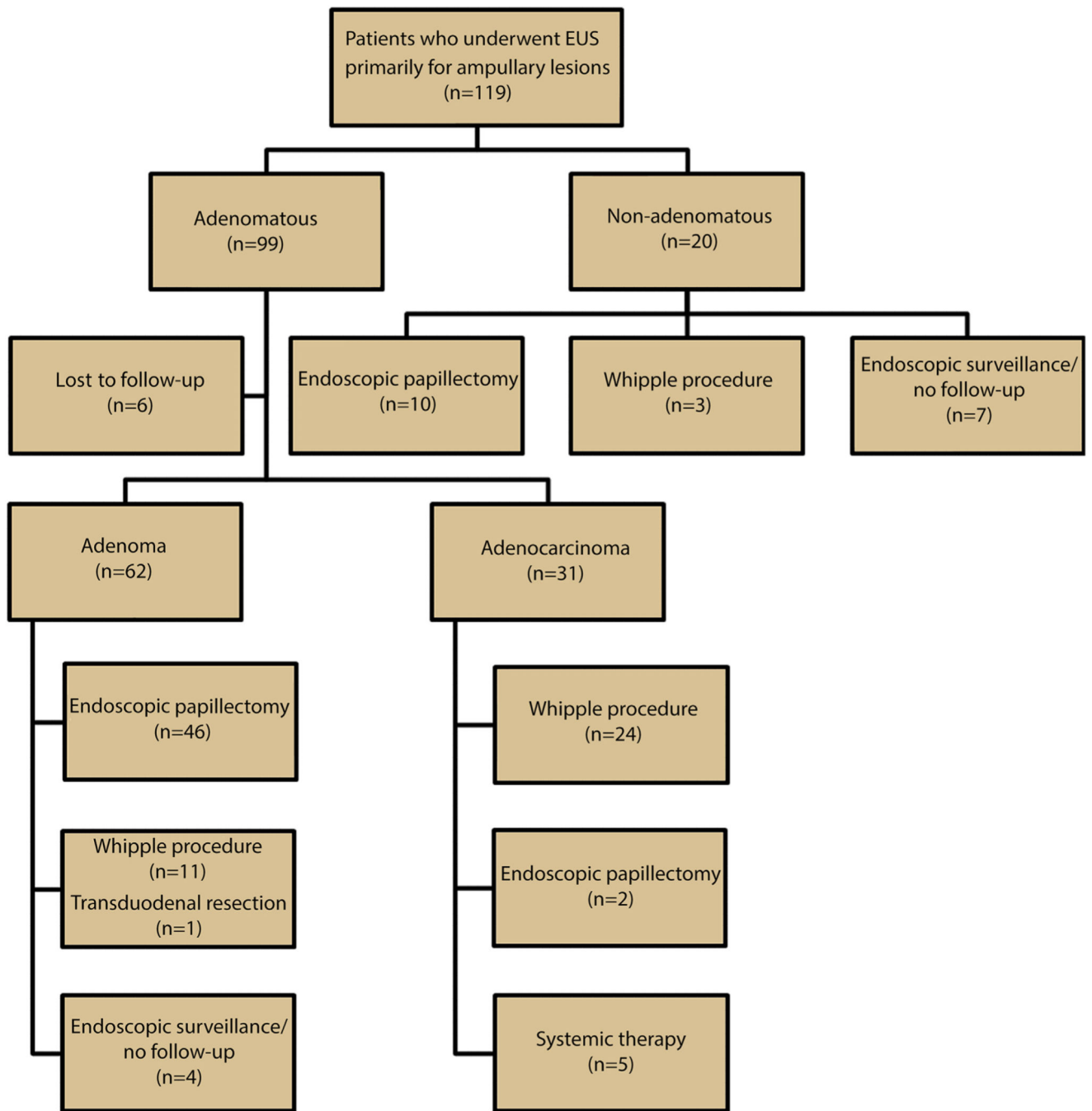


Figure 3. Patient cohort: EUS for ampullary lesions between 1998 and 2012.

TABLE 1

Accuracy of EUS for the assessment of intraductal extension when using ERCP as the reference standard

Intraductal involvement by EUS	Intraductal involvement by ERCP				Total
	None	Bile duct	Pancreatic duct	Both ducts	
None	72	6	0	1	79
Bile duct	0	6	0	0	6
Pancreatic duct	0	0	1	0	1
Both ducts	2	0	0	2	4
Overstaged by EUS	2/74	0/12	0/1	0/3	2/90
Understaged by EUS	0/74	6/12	0/1	1/3	7/90
Accuracy	72/74	6/12	1/1	2/3	81/90 (90%)

TABLE 2

Accuracy of ERCP for the assessment of intraductal extension when using surgical pathology as the reference standard

Intraductal involvement by ERCP	Intraductal involvement by pathology				Total
	None	Bile duct	Pancreatic duct	Both ducts	
None	64	1	0	1	66
Bile duct	5	7	0	0	12
Pancreatic duct	0	0	1	0	1
Both ducts	0	0	0	2	3
Overstaged	5/69	0/8	0/1	0/3	11/81
Understaged	0/69	1/8	0/1	1/3	2/81
Accuracy, n/n (%)	64/69	1/8	1/1	2/3	68/81 (84%)

TABLE 3

Accuracy of EUS for the assessment of intraductal extension when using surgical pathology as the reference standard

Intraductal involvement by EUS	Intraductal involvement by pathology				Total
	None	Bile duct	Pancreatic duct	Both ducts	
None	81	3	0	0	84
Bile duct	3	6	0	0	9
Pancreatic duct	0	0	1	0	1
Both ducts	3	0	0	5	8
Overstaged	6/87	0/9	0/1	0/5	6/102
Understaged	0/87	3/9	0/1	0/5	3/102
Accuracy, n/n (%)	81/87	6/9	1/1	5/5	93/102 (91%)

TABLE 4

Local staging of ampullary lesions by EUS versus surgical pathology

EUS stage	Surgical stage					Total
	No primary tumor	Limited to ampulla	Invasion of duodenal wall	Invasion of pancreas	Invasion of other structures	
Limited to ampulla	2	65	4	0	1	72
Invasion of duodenal wall	0	0	14	1	1	16
Invasion of pancreas	0	1	0	4	0	5
Invasion of other structures	0	0	0	0	7	7
Overstaged	2/2	1/66	0/18	0/5	0/9	3/100
Understaged	0/2	0/66	4/18	1/5	2/9	7/100
Accuracy, n/n (%)	0/2	65/66	14/18	4/5	7/9	90/100 (90%)