

Marco Carraro

**Smile aesthetics: an interdisciplinary approach**



Universidade Fernando Pessoa  
Faculdade de Ciências da Saude  
Porto, 2018



Marco Carraro

**Smile aesthetics: an interdisciplinary approach**



Universidade Fernando Pessoa  
Faculdade de Ciências da Saude  
Porto, 2018

Marco Carraro

**Smile aesthetics: an interdisciplinary approach**

Dissertation submitted to Fernando Pessoa University

As part of the requirements for obtaining

the Master's Degree in Oral Medicine

-----

## **Abstract**

The face is the visiting card of our person to society and the smile is its most important characterization: the presence of anomalies may represent a break in harmony and facial aesthetics.

The main objective of this writing is to identify the main characteristics of a pleasant smile and to analyse some of the available therapeutic approaches aiming to correct dentofacial anomalies.

A bibliographic search was performed using B-on, PubMed and textbooks, based on the keywords “smile aesthetics”.

According to the literature analysed, it seems that following certain guidelines and parameters is crucial in achieving the best possible outcome and the clinician should consider an interdisciplinary therapeutic approach, within the limits of anatomy and function.

## **Keywords**

*Smile aesthetic; beautiful; harmony; golden standard; dental aesthetic; upper incisor; lips; gummy smile.*

## **Resumo**

O rosto é o cartão de visitas de uma pessoa para a sociedade e o sorriso é a sua caracterização mais importante: a presença de anomalias pode representar uma ruptura na harmonia e na estética facial.

O objetivo principal deste trabalho é identificar as principais características de um sorriso agradável e analisar algumas das abordagens terapêuticas disponíveis, visando corrigir as anomalias dentofaciais.

Foi realizada uma pesquisa bibliográfica utilizando B-on, PubMed e livros didáticos, com base na palavra-chave "sorriso estético".

De acordo com a literatura analisada, parece que seguir certas diretrizes e parâmetros seja crucial para alcançar o melhor resultado possível e o clínico deveria considerar uma abordagem terapêutica interdisciplinar, dentro dos limites da anatomia e da função.

## **Palavras-chave**

*Sorriso estético; lindo; harmonia; padrão ouro; estética dentária; incisivo superior; lábios; sorriso gengival.*

## Table of contents

<i>Abstract</i> .....	<i>V</i>
<i>Keywords</i> .....	<i>V</i>
<i>Resumo</i> .....	<i>VI</i>
<i>Palavras-chave</i> .....	<i>VI</i>
<i>Index of Abbreviations</i> .....	<i>IX</i>
<i>Index of figures</i> .....	<i>X</i>
<i>1. Introduction</i> .....	<i>1</i>
1.1 Aesthetic and wellness .....	1
1.2 Aesthetic dentistry .....	1
1.3 The smile .....	2
1.4 Materials and methods .....	2
<i>2. What are the characteristics of a beautiful and healthy smile?</i> .....	<i>3</i>
2.1 The importance of maxillary central incisors vertical position .....	3
2.2 Midline deviation and tooth angulation .....	3
2.3 Incisal line and smile arc .....	3
2.4 Buccal corridors .....	4
2.5 Ideal width-height ratio and tooth-to-tooth proportion .....	4
2.6 Symmetry and perception of beauty .....	5
2.6.1 Face symmetry .....	5
2.6.2 Dental symmetry .....	5
2.7 Gingival design and exposure .....	6
2.7.1 “Pink aesthetics” .....	6
2.7.2 Gingival exposure at smiling .....	6
2.8 Presence of anterosuperior diastemas .....	7
2.9 Tooth shade .....	7
2.10 The frame of the smile: the lips .....	8
<i>3. Dental therapies aiming to reach higher beautiful standards: an interdisciplinary approach</i> .....	<i>8</i>
3.1 The golden “range” .....	8
3.2 The orthodontic guidance to reach facial harmony .....	8
3.2.1 Cephalometric hints .....	8
3.2.2 Cephalometric errors .....	9
3.2.3 Achieving facial harmony, geometrical analysis according to AGIHF principles .....	9
3.3 Correction of the “gummy smile” .....	10
3.4 Teeth shape and colour improvement .....	11
3.4.1 Dental bleaching .....	11
3.4.2 Aesthetic ceramic veneers .....	12

3.4.3 Direct composite veneers .....	12
3.5 Lips remodelling using hyaluronic acid injections.....	12
4. Discussion .....	14
5. Conclusion.....	15
Bibliography.....	16
Appendix n.1 .....	18
Appendix n.2.....	19
Appendix n.3.....	20
Appendix n.4.....	21
Appendix n.5.....	22
Appendix n.6.....	23
Appendix n.7.....	24



## **Index of Abbreviations**

A (point): the deepest landmark of the anterior concavity of the maxilla in a craniofacial lateral radiography.

AGIHF: Análise Geométrica Individualizada da Harmonia Facial.

ANB: Angle formed by A and B landmarks, with the vertex at the Nasion landmark in a craniofacial lateral radiography.

B (point): landmark of maximum concavity in the midline of the alveolar process of the mandible in a craniofacial lateral radiography.

Na or N: (Nasion) the most anterior landmark of the frontal-nasal suture in a latero-lateral craniofacial radiography.

NHP: Natural Head Posture.

PNC: Posição Natural da Cabeça.

S: (Sella) center of pituitary fossa of the sphenoid bone in a craniofacial lateral radiography.

SNA: Angle formed by S and A landmarks, with the vertex at the Nasion landmark in a craniofacial lateral radiography.

SNB: Angle formed by S and B landmarks, with the vertex at the Nasion landmark in a craniofacial lateral radiography.

## Index of figures

<b>Fig.1</b> - The aesthetic impact of changes in vertical positioning of incisors at smiling, (Machado, 2014).	18
<b>Fig.2</b> - Types of smile arc, (Machado, 2014).	18
<b>Fig.3</b> - Ideal incisal design in the aesthetic zone, (Machado, 2014).	18
<b>Fig.4</b> - Different aspect of buccal corridors due to computer manipulation, (Alhammadi <i>et al.</i> , 2018).	19
<b>Fig.5</b> - Four examples of standardized W-L variations by using image-manipulation software, (Wolfard <i>et al.</i> , 2005).	19
<b>Fig.6</b> - Four examples of standardized LC variations by using image-manipulation software, (Wolfard <i>et al.</i> , 2005).	19
<b>Fig.7</b> - Tooth wear in 0.5mm increments, (Ribeiro <i>et al.</i> , 2017).	20
<b>Fig.8</b> - Classification of the gingival exposure, (Camara <i>et al.</i> , 2010).	20
<b>Fig.9</b> - Examples of high, medium and low smile lines, (Machado, 2014).	20
<b>Fig.10</b> - Manipulation of maxillary midline diastema, increased by 0.5mm for each step, (Alhammadi <i>et al.</i> , 2018).	21
<b>Fig.11a</b> - Orthodontic correction of deep bite and maxillary incisors proclination, oral view, (Machado, 2014).	21
<b>Fig.11b</b> - Orthodontic correction of deep bite and maxillary incisors proclination, profile view, (Machado, 2014).	21
<b>Fig.12</b> - Lateral X-ray representing the major skeletal landmarks used in cephalometric analysis, (Grogger <i>et al.</i> , 2018).	22
<b>Fig.13</b> - Error plot of Sella (S) – Nasion (N) – Point A (A) and Sella (S) – Nasion (N) – Point B (B), (Grogger <i>et al.</i> , 2018).	22
<b>Fig.14</b> – Use of the sub-nasal vertical as a telerradiograph orientation guide in the Natural Head Posture, (Silva, 2005).	23
<b>Fig.15</b> - AGHIF: Individualized frame construction, Descriptive and Idealization phase, (Silva, 2005).	23
<b>Fig.16</b> - Muscles of the face: pinpointing sites for botulinum toxin injections for “gummy smile” correction, (Polo, 2008).	24
<b>Fig.17</b> - The same patient before and after botulinum toxin injection, (Polo, 2008).	24

## **1. Introduction**

### **1.1 Aesthetic and wellness**

“Aesthetics” is a cultural and evolving phenomenon that develops and coexists in parallel with human society and that keeps changing, according to different cultures and historical periods. In sharing our concept of aesthetics, we must bear in mind that it will undergo an evolution to which we will have to adapt. Aesthetics is one of the most attractive and stimulating themes in our society: it is a contemporary obsession and implies a "struggle" for that invisible "asset" that defines the value of every individual in the eyes of the society: the "status of being beautiful".

The power of aesthetic appearance and the power of images transmitted by the media are so rooted in the social reality of every culture that one cannot deny that the outward appearance has influence in the way we communicate with others. In any case, beauty is in itself harmony, synonymous with health (well-being). All our efforts to achieve certain levels of aesthetics is an attempt to give or even "restore" our health and well-being to our body, since beauty/harmony and function are correlated. To have a healthy aesthetic appearance, free from signs of diseases or imperfections that may over time make our concept of beauty and health decline.

The primary objective of this writing is to identify the main features of an “aesthetic” smile and consider the therapeutic approaches to achieve it or correct it.

### **1.2 Aesthetic dentistry**

Aesthetic Dentistry is based on rules and techniques to obtain an aesthetically pleasing and pleasant smile and facial expression. There are two fundamental objectives that must be carefully pursued and studied:

- 1 - Making teeth with intrinsic proportions that are pleasant in themselves and with respect to other teeth, and that are biologically integrated and in harmony with gingival tissues.
- 2 - Obtain a harmonious and pleasing arrangement of the teeth with the lips and other facial structures.

Proportion, symmetry and perspective of the teeth themselves must focus the image for our clinical work, always considering that in a face it is also important and reasonable to consider

the personalization of each individual case, according to its facial features. Models and icons transmitted by the media, in one hand can serve as a reference and orientation for our aesthetic diagnosis, in the other they risk of influencing the expectation of the patients. Here the role of the clinician is crucial, because the purpose is to treat the patient to the best possible degree of harmony within his characteristics. It is therefore important to pay attention to the individual with his unique harmony, his characteristics, his desires.

### **1.3 The smile**

According to Claude Rufenacht: *"a pleasant smile can produce an aura that amplifies the beauty of the face, as it is a part of the qualities and virtues of the human personality"*, (Kina *et al*, 2009). In fact, among human expressions it is of paramount importance a beautiful smile, however, with reference to aesthetics, our ability to show a pleasant smile depends directly on the structural beauty of the face and the harmony between the different components (teeth, lips, nose, eyes). Dental elements, gingival tissues and lips, arranged in the composition of the face in a harmonious way will be essential for the quality of the smile. Both at rest and during the smile, the labio-dental relationships are decisive for an aesthetically positive or negative judgment of the appearance, considering that they directly influence the diagnosis, then the clinical work. The extent of dental exposure, considering the height of the upper lip compared to the upper central incisors and the gingival tissues during the smile, depends on various factors (incisors inclination and vertical height of the lower third of the face) In the latter case any irregularities in the gingival outlines become very evident, in particular for the natural gingival asymmetries, iatrogenic or produced by improper tooth brushing by the patient. Regarding the modification of the lip line, the treatments can also be limited and temporary (use of botulinum toxin for the "Gummy Smile"). The use of orthognathic surgery, orthodontic intrusion or the surgical increase of the clinical crown are interesting alternatives to improve the labio-dental relationships, but in any cases are interventions whose invasiveness can be heavy.

### **1.4 Materials and methods**

A bibliographic research was carried out based on scientific articles, scientific journals and textbooks, with a temporal restriction between 2005 and 2018, in English and Italian languages. Material selection was done from B-on and PubMed databases and two textbooks. Using as main keywords "smile aesthetic" in multiple combination with secondary keywords, more than 1500 articles were founded and 26 selected.

## **2. What are the characteristics of a beautiful and healthy smile?**

### **2.1 The importance of maxillary central incisors vertical position**

The maxillary central incisors vertical position is the “conditio sine qua non” an aesthetic analysis/planning of the smile has to begin. The vertical positioning is universally accepted to be a determining factor to achieve an attractive and healthy smile. To make an example, a smile with satisfactory teeth colour, proper anatomical shape and proportion can appear highly unaesthetic due to inappropriate vertical incisors positioning (see Appendix n.1, fig.1), (Machado, 2014).

### **2.2 Midline deviation and tooth angulation**

The midline deviation is a parameter between canons of beauty that has been highlighted by several authors, not always accordingly. As other characteristics of a pleasant smile, a midline deviation is noticed also by laypersons, and considered as unaesthetic if exceeding some values. A systematic literature review by Janson *et al.* (2011), reported that the average value of deviation accepted as limit between acceptable and unpleasant correspond to 2.2mm, whereas an axial midline angulation of 10 degrees, corresponding to 2.0mm measured from the midline papilla and the incisal edges of the incisors is already very apparent both for clinicians and laypersons (Janson *et al.*, 2011). Orthodontically, midline deviations equal or greater than 2.0mm, and any change in tooth angulation must be corrected (Machado, 2014).

### **2.3 Incisal line and smile arc**

Other aspect to consider, is the relationship between central incisors, lateral incisors and canines during the smile. According to Machado (2014), “*The incisal edge of maxillary central incisors must be below the cuspid tip of canines, ensuring dominance of central incisors*”. Drawing a line that follows the edges of anterior maxillary teeth, in frontal view, we obtain the incisal line, that is obviously related to the aesthetic appearance of the smile. Câmara (2010) divides in three categories the shape of this line, deep plate, when the incisal line is convex, shallow plate if it is plane, and inverted if it results to be concave.

Regarding the differences between the clinical crown lengths of central and lateral incisors, an aesthetically significant value, can range from 1.0 – 1.5 mm for women, and from 0.5 – 1.0 mm for men (Machado, 2014). This aspect shows that the different types of smile arc, curved, straight or reverse (see Appendix n.1, Fig.2 and Fig.3), influence the perception of a pleasant

smile, and a slightly less convex or flat incisal line is more acceptable for men, where in women is appreciated more convexity (Machado, 2014).

#### **2.4 Buccal corridors**

Buccal corridors are defined as the bilateral space confined between the lip commissure and the vestibular part of visible posterior teeth at smiling. Three different kind of corridors are described: narrow or inexistent, usually associated with wide transverse dimension of the dental arches, intermediate, and wide, usually accompanied by narrow dental arches (Machado, 2014). Aesthetically speaking, intermediate buccal corridors are accepted as the most pleasant, and wide corridors as the most unaesthetic (see Appendix n.2, Fig.4), but literature does not present a consensus regarding that, and the width of those triangular black shadows is not as crucial as other characteristic in smile aesthetic (Alhammadi *et al.*, 2018).

For the majority of smile's aspects, the perception of beauty between laypersons and dental specialist is slightly different, and the professional are able to notice smaller differences, in the case of buccal corridors this different perception seems to be higher, according to a study conducted by Elhyni *et al.* (2016), to modify a determined treatment plan to include corrections of buccal corridors for aesthetic reason is not what the patient need.

#### **2.5 Ideal width-height ratio and tooth-to-tooth proportion**

In a study conducted by Wolfart *et al.* (2005), in a group of individuals (179 dentists, 24 students and 24 patients), two set of pictures, one concerning the width-to-length ratio of central incisors, and the other the tooth-to-tooth proportion between central and lateral incisors, were used. Each set contained a "golden standard proportion" picture, and seven pictures with different standardized changes. It was asked to rate each photo set for attractiveness on a visual analogue scale.

Results showed that no significant differences between the participant groups were found, width-to-length ratio were assed as more attractive between 75% - 85% for students and patients, and 75% - 80% for dentists (see Appendix n.2, Fig.5). The tooth-to-tooth results were respectively 50% - 74% in student and patient's group, and 56% - 68% for dentists (see Appendix n.2, Fig.6). The aim of this study was first to evaluate that there's not a perfect golden standard of 75% for the width-to-height ratio, and 62% for the tooth-to-tooth proportion, and a second hypothesis was about the difference of opinions between dentists and laypeople. The

results showed that, for this research, it was not possible to standardize an absolute golden proportion value, but it appears that a “aesthetic golden range” does exist, and that the different perception of “beauty” between the two groups was not consistent (Wolfard *et al.*, 2005).

## **2.6 Symmetry and perception of beauty**

### **2.6.1 Face symmetry**

In animal kingdom, the perfect right and left symmetry is regarded as an indicator of wellness and high genetic quality, on the other hand asymmetry is a sign of low resistance to diseases and susceptibility to parasites, animal brains are neuronally attuned for the perception of symmetry (Zaidel *et al.*, 2005). In persons, according to this author, the biological situation is different, being present many asymmetries, skeletal and anatomical; the human brain itself shows asymmetry, functionally and anatomically. Functional asymmetries of the face take part in the social relations, and have been reported for emotions, and attractiveness (Zaidel *et al.*, 2005). A recent study (Jiménez-Castellanos, 2016) in a sample of 158 participant, 93 women and 65 men, three parameters were measured: midline deviation, midline inclination and inclination of the occlusal plane.

The results showed that the incidence of alteration with at least one altered parameter that was influencing smile aesthetic in this sample of population from southern Europe was the 51,9%. A study by Kokich *et al.* (2006), reported that a deviation of 4.0mm was not detected as a change in facial aesthetic, anyway his studies were limited on the perioral region and the rest of the face was not part of the general perception. Many researches confirm that a deviation of the midline up to 2.0mm is not noticed as an alteration of the facial beauty, by clinician and as well by laypeople (Jiménez-Castellanos *et al.*, 2016).

### **2.6.2 Dental symmetry**

Regarding the perception of beauty in a smile, here again a close attention has to be paid to the midline, and to the more noble part of the dental arches from an aesthetical point of view: the central incisors. The demand of symmetry between incisal edges, decrease in the mesio-distal direction starting from the midline, assuming that it is much more noticeable between central incisors then in lateral incisors, and even less between lateral incisors and canines (Machado, 2014).

Asymmetries of incisal edges can have different aetiology, in children for intrinsic reasons or usually due to traumatic events, in adults more often because of abrasion, cracks, vertical errors in brackets positioning and so on. Central incisors asymmetries in crown length of 0.5mm are considered more unaesthetic than 1.5mm asymmetries in the gingival margin (Riberio *et al.*, 2017).

## **2.7 Gingival design and exposure**

### **2.7.1 “Pink aesthetics”**

The terms “pink aesthetics” and “red aesthetics” are used to describe the ideal gingival design, where the canine’s gingival margin coincide with central incisors one and the lateral incisors margin should be lightly below this line. In fact, those parameters provide the higher esthetical value (Machado, 2014). A study conducted by Kokich *et al.*, (2006), with the purpose of evaluate the perceptions of dental professionals and laypersons about altered dental aesthetics, showed that gingival margins asymmetries not greater than 1.5mm – 2.0mm between central incisors are unnoticed by laypersons, but the average range of asymmetries felt by dentist and orthodontist was lower, with a peak of 0.5mm by orthodontists (Kokich *et al.*, 2006).

### **2.7.2 Gingival exposure at smiling**

The amount of gingival and teeth exposure during smiling is of paramount importance for the aesthetic, and many studies tried to determine the ideal exposure (Machado, 2014). Câmara, classified the gingival exposure in three categories (see Appendix n.3, Fig.8 and Fig.9), high smile line, medium smile line, and low smile line (Câmara *et al.*, 2010). According to Machado, (2014), when the gums exposure is not greater than 3.0mm is perfectly acceptable, and the smile is considered unaesthetic when more than 3.0mm are visible.

An interesting study carried out by Dutra *et al.*, (2011), had the purpose of evaluating the different aesthetical opinion in gingival exposure between three groups of people, 30 orthodontists, 30 general dentists and 30 laypersons. They were asked to evaluate using a score scale, some photographs manipulated and ranging from 4.0mm of gingival exposure to 4.0mm of upper lip coverage, ranking the smile attractiveness. Two sets were used, one displaying a female subject and the other a male. Results show that all three groups of participants ranked as the most attractive smile in the female set of pictures the one where the upper lip was resting on the gingival margin of the central incisors (0.0mm). On the other hand, regarding the male



set of pictures, laypersons considered the most aesthetic smile as for the female sample, the one with 0.0mm value, while orthodontists and clinicians considered more attractive smile with upper lip resting at the level of the margin (0.0mm) or covering the maxillary incisors till 2.0mm (Dutra *et al.*, 2011).

## **2.8 Presence of anterosuperior diastemas**

Comparing two studies with different categories of participants, a recent research by Alhammadi *et al.* (2018), with a sample of 408 students, equally represented by both gender (51.2% males, 48.8% females), and a second one by Kokich *et al.* (2006), where participant were divided between three categories, (orthodontists, general dentists and laypeople), similar results about the acceptance of maxillary midline spacing were found.

In one hand for Kokich's study, ( $P < .01$ ), up to 2.0mm of diastema was not rated as unattractive for general dentist and laypersons, where a smaller value, 1.0mm - 1.5mm was perceived by orthodontist as preferred limit of aesthetic spacing range. The results of the more recent study by Alhammadi *et al.*, (2018), ( $P < .05$ ), where participants were younger, showed that most of dental students reported as more aesthetical the absence of diastemas, females significantly preferred that then males (see Appendix n.4, Fig.10).

According to Machado, (2014), from a pure orthodontic point of view, all diastemas in the aesthetic zone should be close, because they are not aesthetically acceptable.

## **2.9 Tooth shade**

In the perception of a pleasant and healthy smile, teeth colour plays certainly a central role. A smile that satisfies most of the aesthetic canons of harmony, included in the acceptable range of beauty mentioned before, if it doesn't show uniformity of teeth shades, because of intrinsic reasons like amelogenesis imperfecta, fluorosis, or extrinsic reasons that could be a wrong matching colour of fillings, crowns, veneers and so on, is not perceived aesthetically acceptable. Indeed, teeth colour is a crucial factor regarding smile aesthetic (Gada *et al.*, 2018). The complexity of colour choice during a dental treatment encompasses both objective and subjective phenomena. The skin and gums tone are referred to be a guideline in assessing the proper colour, but this guideline is variable on different cultures and societies, one example can be the exaggerate bright "Hollywood smile".

## **2.10 The frame of the smile: the lips**

Literature affirms that the anteroposterior positioning of the teeth is a key point in assessing lips volume, as well as the inclination of frontal teeth. A correction of deep bite and lower incisors' proclination, significantly improve lip volume, and patient's profile gain a more harmonic and younger look (see Appendix n.4, Fig.11a and Fig.11b). Lip's volume is of great importance in the perception of beauty, indissolubly with the smile, and the trend of having voluminous lips is a current standard of beauty (Machado, 2014). A systematic review about the perception of frontal smile aesthetic by Parrini *et al.*, (2016), confirmed that lips thickness and lower lip distance from the maxillary central incisors significantly affect the aesthetic smile scores. This aspect is not only noticed by orthodontists and dental specialists, but as well by laypersons of different age and socio/educational background (Zawawi *et al.*, 2013).

## **3. Dental therapies aiming to reach higher beautiful standards: an interdisciplinary approach**

### **3.1 The golden "range"**

The concept of beauty is tied to great subjectivity and highly influenced by opinions of others, and cannot be an absolute conception, it varies from culture to culture and to time to time. Literature reports that Lombardi was the first to suggest the application of the golden proportion in dentistry in 1952. He also admits that the application of this formula, for instance applied for determining tooth size was too strong (Murthy *et al.*, 2008).

Anyways, it appears from the literature consulted, that even if it is not correct to look for a precise value, or a mathematical formula that can be applied to every single case, in the other hand does exist an ideal range of parameters, that is statistically recognised, both by laypersons and dental specialist to be the most appreciate from an aesthetical point of view. Indeed, is of paramount importance for the clinician to follow established aesthetic guidelines (Machado *et al.* 2013).

### **3.2 The orthodontic guidance to reach facial harmony**

#### **3.2.1 Cephalometric hints**

Nowadays, orthodontically speaking, two of the fundamental diagnostic reports used as starting point of a case evaluation are the craniofacial lateral X-ray and pictures of the patient. The

diagnostic phase is crucial in assessing the therapy, and the analysis of the in a craniofacial lateral radiography has been studied by many authors. With the discovery of X-Rays in 1895 and the invention of the cephalometer in 1931, it has been possible to execute craniofacial radiography, and orthodontics gained this new diagnostic document, for the treatment planning, growth path prediction etc., and numerous parameters and cephalometric methods have been conceived and proposed from several authors, seeking alternatives to other methods, or trying to fulfil lack of other currents of thought (Silva, 2005).

### **3.2.2 Cephalometric errors**

Above all method of craniofacial lateral radiography reports analysis, a central scepticism is represented by the cephalometric errors, a frequent divergence among cephalometric and clinical analysis of the same patient, showing that the cephalogram does not perfectly reflect the patient's reality. Some of the main random errors are caused by the geometric distortion of measurements, the variability of intracranial guidance and reference planes, the quality of the radiograph that can cause a difficult reading of the structures and the discrepancy between hard and soft tissue (Silva, 2005). To make an example, a study conducted by Grogger *et al.*, (2018), on cephalometric errors showed that the identification of point A, the deepest landmark of the anterior concavity of the maxilla (see Appendix n.5, Fig.12), is the prevalent source of error in a craniofacial lateral radiography analysis, because it is a landmark starting point to trace planes and angles, (SNA, SNB, ANB etc.), and a mistake in identify it, will produce a cascade effect in many other consequent measurements (see Appendix n.5, Fig.13).

### **3.2.3 Achieving facial harmony, geometrical analysis according to AGIHF principles**

The “Individualized Geometrical Analysis of Facial Harmony” (AGIHF), or “Geometrical Analysis”, conceived by Prof. Carlos A. Silva, it's a new concept of diagnosis, derived from frequents observation of disagreement between the clinical and cephalometric diagnosis in the same individual. The crucial and unique starting point of AGIHF method, is based on the “true vertical line”, derived by the PNC, (see Appendix n.6, Fig 14) or Natural Head Posture if translated in English. It consists of tracing a vertical line in front of the face profile, guided by the natural position of the head that we can notice comparing the photograph records and the craniofacial lateral radiography. This method allows to deduce the best shape and position of the facial structures of a patient from other structures of the same patient and not from statistical norms (individualisation).

The result of this strategy of diagnose, following the rules and principles of the method, is the creation of a cephalometric frame that derivates from the individualisation of the proportion of the patient facial structures and the whole analysis, that is divided in four main steps (individualisation phase, descriptive phase, idealisation phase and planning phase) is free of any average standard, but is built around the unicity of each person analysed (see Appendix n.6, Fig.15). In modern orthodontics, this is a unique concept, and as the first general principle say, “the supremacy of soft tissue harmony over the underlying hard structures” is understandable that this method respects the balance and harmonics proportion of the profile first, to evaluate the kind of therapy that the underlying hard structures, bone bases and teeth, need to undergo during the orthodontic treatment (Silva, 2005).

The principle of priority of the harmony of soft tissues over the hard structures is emphasized by the importance of positioning of the upper incisors as a guide for aesthetics and facial expression. In fact, AGIHF method considers the upper incisor dominant and not adaptive as common analysis and his role of guidance is of paramount importance for achieving a harmonic patient’s profile, because upper incisor plane and axis are directly related to the lip height and thickness, a factor that is fundamental for adequate smile aesthetics.

As discussed before, the harmony of facial structure is a fundamental requirement in pursuing the maximum balanced result of the individual appearance, aiming to reach the higher pleasantness compromise of the patient aspect, therefore Geometrical Analysis method could be applied not only in orthodontics therapies, but also in other dental disciplines, for example in prosthetic dentistry when is crucial to assess the upper incisor vertical position and inclination.

### **3.3 Correction of the “gummy smile”**

One of the imperfections highlighted in literature, is the high labial line, or “gummy smile”. Sometimes, even after a successful orthodontic treatment, a prosthetic or surgical therapy, the aesthetic result can be poor, due to intrinsic factors or unsuccessful treatments. Patients that present this unaesthetic feature, can be self-conscious, embarrassed at smiling, and even psychologically affected, so the scope of the cosmetic procedure of reducing excessive gums display, became often a therapeutic procedure (Polo, 2007). There are many surgical and non-surgical treatment options to correct a gummy smile, impaction of the maxilla, gingivectomy, intrusion of maxillary incisors, botulinum toxin injection, lip lengthening surgery and so on

(Dilaver *et al.*, 2017). An example of surgical treatment is the lengthening surgery by V -Y plasty. This procedure consists of a horizontal incision made 3mm upper to the mucogingival junction, extending from the maxillary first premolar to the correspondent of the other side. The submucosal and underlying muscles are dissected subperiosteally, then the vestibular soft tissues are gently pulled labially and sutured, with a vertical component of the Y portion at least 1 cm long (Dilaver *et al.*, 2017).

Between non-surgical methods we find the botulinum toxin injection, which however has temporary effects, that consist in systematic injections in selected pinpoints of the face, corresponding to specific mimic muscles underneath, (see Appendix n.7, Fig.16), preventing them to contract by blocking nerve activity, causing the lift of the upper lip less marked, therefore showing less gingiva (see appendix n.7, Fig.17) while performing facial expression (Polo, 2007).

### **3.4 Teeth shape and colour improvement**

The aspect of teeth is very important in the perception of beauty and harmony during smiling, and several techniques exist to improve situations where, because of colour discrepancy between teeth in the aesthetic zone, disharmony of shape or dimension of teeth, problems connected with hypo-mineralization, amelogenesis imperfecta and so on, compromise the aesthetic appearance.

#### **3.4.1 Dental bleaching**

Dental bleaching is a very conservative, simple, low cost and safe procedure, widely performed by dental practitioner, that allows patients to have their teeth whitened to some degree, depending by many factors (Alam *et al.*, 2017), by the tooth natural colour, quality of enamel and dentine and age of the patient and in the other hand the quality of the product applied and the contact time with teeth. As longer and as higher concentration of bleaching agent, usually hydrogen peroxide or carbamide, the faster the whitening. A common side effect is temporary tooth sensitivity, during and after the treatment up to 24h - 48h. Dental bleaching can be performed as at-home or in-office procedure, and literature reported the effectiveness of both method (Rezende *et al.*, 2015).

### **3.4.2 Aesthetic ceramic veneers**

A prosthetic approach can be one of the therapies in enhancing the aspect of teeth, when the unaesthetic problem is of higher degree than a simple request of tooth colour enhancement and concerns tooth shape, proportion, missing or compromised teeth because of carious lesions, extended filling, fractures, etc. An aesthetic rehabilitation in these terms, is represented by the use of dental veneers or crowns.

In recent times, the demand by patients of enhancing the aspect of their smile increased, conventionally the use of crowns and veneers were indicated for the correction of atypical teeth contour, gum recession, to mask enamel discoloration or to solve minor teeth alignment problems (Maddula *et al.*, 2018). Minimally invasive preparations, and the use of dental veneers, have gained prestige in restorative dentistry because they allow to reach highly aesthetic and durable results, with good preservation of dental tissue. Ceramic materials have proven biocompatibility, with high resistance to wear and staining but in the other hand laboratory procedures, technique and equipment contribute to increase the cost (Janine *et al.*, 2018).

### **3.4.3 Direct composite veneers**

A different strategy of approaching restoration of teeth in the aesthetic zone, is the direct application on prepared tooth surface, or in some cases even without any preparation, an adhesive agent and subsequently composite resin material, in a single visit appointment. This procedure is also less expensive than conventional ceramic crowns and veneers, and it can be a valid alternative in patients with lower economical condition (Korkut *et al.*, 2018).

Among this type of conservative treatments, a common mistake is the tooth shade selection. The natural tooth is polychromatic and is crucial for the dental specialist to pay a lot of attention to this aspect. Colour selection should be done on clean teeth and with the natural humidity of the oral cavity, with a natural light exposure (Nashan *et al.*, 2010).

### **3.5 Lips remodelling using hyaluronic acid injections**

To redefine lips with fillers, frequently hyaluronic acid (HA), is a common procedure but requires expertise. The lip region is an extremely important area when it comes to facial and smile aesthetic enhancement. The aging, photo-damage, hereditary factors, smoking etc. contribute to loss of lip volume, peri-oral rhytids, and prominence of mentolabial folds.

Various fillers, temporary and permanent, have been tried in shaping the lips, with gratifying results.

Worldwide usage and published reports clearly confirm the efficacy and safety of HA fillers. A deflating vermilion (the red part) is the most common complaint, followed by drooping angles of the mouth. These two together complete the picture of a sorry face. Lips that have good volume can be highlighted by defining them and injecting into the white margins (the vermilion border). Typically, the upper lip is treated more often than the lower (Luthra, 2015)

The best approach to lip augmentation depends on the nature of the defect and the subject's aesthetic desires. For genetically thin lips, structural augmentation with a deeper-placed filler followed by volume correction with a superficial filler is ideal. For pure cosmetic enhancement of lips, a superficially placed filler with emphasis on the white roll and expansion of the vermilion can be the choice. Female lips are, on average, a little fuller than male lips. They bulge forward more than male lips – In other words, they are slightly more “pouty.” Female lips are not noticeably bigger when seen by a frontal point of view, but they do bulge forward more as seen from the side. Over volumizing of the male lip can result in feminization of the area (Luthra, 2015).

It is also important to consider the relationship between lip height and incisor shown in the anatomic analysis, to evaluate possible maxillary hypoplasia and protrusion and to consider the patient's occlusion status.

#### **4. Discussion**

Interpreting what discussed above, the several articles and reviews analysed suggest that the features of the dentofacial complex, if ranging within determined parameters, contribute to enhance the perception of beauty and harmony of the smile.

The upper incisor vertical position is universally accepted to be a determining factor to achieve an attractive smile (Machado, 2014), the midline deviation should not exceed 2.0mm (Janson *et al.*, 2011), while a slight tooth angulation is more noticeable than a consistent midline deviation (Janson *et al.*, 2011).

The dominance of maxillary central incisors should be emphasized, their incisal edge should sit below the cuspid tip of canines, giving to the smile arc a convex shape (Camara, 2010, Machado, 2014, Silva, 2005). Ideal width-to-length ratio of incisors should range within 75% and 85% and lateral incisor's dimension should swing proportionally around the 60% of central incisor (Wolfard *et al.*, 2005). Central incisors asymmetries in crown length are considered more unaesthetic than asymmetries in the gingival margin (Ribeiro *et al.*, 2017, Kokich *et al.*, 2006).

The absence of gingival exposure when smiling is perceived as the most balanced one, although it is considered aesthetically acceptable when it does not exceed 3.0mm (Câmara *et al.*, 2010, Machado, 2014, Dutra *et al.*, 2011). Diastemas should be closed and the absence of spacing in the aesthetic zone is reported as the most pleasant (Machado, 2014, Alhammadi *et al.*, 2018, Kokich *et al.* 2006).

Buccal corridors width does not heavily affect smile aspect (Alhammadi *et al.*, 2018, Elhyni *et al.* 2016) while uniformity of teeth shade and colour are a crucial factor in the perception of beauty (Gada *et al.*, 2018).

Lip volume and height are of great importance and their correlation with upper incisors vertical position is crucial in achieving the best individual harmony (Parrini *et al.*, 2016, Zawawi *et al.*, 2013, Silva, 2005).

A universally accepted value concerning beauty has been researched since time immemorial. The unicity of each individual's propensity and the different perception among people of what is beautiful, differ among cultures, societies and historical periods and are continuously flowing: an absolute standard value appears utopian applied to aesthetic. Anyhow, in a scientific discipline as dentistry is, some parameters are proven to be essential guidelines for the achievement of the higher possible level of smile harmony in each human being. We cannot talk of standardised methods and therapies that can fit to every single individual in the same



way, but within the limits imposed by the anatomy of the singular entity, a scientific guidance respecting a “range” of values can be applied to achieve the adequate balance and harmony of a beautiful smile.

The clinician must evaluate what is the best compromise to achieve function and aesthetics for each clinical case and the individualization of the therapy is of paramount importance, considering all the possibilities detected as a “gold standard” in every area of knowledge, some of them previously discussed in this work.

## **5. Conclusion**

According to the bibliography consulted, the smile is of paramount importance when judging the harmony of the face and some features seem to be perceived as beautiful if ranging between determined parameters.

There is a common thinking about the dominance of maxillary incisors when smiling and their vertical position is also directly related to lip height and volume; lips aspect plays a primary role in defining the beauty of the smile and it seems that their appearance doesn't derivate only by the individual anatomical characteristics.

The gingival display should not exceed 3.0mm and a convex dental arc appears to be the most pleasant; it looks that a midline deviation bigger then 2.0mm is noticed as unpleasant and it is recommended the absence of spacing between teeth, while a golden standard range seems to be applicable in determining proper dental proportions.

It seems that the buccal corridors width does not interfere heavily the perception of a beautiful smile, in the other hand the uniformity of teeth shade and colour appears to be a fundamental aspect.

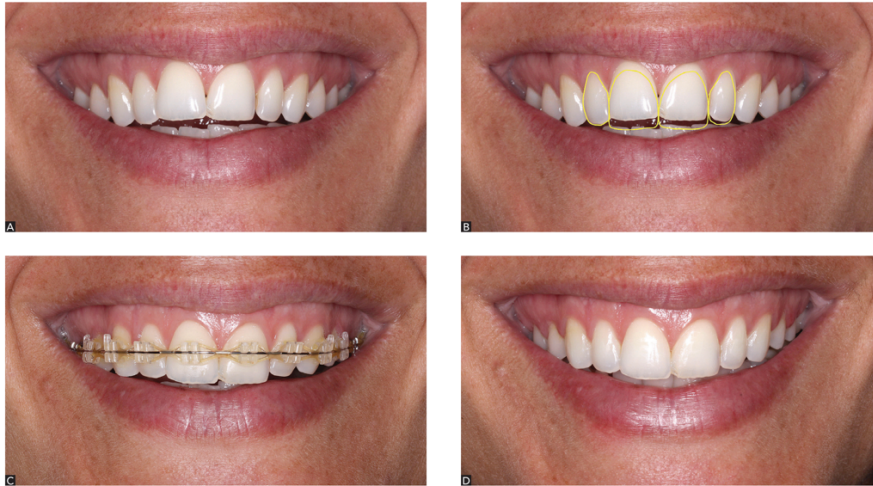The correction of anomalies of the dentofacial complex comprises several treatment options, literature consulted suggest several therapeutic ways. The approach can be orthodontic, for example following the principles of AGHIF method, surgical or non-invasive with the use of botulin toxin in case of gummy smile correction, and several strategies in the teeth colour correction seem to be effective: from dental bleaching to a prosthetic rehabilitation using aesthetic veneers. Lips position appears to be crucial in the perception of a beautiful smile and is a common thinking that the upper incisors vertical position shapes their appearance; some authors suggest that the use of aesthetic medicine treatments as HA injections might improve perioral region aspect at smiling.

## **Bibliography**

- Alam, M. K. *et al.* (2017). Multi-disciplinary approach of bleaching: Clinical note, *International Medical Journal*, 24(1), pp. 154–156.
- Alhammadi, M. S. *et al.* (2018). Perception of facial, dental, and smile esthetics by dental students, *Journal of Esthetic and Restorative Dentistry*, (April), pp. 1–12.
- Azodo CC, O. O. (2018). The influence of gingival exposure on smile attractiveness, *Ibom Medical Journal*, 11(1), pp. 38–44.
- Betrine Ribeiro, J., Alecrim Figueiredo, B. and Wilson Machado, A. (2017). Does the presence of unilateral maxillary incisor edge asymmetries influence the perception of smile esthetics?, *Journal of Esthetic and Restorative Dentistry*, 29(4), pp. 291–297.
- Câmara, C. A. (2010). Aesthetics in Orthodontics: Six horizontal smile lines, *Dental Press J Orthod*, 15(1), pp. 118–131.
- Dilaver, E. and Uckan, S. (2018). Effect of V–Y plasty on lip lengthening and treatment of gummy smile, *International Journal of Oral and Maxillofacial Surgery*. International Association of Oral and Maxillofacial Surgery, 47(2), pp. 184–187.
- Dutra, M. B. *et al.* (2011). Influence of gingival exposure on the smile esthetics, *Dental Press Journal of Orthodontics*, 16(5), 111–8.
- Elhiny, O. A. and Harhash, A. Y. (2016). Buccal corridors: A fact or a myth in the eyes of laymen? , *Macedonian Journal of Medical Sciences*, 4(4), pp. 700–704.
- Gada, S. *et al.* (2018). Perception of esthetic smile based on the evaluation of relationship between skin tone and tooth shade in esthetics, 10(8), pp. 1499–1505.
- Grogger, P. *et al.* (2018). Identification of “Point A” as the prevalent source of error in cephalometric analysis of lateral radiographs, *International Journal of Oral and Maxillofacial Surgery*. International Association of Oral and Maxillofacial Surgery, 47(10), pp. 1322–1329.
- Janine, A. *et al.* (2018). Dental ceramic laminates: current approach for rehabilitation, *Brazilian Journal of Surgery and Clinical Research – BJSCR*, 23, pp. 97–100.
- Janson, G. *et al.* (2011). Influence of orthodontic treatment, midline position, buccal corridor and smile arc on smile attractiveness, *Angle Orthodontist*, Vol 81, No 1. 81:153–161.
- Jiménez-Castellanos, E. *et al.* (2016). Prevalence of alterations in the characteristics of smile symmetry in an adult population from southern Europe, *Journal of Prosthetic Dentistry*. Editorial Council for the Journal of Prosthetic Dentistry, 115(6), pp. 736–740.
- Kina, S. *et al.* (2009). Fondamenti di estetica. In: Kina, S. e Bruguera, A. (Eds.) *Invisibile, restauri estetici in ceramica*. Piccin Nuova Libreria S.p.A, Padova, p.15.
- Kokich, V. O., Kokich, V. G. and Kiyak, H. A. (2006). Perceptions of dental professionals and laypersons to altered dental esthetics: Asymmetric and symmetric situations, *American Journal of Orthodontics and Dentofacial Orthopedics*, 130(2), pp. 141–151.

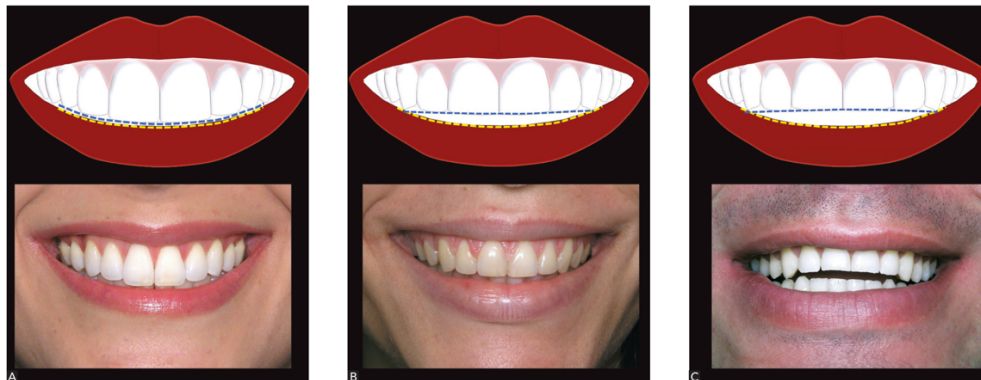- Korkut, B. (2018). Smile makeover with direct composite veneers: A two-year follow-up report, *Journal of Dental Research, Dental Clinics, Dental Prospects*, 12(2), pp. 146–151.
- Luthra, A. (2015). Shaping Lips with Fillers, *Journal of Cutaneous and Aesthetic Surgery*, 8(3), pp. 139–142.
- Machado, A. W. *et al.* (2013). Influence of the vertical position of maxillary central incisors on the perception of smile esthetics among orthodontists and laypersons, *Journal of Esthetic and Restorative Dentistry*, 25(6), pp. 392–401.
- Machado, A. W. (2014). 10 Commandments of Smile Esthetics, *Dental Press Journal of Orthodontics*, 19(4), pp. 136–157.
- Maddula, R. T. *et al.* (2018). Case Report Smile rejuvenation by veneers, 10(9), pp. 1641–1645.
- Nahsan, F. P. S. *et al.* (2012). Clinical strategies for esthetic excellence in anterior tooth restorations: understanding color and composite resin selection, *Journal of Applied Oral Science*, 20(2), pp. 151–156.
- Parrini, S. *et al.* (2016). Laypeople’s perceptions of frontal smile esthetics: A systematic review, *American Journal of Orthodontics and Dentofacial Orthopedics*, 150(5), pp. 740–750.
- Polo, M. (2008). Botulinum toxin type A (Botox) for the neuromuscular correction of excessive gingival display on smiling (gummy smile), *American Journal of Orthodontics and Dentofacial Orthopedics*, 133(2), pp. 195–203.
- Rezende, M. *et al.* (2016). Predictive factors on the efficacy and risk/intensity of tooth sensitivity of dental bleaching: A multi regression and logistic analysis, *Journal of Dentistry*. Elsevier Ltd, 45, pp. 1–6.
- Silva, C. A. (2005a). The distortion in conventional cephalometry. *In: Silva, C. A. (Eds.) Geometric analysis – Technique Manual and Tracing Method*. WFormo Design Publicidade e Comunicacao, Lda, Porto, pp. 5-6.
- Silva, C. A. (2005b). The principles behind AGHIF. *In: Silva, C. A. (Eds.) Geometric analysis – Technique Manual and Tracing Method*. WFormo Design Publicidade e Comunicacao, Lda, Porto, pp. 7-8.
- Silva, C. A. (2005c). The AGIHF and the registries in the Natural Head Position (PNC). *In: Silva, C. A. (Eds.) Geometric analysis – Technique Manual and Tracing Method*. WFormo Design Publicidade e Comunicacao, Lda, Porto, pp. 19-31
- Silva, C. A. (2005d). The phases and the layout of the AGHIF. *In: Silva, C. A. (Eds.) Geometric analysis – Technique Manual and Tracing Method*. WFormo Design Publicidade e Comunicacao, Lda, Porto, pp. 33-34.
- Wolfart, S. *et al.* (2005). Assessment of dental appearance following changes in incisor proportions, *European Journal of Oral Sciences*, 113(2), pp. 159–165.
- Zaidel, D. W. and Cohen, J. A. (2005). The face, beauty, and symmetry: Perceiving asymmetry in beautiful faces, *International Journal of Neuroscience*, 115(8), pp. 1165–1173.
- Zawawi, K. H. *et al.* (2013). Effect of lip position and gingival display on smile and esthetics as perceived by college students with different educational backgrounds, *Clinical, Cosmetic and Investigational Dentistry*, 5, pp. 77–80.

Appendix n.1

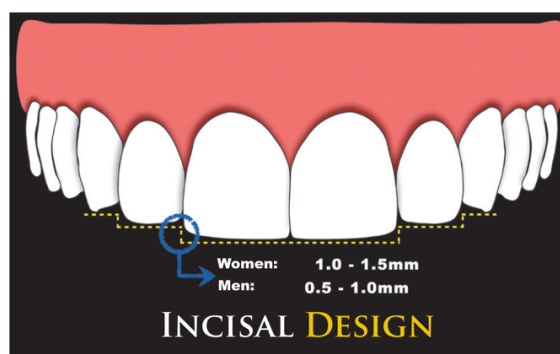


**Fig.1** - The aesthetic impact of changes in vertical positioning of incisors at smiling.

A) Initial situation showing inverted smile arc; B) Illustration of the final incisors positioning; C) Alignment and levelling with fixed orthodontic appliance; D) Final result; (Machado, 2014).

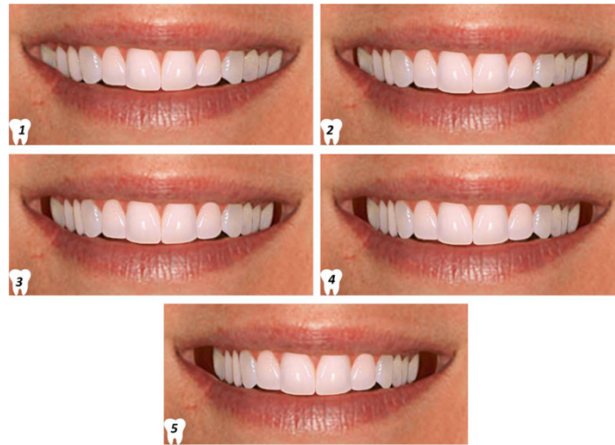

**Fig.2** - Types of smile arc: A) convex; B) plane; C) inverted, (Machado, 2014).

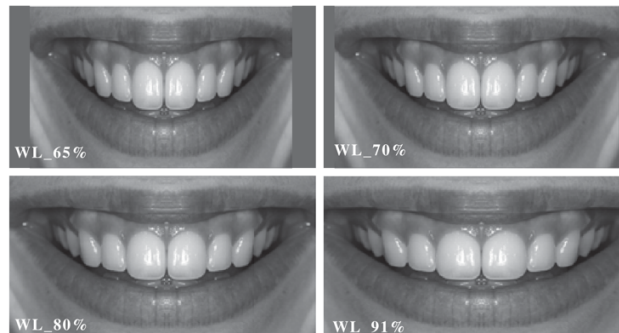


**Fig.3** - Ideal incisal design in the aesthetic zone, (Machado, 2014).

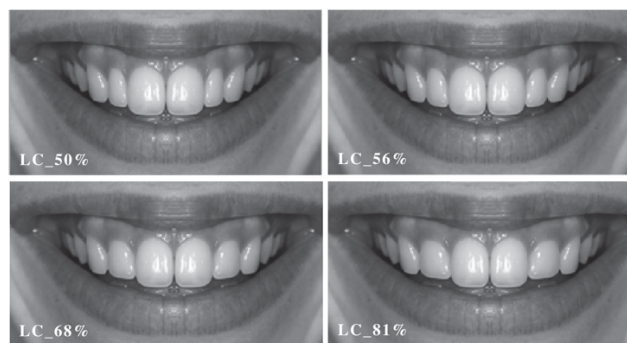
Appendix n.2



**Fig.4** – Different aspect of buccal corridors due to computer manipulation, with the corresponding percentage value of width in comparison to the total smile broadness (between right and left labial commissures): 1) obliterated buccal corridors, 3%; 2) narrow buccal corridors, 10%; 3) normal buccal corridors, 15%; 4) wide buccal corridors, 22%; 5) very wide buccal corridors, 28% (Alhammadi *et al.*, 2018).

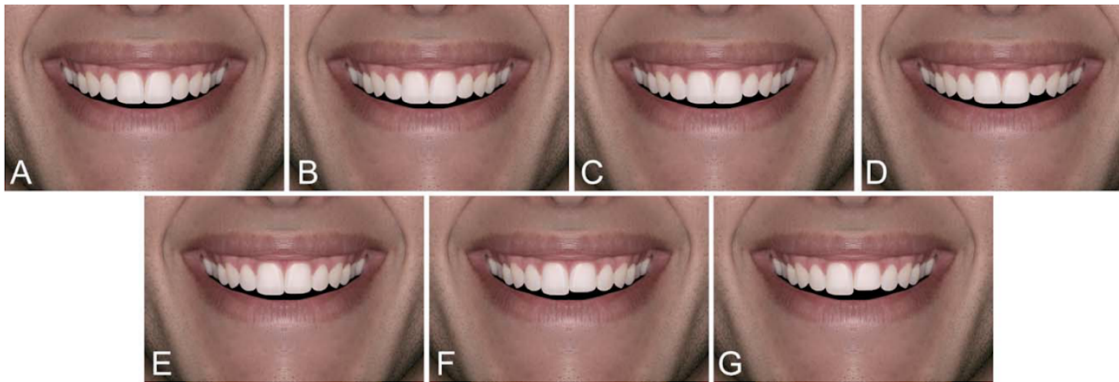


**Fig.5** – Four examples of standardized W-L variations by using image-manipulation software (Wolfard *et al.*, 2005).

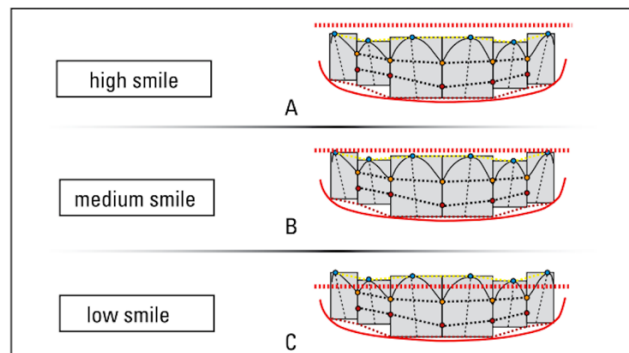


**Fig.6** – Four examples of standardized LC variations by using image-manipulation software (Wolfard *et al.*, 2005).

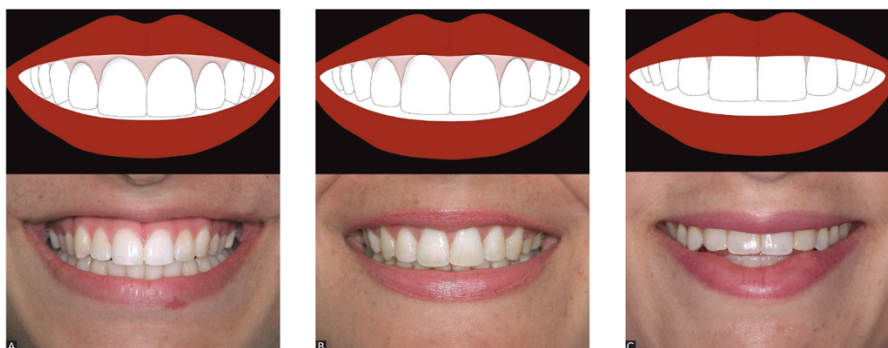Appendix n.3



**Fig.7** – Tooth wear in 0.5mm increments: A) control; B) 0.5mm left lateral incisor wear; C) 1.0mm left lateral incisor wear; D) 1.5mm left lateral incisor wear; E) 0.5mm left central incisor wear; F) 1.0mm left lateral incisor wear; G) 1.5mm left central incisor wear, (Ribeiro *et al.*, 2017).

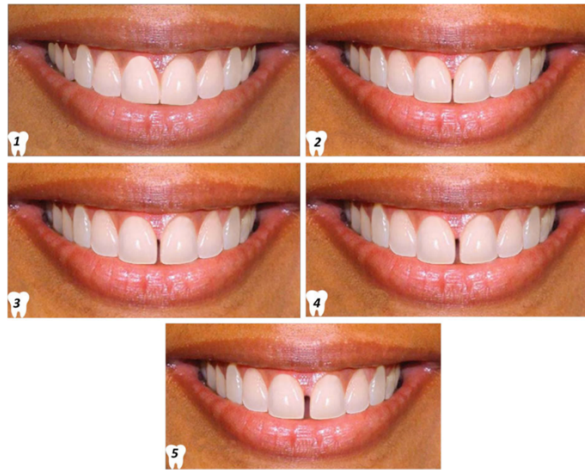


**Fig.8** – Classification of the gingival exposure (Camara *et al.*, 2010).

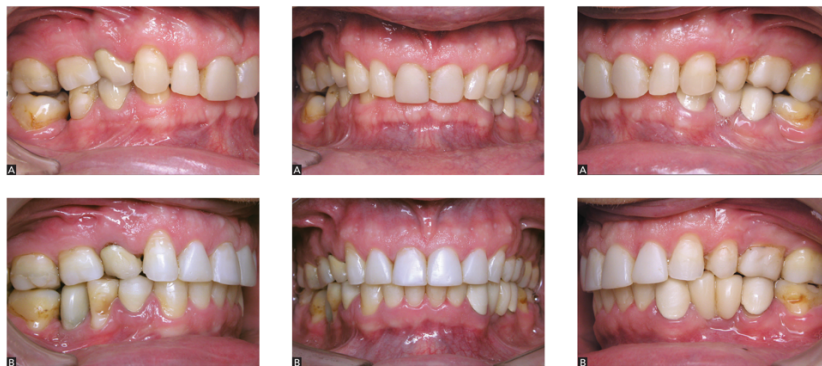

**Fig.9** – A) high smile line, characterized by full length exposure of upper arch clinical crowns and continuous strip of gingival tissue; B) medium smile line, with exposure of 75% - 100% of upper arch clinical crowns and interdental or interproximal papillae; C) low smile line featuring a clinical crowns exposure not greater than 75% and no gingival display (Machado, 2014).

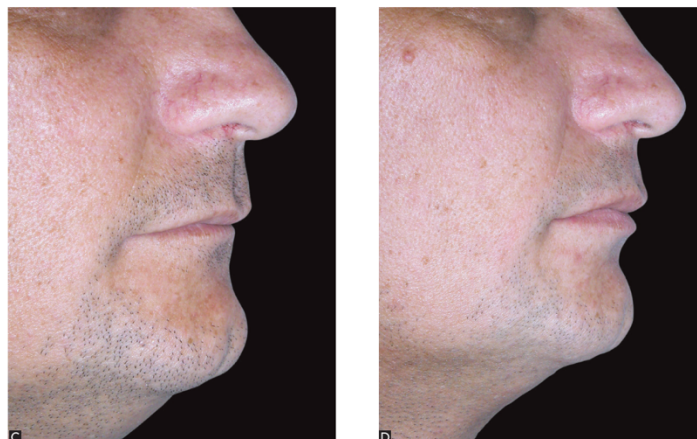Appendix n.4



**Fig.10** – Manipulation of maxillary midline diastema, increased by 0.5mm for each step; 1) 0.0mm; 2) 0.5mm; 3) 1.0mm; 4) 1.5mm; 5) 2.0mm (Alhammadi *et al.*, 2018).

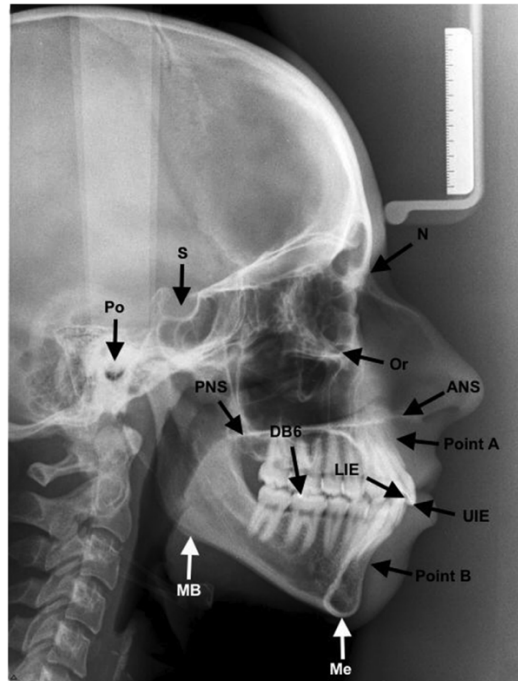


**Fig.11a** – Orthodontic correction of deep bite and maxillary incisors proclination, A - before and B - after (Machado, 2014).

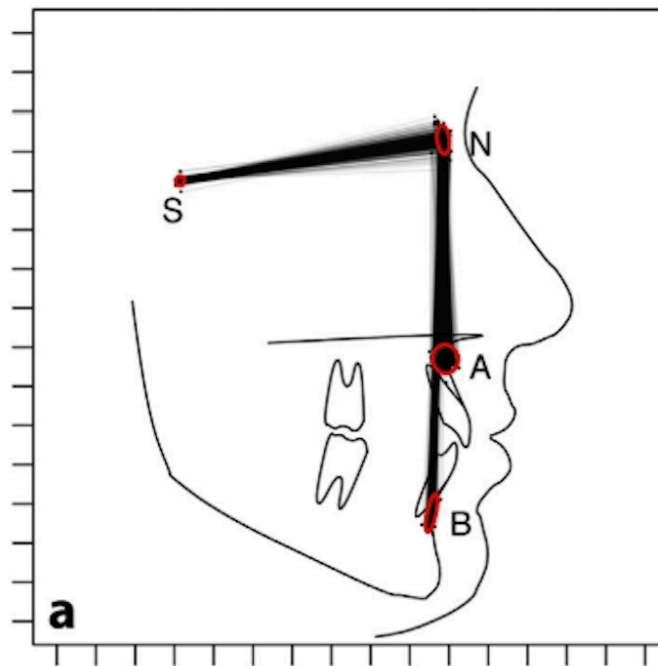


**Fig.11b** – Same patient as in Fig.11a, before (C) and after (D) orthodontic treatment; lips volume improved and patient's profile gained a younger and more harmonic aspect (Machado, 2014).

Appendix n.5



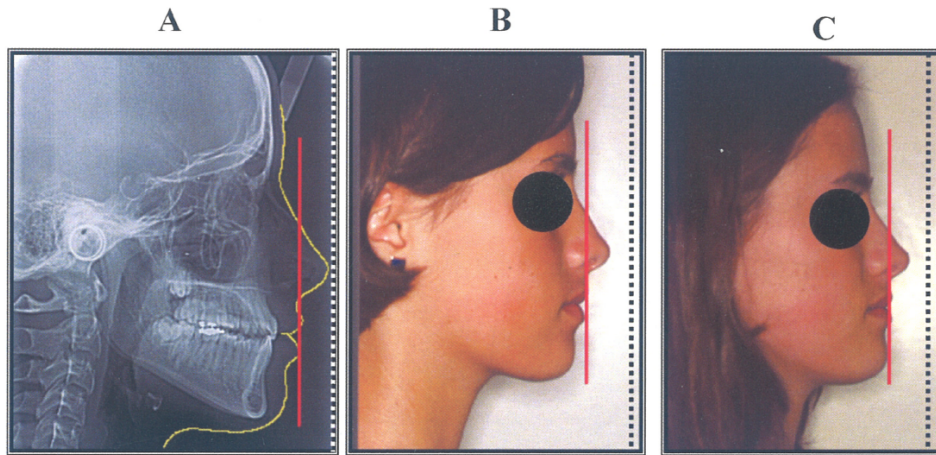
**Fig.12** – Lateral X-ray representing the major skeletal landmarks used in cephalometric analysis. Sella (S), Nasion (N), Point A (A), Point B (B), Distobuccal Cusp of First Lower Molar (DB6), Upper Incisor Edge (UIE), Lower Incisor Edge (LIE), Porion (Po), Orbitale (Or), Anterior Nasal Spine (ANS), Posterior Nasal Spine (PNS), Mandibular Base Point (MB) and Menton (Me), (Grogger *et al.*, 2018).



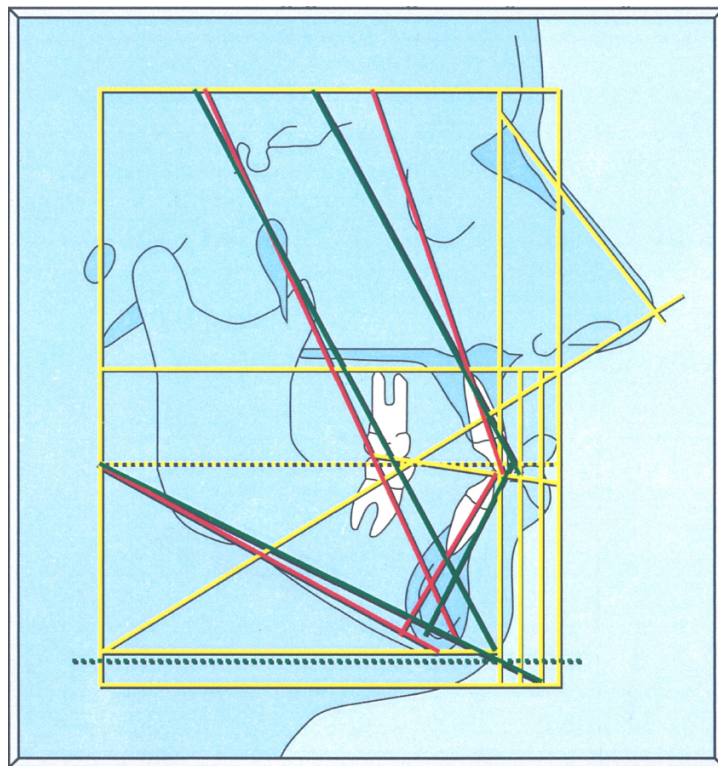
**Fig.13** – Error plot of Sella (S) – Nasion (N) – Point A (A) and Sella (S) – Nasion (N) – Point B (B), (Grogger *et al.*, 2018).



Appendix n.6

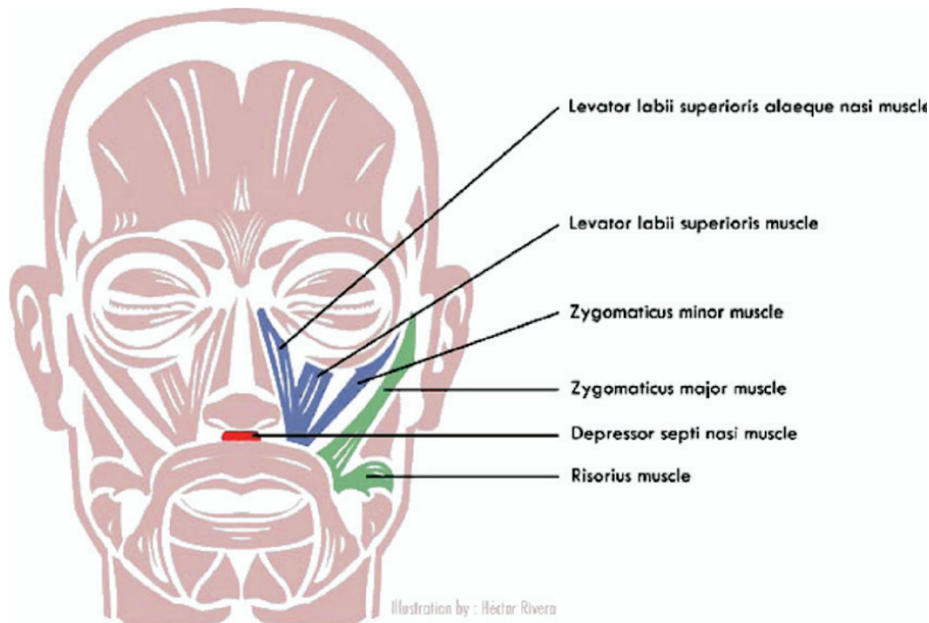


**Fig.14** – Natural Head Posture: in figures A and B is evident the concordance, where in figure C even by simple visual inspection the head extension is noticed, thereby it is clearly discordant (in “Geometrical Analysis, Technique Manual and Tracing Method”, under permission of the author, Silva 2005).

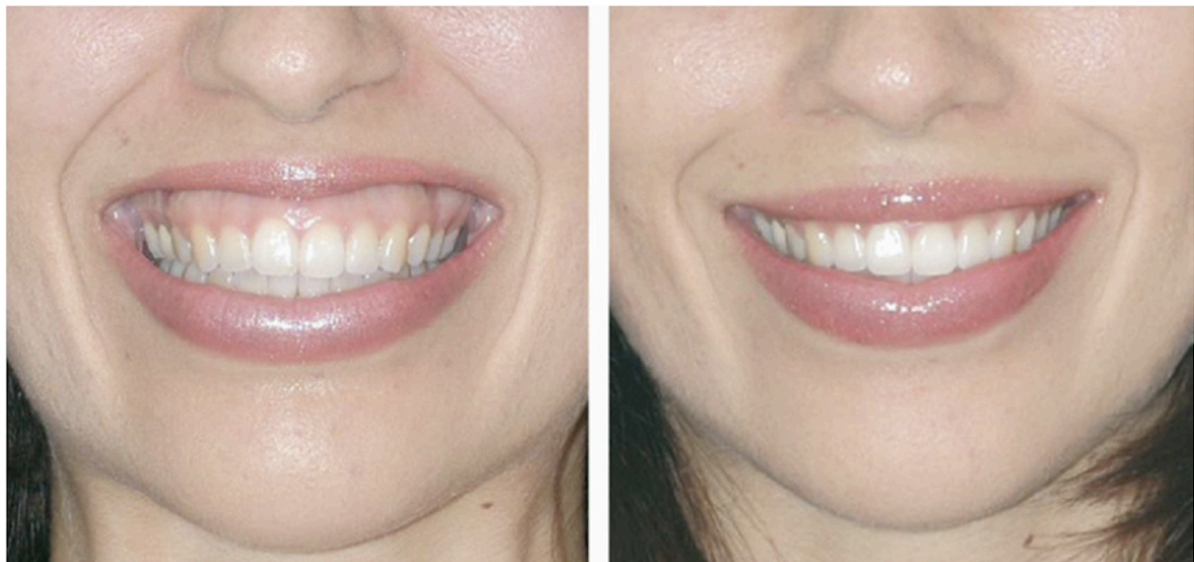

**Fig.15** – AGHIF: Individualized frame construction (yellow), Descriptive phase (red) and Idealization phase (green), (in “Geometrical Analysis, Technique Manual and Tracing Method”, under permission of the author, Silva 2005).

**Appendix n.7**



**Fig.16** – Muscles of the face: pinpointing sites for botulinum toxin injections for “gummy smile” correction (Polo, 2008).



**Fig.17** – The same patient before and after botulinum toxin injection (Polo, 2008).