

CASE REPORT

Open Access

First report of a Chinese strain of coxsackie B3 virus infection in a newborn in Germany in 2011: a case report

Sebastian Ronellenfisch¹, Julia Tabatabai², Sindy Böttcher³, Sabine Diedrich³, David Frommhold¹, Susanne Schubert-Bast⁴, Johannes Poeschl¹ and Paul Schnitzler^{2*}

Abstract

Introduction: Enteroviruses commonly encounter babies and children and infections present in a wide variety of symptoms ranging from asymptomatic infection, benign illness, and aseptic meningitis, hand-foot-and-mouth disease to severe life-threatening disease. Some newborns develop severe disease in the first 2 weeks of life and long-term sequelae may occur among survivors.

Case presentation: We present a case report of a Caucasian newborn baby boy with severe encephalitis and systemic coxsackievirus B3 infection. The coincidence of maternal infection as well as previous mild respiratory illness in his sister suggests either prenatal or horizontal postnatal transmission. An electroencephalogram showed a severe pathologic pattern with theta-delta-rhythm and spike-wave complexes on both hemispheres. We also observed an unusual prolonged viremia for a period of 6 weeks. Due to the lack of specific antiviral treatment options, the supportive management included ventilation and medical treatment of seizures. Phylogenetic analysis revealed a genogroup D2 virus previously exclusively detected in China and now described in Europe for the first time.

Conclusions: Enteroviral infection is an important differential diagnosis in neonatal encephalitis. Prolonged viremia must be taken into account and might correlate with disease severity. The newly observed enterovirus genotype D2 is spreading from Asia to other continents.

Keywords: Coxsackievirus B3, Enterovirus, PCR, Viremia

Introduction

Enteroviruses commonly infect children, with syndromes ranging from asymptomatic infection and benign illness, aseptic meningitis, to severe life-threatening disease [1]. Some newborns develop severe disease in the first 2 weeks of life and long-term sequelae may occur among survivors. Risk factors and clinical features associated with severe disease involve early onset of illness within the first few days of life [2]. Enteroviruses include more than 260 different types of pathogens including polioviruses, echoviruses, coxsackieviruses and rhinoviruses. Illness encompasses a wide spectrum of symptoms from mild fever to upper respiratory tract infections, rash, aseptic meningitis, severe

myocarditis, encephalitis, and paralytic disorders. Enteroviruses are transmitted primarily via a fecal-oral route and respiratory aerosols [3]. Coxsackie A viruses have been associated with mild clinical symptoms such as flu-like illness and meningitis and hand-foot-and-mouth disease. By contrast, coxsackie B viruses may cause pancreatitis, hepatitis, aseptic meningitis, myocarditis/pericarditis, and type 1 diabetes as well as neonatal sepsis [4-6]. In 2006, six neonates with enteroviral meningoencephalitis were described [7]. Five babies presented with prolonged seizures, and one presented with systemic enteroviral disease. Cranial ultrasonography showed increased echogenicity in the periventricular white matter, and magnetic resonance imaging (MRI) confirmed mild to severe white matter damage in all babies. Recent case reports describe a full-term neonate with coxsackie B2 infection presenting with meningoencephalitis with seizures, and lesions in the

* Correspondence: Paul.Schnitzler@med.uni-heidelberg.de

²Department of Infectious Diseases, Virology, University of Heidelberg, Heidelberg, Germany

Full list of author information is available at the end of the article

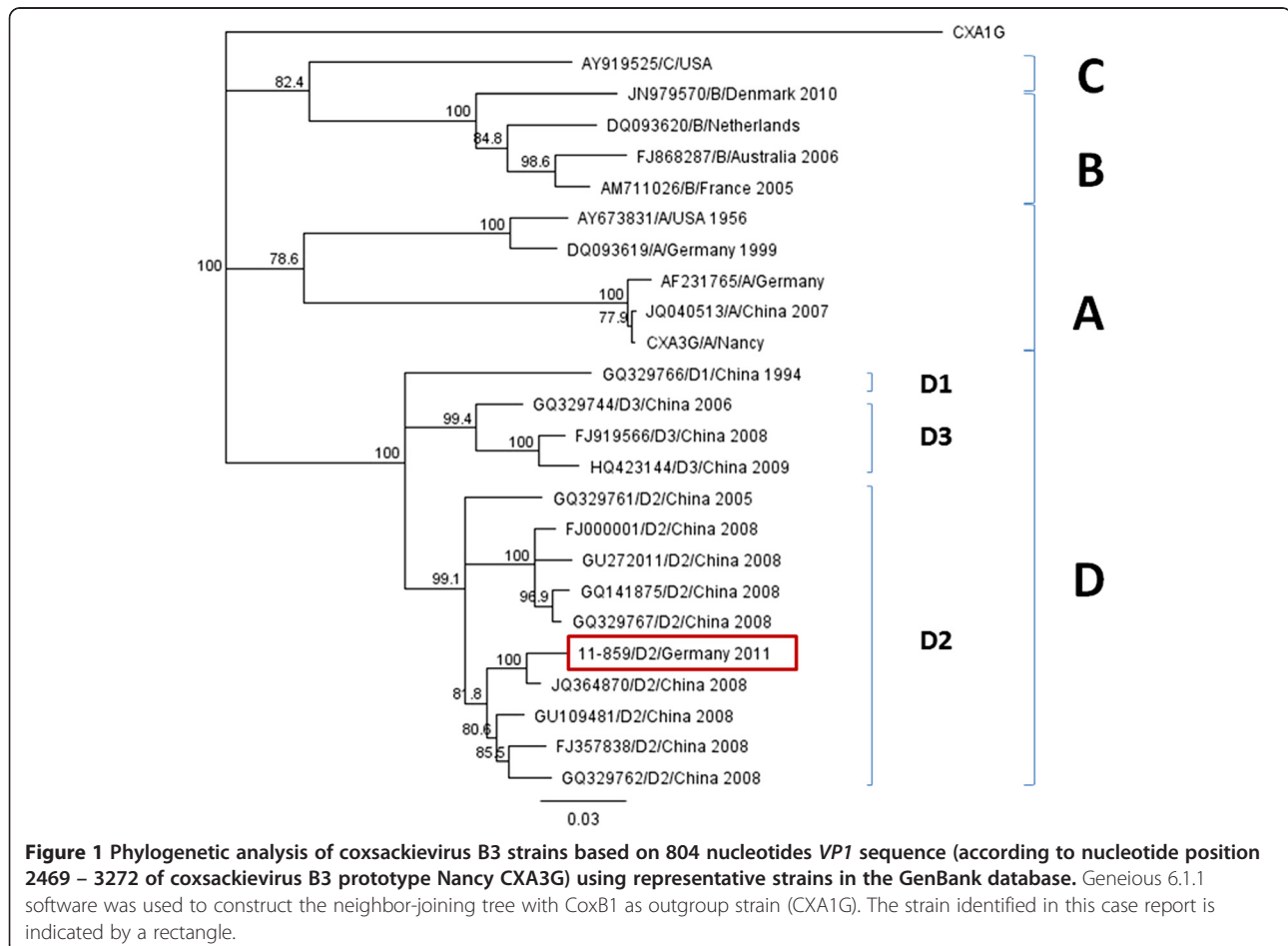
white matter, and a fatal case of newborn coxsackie B1 virus infection with apnoeic episodes and desaturations [8,9]. In these cases, an electroencephalogram (EEG) revealed multifocal epileptiform discharges, and a cranial MRI showed multiple lesions, respectively.

Case presentation

We report here a full-term Caucasian newborn boy, who was delivered by Caesarean section at 38 weeks of gestation in 2011. Within the last weeks of a previously unremarkable pregnancy, his mother showed signs of infection. His 2-year-old sister presented with a common cold within the week of his birth. On the first day postpartum he showed a macular exanthema on his trunk and face. On day 5 postpartum, he showed a decline in his general condition and phases of severe apnea. Hence, he was admitted to a neonatal intensive care unit. Positive airway pressure ventilation was performed for a period of 24 hours followed by spontaneous breathing of the neonate. Broad spectrum antibiotic therapy including gentamicin and ampicillin was started.

In the course of treatment, he showed signs of partial seizures and an EEG performed on day 7 postpartum

indicated a severe pathologic pattern with theta-delta-rhythm and spike-wave complexes on both hemispheres. An intermittent burst-suppression pattern was detected in slow sleep and levetiracetam therapy was initiated. Follow-up EEGs continued to show multifocal spike-wave complexes and burst-suppression. A neurological examination showed a severe muscle hypotonia but no signs of focal neurological deficits. A cardiorespirogram revealed central apnea with desaturations and bradycardias. Due to the clinical picture of encephalitis, a lumbar puncture was performed, showing an elevation of his cell count (29 leucocytes/ μ L) and protein level (1140g/L). Cerebrospinal fluid (CSF) bacterial cultures were sterile and antibiotic treatment was stopped accordingly. Epstein-Barr virus and herpes simplex virus were not detected in his CSF, but enterovirus ribonucleic acid (RNA) was positive by polymerase chain reaction (PCR). The genetic relationship of the virus was revealed by sequencing the *VP1* gene. This analysis showed that this virus isolate is closely related to coxsackievirus B3 (CV-B3) detected in China in 2008 and belonged to D2 genogroup (Figure 1). The accession number of our isolate 11-859-10 is KJ400861. Retrospectively, all available blood and urine samples were



analyzed for enterovirus RNA. In two urine samples and in several serum samples up to week 6 postpartum, enterovirus RNA was still detectable indicating a generalized enterovirus infection with prolonged viremia.

The patient's seizures ceased rapidly after initiation of levetiracetam medication. A cranial MRI on day 5 revealed a deficiency of white matter with subsequent ventriculomegaly which decreased but was still observed in a follow-up MRI at the age of 3 months. During the further course of treatment anti-convulsive therapy could be stopped since the following EEGs revealed a gradual improvement with cessation of epilepsy typical potentials. Nevertheless, he still showed muscle hypotonia at the age of 1 year.

Discussion

Perinatal acquired enterovirus infections may lead to severe disease such as meningitis or encephalitis. Recently, two cases of neonatal enterovirus meningitis were reported and etiologically the parents probably transmitted the infection during rooming-in [10]. Severe disease has been described with infection in the first 2 weeks of life and preceding maternal illness peripartum [11]. In the case presented here, maternal infection as well as previous mild respiratory illness in the neonate's sister preceding the baby's disease indicates either prenatal or horizontal postnatal transmission.

Central nervous system disease in babies can cause significant long-term morbidity including cerebral palsy and seizures [2,12]. Hypoxia or circulatory compromise as cause for the baby's neurological state could be excluded as no prolonged hypoxic episodes occurred and myocarditis was not present. Immunoglobulin has been used as a therapeutic agent for neonates; however, clinical efficacy has not been proven. Specific antiviral therapy is not available. Therefore, treatment is supportive and tailored to organ dysfunction including ventilation and medical treatment of seizures [13].

Whereas the diagnosis of enterovirus infection is traditionally performed by viral isolation in cell culture, PCR has been demonstrated to be highly sensitive, specific and rapid [14-16]. We observed an unusual prolonged viremia for a period of 6 weeks, whereas viremia usually lasts only for a few days [17]. Duration and level of detectable viral RNA in blood specimens are positively correlated with disease severity [11]. Most variable regions of the enterovirus genome are within the gene coding for the capsid protein VP1. In 2008, an outbreak of aseptic meningitis due to coxsackie B3 virus genogroup D2 was described for Shandong Province in China [18]. Phylogenetic analysis revealed that the CV-B3 identified in the presented case is closely related to the Chinese outbreak strain and has so far not been reported in Europe.

Conclusions

Enterovirus infections are of clinical relevance during the neonatal period. In particular, in the typical season, enteroviral infections may be an important differential diagnosis in neonatal encephalitis. We report a newborn presenting with encephalitis and systemic coxsackie B3 virus infection. In addition to the CSE, viral RNA was also detectable in urine and serum samples. The isolated virus is closely related genetically to an enterovirus type previously unique to Eastern China and is now spreading from Asia to Europe.

Consent

Written informed consent was obtained from the patient's parents. A copy of the written consent is available for review by the Editor-in-Chief of this journal.

Abbreviations

CSF: Cerebrospinal fluid; CV-B3: Coxsackievirus B3; EEG: Electroencephalogram; MRI: Magnetic resonance imaging; PCR: Polymerase chain reaction; RNA: Ribonucleic acid.

Competing interests

The authors declare that they have no competing interests.

Authors' contributions

SR, DF, SSB and JP analyzed and interpreted the patient data regarding enterovirus infection. SB and SD performed sequence analysis and sequence comparison. SR, JT and PS wrote the manuscript. All authors read and approved the final manuscript.

Acknowledgements

We would like to thank B. Lenz for excellent technical assistance and C. Gesell for valuable support.

Author details

¹Division of Neonatology, Department of Pediatrics, University of Heidelberg, Heidelberg, Germany. ²Department of Infectious Diseases, Virology, University of Heidelberg, Heidelberg, Germany. ³National Reference Centre for Poliomyelitis and Enteroviruses, Robert Koch Institute, Berlin, Germany. ⁴Division of Pediatric Neurology, Department of Pediatrics, University of Heidelberg, Heidelberg, Germany.

Received: 2 August 2013 Accepted: 3 March 2014

Published: 27 May 2014

References

1. Zaoutis T, Klein JD: **Enterovirus infections.** *Pediatr Rev* 1998, **19**:183-191.
2. Abzug MJ: **Presentation, diagnosis, and management of enterovirus infections in neonates.** *Paediatr Drugs* 2004, **6**:1-10.
3. Pallansch MR, Oberste MS, Whitton JL: **Polioviruses, coxsackieviruses, echoviruses, and newer enteroviruses.** *Fields Virology* 2013, **6**:490-530.
4. Rotbart HA, Brennan PJ, Fife KH, Romero JR, Griffin JA, McKinlay MA, Hayden FG: **Enterovirus meningitis in adults.** *Clin Infect Dis* 1998, **27**:896-898.
5. Oikarinen S, Martiskainen M, Tauriainen S, Huhtala H, Ilonen J, Veijola R, Simell O, Knip M, Hyöty H: **Enterovirus RNA in blood is linked to the development of type 1 diabetes.** *Diabetes* 2011, **60**:276-279.
6. Fuschino ME, Lamson DM, Rush K, Carbone LS, Taff ML, Hua Z, Landi K, St. George K: **Detection of coxsackievirus A10 in multiple tissues of a fatal infant sepsis case.** *J Clin Virol* 2012, **53**:259-261.
7. Verboon-Maciolek MA, Groenendaal F, Cowan F, Govaert P, van Loon AM, de Vries L S: **White matter damage in neonatal enterovirus meningoencephalitis.** *Neurology* 2006, **66**:1267-1269.
8. Hirata O, Ishikawa N, Mizoguchi Y, Nakamura K, Kobayashi M: **A case of neonatal coxsackie B2 meningo-encephalitis in which serial magnetic resonance imaging findings reveal the development of lesions.** *Neuropediatrics* 2011, **42**:156-158.

9. Brecht M, Jyoti R, McGuire W, Chauhan M: A case of neonatal coxsackie B virus brainstem encephalitis. *J Paediatr Child Health* 2010, **46**:699–701.
10. Groneck P, Jahn P, Schuler-Lüttmann S, Beyrer K: Neonatal enterovirus meningitis: transmission via parents during rooming-in and current epidemiology in Germany. *Z Geburtsh Neonatol* 2011, **215**:1–5.
11. Yen M-H, Tsao K-C, Huang Y-C, Huang C-G, Huang Y-L, Lin R, Chang M-L, Huang C-C, Yan D-C, Lin T-Y: Viral load in blood is correlated with disease severity of neonatal coxsackievirus B3 infection: early diagnosis and predicting disease severity is possible in severe neonatal enterovirus infection. *Clin Infect Dis* 2007, **44**:e78–e81.
12. Kaplan MH, Klein SW, McPhee J, Harper RG: Group B coxsackie virus infections in infants younger than three months of age: a serious childhood illness. *Rev Infect Dis* 1983, **5**:1019–1032.
13. Bryant PA, Tingay D, Dargaville PA, Starr M, Curtis N: Neonatal coxsackie B virus infection – a treatable disease? *Eur J Pediatr* 2004, **163**:223–228.
14. Diedrich S, Schreier E: Aseptic meningitis in Germany associated with echovirus type 13. *BMC Infect Dis* 2001, **1**:14.
15. McWilliam Leitch EC, Harvala H, Robertson I, Ubillos I, Templeton K, Simmonds P: Direct identification of human enterovirus serotypes in cerebrospinal fluid by amplification and sequencing of the VP1 region. *J Clin Virol* 2009, **44**:119–124.
16. Reinheimer C, Rabenau H, Berger A, Doerr HW: Diagnostic of neurotropic enteroviruses in children with CSF and/or stool: virus isolation by cell culture or PCR? *Klin Padiatr* 2011, **223**:221–226.
17. Mueller S, Wimmer E, Cello J: Poliovirus and poliomyelitis: A tale of guts, brains, and an accidental event. *Virus Res* 2005, **111**:175–193.
18. Tao Z, Song Y, Li Y, Liu Y, Jiang P, Lin X, Liu G, Song L, Wang H, Xu A: Coxsackievirus B3, Shandong province, China, 1990–2010. *Emerg Infect Dis* 2012, **18**:1865–1867.

doi:10.1186/1752-1947-8-164

Cite this article as: Ronellenfitsch *et al.*: First report of a Chinese strain of coxsackie B3 virus infection in a newborn in Germany in 2011: a case report. *Journal of Medical Case Reports* 2014 **8**:164.

Submit your next manuscript to BioMed Central
and take full advantage of:

- Convenient online submission
- Thorough peer review
- No space constraints or color figure charges
- Immediate publication on acceptance
- Inclusion in PubMed, CAS, Scopus and Google Scholar
- Research which is freely available for redistribution

Submit your manuscript at
www.biomedcentral.com/submit

