

# Leukaemia Section

## Review

## Follicular lymphomas of germinal center (B- or T-cell) origin

**Antonino Carbone, Annunziata Gloghini**

Department of Pathology Centro di Riferimento Oncologico Aviano (CRO), Istituto Nazionale Tumori, IRCCS, Aviano, Italy; [acarbonate@cro.it](mailto:acarbonate@cro.it) (AC); Department of Diagnostic Pathology and Laboratory Medicine, Fondazione IRCCS Istituto Nazionale dei Tumori, Milano, Italy; [annunziata.gloghini@istitutotumori.mi.it](mailto:annunziata.gloghini@istitutotumori.mi.it) (AG)

Published in Atlas Database: September 2017

Online updated version : <http://AtlasGeneticsOncology.org/Anomalies/FollLymphGerminCentID1781.html>

Printable original version : <http://documents.irevues.inist.fr/bitstream/handle/2042/68953/09-2017-FollLymphGerminCentID1781.pdf>  
DOI: 10.4267/2042/68953

This work is licensed under a Creative Commons Attribution-Noncommercial-No Derivative Works 2.0 France Licence.  
© 2018 *Atlas of Genetics and Cytogenetics in Oncology and Haematology*

### Abstract

Follicular lymphomas of germinal center (B- or T-cell) origin include follicular lymphoma (FL), nodular lymphocyte predominant Hodgkin lymphoma (NLPHL), and angioimmunoblastic T-cell lymphoma (AITL). Other lymphomas of presumed follicular origin comprise mantle cell lymphoma (MCL) and marginal zone lymphoma (MZL) (Fig. 1). In this article we describe the clinical, pathological and genetic features of follicular lymphomas of germinal center (B- or T-cell) origin.

### KEYWORDS

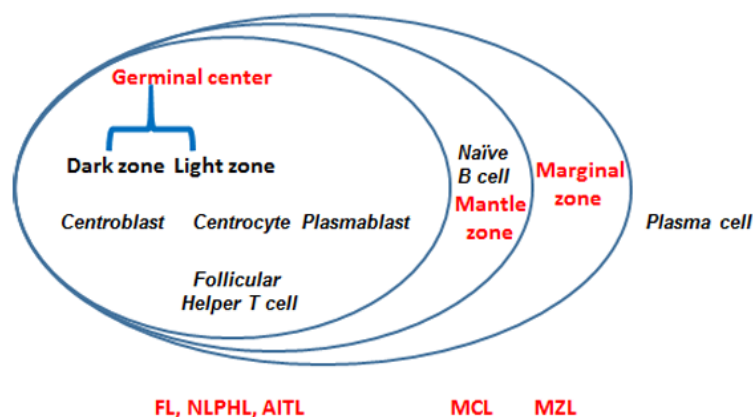
Follicular lymphoma; nodular lymphocyte predominant Hodgkin lymphoma; Angioimmunoblastic T-cell lymphoma

### Identity

Germinal center (GC)-derived lymphomas include follicular lymphoma (FL), nodular lymphocyte predominant Hodgkin lymphoma (NLPHL), and angioimmunoblastic T-cell lymphoma (AITL).

### Clinics and pathology

## Follicular lymphomas of germinal center (B- or T-cell) origin



**Figure 1.** Schematic figure of a lymphoid follicle with its "zones" and the related lymphomas. Lymphomas are placed on the follicular zones according to the location of the putative normal counterpart of the tumor cells. GC-derived lymphomas include both B-cell (Follicular lymphoma [FL], nodular lymphocyte predominant Hodgkin lymphoma [NLPHL]) and T-cell (angioimmunoblastic T-cell lymphoma [AITL]) lymphomas.

### Disease

Follicular lymphomas of germinal center (GC) (B- or T-cell) origin include follicular lymphoma (FL), nodular lymphocyte predominant Hodgkin lymphoma (NLPHL), and angioimmunoblastic T-cell lymphoma (AITL) (Fig. 1). Other lymphomas of presumed follicular origin that comprise mantle cell lymphoma (MCL) and marginal zone lymphoma (MZL) (Fig. 1) are not herein described. Within the microenvironment of all the follicular lymphomas of GC origin, tumour cells show a topographical and

functional relationship with follicular dendritic cells (FDC), and reactive lymphoid and stromal cells (Carbone et al., 2009). The 2008 "WHO Classification of Tumours of Haematopoietic and Lymphoid Tissues" has addressed the problem of early events in the evolution of lymphoid neoplasia (Campo et al., 2011). Examples of early lymphoma subtypes have been recognized for GC-derived lymphomas and include in situ follicular neoplasia/early FL (Campo et al., 2011, Carbone and Santoro, 2011; Swerdlow et al., 2016), early NLPHL (Carbone and Gloghini, 2012) and early AITL (Carbone and Gloghini, 2014B; Swerdlow et al., 20.

### Pathology

#### Follicular lymphomas of germinal center B-cell origin.

**- Follicular lymphomas (FL).** FLs are derived from GC B cells and maintain the gene expression programme of this stage of differentiation. Histology of FL may be indolent with small cells (centrocytes) or aggressive with larger cells (centroblasts). Unlike normal GC B cells, FLs express BCL2, as a result of the characteristic t(14;18) translocation, together with CD20, CD10 and BCL6.

In in situ follicular neoplasia the neoplastic cells are localized "in the place" that is occupied by the normal counterpart of the tumour cell, without invasion of surrounding structures (Carbone and Santoro, 2011; Carbone and Gloghini, 2014 A). The abnormal follicles involved by in situ follicular neoplasia have monotonous-appearing GCs surrounded by well-preserved mantle zones. The intrafollicular BCL2 positive GC B cells are located within the meshwork of the CD23+ FDC and coexpress CD10, BCL6 and CD20 and are CD3 negative. The proliferation index rate, as assessed by Ki67, is low. The FDC meshwork usually form a well-developed "spherical" dendritic meshwork with a sharp outline highlighting well-preserved mantle

zone. Other patterns that can be seen include contracted/distorted/disintegrated FDC meshworks. As compared with in situ follicular neoplasia, the follicles involved by overt FL usually have thinner mantle zones and higher proliferation index rate. However, they have a similar FDC pattern with a well-developed round spherical meshwork.

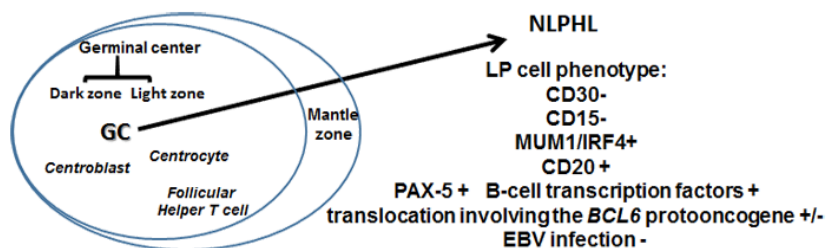
**- Nodular lymphocyte predominant Hodgkin lymphoma (NLPHL).** Tumour cells are derived from antigen-selected mutating GC B cells, as supported by the expression of BCL6 and CD40, the gene expression profile, the presence of CD4+ and PD1+ T cells surrounding the tumour cells and the presence of a follicular dendritic cell meshwork within the tumour nodules. The so-called NLPHL is a B-cell lymphoma, with a typical antigen profile (Carbone and Gloghini, 2017) (Fig. 2) and an indolent clinical behavior (Carbone et al., 2013). Interestingly, pathologic and molecular studies have shown similarities between NLPHL and T-cell or histiocyte-rich large B-cell lymphoma (THCRLBCL) (Boudová et al, 2003; Brune et al., 2008). Other features of NLPHL are reported in the specific article/section of the Atlas of Genetics and Cytogenetics in Oncology and Haematology.

#### Follicular lymphomas of germinal center T-cell origin.

## Follicular lymphomas of germinal center (B- or T-cell) origin

**AITL.** AITL is a peripheral T-cell lymphoma characterized by a prominent proliferation of high endothelial venules. In early lymph-node involvement by AITL, the neoplastic T cells preferentially occupy the B-cell follicles sometimes mimicking a FL of B-cell origin (Carbone and Gloghini, 2014 B). AITL tumour cells show the phenotype of normal follicular helper T cells. For the designation of AITL, the neoplastic cells should express at least 2 or 3 TFH-related antigens,

including CD279/PD1, CD10, BCL6, CXCL13, ICOS, SAP, and CCR5 (reviewed in Swerdlow et al, 2016). Typically, the tumour cells of AITL also express CD3 and CD4. The CD4+ tumour cells represent a minority of the neoplastic cell population, their detection being facilitated by the co-expression of CD10. Neoplastic CD4+ T cells of AITL are admixed with B cells, eosinophils and plasma cells.



**Figure 2.** Phenotypic profile of lymphocyte predominant (LP) tumour cells. Abbreviations. GC, germinal center; NLPHL, nodular lymphocyte predominant Hodgkin lymphoma; EBV, Epstein Barr virus.

## Evolution

### Progression and transformation

FL is the most common subtype of indolent lymphomas. It is characterized by relapses and remissions, usually controlled by Rituximab. On clinical progression, whether FL histology remains indolent or has become aggressive is an important issue: the relevant salvage therapy is selected based on histology, and a watchful waiting strategy can be adopted if the histology remains indolent (Tomita, 2017). It has been reported that 30-40% of FL cases transform into an aggressive lymphoma (tFL) with a poor prognosis (Bouska et al., 2017). An analysis of lymphoma cell specimens at histological transformation has identified multiple transformation-associated abnormalities, such as MYC upregulation, TP53 mutation and changes in the tumour microenvironment (Kahl and Yang, 2016). Transformation to aggressive lymphoma is a critical event in the clinical course of patients affected by FL. Yet, it is a challenge to reliably predict transformation at the time of diagnosis. However, we are currently lacking a prognostic index that would specifically address transformation

rather than disease progression or overall survival (Kridel et al., 2017).

Regarding NLPHL, clinic and pathologic observations have demonstrated that it may evolve to a completely diffuse T-cell-rich proliferation resembling a THCRLBCL. The 2016 revision of WHO classification has recommended the designation of these cases as THCRLBCL-like transformation of NLPHL (Swerdlow et al., 2016). Clinical features of AITL are reported in the specific article/section of the Atlas of Genetics and Cytogenetics in Oncology and Haematology.

## Genetics

### Note

The genes most frequently mutated in tFL include KMT2D (MLL2), CREBBP, EZH2, BCL2 and MEF2B. Many recurrently mutated genes are involved in epigenetic regulation, the Janus-activated kinase-signal transducer and activator of transcription (STAT) or the nuclear factor-kb pathways, immune surveillance and cell cycle regulation (Bouska et al., 2017).

**Table 1** shows genetic alterations of clinical value in follicular lymphoma (FL) and diffuse large B-cell lymphoma (DLBCL), of the GC B-cell origin type).

| Disease subtype | Genes             | Normal function           | Technology used to detect | Genotype-directed therapy |
|-----------------|-------------------|---------------------------|---------------------------|---------------------------|
| FL/GCB DLBCL    | <i>BCL2</i>       | Antiapoptotic             | FISH                      | Venetoclax                |
|                 | <i>KMT2D/MLL2</i> | H3K4 methyltransferase    | Sequencing                |                           |
|                 | <i>CREBBP</i>     | Histone acetyltransferase | Sequencing                | Trials of HDAC inhibitors |

## Follicular lymphomas of germinal center (B- or T-cell) origin

|  |              |                           |            |                           |
|--|--------------|---------------------------|------------|---------------------------|
|  | <i>EP300</i> | Histone acetyltransferase | Sequencing |                           |
|  | <i>EZH2</i>  | H3K27 methyltransferase   | Sequencing | Trials of EZH2 inhibitors |
|  | <i>MEF2B</i> | Transcription factor      | Sequencing |                           |

Modified and adapted from Taylor et al., (2017)

Genetic features of NLPHL are reported in the specific article/section of the Atlas of Genetics and Cytogenetics in Oncology and Haematology.

Recurrent genetic abnormalities in AITL include TET2, IDH2, DNMT3A, RHOA, and CD28 mutations, as well as gene fusions such as ITK/SYK or CTLA4 / CD28 (Leclaire Alirkilicarslan et al., 2017). All these abnormalities have a role in the process of lymphomagenesis and may represent the

target of tailored therapies (reviewed in Swerlow et al., 2016).

## References

Boudová L, Torlakovic E, Delabie J, Reimer P, Pfistner B, Wiedenmann S, Diehl V, Müller-Hermelink HK, Rüdiger T. Nodular lymphocyte-predominant Hodgkin lymphoma with nodules resembling T-cell/histiocyte-rich B-cell lymphoma: differential diagnosis between nodular lymphocyte-predominant Hodgkin lymphoma and T-cell/histiocyte-rich B-cell lymphoma. *Blood*. 2003 Nov 15;102(10):3753-8

Bouska A, Zhang W, Gong Q, Iqbal J, Scuto A, Vose J, Ludvigsen M, Fu K, Weisenburger DD, Greiner TC, Gascoyne RD, Rosenwald A, Ott G, Campo E, Rimsza LM, Delabie J, Jaffe ES, Braziel RM, Connors JM, Wu CI, Staudt LM, D'Amore F, McKeithan TW, Chan WC. Combined copy number and mutation analysis identifies oncogenic pathways associated with transformation of follicular lymphoma. *Leukemia*. 2017 Jan;31(1):83-91

Brune V, Tiacci E, Pfeil I, Döring C, Eckerle S, van Noesel CJ, Klapper W, Falini B, von Heydebreck A, Metzler D, Bräuninger A, Hansmann ML, Küppers R. Origin and pathogenesis of nodular lymphocyte-predominant Hodgkin lymphoma as revealed by global gene expression analysis. *J Exp Med*. 2008 Sep 29;205(10):2251-68

Campo E, Swerlow SH, Harris NL, Pileri S, Stein H, Jaffe ES. The 2008 WHO classification of lymphoid neoplasms and beyond: evolving concepts and practical applications. *Blood*. 2011 May 12;117(19):5019-32

Carbone A, Ghoghini A. Hodgkin lymphoma classification: Are we at a crossroads? *Cancer*. 2017 Oct 1;123(19):3654-3655

Carbone A, Spina M, Ghoghini A, Ponzoni M, Doglioni C, Tirelli U. Nodular lymphocyte predominant Hodgkin lymphoma with non-invasive or early invasive growth pattern suggests an early step of the disease with a highly favorable outcome. *Am J Hematol*. 2013 Feb;88(2):161-2

Kahl BS, Yang DT. Follicular lymphoma: evolving therapeutic strategies. *Blood*. 2016 Apr 28;127(17):2055-63

Kridel R, Sehn LH, Gascoyne RD. Can histologic transformation of follicular lymphoma be predicted and prevented? *Blood*. 2017 Jul 20;130(3):258-266

Leclaire Alirkilicarslan A, Dupuy A, Pujals A, Parrens M, Vergier B, Robson A, Delfau-Larue MH, Ingen-Housz-Oro S, Chosidow O, Haioun C, Beylot-Barry M, Merlio JP, Copie-Bergman C, Gaulard P, Ortonne N. Expression of TFH Markers and Detection of RHOA p.G17V and IDH2 p.R172K/S Mutations in Cutaneous Localizations of Angioimmunoblastic T-Cell Lymphomas. *Am J Surg Pathol*. 2017 Dec;41(12):1581-1592

Swerlow SH, Campo E, Pileri SA, Harris NL, Stein H, Siebert R, Advani R, Ghielmini M, Salles GA, Zelenetz AD, Jaffe ES. The 2016 revision of the World Health Organization classification of lymphoid neoplasms. *Blood*. 2016 May 19;127(20):2375-90

Taylor J, Xiao W, Abdel-Wahab O. Diagnosis and classification of hematologic malignancies on the basis of genetics. *Blood*. 2017 Jul 27;130(4):410-423

*This article should be referenced as such:*

Carbone A, Ghoghini A. Follicular lymphomas of germinal center (B- or T-cell) origin. *Atlas Genet Cytogenet Oncol Haematol*. 2018; 22(10):453-456.