

Leukaemia Section

Short Communication

Nodular lymphocyte-predominant Hodgkin lymphoma

Annunziata Gloghini, Antonino Carbone

Department of Diagnostic Pathology and Laboratory Medicine, Fondazione IRCCS Istituto Nazionale dei Tumori, Milano, Italy; annunziata.gloghini@istitutotumori.mi.it (AG); Department of Pathology Centro di Riferimento Oncologico Aviano (CRO), Istituto Nazionale Tumori, IRCCS, Aviano, Italy; acarbone@cro.it (AC)

Published in Atlas Database: April 2016

Online updated version : <http://AtlasGeneticsOncology.org/Anomalies/NodulLymphPredomClassicHodgkinID1570.html>

Printable original version : <http://documents.revues.inist.fr/bitstream/handle/2042/68131/04-2016-NodulLymphPredomClassicHodgkinID1570.pdf>

DOI: 10.4267/2042/68131

This work is licensed under a Creative Commons Attribution-Noncommercial-No Derivative Works 2.0 France Licence.

© 2016 Atlas of Genetics and Cytogenetics in Oncology and Haematology

Abstract

Diagnostic characteristics of nodular lymphocyte-predominant Hodgkin lymphoma (NLPHL): nodular or nodular and diffuse proliferation of scattered lymphocyte predominant (LP) tumour cells within a background reminiscent of primary or secondary lymphoid follicles. Six different patterns: A) 'classical' nodular, B) serpiginous/interconnected nodular, C) nodular with prominent extra-nodular LP cells, D) T-cell-rich nodular, E) diffuse with a T-cell-rich background, and F) diffuse, B-cell-rich pattern.

Typical histopathologic patterns in NLPHL include patterns A and B. Both of these patterns show a predominantly nodular growth, with LP cells located within the nodules. So called "histopathologic variants" are defined by prominent extranodular LP cells associated to patterns C to F. "Histopathologic variants" may be associated with advanced stage disease and higher relapse rate. Assessing "histopathologic variants" patterns in NLPHL may be useful for the management of the patients.

Keywords

Nodular lymphocyte-predominant Hodgkin lymphoma; NLPHL; Immunoarchitectural patterns; Immunohistological patterns; Clinics; Pathology

Identity

Other names: Lymphocyte-predominant HL

Clinics and pathology

Disease

Nodular lymphocyte predominant Hodgkin lymphoma (NLPHL) is a distinct subtype of Hodgkin lymphoma (HL), usually associated with an indolent course and presenting in the early stages of the disease (Anagnostopoulos et al., 2000).

Phenotype/cell stem origin

Cell origin

Tumour cells are antigen-selected mutating germinal center (GC) B cells. This origin is supported by The expression of BCL6 and CD40 by tumour cells (Carbone et al., 1995; Liso et al., 2006).

The presence of CD4+, CD57+, PD1+ T cells surrounding the tumour cells (Poppema et al., 2008). The presence of a follicular dendritic cell meshwork within the tumour nodules (Mason et al., 1994; Carbone and Gloghini, 2012)

The gene expression profile (Brune et al., 2008).

Rearranged, clonal and mutated (ongoing) Ig genes of tumour cells (Marafioti et al., 1997; Küppers, 2011).

Phenotype

LP cells profile: CD45+, CD20+, CD40+, CD79a+, CD75+, BCL6+, IRF4/MUM1+, and OCT2+, BOB1+, PAX5+, PU.1+, epithelial membrane antigen+. CD15 and CD30 are usually negative (Poppema et al., 2008).

Nodules composition: CD20+ and IgD+ small B cells, CD3+ and CD4+ T cells and histiocytes.

The background of the nodules also includes an increase in GC-derived CD57+, IRF4/MUM1+, and PD-1+ T-cells populations which form a rim around LP cells (Carbone and Gloghini, 2012).

Epidemiology

About 5% of all HL cases are classified as NLPHL. Males are more commonly affected than females (male-female ratio, 3:1). The median age at presentation is about 40 years.

Clinics

NLPHL is a neoplasm usually associated with a favourable clinical course despite a tendency for local recurrences.

Cytology

NLPHL tumour cells are termed lymphocyte predominant (LP) cells. LP cells are large cells with multilobated nuclei and scant cytoplasm. They contain multiple, not prominent, nucleoli in contrast with typical Reed Sternberg cells of classical HL that contain huge eosinophilic nucleoli.

Pathology

LP tumour cells proliferate within a nodular or

nodular and diffuse background (Anagnostopoulos et al., 2000).

The tumour nodules are reminiscent of a primary follicle containing spherical meshworks of follicular dendritic cells (FDCs) admixed with inflammatory cells (Mason et al., 1994).

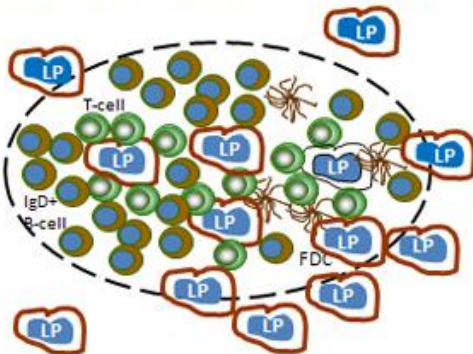
On morphologic and immunohistologic grounds, six patterns are recognizable in NLPHL (Fan et al., 2003): A) 'classical' nodular, B) serpiginous/interconnected nodular, C) nodular with prominent extra-nodular LP cells, D) T-cell-rich nodular, E) diffuse with a T-cell-rich background, and F) diffuse, B-cell-rich pattern.

Typical histopathologic patterns in NLPHL include patterns A and B. Both of these patterns show a predominantly nodular growth, with LP cells located within the nodules.

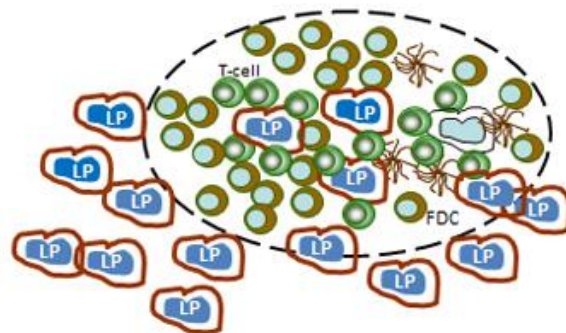
So called "histopathologic variants" include patterns from C to F and are associated to prominent extranodular LP cells or to B-cell depletion of the microenvironment (Hartmann et al. Blood, 2013).

An additional nodular pattern in which LP cells proliferate within a background reminiscent of a secondary follicle without invasion of the extranodular space has been recognized (Carbone and Gloghini, 2012; Gloghini et al., 2015).

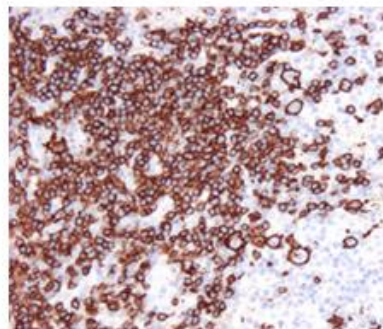
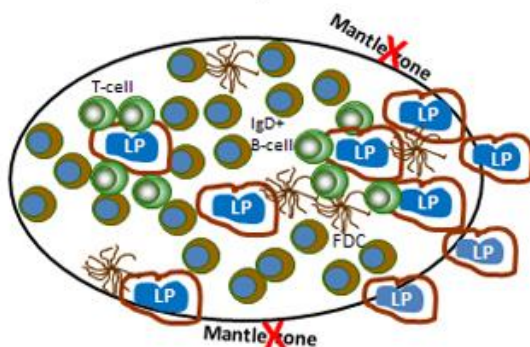
Pattern A of Fan and Colleagues (2003)
"Classical" nodular pattern with rare extranodular LP cells



Pattern C of Fan and Colleagues (2003).
Nodular pattern with prominent extranodular LP cells



Nodular lymphocyte predominant Hodgkin lymphoma showing a nodular pattern in which extranodular LP cells are absent. They do not invade the surrounding spaces (Carbone and Gloghini 2012)



Other features

Virology

The neoplastic cells are usually EBV negative (Anagnostopoulos et al., 2000).

Treatment

Early stage disease: treatment with local radiation provides disease control and good overall survival (Advani and Hoppe, 2015).

Locally extensive or advanced stages: paradigms used for classical HL with similar outcomes (Advani and Hoppe, 2015). Excellent response rates (but increased relapse rates) observed with single agent rituximab. Promising data observed with R-CHOP (Advani and Hoppe, 2013; Younes et al., 2014).

Relapsed disease: single agent rituximab is a reasonable choice because of excellent tolerability (Advani and Hoppe, 2015).

Evolution

Transformation to diffuse large B-cell lymphoma (T-cell/histiocyte rich large B-cell lymphoma).

Prognosis

Favourable clinical course despite a tendency for local recurrences (Advani and Hoppe, 2013).

Compared with "typical NLPHL", "histopathologic variants" are associated with more advanced disease and a higher relapse rate (Hartmann et al. Blood, 2013).

Genetics

Translocation involving the BCL6 protooncogene (Liso et al., 2006). Strong NFκB activity (Küppers, 2011). Aberrant somatic hypermutation of multiple proto-oncogenes (PIM1, RHOH (TTF), MYC, and PAX5) in a fraction of cases. Most of mutations are on the 5' untranslated regions of the genes (Liso et al, 2006). Mutation in SOCS1 (Küppers, 2011). BAG6 (BAT3), HIGD1A, and UBD (FAT10) gene expression (Hartmann et al. PlosOne, 2013).

References

Advani RH, Hoppe RT. XVIII. Management of nodular lymphocyte predominant Hodgkin lymphoma. *Hematol Oncol*. 2015 Jun;33 Suppl 1:90-5

Anagnostopoulos I, Hansmann ML, Franssila K, Harris M, Harris NL, Jaffe ES, Han J, van Krieken JM, Poppema S, Marafioti T, Franklin J, Sextro M, Diehl V, Stein H. European Task Force on Lymphoma project on lymphocyte predominance Hodgkin disease: histologic and immunohistologic analysis of submitted cases reveals 2 types of Hodgkin disease with a nodular growth pattern and abundant lymphocytes. *Blood*. 2000 Sep 1;96(5):1889-99

Brune V, Tiacci E, Pfeil I, Döring C, Eckerle S, van Noesel CJ, Klapper W, Falini B, von Heydebreck A, Metzler D, Bräuninger A, Hansmann ML, Küppers R. Origin and

pathogenesis of nodular lymphocyte-predominant Hodgkin lymphoma as revealed by global gene expression analysis. *J Exp Med*. 2008 Sep 29;205(10):2251-68

Carbone A, Gloghini A. "Intrafollicular neoplasia" of nodular lymphocyte predominant Hodgkin lymphoma: description of a hypothetical early step of the disease. *Hum Pathol*. 2012 May;43(5):619-28

Carbone A, Gloghini A, Gattei V, Aldinucci D, Degan M, De Paoli P, Zagonel V, Pinto A. Expression of functional CD40 antigen on Reed-Sternberg cells and Hodgkin's disease cell lines. *Blood*. 1995 Feb 1;85(3):780-9

Fan Z, Natkunam Y, Bair E, Tibshirani R, Warnke RA. Characterization of variant patterns of nodular lymphocyte predominant Hodgkin lymphoma with immunohistologic and clinical correlation. *Am J Surg Pathol*. 2003 Oct;27(10):1346-56

Gloghini A, Bosco A, Ponzoni M, Spina M, Carbone A. Immunoarchitectural patterns in nodular lymphocyte predominant Hodgkin lymphoma: pathologic and clinical implications. *Expert Rev Hematol*. 2015 Apr;8(2):217-23

Hartmann S, Eichenauer DA, Plütschow A, Mottok A, Bob R, Koch K, Bernd HW, Cogliatti S, Hummel M, Feller AC, Ott G, Möller P, Rosenwald A, Stein H, Hansmann ML, Engert A, Klapper W. The prognostic impact of variant histology in nodular lymphocyte-predominant Hodgkin lymphoma: a report from the German Hodgkin Study Group (GHSG). *Blood*. 2013 Dec 19;122(26):4246-52; quiz 4292

Küppers, R. Hodgkin lymphoma Atlas Genet Cytogenet Oncol Haematol. 2011;15(6):527-528. On line version : <http://AtlasGeneticsOncology.org/Anomalies/HodgkinID2068.html>

Liso A, Capello D, Marafioti T, Tiacci E, Cerri M, Distler V, Paulli M, Carbone A, Delsol G, Campo E, Pileri S, Pasqualucci L, Gaidano G, Falini B.. Aberrant somatic hypermutation in tumor cells of nodular-lymphocyte-predominant and classic Hodgkin lymphoma. *Blood*. 2006; 108(3): 1013-1020.

Marafioti T, Hummel M, Anagnostopoulos I, Foss HD, Falini B, Delsol G, Isaacson PG, Pileri S, Stein H.. Origin of nodular lymphocyte-predominant Hodgkin's disease from a clonal expansion of highly mutated germinal-center B cells. *N Engl J Med* 1997; 337(7): 453-458.

Mason DY, Banks PM, Chan J, Cleary ML, Delsol G, de Wolf Peeters C, Falini B, Gatter K, Grogan TM, Harris NL.. Nodular lymphocyte predominance Hodgkin's disease. A distinct clinicopathological entity. *Am J Surg Pathol* 1994; 18(5): 526-530.

Poppema S, Delsol G, Pileri SA, Stein H.. Nodular lymphocyte predominant Hodgkin lymphoma. Swerdlow SH, Campo E, Harris NL, Jaffe ES, Pileri SA, Stein H, Thiele H, Vardiman JW (eds.) World Health Organization Classification of Tumours, Pathology and Genetics of Tumours of Haematopoietic and Lymphoid Tissues, Lyon: IARC Press, 2008: 323-325

Younes A, Carbone A, Johnson P, Dabaja B, Ansell S, Kuruvilla L.. Hodgkin's lymphoma. De Vita VTJ, Lawrence TS, Rosenberg SA (eds). De Vita, Hellman, and Rosenberg's Cancer: Principles Practice of Oncology: Wolters Kluwer Health/Lippincott Williams & Wilkins; 2014.

This article should be referenced as such:

Gloghini A, Carbone A. Nodular lymphocyte-predominant Hodgkin lymphoma. *Atlas Genet Cytogenet Oncol Haematol*. 2017; 21(1):20-22.