

WJG 20<sup>th</sup> Anniversary Special Issues (14): Pancreatic cancer

## Systematic review of novel ablative methods in locally advanced pancreatic cancer

Margaret G Keane, Konstantinos Bramis, Stephen P Pereira, Giuseppe K Fusai

Margaret G Keane, Stephen P Pereira, Institute for Liver and Digestive Health, University College London, Royal Free Campus, London NW3 2PF, United Kingdom

Konstantinos Bramis, Giuseppe K Fusai, HPB and Liver Transplant Unit, Royal Free Hospital, London NW3 2QG, United Kingdom

**Author contributions:** Keane MG and Bramis K performed the systematic review and wrote the article; Pereira SP and Fusai GK conceived the idea for the article, reviewed and edited the manuscript.

**Supported by** National Institutes of Health Grant PO1CA84203; The work was undertaken at UCLH/UCL, which receives a proportion of funding from the Department of Health's National Institute for Health Research Biomedical Research Centres funding scheme; A CRUK research bursary to Keane MG

**Correspondence to:** Giuseppe K Fusai, MS, FRCS, HPB and Liver Transplant Unit, Royal Free Hospital, London NW3 2QG, United Kingdom. [g.fusai@nhs.net](mailto:g.fusai@nhs.net)

Telephone: +44-20-77940500 Fax: +44-20-78302960

Received: October 27, 2013 Revised: December 11, 2013

Accepted: January 8, 2014

Published online: March 7, 2014

### Abstract

Unresectable locally advanced pancreatic cancer with or without metastatic disease is associated with a very poor prognosis. Current standard therapy is limited to chemotherapy or chemoradiotherapy. Few regimens have been shown to have a substantial survival advantage and novel treatment strategies are urgently needed. Thermal and laser based ablative techniques are widely used in many solid organ malignancies. Initial studies in the pancreas were associated with significant morbidity and mortality, which limited widespread adoption. Modifications to the various applications, in particular combining the techniques with high quality imaging such as computed tomography and intraoperative or endoscopic ultrasound has enabled real time treatment monitoring and significant improvements in safety. We conducted a systematic review of the litera-

ture up to October 2013. Initial studies suggest that ablative therapies may confer an additional survival benefit over best supportive care but randomised studies are required to validate these findings.

© 2014 Baishideng Publishing Group Co., Limited. All rights reserved.

**Key words:** Pancreatic cancer; Radiofrequency ablation; Photodynamic therapy; Cryoablation; Microwave ablation; High frequency focused ultrasound; Irreversible electroporation

**Core tip:** Unresectable locally advanced pancreatic cancer with or without metastatic disease is associated with a very poor prognosis. Current standard therapy is limited to chemotherapy or chemoradiotherapy. Few regimens have been shown to have a substantial survival advantage and novel treatment strategies are urgently needed. Initial studies of ablation in the pancreas were associated with significant morbidity and mortality, which limited widespread adoption. Modifications to the various applications, in particular combining the techniques with high quality imaging such as computed tomography and intraoperative or endoscopic ultrasound has enabled real time treatment monitoring and significant improvements in safety.

Keane MG, Bramis K, Pereira SP, Fusai GK. Systematic review of novel ablative methods in locally advanced pancreatic cancer. *World J Gastroenterol* 2014; 20(9): 2267-2278 Available from: URL: <http://www.wjgnet.com/1007-9327/full/v20/i9/2267.htm> DOI: <http://dx.doi.org/10.3748/wjg.v20.i9.2267>

### BACKGROUND

Pancreatic ductal adenocarcinoma (PDAC) is the tenth most common cancer in the UK but the fifth commonest

cause of cancer death. At diagnosis more than 80% of patients have locally advanced or metastatic disease and are unsuitable for curative surgical resection. Prognosis in pancreatic cancer is dismal; median survival for locally advanced disease is just 6-10 mo, however in patients with metastatic disease this falls to 3-6 mo. Overall 5 year survival is less than 4%<sup>[1]</sup>.

Standard options available for treating patients with inoperable PDAC are limited to chemotherapy, radiotherapy, or a combination of the two. Gemcitabine is the most commonly used chemotherapy agent in pancreatic cancer, however recent studies have shown that in combination with other chemotherapy agent's further improvements in overall survival can be gained. A recent randomised Phase III study (GemCap) reported a median survival in the combination gemcitabine + capecitabine group of 7.1 mo compared with 6.2 mo in those who received gemcitabine alone. The 1-year overall survival (OS) rates were 24.3% for combination therapy and 22% for gemcitabine alone (HR = 0.86, 95%CI: 0.72-1.02,  $P = 0.077$ )<sup>[2]</sup>. A further large European study compared gemcitabine to FOLFIRINOX (fluorouracil, leucovorin, irinotecan and oxaliplatin) and demonstrated a significant survival advantage in the FOLFIRINOX group compared with gemcitabine alone (median 11.1 mo *vs* 6.8 mo)<sup>[3]</sup>. The phase III MPACT study found that weekly intravenous nab-paclitaxel with gemcitabine resulted in a significantly higher overall survival compared to gemcitabine monotherapy (8.5 mo *vs* 6.7 mo, HR = 0.72,  $P < 0.0001$ )<sup>[4]</sup>.

Given that so few patients with PDAC are suitable for curative surgery and most have only a limited response to chemotherapy; tumour debulking or interstitial ablation has been investigated as a potential additional therapy. A recent systematic review compared R2 resections to palliative bypass alone in the management of advanced PDAC. A small non-significant survival advantage was observed in the R2 resection group; 8.2 mo compared to 6.7 mo in the palliative bypass group. However patients undergoing R2 resections had a significantly higher morbidity (RR = 1.75, 95%CI: 1.35-2.26,  $P < 0.0001$ ), mortality (RR = 2.98, 95%CI: 1.31-6.75,  $P = 0.009$ ) and longer hospital stay (mean difference, 5 d, 95%CI: 1-9 d,  $P = 0.02$ ), hence R2 resections are not recommended as part of the standard management of PDAC<sup>[5]</sup>. However minimally invasive ablative therapies delivered percutaneously or endoscopically have become part of standard therapy in many other solid organ tumours, particularly in patients with inoperable disease or who are unfit for surgical resection<sup>[6]</sup>. Early studies of local ablation in the pancreas were associated with high morbidity and mortality<sup>[7]</sup>. However improvements in delivery and in particular combining the technology with high quality real-time imaging, has reduced associated complications. The safety and efficacy of each ablative therapy in non-operable PDAC will be evaluated in this review.

## RESEARCH METHODOLOGY

The primary aim of this review was to assess safety and

efficacy of each ablation therapy in the treatment of locally advanced or metastatic PDAC. Secondary endpoints included improvements in overall survival, changes in symptoms, tumour markers or performance status where available. A systematic literature search was performed using the PubMed, EMBASE databases and the Cochrane Library for studies published in the English language up to 1<sup>st</sup> October 2013. MeSH terms were decided by a consensus of the authors and were (radiofrequency ablation, catheter ablation, photodynamic therapy, PDT, cryoablation, cryosurgery, laser, high intensity focused ultrasound ablation, microwave, electroporation) and (pancreas OR pancreatic), and were restricted to the title, abstract and keywords. Only articles, which described ablation in unresectable PDAC, were included. Articles that described the use of ablative therapies in premalignant pancreatic disease were excluded but outcomes are summarised in Table 1. Similarly studies that included non-ablative therapies were also excluded but have been summarised in Table 2. Any study with fewer than four patients and those reporting on tumours that did not originate in the pancreas were excluded. In cryoablation and high frequency focused ultrasound of the pancreas, many of the largest case-series are published in non-English language medical journals. Although articles not published in the English language were excluded from this systematic review, if an English language abstract was available the results were included in the summary tables. All references were screened for potentially relevant studies not identified in the initial literature search. The following variables were extracted for each report when available: number of patients, disease extent, device used and settings, distance of probe from surrounding structures, duration of therapy and number of ablations applied, additional safety methods used. Thirty-two papers were included (Figure 1).

## THERMAL ABLATIVE TECHNIQUES

### Radiofrequency ablation

Radiofrequency ablation (RFA) causes tissue destruction through the application of a high frequency alternating current that generates high local temperatures leading to a coagulative necrosis. The technique has been widely used in many solid organ malignancies and is now part of standard therapy in several tumours including hepatocellular carcinoma<sup>[6]</sup>. The first application of RFA in the normal porcine pancreas was described in 1999. Although this application was performed under EUS guidance<sup>[8]</sup> it has nearly always been delivered intraoperatively (rarely percutaneously) in combination with palliative bypass surgery<sup>[9]</sup>. Although RFA was deemed to be feasible and safe in animal studies<sup>[8]</sup>, early clinical applications in the pancreas were associated with unacceptably high rates of morbidity (0%-40%) and mortality (0%-25%) (Table 3)<sup>[7,10-14]</sup>. Most RFA of pancreatic tumours has been performed using the Cool-tip™ RF Ablation system (Radionics). Many of the complications arose as a result of inadvertent damage to structures adjacent to

**Table 1** Use of ablative therapies to treat cystic and solid premalignant lesions of the pancreas

Author	Premalignant lesion	n	Treatment	Median area of ablation, mm (range)	Outcome	Complications
Gan <i>et al</i> <sup>[46]</sup>	Cystic tumours of the pancreas	25	EUS guided ethanol lavage	19.4 (6-30)	Complete resolution 35%	None
Oh <i>et al</i> <sup>[73]</sup>	Cystic tumours of the pancreas	14	EUS guided ethanol lavage + paclitaxel	25.5 (17-52)	Complete resolution in 79%	Acute pancreatitis (n = 1) Hyperamylasaemia (n = 6) Abdominal pain (n = 1)
Oh <i>et al</i> <sup>[74]</sup>	Cystic tumours of the pancreas	10	EUS guided ethanol lavage + paclitaxel	29.5 (20-68)	Complete resolution in 60%	Mild pancreatitis (n = 1)
DeWitt <i>et al</i> <sup>[75]</sup>	Cystic tumours of the pancreas	42	Randomised double blind study: Saline <i>vs</i> ethanol	22.4 (10-58)	Complete resolution in 33%	Abdominal pain at 7 d (n = 5) Pancreatitis (n = 1) Acystic bleeding (n = 1) Fever (1/52)
Oh <i>et al</i> <sup>[47]</sup>	Cystic tumours of the pancreas	52	EUS guided ethanol lavage + paclitaxel	31.8 (17-68)	Complete resolution in 62%	Mild abdominal discomfort (1/52) Mild pancreatitis (1/52) Splenic vein obliteration (1/52)
Levy <i>et al</i> <sup>[76]</sup>	PNET	8	EUS guided ethanol lavage (5 patients) and intra-operative ultrasound guided (IOUS) ethanol lavage (3 patients)	16.6 (8-21)	Hypoglycemia symptoms disappeared 5/8 and significantly improved 3/8	EUS guided: No complications. IOUS-guided ethanol injection: Minor peritumoral bleeding (1/3), pseudocyst (1/3), pancreatitis (1/3)
Pai <i>et al</i> <sup>[21]</sup>	Cystic tumours of the pancreas + neuroendocrine tumours	8	EUS guided RFA	Mean size pre RFA, 38.8 mm <i>vs</i> mean size post RFA, 20 mm	Complete ablation in 25% (2/8)	2/8 patients had mild abdominal pain that resolved in 3 d

RFA: Radiofrequency ablation; EUS: Endoscopic ultrasound; PNET: Pancreatic neuroendocrine tumour.

**Table 2** Endoscopic ultrasound administered non-ablative anti-tumour therapies for pancreatic ductal adenocarcinoma

Author	Therapy	Patients	n	Outcome and survival	Complications
Chang <i>et al</i> <sup>[77]</sup>	Cytoimplant (mixed lymphocyte culture)	Unresectable PDAC	8	Median survival: 13.2 mo. 2 partial responders and 1 minor response	7/8 developed low-grade fever 3/8 required biliary stent placement
Hecht <i>et al</i> <sup>[78]</sup>	ONYX-015 (55-kDa gene-deleted adenovirus) + IV gemcitabine	Unresectable PDAC	21	No patient showed tumour regression at day 35. After commencement of gemcitabine, 2/15 had a partial response	Sepsis: 2/15 Duodenal perforation: 2/15
Hecht <i>et al</i> <sup>[79]</sup> Chang <i>et al</i> <sup>[80,81]</sup>	TNFERade (replication-deficient adenovector containing human tumour necrosis factor (TNF)- $\alpha$ gene)	Locally advanced PDAC	50	Response: One complete response, 3 partial responses. Seven patients eventually went to surgery, 6 had clear margins and 3 survived > 24 mo	Dose-limiting toxicities of pancreatitis and cholangitis were observed in 3/50
Herman <i>et al</i> <sup>[82]</sup>	Phase III study of standard care plus TNFERade (SOC + TNFERade) <i>vs</i> standard care alone (SOC)	Locally advanced PDAC	304 (187 SOC + TNFERade)	Median survival: 10.0 mo for patients in both the SOC + TNFERade and SOC arms [hazard ratio (HR), 0.90, 95%CI: 0.66-1.22, <i>P</i> = 0.26]	No major complications. Patients in the SOC + TNFERade arm experienced more grade 1 to 2 fever than those in the SOC alone arm ( <i>P</i> < 0.001)
Sun <i>et al</i> <sup>[83]</sup>	EUS-guided implantation of radioactive seeds (iodine-125)	Unresectable PDAC	15	Tumour response: "partial" in 27% and "minimal" in 20%. Pain relief: 30%	Local complications (pancreatitis and pseudocyst formation) 3/15. Grade III hematologic toxicity in 3/15
Jin <i>et al</i> <sup>[84]</sup>	EUS-guided implantation of radioactive seeds (iodine-125)	Unresectable PDAC	22	Tumour response: "partial" in 3/22 (13.6%)	No complications

PDAC: Pancreatic ductal adenocarcinoma; EUS: Endoscopic ultrasound.

the zone of ablation such as the normal pancreas, duodenum, biliary tree or peri-pancreatic vasculature. These early studies applied high temperatures (> 90 °C) and multiple rounds of ablation to treat large tumours in the head of the pancreas in one session<sup>[13]</sup>. An *ex-vivo* study of the thermal kinetic characteristics of RFA found that the optimal settings for RFA in the pancreas to prevent

injury to the adjacent viscera was 90 °C applied for 5 min<sup>[15]</sup>. Subsequent clinical studies that reduced the RFA temperature from 105 °C to 90 °C, reported only minimal RFA-related complications<sup>[7]</sup>. Active cooling of the major vessels and duodenum with saline during intraoperative RFA and observing at least a 0.5 cm area between the zone of ablation and major structures, reduced compli-

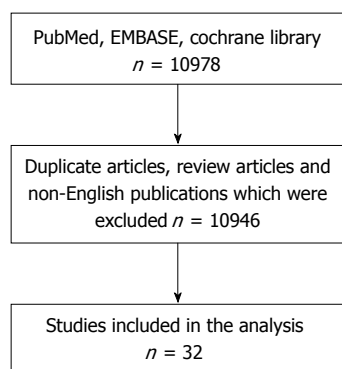


Figure 1 Systematic review schema.

cations<sup>[10,16,17]</sup>. Since most of the mortality resulted from uncontrollable gastrointestinal haemorrhage from ablated tumours in the head of the pancreas, some authors have recommended this probe should only be employed in body or tail tumours<sup>[10,16]</sup>.

All studies have demonstrated that RFA leads to tumour necrosis and a decrease of tumour volume<sup>[9,12,17,18]</sup>. Some studies have also observed an improvement in tumour related symptoms, in particular a reduction of back pain and analgesia requirements. Tumour markers (carbohydrate antigen 19-9) also decrease following effective ablation<sup>[16]</sup>. Although all patients treated with RFA ultimately developed disease progression<sup>[9,11,12,17,18]</sup>, when compared to patients with advanced disease who received standard therapy in a non-randomised cohort study, patients who received combination therapy had prolonged survival (33 mo *vs* 13 mo,  $P = 0.0048$ )<sup>[11]</sup>. However, this was a single centre study that only included 25 patients (12 receiving RFA). An earlier non-randomised study did not demonstrate the same survival advantage<sup>[12]</sup>. Spiliotis *et al*<sup>[11]</sup> also evaluated overall survival following RFA according to tumour stage. Patients with stage III disease had a significant improvement in survival following RFA compared to patients with the same stage of disease receiving best supportive care ( $P = 0.0032$ ). In contrast, no difference in overall survival was shown in patients with metastatic PDAC, following RFA treatment ( $P = 0.1095$ ). Larger studies, in combination with systemic chemotherapy, would be needed to evaluate any potential role of RFA in patients with metastatic disease.

Recently two new RFA probes have been developed that can be placed down the working channel of an endoscope, enabling RFA to be administered under EUS guidance. Twenty-two patients with locally advanced PDAC were treated with the cryotherm probe (CTP) (ERBE Elektromedizin GmbH, Tübingen, Germany) that incorporates radiofrequency ablation with cryogenic cooling. The probe was sited successfully in 16 patients (72.8%); stiffness of the gastrointestinal wall and tumour prevented placement in the others. Following the procedure three patients reported mild abdominal pain and one experienced minor gastrointestinal bleeding, not re-

quiring transfusion<sup>[19]</sup>. In a further study, 7 patients with unresectable PDAC received EUS guided RFA using the monopolar radiofrequency (RF) catheter (1.2 mm Habib EUS-RFA catheter, Emcision Ltd, London). The tumour was shown to decrease in size in all cases and only one patient developed mild pancreatitis<sup>[20]</sup>. Long-term follow up is not available on the efficacy of these new catheters. Early clinical studies have also used the Habib EUS RFA catheter to treat cystic tumours of the pancreas (Table 1)<sup>[21]</sup>.

### Microwave ablation

Microwave (MW) current is produced by a generator connected *via* a coaxial cable to 14-gauge straight MW antennas with a 3.7 cm or 2 cm radiating section. One or two antennae are then inserted into the tumour for 10 min. The largest case series of microwave ablation in locally advanced PDAC includes 15 patients. Although MW ablation can be performed percutaneously or intraoperatively<sup>[22]</sup>, in this series it was performed intraoperatively at the time of palliative bypass surgery. All tumours were located in the head or body of the pancreas and had an average size of 6 cm (range 4–8 cm); none had distant metastasis on imaging. Partial necrosis was achieved in all patients and there was no major procedure-related morbidity or mortality. However minor complications were seen in 40% (mild pancreatitis, asymptomatic hyperamylasia, pancreatic ascites, and minor bleeding). The longest survival of an individual patient in this series was 22 mo<sup>[23]</sup>.

### Cryoablation

The successful use of cryoablation in the pancreas was first reported in primate experiments in the 1970s<sup>[24]</sup>. However its potential application as a therapy in pancreatic cancer was not described for a further 20 years<sup>[25]</sup>. Cryoablation is most commonly performed intraoperatively under ultrasound guidance. Small lesions (< 3 cm) can be reliably frozen with a single, centrally placed probe but larger tumours require the placement of multiple probes or sequential treatments. Most studies have used the argon-gas-based cryosurgical unit (Endocare, Inc., CA, United States) and employ a double “freeze/thaw” cycle. The tumour is cooled to  $-160\text{ }^{\circ}\text{C}$  and the resulting iceball monitored with ultrasound to ensure the frozen region encompasses the entire mass and does not compromise local structures. The tissue is then allowed to slowly thaw to  $0\text{ }^{\circ}\text{C}$  and a second cycle of freezing is performed after any necessary repositioning of the cryoprobes. Like in many of the RFA studies, the authors advocated a 0.5 cm margin of safety from major structures and that ideally the procedure should be performed at the same time as palliative bypass surgery or endoscopic biliary and duodenal stenting. Ablation of liver metastases can also be performed simultaneously<sup>[26]</sup>.

The largest experience of intraoperative and percutaneous cryoablation in pancreatic cancer has been reported from Asia. To date more than 200 patients with

**Table 3 Studies of radiofrequency ablation in pancreatic ductal adenocarcinoma**

Study	Patients	n	Route of administration	Device	RFA temp (°C)	RFA duration (min)	Outcome	Complications
Matsui <i>et al</i> <sup>[12]</sup>	Unresectable PDAC	20 LA:9 M:11	At laparotomy 4 RFA probes were inserted into the tumour 2 cm apart	A 13.56-MHz RFA pulse was produced by the heating apparatus	50	15	Survival: 3 mo	Mortality: 10% (septic shock and gastrointestinal bleeding)
Hadjicostas <i>et al</i> <sup>[14]</sup>	Locally advanced and unresectable PDAC	4	Intraoperative (followed by palliative bypass surgery)	Cool-tip™ RFA ablation system	NR	2-8	All patients were alive one year post-RFA	No complications encountered
Wu <i>et al</i> <sup>[10]</sup>	Unresectable PDAC	16 LA:11 M:5	Intraoperative	Cool-tip™ RFA ablation system	30-90	12 at 30 °C then 1 at 90 °C	Pain relief: back pain improved (6/12)	Mortality: 25% (4/16) Pancreatic fistula: 18.8% (3/16) Morbidity: 16% (biliary leak)
Spiliotis <i>et al</i> <sup>[11]</sup>	Stage III and IV PDAC receiving palliative therapy	12 LA:8 M:4	Intraoperative (followed by palliative bypass surgery)	Cool-tip™ RFA ablation system	90	5-7	Mean survival: 33 mo	Mortality: 0%
Girelli <i>et al</i> <sup>[7]</sup>	Unresectable locally advanced PDAC	50	Intraoperative (followed by palliative bypass surgery)	Cool-tip™ RFA ablation system	105 (25 pts) 90 (25 pts)	Not reported	Not reported	Morbidity 40% in the first 25 patients. Probe temperature decreased from 105°C to 90 °C Morbidity 8% in second cohort of 25 patients. 30-d mortality: 2% Morbidity: 15%. Mortality: 3%
Girelli <i>et al</i> <sup>[8]</sup>	Unresectable locally advanced PDAC	100	Intraoperative (followed by palliative bypass surgery)	Cool-tip™ RFA ablation system	90	5-10	Median overall survival: 20 mo	Morbidity: 15%. Mortality: 3%
Giardino <i>et al</i> <sup>[5]</sup>	Unresectable PDAC. 47 RFA alone. 60 had RFA + radiochemotherapy (RCT) and/or intra-arterial systemic chemotherapy (IASC)	107	Intraoperative (followed by palliative bypass surgery)	Cool-tip™ RFA ablation system	90	5-10	Median overall survival: 14.7 mo in RFA alone but 25.6 mo in those receiving RFA + RCT and/or IADC (P = 0.004)	Mortality: 1.8% (liver failure and duodenal perforation) Morbidity: 28%
Arcidiacono <i>et al</i> <sup>[19]</sup>	Locally advanced PDAC	22	EUS-guided	Cryotherm probe; bipolar RFA + cryogenic cooling	NR	2-15	Feasible in 16/22 (72.8%)	Pain (3/22)
Steel <i>et al</i> <sup>[4]</sup>	Unresectable malignant bile duct obstruction (16/22 due to PDAC)	22	RFA + SEMS placement at ERCP	Habib EndoHPB wire guided catheter	NR	Sequential 2 min treatments - median 2 (range 1-4)	Median survival: 6 mo Successful biliary decompression (21/22)	Minor bleeding (1/22) Asymptomatic biochemical pancreatitis (1/22), percutaneous gallbladder drainage (2/22). At 90-d, 2/22 had died, one with a patent SEMS
Figuerro-Barojas <i>et al</i> <sup>[42]</sup>	Unresectable malignant bile duct obstruction (7/20 due to PDAC)	20	RFA + SEMS placement at ERCP	Habib EndoHPB wire guided catheter	NR	Sequential 2 min treatments	SEMS occlusion at 90 d (3/22) Bile duct diameter increased by 3.5mm post RFA (P = 0.0001)	Abdominal pain (5/20), mild post-ERCP pancreatitis and cholecystitis (1/20)
Pai <i>et al</i> <sup>[20]</sup>	Locally advanced PDAC	7	EUS-guided	Habib EUS-RFA catheter	NR	Sequential 90s treatments - median 3 (range 2-4)	2/7 tumours decreased in size	Mild pancreatitis: (1/7)

PDAC: Pancreatic ductal adenocarcinoma; LA: Locally advanced PDAC; M: Metastatic PDAC; SEMS: Self-expanding metal stent; RFA: Radiofrequency ablation; EUS: Endoscopic ultrasound; ERCP: Endoscopic retrograde cholangiopancreatography.

**Table 4** Studies of cryoablation in pancreatic ductal adenocarcinoma

Study	n	Patients	Study	Outcome	Complications
Patiutko <i>et al</i> <sup>[25]</sup> (non-English article)	30	Locally advanced PDAC	Combination of cryosurgery and radiation	Pain relief and improvement in performance status: 30/30	Not reported
Kovach <i>et al</i> <sup>[52]</sup>	9	Unresectable PDAC	Phase I study of intraoperative cryoablation under US guidance. Four had concurrent gastrojejunostomy	7/9 discharged with non-intravenous analgesia and 1/9 discharged with no analgesia	No complications reported
Li <i>et al</i> <sup>[53]</sup> (non-English article)	44	Unresectable PDAC	Intraoperative cryoablation under US guidance	Median overall survival: 14 mo	40.9% (18/44) had delayed gastric emptying. 6.8% (3/44) had a bile and pancreatic leak
Wu <i>et al</i> <sup>[54]</sup> (non-English article)	15	Unresectable PDAC	Intraoperative cryoablation under US guidance	Median overall survival: 13.4 mo	1/15 patients developed a bile leak
Yi <i>et al</i> <sup>[55]</sup> (non-English article)	8	Unresectable PDAC	Intraoperative cryoablation under US guidance	Not reported	25% (2/8) developed delayed gastric emptying
Xu <i>et al</i> <sup>[26]</sup>	38	Locally advanced PDAC, 8 had liver metastases	Intraoperative or percutaneous cryoablation under US or CT guidance + (125) iodine seed implantation	Median overall survival: 12 mo. 19/38 (50.0%) survived more than 12 mo	Acute pancreatitis: 5/38 (one has severe pancreatitis)
Xu <i>et al</i> <sup>[56]</sup>	49	Locally advanced PDAC, 12 had liver metastases	Intraoperative or percutaneous cryoablation under US or CT guidance and (125) iodine seed implantation. Some patients also received regional celiac artery chemotherapy	Median survival: 16.2 mo. 26 patients (53.1%) survived more than 12 mo	Acute pancreatitis: 6/49 (one had severe pancreatitis)
Li <i>et al</i> <sup>[57]</sup>	68	Unresectable PDAC requiring palliative bypass	Retrospective case-series of intraoperative cryoablation under US guidance, followed by palliative bypass	Median overall survival: 30.4 mo (range 6-49 mo)	Postoperative morbidity: 42.9%. Delayed gastric emptying occurred in 35.7%
Xu <i>et al</i> <sup>[58]</sup>	59	Unresectable PDAC	Intraoperative or percutaneous cryotherapy	Median survival: 8.4 mo. Overall survival at 12 mo: 34.5%	Mild abdominal pain: 45/59 (76.3%) Major complications (bleeding, pancreatic leak): 3/59 (5%) 1/59 developed a tract metastasis
Niu <i>et al</i> <sup>[29]</sup>	36 (CT) 31 (CIT)	Metastatic PDAC	Intraoperative cryotherapy (CT) or cryoimmunotherapy (CIT) under US guidance	Median overall survival in CIT: 13 mo CT: 7 mo	Not reported

PDAC: Pancreatic ductal adenocarcinoma.

unresectable pancreatic cancer have undergone cryoablation alone or in combination with other therapies (Table 4). Effective control of pain, normalisation of CA 19-9, improvement in performance status and prolonged survival have all been reported following cryoablation. Rates of significant complications appear to be lower than in other methods of ablation. Although some patients did encounter delayed gastric emptying following the treatment, this commonly settled with conservative management within a few days. Studies to date are summarised in Table 5. The process has also been shown to initiate antiangiogenesis and a systemic immunological response, which may promote additional anti-tumour effects<sup>[27,28]</sup>. However evaluation through larger studies will be necessary to fully determine this effect.

Early clinical studies have also combined the administration of cryotherapy with immunotherapy. In a study of 106 patients with unresectable PDAC, 31 received cryoimmunotherapy, 36 cryotherapy, 17 immunotherapy and 22 chemotherapy. Median overall survival was higher in the cryoimmunotherapy (13 mo) and cryotherapy groups

(7 mo) than in the chemotherapy group (3.5 mo; both  $P < 0.001$ ) and was higher in the cryoimmunotherapy group than in the cryotherapy ( $P < 0.05$ ) and immunotherapy groups (5 mo;  $P < 0.001$ )<sup>[29]</sup>.

## LASER BASED ABLATIVE THERAPY

### Photodynamic therapy

Photodynamic therapy (PDT) results in tumour ablation by exposure to light following an intravenous injection of a photosensitiser [*e.g.*, *meso*-tetra(hydroxyphenyl)chlorin (mTHPC), porfimer sodium or verteporfin] which is taken up by cells. It leads to a predictable zone of ablation within the tumour. To date, light has been delivered *via* small optic fibers which have nearly always been positioned percutaneously under image guidance (*e.g.*, CT)<sup>[30-32]</sup>. However these fibers can pass through a 19G needle, so administration under endoscopic ultrasound guidance is feasible.

The first Phase I trial of PDT in locally advanced PDAC was conducted in 2002. Substantial tumour necro-

**Table 5 Studies of photodynamic therapy in pancreatic ductal adenocarcinoma**

Study	<i>n</i>	Study	Photosensitiser	Number of fibres	Number of ablations	Outcome and survival	Complications
Bown <i>et al</i> <sup>[30]</sup>	16	CT guided percutaneous PDT to locally advanced but inoperable PDAC without metastatic disease	mTH-PC	Single	1	Tumour necrosis: 16/16. Median survival: 9.5 mo. 44% (7/16) survived > 1 year	Significant gastrointestinal bleeding: 2/16 (controlled without surgery)
Huggett <i>et al</i> <sup>[31,32]</sup>	13 + 2	CT guided percutaneous PDT to locally advanced but inoperable PDAC without metastatic disease	Verteporfrin	Single (13) Multiple (2)	1	Technically feasible: 15/15. Dose dependent necrosis occurred	Single fibre: No complications. Multiple fibres: CT evidence of inflammatory change anterior to the pancreas, no clinical sequelae

PDAC: Pancreatic ductal adenocarcinoma; CT: Computed tomography.

sis was achieved in all 16 patients included in the study. Median survival after PDT was 9.5 mo (range 4-30 mo). 44% (7/16) were alive one year after PDT. Two of the patients who had a pancreatic tumor which involved the gastroduodenal artery developed significant gastrointestinal bleeding following the procedure. However both were managed endoscopically with transfusion, without the need for surgery<sup>[30]</sup>.

A significant drawback of the early PDT treatments was that patients had to spend several days in subdued lighting following the treatment to prevent complications from skin necrosis. However, newer photosensitisers with a shorter drug-light interval and faster drug elimination time have been developed (*e.g.*, verteporfrin) and have been shown in preclinical and early clinical studies to have a similar efficacy and safety profile to mTHPC<sup>[33]</sup>. A Phase I study by our group evaluated verteporfrin-mediated PDT in 15 patients with unresectable locally advanced pancreatic cancer (Vertpac-01) (Table 5)<sup>[31,32]</sup>. The study was designed in 2 parts: the first 13 patients were treated with a single-fibre, with the following 2 patients being treated with light from multiple fibers. A predictable zone of necrosis surrounding the fibers was achieved. No instances of photosensitivity were reported and only one patient developed cholangitis. Patient went on to receive palliative gemcitabine chemotherapy 28 d after ablation.

### YAG Laser

The neodymium-doped yttrium aluminium garnet (Nd:YAG) laser has been used to ablate pancreatic tumours in animal models<sup>[34]</sup>. A well demarcated area of necrosis and no complications were achieved, suggesting the potential for this therapy, but to date there have been no clinical studies.

## NON-THERMAL, NON-LASER METHODS OF ABLATION

Many of the studies of thermal and light ablation techniques in locally advanced and metastatic PDAC have sug-

gested that cytoreduction may improve survival. However in the initial clinical studies some of the techniques were associated with unacceptably high rates of complications. This has led to a search for non-thermal alternative ablative therapies for use in PDAC.

### High-intensity focused ultrasound

High intensity focused ultrasound (HIFU) therapy is a non-invasive method of ablation. Ultrasound energy from an extracorporeal source is focused on the pancreatic tumour to induce thermal denaturation of tissue without affecting surrounding organs<sup>[35]</sup>. Multiple non-randomised studies and case series, largely from Asia, have reported preliminary clinical experiences of using HIFU in PDAC. They have demonstrated that the technique is able to achieve tumour necrosis with relatively few side effects (Table 6). Recently a HIFU transducer has been designed which can be attached to an EUS scope to deliver HIFU locally to pancreatic tumours, thus preventing occasional burns to the skin. Initial animal studies have demonstrated that it can successfully abate the normal pancreas and liver<sup>[36]</sup>.

### Irreversible electroporation

NanoKnife® (Angiodynamics, Inc., NY, United States) or irreversible electroporation (IRE) is an emerging non-thermal ablative technique which uses electrodes, placed in the tumour, to deliver up to 3 kV of direct current. This induces the formation of nanoscale pores within the cell membrane of the targeted tissue, which irreversibly damages the cell's homeostatic mechanism, causing apoptosis. The United States Food and Drug Administration have recently approved the technique for use in the pancreas.

One of the major advantages of this technique is that it can be used in tumours that are in close proximity to peri-pancreatic vessels without risk of vascular trauma. The largest series of percutaneous IRE in PDAC includes 14 patients who had unresectable tumours and were not candidates for, or were intolerant of standard therapy<sup>[37]</sup>. The procedure was performed under general anaesthesia with complete muscle paralysis. Two patients

**Table 6 Studies of high intensity focused ultrasound in pancreatic ductal adenocarcinoma**

Study	<i>n</i>	Study	Outcome and survival	Complications
Wang <i>et al</i> <sup>[59]</sup> (non-English article)	15	HIFU monotherapy in late stage PDAC	Pain relief: 13/13 (100%)	Mild abdominal pain (2/15)
Xie <i>et al</i> <sup>[60]</sup> (non-English article)	41	HIFU alone <i>vs</i> HIFU + gemcitabine in locally advanced PDAC	Pain relief: HIFU (66.7%), HIFU + gemcitabine (76.6%)	None
Xu <i>et al</i> <sup>[61]</sup> (non-English article)	37	HIFU monotherapy in advanced PDAC	Pain relief: 24/30 (80%)	None
Yuan <i>et al</i> <sup>[62]</sup> (non-English article)	40	HIFU monotherapy	Pain relief: 32/40 (80%)	None
Wu <i>et al</i> <sup>[63]</sup>	8	HIFU in advanced PDAC	Median survival: 11.25 mo Pain relief: 8/8	None
Xiong <i>et al</i> <sup>[64]</sup>	89	HIFU in unresectable PDAC	Median survival: 26.0 mo (stage II), 11.2 mo (stage III) and 5.4 mo (stage IV)	Superficial skin burns (3.4%), subcutaneous fat sclerosis (6.7%), asymptomatic pseudocyst (1.1%)
Zhao <i>et al</i> <sup>[65]</sup>	37	Phase II study of gemcitabine + HIFU in locally advanced PDAC	Overall survival: 12.6 mo (95%CI: 10.2-15.0 mo) Pain relief: 78.6%	16.2% experienced grade 3 or 4 neutropenia, 5.4% developed grade 3 thrombocytopenia, 8% had nausea vomiting
Orsi <i>et al</i> <sup>[66]</sup>	6	HIFU in unresectable PDAC	Pain relief: 6/6 (100%)	Portal vein thrombosis (1/6)
Sung <i>et al</i> <sup>[67]</sup>	46	Stage III or IV PDAC	Median survival: 12.4 mo. Overall survival at 12 mo was 30.4%	Minor complications (abdominal pain, fever and nausea): 57.1% (28/29) Major complications (pancreaticoduodenal fistula, gastric ulcer or skin burns): 10.2% (5/49)
Wang <i>et al</i> <sup>[68]</sup>	40	Advanced PDAC	Median overall survival: 10 mo (stage III) and 6 mo (stage IV). Pain relief: 35/40 (87.5%)	None
Lee <i>et al</i> <sup>[69]</sup>	12	HIFU monotherapy in unresectable PDAC (3/12 received chemotherapy)	Median overall survival for those receiving HIFU alone (9/12 patients): 10.3 mo	Pancreatitis: 1/12
Li <i>et al</i> <sup>[70]</sup>	25	Unresectable PDAC	Median overall survival: 10 mo. 42% survived more than 1 year. Perform- ance status and pain levels improved: 23/25	1 <sup>st</sup> degree skin burn: 12% Mortality: 0%
Wang <i>et al</i> <sup>[71]</sup>	224	Advanced PDAC	Not reported	Abdominal distension, anorexia and nausea: 10/ 224 (4.5%). Asymptomatic vertebral injury: 2/224
Gao <i>et al</i> <sup>[72]</sup>	39	Locally advanced PDAC	Pain relief: 79.5% Median overall survival: 11 mo. 30.8% survived more than one year	None

HIFU: High intensity focused ultrasound; PDAC: Pancreatic ductal adenocarcinoma.

subsequently underwent surgery after IRE and both had margin-negative resections; both remain disease-free after 11 and 14 mo, respectively. Complications included spontaneous pneumothorax during anaesthesia ( $n = 1$ ) and pancreatitis ( $n = 1$ ); both patients recovered completely. No deaths were related to the procedure but the three patients with metastatic disease subsequently died from disease progression.

## COMBINING ABLATIVE THERAPIES WITH BILIARY STENTING

Tumours of the head of the pancreas commonly cause distal biliary obstruction, which is managed in most cases by an endoscopically inserted self-expanding metal stent (SEMS). However due to tumour ingrowth SEMS are associated with a shorter patency time than bypass surgery. Hence there has been a growth in interest in using ablative therapies such as PDT or RFA to prolong stent

patency or to unblock a SEMS, which is already *in situ*. Randomised studies comparing PDT with biliary stenting to stenting alone have had conflicting results. Initial studies reported prolonged stent patency and improved survival after PDT<sup>[38,39]</sup>. However, a recent UK phase III study closed early as overall survival was longer in those treated with stenting alone<sup>[40]</sup>. The use of RFA in combination with SEMS placement has been reported in two small studies to date (Table 3). The investigators showed that the median bile duct diameter increased following endobiliary RFA and that 86% (19/22) of the SEMS were patent at 90 d<sup>[41,42]</sup>. Emerging evidence also suggests that endobiliary RFA may confer some early survival benefit in patients with malignant biliary obstruction independent of stent blockage and chemotherapy<sup>[41]</sup>. Occasionally centres have used RFA alone to achieve biliary drainage but results of on-going randomised controlled trials are awaited for validation of this technique<sup>[43]</sup>. Current guidance from the National Institute for Health and Care Excellence in the United Kingdom recommends



that this treatment should only be carried out in specialist centres in the context of clinical trials<sup>[44]</sup>.

## ENDOSCOPIC ULTRASOUND GUIDED NON-ABLATIVE LOCAL THERAPIES

Systemic chemotherapy agents are often associated with significant side effects, which can result in patients having to stop therapy or undergo dose reduction. Several groups have therefore explored using local anti-tumour agents in PDAC. The outcomes are summarised in Table 2.

## PREMALIGNANT LESIONS OF THE PANCREAS

Some investigators have used similar ablative methods in PDAC to ablate premalignant solid and cystic lesions of the pancreas. Cystic lesions of the pancreas are an increasingly common clinical finding and some possess premalignant potential; longterm surveillance or surgery or pancreatic surgery is therefore recommended in accordance with international guidance<sup>[45]</sup>. Given the morbidity of surgery and uncertainties of surveillance for essentially benign disease, minimally invasive ablative therapies are increasingly becoming an attractive alternative treatment.

An EUS-guided injection of alcohol has been reported to have reasonable efficacy for achieving complete ablation of pancreatic cystic tumours (35%-62%). However, total cyst ablation was rare in septated cysts and the technique was associated with complications (pain and pancreatitis) in between 4%-20% of cases<sup>[46,47]</sup>. Occasional case reports have described using EUS guided alcohol injection to successfully ablate hepatic metastases<sup>[48]</sup> and pancreatic gastrointestinal stromal tumours<sup>[49]</sup>. Small case series have demonstrated EUS guided RFA can also be used safely for this indication<sup>[21]</sup>. Further validation will come from larger Phase II studies.

## CONCLUSION

Ablative therapies for unresectable pancreatic cancer are an attractive emerging therapy. All studies demonstrated that ablation is feasible and reproducible. Many of the early concerns that surrounded safety have been addressed with device development and modification of technique. Long-term survival data for many of the techniques is absent currently. Ultimately large prospective randomised studies will be required to assess the efficacy of these techniques and define their position in future treatment algorithms for the management of locally advanced pancreatic cancer.

## REFERENCES

- 1 **Cancer Research UK.** Pancreatic cancer statistics 2010. Available from: URL: <http://www.cancerresearchuk.org/cancer-info/cancerstats/types/pancreas>
- 2 **Cunningham D,** Chau I, Stocken DD, Valle JW, Smith D,

Steward W, Harper PG, Dunn J, Tudur-Smith C, West J, Falk S, Crellin A, Adab F, Thompson J, Leonard P, Ostrowski J, Eatock M, Scheithauer W, Herrmann R, Neoptolemos JP. Phase III randomized comparison of gemcitabine versus gemcitabine plus capecitabine in patients with advanced pancreatic cancer. *J Clin Oncol* 2009; **27**: 5513-5518 [PMID: 19858379]

- 3 **Conroy T,** Desseigne F, Ychou M, Bouché O, Guimbaud R, Bécouarn Y, Adenis A, Raoul JL, Gourgou-Bourgade S, de la Fouchardière C, Bennouna J, Bachel JB, Khemissa-Akouz F, Péré-Vergé D, Delbaldo C, Assenat E, Chauffert B, Michel P, Montoto-Grillot C, Ducreux M. FOLFIRINOX versus gemcitabine for metastatic pancreatic cancer. *N Engl J Med* 2011; **364**: 1817-1825 [PMID: 21561347 DOI: 10.1056/NEJMoa1011923]
- 4 **VonHoff DD,** Ervin TJ, Arena FP, Chiorean EG, Infante JR, Moore MJ, Seay TE, Tjulandin S, Ma WW, Saleh MN, Harris M, Reni M, Ramanathan RK, Taberero J, Hidalgo M, Van Cutsem E, Goldstein D, Wei X, Iglesias JL, Renschler MF. Randomized phase III study of weekly nab-paclitaxel plus gemcitabine vs gemcitabine alone in patients with metastatic adenocarcinoma of the pancreas (MPACT). *J Clin Oncol* 2013; **30** suppl 34: abstr LBA148
- 5 **Gillen S,** Schuster T, Friess H, Kleeff J. Palliative resections versus palliative bypass procedures in pancreatic cancer—a systematic review. *Am J Surg* 2012; **203**: 496-502 [PMID: 21872208 DOI: 10.1016/j.amjsurg.2011.05.004]
- 6 **Llovet JM,** Brú C, Bruix J. Prognosis of hepatocellular carcinoma: the BCLC staging classification. *Semin Liver Dis* 1999; **19**: 329-338 [PMID: 10518312 DOI: 10.1055/s-2007-1007122]
- 7 **Girelli R,** Frigerio I, Salvia R, Barbi E, Tinazzi Martini P, Bassi C. Feasibility and safety of radiofrequency ablation for locally advanced pancreatic cancer. *Br J Surg* 2010; **97**: 220-225 [PMID: 20069610 DOI: 10.1002/bjs.6800]
- 8 **Goldberg SN,** Mallery S, Gazelle GS, Brugge WR. EUS-guided radiofrequency ablation in the pancreas: results in a porcine model. *Gastrointest Endosc* 1999; **50**: 392-401 [PMID: 10462663 DOI: 10.1053/ge.1999.v50.98847]
- 9 **Date RS,** Siriwardena AK. Radiofrequency ablation of the pancreas. II: Intra-operative ablation of non-resectable pancreatic cancer. A description of technique and initial outcome. *JOP* 2005; **6**: 588-592 [PMID: 16286710]
- 10 **Wu Y,** Tang Z, Fang H, Gao S, Chen J, Wang Y, Yan H. High operative risk of cool-tip radiofrequency ablation for unresectable pancreatic head cancer. *J Surg Oncol* 2006; **94**: 392-395 [PMID: 16967436 DOI: 10.1002/jso.20580]
- 11 **Spiliotis JD,** Datsis AC, Michalopoulos NV, Kekelos SP, Vaxevanidou A, Rogdakis AG, Christopoulou AN. Radiofrequency ablation combined with palliative surgery may prolong survival of patients with advanced cancer of the pancreas. *Langenbecks Arch Surg* 2007; **392**: 55-60 [PMID: 17089173 DOI: 10.1007/s00423-006-0098-5]
- 12 **Matsui Y,** Nakagawa A, Kamiyama Y, Yamamoto K, Kubo N, Nakase Y. Selective thermocoagulation of unresectable pancreatic cancers by using radiofrequency capacitive heating. *Pancreas* 2000; **20**: 14-20 [PMID: 10630378]
- 13 **Elias D,** Baton O, Sideris L, Lasser P, Pocard M. Necrotizing pancreatitis after radiofrequency destruction of pancreatic tumours. *Eur J Surg Oncol* 2004; **30**: 85-87 [PMID: 14736529]
- 14 **Hadjicostas P,** Malakounides N, Varianos C, Kitaris E, Lermi F, Symeonides P. Radiofrequency ablation in pancreatic cancer. *HPB (Oxford)* 2006; **8**: 61-64 [PMID: 18333241 DOI: 10.1080/13651820500466673]
- 15 **Date RS,** McMahon RF, Siriwardena AK. Radiofrequency ablation of the pancreas. I: Definition of optimal thermal kinetic parameters and the effect of simulated portal venous circulation in an ex-vivo porcine model. *JOP* 2005; **6**: 581-587 [PMID: 16286709]
- 16 **Tang Z,** Wu YL, Fang HQ, Xu J, Mo GQ, Chen XM, Gao SL, Li JT, Liu YB, Wang Y. Treatment of unresectable pancreatic

- carcinoma by radiofrequency ablation with 'cool-tip needle': report of 18 cases. *Zhonghua Yi Xue Za Zhi* 2008; **88**: 391-394 [PMID: 18581892]
- 17 **Varshney S**, Sewkani A, Sharma S, Kapoor S, Naik S, Sharma A, Patel K. Radiofrequency ablation of unresectable pancreatic carcinoma: feasibility, efficacy and safety. *JOP* 2006; **7**: 74-78 [PMID: 16407624]
  - 18 **Siriwardena AK**. Radiofrequency ablation for locally advanced cancer of the pancreas. *JOP* 2006; **7**: 1-4 [PMID: 16407612]
  - 19 **Arcidiacono PG**, Carrara S, Reni M, Petrone MC, Cappio S, Balzano G, Boemo C, Cereda S, Nicoletti R, Enderle MD, Neugebauer A, von Renteln D, Eickhoff A, Testoni PA. Feasibility and safety of EUS-guided cryothermal ablation in patients with locally advanced pancreatic cancer. *Gastrointest Endosc* 2012; **76**: 1142-1151 [PMID: 23021160 DOI: 10.1016/j.gie.2012.08.006]
  - 20 **Pai M**, Yang J, Zhang X, Jin Z, Wang D, Senturk H, Lakhtakia S, Reddy DN, Kahaleh M, Habib N, Brugge WR. Endoscopic ultrasound guided radiofrequency ablation (EUS-RFA) for pancreatic ductal adenocarcinoma. *Gut* 2013; **62** (Suppl 1): A153
  - 21 **Pai M**, Senturk H, Lakhtakia S, Reddy DN, Cicinnati C, Kabar I, Beckebaum S, Jin Z, Wang D, Yang J, Zhang X, Habib N, Brugge WR. Endoscopic Ultrasound Guided Radiofrequency Ablation (EUS-RFA) for Cystic Neoplasms and Neuroendocrine Tumours of the Pancreas. *Gastrointest Endosc* 2013; **77** (5S): AB143-AB144
  - 22 **Carrafiello G**, Ierardi AM, Fontana F, Petrillo M, Floridi C, Lucchina N, Cuffari S, Dionigi G, Rotondo A, Fugazzola C. Microwave ablation of pancreatic head cancer: safety and efficacy. *J Vasc Interv Radiol* 2013; **24**: 1513-1520 [PMID: 24070507 DOI: 10.1016/j.jvir.2013.07.005]
  - 23 **Lygidakis NJ**, Sharma SK, Papastratis P, Zivanovic V, Kefalourous H, Koshariya M, Lintzeris I, Porfirris T, Koutsiouroumba D. Microwave ablation in locally advanced pancreatic carcinoma--a new look. *Hepatogastroenterology* 2007; **54**: 1305-1310 [PMID: 17708242]
  - 24 **Myers RS**, Hammond WG, Ketcham AS. Cryosurgery of primate pancreas. *Cancer* 1970; **25**: 411-414 [PMID: 4983998]
  - 25 **Patiutko IuI**, Barkanov AI, Kholikov TK, Lagoshnyi AT, Li LI, Samoilenko VM, Afrikan MN, Savel'eva EV. The combined treatment of locally disseminated pancreatic cancer using cryosurgery. *Vopr Onkol* 1991; **37**: 695-700 [PMID: 1843146]
  - 26 **Xu KC**, Niu LZ, Hu YZ, He WB, He YS, Zuo JS. Cryosurgery with combination of (125)iodine seed implantation for the treatment of locally advanced pancreatic cancer. *J Dig Dis* 2008; **9**: 32-40 [PMID: 18251792 DOI: 10.1111/j.1443-9573.2007.00322.x]
  - 27 **Korpan NN**. Cryosurgery: ultrastructural changes in pancreas tissue after low temperature exposure. *Technol Cancer Res Treat* 2007; **6**: 59-67 [PMID: 17375968]
  - 28 **Joosten JJ**, Muijen GN, Wobbes T, Ruers TJ. In vivo destruction of tumor tissue by cryoablation can induce inhibition of secondary tumor growth: an experimental study. *Cryobiology* 2001; **42**: 49-58 [PMID: 11336489 DOI: 10.1006/cryo.2001.2302]
  - 29 **Niu L**, Chen J, He L, Liao M, Yuan Y, Zeng J, Li J, Zuo J, Xu K. Combination treatment with comprehensive cryoablation and immunotherapy in metastatic pancreatic cancer. *Pancreas* 2013; **42**: 1143-1149 [PMID: 23899940 DOI: 10.1097/MPA.0b013e3182965dde]
  - 30 **Bown SG**, Rogowska AZ, Whitelaw DE, Lees WR, Lovat LB, Ripley P, Jones L, Wyld P, Gillams A, Hatfield AW. Photodynamic therapy for cancer of the pancreas. *Gut* 2002; **50**: 549-557 [PMID: 11889078]
  - 31 **Huggett MT**, Jermyn M, Gillams A, Mosse S, Kent E, Bown SG, Hasan T, Pogue BW, Pereira SP. Photodynamic therapy of locally advanced pancreatic cancer (VERTPAC study): Final clinical results. *Progress in Biomedical Optics and Imaging - Proceedings of SPIE* 2013; **8568**
  - 32 **Huggett MT**, Jermyn M, Gillams A, Mosse S, Kent E, Bown SG, Hasan T, Pogue BW, Pereira SP. Photodynamic therapy for locally advanced pancreatic cancer (VERTPAC study): final clinical results. *Pancreatology* 2013; **13**: e2-e3
  - 33 **Ayaru L**, Wittmann J, Macrobert AJ, Novelli M, Bown SG, Pereira SP. Photodynamic therapy using verteporfin photosensitization in the pancreas and surrounding tissues in the Syrian golden hamster. *Pancreatology* 2007; **7**: 20-27 [PMID: 17449962]
  - 34 **Di Matteo F**, Martino M, Rea R, Pandolfi M, Rabitti C, Masselli GM, Silvestri S, Pacella CM, Papini E, Panzera F, Valeri S, Coppola R, Costamagna G. EUS-guided Nd: YAG laser ablation of normal pancreatic tissue: a pilot study in a pig model. *Gastrointest Endosc* 2010; **72**: 358-363 [PMID: 20541187 DOI: 10.1016/j.gie.2010.02.027]
  - 35 **Leslie T**, Ritchie R, Illing R, Ter Haar G, Phillips R, Middleton M, Bch B, Wu F, Cranston D. High-intensity focused ultrasound treatment of liver tumours: post-treatment MRI correlates well with intra-operative estimates of treatment volume. *Br J Radiol* 2012; **85**: 1363-1370 [PMID: 22700259 DOI: 10.1259/bjr/56737365]
  - 36 **Hwang J**, Farr N, Morrison K. Development of an EUS-guided high-intensity focused ultrasound endoscope. *Gastrointest Endosc* 2011; **73** (4S): AB155
  - 37 **Narayanan G**, Hosein PJ, Arora G, Barbery KJ, Froud T, Livingstone AS, Franceschi D, Rocha Lima CM, Yrizarry J. Percutaneous irreversible electroporation for downstaging and control of unresectable pancreatic adenocarcinoma. *J Vasc Interv Radiol* 2012; **23**: 1613-1621 [PMID: 23177107 DOI: 10.1016/j.jvir.2012.09.012]
  - 38 **Zoepf T**, Jakobs R, Arnold JC, Apel D, Riemann JF. Palliation of nonresectable bile duct cancer: improved survival after photodynamic therapy. *Am J Gastroenterol* 2005; **100**: 2426-2430 [PMID: 16279895 DOI: 10.1111/j.1572-0241.2005.00318.x]
  - 39 **Gerhardt T**, Rings D, Höblinger A, Heller J, Sauerbruch T, Schepke M. Combination of bilateral metal stenting and trans-stent photodynamic therapy for palliative treatment of hilar cholangiocarcinoma. *Z Gastroenterol* 2010; **48**: 28-32 [PMID: 20072993 DOI: 10.1055/s-0028-1109983]
  - 40 **Pereira SP**, Hughes SK, Roughton M, O'Donoghue P, Wasan HS, Valle J, Bridgewater J. Photostent-02: porfimer sodium photodynamic therapy plus stenting alone in patients (pts) with advanced or metastatic cholangiocarcinomas and other biliary tract tumours (BTC): a multicentre, randomised phase III trial [abstract]; 2010 Oct 8-12; London. Milan, Italy: ESMO, 2010: Abstract 8020
  - 41 **Steel AW**, Postgate AJ, Khorsandi S, Nicholls J, Jiao L, Vlavianos P, Habib N, Westaby D. Endoscopically applied radiofrequency ablation appears to be safe in the treatment of malignant biliary obstruction. *Gastrointest Endosc* 2011; **73**: 149-153 [PMID: 21184881 DOI: 10.1016/j.gie.2010.09.031]
  - 42 **Figuerola-Barojas P**, Bakhru MR, Habib NA, Ellen K, Millman J, Jamal-Kabani A, Gaidhane M, Kahaleh M. Safety and efficacy of radiofrequency ablation in the management of unresectable bile duct and pancreatic cancer: a novel palliation technique. *J Oncol* 2013; **2013**: 910897 [PMID: 23690775 DOI: 10.1155/2013/910897]
  - 43 **Shariff MI**, Khan SA, Westaby D. The palliation of cholangiocarcinoma. *Curr Opin Support Palliat Care* 2013; **7**: 168-174 [PMID: 23422512 DOI: 10.1097/SPC.0b013e32835f1e2f]
  - 44 **The National Institute for Health and Care Excellence**. Using radiofrequency energy to treat malignant bile or pancreatic duct obstructions caused by cholangiocarcinoma or pancreatic adenocarcinoma 2013. Available from: URL: <http://guidance.nice.org.uk/IPG464/DraftGuidance>
  - 45 **Tanaka M**, Fernández-del Castillo C, Adsay V, Chari S, Falconi M, Jang JY, Kimura W, Levy P, Pitman MB, Schmidt CM, Shimizu M, Wolfgang CL, Yamaguchi K, Yamao K. In-

- ternational consensus guidelines 2012 for the management of IPMN and MCN of the pancreas. *Pancreatology* 2012; **12**: 183-197 [PMID: 22687371 DOI: 10.1016/j.pan.2012.04.004]
- 46 **Gan SI**, Thompson CC, Lauwers GY, Bounds BC, Brugge WR. Ethanol lavage of pancreatic cystic lesions: initial pilot study. *Gastrointest Endosc* 2005; **61**: 746-752 [PMID: 15855986]
- 47 **Oh HC**, Seo DW, Song TJ, Moon SH, Park do H, Soo Lee S, Lee SK, Kim MH, Kim J. Endoscopic ultrasonography-guided ethanol lavage with paclitaxel injection treats patients with pancreatic cysts. *Gastroenterology* 2011; **140**: 172-179 [PMID: 20950614]
- 48 **Barclay RL**, Perez-Miranda M, Giovannini M. EUS-guided treatment of a solid hepatic metastasis. *Gastrointest Endosc* 2002; **55**: 266-270 [PMID: 11818938 DOI: 10.1067/mge.2002.120784]
- 49 **Günter E**, Lingenfeller T, Eitelbach F, Müller H, Ell C. EUS-guided ethanol injection for treatment of a GI stromal tumor. *Gastrointest Endosc* 2003; **57**: 113-115 [PMID: 12518147 DOI: 10.1067/mge.2003.39]
- 50 **Girelli R**, Giardino A, Frigerio I, Salvia R, Partelli S, Bassi C. Survival after radiofrequency of stage III pancreatic carcinoma: a wind of change? *HPB (Oxford)* 2011; **13** (Suppl 2): 15
- 51 **Giardino A**, Girelli R, Frigerio I, Regi P, Cantore M, Alessandra A, Lusenti A, Salvia R, Bassi C, Pederzoli P. Triple approach strategy for patients with locally advanced pancreatic carcinoma. *HPB (Oxford)* 2013; **15**: 623-627 [PMID: 23458679 DOI: 10.1111/hpb.12027]
- 52 **Kovach SJ**, Hendrickson RJ, Cappadona CR, Schmidt CM, Groen K, Koniaris LG, Sitzmann JV. Cryoablation of unresectable pancreatic cancer. *Surgery* 2002; **131**: 463-464 [PMID: 11935137]
- 53 **Li B**, Li JD, Chen XL, Zeng Y, Wen TF, Hu WM, Yan LN. Cryosurgery for unresectable pancreatic carcinoma: a report of 44 cases. *Zhonghua Gandan Waike Zazhi* 2004; **10**: 523-525
- 54 **Wu Q**, Zhang JX, Qian JX, Xu Q, Wang JJ. The application of surgical treatment in combination with targeted cryoablation on advanced carcinoma of head of pancreas: a report of 15 cases. *Zhongguo Zhongliu Linchuang* 2005; **32**: 1403-1405
- 55 **Yi FT**, Song HZ, Li J. Intraoperative Ar-He targeted cryoablation for advanced pancreatic carcinoma. *Zhonghua Gandan Waike Zazhi* 2006; **12**: 186-187
- 56 **Xu KC**, Niu LZ, Hu YZ, He WB, He YS, Li YF, Zuo JS. A pilot study on combination of cryosurgery and (125)iodine seed implantation for treatment of locally advanced pancreatic cancer. *World J Gastroenterol* 2008; **14**: 1603-1611 [PMID: 18330956]
- 57 **Li J**, Chen X, Yang H, Wang X, Yuan D, Zeng Y, Wen T, Yan L, Li B. Tumour cryoablation combined with palliative bypass surgery in the treatment of unresectable pancreatic cancer: a retrospective study of 142 patients. *Postgrad Med J* 2011; **87**: 89-95 [PMID: 21131612 DOI: 10.1136/pgmj.2010.098350]
- 58 **Xu K**, Niu L, Yang D. Cryosurgery for pancreatic cancer. *Gland Surgery* 2013; **2**: 30-39
- 59 **Wang X**, Sun J. High-intensity focused ultrasound in patients with late-stage pancreatic carcinoma. *Chin Med J (Engl)* 2002; **115**: 1332-1335 [PMID: 12411106]
- 60 **Xie DR**, Chen D, Teng H. A multicenter non-randomized clinical study of high intensity focused ultrasound in treating patients with local advanced pancreatic carcinoma. *Zhongguo Zhongliu Linchuang* 2003; **30**: 630-634
- 61 **Xu YQ**, Wang GM, Gu YZ, Zhang HF. The acesodyne effect of high intensity focused ultrasound on the treatment of advanced pancreatic carcinoma. *Zhongguo Linchuang Yixue* 2003; **10**: 322-323
- 62 **Yuan C**, Yang L, Yao C. Observation of high intensity focused ultrasound treating 40 cases of pancreatic cancer. *Linchuang Gandanbing Zazhi* 2003; **19**: 145-146
- 63 **Wu F**, Wang ZB, Zhu H, Chen WZ, Zou JZ, Bai J, Li KQ, Jin CB, Xie FL, Su HB. Feasibility of US-guided high-intensity focused ultrasound treatment in patients with advanced pancreatic cancer: initial experience. *Radiology* 2005; **236**: 1034-1040 [PMID: 16055692 DOI: 10.1148/radiol.2362041105]
- 64 **Xiong LL**, Hwang JH, Huang XB, Yao SS, He CJ, Ge XH, Ge HY, Wang XF. Early clinical experience using high intensity focused ultrasound for palliation of inoperable pancreatic cancer. *JOP* 2009; **10**: 123-129 [PMID: 19287104]
- 65 **Zhao H**, Yang G, Wang D, Yu X, Zhang Y, Zhu J, Ji Y, Zhong B, Zhao W, Yang Z, Aziz F. Concurrent gemcitabine and high-intensity focused ultrasound therapy in patients with locally advanced pancreatic cancer. *Anticancer Drugs* 2010; **21**: 447-452 [PMID: 20075714 DOI: 10.1097/CAD.0b013e32833641a7]
- 66 **Orsi F**, Zhang L, Arnone P, Orgera G, Bonomo G, Vigna PD, Monfardini L, Zhou K, Chen W, Wang Z, Veronesi U. High-intensity focused ultrasound ablation: effective and safe therapy for solid tumors in difficult locations. *AJR Am J Roentgenol* 2010; **195**: W245-W252 [PMID: 20729423 DOI: 10.2214/ajr.09.3321]
- 67 **Sung HY**, Jung SE, Cho SH, Zhou K, Han JY, Han ST, Kim JL, Kim JK, Choi JY, Yoon SK, Yang JM, Han CW, Lee YS. Long-term outcome of high-intensity focused ultrasound in advanced pancreatic cancer. *Pancreas* 2011; **40**: 1080-1086 [PMID: 21926543 DOI: 10.1097/MPA.0b013e31821fde24]
- 68 **Wang K**, Chen Z, Meng Z, Lin J, Zhou Z, Wang P, Chen L, Liu L. Analgesic effect of high intensity focused ultrasound therapy for unresectable pancreatic cancer. *Int J Hyperthermia* 2011; **27**: 101-107 [PMID: 21219135 DOI: 10.3109/02656736.2010.525588]
- 69 **Lee JY**, Choi BI, Ryu JK, Kim YT, Hwang JH, Kim SH, Han JK. Concurrent chemotherapy and pulsed high-intensity focused ultrasound therapy for the treatment of unresectable pancreatic cancer: initial experiences. *Korean J Radiol* 2011; **12**: 176-186 [PMID: 21430934 DOI: 10.3348/kjr.2011.12.2.176]
- 70 **Li PZ**, Zhu SH, He W, Zhu LY, Liu SP, Liu Y, Wang GH, Ye F. High-intensity focused ultrasound treatment for patients with unresectable pancreatic cancer. *Hepatobiliary Pancreat Dis Int* 2012; **11**: 655-660 [PMID: 23232639]
- 71 **Wang K**, Zhu H, Meng Z, Chen Z, Lin J, Shen Y, Gao H. Safety evaluation of high-intensity focused ultrasound in patients with pancreatic cancer. *Onkologie* 2013; **36**: 88-92 [PMID: 23485995 DOI: 10.1159/000348530]
- 72 High Intensity Focused Ultrasound Treatment for Patients with Local Advanced Pancreatic Cancer. *Hepatogastroenterology* 2013; **60**: Epub ahead of print [PMID: 24088318 DOI: 10.5754/hge13498]
- 73 **Oh HC**, Seo DW, Lee TY, Kim JY, Lee SS, Lee SK, Kim MH. New treatment for cystic tumors of the pancreas: EUS-guided ethanol lavage with paclitaxel injection. *Gastrointest Endosc* 2008; **67**: 636-642 [PMID: 18262182 DOI: 10.1016/j.gie.2007.09.038]
- 74 **Oh HC**, Seo DW, Kim SC, Yu E, Kim K, Moon SH, Park do H, Lee SS, Lee SK, Kim MH. Septated cystic tumors of the pancreas: is it possible to treat them by endoscopic ultrasonography-guided intervention? *Scand J Gastroenterol* 2009; **44**: 242-247 [PMID: 18949629 DOI: 10.1080/00365520802495537]
- 75 **DeWitt J**, McGreevy K, Schmidt CM, Brugge WR. EUS-guided ethanol versus saline solution lavage for pancreatic cysts: a randomized, double-blind study. *Gastrointest Endosc* 2009; **70**: 710-723 [PMID: 19577745 DOI: 10.1016/j.gie.2009.03.1173]
- 76 **Levy MJ**, Thompson GB, Topazian MD, Callstrom MR, Grant CS, Vella A. US-guided ethanol ablation of insulinomas: a new treatment option. *Gastrointest Endosc* 2012; **75**: 200-206 [PMID: 22078104 DOI: 10.1016/j.gie.2011.09.019]
- 77 **Chang KJ**, Nguyen PT, Thompson JA, Kurosaki TT, Casey LR, Leung EC, Granger GA. Phase I clinical trial of allogeneic mixed lymphocyte culture (cytoimplant) delivered by endoscopic ultrasound-guided fine-needle injection in pa-

- tients with advanced pancreatic carcinoma. *Cancer* 2000; **88**: 1325-1335 [PMID: 10717613]
- 78 **Hecht JR**, Bedford R, Abbruzzese JL, Lahoti S, Reid TR, Soetikno RM, Kirn DH, Freeman SM. A phase I/II trial of intratumoral endoscopic ultrasound injection of ONYX-015 with intravenous gemcitabine in unresectable pancreatic carcinoma. *Clin Cancer Res* 2003; **9**: 555-561 [PMID: 12576418]
- 79 **Hecht JR**, Farrell JJ, Senzer N, Nemunaitis J, Rosemurgy A, Chung T, Hanna N, Chang KJ, Javle M, Posner M, Waxman I, Reid A, Erickson R, Canto M, Chak A, Blatner G, Kovacevic M, Thornton M. EUS or percutaneously guided intratumoral TNFerade biologic with 5-fluorouracil and radiotherapy for first-line treatment of locally advanced pancreatic cancer: a phase I/II study. *Gastrointest Endosc* 2012; **75**: 332-338 [PMID: 22248601 DOI: 10.1016/j.gie.2011.10.007]
- 80 **Chang KJ**, Lee JG, Holcombe RF, Kuo J, Muthusamy R, Wu ML. Endoscopic ultrasound delivery of an antitumor agent to treat a case of pancreatic cancer. *Nat Clin Pract Gastroenterol Hepatol* 2008; **5**: 107-111 [PMID: 18253139 DOI: 10.1038/ncpgasthep1033]
- 81 **Chang KJ**, Irisawa A. EUS 2008 Working Group document: evaluation of EUS-guided injection therapy for tumors. *Gastrointest Endosc* 2009; **69**: S54-S58 [PMID: 19179171 DOI: 10.1016/j.gie.2008.10.057]
- 82 **Herman JM**, Wild AT, Wang H, Tran PT, Chang KJ, Taylor GE, Donehower RC, Pawlik TM, Ziegler MA, Cai H, Savage DT, Canto MI, Klapman J, Reid T, Shah RJ, Hoffe SE, Rosemurgy A, Wolfgang CL, Laheru DA. Randomized phase III multi-institutional study of TNFerade biologic with fluorouracil and radiotherapy for locally advanced pancreatic cancer: final results. *J Clin Oncol* 2013; **31**: 886-894 [PMID: 23341531 DOI: 10.1200/jco.2012.44.7516]
- 83 **Sun S**, Xu H, Xin J, Liu J, Guo Q, Li S. Endoscopic ultrasound-guided interstitial brachytherapy of unresectable pancreatic cancer: results of a pilot trial. *Endoscopy* 2006; **38**: 399-403 [PMID: 16680642 DOI: 10.1055/s-2006-925253]
- 84 **Jin Z**, Du Y, Li Z, Jiang Y, Chen J, Liu Y. Endoscopic ultrasonography-guided interstitial implantation of iodine 125-seeds combined with chemotherapy in the treatment of unresectable pancreatic carcinoma: a prospective pilot study. *Endoscopy* 2008; **40**: 314-320 [PMID: 18283622 DOI: 10.1055/s-2007-995476]

**P- Reviewers:** Clark CJ, Dai ZJ, Sierzega M  
**S- Editor:** Wen LL **L- Editor:** A **E- Editor:** Wang CH





百世登

**Baishideng**®

Published by **Baishideng Publishing Group Co., Limited**

Flat C, 23/F., Lucky Plaza,

315-321 Lockhart Road, Wan Chai, Hong Kong, China

Fax: +852-65557188

Telephone: +852-31779906

E-mail: [bpgoffice@wjgnet.com](mailto:bpgoffice@wjgnet.com)

<http://www.wjgnet.com>



ISSN 1007-9327



9 771007 932045