

## Filarial nematodes belonging to the superorders Diplostriaenoidea and Aproctoidea from wild and captive birds in Japan

Tomoo YOSHINO<sup>1,2</sup>, Natsuki HAMA<sup>3</sup>, Manabu ONUMA<sup>4</sup>, Masaoki TAKAGI<sup>5</sup>, Kei SATO<sup>6</sup>, Shin MATSUI<sup>5</sup>, Mariko HISAKA<sup>5</sup>, Tokuma YANAI<sup>7</sup>, Haruo ITO<sup>8</sup>, Nobutaka URANO<sup>9</sup>, Yuichi OSA<sup>10</sup> and \*Mitsuhiko ASAKAWA<sup>1</sup>

(Accepted 17 January 2014)

### Introduction

Nematodes belonging to the superorders Diplostriaenoidea and Aproctoidea parasitize many orders of birds and sometimes reptiles [24, 25]. These nematodes are found in the air sac, lungs, orbital cavity, body cavity, abdominal cavity, subcutaneous tissues and/or under the skin [21]. Also, they are well known to often cause subcutaneous emphysema, pneumonia and/or air sacculitis, including fatal cases, especially in Falconiformes [1, 7-10, 14, 15, 21, 23, 26, 30, 31]. Despite their common occurrence throughout the world, there have been few reports of nematodiasis attributed to these two groups in Japan [5, 13, 19]. So, we presented some new data including measurement, morphological characters, pathogenicity, new and additional host record and geographical records of several filarial nematodes isolated from the subdermal layer, lung, air sac and body and abdominal cavities of ten species of wild and captive birds that were collected in Japan.

### Materials and Methods

The nematode specimens were obtained from wild and captive birds, including *Turdus naumani* Temminck, 1820 (15: number of infected individuals), *Poecile varius* (Temminck & Schlegel, 1845) (2), *Parus minor* Temminck & Schlegel, 1848 (1), *Falco columbarius* Linnaeus, 1758 (1), *Falco peregrinus* Tunstall, 1771 (2), *Accipiter gentilis* (Linnaeus, 1758) (2), *Lanius bucephalus* Temminck & Schlegel, 1845 (1), *Lanius cristatus lucionensis* Linnaeus, 1766 (1), *Otus flammeolus* Kaup, 1853 (1) and *Otus sunia* Hodgson, 1836 (2) between 1995 and 2009 in Japan. They were removed in post mortem examination and fixed in 70% ethanol solution. And they cleared using lacto-phenol solution for identification under an optical microscope. The hosts were examined for localized gross regions. If found, these were fixed in 10% formalin solution, sectioned (4 or 5  $\mu$ m thickness), stained with Hematoxylin and Eosin (HE), and mounted using MGL solution. Morphological and biometrical data were recorded using a camera lucida (OLYMPUS Model BH-2DA). All the nematode

<sup>1</sup>) School of Veterinary Medicine, Rakuno Gakuen University. Ebetsu, Hokkaido 069-8501, Japan

<sup>2</sup>) Kushiro Zoo. Kushiro, Hokkaido 085-0201, Japan

<sup>3</sup>) Kobe Oji Zoo. Kobe, Hyogo 657-0838, Japan

<sup>4</sup>) Laboratory of Intellectual Fundamentals for Environmental Studies, National Institute for Environmental Studies. Tsukuba, Ibaraki, 305-8506 Japan

<sup>5</sup>) Division of Biology and Geosciences, Graduate School of Science, Osaka City University. Sumiyoshi, Osaka 558-8585, Japan

<sup>6</sup>) Inokashira Park Zoo. Musashino, Tokyo 180-0005, Japan

<sup>7</sup>) Laboratory of Veterinary Pathology, Faculty of Applied Biological Sciences, Gifu University. Yanagido, Gifu 501-1193, Japan

<sup>8</sup>) Hiroshima Geihoku Livestock Hygiene Service Center. Hiroshima, Hiroshima 731-0221, Japan

<sup>9</sup>) Urano Animal Hospital. Sakai, Osaka 590-0021, Japan

<sup>10</sup>) Eastern Hokkaido Wildlife Station, Institute of Environmental Sciences, Hokkaido Research Organization. Kushiro, Hokkaido 085-8588, Japan

specimens were stored at either the Wild Animal Medical Center of Rakuno Gakuen University and/or the Laboratory of Intellectual Fundamentals for Environmental Studies of the National Institute for Environmental Studies, Japan.

### Results

A total of eight nematode species belonging to the superorders Diplostriaenoidea and Aproctoidea were collected from 12 avian species (Table 2). They includes seven diplostriaenoid species (*Diplostriaena bargusinica*, *D. henryi*, *Hamatospiculum accipitris*, *H. cylindricum*, *H. quadridens*, *Serratospiculum kwangsiensis*, *S. tendo*) and one aproctoid species (*Lissonema noctuae*) respectively. Their host informations, morphological characters, postmortem findings and pathogenicity are below.

Superfamily Diplostriaenoidea (Skrjabin, 1915)  
 Family Diplostriaenidae (Skrjabin, 1915) Subfamily Diplostriaeninae Skrjabin, 1915 Genus *Diplostriaena* Henry & Ozoux, 1909

*Diplostriaena bargusinica* Skrjabin, 1917 (Fig. 1a, b)  
 Additional host record: 15 nematode specimens from 6 of 44 *T. naumanni*, collected from Hiroshima during March 2004. A single female from each of two *T. naumanni* individuals collected in Chiba in 2005. One female specimen was isolated from each of the seven *T. naumanni* individuals, collected at Tomakomai, Hokkaido in November 1995 and February 2004, Sapporo, Hokkaido on December 1995, Rumoi, Hokkaido on February

14, 2004, Fuchinobe, Kanagawa on prior 1998, Isenohara, Kanagawa on January 2003 and Osaka on November 26, 1998, respectively.

Site of infection: Body cavity and air sacs (Fig. 1c)

Postmortem findings: No of lesions caused by the infection were observed.

Remarks: *D. bargusinica* is found primarily in the body cavity and the air sac of wild birds, especially Passeriformes [20, 25]. The present survey is the second report of this species from *T. naumanni* in Japan and the first local record in Hokkaido, Chiba, Kanagawa, Osaka and Hiroshima.

*Diplostriaena henryi* Blanc, 1919 (Fig. 2a, b)

New host record: 34 nematode specimens were collected from two individuals of *P. varius* which died during quarantine at Inokashira Park Zoo (Tokyo) in February 2009.

Additional host record: 22 nematode specimens were collected from one *P. minor* that died during quarantine at Inokashira Park Zoo (Tokyo) in March 2010.

Site of infection: Air sacs and lung (Fig. 2c)

Postmortem findings: Pulmonary hemorrhaging in both two *P. varius* individuals was observed. In one host, we noted that a single nematode had penetrated deeply into the air sac and lung (Fig. 2d). We also found histological evidence of inflammation caused by the infection. This included clusters of macrophages, heterophils, and giant cells surrounding the nematode body (Fig. 2e).

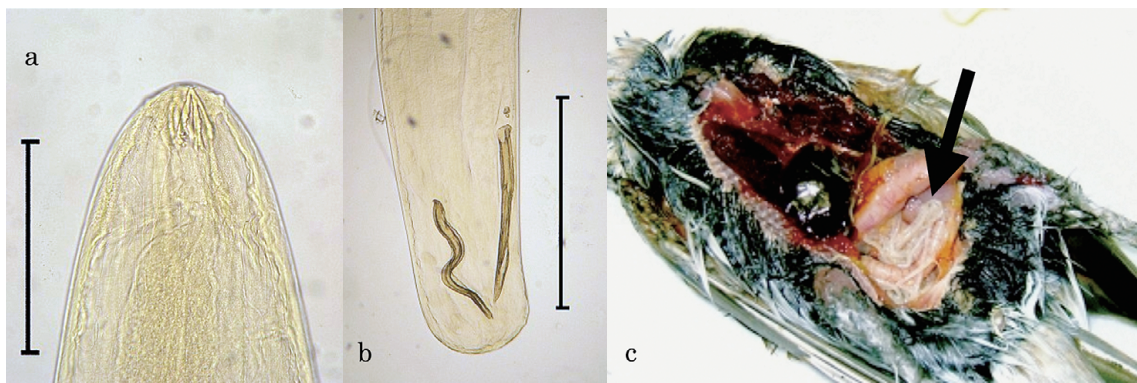


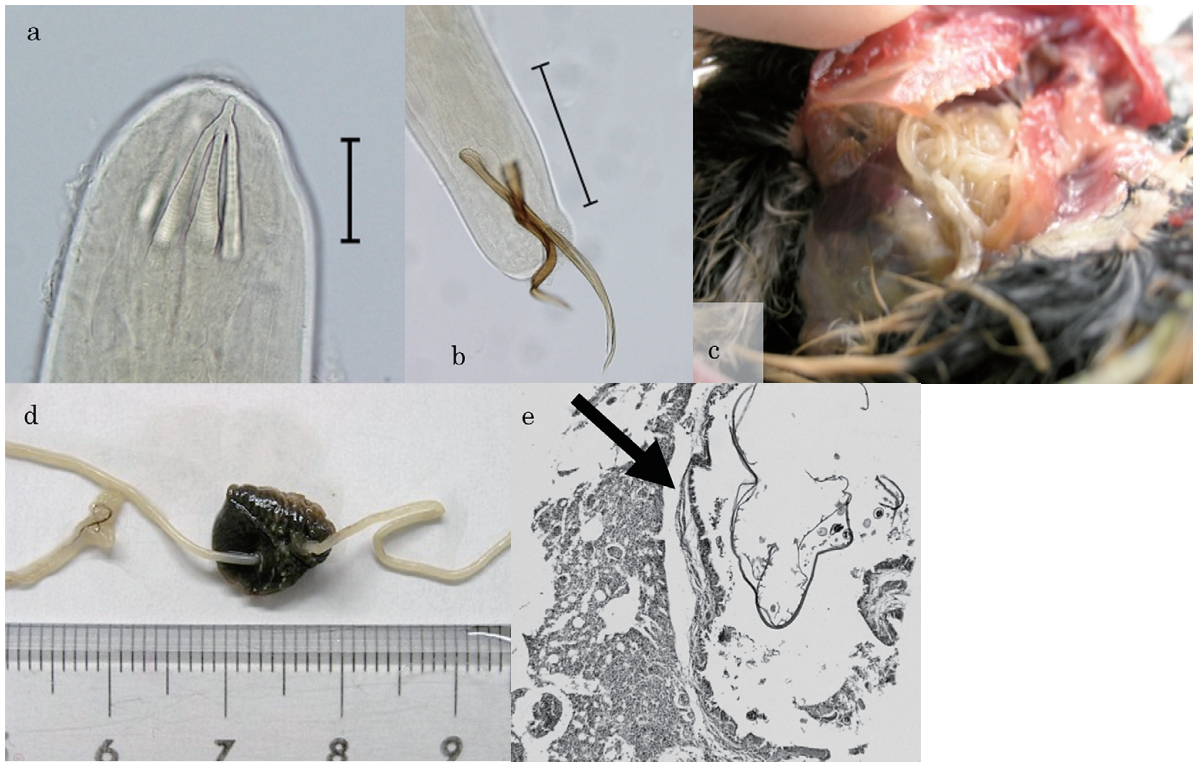
Fig. 1: *Diplostriaena bargusinica*; a: head (scale=0.5 mm), b: spicules and posterior extremity of male (scale=1 mm), c: parasitized in body cavity of *Turdus naumanni*.

**Table 1.** Measurements of the obtained filarial nematodes\*

	<i>D. bargusinica</i>		<i>D. henryi</i>		<i>S. tendo</i>		<i>S. kwangsiensis</i>	
	[28]	present survey	[17]	present survey	[29]	present survey	[11]	present survey
male		n=5		n=5		-		n=1
body length	40	37.46-44.01	32-37	38.3-49.5	-	-	73.9-90	64.16
maximum body width	0.6	0.65-0.77	0.68	0.56-0.61	-	-	-	0.55
esophagus	3.7-4.4	4.34-4.89	2.07-3.87	2.69-3.07	-	-	10.02	10.64
mascular part	0.3	0.22-0.28	0.37	0.33-0.39	-	-	-	-
glandular part	3.4-4.1	4.12-4.61	1.7-3.5	2.36-2.68	-	-	-	-
nurve ring	0.18-0.3	0.17-0.20	-	0.20-0.23	-	-	-	-
right spicule	0.44-0.54	0.50-0.55	0.285	0.63-0.68	-	-	0.336	0.34
left spicule	0.53-0.6	0.49-0.66	0.409	0.76-0.98	-	-	0.688	0.68
trident length	0.132	0.12-0.14	0.14-0.17	0.15-0.17	-	-	-	-
tail	-	0.12-0.15	-	0.09-0.11	-	-	0.096	0.131
female		n=5		n=5		n=3		n=1
body length	104	88.6-112.7	94-134	106.3-133.9	287	202.1-274.1	187-195	163.51
maximum body width	0.8	0.88-0.95	1	0.72-0.91	0.75	0.76-0.81	-	0.9
esophagus	3.7-4.4	4.56-5.13	4.1	3.26-3.60	17.60	13.59-17.37	14.85-16.81	14.05
mascular part	0.3	0.21-0.24	0.4	0.32-0.37	0.45	0.55-0.78	-	-
glandular part	3.4-4.1	4.34-4.89	3.7	2.94-3.23	17.25	13.04-16.59	-	-
nurve ring	0.18-0.3	0.16-0.18	-	0.20-0.21	0.16	0.23-0.25	-	-
Distance to vulva	0.75-0.8	0.73-0.87	0.325	0.61-0.69	2.4	1.12-1.67	0.736-0.819	1.26
egg size (μm)	39-42× 54-60	37-39× 57-64	-	30-33× 46-48	33-48× 18-21	33-38× 17-19	33-37× 56-58	30-32× 54-57
trident length	0.132	0.11-0.13	0.15-0.18	0.14-0.19	-	-	-	-
	<i>H. accipitris</i>		<i>H. cylindricum</i>		<i>H. quadridens</i>		<i>L. noctuae</i>	
	[29]	present survey	[25]	present survey	[25]	present survey	[24]	present survey
male		-		n=3		n=3		n=1
body length	-	-	22	19.5-25.1	27-30	22.4-26.9	16	11.54
maximum body width	-	-	0.567	0.69-0.71	0.542-0.578	0.56-0.62	0.48	0.45
esophagus	-	-	6.3	6.44-6.71	9.012-9.713	7.02-7.20	1.05	0.98
mascular part	-	-	0.315	0.29-0.35	-	0.26-0.33	-	-
glandular part	-	-	5.985	6.15-6.36	-	6.78-6.87	-	-
nurve ring	-	-	0.147	0.14-0.17	0.316-0.344	2.83-3.23	0.19	0.13
right spicule	-	-	2.457	2.68-2.82	0.210-0.273	0.248-0.269	0.16	0.16
left spicule	-	-	0.301	0.30-0.31	2.357-3.248	2.44-2.79	0.16	0.16
tail	-	-	-	-	-	-	0.095	0.098
Distance to cloaca	-	-	0.073	0.083-0.09	0.105-0.115	0.095-0.101	-	-
female		n=1		n=3		n=3		n=1
body length	45-50	50.24	82	81.0-84.3	54-60	40.58-47.63	43	27.47
maximum body width	0.75	0.723	1.05	0.87-0.98	0.945	0.88-0.90	0.65	0.73
esophagus	10.35-10.42	11.74	10.5	10.6-10.7	11.76-15.137	13.5-14.8	1.34	1.19
mascular part	0.35-0.42	0.38	0.42	0.42-0.43	-	0.37-0.42	-	-
glandular part	10	11.36	10.08	10.18-10.27	-	13.13-14.66	-	-
nurve ring	0.175-0.2	0.18	0.168	0.15-0.18	0.542	0.54-0.58	0.17	0.15
Distance to vulva	1.1-1.25	1.09	1.092	0.98-1.05	0.857-0.98	0.87-1.1	0.75	0.60
egg size (μm)	36-39× 21-26	35-37× 20-24	52-56× 33-36	50-53× 31-33	62-65× 34-43	63×36	70-78× 35-40	68-78× 32-36

\*Data are range in mm except for egg size





**Fig. 2:** *Diplotrriaena henryi*; a: head (scale=0.1 mm), b: spicules and posterior extremity of male (scale=0.5 mm), c: parasitized in air sacs and lung of *Poecile varius*, d: deeply piecing into lung, e: inflammation caused by the nematode infection in lung.

Remarks: *D. henryi* is found primarily in the air sacs of Strigiformes, Coraciiformes, and, especially, Passeriformes in Europe, Asia (Russia and Central Asia, Southeast Asia, Middle East), and Africa [15, 17, 25]. This is the first report of *D. henryi* in *P. varius* and the first geographical record instance in Japan.

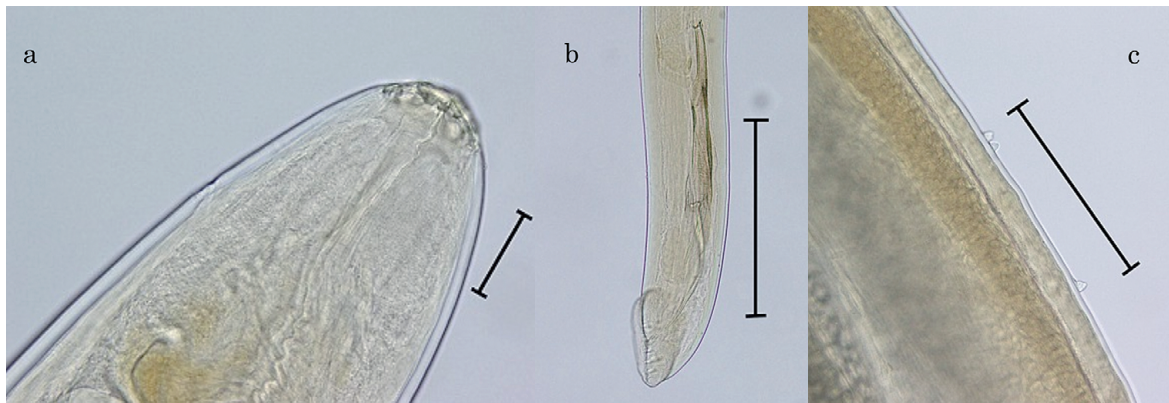Subfamily Dicheilonematinae Wehr, 1835

Genus *Serratospiculum* Skrjabin, 1915

*Serratospiculum kwangsiensis* Hsu, 1963 (Fig. 3a)  
 Additional host record: One male and one female specimen were collected from one *F. columbarius* captured in Sakai, Osaka in 2006 and died at Animal Hospital on January 7, 2008.

Site of infection: Air sacs

Postmortem findings: Some evidences of pulmo-



**Fig. 3:** *Serratospiculum kwangsiensis*; a: head (scale=0.1 mm), b: spicules and posterior extremity of male (scale=0.5 mm), c: bosses of female cuticular ornamentation (scale=0.5 mm).



nary hyperemia and hemorrhaging were observed. However, this was unclear that whether the nematodes direct cause of death or not.

Remarks: This species was first documented in the abdominal cavity of *F. columbarius* in China [11]. Although Sonin [25] considered this species to be a synonym of *Serratospiculum guttatum* (Schneider, 1866), Bain & Mawson [6] described *S. kwangsiensis* based on the female cuticular ornamentation particularly the bosses and the number of preanal papillae in the male (five pairs) (Fig. 3b, c). This is the first report of *S. kwangsiensis* from *F. columbarius* in Japan.

*Serratospiculum tendo* (Nitzsch, 1819) Skrjabin, 1915

Additional host record: Seven female specimens were collected from one *F. peregrinus* collected from Hakodate, Hokkaido on June 12, 2004, and also another one female specimen in the same host were collected from Sapporo, Hokkaido on February 3, 2006.

Site of infection: Air sac and abdominal cavity (Fig 4)

Postmortem findings: There was no evidence of gross lesions caused by the infection.

Remarks: *S. tendo* is found primarily in abdominal cavity and air sac of wild and captive falcons, particularly *F. peregrinus* throughout the world [21, 23, 25, 26]. This is the second report of *S. tendo* from raptors in Japan, but the first local record from Hokkaido.

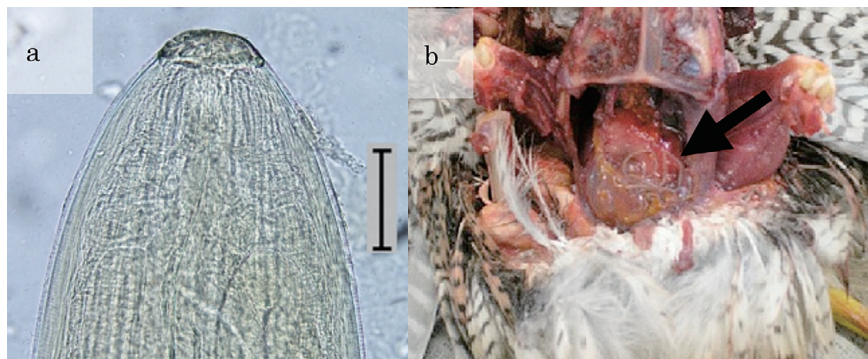


Fig. 4: *Serratospiculum tendo*; a: head (scale=0.1 mm), b: parasitized in air sacs of *Falco peregrinus*.

Genus *Hamatospiculum* Skrjabin, 1916

*Hamatospiculum accipitris* Yamaguti, 1941 (Fig. 5)

New host record: One female specimen was collected from one *A. gentilis* captured from Tomakomai, Hokkaido on September 21, 2005, and subsequently died at Maruyama Zoo in September 22, 2005.

Site of infection: Abdominal cavity

Postmortem findings: There was no evidence of gross lesions as a result of infection.

Remarks: *H. accipitris* was previously recorded in the abdominal cavity of *A. nisus* (Linnaeus, 1758) in Shizuoka, Japan [29]. This is the second report of *H. accipitris* from raptors in Japan, but the first host record for *A. gentilis* and the first local record from Hokkaido.

*Hamatospiculum cylindricum* (Zeder, 1803) (Fig. 6a, b)

New host record: 30 specimens were collected from one *L. bucephalus* collected on July 1, 2005 from Minami Daito Island, Okinawa.

Additional host record: 10 specimens were collected from one *L. cristatus lucionensis* collected on September 2003 from Yonaguni Island, Okinawa.

Site of infection: Under the skin between head and neck (Fig. 6c)

Postmortem findings: There was no evidence of gross lesions in the subcutaneous tissue of the neck. Histopathological section showed cellular infiltration around the nematodes.


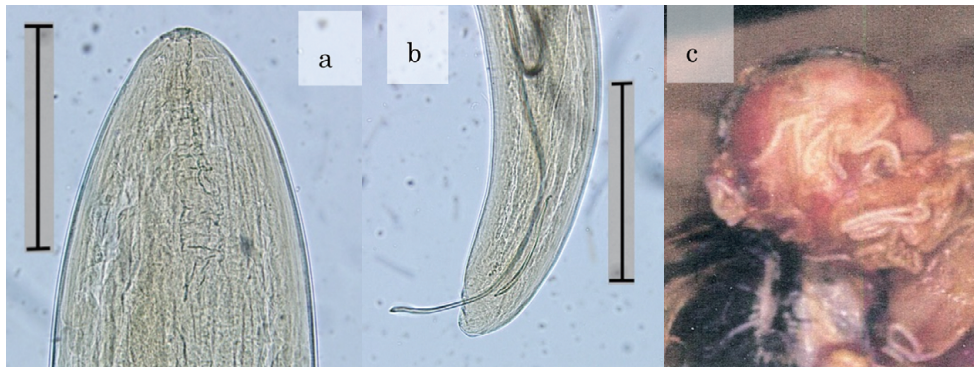


Fig. 5: Head of *Hamatospiculum accipitris* (scale=0.1 mm).



**Fig. 6:** *Hamatospiculum cylindricum*; a: head (scale=0.5 mm), b: spicules and posterior extremity of male (scale=0.5 mm), c: parasitized under the skin of *Lanius bucephalus*.

Remarks: This species was found previously under the skin of wild birds, particularly Passeriformes (mainly Laniidae) and Piciformes [12, 25]. Yamaguti [29] reported this species from the subcutaneous tissue of *L. cristatus* in Taiwan. However, this is the first report of *H. cylindricum* in Japan.

*Hamatospiculum quadridens* (Molin, 1858) (Fig. 7a, b)

New host record: Eight specimens were found from a single *O. flammeolus* captured in Hyogo on December 30, 2007, and died January 18, 2008, at the Kobe Oji Zoo.

Site of infection: Air sac and lungs (Fig. 7c)

Postmortem findings: There was no evidence of gross lesions in the lungs and air sacs. However, granuloma formed by macrophages, heterophils, and foreign-body giant cells were seen around the nematodes.

Remarks: *H. quadridens* is found throughout the

world, primarily in the order Strigiformes [25]. Although Yamaguti [29] reported *Hamatospiculum* sp. from *O. lempiji* (Horsfield, 1821) in Shizuoka, Sonin [25] considered this to be a synonym of *H. quadridens*. Thus, the present survey represents the second report of *H. quadridens* from owls in Japan, and the first host record and the first local record in Japan.

Superfamily Aproctoidea Sonin, 1962–1963

Family Aproctidae Skrjabin & Schikhobalowa, 1945

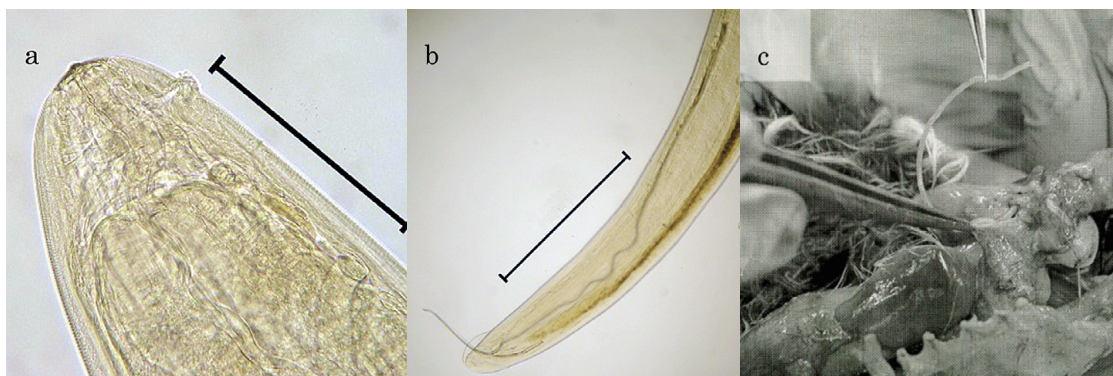
Subfamily Aproctinae Yorke & Maplestone, 1926

Genus *Lissonema* Linstow, 1903

*Lissonema noctuae* (Spaul, 1927) (Fig. 8a, b)

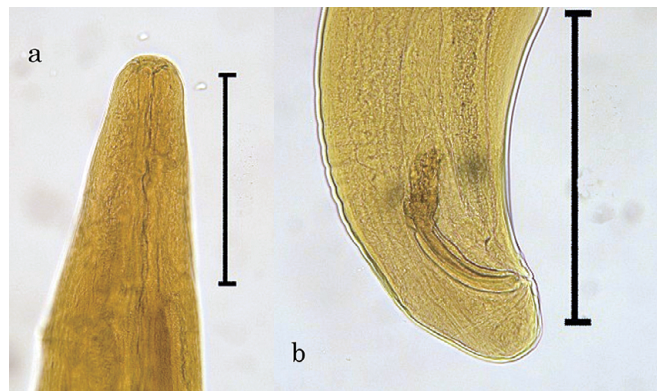
Additional host record: One female and one male specimen found in the abdominal cavity of two *O. sunia* collected on May 7 and May 11, 1997, from Rishiri Island, Hokkaido.

Site of infection: Abdominal cavity



**Fig. 7:** *Hamatospiculum quadridens*; a: head (scale=0.5 mm), b: spicules and posterior extremity of male (scale=1 mm), c: parasitized in air sacs and lung of *Otus flammeolus*.





**Fig. 8:** *Lissonema noctuae*; a: head (scale=0.5 mm), b: same length spicules and posterior extremity of male (scale=0.5 mm)

Postmortem findings: There was no evidence of gross lesions caused by the infection.

Remarks: *L. noctuae* were found in *Athene noctua* (Scopoli, 1769) in Morocco and *O. sunia* in the Far East [24]. Sonin [24] considered the genus *Lissonema* to be a synonym of the genus *Aprocta* (Linstow, 1883). More recently, Bain and Mawson [6] compared the two genera *Aprocta* and *Lissonema* based on ovijector length, absence or presence of deirid, and egg size. As a result, they placed this species into the genus *Lissonema*. This is the first report of *L. noctuae* from Japan.

This specimen had been reported previously by Asakawa *et al.* [4] as Aproctidae gen. sp. as the authors were not able to determine the species at that time.

### Discussion

A total of 11 species of nematodes, belonging to the superorders Diplostriaenoidea and Aproctoidea, have already been reported in 12 species of wild and captive birds in Japan before the present survey (Table 3). Some of the present nematodes, namely *D. bargusinica*, *H. acipitris*, *H. quadridens* and *S. tendo*, have previously been recorded in Japan [25, 28, 29].

Many parasites including the present nematodes use paratenic and/or intermediate hosts, to facilitate their transmission to the definitive host via predation. The nematodes belonging to the superorders Diplostriaenoidea and Aproctoidea are known to require orthopteron or coelepteron insects as intermediate host [2, 3].

Thus, the birds examined in the present survey might be ingested locusts, grasshoppers, and/or beetles which contained the infective larva of the diplostriaenoid or aproctoid nematodes [2, 3].

The site of predilection of the filarial nematodes documented in the current study is consistent with previous reports [24, 25, 28, 29]. These nematodes have been reportedly found in the orbital and nasal cavities, and accidentally in the stomach, but they were not found in the present survey [16, 18, 29].

In all present cases, excluding *D. henryi* in *P. varius* and *P. minor*, we found no evidence of pathogenicity or mortality that could be attributed directly to the nematode infection. However, pathologic changes have been reported in wild birds, especially in raptors, as a result of the filarial nematode infection [1, 7–9, 14, 15, 17, 27]. In the present survey, subcutaneous emphysema, respiratory deficit, and inflammation of the lung were found in the infection of *D. henryi* in *P. varius* and *P. minor*. Infection has also been known to cause death, as a result of subcutaneous emphysema, respiratory deficit, and inflammation of the lungs, trachea, and air sacs, and necrosis and disseminated necrotic foci in the liver, kidneys, and other organs [15, 21, 23]. The pathology appears to be localized to the lungs and air sac based on thickening of the air sac membrane due to fibrosis and mononuclear inflammation, and the presence of nematode eggs within the parabronchi and secondary bronchial lumen, and mixed granulocytic and monocytic inflamma-



**Table 2.** Nematodes belonging to the superorders Diplostriaenoidea and Aproctoidea recorded from wild and captive birds in Japan.

Nematodes	Host	Site	Locality	Reference
<b>Superfamily Diplostriaenoidea</b>				
<b>Family Diplostriaenidae</b>				
<b>Subfamily Diplostriaeninae</b>				
<i>Diplostriaena bargusinica</i>	<i>Turdus naumanni</i>	bc	Tottori	[28]
	<i>Turdus naumanni</i>	as, bc	Hiroshima, Osaka, Kanagawa, Chiba, Hokkaido	present survey
<i>Diplostriaena falconis</i>	<i>Microhierax caerulescens</i> *1	as	Nagano (Nagano Zoo)	[13]
<i>Diplostriaena henryi</i>	<i>Poecile varius</i>	as, lu	Tokyo (Inokashira Park Zoo)	present survey
	<i>Parus minor</i>	as, lu	Tokyo (Inokashira Park Zoo)	present survey
<i>Diplostriaena nocti</i>	<i>Turdus cardis</i>	bc	Kyoto	[29]
<i>Diplostriaena ozouxi</i>	<i>Charadrius hiaticula</i>	as	Osaka (Tennoji Zoo)	[22]
<i>Diplostriaena tricuspis</i>	<i>Garrulus glandarius</i>	bc	Shizuoka	[28]
	<i>Corvus corone</i>	as, bc	Hokkaido	[16]
<b>Subfamily Dicheilonematinae</b>				
<i>Serratospiculum kwangsiensis</i>	<i>Falco columbarius</i>	as	Osaka	present survey
<i>Serratospiculum tendo</i>	<i>Falco peregrinus</i>	ac	Shizuoka	[29]
	<i>Falco peregrinus</i>	as, ac	Hokkaido	present survey
<i>Hamatospiculum accipitris</i>	<i>Accipiter nisus</i>	ac	Shizuoka	[29]
	<i>Accipiter gentilis</i>	ac	Hokkaido	present survey
<i>Hamatospiculum cylindricum</i>	<i>Lanius bucephalus</i>	us	Minami Daito Island (Okinawa)	present survey
	<i>Lanius cristatus lucionensis</i>	us	Yonaguni Island (Okinawa)	present survey
<i>Hamatospiculum quadridens</i>	<i>Otus flammeolus</i> *2	as, lu	Hyogo (Kobe Oji Zoo)	present survey
<i>Hamatospiculum</i> sp.	<i>Otus lempiji</i>	ac	Shizuoka	[29]
<i>Dicheilonema spicularia</i>	<i>Struthio camelus</i> *3	as, ac	Osaka (Osaka Misaki Zoo)	[19]
<b>Superfamily Aproctoidea</b>				
<b>Family Desmidocercidae</b>				
<i>Diomedinema</i> sp.	<i>Ardea cinerea</i>	st	Niigata	[18]
<b>Family Aproctidae</b>				
<i>Lissonema noctuae</i>	<i>Otus sumia</i>	as	Rishiri Island (Hokkaido)	present survey
<i>Aprocta</i> sp.	<i>Corvus corone</i>	oc, nc	Hokkaido	[16]

Abbreviation of Site; as: air sac, ac: abdominal cavity, bc: body cavity, lu: lung, st: stomach, nc: nasal cavity, oc: orbital cavity, us: under the skin

\*1: Imported unlawfully from Thailand and died at Nagano Zoo

\*2: Captured at Hyogo and died at Oji Zoo

\*3: Imported from Africa and died at Osaka Misaki Zoo

tory cells in the proteinaceous fluid [7, 9, 14, 27]. These nematodes may also cause multiple mycotic granulomas in the lungs and air sacs. Furthermore, secondary infection caused by bacterial and/or fungal agents (e.g. *Aspergillus fumigatus*) has been demonstrated from cultures of these lesions [31]. This systematic epidemiological survey is required not only for conservation of wild birds but also for healthcare of captive ones.

Takagi and Matsui observed swelling of the skin and loss of the neck feathers in 61.7% of captured *L. bucephalus* (n=45) at Minami Daito Island in 2005 [unpublished]. However, the relevance of these observations is unclear. Indeed, despite the evidence for pathogenicity resulting from the infection of the internal organs little is known about the effect of parasitization of the

subcutaneous tissue. We hypothesize a high ratio of nematode individuals/host body weight (e.g. *L. bucephalus* infected by *H. cylindricum*) will hinder the mobility and the reproductive capacity of the host.

### Acknowledgements

The present survey was supported in part by the Strategic Research Foundation at Private Universities (2013–2017) from the Ministry of the Education, Science and Culture of Japan. We are grateful for donation of the host samples provided by the Ministry of the Environment, the Hiroshima Geihoku Public Health Center, the Utonai Wildlife Rescue Center, Hashiba Tonton Animal Hospital, the Bird Clinic Kanazawa Animal Hospital, Urano Animal Hospital, Oshima Shicho, Rishiri Town Museum, Sapporo Mar-

uyama Zoo, Kobe Oji Zoo, Nada Police Office, Hayama, H. and Iwao, H. We also thank T. Iwaki and Y. Yokohata for their kindly advice and H. Ueda for assistance during the histological analysis.

### References

- [1] Ackerman, N., Isaza, R., Greiner, E. and Berry, C.R. 1992. Pneumocoelom associated with *Serratospiculum amaculata* in a Bald Eagle. *Vet. Radiol. Ultrasound*, 33: 351-355.
- [2] Anderson, R.C. 2000. *Nematode Parasites of Vertebrates. Their development and transmission*. 2<sup>nd</sup> Edition, Wallingford, UK, CABI Publishing, 650pp.
- [3] Anderson, R.C. and Bain, O. 1976. Keys to genera of the order Spirurida. Part 3. Diplostriaenoidea, Aproctoidea and Filarioidea. In: Anderson, R.C., Chabaud, A.G. and Willmott, S. (Eds.): *CIH Keys to the Nematode Parasite of Vertebrates* No. 3. Wallingford, UK, CABI Publishing, pp. 59-116.
- [4] Asakawa, M., Matsumoto, K. and Sato, M. 1999. Preliminary report on the parasitic helminths of birds on Rishiri and Rebun Islands in Hokkaido, Japan. *Rishiri Study*, 18: 97-106 (in Japanese with English summary).
- [5] Asakawa, M., Nakamura, S. and Brazil, M. A. 2002. An overview of infectious and parasitic diseases in relation to the conservation biology of the Japanese avifauna. *J. Yamashina Inst. Ornithol.*, 34: 200-221.
- [6] Bain, O. and Mawson, P.M. 1981. On some oviparous filarial nematodes mainly from Australian birds. *Rec. South Aust. Mus.*, 18: 265-284.
- [7] Bigland, C.H., Liu, S.K. and Perry, M.L. 1964. Five cases of *Serratospiculum amaculata* (Nematoda: Filarioidea) infection in Prairie Falcons (*Falco mexicanus*). *Avian Dis.*, 8: 412-419.
- [8] Cawthorn, R.J., Anderson, R.C. and Baker, I. K. 1980. Lesions caused by *Diplostriaena tricuspis* (Nematoda: Diplostriaenoidea) in the American crow, *Corvus brachyrhynchos* Brehm. *Can. J. Zool.*, 58: 1892-1898.
- [9] Green, C.H., Gartrell, B.D. and Charleston, W.A.G. 2006. Serratospiculosis in a New Zealand Falcon (*Falco novaeseelandiae*). *New Zeal. Vet. J.*, 54: 198-201.
- [10] Hawkins, M.G., Couto, S., Tell, L.A., Joseph, V. and Lowenstine, L.I. 2001. Atypical parasitic migration and necrotizing sacral myelitis due to *Serratospiculoides amaculata* in a Prairie Falcon (*Falco mexicanus*). *Avian Dis.*, 45: 276-283.
- [11] Hsu, W.N. 1963. Studies on some parasitic nematodes of order Spirurida Chitwood, 1933. *Acta. Zool. Sin.*, 15: 544-552 (in Chinese with English summary).
- [12] Hromada, M., Dudioak, V. and Yosef, R. 2000. An inside-out perspective of the true shrikes. A review of the helminthofauna. *Ring*, 22: 185-204.
- [13] Imai, S., Ikeda, S., Ishii, T. and Uematsu, K. 1988. *Diplostriaena falconis* (Connal, 1912) (Filariidae, Nematoda) from a Red-Legged Falconet, *Microhierax caerulescens*. *J. Vet. Med. Sci.*, 51: 209-212.
- [14] Kocan, A.A. and Gordon, L.R. 1976. Fatal air sac infection *Serratospiculum amaculata* in a Prairie falcon. *J. Am. Vet. Med. Assoc.*, 169: 908.
- [15] Literak, I., Barus, V., Hauptomanova, K. and Halouzka, R. 2003. The nematode *Diplostriaena henryi* (Nematoda: Diplostriaenoidea) as the possible cause of subcutaneous emphysema and respiratory insufficiency in a Great Tit (*Parus major*). *Helminthologia*, 40: 23-25.
- [16] Mizuno, F. 1984. Studies on the parasite fauna of the Eastern Carrion Crow, *Corvus corone orientalis* Eversman, and the Japanese Jungle Crow, *Corvus macrorhynchos japonensis* Bonaparte. *Jpn. J. Vet. Res.*, 32: 105.
- [17] Mobedi, I., Sehhatiasabet, M.E., Rauzmjou, E. and Shafiei, S. 2006. First record of *Diplostriaena henryi* Blanc, 1919 from the Coal Tit, *Parus ater* with new report from the Great Tit, *Parus major* in the Middle East. *Helminthologia*, 43: 239-241.
- [18] Nakamura, S., Yoshino, T., Sato, J., Chiba,

- A. and Asakawa, M. 2003. Parasitic helminthes from avian species in Niigata Pref., Japan. *Jpn. J. Ornithol.*, 52: 116–118 (in Japanese with English summary).
- [19] Nishimura, S., Hoshino, T. and Noda, R. 1960. Filariasis of *Struthio camelus*. *Jpn. J. Vet. Med.*, 285: 922–923 (in Japanese).
- [20] Pinto, R.M., Vicente, J.J. and Noronha, D. 1997. Nematode parasites of Brazilian corvid birds (Passeriformes): A general survey with a description of *Viktorocara braziliensis* n. sp. (Acuariidae: Schistorophinae). *Mem. Inst. Oswald Cruz.*, 92: 209–214.
- [21] Samour, J.H., Naldo, J.N. 2001. Serratospiculiasis in captive falcons in the Middle East: a review. *Avian Med. Surg.*, 15: 2–9.
- [22] Sato, A., Nakamura, S., Takeda, M., Murata, K., Mitsuhashi, Y., Kawai, N., Tanaka, N. and Asakawa, M. 2005. Parasitic helminths from exhibited avian species kept in Kinki District in Japan. *Jpn. J. Zoo Wildl. Med.*, 10: 35–38.
- [23] Smith, S.A. 1993. Diagnosis and treatment of helminthes in birds of prey. In: Redig, P.T., Cooper, J.E., Remple, J.D. and Hunter, D.B. (Eds.): *Raptor Biomedicine*. Minneapolis, University of Minnesota Press, pp. 21–27.
- [24] Sonin, M.D. 1966. Filariata of animals and man and diseases caused by them. Part 1. Aoproctoidea. *Principles of Nematodology*. Vol. 17. Nauka, Moscow.
- [25] Sonin, M.D. 1968. Filariata of animals and man and diseases caused by them. Part 2. Diplotriaeoidea. *Principles of Nematodology*. Vol. 19. Nauka, Moscow.
- [26] Tarello, R. 2006. Serratospiculosis in falcons from Kuwait: incidence, pathogenicity and treatment with Melarsomine and Ivermectin. *Parasite*, 13: 59–63.
- [27] Ward, F.P. and Fairchild, D.G. 1972. Air sac parasites of the genus *Serratospiculum* in falcons. *J. Wildl. Dis.*, 8: 165–168.
- [28] Yamaguti, S. 1935. Studies on helminth fauna of Japan. Part 12: Avian nematodes I. *Jpn. J. Zool.*, 6: 403–441.
- [29] Yamaguti, S. 1941. Studies on helminth fauna of Japan. Part 36: Avian nematodes II. *Jpn. J. Zool.*, 9: 441–480.
- [30] Yaman, M. and Ayaz, E. 2007. A case of *Diplotriaeo monticola* (Yamaguti, 1935) in the White-Spectacled Bulbul (*Pycnonotus xanthopygos*). *Turkiye. Parazitol. Derg.*, 31: 215–218 (in Turkey with English summary).
- [31] Young, E.A., Cornish, T.E., Little, S.E. 1998. Concomitant mycotic and verminous pneumonia in a Blue Jay from Georgia. *J. Wildl. Dis.*, 34: 625–628.

### Abstract

Eight species of filarial nematodes of the superorders Diplotriaeoidea and Aoproctoidea were collected from the lung, air sac, abdominal cavity, and subdermal layer of the neck of wild and captive birds in Japan. The species of the filarial nematodes were identified as *Diplotriaeo bargusinica*, *D. henryi*, *Serratospiculum kwangsiensis*, *S. tendo*, *Hamatospiculum accipitris*, *H. cylindricum*, *H. quadridens*, and *Lissonema noctuae* based on morphometry and pathogenicity. *D. henryi* from *Poecile varius*, *H. accipitris* from *Accipiter gentilis*, *H. cylindricum* from *Lanius bucephalus* and *H. quadridens* from *Otus flammeolus* represent the first host records worldwide. Moreover, *D. henryi*, *S. kwangsiensis*, *H. cylindricum*, and *L. noctuae* were the first geographical records from Japan.

Keywords: aoproctoidea, diplotriaeoidea, new host record, pathogenicity

\*Corresponding author: Mitsuhiko Asakawa

(tel/fax: +81-11-388-4758/+81-11-387-5890, e-mail: askam@rakuno.ac.jp)