



University of St Augustine for Health Sciences
SOAR @ USA

Physical Therapy Collection

Faculty and Staff Research

2017

Rehabilitation After Glenohumeral Microfracture and Type II SLAP Repair Surgery: A Case Report

Judson Williams
Optim Therapy

Eric Chaconas
University of St. Augustine for Health Sciences, echaconas@usa.edu

Follow this and additional works at: <https://soar.usa.edu/pt>

 Part of the [Physical Therapy Commons](#)

Recommended Citation

Williams J, Chaconas E. Rehabilitation after glenohumeral microfracture and Type II SLAP repair surgery: a case report. *Orthop Phys Ther Pract.* 2017;29(3):134-141.

This Article is brought to you for free and open access by the Faculty and Staff Research at SOAR @ USA. It has been accepted for inclusion in Physical Therapy Collection by an authorized administrator of SOAR @ USA. For more information, please contact soar@usa.edu, erobinson@usa.edu.

Rehabilitation After Glenohumeral Microfracture and Type II SLAP Repair Surgery: A Case Report

Judson Williams, PT, DPT, MS, OCS, Cert. SMT, CSCS¹
Eric Chaconas, PT, PhD, FAAOMPT²

¹Director of Physical Therapy, Optim Therapy, Savannah, GA

²Assistant Professor and Assistant DPT Program Director, University of St. Augustine for Health Sciences, Augustine, FL

ABSTRACT

Background and Purpose: There are few rehabilitation protocols for patients who have undergone glenohumeral microfracture procedure. The purpose of this paper is to present a patient case after both glenohumeral microfracture and Type II SLAP repair procedures and present a rehabilitation protocol. **Methods:** The patient in this case is a 41-year-old male who had a sudden onset of pain, mechanical catching, and audible popping in his right shoulder, particularly with athletic activities. This patient was seen for 27 treatments and progressed per the presented protocol. **Findings:** The overall improvement when combining the sections of the QuickDASH was 72.96%, the patient also met his individual goals, as well as the progression goals for each phase of the protocol. **Clinical Relevance:** The most important factors in rehabilitation following microfracture procedure of the shoulder are balancing early range of motion (ROM) and controlled loading conditions. The patient in this case had a successful outcome following a protocol that emphasized early ROM and incremental loading.

Key Words: shoulder, articular cartilage, labrum, injury, QuickDASH

INTRODUCTION

Articular cartilage lesions are becoming more recognized in younger, active, and athletic populations.¹ These lesions can result in pain, mechanical dysfunction, and decreased function.² Injury to the articular cartilage can occur secondary to trauma, joint instability, iatrogenic injury, and certain metabolic conditions.³ Inappropriate medical management can result in further joint deterioration and osteoarthritis.^{1,4} The lack of long-term success with conservative measures such as non-operative rehabilitation, cortisone injection, and visco-supplementation in the active individual has been documented.^{5,6} The failure of conservative treatment can be attributed to the avascularity of the articular cartilage and

the lack of undifferentiated pluripotent cells that are necessary for the healing process.^{1,4}

There are several surgical procedures to address full-thickness articular cartilage lesions. These include open techniques, such as osteochondral autograft transplantation and autologous chondrocyte transplantation,⁵ as well as arthroscopic techniques including lavage and debridement, drilling, abrasion arthroplasty, and microfracture.^{7,8} Considerations when choosing the type of surgical intervention are the patient's age, activity level, size, location, and severity of the lesion. Classification of articular cartilage injury is important when selecting an appropriate intervention. The Outerbridge classification system is a commonly used system to classify articular cartilage injury.^{3,9} Radiologists and orthopedists use it to grade the degree of articular cartilage injury.⁸ This system categorizes articular cartilage injury grades 2 to 4 with 4 being full-thickness lesions (Figure 1). While debridement and chondroplasty are more appropriate for grades 2 and 3, full-thickness injury requires a marrow stimulating procedure such as drilling or microfracture. Marrow stimulating procedures such as abrasion, drilling, or microfracture rely on the body's healing response for chondral resurfacing.¹⁰

Currently, one of the most popular and conservative surgical interventions for grade 4 full-thickness articular cartilage lesions is the microfracture procedure. The microfracture procedure involves debridement of loose cartilage around the periphery of the lesion to create perpendicular walls of healthy articular cartilage.¹¹ The next step is to remove the calcified cartilage layer exposing the subchondral bone¹¹ (Figure 2). After the calcified cartilage layer is removed, the subchondral bone is perforated using an arthroscopic awl (Figure 3). In the knee, the holes should be 3 mm to 4 mm apart and 3 mm to 4 mm deep.^{1,11} In the shoulder, it is suggested for the holes to be 2 mm to 3 mm apart and 4 mm deep.³ The final step is to decrease the arthroscopic pump pressure to assess bleeding from the

microfracture perforations.^{1,11}

Healing from the microfracture procedure begins with marrow elements such as mesenchymal cells (undifferentiated cells), stem cells, growth factors, platelets, and fibrin. This matrix combines to form a clot within the perpendicular walls of the lesion that were created as a step during the procedure.¹⁰ These initial cells undergo metaplasia or cell differentiation to form granulation tissue.^{10,12} The stimulation of undifferentiated cells allows them to become chondroblasts or fibroblasts.¹¹ These cells begin to form a fibrocartilaginous repair in the area of the microfracture.¹² The fibrocartilaginous matrix undergoes a process of hyalinization and chondrification to form the mature repair over the course of 6 to 12 months.¹⁰ The mature fibrocartilaginous area consists of 70% to 80% Type II collagen and 20% to 30% Type I collagen indicating a hyaline and fibrocartilage mix.^{11,12}

There are several advantages of microfracture as an initial surgical treatment for full-thickness articular lesions. First, microfracture is minimally invasive and can be performed arthroscopically. It is technically simple and relatively easy to perform along with other procedures if needed.^{10,12} Secondly, it allows for further and more invasive procedures if needed at a later date as the microfracture procedure does not create thermal damage observed with drilling techniques.¹²

It is common for articular cartilage lesions of the shoulder to have concomitant injuries, such as, but not limited to labral pathology and instability.^{1,3,8,13} Other surgical procedures are commonly performed at the same time as microfracture due to the high incidence rate of other pathology found in conjunction with articular cartilage lesions. Recurrent instability and rotator cuff pathology have been associated with glenohumeral articular pathology.¹³ One study by Paley et al¹⁴ found 5% to 17% incidence of glenohumeral articular cartilage injury at the time of surgery in overhead throwing athletes and patients with rotator cuff pathology. Labrum injuries are commonly found in conjunction

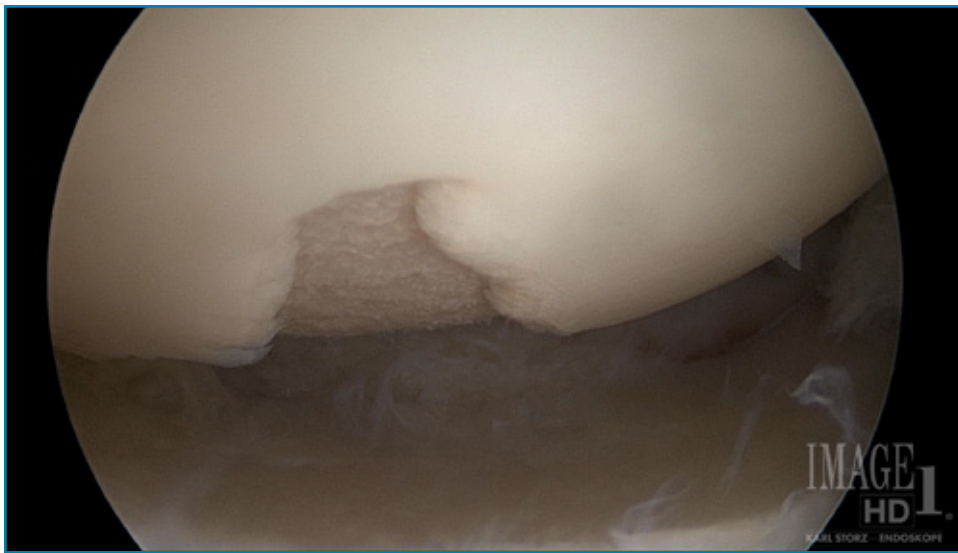

Figure 1. Humeral head grade 4 (full-thickness) articular lesion.

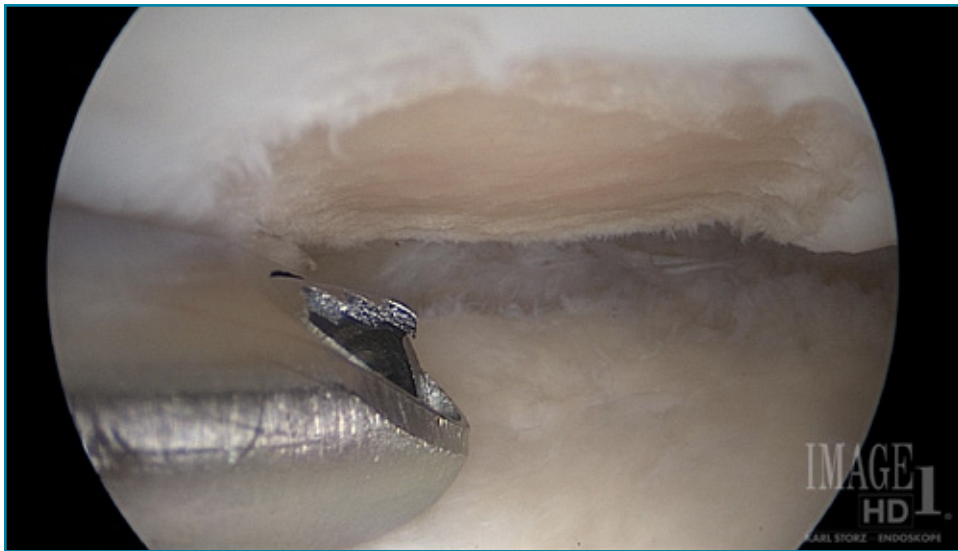

Figure 2. Microfracture site prepared with vertical walls and removed calcified cartilage layer.

rehabilitation protocol following glenohumeral microfracture procedure. The purpose of this case report is to present and discuss a rehabilitation protocol for a patient following glenohumeral microfracture procedure and Type II SLAP repair.

CASE DESCRIPTION

The patient in this case is a 41-year-old male kinesiology professor who had a sudden onset of pain, recurrent mechanical catching, audible popping, and pain in his right shoulder, particularly with athletic activities. He had no prior trauma but was very active in sports throughout his adolescent period into his adulthood. He had no previous past medical or surgical history. He was currently active in weight training, volleyball, and cross-fit training. He first noticed these symptoms after doing high repetition pull-ups and barbell bench pressing during a cross-fit session two months prior to surgery. Within a period of one to two days after symptom onset, he was unable to perform overhead activities with his right upper extremity due to pain and mechanical symptoms. He had a magnetic resonance imaging with arthrogram, which was positive for a SLAP tear and full-thickness defects of the glenoid and humeral head articular cartilage. Prior to surgery, he completed a course of physical therapy, activity modification, and anti-inflammatory medication with no improvement in symptoms. Despite conservative measures, he continued to have symptoms limiting his function. Eventually after receiving Type II SLAP repair and microfracture of the central humeral head and glenoid, he was referred to a physical therapist. The size of the humeral head articular cartilage lesion was 1.5 mm x 20 mm, the glenoid lesion measured 6 mm x 8 mm.

EXAMINATION

The patient presented to the clinic two days postsurgery in a shoulder immobilization device. There was noted ecchymosis in the upper anterior brachium with no increased skin temperature. The patient had a visual analogue scale (VAS) pain rating of 4/10 and he described his pain as a dull ache local to the right shoulder (Figure 5). The patient's goal was to resume exercise as well as athletic activities without pain.

Visual analogue scales for rating pain are commonly used by physical therapists as a means for patients to subjectively rate their level of pain. The scale used in this case report was a 10-point scale, which was administered to the patient at frequent intervals through-

with articular cartilage injuries. Both articular cartilage and labrum injuries are common in the unstable shoulder.⁸ The labrum adds to the stability of the glenohumeral joint by increasing the depth of the glenoid cavity, acting as a bumper limiting translation, serving as an attachment of the long head of the biceps, and improving the concave-convex relationship of the glenohumeral joint¹⁵

One of the most common types of labrum injuries in young, athletic populations are superior labrum anterior to posterior (SLAP) injuries. This term was first coined by Snyder¹⁶ in 1990. The SLAP tears were initially categorized into Types I to IV although there are several different classification systems in use now (Figure 4). SLAP lesions have two proposed mechanisms of injury.¹⁷ Andrew et

al¹⁸ described a mechanism of traction injury from bicep contraction, as seen during the follow through in over-head throwing. A peel back mechanism of injury resulting in SLAP lesions was described by Burkhart and Morgan.¹⁹ The "peel back" mechanism theory proposes that the labrum is "peeled back" during the cocking phase of the overhead throwing motion.

Microfracture has been studied and performed on the knee for several years. Recently this procedure has been applied to the talus, the hip, and the glenohumeral joints. While success has been well documented in the knee, there are fewer studies examining the long-term success of this procedure when applied to the glenohumeral joint. There are still fewer studies illustrating the appropriate

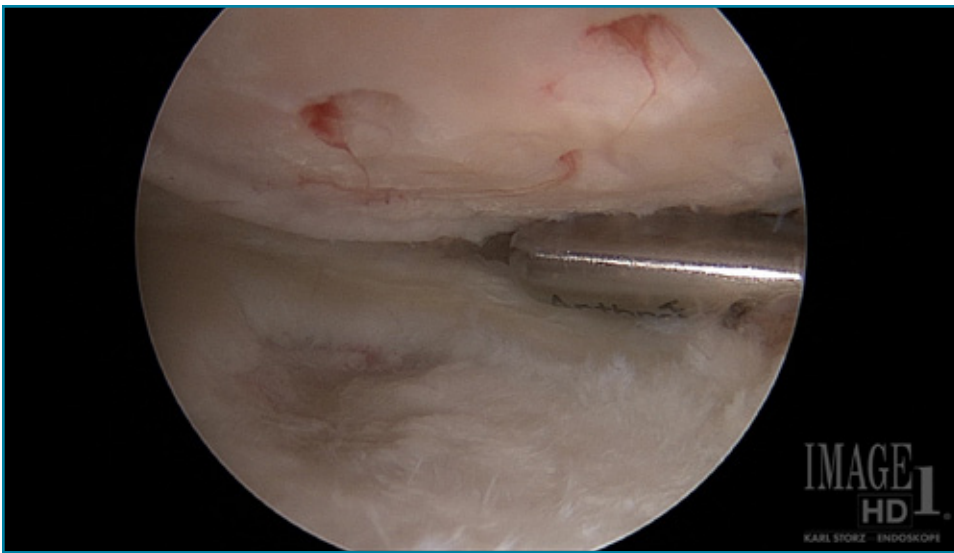


Figure 3. Microfracture procedure completed with bleeding perforations of the subchondral bone. This picture also demonstrates a full-thickness glenoid articular defect.

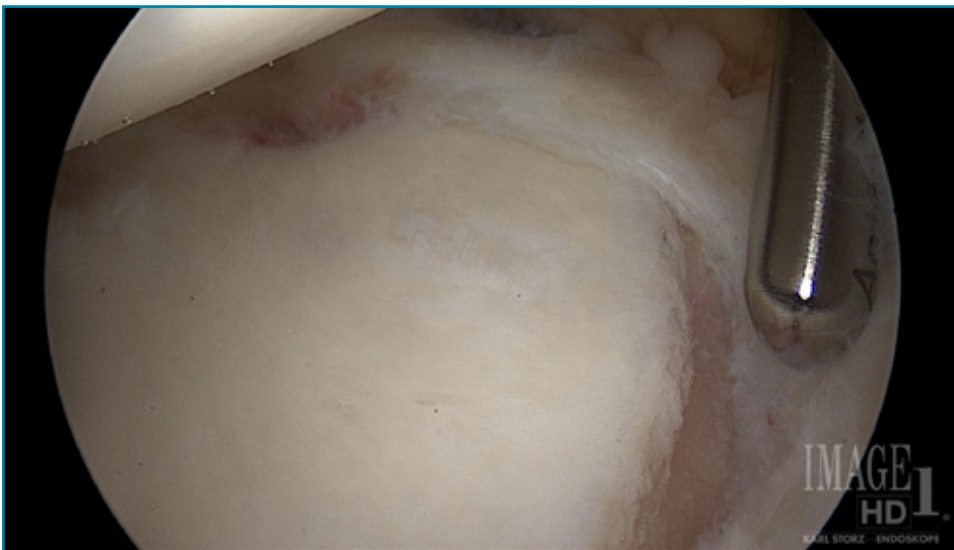


Figure 4. Type II SLAP tear after preparation.

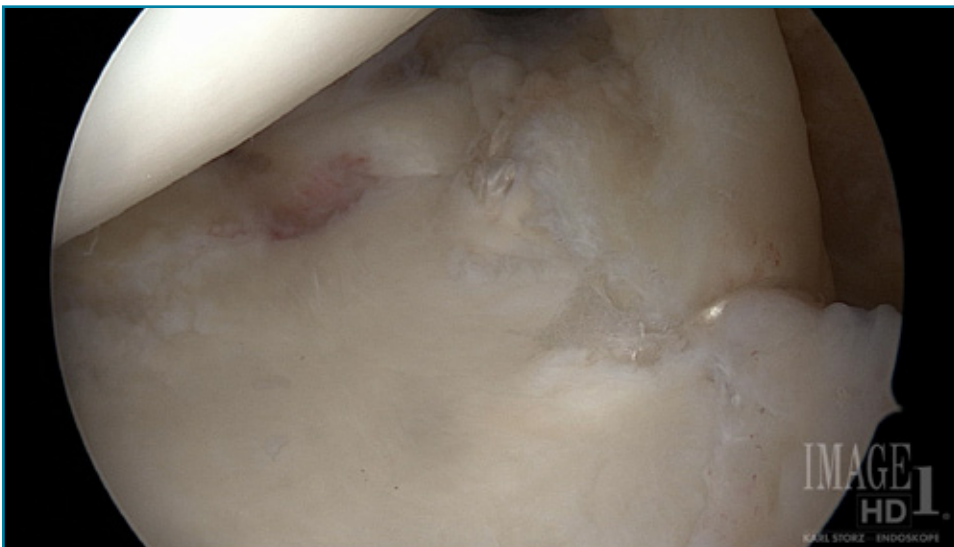

Figure 5. Type II SLAP repair.

out his course of treatment. A study by Bijur et al²⁰ examined the reliability of VAS pain ratings in the acute setting. Their findings indicate 50% of paired measurements were within 2 mm, 90% were within 9 mm, and 95% were within 16 mm. This study supports the reliability of the use of VAS for patient pain ratings in the acute setting.

Due to the patient's SLAP repair, passive range of motion (ROM) was limited to forward flexion 60°, external rotation (ER) 10°, and internal rotation (IR) to 45°. To avoid excessive compressive and shear forces to the newly forming fibrocartilaginous clot following the microfracture procedure that could be caused with active ROM, only passive ROM was employed. No strength testing or mobility testing of the shoulder was performed at the time of initial evaluation as warranted by precautions due to the SLAP and microfracture procedures.

The Quick Disabilities of Arm, Shoulder and Hand (QuickDASH) was administered as a patient-report outcome measure in this case. The QuickDASH questionnaire was developed from the original 30 question DASH questionnaire that can be used to assess the effect of any upper extremity injury.²¹ The original DASH questionnaire has shown reliability, cross-sectional and longitudinal validity in assessing upper extremity musculoskeletal disorders and the more user-friendly QuickDASH has similar test-retest reliability and measurement properties.^{21,22} The QuickDASH is an 11-item patient disability/symptom questionnaire completed by the patient. Each question has 5 response options, and scores are calculated from a 0 (no disability) to 100 (maximum disability). The QuickDASH also has two additional 4 question sections consisting of sports and work-related performance questions. The entire series was used in this case and tracked for one year post-operatively. Each item of the QuickDASH is scored 1 to 5 with 1 being "no difficulty" to 5 being "unable" to complete the activity in question. The sum of the higher scores indicate decreased function and severity.²³

Diagnosis and Prognosis

Primary impairments in this case were decreased joint mobility, decreased muscular strength, and decreased ROM. Inability to actively reach and perform activities of daily living (ADLs) were functional or activity limitations in this case. This patient's participation restrictions or disabilities included an inability to perform weight lifting, cross-fit, and volleyball. The prognosis in this case was dependent on creating the optimal healing

environment for both the microfracture procedure and Type II SLAP repair. The protocol that was developed for this case was based on limited previous research on microfracture of the shoulder despite the extensive research on microfracture of the knee. The morphologic and biomechanical differences of the knee and shoulder were key considerations when developing our protocol. Treatment strategy in this case was to follow the established protocol and examine the outcomes following the protocol. While there have been many studies performed on outcomes after glenohumeral microfracture, virtually none of these described a detailed and successful rehabilitation protocol.²⁴⁻²⁶ The patient was seen twice per week during phases 1 through 3 and once per week during phase 4 as the patient was allowed to begin to progress into a gym program during this phase. Specific goals for each phase of our protocol were included to ensure appropriate progression and protection of healing structures (Table 1). The patient's primary goal was to return to previous recreational activities not limited by pain.

Intervention

Phase 1: 0 to 6 weeks (protection-controlled ROM)

The primary goals of this phase of rehabilitation are to prevent the deleterious effects of immobilization and to provide an optimal healing environment for the Type II SLAP repair and microfracture site, using passive ROM to smooth the newly forming fibrocartilaginous matrix site.⁷ Specific ROM goals during the first week of rehabilitation were dictated by the Type II SLAP repair. The SLAP repair protocol referenced closely resembles other contemporary Type II SLAP repair protocols in regards to ROM and resistance exercise progression. Some studies advocate continuous passive range of motion (CPM) for microfracture rehabilitation of the knee and in the shoulder when there are no other complicating procedures dictating ROM limitations.^{10,24} When considering the ROM limitations exhibited following a SLAP procedure, a CPM device is not practical. In this case, the patient was issued a home exercise program (HEP) using 600 to 800 pendulum rotations divided into 3 different sessions throughout the day.^{1,11,25} This continued until the patient removed the sling at 6 weeks post-operatively. During the first 2 weeks, ROM was limited to flexion of 75°, ER to 15°, and IR to 45°. The patient was allowed to progress passive ROM during weeks 3 to 6 to flexion of 145°, ER to 45° at 45° of abduction and IR to 60° at 45° of abduction. To protect the

microfracture site from shear or compressive forces, no isometrics or strengthening exercises were performed during weeks 0 to 6. Manual therapy during phase 1 consisted of joint mobilization, soft tissue techniques, and passive ROM. Joint mobilization included grade 1 and 2 glenohumeral joint mobilization, grade 1 and 2 glenohumeral distraction. Soft tissue techniques included myofascial release techniques of the upper quarter and portal scar mobilization techniques. Pain control modalities included electrical stimulation and cryotherapy. The patient's HEP included pendulums, self-supine flexion, cane external rotation at both at 0° and 45° of abduction, and sidelying internal rotation stretching. The patient in this case had normal acromioclavicular, sternoclavicular, and scapulothoracic mobility within the first 2 weeks of therapy. Glenohumeral mobility was not assessed due to healing structure and postsurgical precautions. Range of motion goals were met for this period.

Phase 2: 7 to 11 weeks (controlled ROM to full ROM and initiation of open kinetic chain strengthening)

Primary goals of this phase were careful progression to full active ROM and a very careful progression of loading of the glenohumeral joint. During this phase, the sling was discontinued and ROM was progressed to include active assisted ROM, active ROM, and passive ROM/stretching. Strengthening was initiated with light open chain strengthening using low tension resistance bands and dumbbell exercises. The ROM goal during this period was to achieve full ROM in all planes by 12 weeks. At this time, the strengthening exercises chosen were appropriate for both SLAP repair and microfracture repairs, although the amount of weight was progressed more slowly in an effort to control the loading conditions applied to the microfracture site. During this phase, the primary goal was to continue to provide an optimal healing environment for both the Type II SLAP repair and the microfracture site. Controlled loading of the glenohumeral joint was initiated with light resistance exercise to begin to lightly stress the now maturing fibrocartilaginous matrix to allow for cell differentiation. Studies have shown at 6 weeks, the matrix is still not mature and is still undergoing cellular differentiation from Type I collagen to more of a Type II collagen composition.^{10,12} The healing fibrocartilaginous matrix is not mature enough for full weightbearing and heavy strengthening exercise at 6 weeks, but by 12 weeks is more mature and weight-

bearing strength exercise can be initiated.^{12,13} Strengthening during this period began with 1 pound to 2 pound dumbbell exercises and light resistance band exercises. The SLAP repair was protected by avoiding resistance applied through the long head of the bicep and labrum until 8 weeks, which has been promoted in several Type II SLAP repair protocols.^{15,18} Strength progression during this phase was progressed from lighter dumbbells and bands at week 7 to heavier dumbbells and resistance bands by week 11 in preparation for closed chain exercises that began at 12 weeks. Secondary to this patient being athletic and previously participating in overhead sports, a selection of short-arc Thrower's Ten exercises were included during this phase. No pressing or closed chain exercises were allowed during this phase to prevent excessive joint compression forces. This phase is a critical healing phase of the microfracture fibrocartilaginous matrix as controlled compression and stress are implemented. The gradual progression from lighter to heavier open chain resistance during this phase mimics a progression from partial weight bearing to weight bearing as described in microfracture protocols in the knee. Controlled loading and compression assist cellular differentiation and promote a more durable repair.⁷ The decision to begin open kinetic chain exercise and no closed chain exercise was derived from studies demonstrating greater compressive joint stress with closed chain exercises.^{27,28} Light open chain strength exercises were implemented in this phase and cause more shear stress and less compressive force as compared to closed kinetic chain exercises.²⁷

Joint mobility testing of the glenohumeral joint at 7 weeks revealed grade 2 hypomobility with a posterior to anterior glide and superior to inferior glide of the glenohumeral joint indicating inferior and anterior capsule restriction. Manual therapy during this phase was advanced regarding the glenohumeral joint to grade 3 and 4 mobilizations as well as grade 2 and 3 distraction to address glenohumeral capsular restriction. The advancement of the grades of mobilization and distraction were appropriate at this time to promote normal mobility and ROM. At 10 weeks postsurgery, the patient had full flexion, IR, and abduction. External rotation at 90° of abduction was still considered minimally limited at 80°. With continued manual therapy and stretching exercises, the patient had full active and passive ROM in all motions as compared to his opposite (left) shoulder by 12 weeks postsurgery. Glenohumeral joint mobility at this time was assessed

Table 1. Postoperative Rehabilitation for Type II SLAP and Glenohumeral Microfracture Protocol

I. Post-op Phase 1: Protection-Controlled Range of Motion (0-6 weeks):

GOALS

1. Protection-sling for 6 weeks
2. Pain management
3. Gentle mobilization within the limits of available motion
4. Prevent negative effects of immobilization
5. Provide ideal environment for healing

EXERCISES

Week 0-2

- Pendulum minimum 600-800 cycles per day (3-4 sessions/day)
- Passive range of motion shoulder
 - Week 1 flexion 60° (week 2, flexion 75°)
 - 60° abduction in the scapular plane
 - External rotation 10°-15° and internal rotation 45° in scapular plane
 - No active external rotation or extension or abduction
- Scapulothoracic, wrist, hand active range of motion exercises, grip exercises
- No isolated biceps contraction
- Manual therapy for grade 1-2 mobilization and distraction of the glenohumeral joint, grade 1-4 mobilization of the scapulothoracic, acromioclavicular, sternoclavicular joints, and soft tissue techniques as needed
- Cryotherapy, modalities as indicated

Week 3-4

- Continue use of sling until 6 weeks
- Continue 600-800 pendulums per day
- Continue gentle range of motion exercises (passive ROM)
 - Flexion to 90°
 - Abduction to 75°-85°
 - External rotation at 45° abduction to 25°-30°
 - Internal rotation at 45° abduction to 55°-60°
 - Resistance band rotator cuff strengthening
 - Scapulothoracic stabilization/strengthening, dumbbell rows multi-angle, scapular protraction, elevation, setting
 - Body blade in scaption
 - Proprioceptive neuromuscular facilitation patterns with light bands
 - Manual techniques
 - Proprioceptive neuromuscular facilitation patterns and rhythmic stabilization strengthening
 - Open kinetic chain perturbation exercises
 - Progression to grade 3-4 joint mobilization and soft tissue mobilization as needed

II. Post-op Phase 2: Controlled ROM to Full ROM and initiation of open kinetic chain strengthening (7-11 weeks):

GOALS

1. Gradually restore full ROM by 10-12 weeks
2. Protect SLAP and microfracture repairs
3. Begin controlled loading of the microfracture repair and begin light open chain strength program

Week 7-9

- Gradually improve ROM to full ROM
 - Flexion to 180°
 - External rotation at 90° abduction: 90°-95°
 - Internal rotation at 90° abduction: 70°-75°
- Begin open chain strengthening program short lever (limit 5 lbs. and light resistance bands) selected short lever Thrower's Ten exercises

Week 10-11

- May progress resistance program (light-medium resistance bands and 15#)
- Progress external rotation ROM
 - External rotation at 90°-100° (goal to be equal to opposite)
 - Continue all stretching and strengthening exercises
 - Consider additional ROM needed for the overhead athlete
 - May begin light bicep resistance exercises

EXERCISES

- Active warm-up

- Sidelying external rotation, prone series
- Resistance band rotator cuff strengthening
- Scapulothoracic stabilization/strengthening, dumbbell rows multi-angle, scapular protraction, elevation, setting
- Body blade in scaption
- PNF patterns with light bands

Manual techniques

- Proprioceptive neuromuscular facilitation patterns and rhythmic stabilization strengthening
- Open kinetic chain perturbation exercises
- Progression to grade 3-4 joint mobilization and soft tissue mobilization as needed

III. Post-op Phase 3: Initiation of closed chain, advanced open chain, and dynamic strengthening (12-19 weeks):

GOALS

1. Maintain full ROM
2. Continue controlled loading conditions
3. Promote muscular strength and joint stability
4. Gradually initiate functional activities

Criteria to enter phase III

- Full nonpainful ROM
- 4/5 to 4+5 muscular strength (scapular and rotator cuff muscle groups)
- No pain or tenderness with phase II strength exercises

Weeks 12-15

- Continue open chain strengthening exercises
 - Advanced band and dumbbell exercise and advanced Thrower's Ten program
 - PNF manual resistance
 - Initiate light plyometric program
 - Low level aquatic/swimming exercises
 - Continue stretching program as needed
- Closed chain exercises
 - Front and side planks
 - Ball stability exercises
 - Closed chain upper extremity yoga poses

Week 16-19

- Continue plyometric program
- Continue manual strength exercise (PNF, rhythmic stabilization)
- Continue open chain strength program
- Body weight push-ups and pull-ups
- Closed chain perturbation exercises
- Dumbbell and barbell isotonic exercises not to exceed previous 50% of 1 RM (or estimate)

IV. Phase 4: Advanced strengthening phase (20-24 weeks)

GOALS

1. Promote dynamic strength and stability
2. Prepare for return to sport

Criteria to enter phase IV

- Full range of motion
- Painless performance of phase 3 exercise

Week 20-24

- Continue open and closed chain strength program
- Proprioceptive neuromuscular facilitation manual-resistance patterns
- Continue plyometric strengthening
- Initiate throwing program and/or sport specific training

V. Phase 5: Return-to-activity phase (6 months +)

GOALS

1. Gradual return to sport activities
2. Maintain strength, mobility, and stability

Criteria to enter phase V

- Full functional range of motion
- Muscular performance 5/5 strength or isokinetic benchmarks
- No pain or tenderness

Continue stretching and advanced strengthening program

Abbreviations: ROM, range of motion; SLAP, superior labrum anterior to posterior; PNF, proprioceptive neuromuscular facilitation; 1 RM, one rep max

as normal, allowing progression to phase 3 of the protocol.

Phase 3: 12 to 19 weeks (initiation of closed chain, advanced open-chain, and dynamic strengthening)

In this phase, closed kinetic chain strength exercises were introduced. At 12 weeks post-microfracture procedure, the fibrocartilaginous matrix filling the microfracture site has been shown to be relatively mature.^{12,13} The decision to begin resistance with open chain exercise and begin closed chain strengthening at 12 weeks was in an effort to control the force or loading conditions of the fibrocartilaginous matrix. Gradually increase the loading conditions to which the microfracture site was exposed to allow cell differentiation and further maturation of the microfracture repair. Strength exercises during this phase included isotonic exercise and closed kinetic chain exercises using the patient's body weight. Isotonic exercises included resistance bands, dumbbells, cable machines, and barbell weights. Initially, closed chain body weight exercises were isometric or static exercises which were then progressed to compound body weight exercises beginning during week 16. All exercises were monitored for careful progression of resistance over the course of this 8 week phase. Plyometric exercises such as the body blade and ball rebounding were also implemented and progressed during this phase. Manual therapy during this phase consisted of rhythmic stabilization at various angles, diagonal proprioceptive neuromuscular facilitation patterns, and closed chain perturbations applied by the physical therapist. At this time, very little soft tissue or joint mobilization was needed as the patient had full, pain-free ROM prior to beginning this phase by week 12.

Phase 4: 20-24 weeks (advanced strengthening)

During this final phase of supervised rehabilitation, the patient was allowed to resume a semi-independent gym program, yet he was educated on avoiding extremes in joint loading, such as heavy pressing activities. The goal for his gym program was to never exceed 75% of his previous 1 rep max on any upper body pressing exercises. The patient was seen for advanced lifting and resisted manual therapy training once per week. Sport specific exercises such as low level volleyball drills and weighted ball plyometric drills were implemented during supervised therapy sessions.

Phase 5: 6 months + (return to activity)

This phase marked the end of supervised training and the beginning of the patient's independent resistance and sports training. The patient had met all of his goals for each phase of the protocol and was also well educated on his future training plan. The patient was cautioned to limit and avoid high-impact and extreme loading activities. A graduated volleyball serving program was also provided to the patient.

OUTCOMES

Outcomes for this case were measured with the following parameters: ROM, strength, pain, and the QuickDASH self-report questionnaire. Factors affecting the outcome following microfracture procedure in the glenohumeral joint are of course proper surgical technique, rehabilitation, patient selection, and whether there are unipolar (involving one joint surface) or bipolar lesions (involving both the glenoid and humeral head). Unipolar lesions have been observed to have a higher success rate when compared to bipolar lesions in the shoulder.^{1,12,25,26}

The patient in this case failed conservative measures, underwent microfracture and Type II SLAP repair surgery, completed a 6-month course of postsurgical physical therapy, and was followed postoperatively for one year. One unique aspect of this case is that his supervised physical therapy began two days postoperatively. His final supervised visit was during his 24th week, which according to the protocol, is the appropriate time for him to begin independent, sport-specific training. He was able to meet all of his previously established physical therapy goals. The patient had several phone interviews to answer minor questions he had regarding his independent training and check on his independent progression. His final measurement was in the form of verbal questioning for his pain level and to complete the QuickDASH questionnaire at his one year anniversary date following surgery.

This patient made consistent progress in regards to his ROM and progressed within the ROM guidelines dictated primarily by his Type II SLAP repair. He did experience stiffness, particularly in progressing external rotation from weeks 7 through 11. He was however able to meet his goal of being equal to his contralateral shoulder prior to 12 weeks postsurgery.

This patient also met his strength goals of 5/5 strength with rotator cuff, scapular, and upper extremity muscle groups. Due to both the SLAP and microfracture procedures,

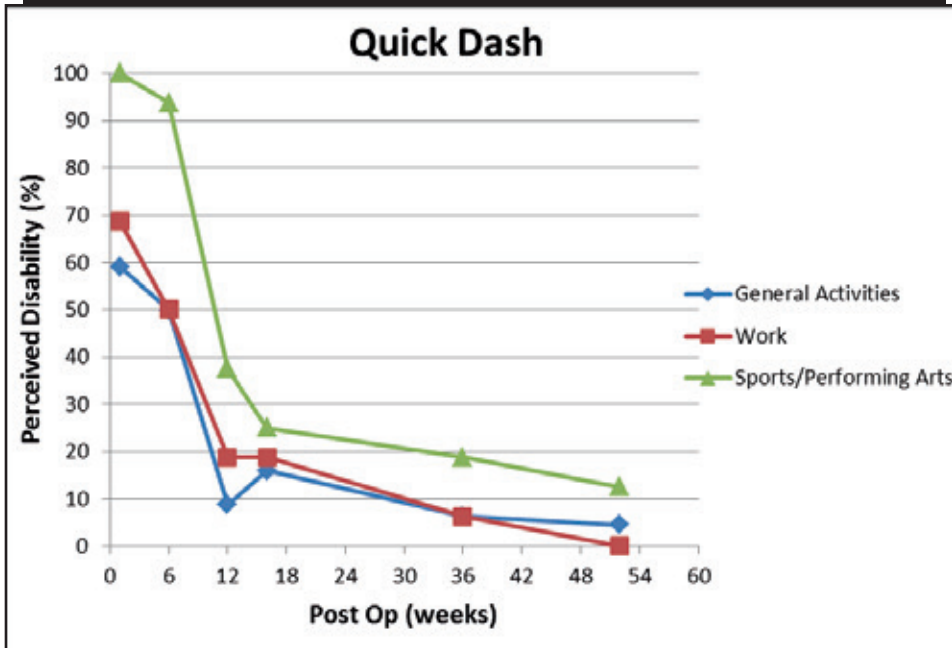
light open chain strength exercises were initiated first and gradually progressed to heavier weight and eventually closed chain exercises. Open chain exercises have been shown to be effective in addressing specific rotator cuff muscle imbalances or weakness. Closed chain strength exercises have been shown to be essential in promoting functional and overall rotator cuff strength.²⁹ In this case, open chain strength exercises initiated first in an effort to limit compressive joint forces. This is imperative in creating an optimal healing environment after the microfracture procedure.

Pain ratings during the course of this patient's rehabilitation remained relatively low ranging from 4 to 0 on a visual analog scale. The progression of pain scores followed a linear scale and the patient was able to meet his pain-related goal of returning to full, painfree function. This patient did continue to experience what he described as a "dull ache" after weight training or sporting activities such as volleyball. These symptoms usually lasted 24 to 48 hours and were 1-2/10 on the VAS.

The QuickDASH was implemented in this case and demonstrated considerable improvement during the course of treatment. It was developed from the original DASH questionnaire to be a shortened yet still accurate measure of disabilities of the upper extremity.²¹ A study by Gummesson et al²² compared the longitudinal construct validity of the DASH versus the QuickDASH in distinguishing patients after shoulder surgery and found the effect size for the DASH was 0.79 and for QuickDASH was 0.74. The standardized mean response was for the DASH was 0.45 and QuickDASH was 0.46. The ROC analysis indicated no difference in their ability to distinguish between groups. In this same study by Gummesson et al²² the reliability of the QuickDASH when compared to the original DASH was also found to be similar. In a study by Matheson et al²³ test re-test reliability of the QuickDASH was found to be 0.90 without the work component and 0.94 with the work component included. The minimal clinically important difference (MCID) is the amount of change in the score of a measure that must occur to indicate an important or meaningful difference in the patient's condition. In a study by Minken et al,³⁰ MCID was determined to be 8 points for the QuickDASH in rating patients with shoulder pain.

In this case report, QuickDASH scores continued to show improvement in all categories up to the one year follow-up. The general activities section showed an improvement of 68.75% from 68.75 to 0, the sports sec-

Table 2. DASH Scores Over a One-year Period



tion showed an improvement of 87.5% from 100 to 12.5, and work section showed an improvement of 59.09% from 62.64 to 4.55 over the course of the year following surgery (Table 2).

DISCUSSION

The purpose of this case report was to present a detailed rehabilitation protocol following glenohumeral microfracture and Type II SLAP repair. Although the microfracture procedure has become the first-line choice for focal full-thickness articular cartilage lesions in the knee, less research has been done on outcomes following microfracture in the shoulder.^{12,26} There is an abundance of outcome studies and rehabilitation protocols following a microfracture procedure in the knee. However, there are few studies following outcomes of microfracture in the shoulder. There are still fewer studies following a detailed rehabilitation protocol after microfracture of the shoulder.

The success of fibrocartilaginous repair depends on appropriate rehabilitation, proper surgical technique, and consideration of any other procedures performed. A study performed by Kerr and McCarty³¹ on arthroscopic debridement of unipolar and bipolar articular cartilage lesions in the shoulder found significantly improved outcomes in patients with unipolar lesions. A study by Millett et al²⁶ performed on outcomes following glenohumeral microfracture found patients with smaller lesions and patients who were treated for unipolar lesions of the humerus

had better outcomes versus poorer outcome for patients with bipolar lesions. In a study by Frank et al²⁵ the overall success rate following glenohumeral microfracture was 80%.

Physiologic cartilage characteristics and morphologic differences between the knee and shoulder joint were taken into account when developing this protocol. The shoulder has more degrees of freedom, thinner articular cartilage, and is a nonweight-bearing joint when compared to the knee joint.^{1,4,10,26} These differences are imperative to understand when considering rehabilitation after surgery. One of the most considerable differences is the thickness of the articular cartilage of the shoulder versus the knee joint. Average articular cartilage may range from 1 mm to 1.5 mm in the glenohumeral joint compared to 2 mm to 3 mm in the knee.^{8,10,32} Another major difference between the knee and the shoulder joint would be the loading conditions that each joint experiences in daily life.⁵ Strength and loading conditions were progressed at a slower pace during this study due to these differences. Motion is critical in stimulating synovial fluid, which in turn nourishes the forming fibrocartilaginous clot and surrounding articular cartilage.¹⁰ Controlled mechanical loading and motion are also thought to aid in cell differentiation and collagen synthesis.^{6,9,21}

CONCLUSION

This case report presented a protocol and treatment approach used on a patient with both a Type II SLAP tear repair and gleno-

humeral microfracture procedure. Due to the extensive amount of research and plethora of protocols on rehabilitation of Type II SLAP repairs, much of this case study discussed principles and research guiding the development of the glenohumeral microfracture portion of this case since frequently articular cartilage injuries are linked to trauma, instability, and impact or torsional loading. Rehabilitation of articular injury is often performed while considering other injuries and their respective treatment protocols.^{2,8,11} Early motion is required for synovial fluid production and cellular differentiation, both are necessary for a successful outcome following microfracture.^{2,8} The most important factors in rehabilitation following a microfracture procedure of the shoulder are early ROM and controlled loading conditions.

In this case report, we elected to initiate a light open chain strength program to minimize compressive force to glenohumeral joint at 7 weeks postsurgery. Closed chain strength exercises were implemented at 12 weeks once the microfracture site had matured enough to tolerate increased compressive force or joint loading. Several studies support a more mature fibrocartilaginous matrix at 12 weeks, which would tolerate compressive loading more easily.^{9,12,13} While this patient had an outstanding outcome following this surgery and rehabilitation protocol, there are many factors affecting each individual's outcome. The single subject design of this case report prevents any cause and effect relationship or generalization to other patients. The presented protocol is based on current evidence and can be used as a starting point for further glenohumeral microfracture protocol development.

One area of future consideration would be application of resistance exercise and weight-bearing exercise later during postsurgery recovery. Several studies suggest the vulnerability of the fibrocartilaginous clot between weeks 6 and 12.^{12,13} Of great benefit would be a long-term outcome study performed with patients who have undergone unipolar humeral head microfracture procedure with delayed strength training until 12 weeks versus patients who followed a progression of strength from open chain to closed chain such as our described protocol.

REFERENCES

- Salata MJ, Kercher JS, Bajaj S, Verma NN, Cole BJ. Glenohumeral microfracture. *Cartilage*. 2010;1(2):121-126. doi:10.1177/1947603510366577.
- Buckwalter JA. Articular cartilage: injuries and potential for healing. *J Orthop Sports Phys Ther*. 1998;28(4):192-202. doi:10.2519/jospt.1998.28.4.192.
- Elser F, Dewing CB, Millett PJ. Chondral and osteochondral lesions of the humerus: diagnosis and Management. *Oper Tech Sports Med*. 2008;16(4):178-186. doi:10.1053/j.otsm.2008.12.005.
- Van der Meijden OA, Gaskill TR, Millett PJ. Glenohumeral joint preservation: a review of management options for young, active patients with osteoarthritis. *Adv Orthop*. 2012;2012:160923. doi:10.1155/2012/160923 Epub 2012 Mar 27.
- Camp CL, Stuart MJ, Krych AJ. Current concepts of articular cartilage restoration techniques in the knee. *Sports Health*. 2014;6(3):265-273. doi:10.1177/1941738113508917.
- Vanwanseele B, Lucchinetti E, Stüssi E. The effects of immobilization on the characteristics of articular cartilage: current concepts and future directions. *Osteoarthritis Cartilage*. 2002;10(5):408-419. doi:10.1053/joca.2002.0529.
- Reinold MM, Wilk KE, Macrina LC, Dugas JR, Cain EL. Current concepts in the rehabilitation following articular cartilage repair procedures in the knee. *J Orthop Sports Phys Ther*. 2006;36(10):774-794. doi:10.2519/jospt.2006.2228.
- Elser F, Braun S, Dewing CB, Millett PJ. Glenohumeral joint preservation: current options for managing articular cartilage lesions in young, active patients. *Arthroscopy*. 2010;26(5):685-696. doi:10.1016/j.arthro.2009.10.017. Epub 2010 Apr 8.
- Snow M, Funk L. Microfracture of chondral lesions of the glenohumeral joint. *Int J Shoulder Surg*. 2008;2(4):72-76. doi:10.4103/0973-6042.44142.
- Slabaugh MA, Frank RM, Cole BJ. Resurfacing of isolated articular cartilage defects in the glenohumeral joint with microfracture: a surgical technique & case report. *Am J Orthop (Belle Mead NJ)*. 2010;39(7):326-332.
- Steadman JR, Briggs KK, Rodrigo JJ, Kocher MS, Gill TJ, Rodkey WG. Outcomes of microfracture for traumatic chondral defects of the knee: average 11-year follow-up. *Arthroscopy*. 2003;19(5):477-484. doi:10.1053/jars.2003.50112.
- Gill TJ, Asnis PD, Berkson EM. The treatment of articular cartilage defects using the microfracture technique. *J Orthop Sports Phys Ther*. 2006;36(10):728-738. doi:10.2519/jospt.2006.2444.
- McCarty LP 3rd, Cole BJ. Nonarthroplasty treatment of glenohumeral cartilage lesions. *Arthroscopy*. 2005;21(9):1131-1142. doi:10.1016/j.arthro.2005.06.023.
- Paley KJ, Jobe FW, Pink MM, Kvitne RS, ElAttrache NS. Arthroscopic findings in the overhand throwing athlete: evidence for posterior internal impingement of the rotator cuff. *Arthroscopy*. 2000;16(1):35-40. doi:10.1016/S0749-8063(00)90125-7.
- Wilk KE, Reinold MM, Dugas JR, Arrigo CA, Moser MW, Andrews JR. Current concepts in the recognition and treatment of superior labral (SLAP) lesions. *J Orthop Sports Phys Ther*. 2005;35(5):273-291. doi:10.2519/jospt.2005.35.5.273.
- Snyder SJ, Karzel RP, Del Pizzo W, Ferkel RD, Friedman MJ. SLAP Lesions of the Shoulder. *Arthroscopy*. 1990;6(4):274-279. doi:10.1016/0749-8063(89)90025-x.
- Dodson CC, Altchek DW. SLAP Lesions: An update on recognition and treatment. *J Orthop Sports Phys Ther*. 2009;39(2):71-80. doi:10.2519/jospt.2009.2850.
- Andrews JR, Carson WG. The arthroscopic treatment of glenoid labrum tears in the throwing athlete. *Orthop Trans*. 1984;8:44-49.
- Burkhart SS, Morgan CD. The peel-back mechanism: Its role in producing and extending posterior type II SLAP lesions and its effect on SLAP repair rehabilitation. *Arthroscopy*. 1998;14(6):637-640. doi:10.1016/S0749-8063(98)70065-9.
- Bijur PE, Silver W, Gallagher EJ. Reliability of the visual analog scale for measurement of acute pain. *Acad Emerg Med*. 2001;8(12):1153-1157.
- Beaton DE. Development of the QuickDASH: comparison of three item-reduction approaches. *J Bone Joint Surg Am*. 2005;87(5):1038-1046. doi:10.2106/JBJS.D.02060.
- Gummesson C, Ward MM, Atroshi I. The shortened disabilities of the arm, shoulder and hand questionnaire (QuickDASH): validity and reliability based on responses within the full-length DASH. *BMC Musculoskeletal Disord*. 2006;7:44. doi:10.1186/1471-2474-7-44.
- Matheson LN, Melhorn JM, Mayer TG, Therodore BR, Gatchel RJ. Reliability of a visual analog version of the QuickDASH. *J Bone Joint Surg Am*. 2006;88(8):1782-1787. doi:10.2106/JBJS.F.00406.
- Hensley CP, Sum J. Physical therapy intervention for a former power lifter after arthroscopic microfracture procedure for grade iv glenohumeral chondral defects. *Int J Sports Phys Ther*. 2011;6(1):10-26.
- Frank RM, Van Thiel GS, Slabaugh MA, Romeo AA, Cole BJ, Verma NN. Clinical outcomes after microfracture of the glenohumeral joint. *Am J Sports Med*. 2010;38(4):772-781. doi:10.1177/0363546509350304. Epub 2010 Jan 21.
- Millett PJ, Huffard BH, Horan MP, Hawkins RJ, Steadman JR. Outcomes of full-thickness articular cartilage injuries of the shoulder treated with microfracture. *Arthroscopy*. 2009;25(8):856-863. doi:10.1016/j.arthro.2009.02.009.
- Lutz GE, Palmitier RA, An Kn, Chao EY. Comparison of tibiofemoral joint forces during open-kinetic-chain and closed-kinetic-chain exercises. *J Bone Joint Surg Am*. 1993;75(5):732-739. doi:10.2106/00004623-199305000-00014.
- Dillman CJ, Murray TA, Hintermeister RA. Biomechanical differences of open and closed chain exercises with respect to the shoulder. *J Sport Rehabil*. 1994;3(3):228-238. doi:10.1123/jsr.3.3.228.
- Giannakopoulos K, Beneka A, Malliou P, Godolias G. Isolated vs. complex exercise in strengthening the rotator cuff muscle group. *J Strength Cond Res*. 2004;18(1):144-148.
- Mintken PE, Glynn P, Cleland JA. Psychometric properties of the shortened disabilities of the arm, shoulder, and hand questionnaire (QuickDASH) and numeric pain rating scale in patients with shoulder pain. *J Shoulder Elbow Surg*. 2009;18(6):920-926. doi:10.1016/j.jse.2008.12.015. Epub 2009 Mar 17.
- Kerr BJ, McCarty EC. Outcome of arthroscopic debridement is worse for patients with glenohumeral arthritis of both sides of the joint. *Clin Orthop Relat Res*. 2008;466(3):634-8. doi:10.1007/s11999-007-0088-0. Epub 2008 Feb 10.
- Graichen H, Jakob J, von Eisenhart-Ropthe R, Englemeier KH, Reiser M, Eckstein F. Validation of cartilage volume and thickness measurements in the human shoulder with quantitative magnetic resonance imaging. *Osteoarthritis Cartilage*. 2003;11(7):475-482. doi:10.1016/S1063-4584(03)00077-3.