

Ida-Maria Leppäpuska

**Novel combined surgical treatment for chronic upper extremity lymphedema patients:
simultaneous lymph node transfer and liposuction**

Syventävien opintojen kirjallinen työ
Syyslukukausi 2018

Ida-Maria Leppäpuska

**Novel combined surgical treatment for chronic upper extremity lymphedema patients:
simultaneous lymph node transfer and liposuction**

Plastiikka- ja yleiskirurgian klinikka

Syyslukukausi 2018

Vastuuhenkilö: Pauliina Hartiala

The originality of this thesis has been checked in accordance with the University of Turku quality assurance system using the Turnitin OriginalityCheck service.

TURUN YLIOPISTO
Lääketieteellinen tiedekunta

LEPPÄPUSKA, IDA-MARIA: Imusolmuke siirto ja rasvaimu samassa leikkauksessa
kroonisen lymfedeman hoidossa

Syventävien opintojen kirjallinen työ, 25 s., 6 liites.

Kirurgia

Lokakuu 2018

Rintasyövän kirurgiseen hoitoon kuuluu joko vartijaimusolmuketutkimus tai kainalon imusolmukkeiden poisto syövän levinneisyydestä riippuen. Näiden seurauksena osalla potilaista imutiejärjestelmä vaurioituu, joka voi aiheuttaa turvotusta (lymfedeemaa), kipuoireistoa ja altistaa toistuville ruusuinfektioille. Tiedetään, että lymfaneste indusoi rasvakudoksen kasvua jolloin myöhäisessä vaiheessa ja hoitamattomana lymfedema pahimmillaan kehittyy krooniseksi rasvakudositylimääräksi vaikeuttaen potilaan jokapäiväistä elämää. Lymfedeman tarkka syntymekanismi tunnetaan huonosti, mutta tiedetään että imutiekasvutekijöillä ja inflammaatiolla on merkittävä rooli tässä. Tutkimusten mukaan 9-41 %:lle kainaloevakuaatiopotilaista yläraajaan kehittyy pysyvä turvotus. Tällä hetkellä hoitona lymfedemaan on pääasiassa konservatiiviset keinot, kuten kompressiotekstiilit ja lymfaterapia. Lymfedemaa pyritään parantamaan mm. mikrokirurgisin menetelmin, kuten imusolmukkeita siirtämällä kudostekielekkeen avulla terveestä nivusesta lymfedemaraajan kainaloon.

Tutkimuksessamme oli mukana 21 lymfedemapotilasta, jotka operoitiin Turun yliopistollisessa keskussairaalassa 10/2009–2/2015 kombinoidulla tekniikalla eli potilaille tehtiin samassa operaatiossa sekä imusolmuke siirto sekä käden rasvaimu. Osalle potilaista (n=11) tehtiin imusolmuke siirto nivusesta kainaloon ja osalle potilaista (n=10) imusolmuke siirto yhdistettiin rinnan TRAM-rekonstruktioon. Seurasimme potilaita $48,9 \pm 15,4$ kuukautta ja vertasimme tuloksia potilasaineistoomme, jossa lymfedema hoidettiin pelkällä imusolmuke siirteellä ilman rasvaimua. Hyötyä mitattiin raajan tilavuusmittausten, konservatiivisen hoidon tarpeen, ja imuteiden lymfoskintigrafiakuvausten avulla.

Postoperatiivisesti raajan volyymi pysyi pienenä eikä kompressiohihan poisto lisännyt turvotusta. Kompressiotekstiilien tarve väheni 17/21:lla potilaalla, lymfoskintigrafiatulokset paranivat 12/15:lla potilaalla, ruusuinfektiot vähenivät 7/10:lla ja neuropaattinen kipu raajassa väheni 4/5:lla potilaalla. Rasvaimuun liittyviä komplikaatioita ei ilmennyt ja leikkausten komplikaatioprofiilit vastasivat toisiaan rasvaimulla ja ilman. Tulokset osoittavat ensimmäistä kertaa, että rasvaimu voidaan turvallisesti yhdistää imusolmuke siirtoleikkaukseen. Kombinoidulla operaatiossa potilaiden käden volyymi saadaan tervettä kättä vastaavaksi, imunestekiertoa palautettua ja konservatiiviset hoidot pystytään osin tai kokonaan lopettamaan. Kliiniset tulokset ovat hyviä huomioiden potilaiden lähtökohtaisesti vaikeasteisen lymfedeman.

Avainsanat: Lymfedema, imusolmuke siirre, rasvaimu

**Novel combined surgical treatment for chronic upper extremity
lymphedema patients: simultaneous lymph node transfer and
liposuction**

**Leppäpuska IM¹, Suominen E¹, Viitanen T¹, Sulo E¹, Visuri MT¹,
Mäki M², Saarikko AM³, Hartiala P^{1,4}**

1. Department of Plastic and General Surgery, Turku University Hospital, Turku, Finland.
2. Department of Clinical Physiology and Nuclear Medicine, Turku University Hospital, Turku, Finland.
3. Department of Plastic Surgery, Helsinki University Central Hospital, Helsinki, Finland.
4. Institute of Biomedicine, University of Turku, Finland.

Abstract

BACKGROUND: Upper limb lymphedema is a common problem after axillary lymph node dissection. Lymphatic drainage can be improved by microvascular lymph node transfer, whereas liposuction can be used to reduce arm volume and excess of adipose tissue. We present the results of chronic lymphedema patients who have undergone lymph node transfer and liposuction simultaneously in one operation and compare the results to patients who have undergone lymph node transfer without liposuction.

METHODS: During May 2007 to February 2015, 20 postmastectomy patients and one Hodgkin's lymphoma patient presenting with chronic non-pitting lymphedema (age between 37-74 years, average 56.7 years) were operated using the combined technique and 27 postmastectomy patients presenting with early stage lymphedema (age between 31 to 68 years, average age 50.2 years) were operated using only the lymph node transfer. Changes in clinical parameters, arm volume, lymphoscintigraphy and compression garment usage were compared. The study was retrospective observational study.

RESULTS: In the combined technique group the average arm volume excess decreased postoperatively 87.7% and in 7/10 patients the edema volume did not increase even without compression. 17/21 patients were able to reduce the use of compression garment. Lymphoscintigraphy results were improved in 12/15 patients and the improvement was significantly greater than in the lymph node transfer group. The number of erysipelas infections was decreased in 7/10 patients and the decrease was significantly greater than in the lymph node transfer group. In the lymph node transfer group the average excess volume decreased postoperatively 27.5%. 14/27 patients were able to reduce the use of compression garment. Lymphoscintigraphy results were improved in 8/19 patients, the number of erysipelas infections was decreased in 1/3 patients.

CONCLUSIONS: Liposuction can safely be performed with lymph node transfer in one operation to achieve optimal results in patients with chronic lymphedema. The combined technique provides immediate volume reduction and further regenerative effects on the lymphatic circulation. The significantly greater reduction in lymphoscintigraphy values and erysipelas infections suggests that the combined technique might be better for late stage lymphedema patients than lymph node transfer alone.

Keywords

Lymphedema, Breast reconstruction, Reconstructive surgery, Liposuction

Introduction

The incidence of postmastectomy lymphedema varies from 9 to 41 % in patients who have undergone axillary lymph node dissection¹⁻⁴. Chronic lymphedema is a progressive disease characterized by the accumulation of interstitial fluid leading to the pitting edema of the affected limb, later accompanied by the proliferation of irreversible fibro-adipose tissue and non-pitting edema. These changes cause pain and decrease the function of the affected arm. It is not clear why only some patients develop lymphedema after axillary dissection. Vascular endothelial growth factors (VEGF-C and VEGF-D) have been thought to play a role in the process⁵.

Treatment of lymphedema is based on manual lymphatic drainage and compression garments, which are effective in early stage lymphedema. Patients at later stages suffering from non-pitting lymphedema and fat hypertrophy do not respond to conservative treatment well as the hypertrophic tissue does not respond to compression therapy. During the recent years surgical treatment options have developed including lymph node transfer⁶⁻¹⁰. Lymph node transfer can improve lymphatic drainage and it can be used as a treatment in early stage lymphedema^{11,12}. At later stages of lymphedema presenting as excess of fatty tissue of the affected arm, liposuction must be included to reduce the volume of the arm. Liposuction has been shown to be an effective treatment for reducing limb volume and it also has good functional results^{13,14}. Liposuction reduces the arm volume and also the infection risk but patients need to continue wearing the compression garments after the operation¹⁴.

Several case report studies have presented a combined treatment modality in which liposuction and lymph node transfer have been performed for the same patients. However, in these studies liposuction has been performed 10 weeks, 11 months or 22 months before or 1 to 3 months after lymph node transfer in a separate operation¹⁵⁻¹⁷. In this article, we introduce how liposuction can safely be performed simultaneously with lymph node transfer for chronic late-stage lymphedema patients and present the results of the first 21 patients operated using the combined technique. We also analyzed lymphangiogenesis associated growth factor (VEGF-C, VEGF-D) concentrations in the wound fluids of these patients.

Patients and methods

Between October 2009 and February 2015, 20 postmastectomy patients and one Hodgkin's lymphoma patient were operated in Turku University Hospital. All patients had a long history (range between 12 to 185 months, average 52 months) of chronic lymphedema with non-pitting edema and deposition of fat and fibrotic tissue after axillary lymphadenectomy and radiation therapy. Indications for the combined lymph node transfer and liposuction were clinically diagnosed lymphedema with over 500 ml non-pitting edema compared to contralateral arm and reduced lymphatic function in lymphoscintigraphy. Clinical efficacy of the combined lymph node transfer and liposuction was evaluated. The study was retrospective observational study.

Operative technique

A total of 21 patients (age between 37 to 74 years, average age 56.7 years) with moderate to severe stage II upper extremity lymphedema underwent lymph node flap transfer (LN). Of these, 11 patients underwent lymph node transfer combined with liposuction (LIPO) of the affected arm and 10 patients underwent simultaneous breast reconstruction and lymph node transfer¹¹ combined with liposuction of the affected arm. We performed free lymphatic reconstruction using a flap containing the accompanying lymphatic tissue: lymph nodes, lymphatic vessels and fat from the groin area surrounding the superficial circumflex vessels. For some patients this was combined with breast reconstruction using a lower abdominal flap (DIEP or ms-TRAM flap). A two-team and three surgeon surgical approach was used. The lymphatic flap based on the superficial circumflex iliac vessels was raised as previously described^{11,18,19}. Simultaneously the axillary scar was removed and the recipient thoracodorsal vessels or its branches were prepared. Two or four microvascular anastomoses were performed depending on whether the lymph node transfer was combined with a DIEP or ms-TRAM breast reconstruction.

Liposuction of the affected arm was performed simultaneously with the dissection of the lymphatic flap (Figure 1). The amount of fat to be removed was determined by the excess volume of the affected arm compared to the healthy arm. Either dry liposuction (n=18) or wet technique liposuction (n=3) was used. A solution with 1 mg epinephrine in 1000 ml 0.9% NaCl was used in wet techniques. Dry liposuction was performed using a tourniquet with 250 mmHg pressure for a maximum of 60 minutes. In dry liposuction no wetting solution or epinephrine

was used and thus the amount of adipose tissue removed could be determined exactly. The arm was immediately compressed with a tight elastic bandage after liposuction.

Lymph node transfer (LN) without liposuction

Some of the results were compared with the results of 27 patients (age between 31 to 68 years, average age 50,2 years) who underwent only lymph node transfer (n=6) or lymph node transfer combined with breast reconstruction using the DIEP or ms-TRAM flap (n=21). These patients were mainly stage I lymphedema patients. The operation was performed similarly with the exclusion of liposuction.

Postoperative care

We used tissue an oxygen sensor (Licox®, GMS, Kiel-Mielkendorf, Germany) to monitor the perfusion of the flap for 3–4 days postoperatively. Suction drainages from the axillary and abdominal wounds were removed when the production was less than 40 mL/d, latest the 7th postoperative day. Compression was used in the lower abdominal wall and inguinal area for 4 weeks to prevent seroma formation. Manual lymphatic drainage was started two weeks after the operation and continued 2 times a week for 3 months after the surgery. For the first 6 months postoperatively, all patients used an elastic compression dressing on the treated arm.

Volumetry measurements

Measurements of both the normal and affected arms were taken preoperatively and at 6, 12, 18 and 24 months postoperatively. Limb circumference was measured every 4 cm between the wrist and the axilla. The edema volume was calculated using Brorson's truncated

cone model²⁰. Measurements with compression were done when patients used compression garments daily.

Measurements without compression were done in patients who discontinued the daily usage of compression or when patients had been requested to suspend the use of the compression seven days prior to the measurement. If volume reduction was maintained even without the compression therapy, the result was regarded as a resolution of the lymphedema. A volume change of less than 100 ml was considered normal variance and above 100 ml a true reduction/increase. This was based on the criteria for lymphedema diagnosis (200 ml or 10 % volume excess) and on Brorson's article on normal course of arm volume increase after liposuction when compression garment is removed²¹.

Postoperative and preoperative compression garment usage was scaled: 5 = 23-20 hours per day, 4 = sometimes without, 3 = 16-12 hours per day, 2 = under 12 hours per day, 1 = rarely using compression garment and 0 = no compression garment.

Lymphoscintigraphy

Upper limb lymphoscintigraphy was performed preoperatively and at 6, 12 and 24 months postoperatively as previously described¹⁸. For a semiquantitative evaluation of lymphatic drainage, a numerical transport index (Ti) was used as described previously^{22,23}.

Evaluation of wound exudate VEGF-C and VEGF-D concentrations

To compare the wound healing profiles of LN and LN+LIPO surgery, 10 ml of wound exudate was taken from the recipient axilla suction drainage on the 1st and 6th postoperative days (POD). Sample preparation, storage and VEGF-C and VEGF-D measurements were performed as previously described⁵.

Statistical analysis

Statistical analyses were performed using GraphPad Prism 7.0 (GraphPad Software, Inc., CA, USA). Growth factor concentrations on the 1st and 6th POD were compared independently between the groups using the unpaired two-tailed t-test. The group-wise differences between pre- minus postoperative Ti-values were compared using the unpaired two-tailed t-test. Group-wise differences between pre- minus postoperative compression garment usage and number of erysipelas infections were compared using a nonparametric Mann-Whitney U test. Statistical significance was set at $p \leq 0.05$.

Results

Patient characteristics

We analyzed the results of 21 upper limb lymphedema patients who underwent simultaneous microvascular lymph node transfer and liposuction (n=21) during the same operation. The mean age of the patients was 56.7 ± 7.7 years and the mean follow-up time 48.9 ± 15.4 months. The average body mass index was 28.1 ± 2.6 . Ten patients had at least one episode of erysipelas preoperatively and six patients were using prophylactic antibiotics preoperatively (Table 1).

Transport indexes, lymphedema volumes and cytokine concentrations were compared with the results of 27 patients undergoing only lymph node transfer without liposuction (LN, n=27). The mean age of these patients was 50.2 ± 8.7 years. The average body mass index was 30.1 ± 10.7 . Three patients had at least one episode of erysipelas preoperatively and two patients were using prophylactic antibiotics preoperatively, the other continued the usage also postoperatively. None of the patients in this study presented with donor limb lymphedema, which was verified normal TI values in lymphoscintigraphy.

Operation

In the LN+LIPO group with breast reconstruction the operation time was 522 ± 77 minutes and in the LN+LIPO group without breast reconstruction 356 ± 63 minutes. Operation time in the LN group with breast reconstruction was 484 ± 89 minutes and in the LN group without breast reconstruction 351 ± 83 minutes. The operation lasted on average only 37 minutes longer in the LN+LIPO with breast reconstruction and 4 minutes longer in the LN+LIPO without breast reconstruction compared to the corresponding operations without liposuction. Blood loss was 506 ± 277 mL in the LN+LIPO group with breast reconstruction and 202 ± 64 mL in the LN+LIPO group without breast reconstruction. On average 912 ± 326 ml fat was removed in the LN+LIPO group.

Clinical results of LN+LIPO

10/21 (47.6%) patients from the LN+LIPO group had suffered at least one episode of erysipelas preoperatively. Postoperatively 3/21 (14.3%) patients had one erysipelas infection during the follow-up. 4/6 patients continued antibiotic prophylaxis postoperatively. The pain was alleviated in 4/5 patients. There were no complications of the liposuction arm. 9/21 patients had minor complications (postoperative numbness, wound infection, limited skin necrosis, seroma) of the flap donor or recipient area and these are listed in detail in Table 1. One patient needed a re-operation due to a thrombosis of the arterial anastomosis on the 1st POD (wet liposuction technique). All complications were treated accordingly. The average hospital stay was 5.4 ± 0.5 days with the LN+LIPO patients without breast reconstruction and 6.6 ± 1.3 days with the LN+LIPO patients with reconstruction (Table 1).

3/27 (11.1%) patients from the LN group had suffered at least one episode of erysipelas preoperatively. In the LN group 2/27 (7.4%) patients had two or more erysipelas infections postoperatively during the follow up. 1/2 patients continued antibiotic prophylaxis postoperatively. The pain of the affected arm was relieved in 8/10 patients. When comparing the reduction in the number of erysipelas infections, the decrease in the number of erysipelas infections was greater in the LN-LIPO group compared to the LN group and the difference was statistically different ($p=0.02$) (Figure 2).

Limb volume measurements

We used upper limb volume measurements and lymphoscintigraphy to evaluate the lymphatic vessel function pre- and postoperatively. Volume differences were compared between the LN+LIPO and LN groups (Figure 3). The preoperative excess volumes with compression were 788.3 ± 260.3 mL in the LN+LIPO group and 410.6 ± 420.3 ml in the LN group. Preoperatively the volume excess increased in the LN+LIPO group (from 788.3 ± 260.3 mL to 978.2 ± 348.3 mL) when patients were measured after being seven days without compression.

The arm volume was immediately reduced postoperatively in all patients who underwent liposuction. The edema volume was 96.6 ± 154.3 mL after a follow-up time of 18.0 ± 9.8 months in the LN+LIPO group with compression (Figure 3A) and the reduction of the volume excess was 87.7%. Interestingly, in the LN+LIPO group the average arm volume did not increase even during a seven-day pause in the use of compression when the patients were measured postoperatively (78.0 ± 184.7 mL after a follow-up time of 20.0 ± 8.2 months) (Figure 3B). In detail, in 7/10 patients no increase/decrease was noted (criteria explained above, range of volume difference -192ml - +70ml) and in 3/10 patients an increase was noted (range +270 - +329ml). The average excess volume was decreased postoperatively also in the LN group (27.5%) (298.0 ± 297.4 mL after a follow-up of 9.9 ± 4.9 months) and the average volume did not increase after a seven-day pause of compression treatment (249.0 ± 166.0 mL after a follow-up time of 25.3 ± 4.4 months) (Figure 3A).

Preoperatively the average score of compression garment usage was 2.6 in the LN group and 4.2 in the LN+LIPO group. 17/21 LN+LIPO patients could reduce the usage of compression therapy after the operation. 7/17 of them used compression less than 12 hours per day. Postoperatively the average index of compression usage was 1.9 in the LN group and 2.7 in the LN+LIPO. The reduction was slightly greater in the LN+LIPO group but the result was not significant compared to LN group ($p=0,28$)(Figure 4)(Table 2).

Lymphoscintigraphic changes

The transport index was improved in 12/15 patients in the LN+LIPO group and 8/19 patients in the LN group (during a 12-24 months follow-up). The difference of pre- and 24 months postoperative Ti-values was significantly greater in the LN+LIPO group (25.4%) compared to the LN group (4.3%) ($p=0.01$) (LN+LIPO: pre-op 30.7 ± 10.6 , post-op at 24 months 22.9 ± 13.2 ; LN: pre-op 18.6 ± 15.4 , post-op at 24 months 17.8 ± 16.0) (Figure 5).

Wound fluid cytokine concentrations

On the 1st POD the VEGF-C concentrations were higher in patients without liposuction. On the 6th POD VEGF-C concentrations were decreased to a greater extent in the LN group (LN 278.4 ± 45.8 pg/mL, LN+LIPO 332.1 ± 51.8 pg/mL, $p=ns$). On the 6th POD the VEGF-D concentrations were higher in the liposuction group (LN+LIPO: 150.4 ± 42.6 pg/mL; LN 85.4 ± 38.4 pg/mL). However, the result did not reach statistical significance ($p=0.06$) (Figure 6).

Discussion

Lymph node transfer can easily be combined with routine microvascular breast reconstruction¹¹ and this method is now gaining popularity. However, for patients with stage II or III lymphedema presenting with non-pitting edema and soft tissue accumulation, lymph node transfer surgery cannot alone reduce the arm volume. Therefore, we combined liposuction and lymph node transfer in order to utilize the benefits of both operations for late stage lymphedema patients. Our results show that proximal lymph node transfer (and combined breast reconstruction) can easily and safely be combined with liposuction of the affected arm during the same operation with good results on the volume reduction and lymphatic flow. To our knowledge this is the first report showing that these operations can safely be performed simultaneously.

Both lymph node transfer and liposuction have been reported in earlier publications^{11,14,24}. Several case report studies (total 13 patients) have presented a combined

treatment modality in which liposuction and lymph node transfer have been performed for the same patients in different operations. Studies have shown reduction in excess limb volume/circumference, decrease in the need of compression garments and manual lymphatic drainage¹⁵⁻¹⁷. However, in these studies patients were measured only after 6 months¹⁶ and they were not measured after being without compression garments. Thus, it cannot be stated that the operation has resulted in true resolution of lymphedema.

In our results 12/15 patients of the LN+LIPO group showed improvement of the lymphatic flow function in postoperative lymphoscintigraphy. 81 % of the patients (17/21) were able to discontinue or reduce the use of compression garment at 6–24 months after the operation. The need or will of the patients to discontinue compression garment usage varies and some of the patients did not even want to try to reduce compression usage due to being used to wearing them. The arm volume was immediately reduced in all patients after the liposuction and patients were very satisfied also with the long-term results. In lymphedema patients who have undergone only liposuction, the arm volume increases remarkably (average 370 ml) when the compression garment was removed for 1 week 1 year postoperatively²¹. Our results showed, that in 7/10 patients the edema volume did not increase when compression garments were discontinued for 7 days as opposed to the preoperative situation. This can be considered to be a remarkable result as patients undergoing liposuction are already at a later stage of lymphedema. The results can be seen as a remission of the lymphedema development in these patients.

The transport index in lymphoscintigraphy improved in 12/15 LN+LIPO patients and in 8/19 LN patients. It has been previously shown that liposuction alone does not alter lymphoscintigraphy results²⁵. However, a recent correspondence reported improvement in swelling and lymphoscintigraphy results solely after liposuction in three lymphedema patients and the authors speculate multiple explanations for this including increased blood flow to the limb and decreased production of lymphatic fluid because of less subcutaneous tissue²⁶. In our study, the patients who had later stage lymphedema, more difficult symptoms and longer history of lymphedema were selected to the liposuction group and the patients with earlier stage of lymphedema were selected to the lymph node transfer group without liposuction. When comparing the results between the LN and LN+LIPO groups this should be taken into account. However, in our study the improvement of Ti-values was significantly greater in the LN+LIPO group compared to the LN group. It can be speculated that reconstruction of the lymphatic network is possible even in worse lymphedema cases and our results are supported by the

observations by Greene at al²⁶.

Most of the patients suffering from preoperative erysipelas infections (n=10) did not have upper limb infections (n=7) during the follow-up period. There are previous reports that the incidence of arm cellulitis has decreased after reduction of the edema volume of chronic lymphedema by liposuction²⁷ and lymph node transfer^{11,12,23}. Based on our results, the incidence of erysipelas infections decreased more in the LN-LIPO group, which supports the use of the combined technique in chronic lymphedema patients.

Most patients had dry liposuction (18/21). 3/21 of the patients underwent liposuction with wet technique. In wet technique liposuction was performed using 0.0001% epinephrine which may effect the blood circulation of the flap. One patient with wet liposuction had a thrombosis of the arterial anastomosis on the 1st POD which could be related to the wet technique. In dry liposuction no epinephrine was used and the amount of liposuctioned fat was known exactly. Results of liposuction for lymphedema patients have been published by Hoffner M. et al²⁸. In this study, dry technique liposuction was performed for 60 patients without surgical complications. In most of our patients the dry liposuction technique was used without liposuction related complications and it can be said to be a safe and reliable technique also combined to proximal lymph node transfer. It could be speculated, that with distal lymph node transfer it might be safer to employ a two-stage technique with the liposuction performed in one procedure and the LN transfer in a second operation, to minimize trauma to the distal flap area.

VEGF-C and VEGF-D are vascular endothelial growth factors and they have an active role in angiogenesis, lymphangiogenesis and endothelial cell growth. On day 1 postoperatively, there was secretion of VEGF-C in both groups. However it was clearly reduced on day 6. VEGF-D secretion was also reduced on day 6 but it stayed on a clearly higher level especially in the LN+LIPO group. This can be a result of the liposuction as it induces greater trauma and capillary damage than the LN operation alone. VEGF-D has both lymphangiogenic and angiogenic effects²⁹, which may be beneficial postoperatively.

No sufficient explanation can be given on the mechanism of improved lymphatic flow of LN+LIPO patients. Previously it has been shown that the skin blood flow increases after liposuction²⁷. It can be speculated that the effect is a combination of the increased VEGF-C secretion from the lymphatic flap^{5,11}, the increased skin blood flow, the possibly decreased

production of lymphatic fluid and also the increased late VEGF-D and VEGF-C secretion in the liposuction group.

The limitations of this study are the retrospective nature of the data gathering and the small number of patients. A randomized controlled trial for stage II lymphedema patients comparing lymph node transfer, liposuction with CCT (controlled compression therapy) and the combination of these two techniques in the future would be feasible to compare these techniques in the same patient material.

Our results show for the first time that liposuction can be safely performed simultaneously with lymph node transfer. With a two-team approach, the operation time was only slightly longer when LN transfer was combined with liposuction. When combining liposuction to lymph node transfer, we can reduce the number of operations per patient and patients need less postoperative days in the hospital. Most importantly, our results show that with this combined technique, remission of the lymphedema is possible to achieve and life-long compression therapy is no longer a necessity for all chronic lymphedema patients. The significantly greater reduction in TI-values and erysipelas infections in the LN+LIPO groups suggests that the combined technique might be better for late stage lymphedema patients than LN transfer alone. The results are promising and provide new hope for late stage lymphedema patients.

Acknowledgements

The authors thank the Department of Clinical Physiology and Nuclear Medicine for co-operation and all nurses, physiotherapists and secretaries at the Department of Plastic and General Surgery in the Turku University Hospital Plastic Surgery unit for their assistance. The authors have received financial support for the study from The Finnish Medical Foundation, the Special Governmental Funding (EVO) allocated to Turku University Hospital and the Varsinais-Suomi Regional Fund of the Finnish Cultural Foundation.

Conflict of interest

Herantis Pharma: Research scientist involved in clinical trial (TV, ES, AS, PH)

References

1. DiSipio T, Rye S, Newman B, et al. Incidence of unilateral arm lymphoedema after breast cancer: A systematic review and meta-analysis. *Lancet Oncol.* 2013;14:500-515.
2. Clark B, Sitzia J, Harlow W. Incidence and risk of arm oedema following treatment for breast cancer: a three-year follow-up study. *QJM.* 2005;98:343-348.
3. Suami H, Chang DW. Overview of surgical treatments for breast cancer-related lymphedema. *Plast Reconstr Surg.* 2010;126:1853-1863.
4. McLaughlin SA, Wright MJ, Morris KT, et al. Prevalence of lymphedema in women with breast cancer 5 years after sentinel lymph node biopsy or axillary dissection: objective measurements. *J Clin Oncol.* 2008;26:5213-5219.
5. Viitanen TP, Visuri MT, Sulo E, et al. Anti-inflammatory effects of flap and lymph node transfer. *J Surg Res.* 2015;199:718-725.
6. Becker C. Autologous lymph node transfers. *J Reconstr Microsurg.* 2016;32:28-33.
7. Silva AK, Chang DW. Vascularized lymph node transfer and lymphovenous bypass: Novel treatment strategies for symptomatic lymphedema. *J Surg Oncol.* 2016;113:932-939.
8. Allen RJ Jr, Cheng MH. Lymphedema surgery: Patient selection and an overview of surgical techniques. *J Surg Oncol.* 2016;113:923-931.
9. Hartiala P, Saaristo AM. Growth factor therapy and autologous lymph node transfer in lymphedema. *Trends Cardiovasc. Med.* 2010;20:249-253.
10. Raju A, Chang DW. Vascularized Lymph Node Transfer for Treatment of Lymphedema A Comprehensive Literature Review. *Ann Surg.* 2015;261:1013-1023.
11. Saaristo AM, Niemi TS, Viitanen TP, et al. Microvascular breast reconstruction and lymph node transfer for postmastectomy lymphedema patients. *Ann Surg.* 2012;255:468-473.

12. Ozturk CN, Ozturk C, Glasgow M, et al. Free vascularized lymph node transfer for treatment of lymphedema: A systematic evidence based review. *J Plast Reconstr Aesthet Surg.* 2016;69:1234-1247.
13. O'Brien BM, Khazanchi RK, Kumar PA, et al. Liposuction in the treatment of lymphoedema: a preliminary report. *Br J Plast Surg.* 1989;42:530–533.
14. Brorson H, Ohlin K, Svenssen B. The facts about liposuction as a treatment for lymphoedema. *J Lymphoedema.* 2008;3:38-47.
15. Granzow JW, Soderberg JM, Dauphine C. A novel two-stage surgical approach to treat chronic lymphedema. *Breast J.* 2014;20:420-422.
16. Nicoli F, Constantinides J, Ciudad P, et al. Free lymph node flap transfer and laser-assisted liposuction: a combined technique for the treatment of moderate upper limb lymphedema. *Lasers Med Sci.* 2015;30:1377-1385.
17. Cook KH, Park MC, Lee IJ, et al. Vascularized Free Lymph Node Flap Transfer in Advanced Lymphedema Patient after Axillary Lymph Node Dissection. *J Breast Cancer.* 2016;19:92-95.
18. Viitanen T, Visuri M, Hartiala P, et al. Lymphatic vessel function and lymphatic growth factor secretion after microvascular lymph node transfer in lymphedema patients. *Plast Reconstr Surg Glob Open.* 2013;1:1-9.
19. Sulo E, Hartiala P, Viitanen T, et al. Risk of donor-site lymphatic vessel dysfunction after microvascular lymph node transfer. *J Plast Reconstr Aesthet Surg.* 2015;68:551-558.
20. Brorson H, Höijer P. Standardised measurements used to order compression garments can be used to calculate arm volumes to evaluate lymphoedema treatment. *J Plast Surg Hand Surg.* 2012;46:410-415.
21. Brorson H, Svensson H. Liposuction combined with controlled compression therapy reduces arm lymphedema more effectively than controlled compression therapy alone. *Plast Reconstr Surg.* 1998;102:1058-1067.

22. Weiss M, Baumeister RG, Hahn K. Post-therapeutic lymphedema: scintigraphy before and after autologous lymph vessel transplantation: 8 years of long-term follow-up. *Clin Nucl Med.* 2002;27:788–792.
23. Kleinhans E, Baumeister RG, Hahn D, et al. Evaluation of transport kinetics in lymphoscintigraphy: follow-up study in patients with transplanted lymphatic vessels. *Eur J Nucl Med.* 1985;10:349-352.
24. Becker C, Assouad J, Riquet M, et al. Postmastectomy lymphedema: long-term results following microsurgical lymph node transplantation. *Ann Surg.* 2006;243:313-315.
25. Brorson H, Svensson H, Norrgren K, et al. Liposuction reduces arm lymphedema without significantly altering the already impaired lymph transport. *Lymphology.* 1998;31:156-172.
26. Greene AK, Voss SD, Maclellan RA. Liposuction for Swelling in Patients with Lymphedema. *N Engl J Med.* 2017;377:1788-1789.
27. Brorson H, Svensson H. Skin blood flow of the lymphedematous arm before and after liposuction. *Lymphology.* 1997;30:165-172.
28. Hoffner M, Bagheri S, Hansson E, et al. SF-36 Shows Increased Quality of Life Following Complete Reduction of Postmastectomy Lymphedema with Liposuction. *Lymphat Res Biol.* 2017;15:87-98.
29. Rissanen TT, Markkanen JE, Gruchala M, et al. VEGF-D is the strongest angiogenic and lymphangiogenic effector among VEGFs delivered into skeletal muscle via adenoviruses. *Circ Res.* 2003;92:1098-1106.

Figure legends

Figure 1A. Operation technique. A LN flap or LN flap with breast reconstruction is raised from the lower abdomen and simultaneously the axillary scar is released and the recipient vessels prepared. Liposuction is performed and the arm compressed with a tight elastic bandage. The flap is placed in the axilla and microvascular anastomosis are performed. B. Preoperatively, one day before operation. Right hand affected. C, D. Postoperative images 45 months after the operation. Right hand circumference at shown point 28 cm and left hand 29.5 cm. The patient uses compression garments only occasionally and is mostly without. Patient's ID=19.

Figure 2. Total number of erysipelas infections per patient before and after the operation in LN-LIPO and LN groups. Amounts per individual patient and mean \pm sd per group are shown. $p < 0.05$ difference of pre-postoperative infections LN-LIPO vs LN.

Figure 3A. Measurements of upper limb edema volumes preoperatively and postoperatively, latest measurements were used. The average measurement time of LN+LIPO patients was 18.0 ± 9.8 months postoperatively with compression and 20.0 ± 8.2 months postoperatively without compression and LN patients average was 9.9 ± 4.9 months postoperatively with compression and 25.3 ± 4.4 months without compression. B. Measurements of upper limbs edema volumes preoperatively and postoperatively. The latest measurements were used in postoperatively values: average was 18.0 ± 9.8 months postoperative with compression and 20.0 ± 8.2 months postoperatively without compression. Data shown as mean \pm sd.

Figure 4. Use of compression garments in LN+LIPO and LN patients scaled from 0-5. 5 = 23-20 hours per day, 4 = sometimes without, 3 = 16-12 hours per day, 2 = under 12 hours per day, 1 = rarely using compression garment and 0 = no compression garment. The average timepoint in LN+LIPO group is 16.3 ± 7.3 months and in LN group 13.9 ± 8.8 months. Data shown as medians and interquartile ranges.

Figure 5A. Transport index of LN+LIPO patients measured preoperatively, 6 months postoperatively and 24 months postoperatively. B. Transport index of LN patients measured preoperatively, 6 months postoperatively and 24 months postoperatively. The improvement of Ti-values was significantly greater in the LN+LIPO group compared to the LN group. Oper = operated arm, Non-oper = non-operated control arm. Data shown as mean \pm sd.

Figure 6A. VEGF-C concentrations of LN+LIPO patients and LN patients assessed on the first and on the sixth postoperative days. B. VEGF-D concentrations of LN+LIPO patients and LN patients assessed on the first and on the sixth postoperative days. Data shown as mean±sd.

Table 1. Summary about the LN+LIPO patients characteristics and details of the operations. CD=daily compression therapy discontinued; CR=compression therapy reduced; E=no erysipelas infections; P=pain relieve

Table 2. The usage of compression garment pre- and postoperatively per every LN and LN+LIPO patient and timepoint when the patient could reduce the usage to the sustained level. Scaled from 0-5. 5 = 23-20 hours per day, 4 = sometimes without, 3 = 16-12 hours per day, 2 = under 12 hours per day, 1 = rarely using compression garment and 0 = no compression garment.

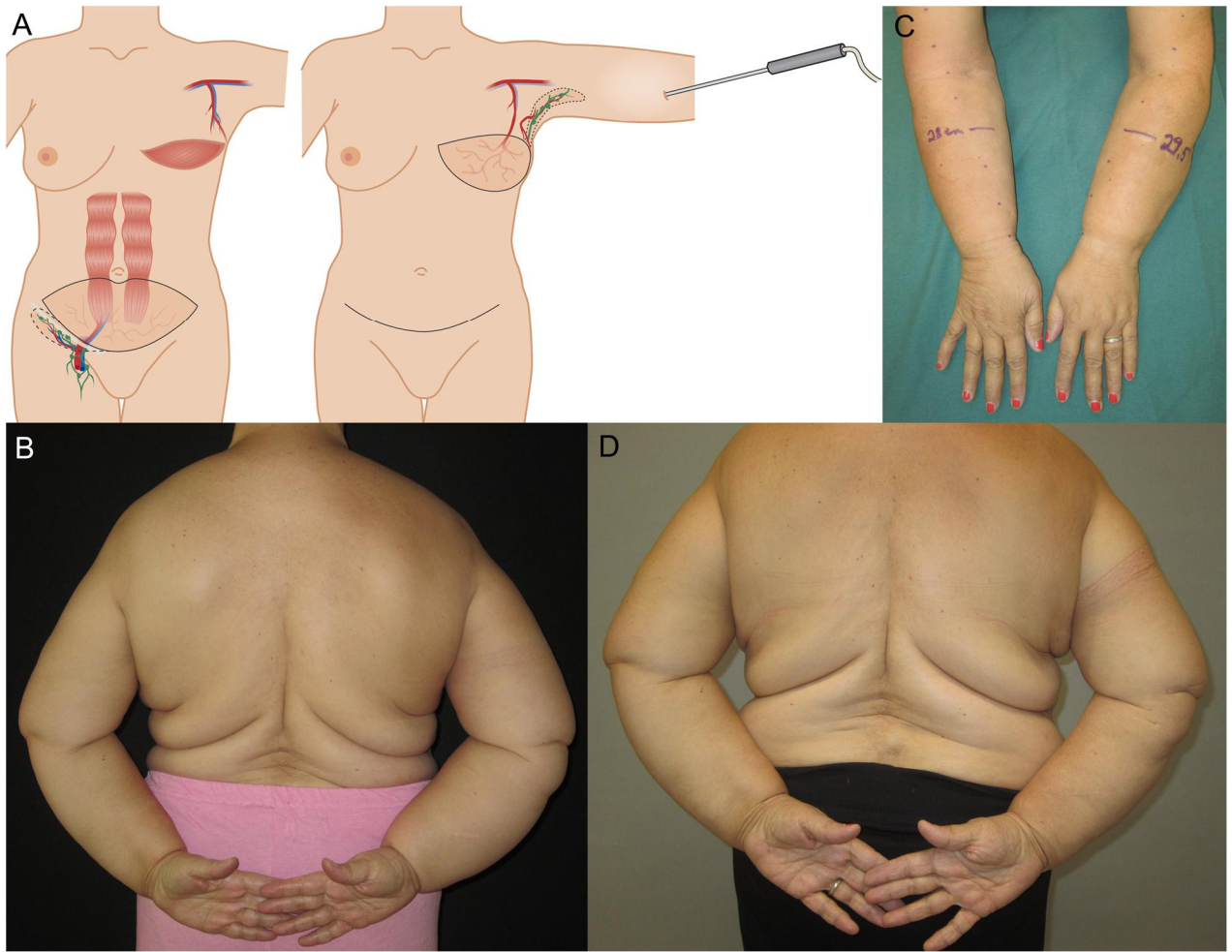


Figure 1.

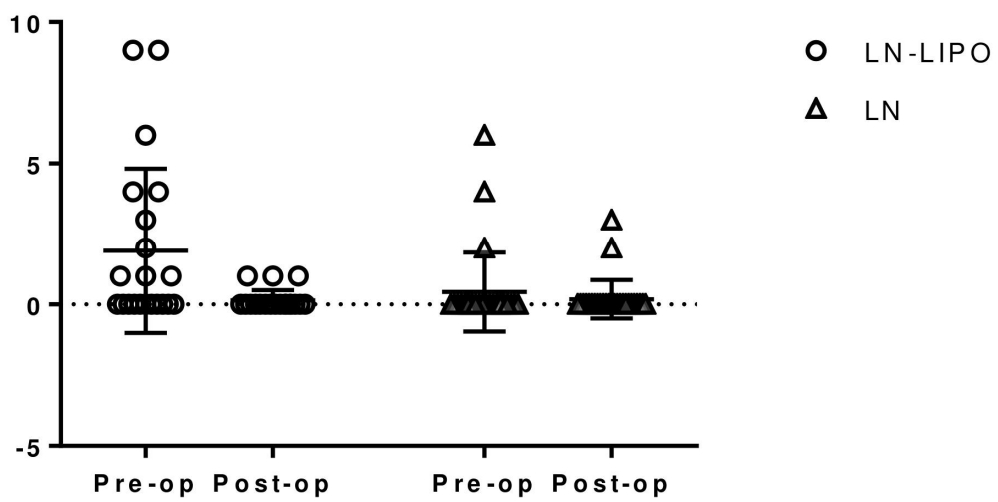
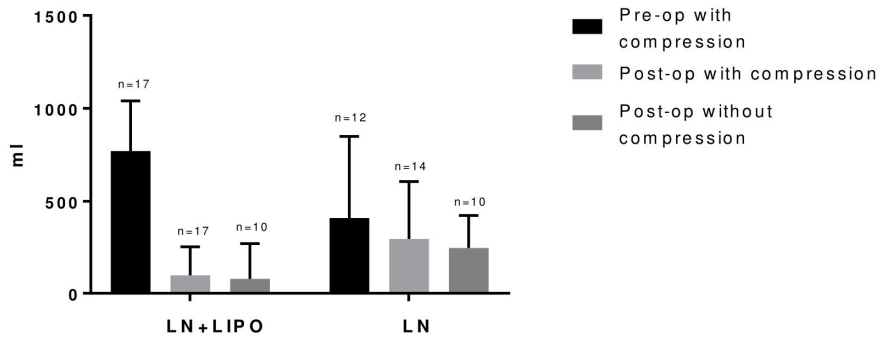
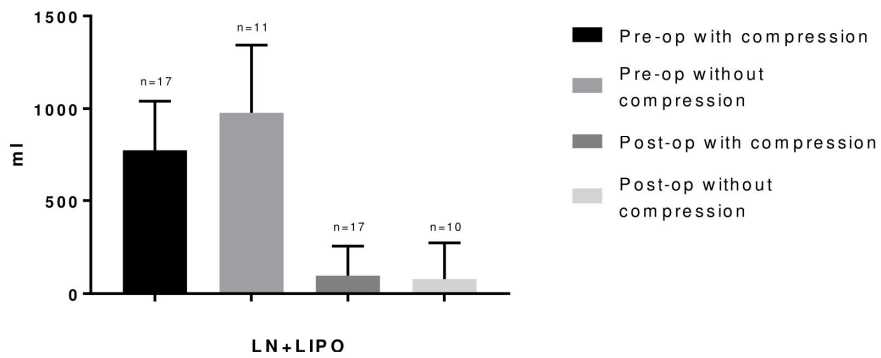


Figure 2.



3A



3B

Figure 3.

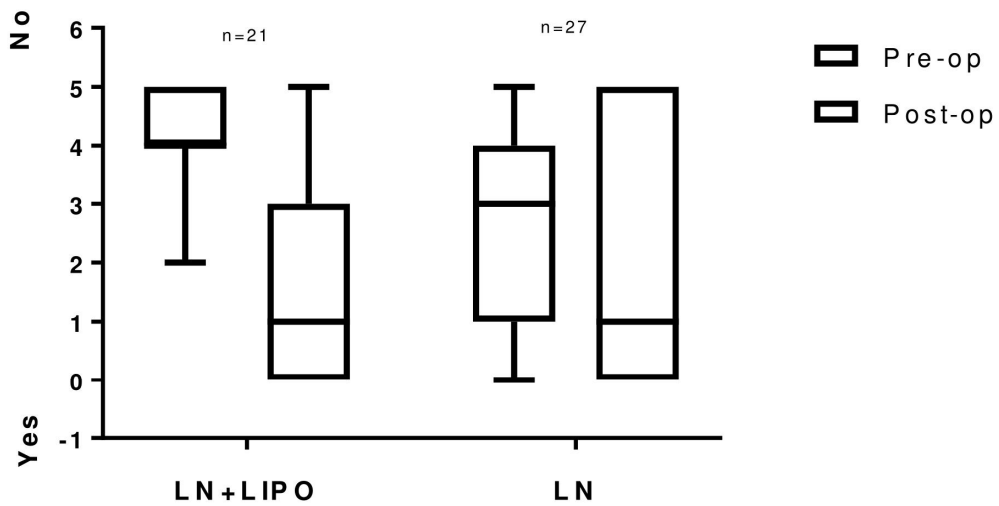


Figure 4.

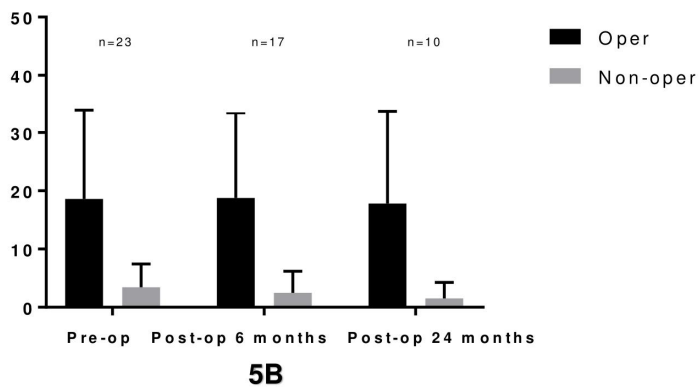
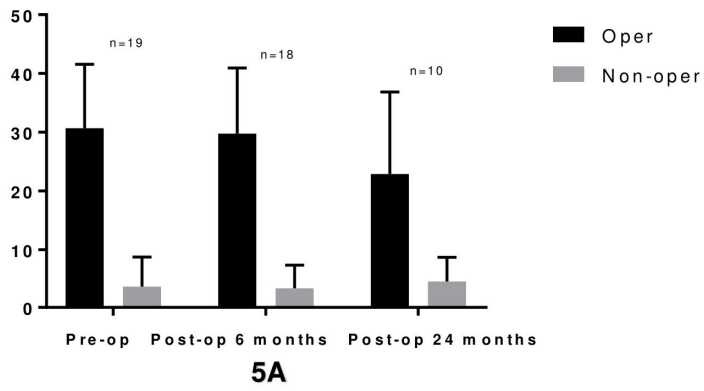


Figure 5.

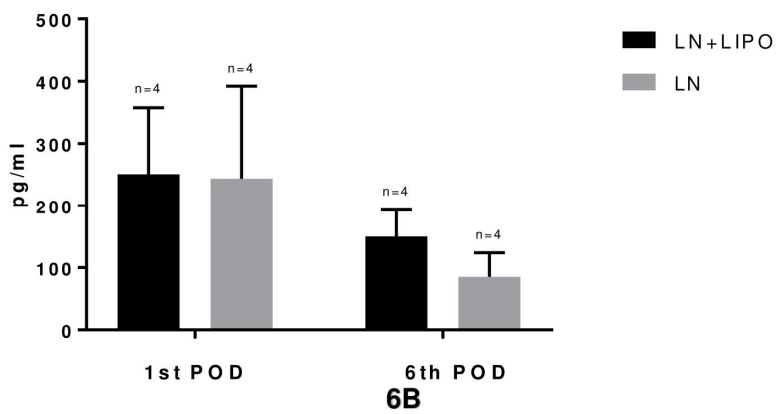
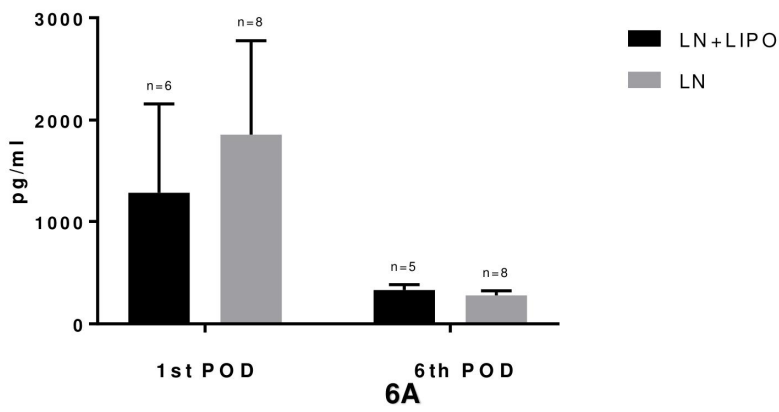


Figure 6.

**Summary of
LN+LIPO
patients**

Patient	Breast reconstruction	Duration of symptoms (mo)	Age at operation	Transport index			Excess of edema			Additional effect of treatment	Follow-up (mo)
				Pre-op	Post-op	Timepoint	Pre-op (ml)	Post-op (ml) with compression	Post-op (ml) without compression		
1	No	12	37	41	39	24				P, E	71
2	No	17	74	19,2	8,6	18			-192	E, CD	71
3	No	36	53	6,6				225		P, E, CD	67
4	No	60	55	20,8	9,6	30	763	104	121	E, CD	61
5	No	65	55	14,8	14,8	12	578	46	64	E, CR	47
6	No	68	67	34	31	24	467	-33		E, CR	44
7	No	23	59		26,2	12	1167	89	418	E	42
8	No	120	55		45	14	956	32		E, CR	41
9	No	156	64	20,2			868	48	176	E, CR	39
10	No	185	62	41	20,8	24	312	-145	-221	E, CD	29
11	No	38	58	34,8	22,8	12	589	13		E, CR	26
12	Yes	28	55	39	36	24				CR	90
13	Yes	50	61	22,8	16,6	30		126	126	CD	67
14	Yes	43	52	37	24,8	12	773	261		P, E, CR	54
15	Yes	28	51	35	45	24	597	-4	268	E	50
16	Yes	28	47	35	17,2	27	822	336		E, CR	49
17	Yes	15	52	45			1224			E, CR	42
18	Yes	28	68	22,8	5,6	30	840	-15	55	E, CD	39
19	Yes	30	59	33	8,2	24	742	-71	-35	E, CD	39
20	Yes	14	54	36	36	18	640	135		P, E	32
21	Yes	41	52	45			1275	496			27

Duration of the operation (min)	Blood loss (ml)	Liposuction (ml)	Days spent in hospital	Complications	Drain (day)
486	150	900	6	postoperative numbness	5
415		1500	6	no	6
360	200	550	6	postoperative numbness, seroma	6
367	200	750	5	wound infection	5
349	300	600	5	seroma	6
307	200	500	6	no	5
401	200	1400	5	no	3
308	300	900	5	no	5
363	150	850	5	no	4
291	220	600	5	no	2
265	100	650	5	no	3
		1500	5	wound infection	2
		700	6	no	6
545	500	900	6	limited skin necrosis, liponecrosis	6
415	500	600	6	no	6
435	300	700	6	no	6
516	400	1400	6	umbilical hernia	6
673	500	950	9	postoperative numbness, seroma	9
546	400	1050	9	no	12
477	250	750	5	wound infection, limited skin necrosis	5
566	1200	1400	6	no	5

Table1.
Summary of the LN+LIPO patients

The summary of compression garment usage of the LN and LN+LIPO patients							
LN+LIPO				LN			
ID	Preop	Postop	Timepoint	ID	Preop	Postop	Timepoint
1	5	5		1	4	1	12
2	4	1	12	2	2	0	36
3		1	11	3	0	0	18
4	2	1	7	4	0	5	
5	5	3	20	5	3	2	6
6	4	4		6	0	0	12
7	5	3	26	7	0	0	6
8	3	3		8	0	0	6
9	5	3	24	9	0	0	6
10	4	0	12	10	3	0	24

11	3	3		11	1	0	24
12	4	3	30	12	2	0	24
13	4	1	7	13	5	5	
14	5	3	24	14	3	0	12
15	5	5		15	3	5	
16	4	3	12	16	4	0	12
17	4			17	5	5	
18	4	1	15	18	3	0	4
19	5	0	12	19	3	2	
20	5	5		20	4	5	
21	5	5		21	5	5	
				22	3	5	
				23	2	1	12
				24	4	0	6
				25	3	5	
				26	3	2	6
				27	5	1	24

Table2.

The summary of compression garment usage of the LN and LN+LIPO patients