
HISTOLOGICAL TECHNIQUES FOR MARINE BIVALVE MOLLUSKS AND CRUSTACEANS



NOAA Technical Memorandum NOS NCCOS 5

Mention of trade names or commercial products does not constitute endorsement or recommendation for their use by the United States government.

This manual is dedicated to Dr. Aaron Rosenfield and Frederick G. Kern for their support in making the manual possible; and to NOAA staff researchers, past and present.

Cover photograph of skipjack *Martha Lewis* is courtesy of Chesapeake Heritage Conservancy, Havre de Grace, MD.

Citation for this Report

Howard, D. W., E. J. Lewis, B. J. Keller, and C. S. Smith. 2004.
Histological techniques for marine bivalve mollusks and crustaceans.
NOAA Technical Memorandum NOS NCCOS 5, 218 pp.

HISTOLOGICAL TECHNIQUES FOR MARINE BIVALVE MOLLUSKS AND CRUSTACEANS

Dorothy W. Howard, Earl J. Lewis, B. Jane Keller, and Cecelia S. Smith

NOAA, National Ocean Service
National Centers for Coastal Ocean Science
Center for Coastal Environmental Health and Biomolecular Research
Cooperative Oxford Laboratory
904 South Morris Street
Oxford, MD 21654-1323

2d Edition

NOAA Technical Memorandum NOS NCCOS 5

August 2004



United States Department of
Commerce

National Oceanic and
Atmospheric Administration

National Ocean Service

Donald L. Evans
Secretary

Conrad C. Lautenbacher, Jr.
Administrator

Richard W. Spinrad
Assistant Administrator

TABLE OF CONTENTS

TABLE OF CONTENTS	iii
LIST OF TABLES	vii
LIST OF PHOTOMICROGRAPHS AND ILLUSTRATIONS	viii
LIST OF APPENDICES	ix
Foreword	x
Acknowledgments	xi
Introduction	xii
Chapter 1. Safety	
A. Introduction	1
B. General Safety	1
C. Chemical Safety and Environmental Compliance	2
D. Health Hazards and Chemical Terminology	3
E. Safety and Environmental Compliance Websites	5
F. Footnotes	5
G. References	5
H. Recommended Reading	5
Chapter 2. Handling of Live Animals: Mollusks and Crustaceans	
A. Introduction	7
B. Specimen Collection	7
1. Oysters	7
2. Softshell Clams	7
3. Crabs	7
C. Shipping Instructions	8
D. Care, Handling, and Maintaining Live Shellfish	8
1. Oysters	8
2. Softshell Clams	9
3. Crabs	9
E. Footnotes	9
F. References	9
Chapter 3. Necropsy and Examination of Shellfish Specimens	
A. Introduction	11
1. Processing Procedures	11
2. Figures and Explanations	12
B. Processing of Specimens	16
1. Oysters (<i>Crassostrea</i> and <i>Ostrea</i> spp.)	16
2. Clams (<i>Spisula</i> , <i>Mya</i> , <i>Macoma</i> , <i>Mercenaria</i> , <i>Arctica</i> spp.)	17
3. Mussels (<i>Mytilus</i> spp.)	19
4. Scallops (<i>Argopecten</i> and <i>Placopecten</i> spp.)	19
5. Shellfish Larvae	19
6. Blue Crabs (<i>Callinectes sapidus</i>)	20
C. Footnotes	20
D. References	20
Photomicrographs and Illustrations	22
Chapter 4. Cryosection Technique	
A. Introduction	57

B. Description of Technique	57
C. Footnote	58
D. References	58
Chapter 5. Fixation	
A. Introduction	59
B. Formulas for Fixatives and Methods	59
C. Special Note on Seawater	66
D. Notes on Fixation	66
E. Problems and Resolutions	66
F. Footnotes	68
G. References	68
Chapter 6. Embedding	
A. Introduction	69
B. General Procedures	69
C. Infiltration Schedules	70
D. Problems and Resolutions	70
E. References	70
Photomicrographs	73
Chapter 7. Sectioning	
A. Introduction	75
B. General Procedures	75
C. Adhesives	75
1. Poly-L-Lysine (PLL)	75
2. Mayer's Albumin	76
3. Haupt Gelatin	76
4. Aminoalkylsilane	76
D. Preparation of Paraffin Tissue Sections	77
1. Blocks	77
2. Microtome	77
3. Knives	77
4. Sectioning	78
E. Problems and Resolutions	79
F. Footnotes	79
G. References	79
Photomicrographs	83
Chapter 8. Staining	
A. Introduction	85
B. Methods and Use	85
1. Standard Format for Paraffin-embedded Sections	89
2. Pre-staining Techniques	90
3. Deactivation of Ammoniacal Silver Solutions	91
4. Staining Methods	92
C. Problems and Resolutions	125
D. Footnotes	125
E. References	125
Photomicrographs	129

Chapter 9. Coverslipping

A. Introduction	137
B. Tools and Techniques	137
C. Problems and Resolutions	137
D. Mounting Media	137
1. Resins	137
2. Aqueous Media	138
E. Footnotes	138
F. References	138
Photomicrographs	141

Chapter 10. Histocytology: A Diagnostic Method for Examining Invertebrate Hemolymph - C. Austin Farley

A. Introduction	143
B. Preparation of Materials	143
1. Suspension Chambers	143
2. Preparation of Reagents	144
3. Artificial Seawater	144
C. Hematological Procedures	144
D. Sampling Procedures	144
E. Detection of Systemic Parasites and Pathogens by Histocytology	145
1. Oysters	145
2. Clams	145
3. Mussels	145
F. <i>Perkinsus marinus</i> Detection by Hemanalysis	146
1. Oysters	146
G. Footnotes	146
H. References	146
Photomicrographs	148

Chapter 11. Diagnostic Techniques for Blue Crabs - Gretchen A. Messick

A. Introduction	151
1. Macroscopic Manifestations	151
2. Cytological Techniques	151
3. In vivo Microscope Technique (modified Field technique-MFT)	153
B. Discussion	153
C. References	154
Photomicrographs	157

Chapter 12. Miscellaneous Techniques and Methods for Mollusks - Earl J. Lewis

A. Introduction	159
B. Juvenile Oyster Disease (JOD)	159
C. <i>Cryptosporidium</i> and <i>Giardia</i> in Shellfish	159
1. Techniques for Processing and Evaluating Oyster Gill Washes, Blood, and Water for <i>Cryptosporidium</i> and <i>Giardia</i>	161
D. Footnotes	164
E. References	164
Photomicrographs	166

Chapter 13. Diagnostic Techniques for the Softshell Clam *Mya arenaria* Linnaeus, 1758 - Shawn M. McLaughlin

A. Introduction	169
B. Health Assessment	169
1. Gross Examination	169
2. Hemolymph Examination	171
C. Tissue Incubation and Special Media	172
1. Formation of Hypnospores in Ray's Fluid Thioglycolate Medium (RFTM)	172
2. In Vitro Propagation	173
D. Bacteriology	173
E. Histology	174
F. Electron Microscopy (EM)	174
G. Footnotes	174
H. References	174
Photomicrographs	177

Chapter 14. Special Techniques

A. Introduction	179
B. Detection of <i>Perkinsus</i> spp.	179
C. Ciliate Culture Preparation from Oysters	180
D. Electron Microscopy	180
1. Preparation of Fresh Tissues for Transmission Electron Microscopy (TEM)	180
2. Preparation of Hemolymph or Cell Suspensions for TEM	182
3. Preparation of Paraffin-embedded Tissues for TEM	183
4. Transfer of Tissues from Histological Slides for TEM	183
5. Scanning Electron Microscopy (SEM) Procedure	183
E. Decalcification	184
F. Transfer of Paraffin-embedded Tissues	184
1. Transfer from Broken Slides or Serial Sections	184
2. Transfer from Paraffin to Plastic	185
G. Agar-enrobing for Embedment and Sectioning	185
H. Footnotes	186
I. References	186
Photomicrographs	187

General References and Recommended Reading	201
---	------------

Index	211
--------------------	------------

LIST OF TABLES

Table 5-1.	Fixatives and applications	59
Table 5-2.	Fixative formulas and methods	60
Table 5-3.	Fixative problems and resolutions	67
Table 6-1.	Infiltration schedules for specific types of tissue.....	71
Table 6-2.	Embedment problems and resolutions	72
Table 7-1.	Sectioning problems and resolutions	80
Table 8-1.	Synoptic listing of stains	85
Table 8-2.	Synoptic listing of stains for diagnostic elements.....	87
Table 8-3.	McIlvaine-Lillie buffer stock solutions	96
Table 8-4.	Staining problems and resolutions	127
Table 9-1.	Coverslipping problems and resolutions	139
Table 10-1.	Artificial seawater dilution table	144
Table 10-2.	Histocytology staging criteria for <i>Haplosporidium nelsoni</i> and <i>Perkinsus marinus</i>	147
Table 10-3.	Staging criteria for <i>Perkinsus marinus</i> by hemanalysis using tissue culture plates	147
Table 11-1.	Manifestations of some disease agents of the blue crab	152
Table 12-1.	Criteria for evaluation of JOD	160
Table 12-2.	Criteria for stained <i>Cryptosporidium</i> and <i>Giardia</i> spp.....	161
Table 13-1.	Examples of parasites, diseases, and disorders of softshell clams.	170
Table 13-2.	Stages of softshell clam sarcomas.....	172

LIST OF PHOTOMICROGRAPHS AND ILLUSTRATIONS

Figures 3-1 to 3-18. Shell abnormalities	22-27
Figures 3-19 to 3-24. Fouling organisms	28-29
Figures 3-25 to 3-27. Obvious parasites	30
Figures 3-28 to 3-39. Physiological indicators	31-34
Figures 3-40 to 3-42. Other gross abnormalities	35
Figures 3-43 to 3-48. Predators	36-37
Figures 3-49 to 3-56. Processing of oyster <i>Crassostrea virginica</i>	38-40
Figures 3-57 to 3-70. Processing of soft clam <i>Mya arenaria</i>	41-44
Figures 3-71 to 3-76. Processing of Baltic clam <i>Macoma balthica</i>	45
Figures 3-77 to 3-84. Processing of hard clam <i>Mercenaria mercenaria</i>	46-48
Figures 3-85 to 3-92. Processing of blue mussel <i>Mytilus edulis</i>	49-51
Figures 3-93 to 3-100. Processing of scallop <i>Argopecten irradians</i>	52-54
Figures 3-101 to 3-105. Processing of blue crab <i>Callinectes sapidus</i>	55-56
Figure 4-1. Frozen tissue technique	58
Figures 6-1 to 6-6. Embedding	73
Figures 7-1 to 7-6. Sectioning	83
Figure 7-7. Action used in hand honing knife blades	84
Figures 8-1 to 8-24. Stains	129-136
Figures 9-1 to 9-6. Coverslipping	141
Figures 10-1 to 10-6. Examination of oyster hemolymph	148
Figures 10-7 to 10-12. Detection of <i>Perkinsus marinus</i> (Dermo) by hemanalysis	149
Figures 11-1 to 11-6. Diagnostic techniques for blue crabs	157
Figures 12-1 to 12-4. Juvenile oyster disease (JOD)	166
Figures 12-5 to 12-16. Diagnosis of <i>Cryptosporidium</i> and <i>Giardia</i> from oysters and water	167-168
Figures 13-1 to 13-6. Diagnosis of sarcoma and rickettsia-like organisms in the softshell clam <i>Mya arenaria</i>	177
Figures 13-7 to 13-12. Diagnosis of <i>Perkinsus</i> spp. in the softshell clam <i>M. arenaria</i>	178
Figures 14-1 to 14-6. Detection of <i>Perkinsus marinus</i> (Dermo) in rectal tissue	187
Figures 14-7 to 14-12. Transfer of paraffin-embedded tissue, serial sections, or broken slides onto new slide	188

LIST OF APPENDICES

U.S./Metric Conversions	189
Laboratory Calculations	190
Recordkeeping	192
Field Data Form on Shellfish Samples	193
Gross Macroscopic Exam Form	194
Dermo Report Form	195
Molluscan Pathology Report Form	196
List of Scientific and Common Names	197
List of Acronyms	198
List of Abbreviations and Definitions	199
U.S. State Abbreviations	200

FOREWORD

During the mid-1950s, massive and widespread oyster mortalities, particularly in the Delaware and Chesapeake Bay areas, served as a stimulus to establish a federal oyster mortality study program. Consequently, Congress appropriated funds to the then Bureau of Commercial Fisheries (BCF) within the U.S. Department of the Interior. These appropriations enabled federal, state, and academic institutions and laboratories to conduct research and management programs. These programs, either by contract, interagency agreement, or direct grant, were designed to recognize and understand symptoms of disease, disease processes, their cause(s), and, furthermore, to assist in the development of strategies to prevent or control shellfish mortalities and the spread of disease agents. At that time, the Annapolis Laboratory of the BCF, under the leadership of James B. Engle, was housed in an apartment building in Annapolis, MD, and the disease study was staffed by one biologist, Richard Burton, and two temporary summer technicians. I was one of those technicians, and started my career with strictly on-the-job training in histological and, later, pathological methods. In 1960, the laboratory was moved to Oxford, MD, where a larger disease research and ecology program was initiated.

Little was known at that time about oyster diseases, or even how to go about studying them. Standard vertebrate methods were used in the beginning, but it soon became obvious that many techniques needed modification and refinement. Because of the unique nature of invertebrate tissues and their parasites, protocols were developed by Dr. Melbourne R. Carriker for the study of oyster diseases in individual specimens and in populations.

Since that time, well over one million sections of oysters and other mollusks, crustaceans, and fishes have been processed. In this second edition of the manual, new and revised histological protocols, methodologies, and techniques developed through the cooperative efforts of several laboratory staff and from information published in the scientific literature have been included to provide a more comprehensive publication. Handwritten laboratory notes, diaries, and methods collected over the past several decades have been incorporated into this manual by the authors. The result is a working manual designed and written primarily for technicians, using very practical approaches and language which are comprehensible for someone just beginning, yet detailed and accurate enough to produce professional results in the hands of the experienced scientists should they elect to do the work themselves.

I am proud to have been able to work with the authors. Over the past years, their efforts and those of the staff of molluscan, crustacean, and fish pathologists resulted in the development of this manual. I feel that the authors' diligent efforts, both in the production of excellent histologic material and of this manual, will continue to substantially enhance the field of invertebrate pathology worldwide.

C. Austin Farley

ACKNOWLEDGMENTS

It is with a great deal of satisfaction that we recognize the following NOAA and Maryland Department of Natural Resources (MDNR) staffs that comprise the Cooperative Oxford Laboratory (COL) for their tireless assistance with this second edition of the manual. To Fred Kern for making the second edition possible; to Sally Otto for years of guidance and support; to Susie Hines for literature searches; to Dr. Shawn McLaughlin, Gretchen Messick, and Austin Farley for their contributions in making this edition a more diverse manual; to George Ward for years of helping with special projects; to Karen Hayman for many hours of typing; to Nadine Wheatley (deceased) for researching the publishing information involved in this project; to Sue Tyler and Lee Hamilton for collaborative efforts; to Emily Ort for her support; and to Drs. Aaron Rosenfield, Carl Sindermann, Kilho Park, Bud Cross, Geoff Scott, and Bob Wood for their help and advice.

We are honored once again to have had the talent of Alice J. Lippson, Bozman, MD, who created the excellent anatomical illustrations.

Special thanks to our colleagues Dr. Eugene Small and Tim Mangel, University of Maryland, College Park, and Phil Rutledge, University of Maryland Baltimore County, for their contributions in electron microscopy and special techniques used for ciliates; Drs. Ron Fayer and James Trout, U.S. Department of Agriculture, Beltsville, MD, and Dr. Thaddeus Graczyk, Johns Hopkins University, Baltimore, MD for collaborative research on *Cryptosporidium* and *Giardia*.

We gratefully acknowledge the reviews of in-house ASCP (American Society of Clinical Pathology) histotechnicians Robert Bingaman, Sue Tyler, Kathy Price, and Donna Real; librarian Susie Hines; scientists Gretchen Messick, Dr. Shawn McLaughlin, and Dr. Melba Reantaso; and the following external reviewers: Yvonne Bobo, South Carolina Department of Natural Resources, Charleston; Dr. Victor Kennedy, University of Maryland Horn Point Laboratory, Cambridge; and Mary Stephenson, Fisheries and Oceans, Moncton, NB, Canada.

We acknowledge all those who contributed to the success of the first edition of the manual—the past and present staff of the NOAA facility in Oxford. They provided us with ideas, techniques, approaches, and counsel.

INTRODUCTION

Investigators at the Cooperative Oxford Laboratory (COL) diagnose and study crustaceans, mollusks, finfish, and a variety of other marine and estuarine invertebrates to assess animal health. This edition updates the *Histological Techniques for Marine Bivalve Mollusks* manual by Howard and Smith (1983) with additional chapters on molluscan and crustacean techniques. The new edition is intended to serve as a guide for histological processing of shellfish, principally bivalve mollusks and crustaceans. Basically, the techniques included are applicable for histopathological preparation of all marine animals, recognizing however that initial necropsy is unique to each species. Photographs and illustrations are provided for instruction on necropsy of different species to simplify the processing of tissues. Several of the procedures described are adaptations developed by the COL staff. They represent techniques based on principles established for the histopathologic study of mammalian and other vertebrate tissues, but modified for marine and aquatic invertebrates. Although the manual attempts to provide adequate information on techniques, it is also intended to serve as a useful reference source to those interested in the pathology of marine animals. General references and recommended reading listed in the back of the manual will provide histological information on species not addressed in the text.

We chose to address safety as the first chapter to emphasize its importance in the histology laboratory. Histological technicians are exposed to many toxic, carcinogenic, reactive, and flammable reagents in the course of their work. Expanding awareness to chemical and environmental safety is essential. Handling of animals and processing of tissues are discussed in Chapters 2 through 9. These chapters discuss the necropsy and examination of shellfish specimens, and describe the procedures employed for oysters, clams, mussels, scallops, shellfish larvae, and blue crabs, from receipt to the point of fixation. Staining methods (Chapter 8) include general tissue stains, special stains for specific tissue components, stains for frozen sections, and stains for fresh and fixed blood smears. Variations in the stain protocols are given to correlate the pH of the stains with the fixatives and tissues. Most of the stains also have been successfully used on tissues of finfishes. Color plates showing expected results for special stains using protocols in this manual are provided from various tissues and species. Chapters 10 through 14 detail specialized techniques for the diagnosis of prominent parasites and diseases found in shellfish. Helpful information on conversions of metric and English units of measure, laboratory calculations, and data entry forms is provided in the Appendix.

CHAPTER 1. SAFETY

A. Introduction

In recent years, workplace safety has become a primary issue for employers, with numerous government regulations enacted to protect employees. Employers and supervisors who are negligent in enforcing safety and environmental management issues face stiff penalties. This chapter is not meant to provide a thorough and complete discussion of safety and environmental compliance in the histology laboratory, but to highlight some recognized practices. For a more in-depth perspective, consult references on federal, state, and local government requirements and publications on safety and environmental compliance. Safety catalogs also carry many references on this subject.

Safety cannot be overemphasized in a histology laboratory since the many volatile solvents and other hazardous chemicals used can affect employee health. Laboratory supervisors must provide training for the proper operation of specialized equipment, as well as protocols for the ordering, storing, safe use, and proper disposal of chemicals. Technicians who have not had adequate instruction risk serious injury to themselves and their coworkers. Safety and environmental refresher training need to be provided at least annually.

Safety and environmental compliance regulations are mandated by various federal government agencies and some states have additional regulations. The U.S. Department of Labor, Occupational Safety and Health Administration (OSHA)^a is the federal regulatory agency that establishes and enforces standards to save lives, prevent injuries, and protect the health of American workers. Workplace inspections are another of OSHA's principal activities. OSHA requires every employer to "furnish employees with a place of employment which is free from recognized hazards that are causing or likely to cause death or serious physical harm" (29 CFR 1903.1), commonly referred to as a safe and healthy workplace. Facility inspections by trained in-house representatives also aid in maintaining a safe workplace. In addition, training films and computer software are available from

numerous sources for implementing safety and environmental compliance programs to meet government regulations.

Employers are required by the OSHA Hazard Communication Standard (HAZCOM) to have a written program to inform employees of hazards they are exposed to on the job and how to protect themselves from those hazards (29 CFR 1910.1200). OSHA Laboratory Standard 29 CFR 1910.1450 requires all employers engaged in the laboratory use of hazardous chemicals to also develop a Chemical Hygiene Plan (CHP), the purpose of which is to protect all personnel, including volunteers and contractors, from harm due to chemical exposure in the workplace. The Code of Federal Regulations (CFR) may be downloaded from the U.S. Government Printing Office (GPO) website^b.

The National Institute for Occupational Safety and Health (NIOSH)^c is the federal agency responsible for conducting research and making recommendations for the prevention of work-related diseases and injuries. Information, training, resource materials, and guidelines are available from NIOSH to help with a variety of safety concerns.

The mission of the U.S. Environmental Protection Agency (EPA)^d is to protect human health and to safeguard the natural environment—air, water, and land. Its publication *Environmental Management Guide for Small Laboratories* (EPA 2000) provides compliance guidance on regulatory and management issues pertinent to a histology laboratory.

B. General Safety

Written hazard assessments are needed for each job activity or work area in the laboratory to identify associated dangers, establish safe working protocols, and determine appropriate personal protective equipment (PPE) or countermeasures. It is important to then train employees to safely accomplish their job assignments and enforce workplace protocols.

Protective equipment useful in a marine histopathology laboratory include stainless steel mesh gloves^e to protect hands from the hazards of special knives; synthetic hypoallergenic or thin nitrile gloves to protect against chemical and biological hazards; and thermal-insulated gloves for procedures involving hot substances. Disposable aprons or lab coats also should be used as necessary. Chemical goggles are required for eye protection. Pipet aids such as fillers, bulbs, pumps, dispensers, or pipettors and disposable pipets should be provided for working with contaminating and dangerous chemicals. Pipetting by mouth is dangerous and never recommended. Procedures involving hazardous chemicals should be undertaken in a chemical fume hood. Use biological safety hoods or cabinets to protect against hazards of biological agents and/or to protect biological cultures from contamination. Laboratories also need to be equipped with emergency eyewashes and showers, according to the specifications of the American National Standards Institute (ANSI 1998), and inspected and flushed according to ANSI standards. In the event of an accident, affected areas such as eyes and skin must be flushed with water for a minimum of 15 min with an approved safety device. After proper flushing, assess the situation and seek appropriate medical assistance.

Safe operation of equipment such as microtomes is essential. Locking levers on microtome handwheels should be kept in working order. Never disable safety mechanisms.

Gas line hoses to bunsen burners should be routinely checked. Portable fire extinguishers need to be inspected on a monthly basis to ensure they are in their designated location and in good condition. An annual inspection of fire extinguishers by a certified fire equipment company is required.

C. Chemical Safety and Environmental Compliance

Regulations imposed by the federal government emphasize the importance of safety and environmental compliance in the laboratory. Technicians need to understand job hazards and employ proper workplace protection. Safeguards should be taken against the four routes of exposure to hazardous chemicals—(1) inhalation, (2) contact with skin or eyes, (3) ingestion, and (4) injection. Development of and adherence to sound workplace protocols will help reduce or eliminate these exposures.

Many extremely hazardous chemicals are used in special staining techniques. Chemicals in original shipping containers are identified by their hazard characteristics, such as *flammable*, *corrosive*, *reactive*, and *toxic*. Extreme care is needed with chemicals such as anhydrous picric acid salts, ether, and dried ammoniacal silver salt solutions that have specific hazardous characteristics. Appropriate labeling and chemical storage facilities are necessary to accommodate the specific hazards of each chemical. After use, chemical wastes must be disposed of properly.

Labeling systems have been devised to alert technicians to the dangers associated with chemical reagents. All chemicals arrive with manufacturers' warnings, safety labels, and Material Safety Data Sheets (MSDSs) that give extensive information about the chemicals, their proper use, and disposal. MSDSs must be available to workers. It is also recommended that copies of MSDSs be kept in the laboratory or work area where each of the chemicals are used. Appropriate MSDSs will be required by physicians if emergency medical attention is needed. Some websites where MSDSs can be obtained are listed on page 5.

Chemicals that are mixed in the laboratory must be labeled by name, e.g., Davidson's fixative, and each ingredient should be listed. Appropriate warning labels, including the target organ, of each hazardous ingredient must be provided for newly prepared mixtures. Only one chemical name is allowed on a chemical container. A common problem occurs when employees leave original labels on containers, then reuse the containers after emptying, washing, and relabeling them to store another chemical. This is considered double labeling and is a violation of federal code.

At the Cooperative Oxford Laboratory (COL), the J.T. Baker^f labeling system is used. This system has been found to be particularly useful in laboratory settings. The National Fire Protection Association (NFPA) labeling system which was devised for firefighters in emergency situations has less utility in laboratories. In the J.T. Baker system, each chemical group is color coded to help in the segregation and storage of compatible chemicals. According to this system, chemicals should be separated into acid and base corrosives (white), poisons (blue), reactive substances (yellow), flammables (red), and general storage (green). Chemicals incompatible with other materials within the same color group are further separated by identically colored striped labels.

There are chemical compatibility charts and computer programs available, such as the National Oceanic and

Atmospheric Administration (NOAA) Chemical Reactivity Worksheet (CRW), that inform the technician if chemicals are compatible. In the preparation of any mixture, the technician should be knowledgeable of the dangers associated with those chemicals. The CRW can be downloaded from a NOAA website^e. A hazardous waste compatibility chart, EPA-600/2-80-076, is also available from an EPA website^h.

Chemical fume hoods are essential to remove toxic vapors from working environments. They are utilized from the initial steps of preparing fixatives, solvents, and noxious reagents through the final steps of coverslipping and cleaning the stained and dried slides. Hoods are not to be used for storage. Items stored in hoods change air flow patterns and reduce efficiency. Fume hoods must be certified annually to ensure they are in proper working order and have adequate face velocity or air flow. They should be set to maintain a face velocity of 100-120 linear ft/min, depending on the chemicals used. Also, workers and work spaces need to be monitored for exposure to hazardous chemicals at least annually and more frequently if there is reason to suspect chemical exposure. Logs should be maintained to show compliance.

The use and disposal of all chemicals need to be carefully monitored. Chemical inventories are required by OSHA and need to be updated annually. Inventories should give the name, amount, and location of chemicals in the facility. Other information, such as known hazards and EPA hazardous waste numbers, may be included pertinent to facility needs. Updated inventories and MSDSs need to be maintained in each laboratory where chemicals are used.

Proper chemical disposal is important as well as a legal responsibility. Records should be kept on the generation of chemical wastes for disposal and the accumulation start date (the date container is completely filled). Once a chemical has been identified as a waste, there are time constraints, usually 90-180 days, for on-site storage before disposal by a licensed waste company. Check federal, state, and county guidelines for local requirements. Be informed of chemical compatibility before mixing wastes for disposal. It is best to keep waste streams separate. However, various solvents usually can be combined as one waste stream, as can various fixatives. The COL combines most alcohol-based stains with solvents and many aqueous-based stains with fixatives. Establish facility disposal protocols in collaboration with the chemical waste hauler. For disposal of bulk wastes, such as fixatives and solvents, keep a log to identify concentrations and quantities of each chemical in the waste stream. Lists of

chemical wastes likely will be required by contractors prior to waste pickup so they can be aware of any unusual chemicals that may be on hand and thus obtain approval from the designated waste disposal company. Unknown chemical wastes are the most difficult and costly to dispose of. Clear and proper labeling of chemicals will eliminate this problem and improve safety.

Employees who manage or ship hazardous wastes are required to pass a course on U.S. Department of Transportation (DOT) hazardous materials management as well as an EPA^d course on hazardous waste management.

Most laboratories have a safety officer or representative who can help with guidelines for keeping chemicals properly inventoried and safely stored.

When transporting hazardous materials, follow government and facility environmental and safety regulations; see NOAA websiteⁱ.

D. Health Hazards and Chemical Terminology

Some common health hazards, chemical terminology associated with the histology laboratory, and related safety tips have been abstracted from the MSDSs, *Prudent Practices in the Laboratory - Handling and Disposal of Chemicals* (NRC 1995), and *Humason's Animal Tissue Techniques* (Presnell and Schreibman 1997), and are provided below:

Acids are highly reactive with water. Add acids *slowly* to water, and work in a fume hood to avoid breathing the fumes. If acids are involved in a fire, never use water to extinguish; use a dry chemical or a CO₂ extinguisher. Acids have a corrosive action on the skin; immediately wash affected area repeatedly with soap and warm water.

Alkalis are also corrosive and must be thoroughly washed off after contact with skin, preferably first with a weak acid or vinegar and then by repeated washing with water. Seek medical attention if eyes are affected.

Allergen is a substance, i.e., a chemical, capable of inducing allergy or specific hypersensitivity by the immune system. Individuals may exhibit wide differences in sensitivity to laboratory chemicals. For instance, gloves containing latex rubber pose problems for some and should be avoided.

Alums can cause burns. Wash affected area thoroughly.

Asphyxiants are substances that interfere with the transport of an adequate supply of oxygen to vital organs of the body.

Carcinogen is a substance capable of causing cancer. Many histological stains are now being investigated as possible carcinogens.

Chromic acid is a strong oxidizer and toxic. It can cause inflammation and ulcers on the skin. Wash affected area immediately and thoroughly for at least 15 min. Avoid inhalation; chemical can cause damage to the respiratory tract.

Corrosive substances cause destruction of living tissues by chemical action at the site of contact and can be solid, liquid, or gaseous.

Ethers are highly flammable; a can of ether can be readily ignited by a spark or open flame. An electrical charge can occur when pouring ether; ground by keeping the two containers in contact when pouring, or use a grounding strap. Quickly cover burning vapors to cut off oxygen. Keep container tightly closed, and store in a refrigerator designed for flammable or explosive materials.

Ethylene glycol is very toxic. Avoid breathing vapors; wash contaminated skin for 15 min. Use propylene glycol whenever possible.

Explosive is any chemical compound or mechanical mixture that, when subjected to heat, impact, friction, detonation, or other suitable initiation, undergoes rapid change, evolving large volumes of highly heated gases that exert pressure on surrounding medium.

Flammable substances are those that readily catch fire and burn in the air; they may be solid, liquid, or gaseous.

Flashpoint is the lowest temperature at which a liquid has sufficient vapor pressure to form an ignitable mixture with air near the surface of the liquid.

Formaldehyde, used primarily as a fixative, is recommended to be handled as a potential carcinogen by NIOSH. Use of a chemical fume hood, protective gloves and clothing, and eye/face shields are recommended.

Iodine is poisonous; avoid contact. Medical attention is required if swallowed.

Irritants are noncorrosive chemicals that cause reversible inflammatory effects (swelling and redness) on living tissue

by chemical action at the site of contact.

Mercury, frequently used in histopathology labs, *is considered very hazardous* and must be disposed of properly. Efforts should be made to use less hazardous substances. Replace mercury thermometers with a nonhazardous (e.g., alcohol) type .

Nitrocellulose (=parlodion, collodion, celloidin, cellulose nitrate, pyroxylin) *is highly flammable*. Avoid inhaling.

Osmium tetroxide (osmic acid) is toxic; keep away from skin and eyes, and avoid fume inhalation. *Chemical is extremely damaging to eyes.*

Oxalic acid can be absorbed in the blood to form calcium oxalate. Wash affected area immediately.

Periodic acid is an oxidizing agent and can cause skin burns. Wash affected area well.

Peroxides are among the most hazardous substances handled in the chemical laboratory, and may cause irritation to skin, eyes, and respiratory tract. They generally are low-powered explosives that are sensitive to shock, sparks, and other accidental ignition. Keep bottles away from heat, and store in refrigerator to prolong shelf life.

Picric acid can be explosive. Crystalline form must always be kept moist; do not allow it to dry. Chemical can be purchased as a saturated aqueous solution.

Silver compounds become dangerous when combined with ammonium. *Aging of these solutions or exposure to air or light can form explosive silver compounds.* Silver nitride and silver azide may form if alcohol or formalin is present in the solution. Do not store silver solutions. Some jurisdictions will allow unused solutions to be inactivated by adding sodium chloride or dilute hydrochloric acid and discarded. *Handle HCl with care.*

Toxic effects of chemicals can occur after single (acute), intermittent (repeated), or long term, repeated (chronic) exposure.

Toxicology, the science of poisons, is the study of the adverse effects of chemicals on living systems.

Xylene and other clearing agents are flammable, should be stored in flammable storage cabinets, and used only in well-ventilated laboratories. If contact is made with skin, wash immediately and cleanse thoroughly with soap. Rewash several times.

E. Safety and Environmental Compliance Websites

Material Safety Data Sheets (MSDSs) websites:

- Chempliant: www.chempliant.com
- Cornell University: <http://msds.pdc.cornell.edu/msdssrch.asp>
- Fisher Scientific: www.fishersci.com
- J.T. Baker: www.jtbaker.com
- MSDS online: www.msdonline.com
- Oklahoma State University: www.pp.okstate.edu/ehs/links/msds.htm
- Prevent web.net: <http://www.oshweb.com>
- Sigma Aldrich Chemicals: www.sigma-aldrich.com
- University of Vermont: www.siri.org
- Where to find MSDSs on the internet: www.ilpi.com/msds/index.html

Other websites:

- Oklahoma State University Environmental Health and Safety: www.pp.okstate.edu/ehs/index.htm
- Vermont Safety Information Resources, Inc.: <http://siri.uvm.edu>
- Yale University Office of Environmental Compliance: www.yale.edu/oehs

F. Footnotes

^aOSHA: www.OSHA.gov

^bGPO website: <http://www.access.gpo.gov/nara/cfr/cfr-retrieve.html#page1>

^cNIOSH: (800) 356-4674 or www.cdc.gov/niosh/homepage.html

^dEPA: www.epa.gov

^ePerfect Fit Glove Co., 85 Inns Bruck Drive, Buffalo, NY 14227. (800) 876-6374. www.perfectfitglove.com

^fJ.T. Baker, 222 Red School Lane, Phillipsburg, NJ 08865. (800) 582-2537. www.jtbaker.com

^gNOAA website: www.response.restoration.noaa.gov

^hNew England Universities Laboratories: <http://www.epa.gov/ProjectXL/nelabs/0480.pdf>

ⁱNOAA website: www.easc.noaa.gov/enviro/index.html

G. References

ANSI (American National Standards Institute). 1998. American National Standard for Emergency Eyewash and Shower Equipment. ANSI Z358.1-1998, American National Standards Institute, New York. 29 p.

EPA (U.S. Environmental Protection Agency). 2000. Environmental Management Guide for Small Laboratories. EPA 233-B-00-001, U.S. Environmental Protection Agency, Washington, DC. 139 p.

NRC (National Research Council). 1995. Prudent Practices in the Laboratory - Handling and Disposal of Chemicals. National Academy Press, Washington, DC. 427 p.

Presnell, J.K. and M.P. Schreiber. 1997. Humason's Animal Tissue Techniques. 5th ed. Johns Hopkins Univ. Press, Baltimore, MD. 572 p.

H. Recommended Reading

Dapson, J.C. and R.W. Dapson. 1995. Hazardous Materials in the Histopathology Laboratory. Regulations, Risks, Handling and Disposal. 3d ed. Anatech Ltd., Battle Creek, MI. 255 p.

Mercier, P. 1996. Laboratory Safety Pocket Handbook. Genium Publ. Corp., Schenectady, NY. 212 p.

Steere, N.V., Editor. 1971. Handbook of Laboratory Safety. 2d ed. CRC Press, Boca Raton, FL. 854 p.

U.S. Department of Labor, Occupational Safety and Health Administration. 2001. Code of Federal Regulations, No. 29, Parts 1910.1000-1450. National Archives and Records Administration, Washington DC. 572 p.

CHAPTER 2. HANDLING OF LIVE ANIMALS: MOLLUSKS AND CRUSTACEANS

A. Introduction

Animals should be collected directly from their natural habitats and processed as soon as possible. Alternatively, they can be obtained from a commercial source such as a seafood market. The disadvantage of the latter method is that the site of origin and date of collection may not be known (factors which could affect viability and specimen quality).

Take extreme care to ensure that nonindigenous species do not contaminate local waters. Quarantine facilities or separate aquaria need to be used if specimens are to be held in water. Before disposal, consideration must be given to treatment of animal wastes and aquarium water with recommended forms of disinfectants such as chlorine, iodine, or ultraviolet light. Contact government authorities for specific permit and handling requirements. Investigators also should consider tolerance of parasites in tissues to respective disinfectants (Bushek et al. 1997).

If shellfish are to be processed quickly, refrigerated storage is preferred. To hold for longer periods, place animals in aquaria or holding tanks with ambient flow-through or recirculated seawater. Specimens survive much better in a chilled environment at 5-15°C. Oysters *Crassostrea* spp. are the hardiest bivalves to transport; they maintain watertight integrity for periods of more than a week when held dry in a refrigerator. Other oysters such as *Ostrea edulis* tend to gape, lose mantle fluid, and hence cannot be held dry as long. This is also true for scallops *Argopecten* or *Placopecten*, mussels *Mytilus*, *Gukensia*, or *Modiolus*, and to a certain extent some clams such as *Spisula*. Softshell clams *Mya arenaria* and Baltic macoma clams *Macoma balthica* retain their mantle fluid relatively well but must be handled carefully to avoid shell fractures.

B. Specimen Collection

Care should be taken during collection to prevent damage and stress to specimens, which may affect histological

interpretations. While some specimens may be collected easily by hand, others require the use of dredges, nets, traps, and mechanical or commercial gear. Most mollusks, may be transported in open plastic bags on ice after collection. Species that tend to gape should be placed in damp towels or seaweed, then bagged and chilled.

1. Oysters

Oysters are most frequently sampled by tonging or by dredge. At the time of collection, specimens should be rinsed well and scrubbed to remove sediments and as much of the epifauna (barnacles, mussels, sea squirts) as possible. Randomly select individuals with unbroken shells or without other obvious signs of damage. Place in a labeled mesh bag or other ventilated type of container on "blue ice."

2. Softshell Clams

Softshell clams burrow into sand and mud bottoms, and extend their siphons into the water for feeding and respiration. A hydraulic escalator dredge is needed to collect clams subtidally, and clam forks or hoes are used to dig clams intertidally. Handle softshell clams carefully, as the shells are fragile and easily broken. Chill clams immediately upon collection; clams may be held briefly in open plastic bags on ice during transport to a holding facility.

3. Crabs

Handle crabs with prudence to reduce stress. Bacterial and viral infections become patent due to stress from captivity and crowding (Johnson 1976, Messick and Kennedy 1990).

In the field, protect crabs from the wind and heat by placing them in a cooler of ice on a layer of burlap dampened with ambient seawater; avoid loose ice which

can melt, causing crabs to suffocate in the shallow water or to become stressed from the drastic salinity difference.

If collecting early juvenile or small species, animals can be placed in a bucket of ambient seawater with a battery-operated bubbler.

C. Shipping Instructions

Live animals must be shipped and received in good physiological condition for optimal tissue analysis. The following instructions provide for the shipment of live shellfish to ensure viable samples on arrival:

- Pack live shellfish in a well-insulated, waterproof shipping container beneath a layer of ambient seawater-soaked burlap, seaweed, or newspaper; place cold packs on top. Leakproof containers, such as plastic soda bottles filled with water and frozen, work well for cold packs if “blue ice” is not available. Care should be taken to prevent specimen damage during transport from repeated shifting of ice, cold pack containers, or other materials placed in the shipping container. Mollusks that tend to gape may be wrapped with a rubberband and placed in seaweed or damp towels inside plastic bags. For crabs, chill before shipping during warm months. If animals are placed in ziplock bags, seals should remain open to avoid possible suffocation of specimens. **Ship early in the week (Monday or Tuesday) to avoid arrival during the weekend period and possible loss of samples because of improper storage conditions.**
- On outside of container, clearly label “**LIVE SPECIMENS, REFRIGERATE BUT DO NOT FREEZE.**”
- Email or phone the recipient immediately after a shipment has been made, indicating where and when sent, estimated time of arrival, name of carrier, flight number and, most importantly, the waybill number.
- Ship by overnight air freight (prepaid) directly to destination.
- Provide background information with each sample, such as: name of requestor; to whom report should be sent, including address and phone number; and pertinent collection data, such as temperature, salinity, pH, species, origin, history, sampling location, number of specimens in sample, and date collected.

Fixed tissues may be an alternative to shipping live specimens. Fix the tissues according to protocols in Chapter 5, and drain, rinse, and wrap in cheesecloth or an equivalent material. Insert tissues in a ziplock bag and seal. Place inside one or more additional bags and seal to prevent leakage. Then, place package for delivery in a sturdy puncture- and leakproof container.

Many overnight air freight carriers have standard requirements for shipping live or fixed specimens, and should be contacted for that information. Also, airlines have recently tightened their regulations for transporting live animals and require packaging in leakproof containers. For further information, see general requirements for shipments and packagings (49 CFR 173), U.S. Government Printing Office website^a and/or the International Air Transport Association (IATA) Dangerous Goods Regulations Manual^b.

D. Care, Handling, and Maintaining Live Shellfish

Proper care, handling, and maintenance of animals are essential to avoid stress which, if not properly managed, may cause tissue artifact and erroneous interpretation of health. These guidelines easily can be generalized to include most species. Nonindigenous animals should be quarantined so that exotic diseases and parasites are not introduced into local waters.

Short term refrigeration for holding animals is preferred. However, try to maintain enough moisture to prevent dehydration of tissues.

Holding systems used for experimentation of live specimens should be large enough to accommodate a sufficient number of animals. Feed animals regularly and recreate natural temperature, salinity, and light conditions to prevent excessive stress on animals maintained for experimental purposes. Flow-through tanks for local shellfish should provide sufficient water flow to feed the animals for short periods of time. Algal preparations are commercially available to maintain bivalve shellfish kept in recirculating tanks.

1. Oysters

Oysters filter such a large quantity of water that a flow-through system or a self-contained “living stream”^c is recommended to hold samples for extended time periods. Aquaria may be used to hold small animals or small samples, in which case extra air stones and continual

monitoring may be necessary. A properly conditioned 10-gal (38-L) aquarium may hold up to 350 oysters (5-20 mm) for experimental purposes. As the size of animals increases, the number that can be held in an aquarium decreases.

It is important to immediately remove moribund and dead shellfish from tanks due to the rapid deterioration of tissues (Tubiash 1971).

2. Softshell Clams

Clam samples destined for histology should be purged to remove sand and mud that interfere with sectioning of tissues. Purging for 12-24 h is usually adequate in flow-through or recirculating aquaria at salinities and temperatures approximating the collection site. Samples may then be held in open plastic bags in a refrigerator 1-2 days until processed. Softshell clams may be held for extended periods in flow-through systems at water temperatures below 23°C (McLaughlin et al. 1992).

Softshell clams are extremely sensitive to water quality and heat stress (Kennedy and Mihursky 1971). Only small numbers of clams under constant observation should be held in recirculating or closed aquaria (Tubiash 1971). Clams survive best when water temperature is held between 5-12°C.

For clinical studies, softshell clams may be easily labeled. Gently scrub the shell surface under cold tap water, then blot with paper towels and wipe with alcohol to dry. Label the shell with a permanent, solvent-resistant marker and cover the label with clear nail polish. Colored nail polishes may be used for additional markings on the shell surface. Nail polish labels last for several months.

3. Crabs (Messick 1995)

Crabs should be assayed as soon as possible after collection to reduce physiological changes. If holding crabs, observe the following guidelines:

- Place crabs in flowing seawater adjusted to within ± 10 ppt salinity of the collection site (Haefner and Garten 1974).
- If necessary, acclimate crabs to local salinity by slowly increasing or decreasing salinity of holding water until desired salinity is reached.

- If flowing seawater is unavailable, holding tanks or aquaria filled with artificial seawater are useful; 20-gal aquaria hold up to 50 early juvenile (5-35 mm) or 3 adult (200-260 mm) crabs.
- Crabs held at lower temperatures (5-15°C) have better survival rates.
- Recirculating tanks similar to commercial shedding tanks can hold large numbers of crabs when flow-through seawater is unavailable (Manthe et al. 1983, Malone and Manthe 1985, Hochheimer 1986).
- Blue crabs can survive short periods of captivity in a flow-through tank by feeding on detritus in the water, especially during cooler months when activity is diminished. For prolonged captivity, maintenance feeding is highly recommended for optimal health.
- Crabs will feed on small clams, mussels, other bivalves, or fish pieces (Laughlin 1982). To prevent cannibalism, do not hold small and large crabs in the same holding tank.

E. Footnotes

- ^aGPO website: <http://www.gpoaccess.gov/cfr/index.html>
^bIATA Dangerous Goods Regulations Manual website: <http://www.iata.org/dangerousgoods/index>
^cFrigid Units, Inc., 5072 Lewis Ave., Toledo, OH 43612. 419.478.4000. www.frigidunits.com

F. References

- Bushek, D., R. Holley, and M. Kelly. 1997. Chlorine tolerance of *Perkinsus marinus*. J. Shellfish Res. 16: 260 (abstract).
- Haefner, P.A., Jr. and D. Garten. 1974. Methods of handling and shedding blue crab, *Callinectes sapidus*. Va. Inst. Mar. Sci., Mar. Resour. Advis. Ser. 8: 1-14.
- Hochheimer, J. 1986. Water quality in crab shedding. *The Shedder*, Vol. 2. Univ. Maryland Sea Grant Extension Program, Cambridge, MD.
- Johnson, P.T. 1976. Bacterial infection in the blue crab, *Callinectes sapidus*: course of infection and histopathology. J. Invertebr. Pathol. 28: 25-36.

- Kennedy, V.S. and J.A. Mihursky. 1971. Upper temperature tolerances of some estuarine bivalves. *Chesapeake Sci.* 12: 193-204.
- Laughlin, R.A. 1982. Feeding habits of the blue crab, *Callinectes sapidus* Rathbun, in the Apalachicola estuary, Florida. *Bull. Mar. Sci.* 32: 807-822.
- Malone, R.F. and D.P. Manthe. 1985. Chemical addition for accelerated nitrification of biological filter in closed blue crab shedding systems, pp. 41-47. *In: H.M. Perry and R.F. Malone (eds.), Proceedings of the National Symposium on the Soft-Shelled Blue Crab Fishery.* Gulf Coast Research Lab., Ocean Springs, MS.
- Manthe, D.P., R.F. Malone, and H.M. Perry. 1983. Water quality fluctuations in response to variable loading in a commercial, closed shedding facility for blue crabs. *J. Shellfish Res.* 3: 175-182.
- McLaughlin, S.M., C.A. Farley, and F.M. Hetrick. 1992. Transmission studies of sarcoma in the soft-shell clam, *Mya arenaria*. *In Vivo* 6: 367-370.
- Messick, G.A. 1995. Laboratory techniques for detecting parasites and diseases of blue crabs, *Callinectes sapidus*, pp. 187-200. *In: J.S. Stolen, T.C. Fletcher, S.A. Smith, J.T. Zelikoff, S.L. Kaattari, R.S. Anderson, K. Söderhäll, and B.A. Weeks-Perkins (eds.), Techniques in Fish Immunology-4.* SOS Publ., Fair Haven, NJ.
- Messick, G.A. and V.S. Kennedy. 1990. Putative bacterial and viral infections in blue crabs, *Callinectes sapidus* Rathbun, 1896 held in a flow-through or a recirculation system. *J. Shellfish Res.* 9: 33-40.
- Tubiash, H.S. 1971. Soft-shell clam, *Mya arenaria*, a convenient laboratory animal for screening pathogens of bivalve mollusks. *Appl. Microbiol.* 22: 321-324.

CHAPTER 3. NECROPSY AND EXAMINATION OF SHELLFISH SPECIMENS

A. Introduction

Shellfish for histological processing should be sampled in the field by methods causing minimal, if any, damage to the specimens. Refrigerate or hold in an aquarium or flow-through water system at the proper salinity until processed (see *Care, Handling, and Maintaining Live Shellfish*, p. 8). Perform necropsy and fix tissues as soon as possible after collection to reduce physiological or postmortem changes.

1. Processing Procedures

- Record field data and history of sample (see *Gross Macroscopic Exam* form, p.194)
- Assign code: location, species, year, and/or project
- Scrub animals to remove fouling organisms
- Drill or notch shells to prepare for histocytology and allow shellfish to purge shell fragments overnight
- Measure shells:
 - From bill to hinge for oysters and mussels
 - Across shell, side to side, for clams and scallops
 - Across shell, point to point, for crabs
- Open shellfish
 - Pry open bill or hinge and cut adductor muscle (avoid damaging tissues)
- Record the following:
 - Gaping bivalves (gapers) that do not close
 - Weak muscle or loss of muscle adhesion to shell
 - Lack of mantle reaction (dry)
 - Any unusual odor or color
 - Stabbing, cutting, or tearing specimen upon opening (causing possible acute inflammatory infiltration of hemocytes to localized areas)
 - Presence, number, and size of spat
- Record macroscopic information (see examples below)

Experience has shown that some conditions are predictable in samples from certain geographic areas. Each condition and degree of prevalence have an effect

on the animal and how the animal has adjusted. Shell abnormalities, fouling organisms, parasites, gross abnormalities, predators, and physiologically related conditions represent only a few of the criteria for assessing marine shellfish. Examples provided below represent common conditions that may be found during examination of specimens. A detailed explanation of each condition is provided in *Figures and Explanations* (p. 12). Photographic representations of each of these conditions are provided at the end of the chapter. Any observations noted during the macroscopic examination will aid the investigators in their analyses.

a. Shell abnormalities

- 1) Shell checks (Figs. 3-1, 3-2)
- 2) Mantle recession/retraction (Fig. 3-3)
- 3) Recovery from mantle recession (Fig. 3-4)
- 4) *Cliona* sp. (boring sponge) penetrations, including estimated degree of infestation (Figs. 3-5a, b, 3-6)
- 5) *Diplothyra smithii* (boring clam/oyster piddock) (Fig. 3-7a, b)
- 6) *Polydora* sp. (mud worm) tunnels, including estimated degree of infestation (Figs. 3-8, 3-9)
- 7) "Maladie du pied" (Fig. 3-10)
- 8) Shell and mud blisters (Figs. 3-11, 3-12)
- 9) Shell pustules (Figs. 3-13, 3-14)
- 10) Calcareous malformations (Fig. 3-15)
- 11) Conchiolin deposits (Figs. 3-16, 3-17)
- 12) Drill egg cases and drill holes (Fig. 3-18a, b)

b. Fouling organisms

- 1) Barnacles (Fig. 3-19)
- 2) Mussels (Figs. 3-19, 3-21a)
- 3) *Molgula* sp. (sea squirts) (Fig. 3-20)
- 4) Anemones (Fig. 3-21a, b)
- 5) Encrusting bryozoa and worm tubes (Fig. 3-22a, b)
- 6) *Crepidula fornicata* (slipper shells) (Fig. 3-23)
- 7) Sponges (Fig. 3-24)

c. Obvious parasites

- 1) Pea crab *Pinnotheres* sp. (gill area) (Fig. 3-25)
- 2) Copepod *Mytilicola* sp. (gut area) (Fig. 3-26)
- 3) Encysted ciliates (gill area) (Fig. 3-27)

d. Physiological indicators

- 1) Fat, medium, or watery condition (Figs. 3-28, 3-29, 3-30)
- 2) Pale digestive diverticulum (Fig. 3-31)
- 3) Swollen tissue (edema) (Fig. 3-32)
- 4) Obvious gonad (Fig. 3-33a, b)
- 5) Gill lesions:
 - Gill erosion (Fig. 3-34)
 - Dirty gills (Fig. 3-35)
- 6) Color/pigmentations:
 - Copper - blue-green (Fig. 3-36)
 - Melanin - black (Fig. 3-37)
 - Diapedesis - yellow to green (Fig. 3-38)
- 7) New shell growth (Fig. 3-39)

e. Other gross abnormalities

- 1) Watery cyst (Fig. 3-40)
- 2) Abscesses (Fig. 3-41a, b)
- 3) Pearls (Fig. 3-42a, b)

f. Predators (Galtsoff 1964)

- 1) Blue crabs *Callinectes sapidus* (prey on spat attached to shells) (Fig. 3-43a,b)
- 2) Mud crabs (prey on spat) (Fig. 3-44)
- 3) Toadfish *Opsanus tau* (Fig. 3-45)
- 4) Drills *Urosalpinx cinerea* (Fig. 3-46)
- 5) Flatworms *Stylochus ellipticus* (Fig. 3-47)
- 6) Starfish *Asterias forbesi* (Fig. 3-48)
- 7) Conchs and whelks *Busycon carica*
- 8) Mud prawns *Callinassa* sp.
- 9) Black drum, sting ray, birds, and man

2. Figures and Explanations

a. Shell abnormalities

- 1) Shell checks (Figs. 3-1, 3-2)

Shell checks are external anomalies formed in oysters that survive juvenile oyster disease (JOD). Survivors produce a distinct ridge or band that correlates with the size of the oyster at disease onset and is visible in the shell upon regrowth. Checks are often found with

conchiolin deposits on the interior of the shell of 10- to 30-mm juveniles during periods of active JOD (Lewis et al. 1996). A similar abnormality is also seen in larger shellfish and may be a reflection of growing and husbandry techniques, spawning, or other conditions that affect growth patterns.

- 2) Mantle recession/retraction (Fig. 3-3)

Mantle recession or retraction is indicated by heavy fouling of the inside posterior margin of the bottom shell. It is caused by prolonged retraction of the mantle from the "growing" edge of the shell. This condition usually indicates a sick oyster (Farley 1968).

- 3) Recovery from mantle recession/retraction (Fig. 3-4)

An indication that an oyster is recovering from previous recessive growth (mantle recession) is the overlay of new periostracum on the fouled inner shell margin. "The periostracum is a film of organic material (scleroprotein called conchiolin), secreted by the cells located near the very edge of the mantle . . . the conchiolin appears as amorphous, viscous and transparent material which hardens shortly after being deposited" (Galtsoff 1964).

- 4) *Cliona* sp. (boring sponge) (Figs. 3-5a, b, 3-6)

According to Galtsoff (1964), "Small round holes on the surface of mollusk shells indicate the presence of the most common animal associated with the oyster, the boring sponge." The sponge reaches the oyster tissue itself only in cases of old, heavy infestation. Usually, holes made by the sponge that penetrate to the inner shell surface are rapidly covered by a deposition of conchiolin. "However, should the deposition of shell material be delayed by adverse conditions, the sponge makes direct contact with the mantle and produces lysis of the epithelium and underlying connective tissue. Dark pigmented pustules form exactly opposite the holes in the shell" (Galtsoff 1964). Heavy infestations of *Cliona* boring into shells make valves brittle, often causing shell breakage upon opening.

- 5) *Diplothyra smithii* (oyster piddock) (Fig. 3-7a, b)

Diplothyra smithii is a boring clam found in oyster and clam shells in high salinity waters. "The range of distribution extends from northern Cape Cod (Provincetown, Mass.) south to the east and west coast of Florida, Louisiana, and Texas. . . . As the cavity bored by the clam increases and approaches the inner shell surface, the oyster protects itself by depositing layers of conchiolin. . . ." (Galtsoff 1964).

6) *Polydora* sp. (oyster mud worm) tunnels (Figs. 3-8, 3-9)

"*P. websteri* invades the shell cavity of the oyster, settles on the inner surface at a right angle to the edge, and builds a U-shaped mud tube with both orifices external. The structure is soon covered by a layer of conchiolin deposited by oyster and becomes a semitransparent blister" (Galtsoff 1964).

7) "Maladie du pied" (Fig. 3-10)

According to Galtsoff's (1964) *The American Oyster*, "The disease affects the area of the attachment of the adductor muscle, primarily on the lower concave (left) valve, and in certain cases the upper, flat valve. . . .In advanced cases the muscle becomes detached from the valve and forms irregular cysts of horny and slightly elastic material. Later on when the cyst extends beyond the area of the muscle attachment, the cyst walls become covered with calcareous shell deposit" (Galtsoff 1964).

8) Shell and mud blisters (Figs. 3-11, 3-12)

Blisters frequently are found on the inside of mollusk shells near the adductor muscle. "Chambers found in *C. virginica* consist of irregular cavities containing mud or sea water. Such formations are called blisters. Blisters can be artificially induced by inserting a foreign object between the mantle and the shell. They are also caused by the invasion of shell cavity by *Polydora* or by perforations of the shell by boring sponges and clams" (Galtsoff 1964).

9) Shell pustules (Figs. 3-13, 3-14)

Condition is related to haplosporidiosis (MSX). "Oysters with raised yellow-brown conchiolin deposits on the nacreous surface of the shell. . . .These deposits contained a creamy yellow fluid which consisted of moribund *M. nelsoni* (= *Haplosporidium nelsoni*) plasmodia, hemocytes, and cellular debris. . . .when present it was a reliable gross indication of the disease" (Farley 1968). Farley termed a stage of the MSX disease "remission" when the shell pustules appeared as described above.

10) Calcareous malformations (Fig. 3-15)

These mollusk abnormalities are pathological. "They are associated with the disturbance of calcium metabolism which manifests itself in an overcalcification of selected parts of the organism. . . .They fall into two classes: 1) cysts and calcified cups; and 2) calcified tumors and pearl-like structures attached to the valve or formed inside the soft tissues. . . .It is reasonable to assume that

the described malformations represent a phenomenon analogous to the over-calcifications of various selected part of mammals described by Selye (1962) under the general term calciphylaxis" (Galtsoff 1969).

11) Conchiolin deposits (Figs. 3-16, 3-17)

Various diseases cause deposits to present differently. In JOD, conchiolinous lesions form on the inner shell surface and vary from a thin layer to a wall of conchiolin that encapsulates the oyster (Lewis 2001). The disease MSX causes the formation of conchiolinous pustules (Farley 1968). Lesions associated with shell repair can result from shell damage or penetration by various organisms. Shell blisters also demonstrate another form of conchiolinous deposits that generally appear as yellowish-brown layers on the inner shell. C.A. Farley and E.J. Lewis (NOAA, Oxford, MD, pers. commun. 1992) distinguished between new and old deposits depending on the thickness and flexibility of the conchiolin.

12) Drill egg cases and/or drill holes (Fig. 3-18a, b)

The presence of oyster drill egg cases are recorded when attached to oyster shells in a sample since oyster drills are the most persistent predator of the oyster. The drill cases are tough greenish leathery capsules in which oyster drill eggs are deposited. Small symmetrical holes in molluscan shells can be attributed to the action of oyster drills or other gastropods.

b. Fouling organisms

Many fouling organisms are seasonal; however, their abundance directly affects the health of the oyster. They do not penetrate the shell or contact the oyster directly. They do compete for food and space with an oyster population, and influence survival of larvae and juveniles (Galtsoff 1964, White and Wilson 1996).

1) Barnacles (Fig. 3-19)

Barnacles are a common fouling organism on oysters and other hard substrates in intertidal areas along the western Atlantic and Gulf coasts. Barnacles compete with oysters for available space and also ingest oyster larvae (Steinberg and Kennedy 1979).

2) Mussels (Figs. 3-19, 3-21a)

Common species in the mid-Atlantic region of the United States include the blue mussel *Mytilus edulis*, the hooked mussel *Ischadium recurvum*, and the dark falsemussel

Mytilopsis leucophaeata. The blue mussel grows to 102 mm in length and is found in high salinity areas. The shells are smooth with a glossy blue-black or brownish exterior and a light purple interior. These mussels have a distinct dark muscle scar. Hooked mussels attach to most hard surfaces including oyster shells. They are generally 25-50 mm in length and a dull black to gray on the exterior surface, with a purple to rosy brown interior shell color. The surface of the shells are distinctly ridged and curved. Dark falsemussels are found in freshwater to 10 ppt salinity, grow to 20 mm, and attach to hard substrates. Shells are brown to tan, smooth, and have a shelf under the hinge (Lippson and Lippson 1997).

3) *Molgula* sp. (sea squirts) (Fig. 3-20)

Sea squirts or sea grapes *Molgula manhattensis* are tunicates found along the entire Atlantic coast of the United States. They are common in Chesapeake Bay where they grow in dense clusters and have the appearance of grapes (Lippson and Lippson 1997). "In Chesapeake Bay, tunicates can be so densely packed that anoxic conditions can develop close to the substrate surface and kill many spat" (White and Wilson 1996).

4) Anemones (Fig. 3-21a, b)

Two species of anemones are found on oyster shells in Chesapeake Bay. The most common is the white anemone or "flower of the sea," *Diadumene leucolena*. The green-striped anemone *Haliplanella luciae* is less common. When disturbed or exposed to air, anemones withdraw their tentacles into the stalk, leaving a small inconspicuous jelly-like mass (Lippson and Lippson 1997). Anemones are predators of oyster larvae and have been thought to limit oyster populations throughout Chesapeake Bay (White and Wilson 1996).

5) Encrusting bryozoa and worm tubes (Fig. 3-22a, b)

Bryozoans are often referred to as moss animals since they have the appearance of brown marine mosses. Although there are other forms, most bryozoans occur either as bushy colonies or calcareous encrustations. "The bushy types take on various appearances, some looking like moss, seaweed, or hydroids. The encrustations form delicate, lacy patterns over almost any hard surface and grow in geometric shapes, like cobblestone paving. . . ." (Lippson and Lippson 1997).

A number of worms construct a maze of intricate and entangling tubes on and around oysters. These range from the whip mud worm that builds its soft tube from

mud to the fragile, narrow, sand grain tubes of the sandbuilder worm, the leathery tubes of the fan worm, and the large calcareous tubes of the limy tube worm (Lippson and Lippson 1997).

6) *Crepidula fornicata* (slipper shells) (Fig. 3-23)

Slipper shells are shallow water snails that attach to a variety of shellfish or hard surfaces in high salinity areas. Shell size may be 38 mm in length. *Crepidula* are commonly found in groups and attach to one another in a communal life style. The exterior of the cup-shaped shells vary from a somewhat flattened to a high arch form and mimic the texture of the surface they attach to (Lippson and Lippson 1997). In some areas, *C. fornicata* or *C. plana* may be the most common and abundant of the fouling competitors of oysters (White and Wilson 1996).

7) Sponges (Fig. 3-24)

"Various siliceous sponges are very common members of the epifauna of oyster bottoms. . . .The red sponge, *Microciona prolifica*, is often found on highly productive oyster bottoms" (Galtsoff 1964). Sponges can be very common in some areas, but typically disappear in mid- to low-salinity waters.

c. Obvious parasites

1) *Pinnotheres* sp. (gill area) (Fig. 3-25)

Often called pea crabs, these small crustaceans are most abundant in high salinity waters. Young oyster crabs *Pinnotheres ostreum* invade the mantle cavity of oysters and other bivalve mollusks where they grow to maturity (White and Wilson 1996). Females become permanent residents while males have a more free-living existence. The smaller males (approximately 6 mm) are rarely seen and die after mating (White and Wilson 1996, Lippson and Lippson 1997). Females (approximately 13 mm) attach to the surface of gills where they feed on food particles brought in by the oyster and cause harm to the host by gill erosion and impaired gill function (White and Wilson 1996, Lippson and Lippson 1997). Extensive gill damage caused by some crabs can be rapidly regenerated when crabs are removed, but impaired gill function causes a relatively poor condition in many infested oysters (Galtsoff 1964).

2) *Mytilicola* sp. (gut area) (Fig. 3-26)

With the exception of the oyster *Crassostrea virginica*, this parasitic copepod is found in the intestinal tract of bivalves and is easily recognized by its red color and

relatively large size which makes it visible to the naked eye (Galtsoff 1964, White and Wilson 1996).

3) Encysted ciliates (gill area) (Fig. 3-27)

These ciliates attack oyster gills. "The disease is caused by a microparasite which has been *tentatively* placed in the genus *Sphenophrya*. The organism is a ciliate found in large cysts (xenomas) on the gill surface of diseased oysters" (Anonymous 1965). According to Dr. Eugene Small (University of Maryland, Department of Zoology, College Park, MD, pers. commun. 1998), recent identification by scanning electron microscopy has placed this organism in the genus *Hypocomella*.

d. Physiological indicators

1) Fat, medium, or watery condition (Figs. 3-28, 3-29, 3-30)

During the initial necropsy, each shellfish is visually rated for its gross physiological condition as fat, medium, or watery. This condition reflects the oyster's general health which is affected by its environmental surroundings, stress, and seasonal and sexual changes. Fat oysters are firm and usually fill their shell. The anterior portion is very rigid when lifted from the shell. Often, they are sexually ripe and exhibit a creamy tan color. Medium oysters generally are smaller within their shell, flatter, and less rigid than fat oysters; there is more fluid inside the shell and their color is basically tan. Watery oysters are limp, exhibit a grayish-tan color, and are slightly translucent.

2) Pale digestive diverticulum (Fig. 3-31)

Oysters from the same location usually show uniform-colored digestive diverticula (reddish-brown, greenish-brown, yellowish-tan, or blackish-brown) since they have been exposed to the same environmental conditions and food. Occasionally, a pale digestive diverticulum occurs, and is recorded. The pale color is often associated with a health problem, diagnosed only after histological examination.

3) Swollen tissue (edema) (Fig. 3-32)

In shellfish, edema is demonstrated by an abnormal accumulation of fluid in the intercellular tissue spaces causing swelling. During a survey for parasite distribution in Chesapeake Bay oysters, Tubiash et al. (1971) noted sporadic cases of greatly enlarged and edematous pericardia. "Examination of aseptically aspirated pericardial fluid showed heavy concentrations of gram-negative motile rods which proved morphologically and culturally compatible

with *Vibrio anguillarum*, an organism implicated in diseases of fishes and larval bivalve mollusks. Except for pericardial enlargement, the animals appeared to be grossly and histologically normal" (Tubiash et al. 1971).

4) Obvious gonad (Fig. 3-33a, b)

Gonadal tissues develop and mature as shellfish prepare for spawning. The gonad becomes particularly obvious or ripe with ova or sperm during spawning. Various colors may be associated with this transition, but the development of a more creamy coloration would be typical. *Obvious gonad* provides a quick determination on how ripe or ready to spawn the animal might be.

5) Gill lesions (Figs. 3-34, 3-35)

Gills provide several important life-sustaining functions, such as respiration, water filtration, and food collection; therefore, it is important to note the following irregularities that would impact directly on the health of the bivalve:

Gill erosion, often occurring when *Pinnotheres* are present. Extensive gill erosion corresponding with high mortalities also occurs from gill disease in *Crassostrea angulata* and *C. gigas*. Signs include presence of yellow spots to brown discoloration on the gills with necrosis and degeneration that leave a perforation or V-shaped indentation if the lesion occurs on the edge of the gill (Kinne 1983).

Dirty gills, indicating the state of the (1) direct environment (currents or turbulence), (2) reduced adductor muscle function, or (3) heavy *Polydora* infestation.

6) Color/pigmentations (Figs. 3-36, 3-37, 3-38)

"Pigmentation may be considered as a certain phase of excretion. Green oysters of Long Island Sound develop dark green pigment as the result of absorption and storage of copper by the phagocytes. . . ." (Galtsoff 1964).

Other colorations sometimes associated with mollusks are the result of pigments from the microscopic plants (algae) they consume. Often, the pink pigmentation of stored shellfish may be the result of the growth of so-called pink yeasts or pigmented bacteria (McCormack 1956, Boon 1972, Paparella 1973). Melanin, a black pigment, is produced by and incorporated into the mantle tissue (USDI 1970). Visible yellow to green aggregates of hemocytes may result from a number of causes including diapedesis, the process whereby whole hemolymph is

expelled from the body by passage across membranous body surfaces (Cheng 1981).

7) New shell growth (Fig. 3-39)

This is documented during the initial necropsy as a general physiological indicator. The oyster grows by secreting a thin layer of periostracum at the valve margins which is pliable and easily broken. This layer is later incorporated into the hard shell by a calcification process. Growth is influenced by season of the year, health of the animal, and environmental conditions.

e. Other gross abnormalities

1) Watery cysts in the visceral mass, palp, or mantle (Fig. 3-40)

“The cysts, seen in the live oyster, are large conspicuous bubble-like cavities generally distended by internal pressure of accumulated fluid. Sections show these cysts to contain a central granular material usually in concentric layers. . . . The cyst walls are formed of leucocytic cells which form themselves into an epithelium similar to that of the external epithelium of the mantle” (Mackin 1962).

2) Abscesses (Figs. 3-41a, b)

Abscesses are aggregations of hemocytes (blood cells) associated with necrotic (decaying) host cells. They frequently involve breakdown of epithelial linings and may be surrounded by phagocytic and/or fibrocytic hemocytes (Bondad-Reantaso et al. 2001).

3) Pearls (Fig. 3-42a, b)

“In the case of pearl formation, Boutan (1923) has shown that calcareous deposits are formed by amoeboid cells which crawl through the mantle epithelium, while the latter secretes the concentric layers of the organic matrix (conchiolin)” (Galtsoff 1964).

f. Predators (Figs. 3-43, 3-44, 3-45, 3-46, 3-47, 3-48)

“The list of many enemies that prey on oysters includes crustaceans, flatworms, mollusks, echinoderms, fishes, birds, and mammals” (Galtsoff 1964).

B. Processing of Specimens

A random sample of 30 specimens is normally collected and processed to detect diseases and parasites with a

10% or greater prevalence in a population (Ossiander and Wedemeyer 1973). Detection of lower prevalences requires examination of a larger sample. A tracking code is assigned for further in-house reference to the sample and for permanent filing. All pertinent data furnished with the sample should be included with the code, along with the name of the requestor and the date(s) of collection (see *Molluscan Pathology Report*, p. 196).

The initial steps employed in processing molluscan species are provided below, with a discussion on processing oysters presented in a stepwise manner. Separate sections follow to provide for special techniques and processing of clams, mussels, scallops, shellfish larvae, and blue crabs.

During processing, calipers rather than rulers are recommended for taking shell measurements. Open shellfish and cut adductor muscle quickly; the longer it takes to open the animal the tighter it will close its shell. For consistent cross-sections, orient each animal in the same position prior to cutting tissues. When polymerase chain reaction (PCR) assays are anticipated, aseptic methods are required.

1. Oysters (*Crassostrea* and *Ostrea* spp.)

An illustration of oyster anatomy (Fig. 3-49) is provided to orient the technician. Bold parallel lines in the illustration indicate where the cross-section is taken. Figure 3-50 illustrates oyster tissues that will be included in a 2- to 5-mm transverse cross-section when taken as instructed.

To begin processing, the oysters are placed in numerical sequence and scrubbed to remove sediment and fouling organisms. They are measured from the tip of the right valve near the hinge to the longest point on the bill, and their size (mm) is recorded (Fig. 3-51). Oysters are then opened by inserting an oyster knife between the valves at the hinge arch and twisting to separate the hinge (Fig. 3-52). The adductor muscle is severed as close to the right valve as possible, taking care not to injure internal tissue. The opened oysters are then examined (Fig. 3-53) for color, condition (fat, medium, or watery) (see Figs. 3-28, 3-29, 3-30), macroparasites, and shell and tissue abnormalities. The body is removed from the shell by severing the adductor muscle as close to the left valve as possible. The rectum is excised with scissors (Fig. 3-54) and placed in a correspondingly coded tube containing thioglycolate medium for determining the presence of *Perkinsus* (Ray 1952). Rinse scissors between use. The animal is washed in clean, filtered ambient or artificial seawater (see dilution table, p. 144) to remove sand and debris. It

is then placed on a clean No. 14 rubber stopper where a cross-section is made with a sharp razor blade (Fig. 3-55) or a patho knife and blade (available from cat. # 25861-010 and # 25861-012 at VWR^a).

Prior to cutting the tissue, lay back the mantle to locate the palps and gills, then replace the mantle to normal position. The first transverse cut is made where the palps and gills meet (see Fig. 3-49). For histological sections, a second cut is made 2-5 mm (depending on fixative used) toward the adductor muscle side of the initial cut. On very small specimens, this may be just above the adductor muscle. Scissors, razor blade, and stopper used for cutting should be thoroughly cleansed or flame-sterilized between oysters to avoid carryover contamination.

A confusing point may be the absence of the crystalline style. If oysters have not been kept in running seawater, the style rarely will be seen during processing. If visible, remove it since it will harden during fixation and cause problems when sectioning. According to Galtsoff (1964), "The crystalline style is not a permanent structure. In oysters removed from the water and left in the air the style dissolves in a short time."

When tissue is also desired for frozen sections, electron microscopy, or immunohistochemistry, the second cut will be made 1-2 mm toward the adductor muscle side of the initial cut and a third cut made 2-5 mm beyond the second to obtain a section for histology. Discard the portion below the last cut from each animal. See Chapter 4 for cryosection technique or Chapters 5 and 14 for fixing tissues for electron microscopy.

The anterior portion of tissue containing the palps can be placed in a correspondingly coded, 2-oz screw-top jar containing ambient seawater and used within 24 h for fresh squash examination (many parasites can be diagnosed by this method). The remaining 2- to 5-mm-thick cross-section with its identifying coded label is placed in an autopsy tray or tissue cassette (Fig. 3-56). The tray is immersed in a petri dish of seawater so the tissue will not dry out before fixing. When using cassettes, tissues may be fixed immediately.

The 1- to 2-mm section of tissue to be used for frozen sectioning is placed in a labeled petri dish with the just-cut surface facing up, and is sectioned as described in Chapter 4.

As each animal is processed, place tissues for histology in coded autopsy trays or cassettes, then in a jar of fixative, and process as appropriate for the fixative.

When processing nonindigenous oysters, care must be taken to avoid contaminating local waters with possible parasites or diseases from off-site areas. We recommend incinerating, autoclaving, or bleaching shells, equipment, and wastes associated with non-native species after processing is complete. When bleaching, adequate concentration and time must be used to penetrate and decontaminate tissues. Bushek et al. (1997) have raised questions on the efficacy of decontaminating with bleach.

When bleeding for histocytological examination, drill or notch oysters (see Fig. 3-49) the day prior to processing so the animals may purge any shell, sand, or mud introduced during drilling. Chapter 10 gives complete instructions for bleeding oysters to evaluate the blood—a quick diagnosis for the presence of both *Haplosporidium nelsoni* (MSX) and *Perkinsus marinus* (Dermo).

2. Clams (*Spisula*, *Mya*, *Macoma*, *Mercenaria*, *Arctica* spp.)

Hold clams in a chilled environment until ready for processing. Chilling retards the metabolic rate and renders the clams sluggish and relaxed.

If running ambient seawater tanks are available, local clams should be placed in tanks to purge the sand and debris from tissues. If the sand has not been successfully removed before the animal is fixed and embedded, it will be incorporated with the tissue and will present an obvious problem when sectioning. Sand will leave sawtooth nicks on the knife-edge, and is extremely destructive to the tissue as well, creating lines and torn ridges throughout the entire section. Broken chips of shell and pearls can cause similar problems, so wash the tissue well before making the cross-section.

Clams can be successfully opened with relative ease when the right equipment and techniques are employed. Species and size variation will dictate the appropriate technique.

a. Surf clams (*Spisula solidissima*)

These large clams have an extensive muscular foot that prevents tight shell closure, and can be easily shucked with a long, sharp, flexible knife such as a fillet knife. Beginning near the anterior adductor muscle, insert the knife behind the mantle next to the shell and sever the muscle. Work the knife around the edge of the shell and cut the posterior adductor muscle. The same manipulation is used on the bottom shell. Immerse the clam in a bucket of ambient seawater and wash well, since these animals

often contain much sand. Change the water frequently.

b. Softshell clams (*Mya arenaria*)

Figure 3-57 is provided to orient the technician to the anatomy of the softshell clam and where a cross-section is to be taken. Figure 3-58 illustrates tissues that would be present in a cross-section following these procedures. The figure also reflects a modification to include more gill tissue in the cross-section.

Softshell clams are measured longitudinally between the most anterior and posterior portions of the shell (Fig. 3-59). Use a disposable scalpel when opening this species. The shells are fragile and brittle, so a light grip is recommended. Insert the blade along the shell below the "snout" or siphon (Fig. 3-60). Position the knife just below the mantle next to the shell, and cut around shell to the hinge. Gently pry the shell open and cut the remaining tissue from the shell. The longer it takes to insert the blade into the clam, the tighter the clam will close its shell. Therefore, insert the blade and cut the muscle as quickly as possible. If clams are to be tested for *Perkinsus*, excise gill, labial palp, or rectal tissue (Fig. 3-61) and place into a marked tube containing thioglycolate medium (Fig. 3-62) (McLaughlin and Faisal 1999). Cut off the mantle and siphon (Fig. 3-63). Wash well before making a cross-section. Remove sand and grit by grasping the clam by the foot and dipping the body into ambient seawater with gills hanging downward. Place clam in palm of hand with gills extended toward fingers. Just above the labial palps, with small scissors carefully clip the connective tissue between the anterior portion of the gills and the visceral mass (Fig. 3-64). Lay the clam on a flat surface with gills properly positioned (Fig. 3-65). Continue clipping posteriorly along the attachment of the gills until approximately one-half of the gill tissue has been disconnected, but not completely severed, from the visceral mass (Fig. 3-66). Once again, grasp the clam's foot, dip the body into ambient seawater, and let the gills fall forward. Lay the clam on top of a rubber stopper with gills oriented anteriorly and make a single cut through the major body organs using a sharp scalpel (Figs. 3-67). Remove the crystalline style (Fig. 3-68). Place tissue section into an embedding cassette with the cut surface of the body facing down and the gills rearranged to extend posteriorly (Fig. 3-69). Clip the upper surface of the clam tissue if it is too thick to fit into the cassette. The artificial orientation of the gills improves access to major body organs, increases the amount of gill tissue in the section, and decreases the amount of reproductive tissue. Place cassette containing tissue into fixative (Fig. 3-70).

c. Baltic macoma clams (*Macoma balthica*)

These clams have paper-thin shells and are frequently damaged during collection. Disposable scalpels (available from VWR^a cat. # 25053-003) are recommended for opening these clams. The scalpel can easily be maneuvered into and around the shell (Fig. 3-71), separating the tissue (adductor muscles) from the shell without tissue damage. Wash clams in ambient seawater and evaluate for condition and notable abnormalities (Fig. 3-72). Locate and excise the rectum if thioglycolate cultures are requested (Figs. 3-73, 3-74). After making the cut for the cross-section, remove the crystalline style (Fig. 3-75), place tissue cross-section into cassette (Fig. 3-76), and process as usual.

d. Hard clams (*Mercenaria* and *Arctica* spp.)

The gross anatomy of the hard clam, with mantle tissue removed, is shown in Figure 3-77. The cross-section taken should include as many major organs as possible (see Fig. 3-78).

Clams with thick hard shells are the most challenging bivalves to open. First, measure from side to side (Fig. 3-79). A thin-blade clam knife works best for shucking hard clams. Holding clam in the palm of hand, use the broad sharp edge of the clam knife and insert between the valves near the siphon (Fig. 3-80). Use fingers to move the knife between the valves and cut the posterior adductor muscle. Work the knife around the inner edge of the shell to cut the anterior adductor muscle. Gently open clam, cut adductor muscles from top shell (Fig. 3-81), and carefully slide the knife along the edge of the shell to free the attached mantle. Use the same cutting action on the lower shell to free the clam (Fig. 3-82). Remove clam from shell and rinse well in ambient seawater. Evaluate for condition and notable abnormalities. If testing for *Perkinsus* (Fig. 3-83), locate and excise gill, palps, or rectum, then take a cross-section approximately 3- to 5-mm thick (Fig. 3-84). For a successful cut, a very sharp knife blade or large scalpel is needed (change blade frequently). Use a sawing motion with very light pressure of the blade to avoid displacing the soft tissue.

Large clams are difficult to cut uniformly. When the first cut is made, the clam retracts the muscular foot so tightly that it is hard to make a straight, *thin*, second cut. *Thinly* cut tissue sections are emphasized because the texture of the internal clam tissue is so soft that good fixative penetration is otherwise difficult to accomplish.

The crystalline style in the clam is generally severed as the cross-section is taken. Remove the style if present, careful not to damage the surrounding tissue. Depending on the clam species, the crystalline style may harden during the embedment process and cause problems when sectioning.

3. Mussels (*Mytilus* spp.)

Mussels from intertidal habitats often contain many organisms within the byssus threads surrounding the shell; therefore, initial processing begins with a thorough scrubbing to reduce the likelihood of transferring contaminating artifacts to tissues.

The gross anatomy of the mussel is shown in Figure 3-85. The cross-section taken should include as many major organs as possible (see Fig. 3-86). Measure each mussel from hinge to bill and record length (Fig. 3-87). To open the mussel, insert a scalpel (Fig. 3-88) into the ventral byssal cavity, cut posterior adductor muscle, and gently pry open and cut remaining muscles. Separate the mantle from the edge of the shell (Fig. 3-89). Carefully position the blade behind the mantle next to the shell, and cut in a clockwise motion around the bill to the hinge of the shell. Return the knife to the byssal cavity and, in the same fashion, cut to the top of the shell. The meat condition is recorded, along with any pertinent macroscopic information (Fig. 3-90). Wash the animal in ambient seawater and cut the byssus just into the byssal cavity tissue (Fig. 3-91). The mussel is then placed on a rubber stopper and a cross-section is taken (Fig. 3-92), making sure all gill and mantle tissues are in place before the cut is made.

4. Scallops (*Argopecten* and *Placopecten* spp.)

Scallops are relatively delicate animals and should be handled with care prior to processing. Their muscle system is weak and easily detaches from the shell. They tend to gape and dehydrate quickly when out of the water. They are usually collected by dredging, which leaves them full of sand and grit. Optimum treatment of these animals would be to immerse them in holding tanks of ambient seawater cooled to 10-15°C for 24 h to purge sand from tissues. If this is not possible, wrap them in seawater-soaked burlap or seaweed and keep cool and damp with ambient seawater until processing.

Figure 3-93 illustrates the gross anatomy of the scallop. If care is taken during processing, the organs seen in

Figure 3-94 will be included in the cross-section taken for examination.

Begin processing by measuring the shell from side to side (Fig. 3-95). Then, open with a scalpel on either side of the hinge. Once the hinge is "popped," the scalpel is gently slipped into and around the shell to cut the muscle from the upper shell (Fig. 3-96). After the upper shell is removed, cut the adductor muscle from the bottom shell (Fig. 3-97). Excise sensory eyes from the mantle if not required by the investigator (Fig. 3-98). The eyes can cause extensive problems and damage to the microtome knife blade when sectioning the tissue. Remove the scallop from its shell, wash thoroughly but carefully, since fine sand grains stick between the gill filaments (ambient synthetic seawater is used to wash animals, see p. 144). Locate and excise the rectum if testing for *Perkinsus* (Fig. 3-99). When taking the cross-section of the scallop as shown in Figure 3-100, the gills and mantle can easily detach from the animal and cause the tissues to orient incorrectly. For abnormally large specimens, divide the entire cross-section to fit into tissue cassettes.

5. Shellfish Larvae

Before fixation, place tiny larvae in lens paper or in Cell Safe tissue cassette inserts (available from Mercedes Medical[®] cat. # 15-1110) until embedment.

Most larvae are fixed in Davidson's fixative (see p. 61). The acetic acid aids in disintegrating the shell. Since the dissolved carbonate neutralizes the fixative, change the fixative frequently to maintain its effectiveness. Occasional agitation will enhance fixation. After the animals have been fixed, wash and place in a 10% versenate solution (disodium ethylene-diaminetetraacetate, EDTA) (Sanders 1972) to complete decalcification of the shells (see *Decalcification*, p. 184). The time required for complete decalcification will vary with size and species of animal. Change the versenate solution daily and check the sample at that time. Once the endpoint of decalcification is determined, wash the larvae well and place in 70% ethyl alcohol (ETOH) until embedment. Bivalve larvae are processed either by hand or mechanically with the tissue processor. If the larvae are processed by hand, the solutions are pipetted onto and off the larvae at designated times, using processing schedules compatible with the size of the animals (see p. 71). A vacuum oven is often used to speed larval dehydration and paraffin infiltration. After a 70% ETOH rinse, very small animals can be stained with a light solution of eosin to aid the technician in visually tracking them during the embedding process.

Juvenile bivalves, smaller than 40 mm, are generally shucked with a scalpel. Pry the hinge with a firm but light pressure to expose the adductor muscle which, when cut, will allow inspection of the specimen. Smaller shells tend to chip when opening; therefore, once shucked, the animals are completely immersed in ambient seawater to wash away any shell debris. Each animal is placed into a divided cassette or encircled by a correspondingly coded label, then carefully placed into an autopsy tray for fixation and later tissue processing. These very small animals may also be wrapped in lens paper and placed in coded tissue cassettes.

6. Blue Crabs (*Callinectes sapidus*)

Blue crabs have numerous parasites and disease conditions that are observed through histologic preparations. The scope of this subject is immense and this section can only touch on the subject. A good reference source is *Histology of the Blue Crab, Callinectes sapidus. A Model for the Decapoda* by Phyllis T. Johnson (1980).

In a fume hood, prepare implements and have containers of fixative ready for dissection. It is essential that dissected tissues be placed immediately in labeled cassettes flooded with fixative in a petri dish; keep the petri dish covered during dissection to prevent inhalation of fumes. To provide adequate penetration of the fixative, tissues should be less than 3-mm thick in at least one dimension.

The gross anatomy of the blue crab is shown in Figure 3-101. The first step to dissection is to anesthetize the crab by cooling to around 4°C. Once the crab is chilled, decrease hemolymph flow to tissues by removing as much hemolymph as possible (see Chapter 11). Measure the crab from point to point and note the sex and maturity when possible. Cut the dorsal carapace as shown in Figure 3-102, removing one point as shown in Figure 3-103. Remove a sample of hepatopancreas from the apex of the detached point (Fig. 3-103) and place in fixative. Using a probe, carefully sever the muscle attachments between the cardiac stomach and exoskeleton, keeping the epidermis intact. Remove eyestalks with scissors; make a longitudinal slit in the eyestalk cuticle to allow fixative to penetrate tissues.

Sever a gill (see Fig. 3-104) at the base and place the entire gill in the fixative. Remove the heart (see Fig. 3-104) and

place a portion in the fixative. Epidermis (thin, dark, pigmented tissue) and associated connective tissue overlie the cardiac stomach. Hemopoietic tissue is the translucent mass lying on the dorsal surface of the posterior half of the cardiac stomach (see Fig 3-104). Next, dissect a portion of the anterior midgut ceca, along with muscle and a portion of gonad. Remove and discard the cardiac stomach by carefully separating it from the esophagus, connective tissue, and muscle attachments.

After removing the cardiac stomach, the exposed brain (Fig. 3-105) lies centrally located on the anterior face of the exoskeleton just above the esophagus. Carefully remove connective tissue overlying the antennal gland which lies lateroventrally and next to the anterior face of the exoskeleton below the eyestalks. The organ should be teased loose and placed whole in fixative.

Hold the crab ventral side up and gently scrape out the remaining hepatopancreas, ovary, vas deferens, gut, and connective tissues. Dissect the thoracic ganglion (Fig. 3-105) that lies ventrally below and slightly anterior to where the heart was located. Dissect the posterior midgut cecum, a highly coiled mass lying dorsally, somewhat to one side, and posterior to the main body cavity. Portions of the bladder will be attached to the hemopoietic tissue, epidermis, or anterior midgut cecum. Testis and ovary may be included with the hepatopancreas. Additionally, the skeletal muscle, connective tissues, and blood vessels will be found in association with many of the tissues and organs.

C. Footnotes

^aVWR International, 405 Heron Drive, Bridgeport, NJ 08014. (800) 932-5000. www.vwr.com

^bMercedes Medical, Inc., 1435 Tallevasy Road, Sarasota, FL 34243. (800) 331-2716.

D. References

Anonymous. 1965. New parasite disease under study. U.S. Bur. Commer. Fish., Commer. Fish. Rev. 27(6): 44.

Bondad-Reantaso, M.G., S.E. McGladdery, I. East, and R.P. Subasinghe, Editors. 2001. *Asia Diagnostic Guide to Aquatic Animal Diseases*. FAO Fish. Tech. Pap. 402/2, 240 p.

- Boon, D.B. 1972. The red pigment in discolored oysters and soft-shelled clams from the Chesapeake Bay. *Chesapeake Sci.* 13: 334-335.
- Bushek, D., R. Holley, and M. Kelly. 1997. Treatment of *Perkinsus marinus*-contaminated materials. *J. Shellfish Res.* 16: 330 (abstract).
- Cheng, T.C. 1981. Hemocytes: forms and functions, pp. 299-333. In: V.S. Kennedy, R.I.E. Newell, and A.F. Eble (eds.), *The Eastern Oyster, Crassostrea virginica*. Publ. UM-SG-TS-96-01, Maryland Sea Grant College, College Park, MD.
- Farley, C.A. 1968. *Minchinia nelsoni* (Haplosporida) disease syndrome in the American oyster *Crassostrea virginica*. *J. Protozool.* 15: 585-599.
- Galtsoff, P.S. 1964. The American oyster *Crassostrea virginica* Gmelin. U.S. Fish Wildl. Serv., Fish. Bull. 64, 480 pp.
- Galtsoff, P.S. 1969. Anomalies and malformations in the shells of *Crassostrea virginica*, pp. 575-580. In: C.J. Dawe and J.C. Harshbarger (eds.), *Neoplasms and Related Disorders of Invertebrate and Lower Vertebrate Animals*. Natl. Cancer Inst. Monogr. 31.
- Johnson, P.T. 1980. *Histology of the Blue Crab, Callinectes sapidus: A Model for the Decapoda*. Praeger, New York. 440 p.
- Kinne, O., Editor. 1983. *Diseases of Marine Animals*. Vol. II, Introduction, Bivalvia to Scaphopoda. Biologische Anstalt Helgoland, Hamburg, FRG. 1038 p.
- Lewis, E.J. 2001. Juvenile oyster disease (JOD) and management strategies: a review. *Bull. Natl. Res. Inst. Aquacult., Suppl.* 5: 101-109.
- Lewis, E.J., C.A. Farley, E.B. Small, and A.M. Baya. 1996. A synopsis of juvenile oyster disease (JOD) experimental studies in *Crassostrea virginica*. *Aquat. Living Resour.* 9: 169-178.
- Lippson, A.J. and R.L. Lippson. 1997. *Life in the Chesapeake Bay*. 2d ed. Johns Hopkins Univ. Press, Baltimore, MD. 294 p.
- Mackin, J.G. 1962. Oyster disease caused by *Dermocystidium marinum* and other microorganisms in Louisiana. *Publ. Inst. Mar. Sci. Univ. Tex.* 7: 132-229.
- McCormack, G. 1956. Growth characteristics of the pink yeast that causes discoloration of oysters. *U.S. Bur. Commer. Fish., Commer. Fish. Rev.* 18(11): 21-23.
- McLaughlin, S.M. and M. Faisal. 1999. A comparison of diagnostic assays for detection of *Perkinsus* spp. in the softshell clam *Mya arenaria*. *Aquaculture* 172: 197-204.
- Ossiander, F.J. and G. Wedemeyer. 1973. Computer program for sample sizes required to determine disease incidence in fish populations. *J. Fish. Res. Board Can.* 30: 1383-1384.
- Paparella, M., Editor. 1973. Red oysters, pp. 2-3. In: *Information Tips*. Univ. Maryland Marine Products Lab., Crisfield, MD.
- Pyle, R.W. and L.E. Cronin. 1950. The general anatomy of the blue crab *Callinectes sapidus* Rathbun. Publ. 87, Chesapeake Biological Lab., Solomons, MD. 40 pp.
- Ray, S.M. 1952. A culture technique for the diagnosis of infections with *Dermocystidium marinum* Mackin, Owen, and Collier in oysters. *Science* 116: 360-361.
- Sanders, B.J. 1972. *Animal Histology Procedures of the Pathological Technology Section of the National Cancer Institute*. DHEW Publ. No. 72-275, National Institutes of Health, Bethesda, MD. 185 p.
- Steinberg, P.D. and V.S. Kennedy. 1979. Predation upon *Crassostrea virginica* (Gmelin) larvae by two invertebrate species common to Chesapeake Bay oyster bars. *Veliger* 22: 78-84.
- Tubiash, H.S., S.V. Otto, and R. Hugh. 1971. Cardiac vibriosis, an infection of the American oyster, *Crassostrea virginica*. *Bacteriol. Proc.*, p. 47.
- USDI (U.S. Department of the Interior). 1970. Black oyster found. News release, Fish Wildl. Serv., Bur. Commer. Fish., p. 2.
- White, M.E. and E.A. Wilson. 1996. Predators, pests, and competitors, pp. 559-579. In: V.S. Kennedy, R.I.E. Newell, and A.F. Eble (eds.), *The Eastern Oyster, Crassostrea virginica*. Publ. UM-SG-TS-96-01, Maryland Sea Grant College, College Park, MD.

Figure 3-1.

Shell checks (arrows) of JOD-infected oysters *Crassostrea virginica*. Left valve (bottom, curved side of oyster).

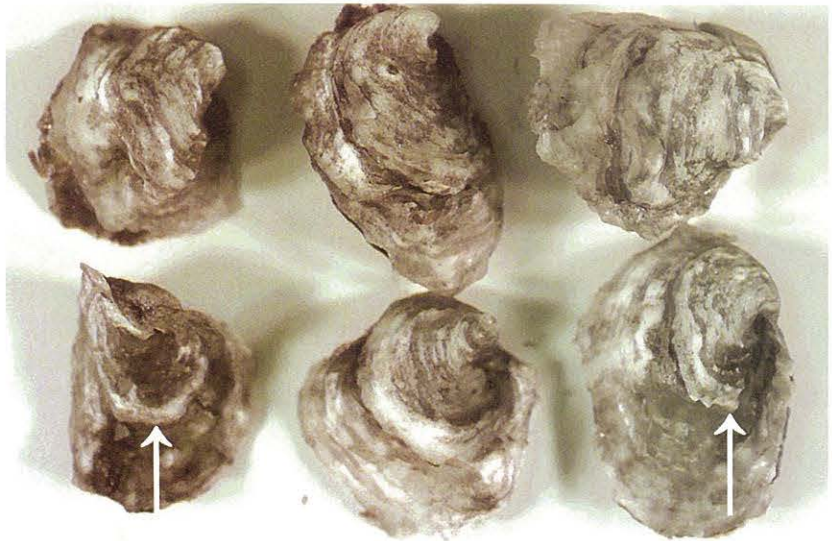


Figure 3-2.

Shell checks (arrows) of JOD-infected oysters *C. virginica*. Right valve (top, flat side of oyster).




Figure 3-3.

Oyster *C. virginica* displaying an active case of mantle recession/retraction (arrows).

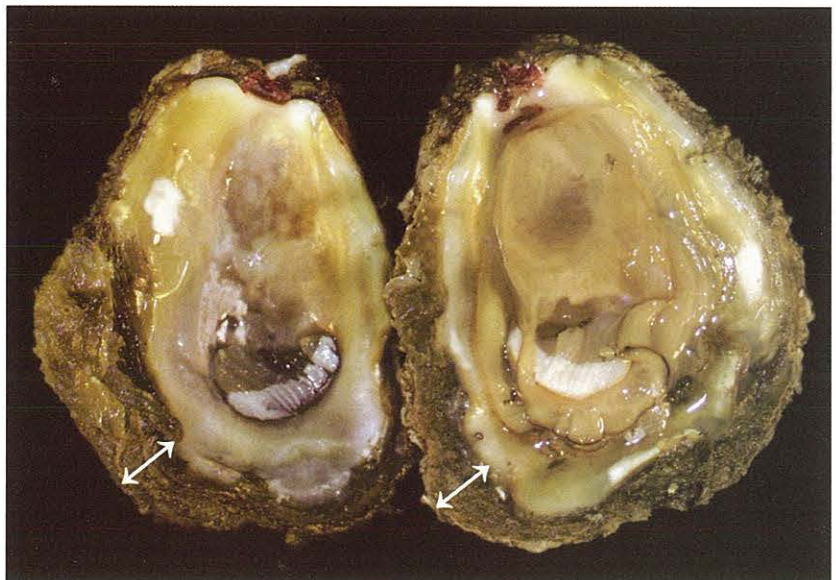


Figure 3-4.

Oyster shell of *C. virginica* showing recovery from mantle recession/retraction (arrows). (Specimen courtesy of C.A. Farley, NOAA, Oxford, MD.)

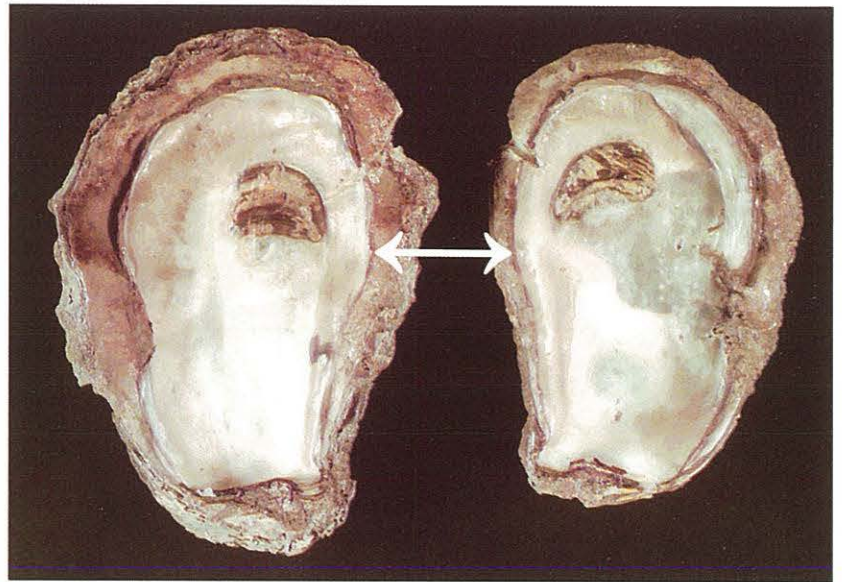


Figure 3-5a.

Live *Cliona* sp. infection (arrow) visible on external shell of oyster *C. virginica*.

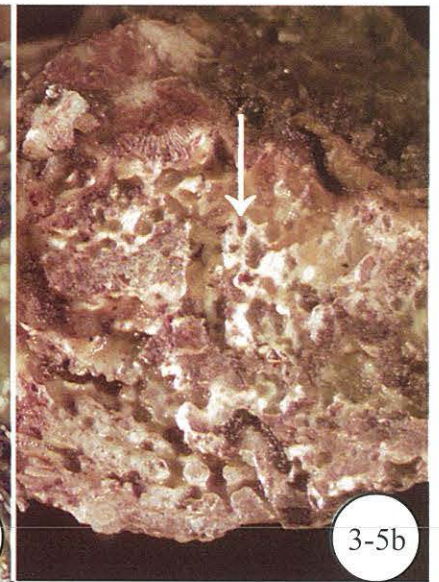
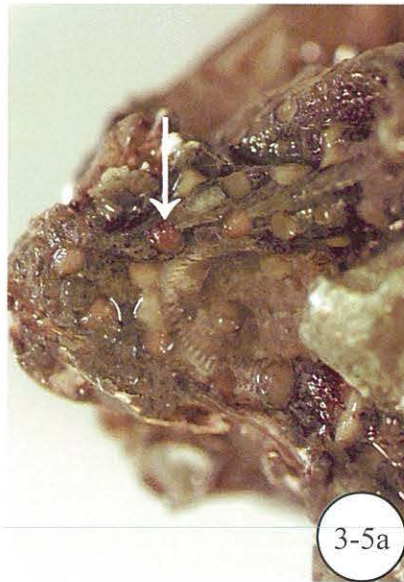
Figure 3-5b.

Oyster shell of *C. virginica* riddled with live *Cliona* sp. (arrow).

Figure 3-6.

Boring holes in shell of oyster *C. virginica* from previous infection by *Cliona* sp.

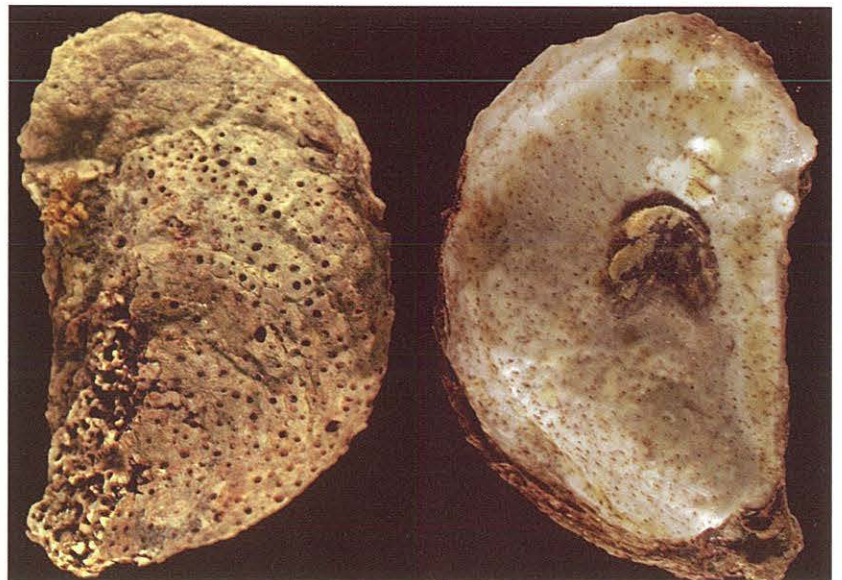


Figure 3-7a.

Boring clams *Diplothyra smithii* (arrows) found on shell of oyster *C. virginica* from high salinity waters.

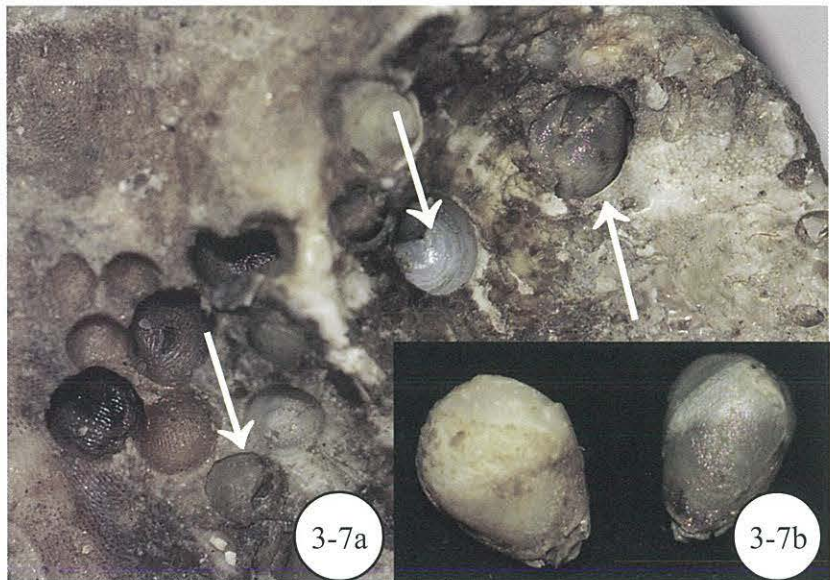


Figure 3-7b.

Clams *D. smithii* removed from shell of oyster *C. virginica*.

Figure 3-8.

Oyster *C. virginica* with *Polydora* sp. (mud worm) tunnels on inner surface of valve (arrow). Light intensity.

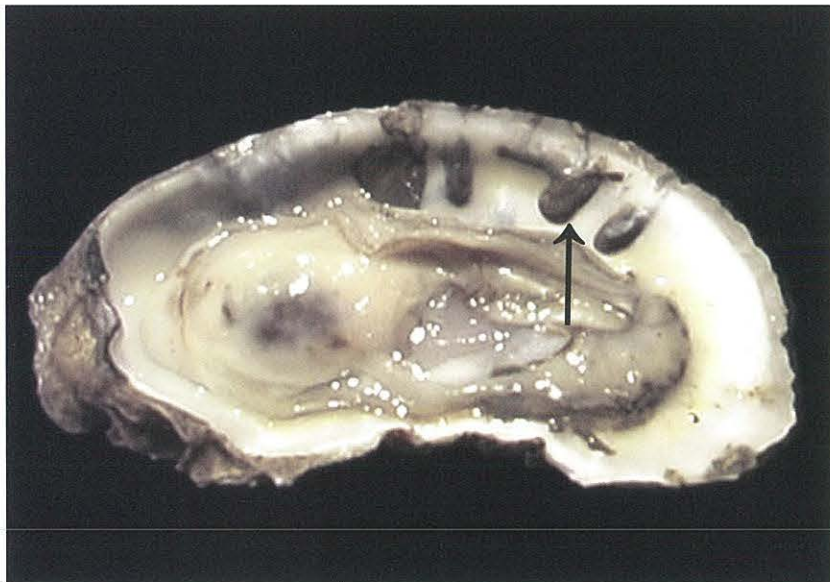

Figure 3-9.

Moderate intensity (arrow) of *Polydora* sp. (mud worm) tunnels on inner shell surface of oyster *C. virginica*.

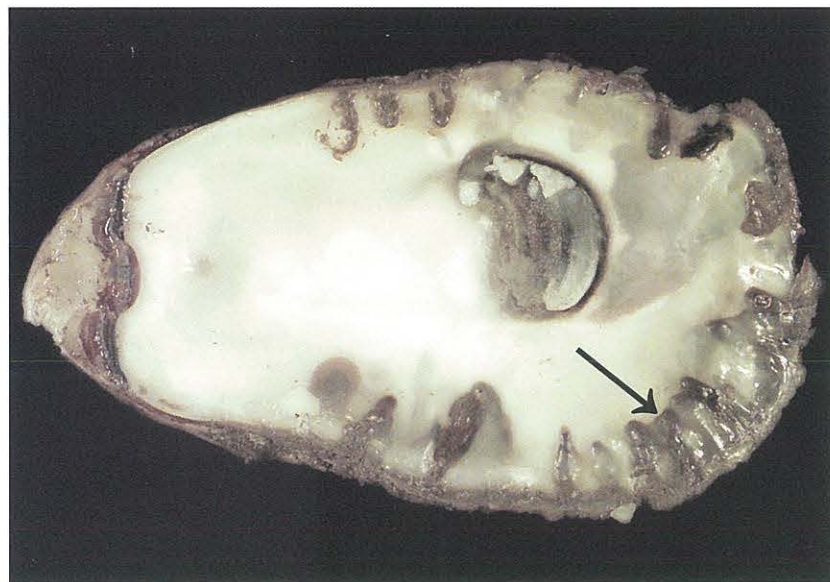


Figure 3-10.

“Maladie du pied” (arrow) covering much of muscle scar on inner shell surface of oyster *C. virginica*. (Specimen courtesy of S.V. Otto, Maryland Dept. Natural Resources, Oxford, MD.)



Figure 3-11.

Blisters (arrow) on inner shell surfaces of oyster *C. virginica*. (Specimen courtesy of C.A. Farley, NOAA, Oxford, MD.)

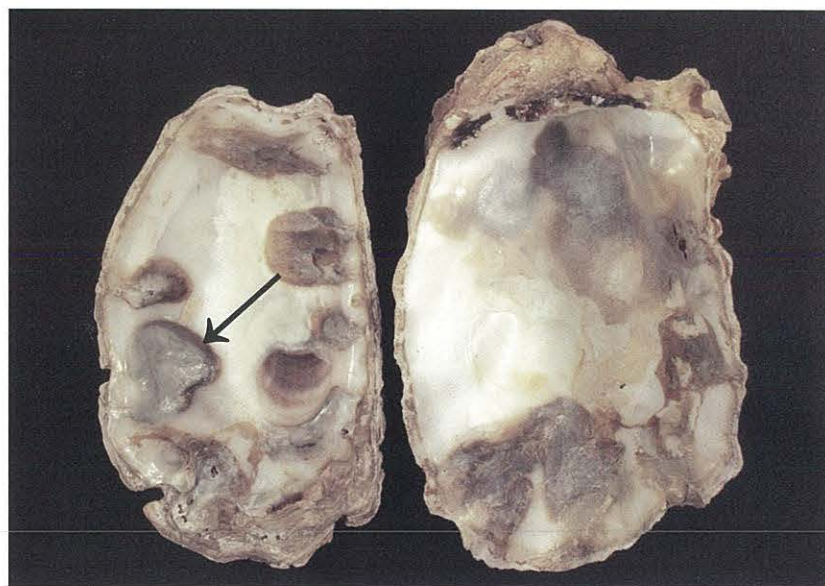


Figure 3-12.

Mud blister (arrow) on inner shell surface under oyster *C. virginica*.

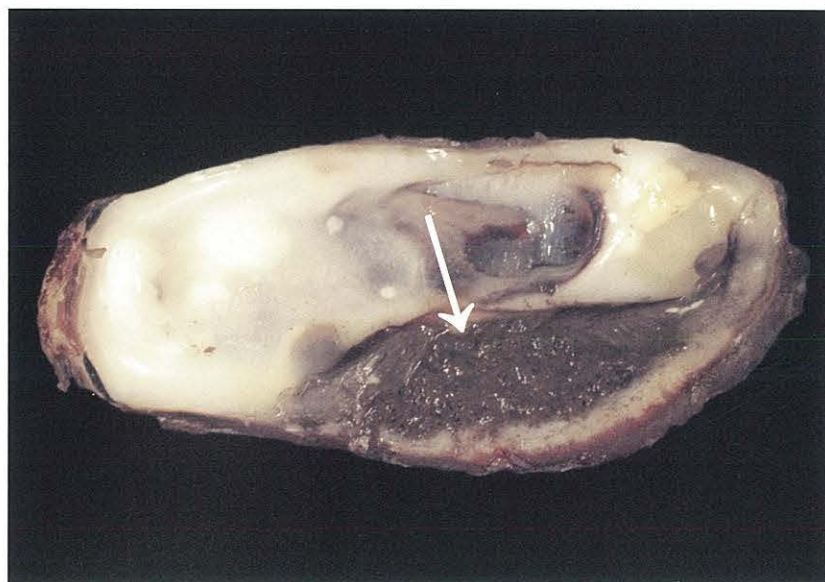

Figure 3-13.

Fresh shell pustules (arrows) on inner valve surfaces of oyster *C. virginica*. (Specimen courtesy of S.V. Otto, Maryland Dept. Natural Resources, Oxford, MD.)

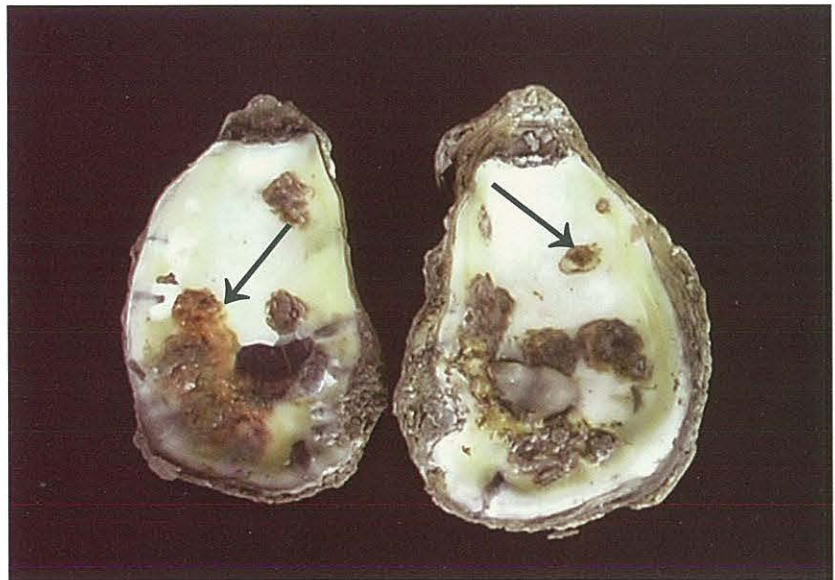


Figure 3-14.

Dry shell pustules (arrows) on inner valve surfaces of oyster *C. virginica*. (Specimen courtesy of C.A. Farley, NOAA, Oxford, MD.)

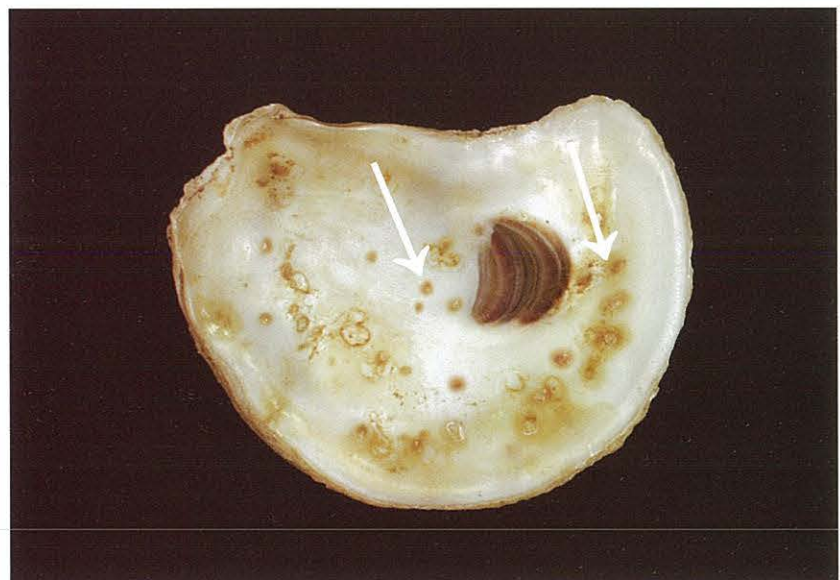

Figure 3-15.

Calcareous malformation (arrow) on inner shell of oyster *C. virginica*. (Specimen courtesy of C.A. Farley, NOAA, Oxford, MD.)

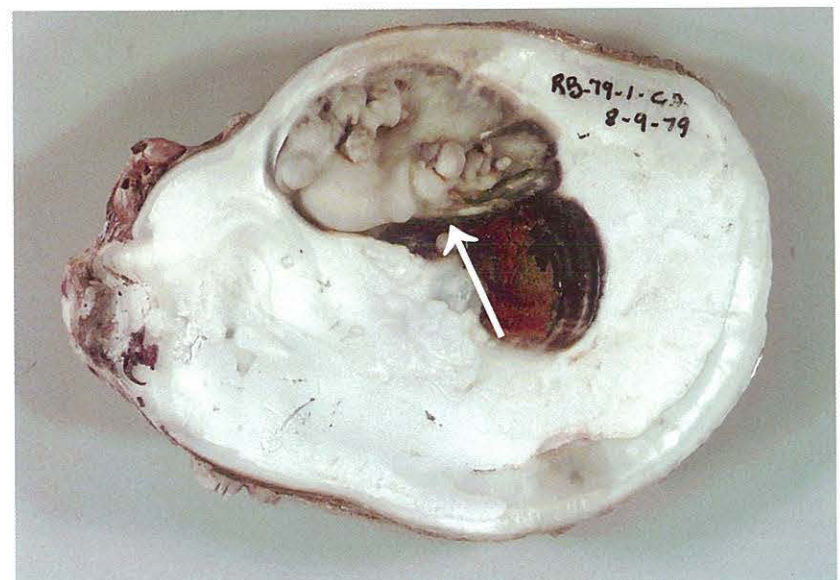


Figure 3-16.
Conchiolin deposits (arrows) on inner valve surfaces of adult oyster *C. virginica*.

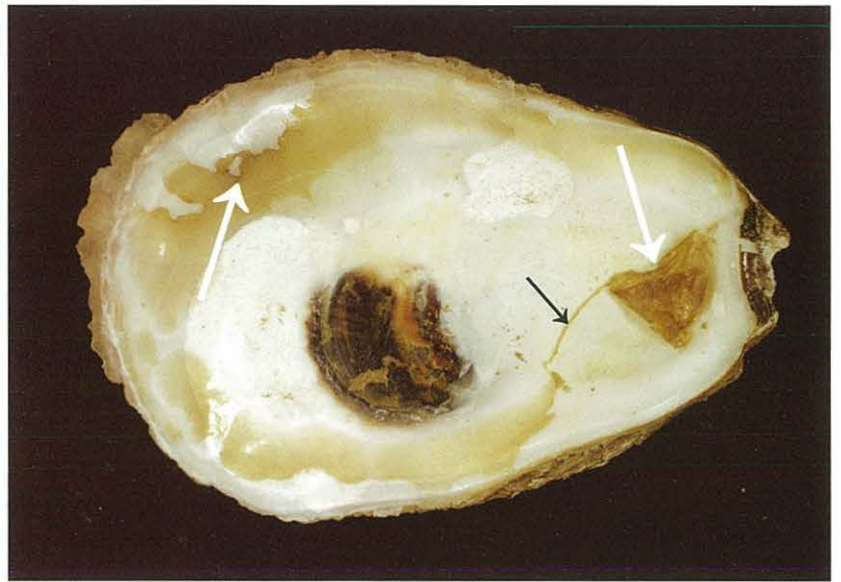


Figure 3-17.
JOD-infected oysters. Inner shells of juvenile oysters *C. virginica* with characteristic coating of conchiolin (arrows).

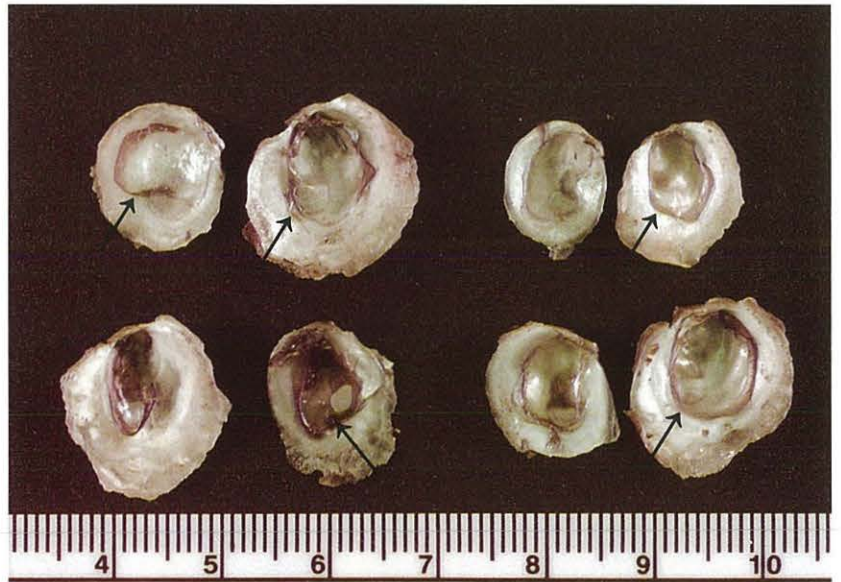


Figure 3-18a.
Drill egg cases (arrow) on shell of oyster *C. virginica*.

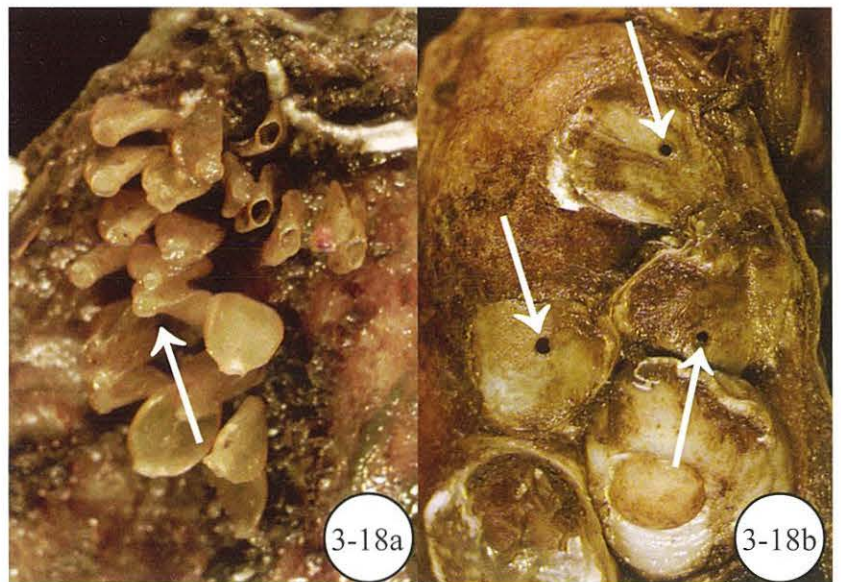


Figure 3-18b.
Drill holes (arrows) in spat of oyster *C. virginica*.

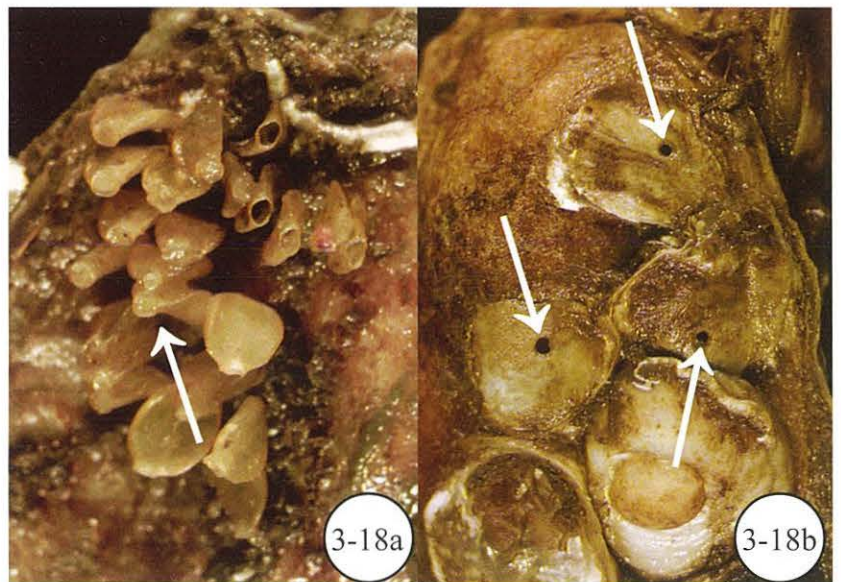


Figure 3-19.

Barnacles and hooked mussels on oyster *C. virginica*.

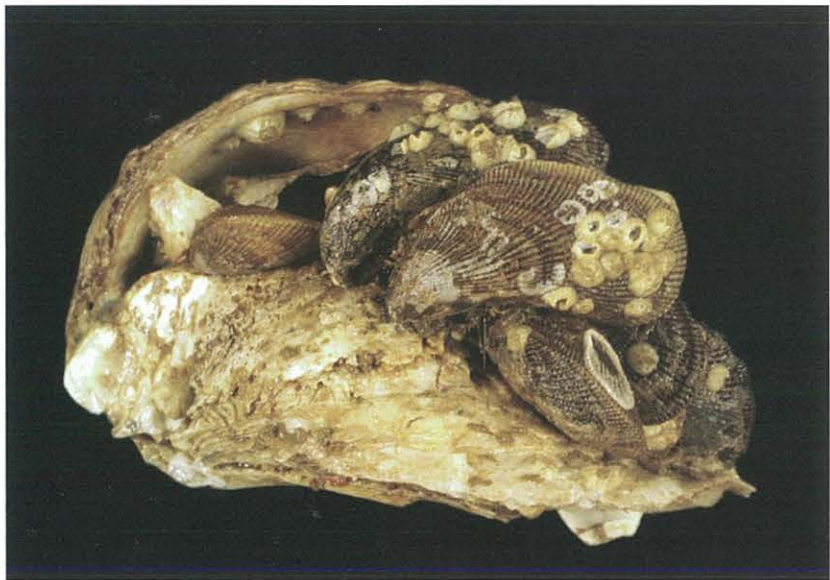

Figure 3-20.

Molgula sp. on oyster *C. virginica*.

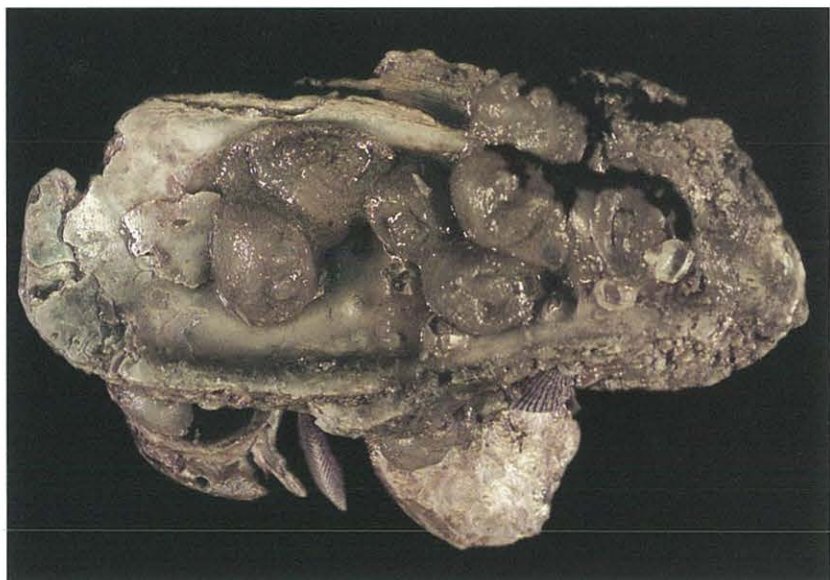

Figure 3-21a.

Anemones (arrows) and hooked mussels *Ischadium recurvum* on shells of oyster *C. virginica* as they appear out of the water.



Figure 3-21b.

Undisturbed anemone as it appears in the water. (Specimen courtesy of Dr. D. Meritt, Univ. Maryland Horn Point Lab., Cambridge, MD.)



Figure 3-22a.

Encrusting bryozoan (arrows) on shell of oyster *C. virginica*.



Figure 3-22b.

Calcareous worm tubes (arrows) encrusting surface of oyster shell *C. virginica*.

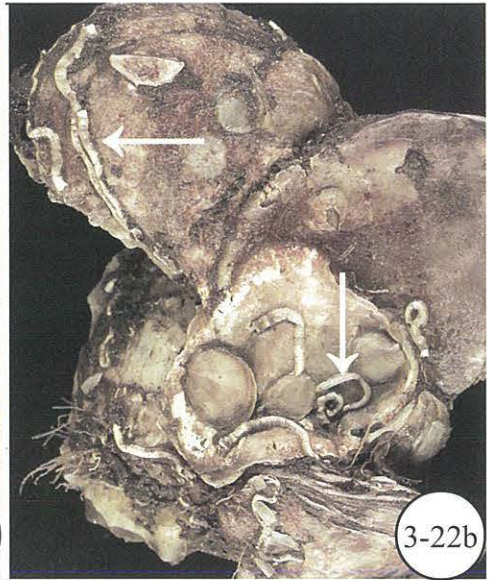


Figure 3-23.

Slipper shells *Crepidula fornicata* (arrows) on shell of oyster *C. virginica*.

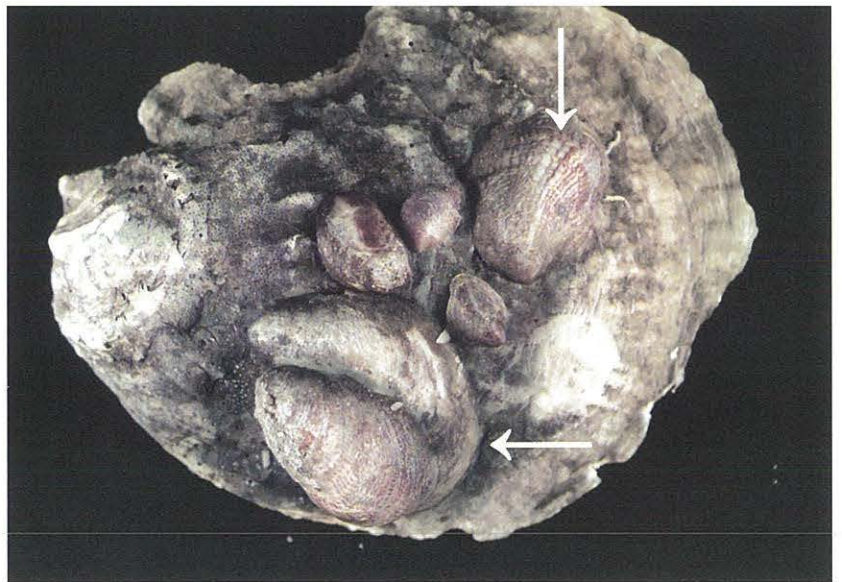


Figure 3-24.

Sponge covering inner shell surface of dead oyster *C. virginica*.

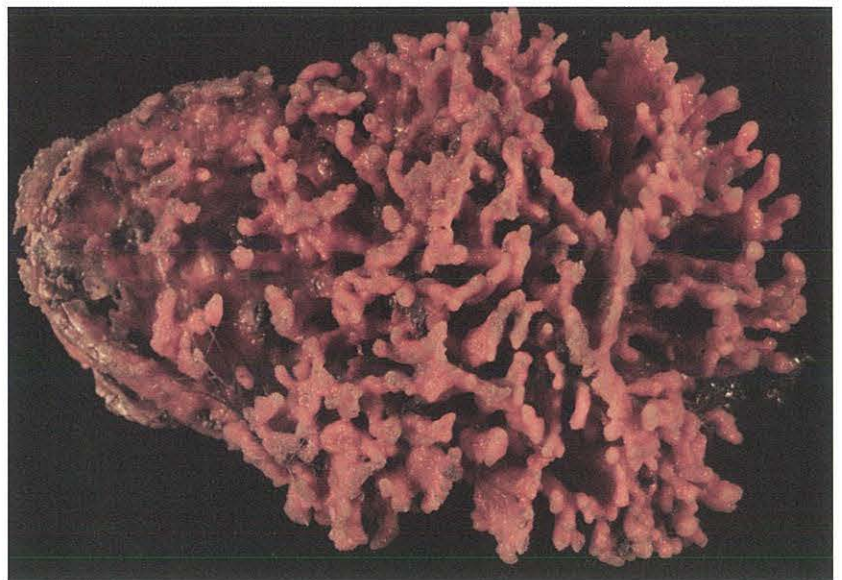


Figure 3-25.

Pinnotheres sp. (see inset) in gill area of oyster *C. virginica*.

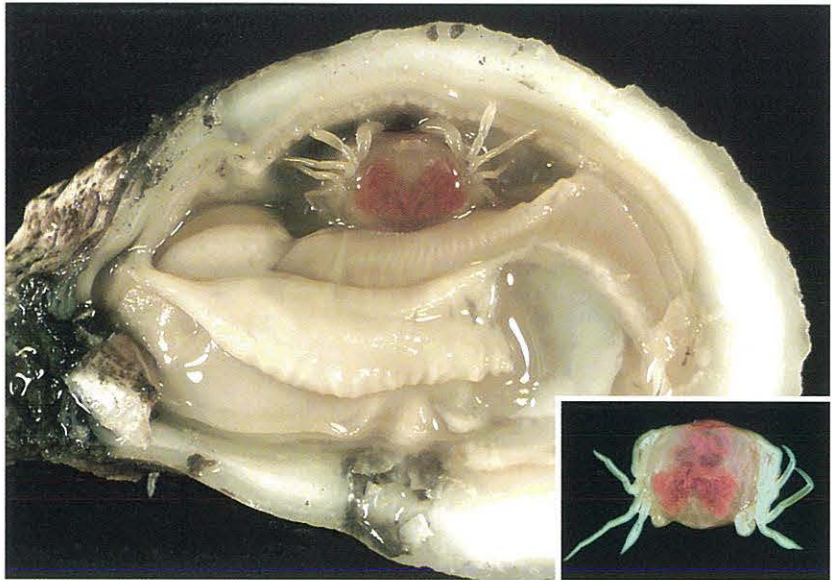


Figure 3-26.

Copepod *Mytilicola* sp. (see inset) in gut (arrow) of clam *Macoma balthica*.

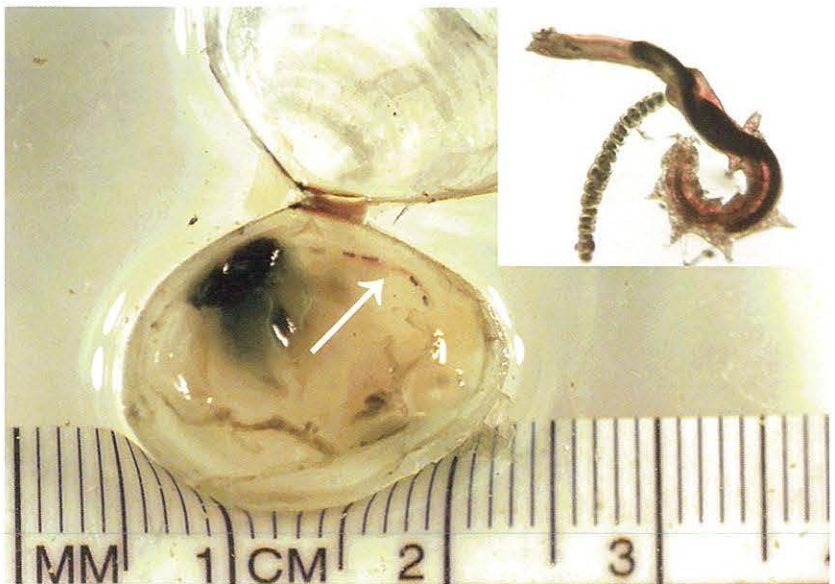

Figure 3-27.

Encysted rhynchodid ciliates *Hypocomella* sp. (= *Sphenophrya* sp.) forming xenomas (arrow) in gills of oyster *C. virginica*. (Photo courtesy of C.A. Farley, NOAA, Oxford, MD.)

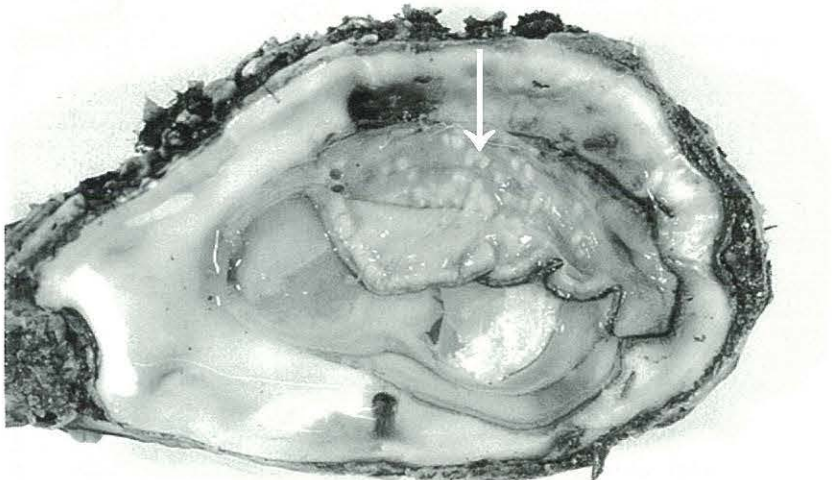


Figure 3-28.

Physiological condition of oyster *C. virginica*. Fat condition.

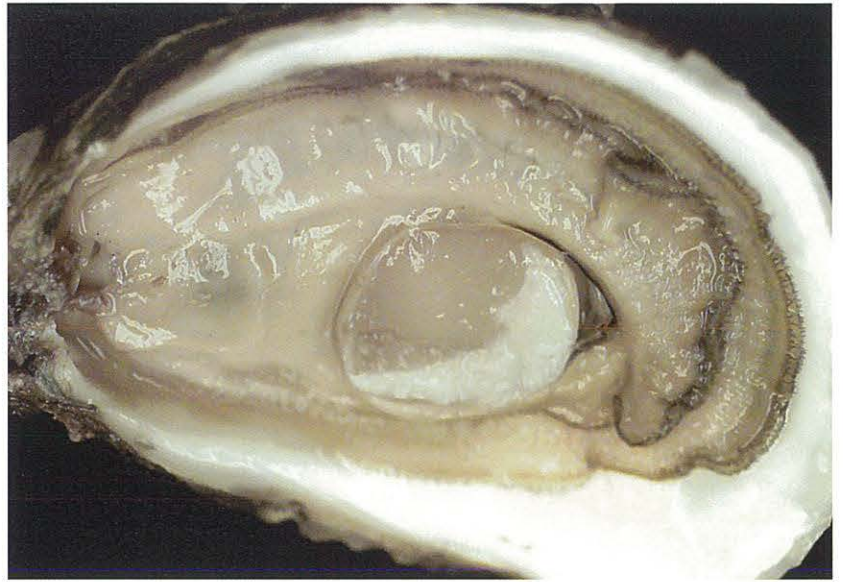

Figure 3-29.

Physiological condition of oyster *C. virginica*. Medium condition.

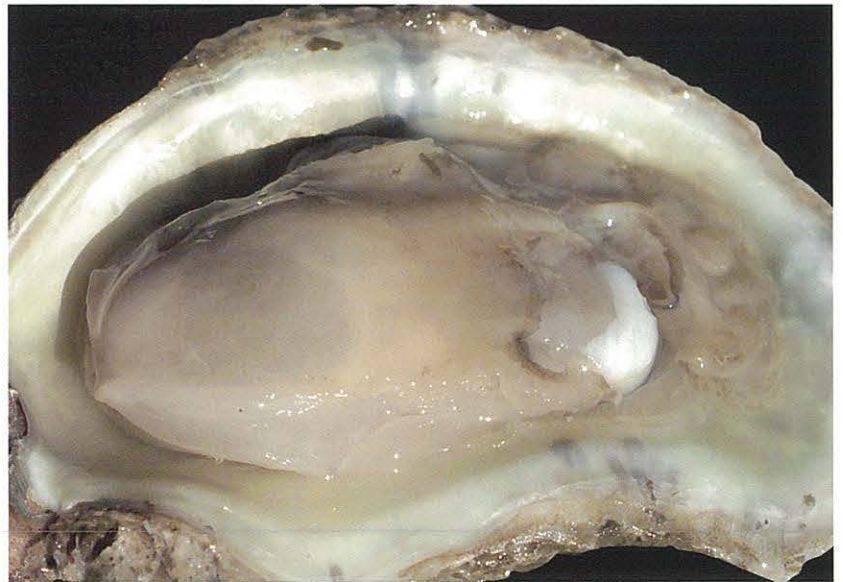

Figure 3-30.

Physiological condition of oyster *C. virginica*. Watery condition.

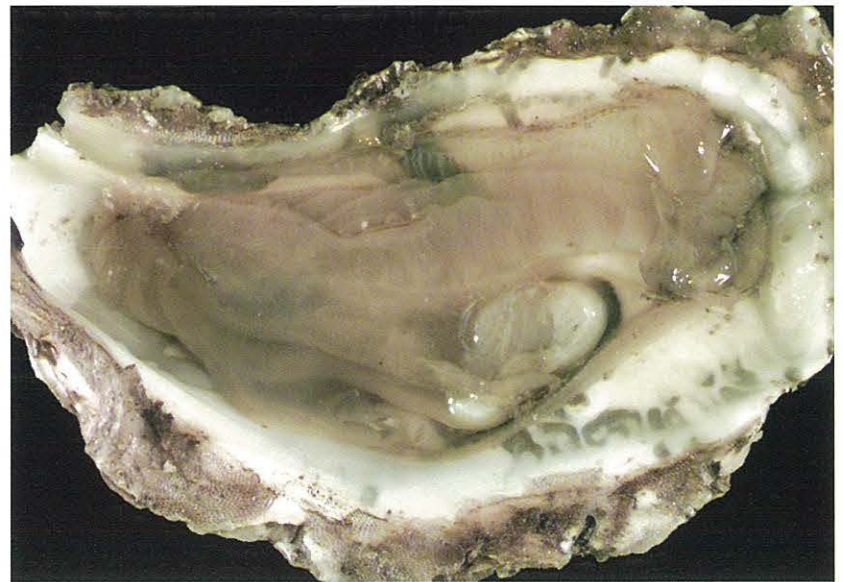

Figure 3-31.

Pale digestive diverticulum (left arrow) compared to normal diverticulum (right arrow) in cross-section of oyster *C. virginica*.

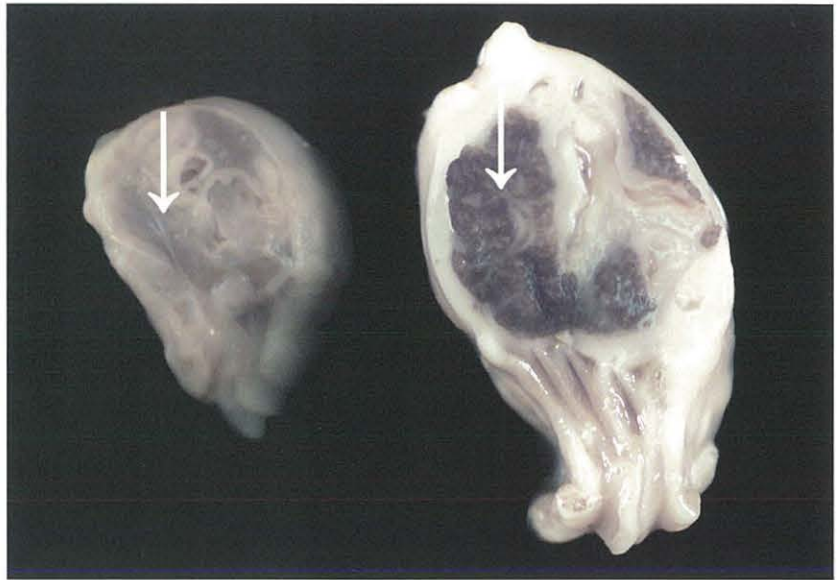

Figure 3-32.

Swollen mantle tissue (edema) of oyster *C. virginica*.

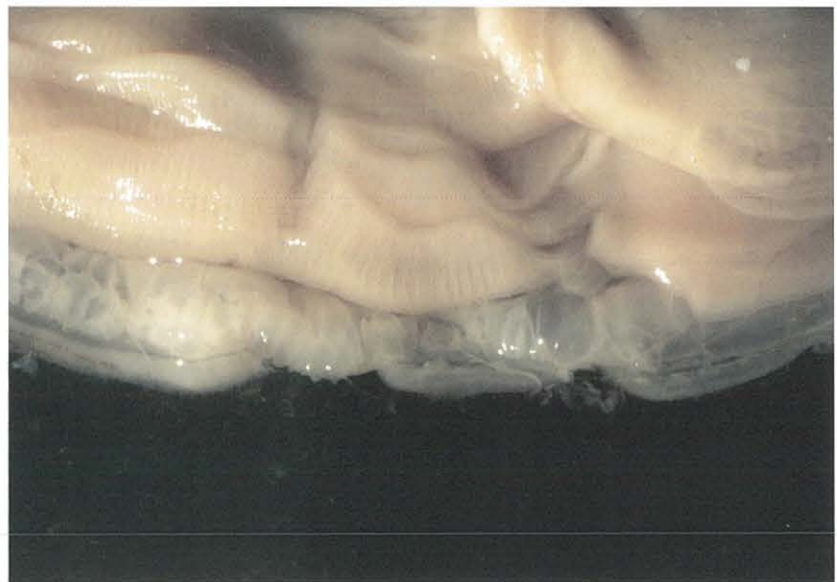


Figure 3-33a.

Obvious gonad (arrow) in soft clam *Mya arenaria*.



Figure 3-33b.

Obvious gonad in cross-section (arrow) of oyster *C. virginica*.

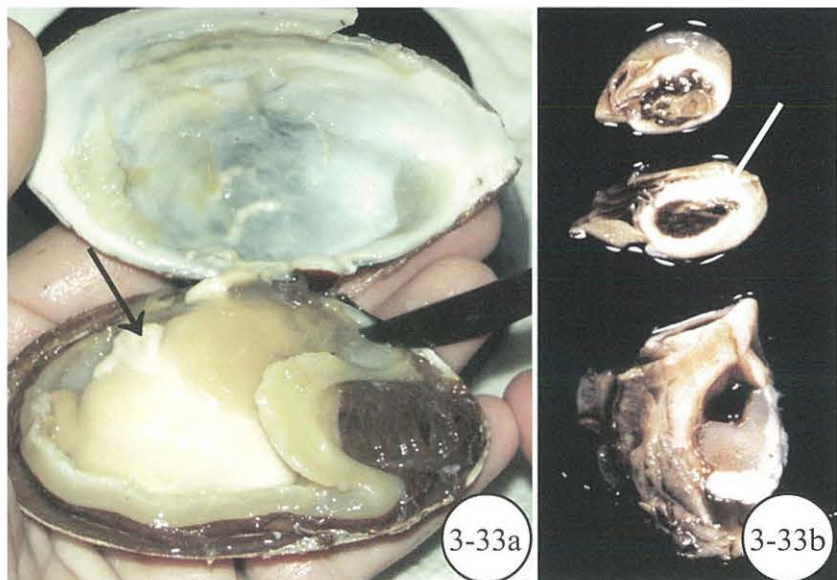


Figure 3-34.

Gill erosion (arrows) in oyster *C. virginica*, commonly observed in the presence of *Pinnotheres* sp.

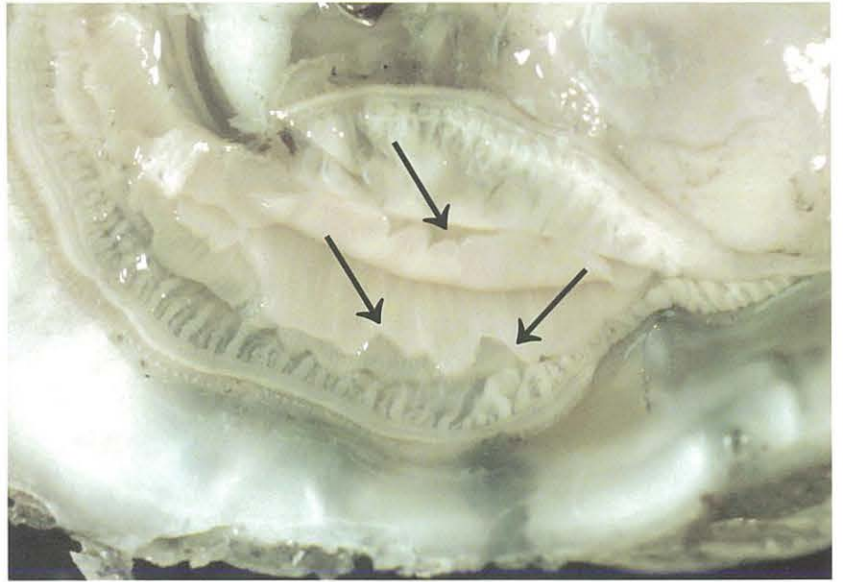


Figure 3-35.

Dirty gills in oyster *C. virginica*.

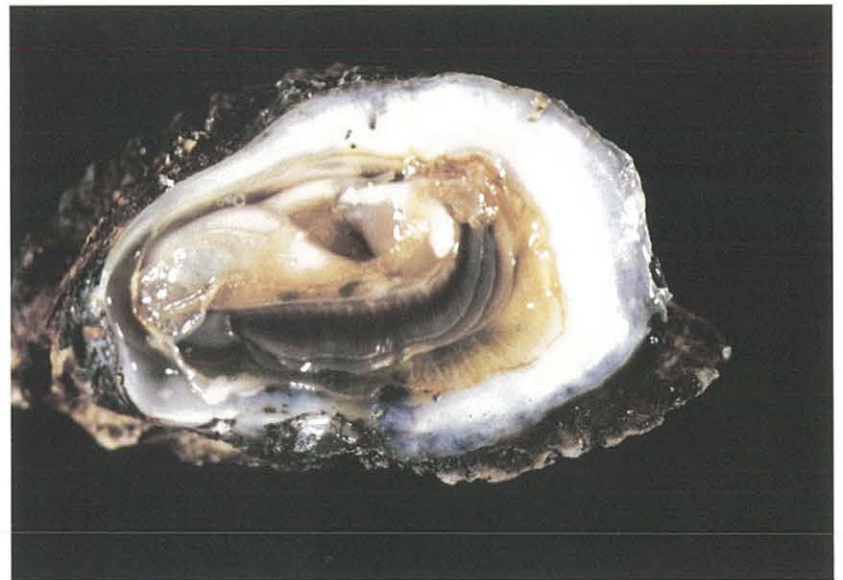

Figure 3-36.

Copper (blue-green pigmentation) in oyster *C. virginica* from Stony Brook Harbor, NY. (Specimen courtesy of K. McShane, Smithtown, NY.)

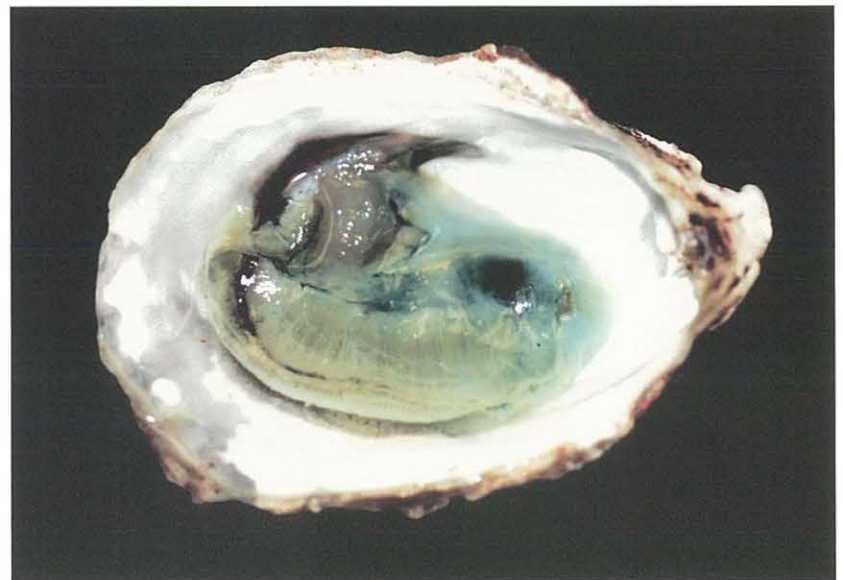

Figure 3-37.

Melanin (black) pigmentation in mantle of oyster *C. virginica* (left). Oyster on right shows normal mantle pigmentation.

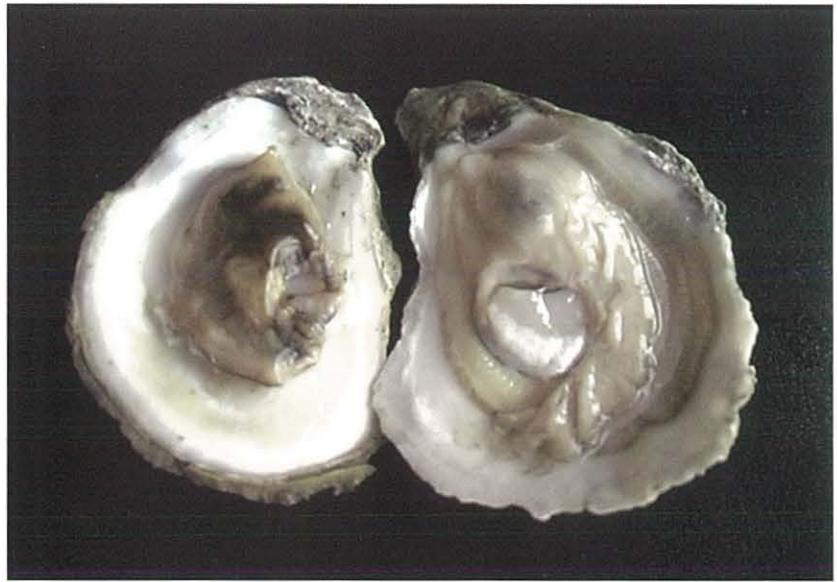

Figure 3-38.

Yellow to green coloration (arrow) due to diapedesis in oyster *C. virginica*.

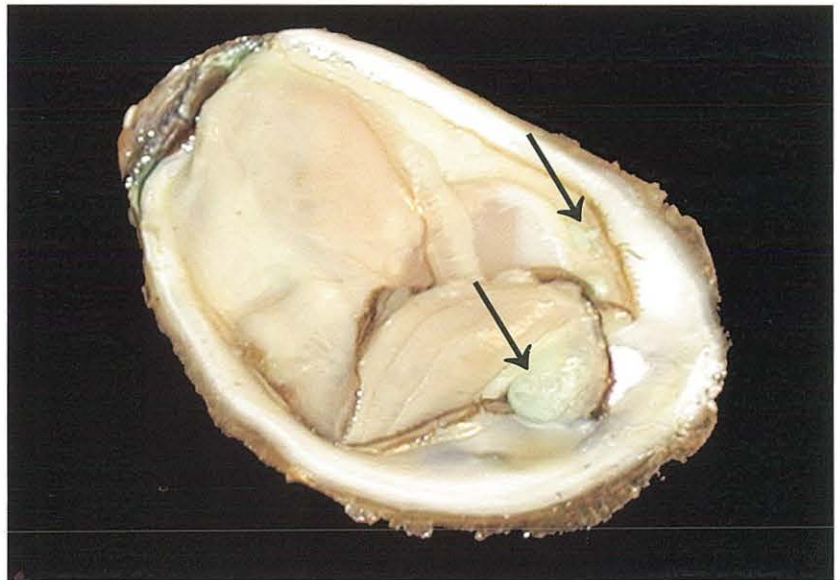


Figure 3-39.

New growth of shell (arrow) in oyster *C. virginica*. Note that new growth is pliable and easily breaks off. (Specimen courtesy of Dr. D. Meritt, Univ. Maryland Horn Point Lab., Cambridge, MD.)

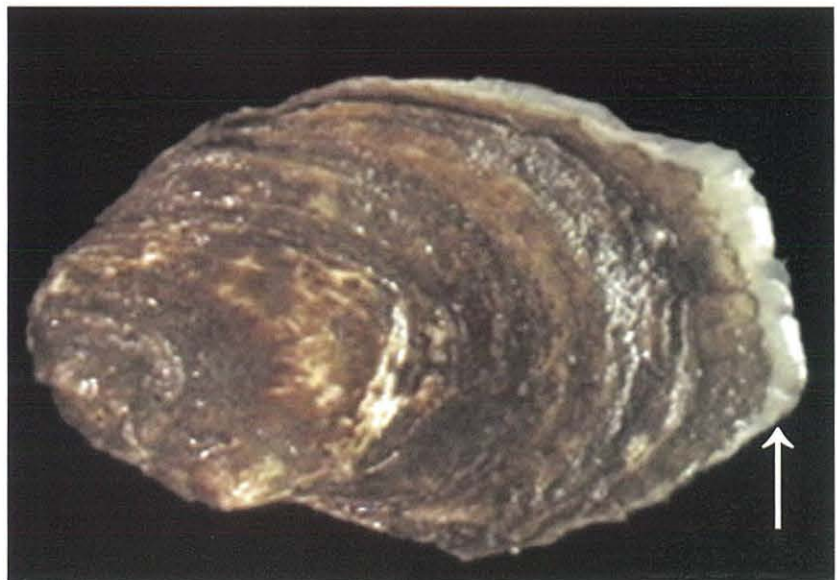

Figure 3-40.
Watery cyst (arrow) in oyster *C. virginica*.

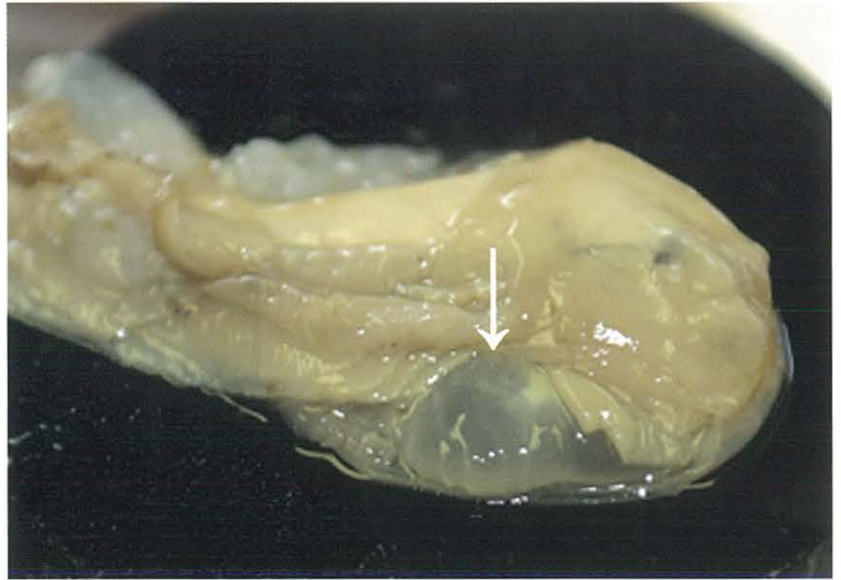

Figure 3-41a.
Abscess (arrow) in mantle of oyster *C. virginica*.

Figure 3-41b (inset).
Abscess (arrow) on edge of adductor muscle in oyster *C. virginica*.

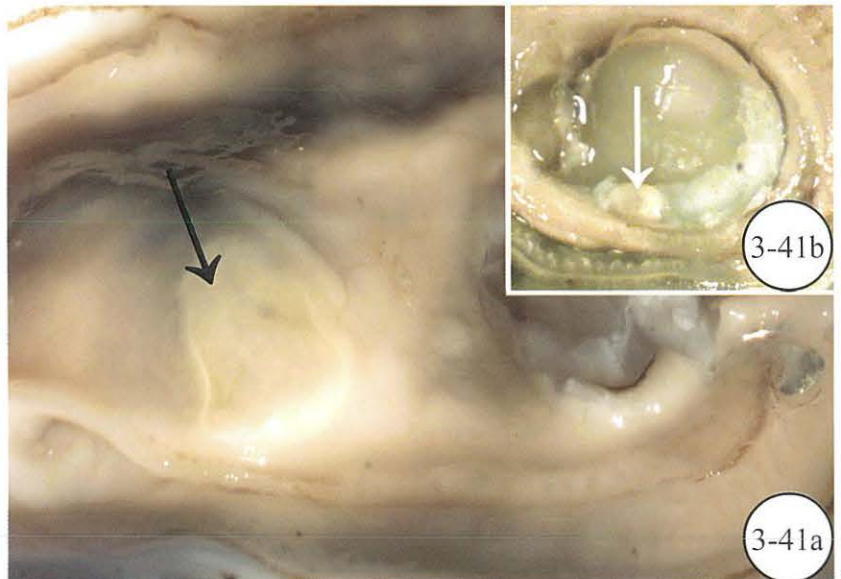


Figure 3-42a.
Pearls (arrow) in mantle of mussel *Mytilus edulis*.

Figure 3-42b.
Pearl (arrow) in mantle of scallop *Argopecten irradians*. (Specimen courtesy of G. Rivara, Cornell Cooperative Extension, Southold, NY.)

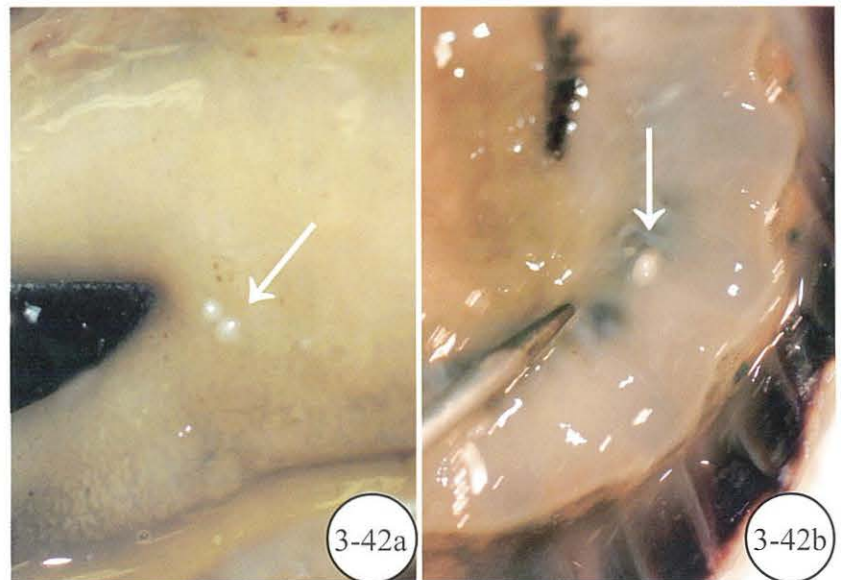


Figure 3-43a.

Blue crab *Callinectes sapidus*.

Figure 3-43b (inset).

Crab damage to oyster shell resulting in death of oyster.




Figure 3-44.

Mud crab *Rhithropanopeus harrisii*.
(Photo courtesy of C.A. Farley, NOAA, Oxford, MD.)



Figure 3-45.

Toadfish *Opsanus tau*. (Photo courtesy of C.A. Farley, NOAA, Oxford, MD.)



Figure 3-46.

Oyster drill *Urosalpinx cinerea*. (Specimen courtesy of G. Rivara, Cornell Cooperative Extension, Southold, NY.)

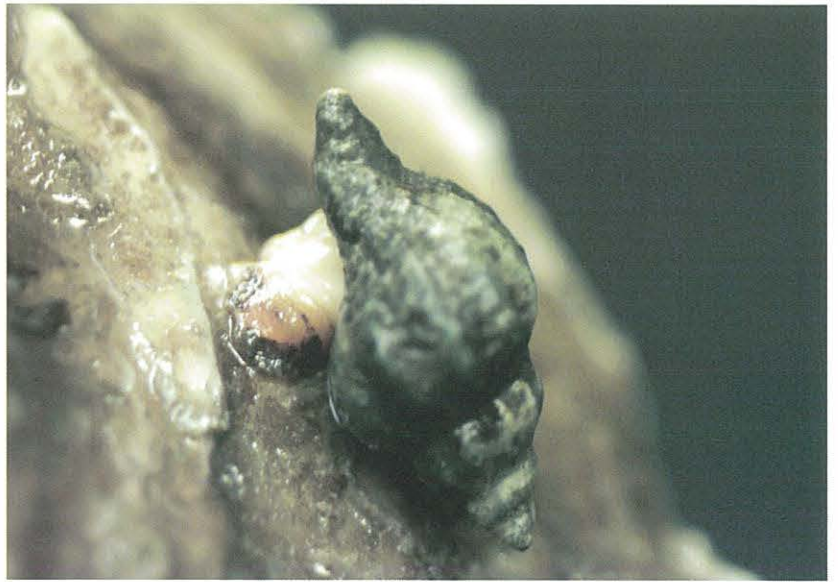

Figure 3-47.

Flatworm *Stylochus ellipticus* (arrow). (Specimen courtesy of Dr. D. Meritt, Univ. Maryland Horn Point Lab., Cambridge, MD.)

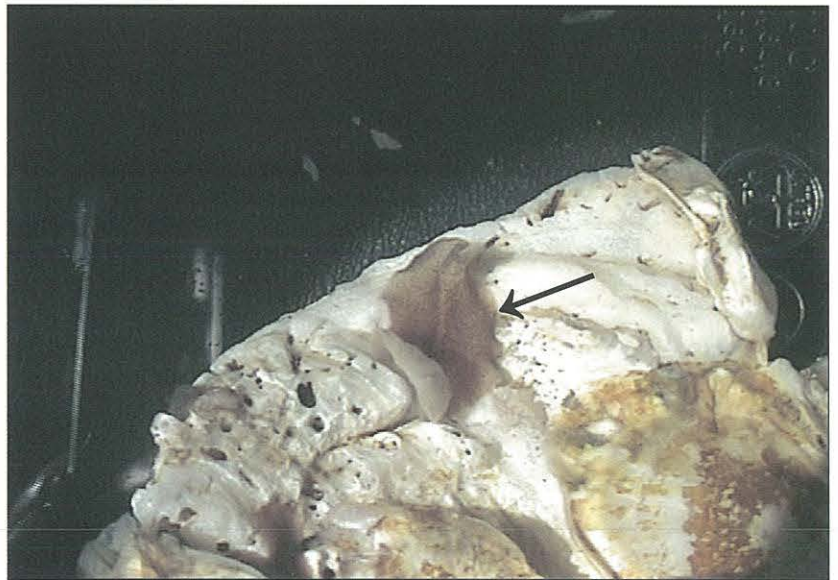


Figure 3-48.

Starfish *Asterias forbesi* on bay scallop *Argopecten irradians*. (Specimen courtesy of G. Rivara, Cornell Cooperative Extension, Southold, NY.)



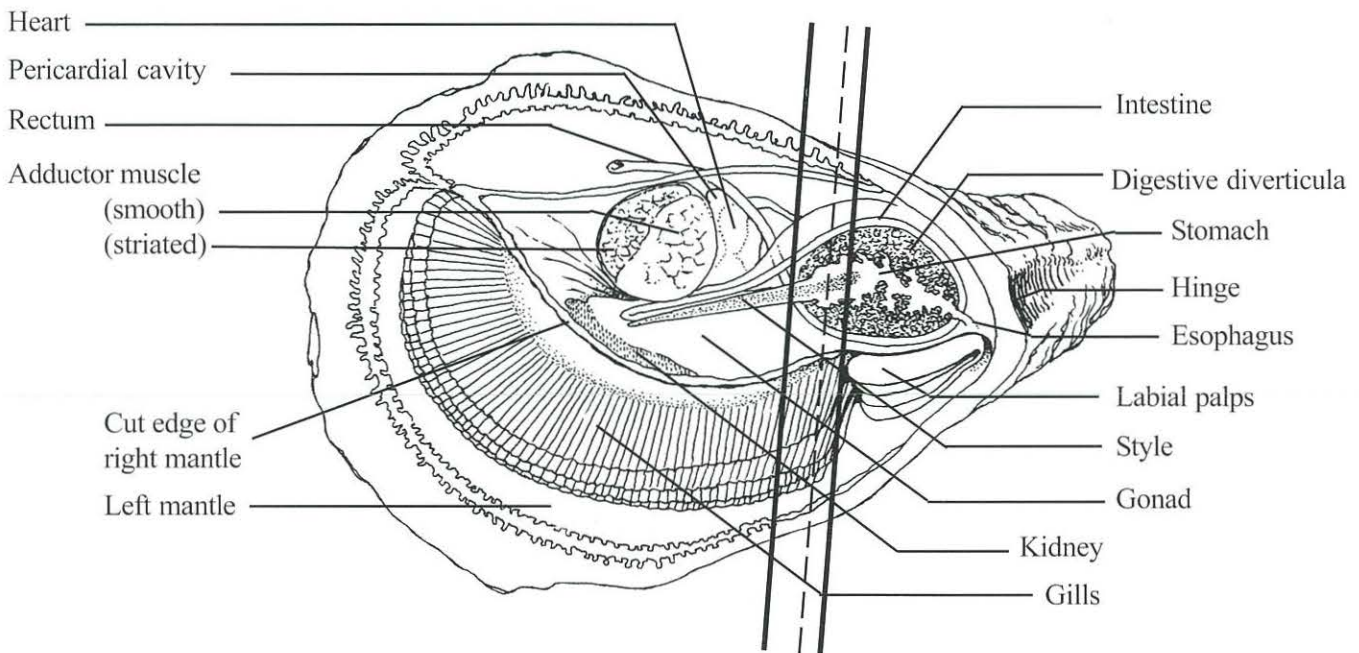
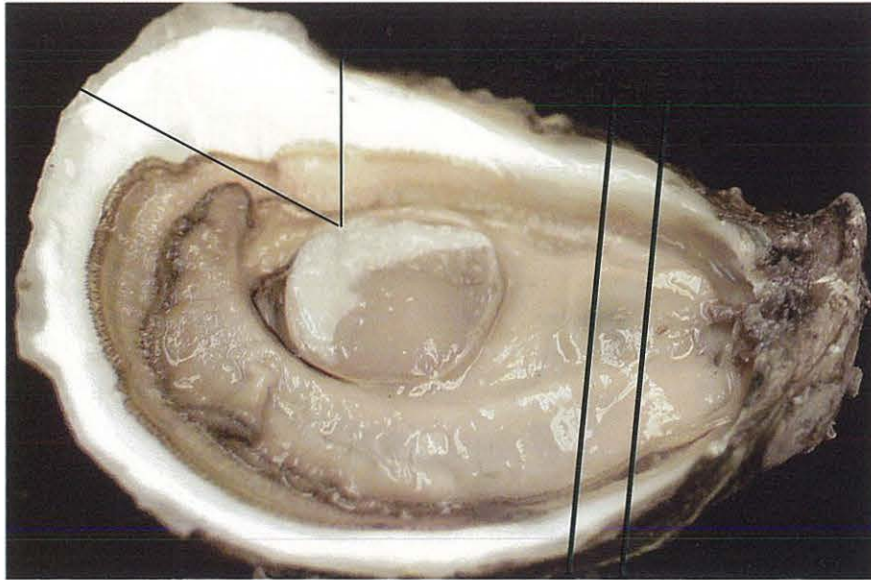


Figure 3-49.

Gross anatomy of oyster *Crassostrea virginica*.

Thin V-shaped lines in top micrograph indicate area to drill or notch for bleeding oyster.

Bold parallel lines show location where cross-section should be taken for histology;
dashed line indicates cut for frozen section.

(Illustration by A.J. Lippson, Bozman, MD.)

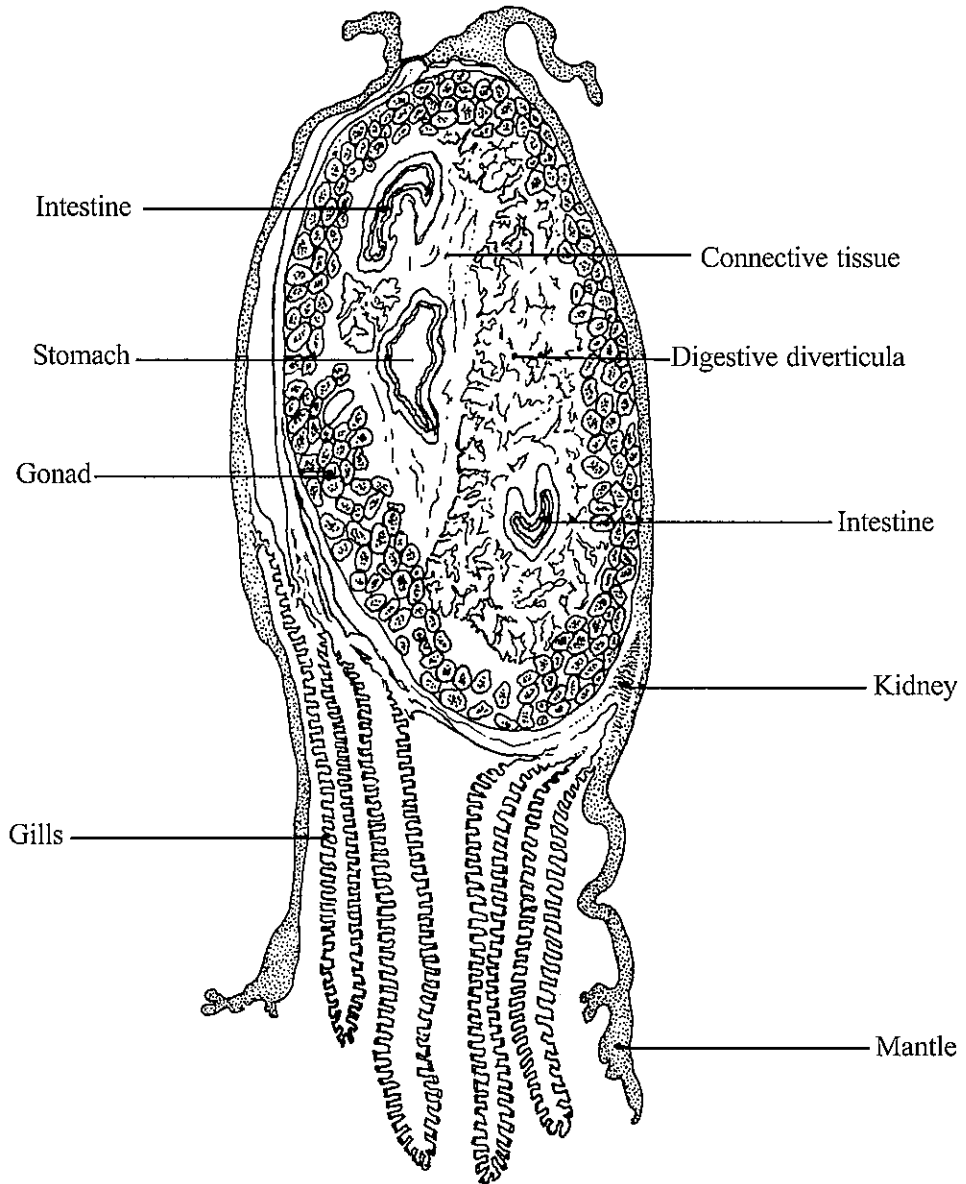
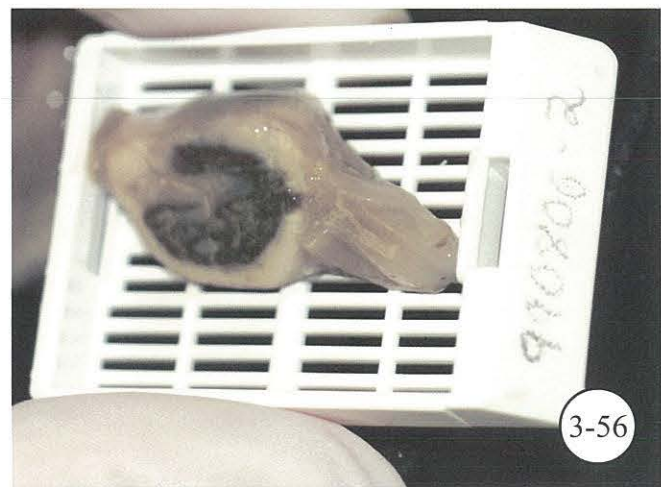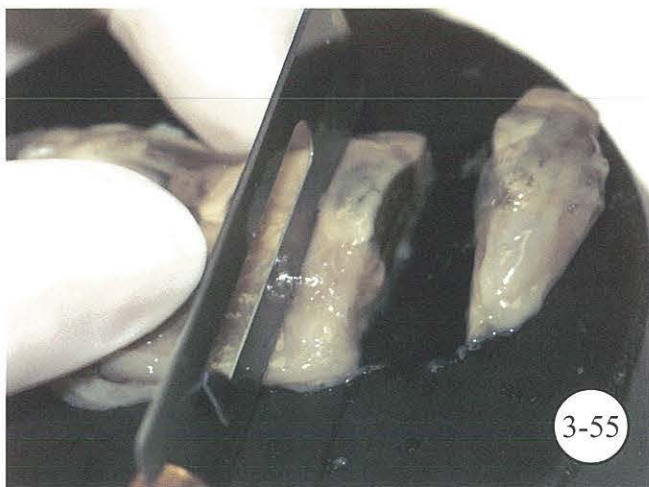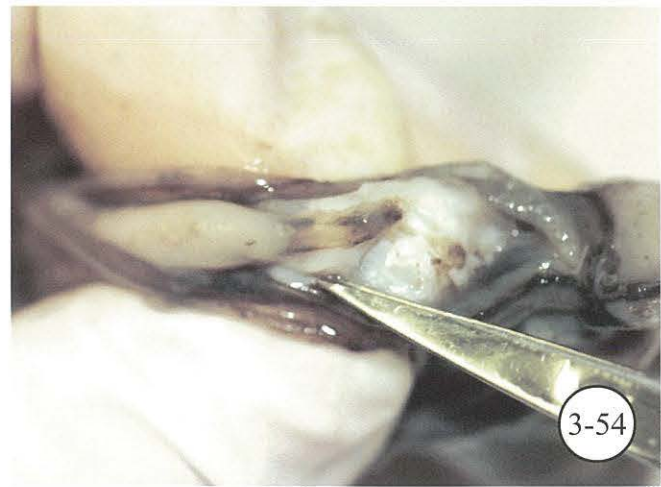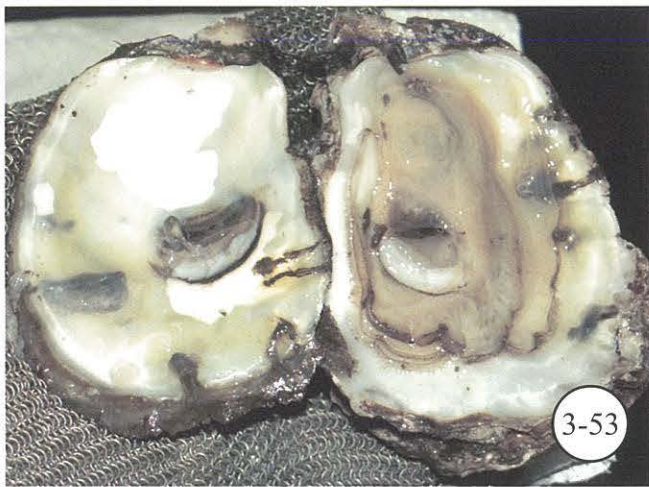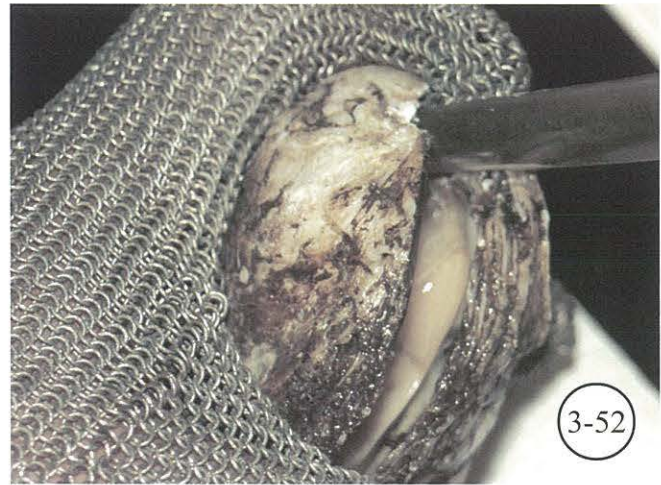


Figure 3-50.

Illustration of cross-section of oyster *C. virginica*.
 Bold parallel lines in Figure 3-49 show location where cross-section was taken.
 (Illustration by A.J. Lippson, Bozman, MD.)



Processing of oyster *C. virginica*.

Figure 3-51. Measure oyster from hinge on right valve to longest part of bill. **Figure 3-52.** “Pop” hinge and twist to open. **Figure 3-53.** Evaluate oyster for condition, parasites, and shell anomalies. **Figure 3-54.** Locate rectum for *Perkinsus* culture. **Figure 3-55.** Take cross-section from oyster as indicated in diagram 3-49. **Figure 3-56.** Cross-section in tissue cassette ready for fixation.

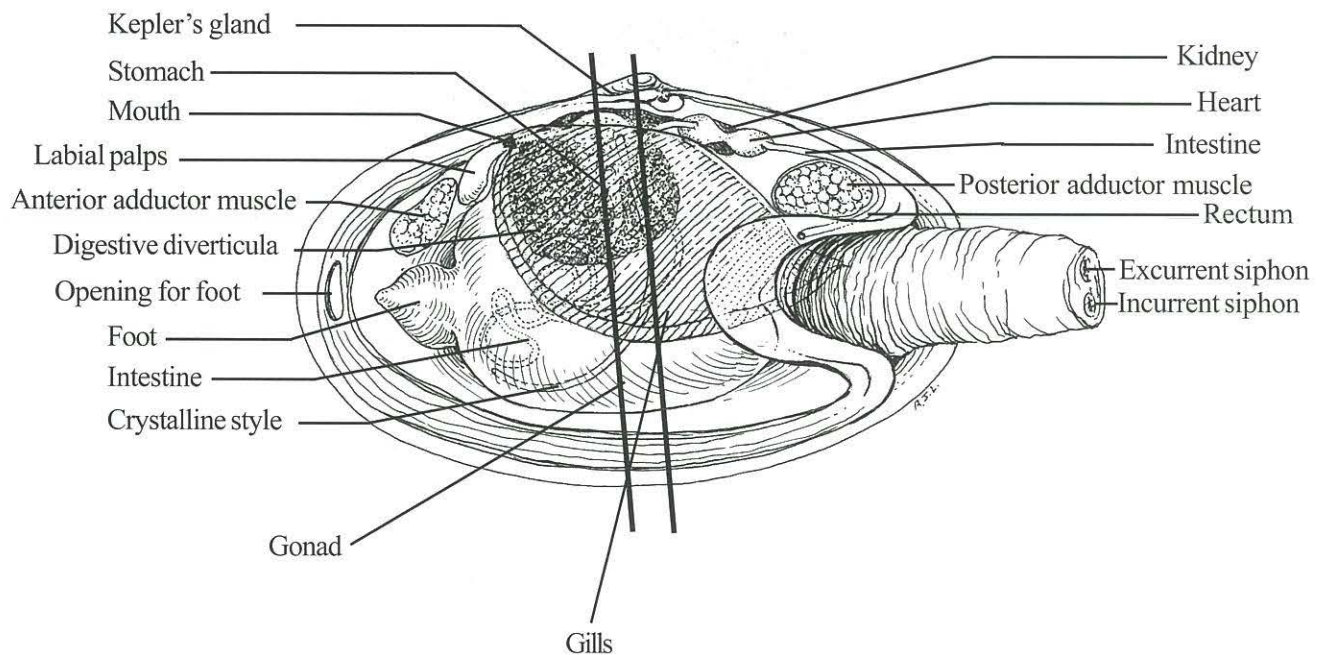
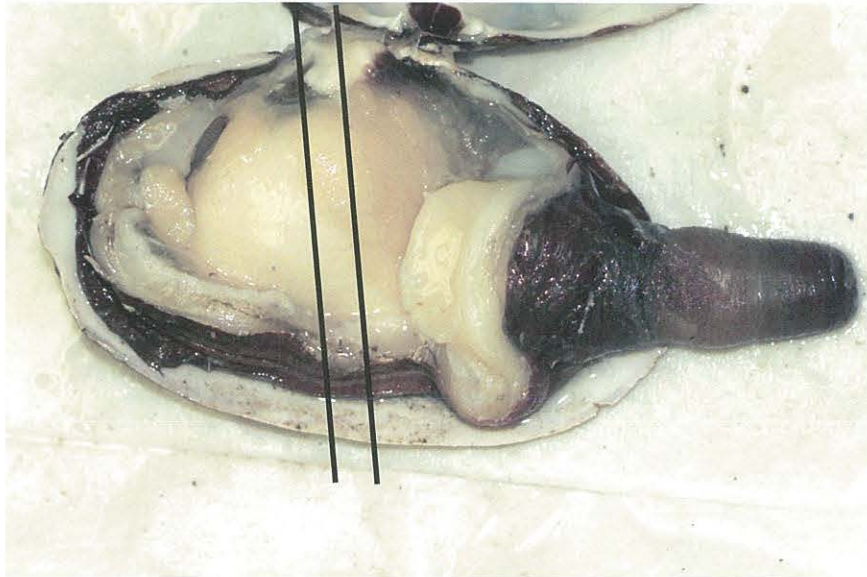


Figure 3-57.
 Gross anatomy of soft clam *Mya arenaria*.
 Bold parallel lines show location where cross-section should be taken.
 (Illustration by A.J. Lippson, Bozman, MD.)

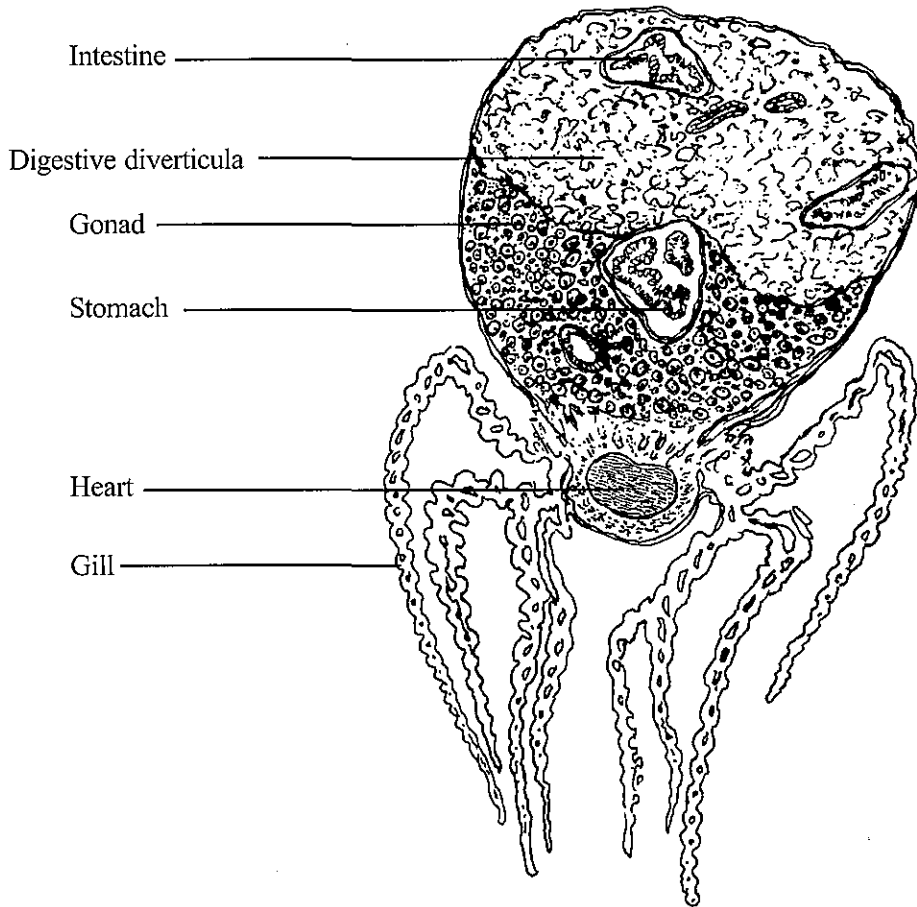
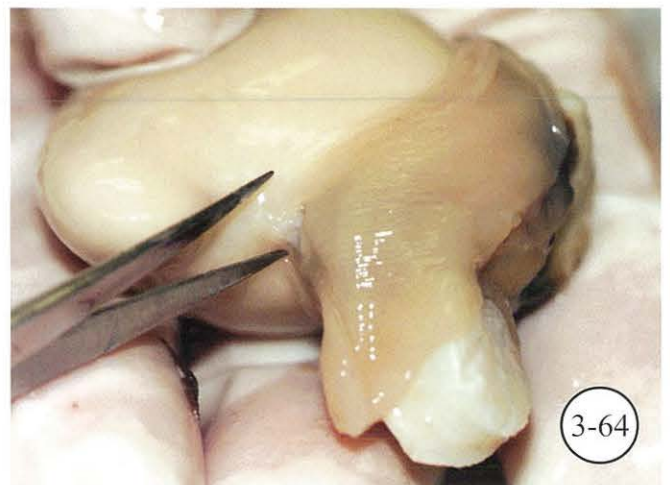
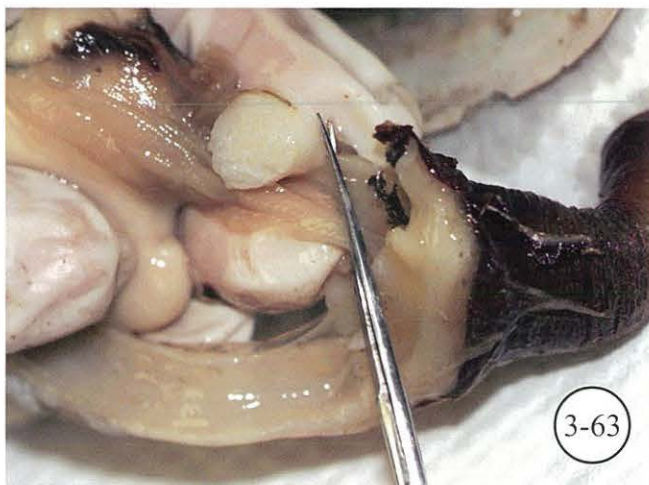
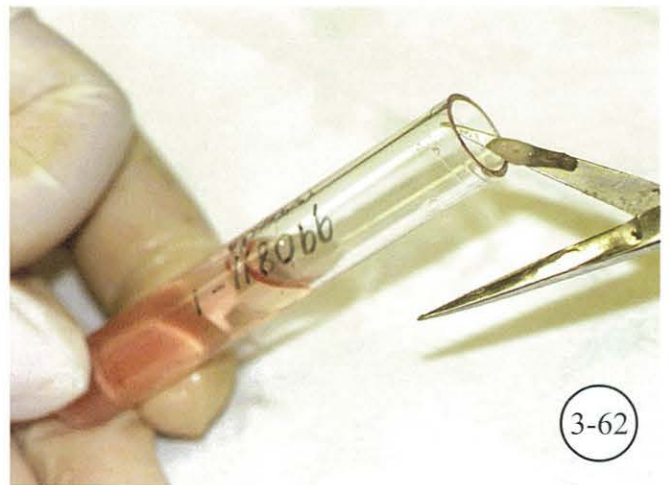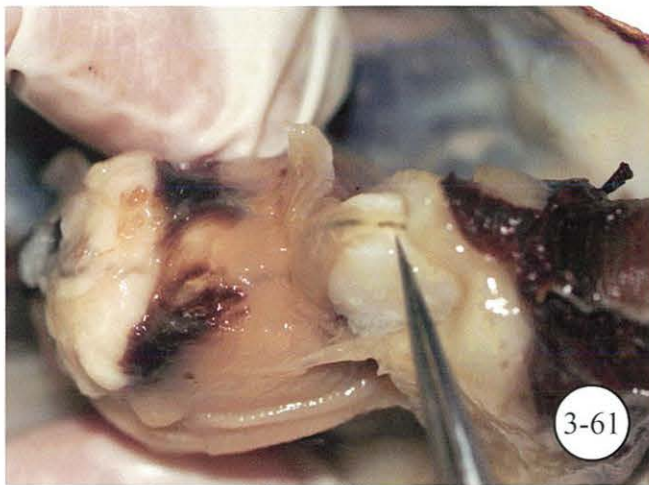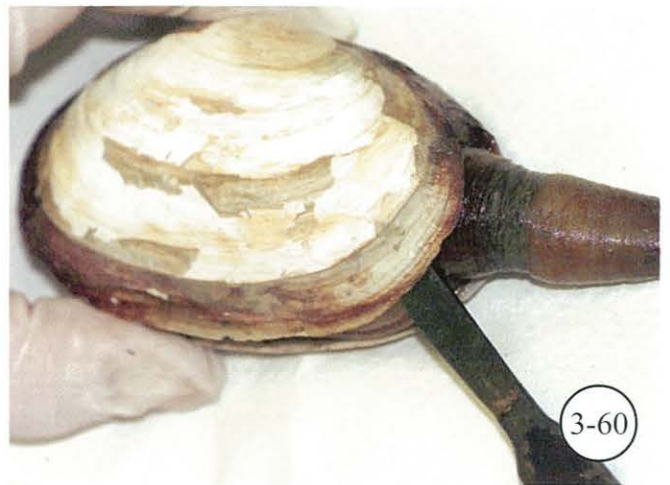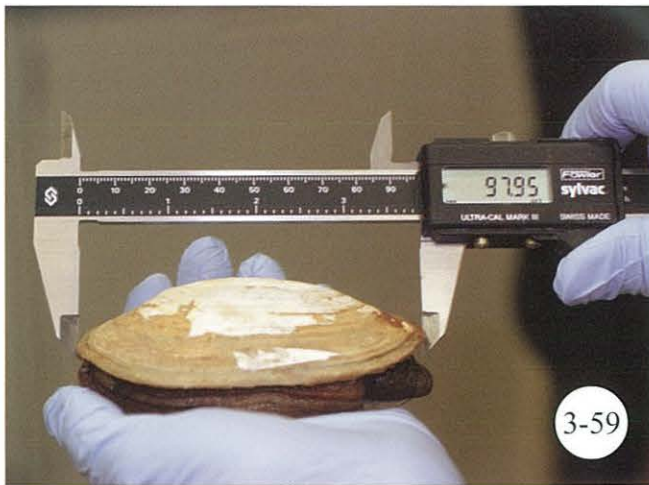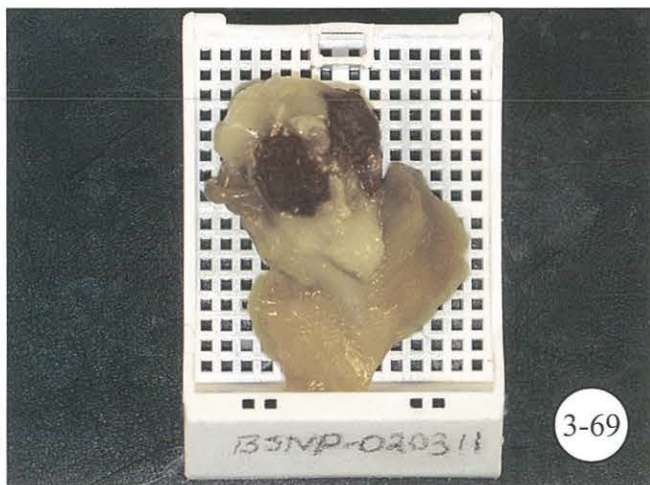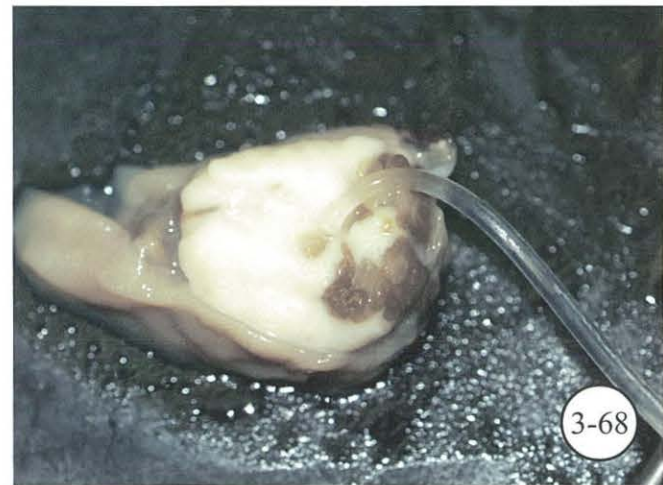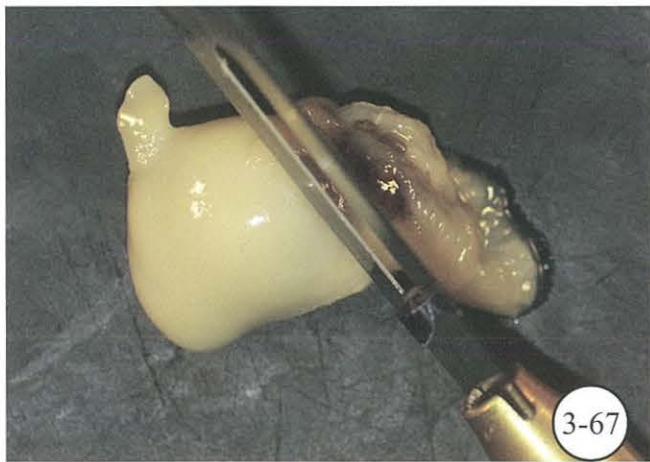
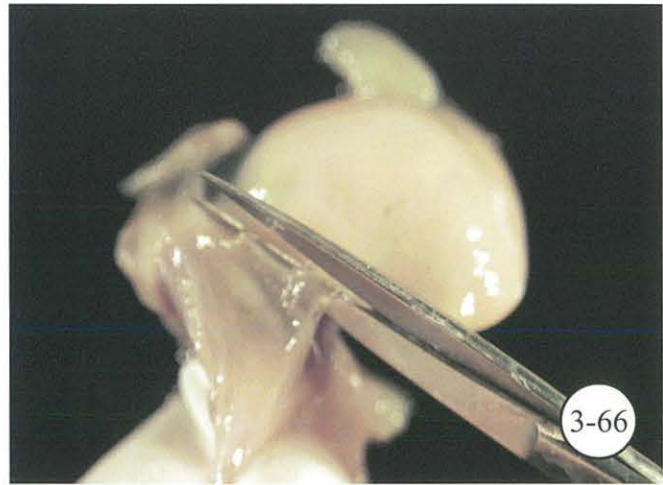
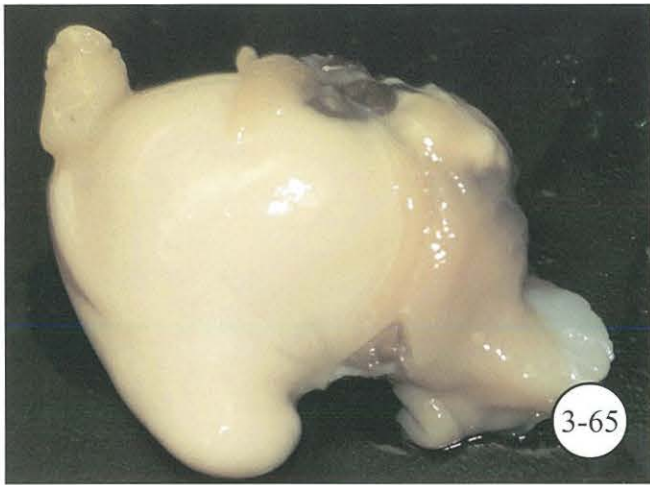
Figure 3-58.

Illustration of cross-section of soft clam *M. arenaria*.
Gills are artificially oriented away from clam body. Bold parallel lines in
Figure 3-57 show location where cross-section was taken.
(Illustration by A.J. Lippson, Bozman, MD.)



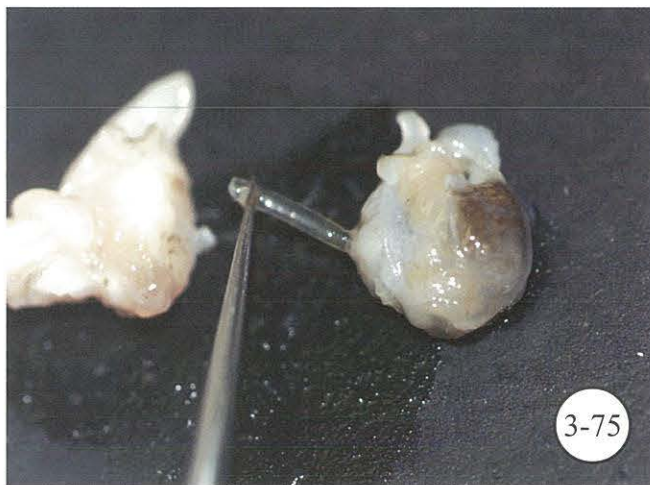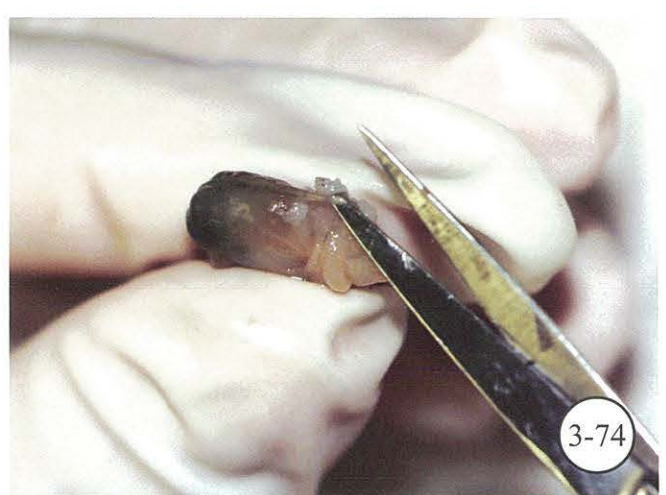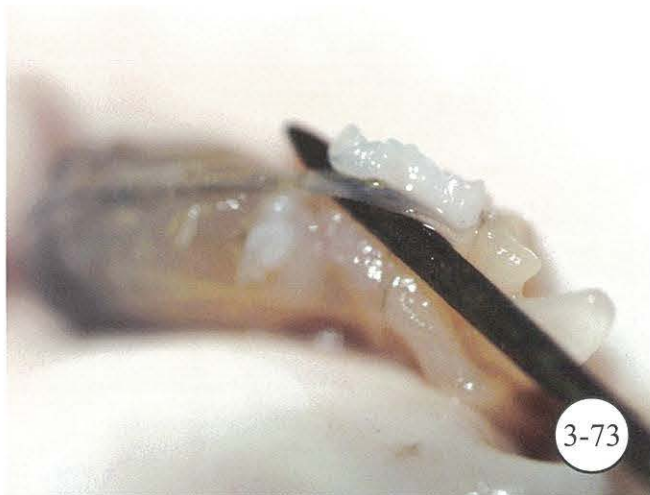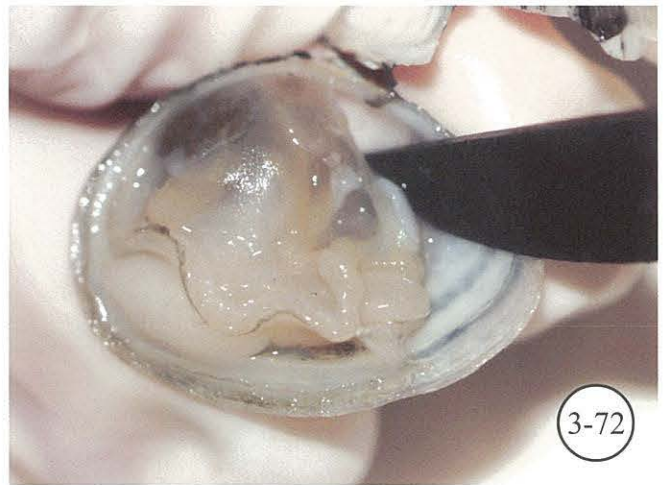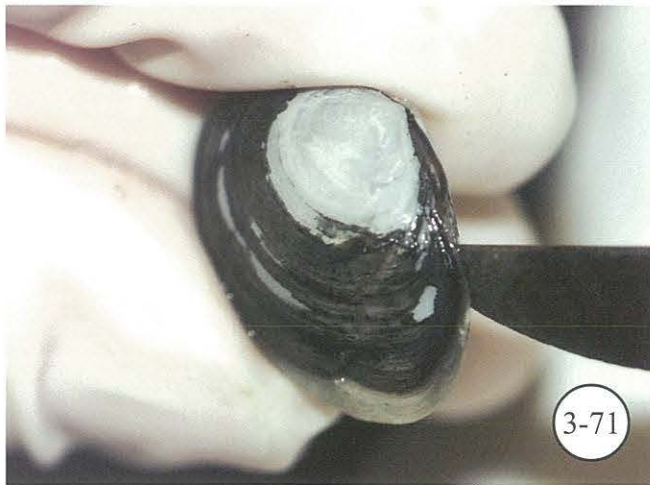Processing of soft clam *M. arenaria*.

Figure 3-59. Measure clam from side to side. **Figure 3-60.** Carefully insert knife to prevent breaking of shell and cut along edge of shell to open. Cut adductor muscles to remove clam from shell. Evaluate clam for condition, parasites, and shell anomalies. **Figure 3-61.** Locate tissues for *Perkinsus* culture. **Figure 3-62.** Place tissue into marked tube containing thioglycolate medium. **Figure 3-63.** Cut to remove siphon and mantle tissue from body of clam. **Figure 3-64.** Clip connective tissue between anterior portion of gills and visceral mass.



Processing of soft clam *M. arenaria* (cont.).

Figure 3-65. Place clam on surface with gills properly positioned for cutting. **Figure 3-66.** Continue clipping gills posteriorly until approximately one-half of tissue is disconnected. **Figure 3-67.** Take cross-section from clam as indicated in diagram 3-57. **Figure 3-68.** Crystalline style in tissue. Cross-section ready to be placed in tissue cassettes and fixed. **Figure 3-69.** Tissue section oriented properly in tissue cassette. **Figure 3-70.** Tissue cassette in fixative.



Processing of Baltic macoma clam *Macoma balthica*.

Figure 3-71. Carefully insert knife to prevent breaking of shell. **Figure 3-72.** Cut adductor muscles. Evaluate clam for condition, parasites, and shell anomalies. **Figure 3-73.** Locate rectum. **Figure 3-74.** Excise rectum for *Perkinsus* culture. **Figure 3-75.** Take cross-section of tissue and remove crystalline style. **Figure 3-76.** Cross-section in tissue cassette ready for fixation.

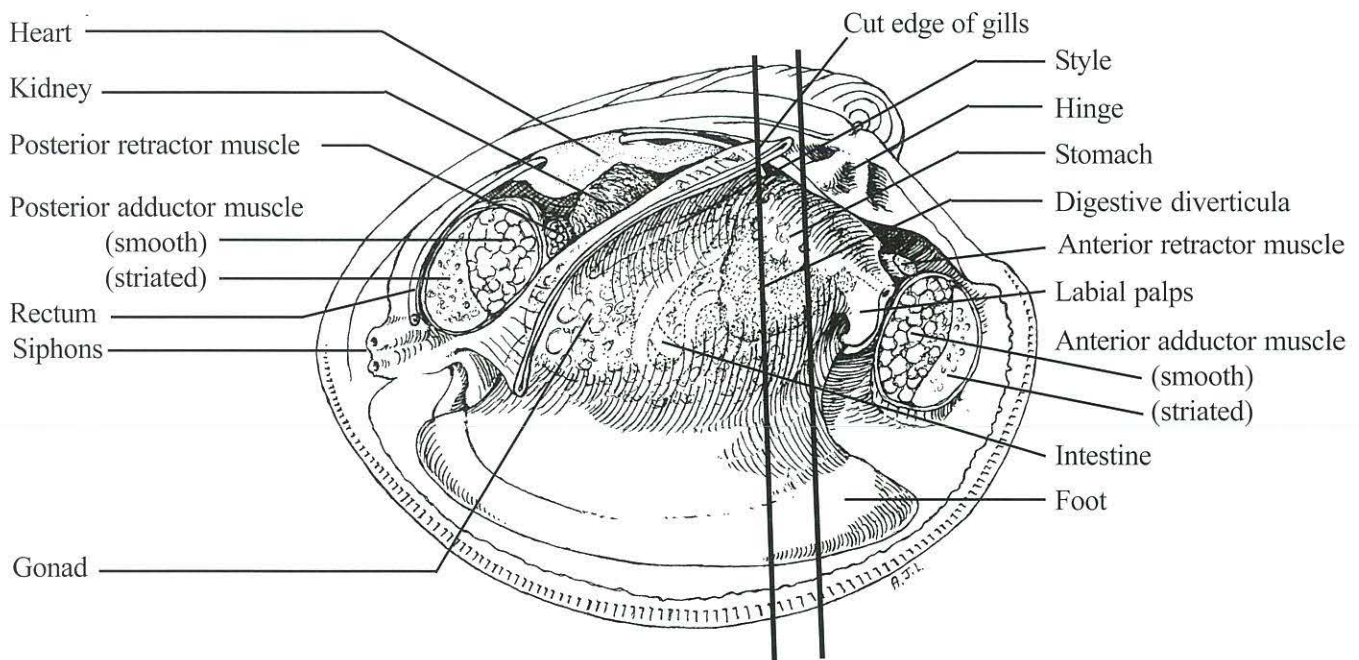
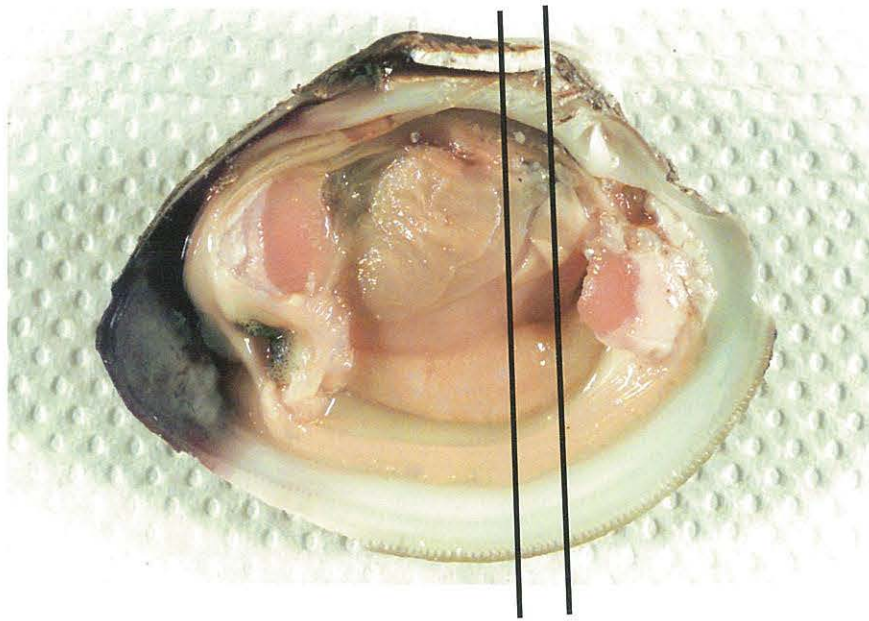


Figure 3-77.

Gross anatomy of hard clam *Mercenaria mercenaria*.
 Bold parallel lines show location where cross-section should be taken.
 (Illustration by A.J. Lippson, Bozman, MD.)

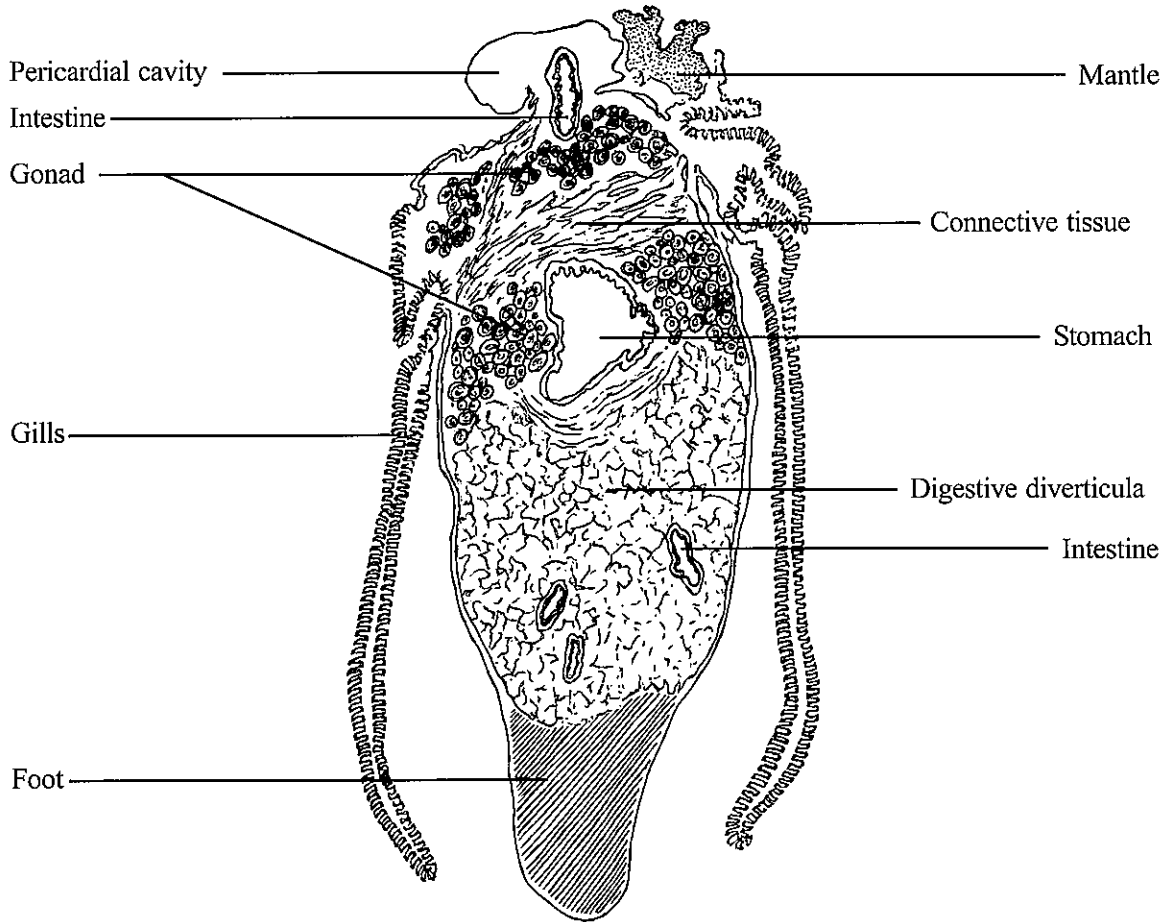


Figure 3-78.

Illustration of cross-section of hard clam *M. mercenaria*.
 Bold parallel lines in Figure 3-77 show location where cross-section was taken.
 (Illustration by A.J. Lippson, Bozman, MD.)

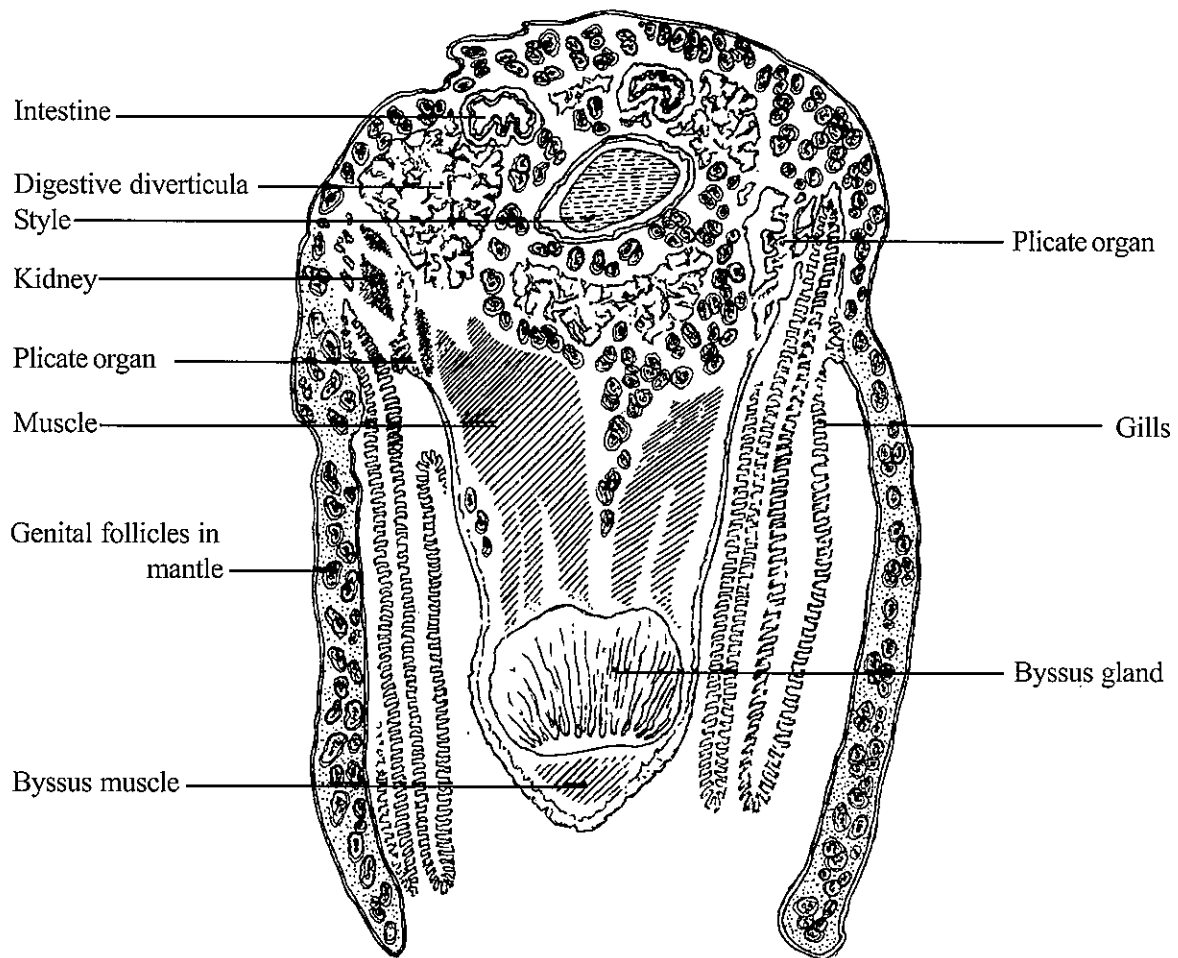
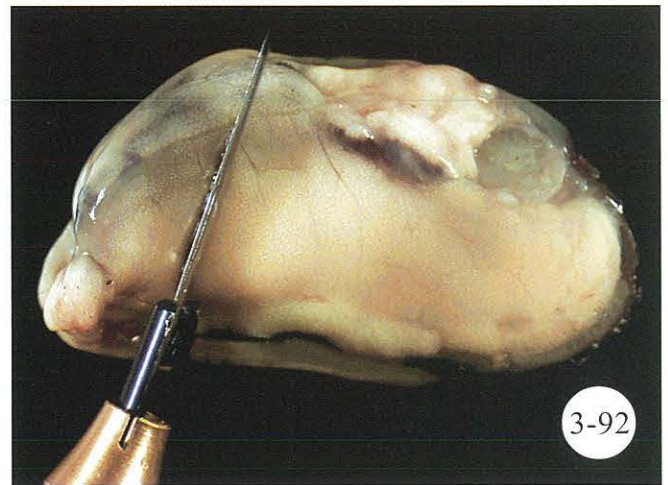
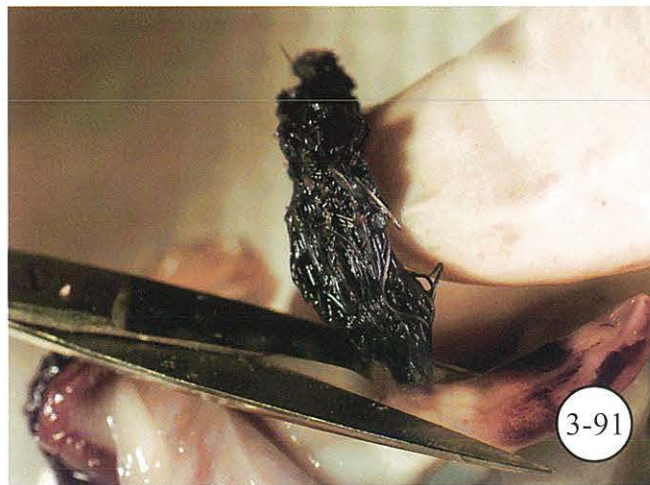
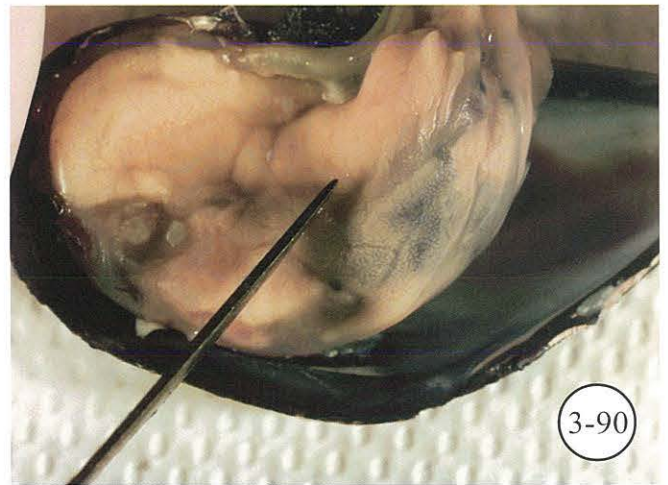


Figure 3-86.

Illustration of cross-section of blue mussel *M. edulis*.

Bold parallel lines in Figure 3-85 show location where cross-section was taken.

(Illustration by A.J. Lippson, Bozman, MD.)



Processing of blue mussel *M. edulis*.

Figure 3-87. Measure mussel from hinge to longest part of bill. **Figure 3-88.** Carefully insert knife at ventral byssal cavity. **Figure 3-89.** Cut adductor muscles and mantle along edge of shell to open. **Figure 3-90.** Evaluate mussel for condition, parasites, shell anomalies, and pearls. **Figure 3-91.** Cut byssal thread from body. **Figure 3-92.** Take cross-section from mussel as indicated in Figure 3-85.

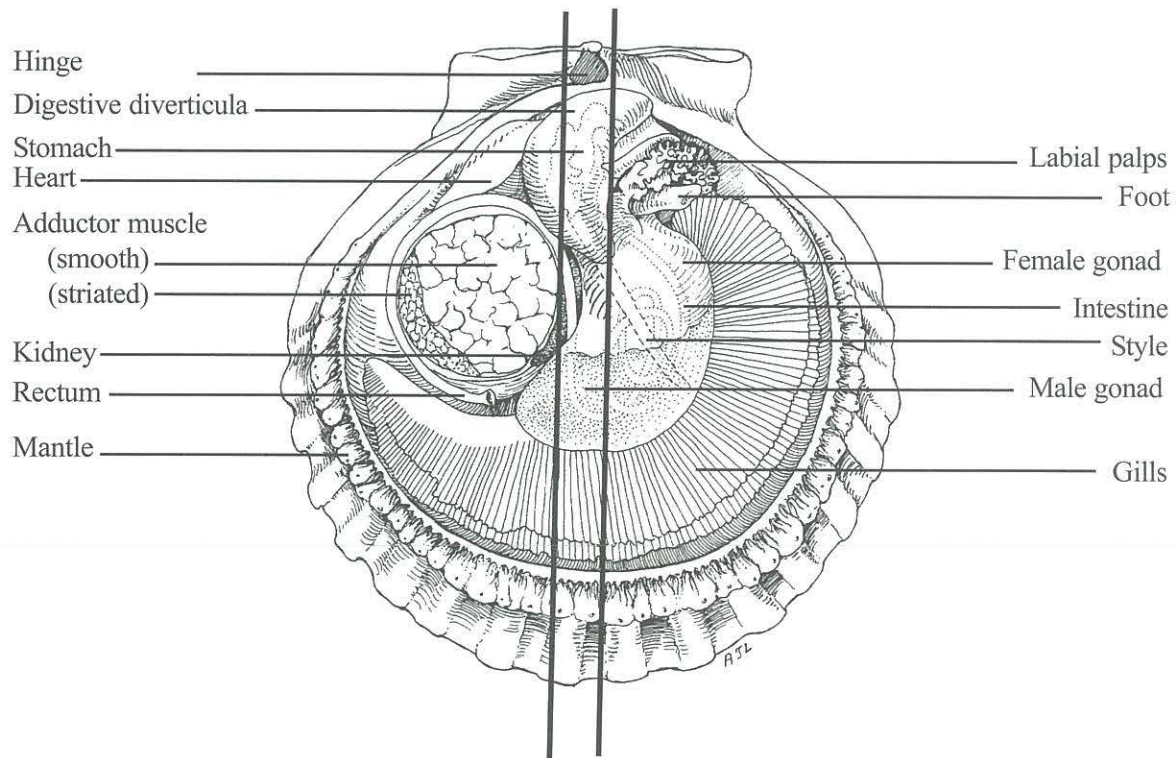
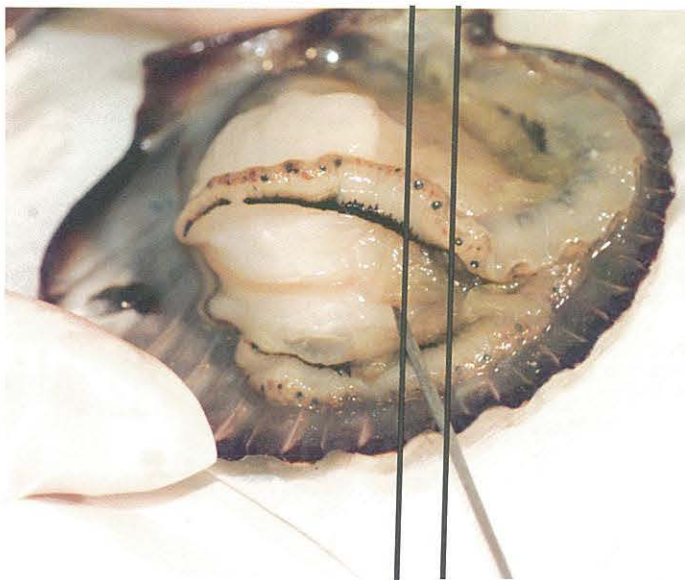


Figure 3-93.

Gross anatomy of scallop *Argopecten irradians*.
 Bold parallel lines show location where cross-section should be taken.
 (Illustration by A.J. Lippson, Bozman, MD.)

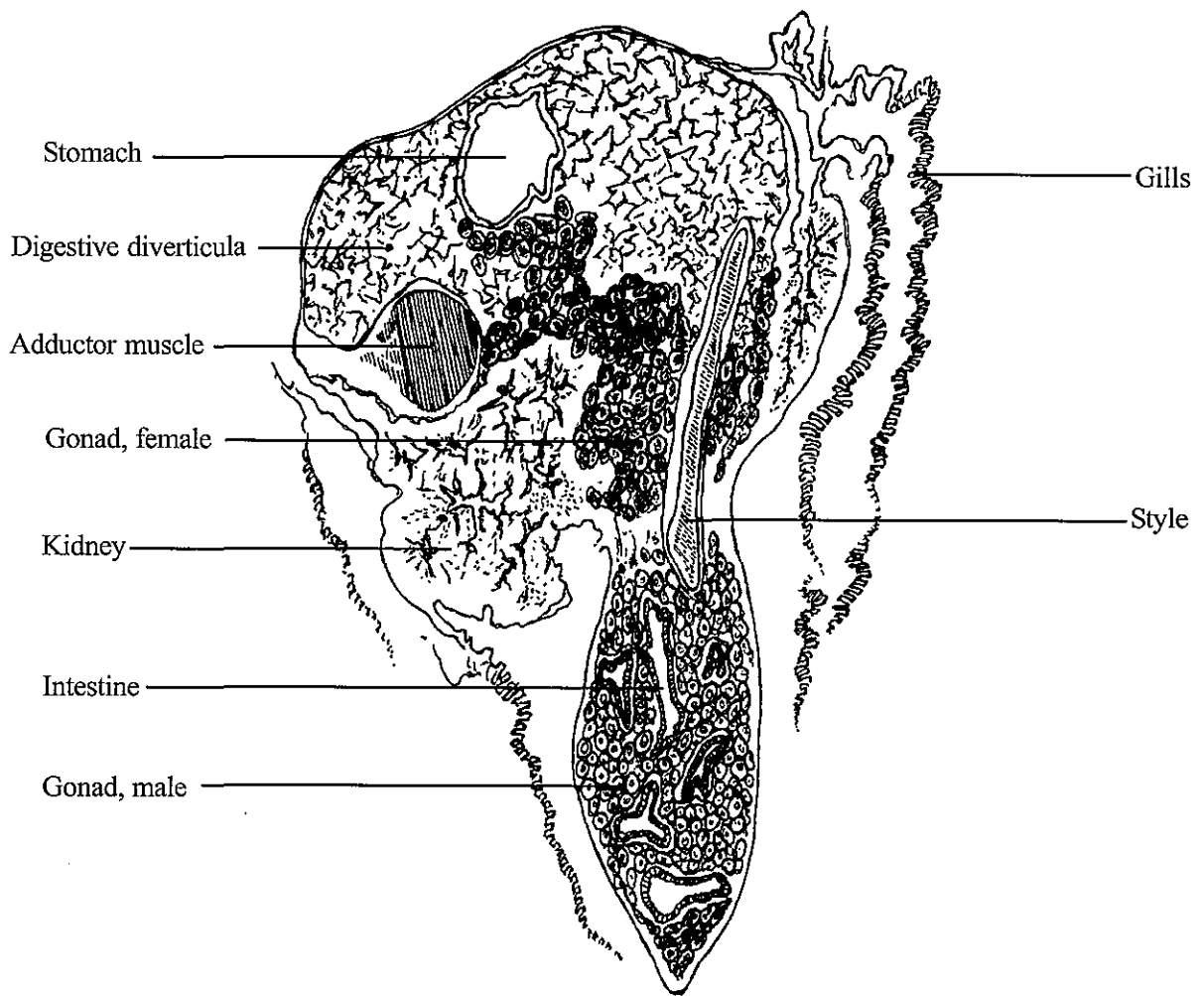
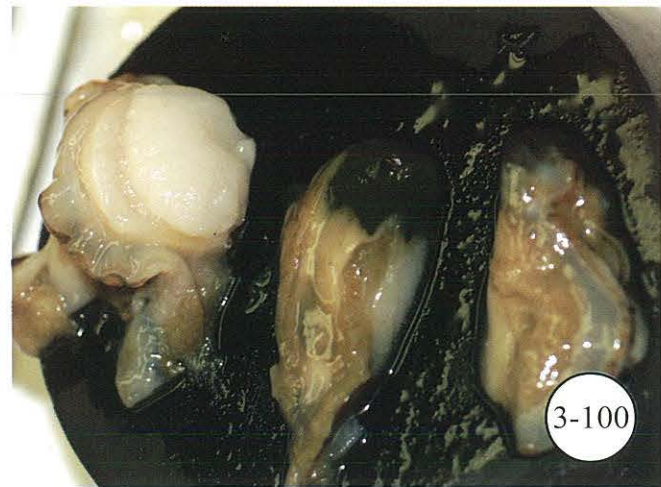
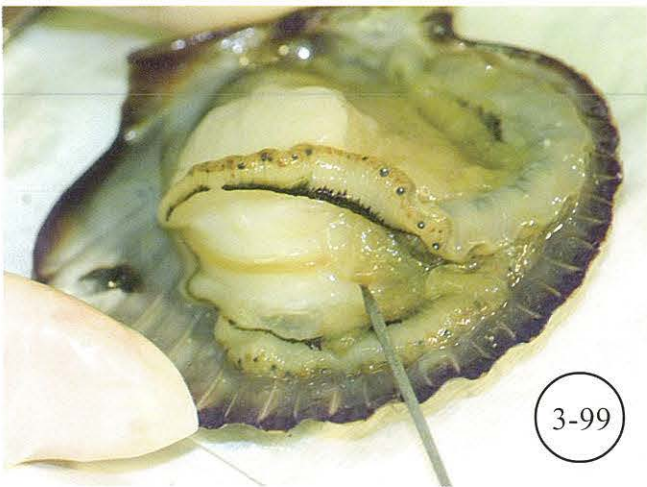
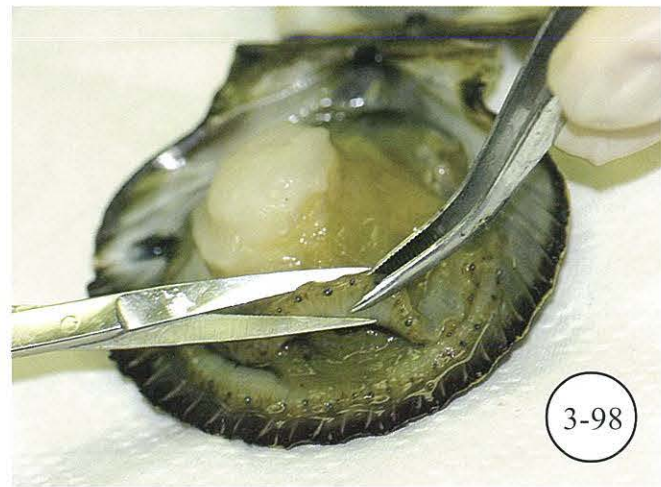
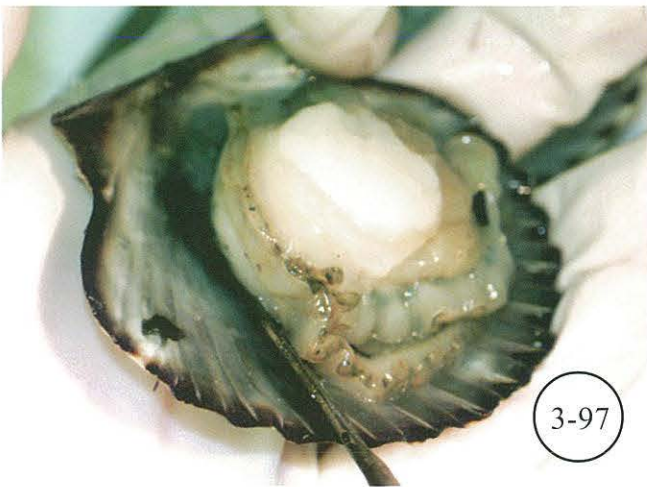


Figure 3-94.
 Illustration of cross-section of scallop *A. irradians*.
 Bold parallel lines in Figure 3-93 show location where cross-section was taken.
 (Illustration by A.J. Lippson, Bozman, MD.)



Processing of bay scallop *A. irradians*.

Figure 3-95. Measure scallop from side to side. **Figure 3-96.** Insert knife to cut adductor muscle from upper shell. **Figure 3-97.** Cut adductor muscle from bottom shell. **Figure 3-98.** Optional, remove edge of mantle prior to taking cross-section if sensory eyes are not requested by investigator. **Figure 3-99.** Locate rectum for *Perkinsus* culture. **Figure 3-100.** Cross-section from scallop as indicated in Figure 3-93. Cross-section ready to be placed in tissue cassette and fixed.

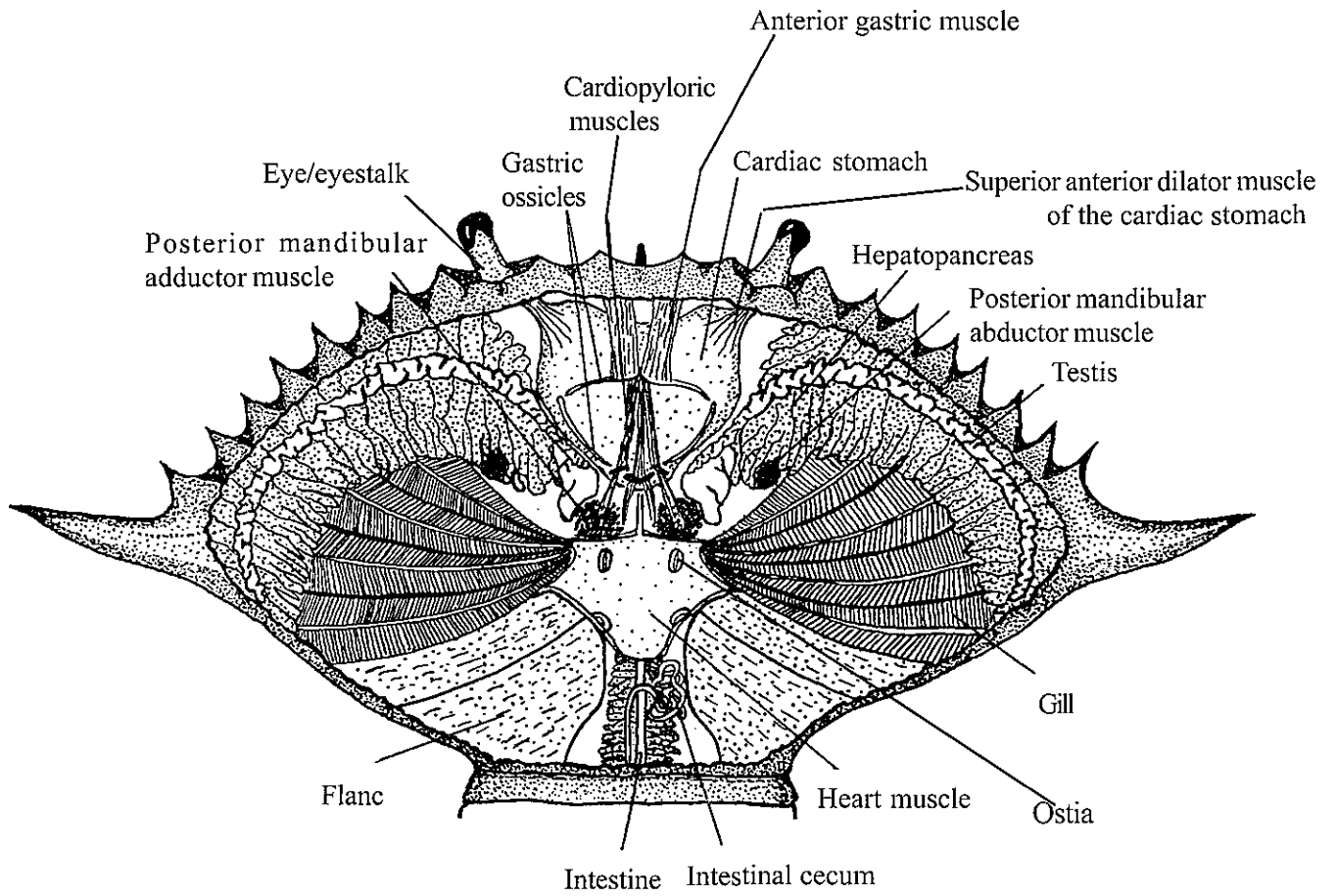
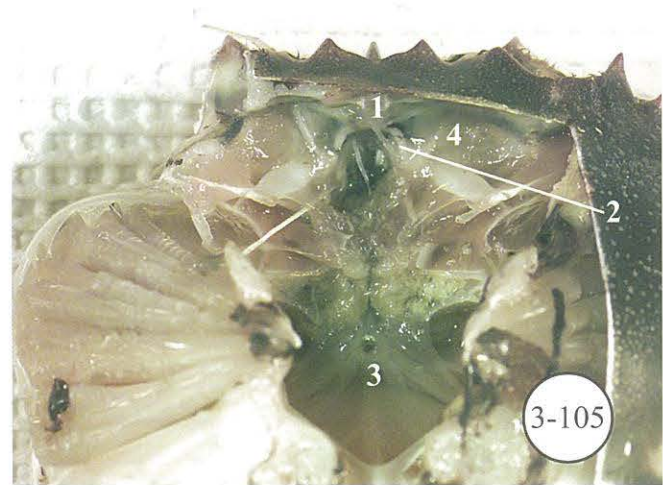
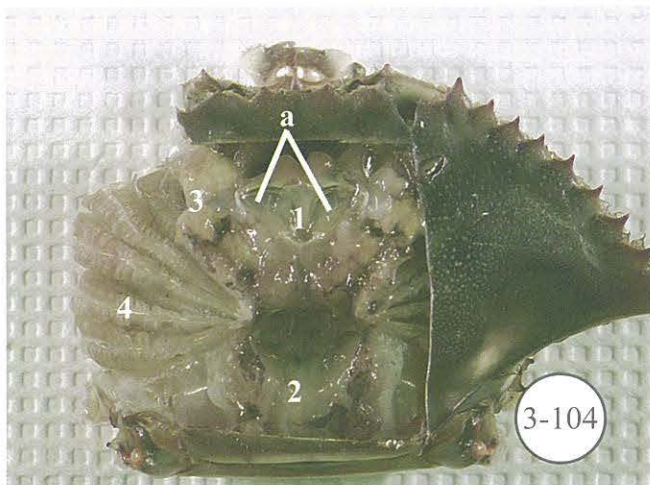




Figure 3-101.
 Gross anatomy of blue crab *Callinectes sapidus*.
 (Modified from Pyle and Cronin 1950.)



Processing of blue crab *Callinectes sapidus*.

Figure 3-102. Dorsal carapace. Lines A, B, and C indicate where carapace is to be cut and removed. **Figure 3-103.** One lateral spine area has been removed to expose gills (1). Removed portion, resting with spine down, contains hepatopancreas (2) to be sampled. **Figure 3-104.** Medial parts of carapace and epidermis have been removed. Large cardiac stomach (1) is visible. Hemopoietic tissue lies on each lateral portion (a). Semitransparent heart is visible (2). Intermingled hepatopancreas and testes (3) and gills (4) are also visible. **Figure 3-105.** Hepatopancreas, testes, and vas deferens have been removed, revealing anterodorsal brain (1) and circumesophageal commissures (2). Large thoracic ganglion (3) lies medioventrally. Its central aperture is visible. Sternal artery passes through aperture. Connective tissues have been removed in order to show location of antennal glands (4) which lie against anteroventral face of exoskeleton.

CHAPTER 4. CRYOSECTION TECHNIQUE

A. Introduction

Frozen tissue techniques enable a sample to be quickly examined microscopically for obvious parasites or lesions. Specimens that exhibit suspicious macroscopic signs of disease, such as pale digestive diverticula, watery condition, mantle recession, or other observable abnormalities, may be selected for frozen sectioning and quick diagnosis. Cryosections are preferred for RNA/DNA or protein analyses of fresh tissue specimens.

B. Description of Technique

The frozen tissue technique presented here may differ from methods used with vertebrate tissue primarily by its simplicity. Liddell (1967) outlined the following frozen sectioning method useful for most molluscan tissue:

- When performing the necropsy analyses, take an extra thin cross-section approximately 2 mm below the palps.
- Quick-freeze the tissue, with its appropriate code, to the object holder which has been chilled to -25°C (Fig. 4-1a).
- Place object holder disc into microtome chuck inside cryostat and then align tissue to microtome knife (Fig. 4-1b).
- Gradually advance the tissue and rough trim until the full surface of the cross-section is exposed.
- Carefully brush the knife blade and surrounding area so that ice chips or tissue residue will not interfere with the surface of the tissue block.
- Cut the frozen section at 6-8 μm (Fig. 4-1c).
- Pick up the tissue section with a clean glass slide or coverglass (Fig. 4-1d).

- The section adheres immediately to the room temperature glass and melts into place.
- Slide is now ready for staining or frozen storage. Once sectioned, store at -80°C

If immediate inspection of the tissue is desired, the section can be stained for quick diagnosis.

Successful cutting of frozen tissue on a cryostat or freezing microtome is accomplished by the same method that is used on a standard rotary microtome designed for sectioning paraffin blocks; however, there is a difference in the consistency of the frozen tissue. Since molluscan tissue is soft and very moist, it should be quick-frozen while fresh. Before attempting to cut the tissue, the knife should be sharpened and cleaned, and the knife and microtome chilled to -25°C .

Rapid freezing for 1-2 min avoids the formation of ice crystals and subsequent artifacts that result from ice crystals in the tissue. Each tissue type has an optimum cutting temperature; however, for quick diagnosis of large samples, cutting tissues at or about -20°C often works well (Prophet et al. 1992).

Attach the tissue to the cryostat stub by freezing with ambient seawater or an embedding media like OCT^a to provide a stabilizing matrix around the tissue. A 2-mm matrix border surrounding the tissue will support and improve the cutting quality.

Disposable blades are of such good quality today that they are recommended for cryostats and standard microtomes. To use the blades on older machines, however, an adapter may be necessary. Hand-honed knives must be carefully cleaned and dried between use to prevent dulling and corrosion of the cutting edge.

Adhesives are rarely necessary to adhere frozen tissue to glass. However, some fixed tissues that are cut tend to

float off the slides. With the exception of albumin which requires heating, any precoated treatment of slide adhesives (see pp. 75-76) may be used in these instances.

Quick stains recommended for frozen tissues are: (1) toluidine blue O (TBO₂) in a 0.5% aqueous solution, (2) Harris' hematoxylin and eosin (HHE₃) quick version (Prophet et al. 1992), and (3) oil red O (ORO).

C. Footnote

^aFisher Scientific, 3970 Johns Creek Court, Suwanee, GA 30024. (800) 766-7000. www.fishersci.com

D. References

Liddell, V.A. 1967. Frozen-section technique in shellfish research. *J. Invertebr. Pathol.* 9: 283-284.

Prophet, E.B., B. Mills, J.B. Arrington, and L.H. Sobin, Editors. 1992. *Armed Forces Institute of Pathology - Laboratory Methods in Histotechnology*. American Registry of Pathology, AFIP, Washington, DC. 279 p.

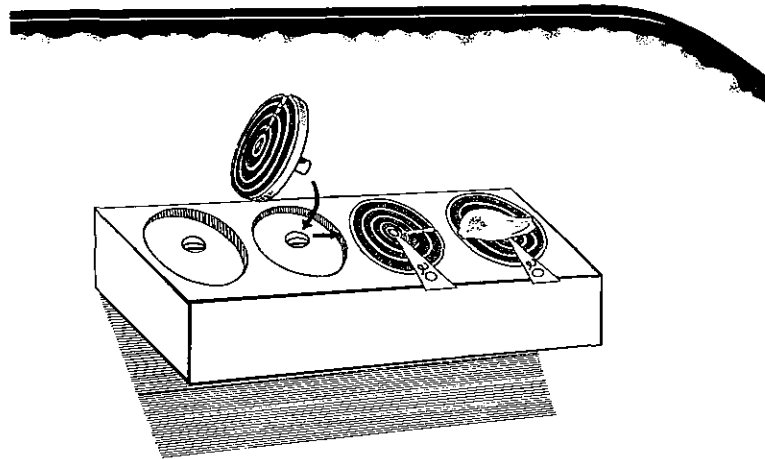


Figure 4-1a

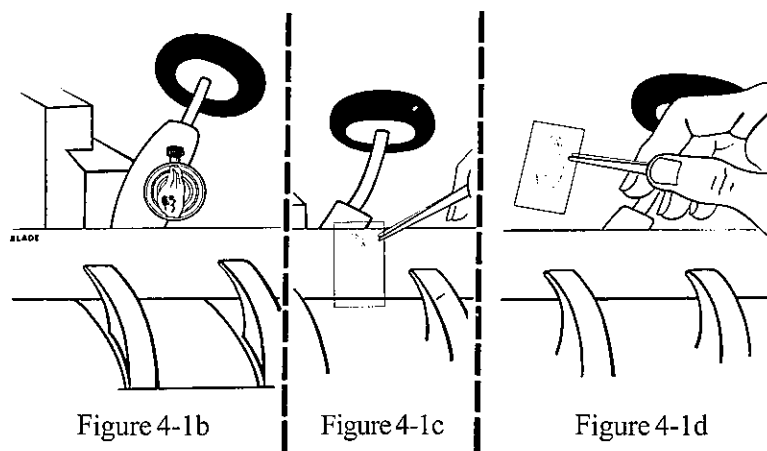


Figure 4-1b

Figure 4-1c

Figure 4-1d

Figure 4-1. Frozen tissue technique.

Figure 4-1a. Code tissue and freeze on object holder. **Figure 4-1b.** Align tissue to microtome knife. **Figure 4-1c.** Cut tissue. **Figure 4-1d.** Pick up tissue and place on coverglass. (Illustration by R. Tolley, Cambridge, MD.)

CHAPTER 4. CRYOSECTION TECHNIQUE

A. Introduction

Frozen tissue techniques enable a sample to be quickly examined microscopically for obvious parasites or lesions. Specimens that exhibit suspicious macroscopic signs of disease, such as pale digestive diverticula, watery condition, mantle recession, or other observable abnormalities, may be selected for frozen sectioning and quick diagnosis. Cryosections are preferred for RNA/DNA or protein analyses of fresh tissue specimens.

B. Description of Technique

The frozen tissue technique presented here may differ from methods used with vertebrate tissue primarily by its simplicity. Liddell (1967) outlined the following frozen sectioning method useful for most molluscan tissue:

- When performing the necropsy analyses, take an extra thin cross-section approximately 2 mm below the palps.
- Quick-freeze the tissue, with its appropriate code, to the object holder which has been chilled to -25°C (Fig. 4-1a).
- Place object holder disc into microtome chuck inside cryostat and then align tissue to microtome knife (Fig. 4-1b).
- Gradually advance the tissue and rough trim until the full surface of the cross-section is exposed.
- Carefully brush the knife blade and surrounding area so that ice chips or tissue residue will not interfere with the surface of the tissue block.
- Cut the frozen section at $6-8\ \mu\text{m}$ (Fig. 4-1c).
- Pick up the tissue section with a clean glass slide or coverglass (Fig. 4-1d).

- The section adheres immediately to the room temperature glass and melts into place.
- Slide is now ready for staining or frozen storage. Once sectioned, store at -80°C

If immediate inspection of the tissue is desired, the section can be stained for quick diagnosis.

Successful cutting of frozen tissue on a cryostat or freezing microtome is accomplished by the same method that is used on a standard rotary microtome designed for sectioning paraffin blocks; however, there is a difference in the consistency of the frozen tissue. Since molluscan tissue is soft and very moist, it should be quick-frozen while fresh. Before attempting to cut the tissue, the knife should be sharpened and cleaned, and the knife and microtome chilled to -25°C .

Rapid freezing for 1-2 min avoids the formation of ice crystals and subsequent artifacts that result from ice crystals in the tissue. Each tissue type has an optimum cutting temperature; however, for quick diagnosis of large samples, cutting tissues at or about -20°C often works well (Prophet et al. 1992).

Attach the tissue to the cryostat stub by freezing with ambient seawater or an embedding media like OCT^a to provide a stabilizing matrix around the tissue. A 2-mm matrix border surrounding the tissue will support and improve the cutting quality.

Disposable blades are of such good quality today that they are recommended for cryostats and standard microtomes. To use the blades on older machines, however, an adapter may be necessary. Hand-honed knives must be carefully cleaned and dried between use to prevent dulling and corrosion of the cutting edge.

Adhesives are rarely necessary to adhere frozen tissue to glass. However, some fixed tissues that are cut tend to

float off the slides. With the exception of albumin which requires heating, any precoated treatment of slide adhesives (see pp. 75-76) may be used in these instances.

Quick stains recommended for frozen tissues are: (1) toluidine blue O (TBO₂) in a 0.5% aqueous solution, (2) Harris' hematoxylin and eosin (HHE₃) quick version (Prophet et al. 1992), and (3) oil red O (ORO).

C. Footnote

^aFisher Scientific, 3970 Johns Creek Court, Suwanee, GA 30024. (800) 766-7000. www.fishersci.com

D. References

Liddell, V.A. 1967. Frozen-section technique in shellfish research. *J. Invertebr. Pathol.* 9: 283-284.

Prophet, E.B., B. Mills, J.B. Arrington, and L.H. Sobin, Editors. 1992. *Armed Forces Institute of Pathology - Laboratory Methods in Histotechnology*. American Registry of Pathology, AFIP, Washington, DC. 279 p.

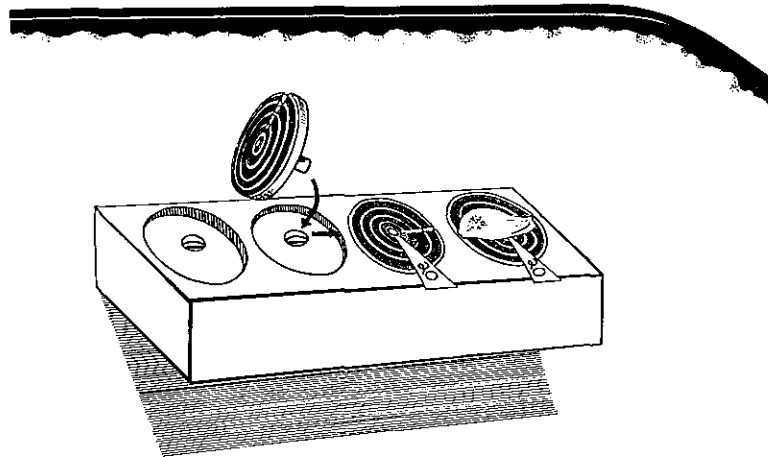


Figure 4-1a

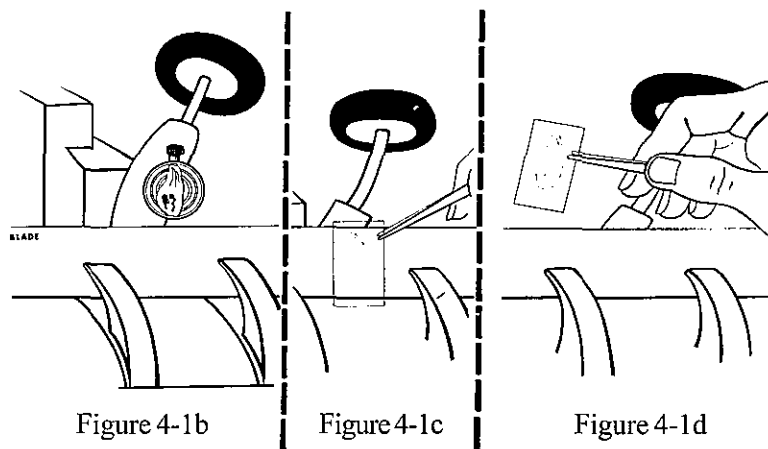


Figure 4-1b

Figure 4-1c

Figure 4-1d

Figure 4-1. Frozen tissue technique.

Figure 4-1a. Code tissue and freeze on object holder. **Figure 4-1b.** Align tissue to microtome knife. **Figure 4-1c.** Cut tissue. **Figure 4-1d.** Pick up tissue and place on coverglass. (Illustration by R. Tolley, Cambridge, MD.)

CHAPTER 5. FIXATION

A. Introduction

Tissue fixation preserves cellular detail for examination by microscopy. An ideal fixative rapidly penetrates tissue to prevent postmortem degeneration, coagulates cell proteins, hardens tissue so it is not altered by histological processes, and protects tissue from shrinkage and other misleading structural changes.

B. Formulas for Fixatives and Methods

The choice of fixative depends on the nature of the tissue, the interests of the investigator, the purpose of the study, the facilities at hand, and the stains to be used. Fume hoods

are essential in fixative preparation. In most cases, a 20:1 volume of fixative to tissue is preferable. Examination of tissues for ultrastructural and molecular studies require specific fixatives. Table 5-1 lists fixatives and applications and Table 5-2 lists formulas for fixatives and methods.

Historically, mercury-based fixatives were common in certain applications. Current environmental and safety concerns and cost of proper disposal for hazardous chemicals, however, have led to mercury substitutes, many of which do not perform as well as mercury-based fixatives. In addition, formaldehyde substitutes are becoming more common, but may not provide the appropriate safety nor the quality of fixation for certain tissues and human pathogens.

Table 5-1. Fixatives and applications.

Fixatives	Applications
Alcohols, ethanol/methanol	Cytological preps, molecular analyses
Bouin's	Light microscopy, protozoa, glycogen in tissues, fish, cytological preps
Bouin's for ciliates	Light microscopy, scanning electron microscopy, ciliates, cytological preps
Bouin's/Davidson's	Light microscopy, scanning electron microscopy, ciliates, cytological preps
Davidson's	Light microscopy, preferred fixative for marine bivalves, cytological preps
Davidson's (stock)	Light microscopy, molecular DNA , laser capture microdissection
Formalin	Light microscopy, field analyses, fish
Neutral buffered formalin	Light microscopy, preferred general fixative, cytological preps
Glutaraldehyde (2%) and glutaraldehyde for ciliates (2%)	Electron microscopy, ciliates
1% glutaraldehyde/4% formaldehyde	Light and electron microscopy, recommended for proteins, cytological preps
Helly's (Zenker formalin)	Light microscopy, excellent nuclear detail; mercury substitutes recommended
Russell's modified-Zenker	Mercury substitute, light microscopy, good nuclear detail
Z-Fix ^a	Light microscopy, immunohistochemistry, molecular analyses
Zenker (base and acetic)	Light microscopy, preferred for proteins and cytological detail; mercury substitutes recommended

Table 5-2. Fixative formulas and methods.

Fixative	Fixation time	Preparation for sectioning	Remarks
BOUIN'S (Coolidge and Howard 1979)			
Saturated aqueous picric acid 75.0 ml	Optimum fixation, 4-18 h (cytological preps, 5-15 min); room temp.; pH, acid.	Optimum tissue thickness, 5-7 mm. To prepare for embedment, wash in several changes of 70% ethyl alcohol (ETOH) to remove picric acid. Store larger tissues (if necessary) in Bouin's or 70% ETOH. Wash cytological preps in tap water 5-30 min before staining.	Good fixative for glycogen in tissues, protozoans, or large whole objects such as fish eyeballs. Also good for trichrome stains and special techniques, e.g., protargol silver. Not recommended for staining with azure eosin or Feulgen reaction. Purchase of ready-made saturated solutions of aqueous picric acid is recommended. Dry picric acid is explosive; keep moist.
37-40% formaldehyde . . 25.0 ml (potential carcinogen)			
Glacial acetic acid 5.0 ml			
BOUIN'S FOR CILIATES (Lee et al. 1985)			
37-40% formaldehyde saturated with picric acid 4.5 ml (potential carcinogen)	Optimum fixation, 1-8 h (cytological preps, 5-15 min); room temp.; pH, acid.	Rinse tissues in 70% ETOH to remove excess Bouin's before staining or embedment. To fix ciliates, pipet directly onto slides or into scintillation vials. Wash cytological preps in tap water 5-30 min before staining.	Specific for staining ciliates on filters or separate slides. For field procedures, use ambient seawater. When working in laboratory, use artificial seawater adjusted to ambient conditions. Dry picric acid is explosive; keep moist.
Ambient seawater 4.5 ml			
Glacial acetic acid 1.0 ml			
BOUIN'S/DAVIDSON'S (C.A. Farley, NOAA, Oxford, MD, pers. commun. 1995)			
Davidson's stock 17 parts	Optimum fixation, 1-8 h (cytological preps, 5-15 min); refrigerate; pH, acid.	Rinse tissues in 70% ETOH to remove excess Bouin's before staining or embedment. To fix ciliates, pipet directly onto slides or into scintillation vials. Wash cytological preps in tap water 5-30 min before staining.	Successful fixative for ciliates and xenomas of ciliates found in gill tissues.
37-40% formaldehyde saturated with picric acid 2 parts (potential carcinogen)			
Glacial acetic acid 1 part			

Table 5-2. Fixative formulas and methods (cont.).

Fixative	Fixation time	Preparation for sectioning	Remarks
DAVIDSON'S (Shaw and Battle 1957)			
<i>1 gal stock (3600 ml):</i>			
Glycerin 400.0 ml	Optimum fixation, 24-48 h (cytological preps, 5-15 min); refrigerate, 4°C; pH, acid.	Optimum tissue thickness, 4-5 mm. To prepare for embedment, change to 50% ETOH, 2-h minimum; change to 70% ETOH, 2-h minimum. Store tissue (if necessary) in 70% ETOH or stock Davidson's without acetic acid. Wash cytological preps in tap water 5-30 min before staining.	Recommended fixative for general molluscan pathology; acceptable for most stains. For best results, follow order of ingredients when preparing stock fixative; store at room temp.; shake well before use. <i>Note:</i> For future DNA extractions, fix with stock solution. Acetic acid in working solution interferes with DNA recovery.
37-40% formaldehyde . . . 800.0 ml (potential carcinogen)			
95% ETOH . . . 1200.0 ml			
Filtered ambient or artificial seawater (see p. 144) . . . 1200.0 ml			
<i>Working solution (10% acetic acid):</i>			
Davidson's stock 9 parts			Add acetic acid to stock Davidson's immediately prior to use. Refrigerate once acetic acid is added to fixative. Acetic acid aids in disintegration of small bivalve shells. For cytological preps, use 1% glacial acetic acid.
Glacial acetic acid 1 part			
ETHANOL, 70% (V. Espina, NIH, Bethesda, MD, pers. commun. 2004)			
95% ETOH 70.0 ml	Optimum fixation, 4-6 h for small biopsy specimens; up to 24 h for specimens to 3 mm; or 5-15 min for cytological preps. Place tissue specimens in 10X volume of 70% ETOH at 4°C; pH, neutral.	Optimal tissue thickness, up to 3 mm. Prepare specimens according to specific protocols for molecular studies. Wash cytological preps in tap water 5-30 min before staining.	Recommended fixative for laser capture microdissection (LCM) and molecular studies. Tends to make tissues brittle.
Distilled water . . 25.0 ml			
FORMALIN (10% seawater) (Lillie 1965)			
37-40% formaldehyde 10.0 ml (potential carcinogen)	Optimum fixation, 24-48 h; room temp.; pH, neutral for best results.	Optimum tissue thickness, 4-5 mm. To prepare for embedment, wash 30 min-4 h, depending on size of tissue, to remove excess formalin pigment. Store tissue in 70% ETOH or 10% formalin.	General fixative, particularly good for field and cruise work because of simplicity. <i>Note:</i> After opening new bottle of commercial formalin, add a few marble chips or calcium carbonate to prevent onset of acidity.
Filtered ambient or artificial seawater (see p. 144) 90.0 ml			

Table 5-2. Fixative formulas and methods (cont.).

Fixative	Fixation time	Preparation for sectioning	Remarks
NEUTRAL BUFFERED FORMALIN (NBF) (C.A. Farley, NOAA, Oxford, MD, pers. commun. 1998)			
<i>37-40% formaldehyde stock:</i>			
Formaldehyde . . . 1.0 L			
(potential carcinogen)			
Sodium phosphate diabase anhydrous 15.0 gm			
Sodium hydroxide . . . 0.064 gm			
Phenol red (optional) 0.025 gm			
<i>10% NBF working solution:</i>			
Stock 1 part	Optimum fixation, 24-48 h (cytological preps, 5-15 min); room temp.; buffer to pH 7.4-8.0.	Wash to remove excess formalin before placing tissue in 70% ETOH. Wash cytological preps in tap water 5-30 min before staining.	General all-purpose fixative. Phenol red is a quick test for fixative pH.
Filtered ambient or artificial seawater (see p. 144). 9 parts			
GLUTARALDEHYDE (2%) (Feng et al. 1971)			
50% glutaraldehyde . . . 4.0 ml	Optimum fixation, 2-24 h; refrigerate, 4°C; buffer to physiological pH of tissues, typically 7.2-7.4 for osmoregulating animals and 8.0-8.4 for non- osmoregulating marine invertebrates (see pp. 180-182).	Do not exceed 1-mm tissue thickness. To prepare for embedment, dehydrate as for plastic embedding medium. Wash (4 times, 5 min each) in buffered seawater, pH 7.2-7.4. Postfix in buffered 1% osmium tetroxide, pH 7.2-7.4.	Recommended for electron microscopy (EM). Thickness of tissue is key to successful penetration of fixative. Osmium tetroxide fumes are hazardous to eyes, nose, and throat; use only in fume hood and wear proper personal protective equipment.
Filtered ambient or artificial seawater (see p. 144) 96.0 ml			

Table 5-2. Fixative formulas and methods (cont.).

Fixative	Fixation time	Preparation for sectioning	Remarks
GLUTARALDEHYDE FOR CILIATES (2%) (Feng et al. 1971)			
50% glutaraldehyde . . . 4.0 ml	Optimum fixation, 1 h.	To fix, pipet ciliates directly onto slides or into scintillation vials.	If scanning EM is planned, postfix ciliates in Bouin's before protargol staining. For transmission EM, postfix ciliates in osmium tetroxide. Osmium tetroxide fumes are hazardous to eyes, nose, and throat; use only in fume hood and wear proper personal protective equipment.
Filtered ambient or artificial seawater (see p. 144) . . . 96.0 ml			
1% GLUTARALDEHYDE/4% FORMALDEHYDE (1G4F) (McDowell and Trump 1976)			
<i>37-40% buffered formaldehyde stock:</i>			
Formaldehyde . . . 5 gal (potential carcinogen)			
Na ₂ HPO ₄ (disodium phosphate) . . . 284.0 gm			
Phenol red . . . 0.5 gm			
NaOH (sodium hydroxide) 1.2 gm			
<i>1G4F working solution:</i>			
37-40% buffered formaldehyde stock 120.0 ml (potential carcinogen)	Optimum fixation, 24-48 h (cytological preps, 30 min); room temp.; pH 7.2-7.4.	For tissues, optimum thickness, 2-3 mm. Store tissue in fixative at room temp. until ready to embed. Prior to embedment, wash (approx. 4 h) in ambient seawater. For ciliates or cell suspensions, prepare double strength by combining first 3 ingredients. Fix volume/volume: 1 drop of ciliate culture to 1 drop of double strength 1G4F working solution. Wash cytological preps in tap water 30-60 min before staining.	Good fixative for tissues viewed by light or EM. Recommended for fixation of protein. Store working fixative at 4°C; stable for 3 mo. For 10% buffered formalin, dilute 100 ml of 37-40% buffered formaldehyde stock with 900 ml of diluent (distilled water or seawater), depending on tissue to be fixed. Note: If not washed well, fixative will interfere with Schiff reaction in periodic acid Schiff (PAS), malt PAS, and Feulgen stains. May use aldehyde blocker (see p. 90).
50% glutaraldehyde . . 20.0 ml			
Tap water 360.0 ml			
Filtered ambient or artificial seawater (see p. 144) . . . 500.0 ml			

Table 5-2. Fixative formulas and methods (cont.).

Fixative	Fixation time	Preparation for sectioning	Remarks
HELLY'S (Zenker formalin) (Coolidge and Howard 1979)			
Zenker base . . . 95.0 ml 37-40% formaldehyde . . . 5.0 ml Add just before using (potential carcinogen)	Optimum fixation, 6-18 h; room temp.; pH, acid.	Optimum tissue thickness, 2-4 mm. To prepare for embedment, wash well in running water 6-24 h, depending on thickness of tissue. Store (if necessary) in 70% ETOH. When fixative becomes turbid, it loses its effectiveness; discard.	See instructions for Zenker base. Remove mercury crystals before staining. See <i>Notes on Fixation</i> (p. 66) to recover mercury from used fixing fluid. Mercury-based fixatives pose environmental and safety concerns. Use special caution in handling and disposing of mercury. Avoid using metal containers.
METHANOL			
100% methanol . . 70.0 ml	Optimum fixation, 5-15 min for cytological preps. pH, neutral.	Wash cytological preps in tap water 5-30 min before staining.	Recommended fixative for fish blood smears, cytological preps, and molecular studies. Tends to make tissues brittle.
RUSSELL'S MODIFIED-ZENKER (Russell 1941)			
Zinc chloride . . . 50.0 ml Potassium dichromate . . . 25.0 gm Sodium sulfate . . 10.0 gm Glacial acetic acid 50.0 ml Distilled water 1000.0 ml	Optimum fixation, 6-24 h; room temp.; pH, acid.	Optimum tissue thickness, 2-4 mm. To prepare for embedment, wash well in running water 6-24 h, depending on thickness of tissue, to prevent precipitate from forming.	Russell's modified-Zenker substitutes zinc chloride in place of mercuric chloride, eliminating environmental and safety concerns associated with mercury compounds. Results, particularly nuclear detail, are not as good as those achieved with Zenker.
Z-FIX^a			
Contains formaldehyde, ionized zinc, buffer, and proprietary ingredients	Optimum fixation, 6-8 h; room temp.; pH, acid.	Optimum tissue thickness, 4-5 mm. To prepare for embedment, wash in running water 5-30 min, depending on thickness of tissue. Store tissue (if necessary) in 70% ETOH.	Purchase ready-made; dilute 1:4 before use. Recommended as a primary fixative for histology, molecular analyses, and immunohistochemistry. Phosphate salts will precipitate zinc.

Table 5-2. Fixative formulas and methods (cont.).

Fixative	Fixation time	Preparation for sectioning	Remarks
ZENKER (base) (Coolidge and Howard 1979)			
Mercuric chloride50.0 gm	Optimum fixation, 6-24 h; room temp.; pH, acid.	Optimum tissue thickness, 2-4 mm. To prepare for embedment, wash well in running water 6-24 h, depending on thickness of tissue. Store tissue (if necessary) in 70% ETOH.	Recommended for fixation of protein; yields exceptional cytologic detail. Overfixing dulls nuclear detail. Remove mercury crystals before staining. <i>Note:</i> Good mordant for metachromatic staining. See <i>Notes on Fixation</i> (p. 66). See Russell's modified-Zenker (p. 64) as possible substitute. Mercury-based fixatives pose environmental and safety concerns. Use special caution in handling and disposing of mercury. Avoid using metal containers.
Potassium dichromate25.0 gm			
Sodium sulfate10.0 gm			
Distilled water1000.0 ml			
ZENKER (acetic) (Coolidge and Howard 1979)			
Zenker base95.0 ml	Optimum fixation, 6-18 h; room temp.; pH, acid.	Optimum tissue thickness, 2-4 mm. To prepare for embedment, wash well in running water 6-24 h, depending on thickness of tissue. Store tissue in 70% ETOH.	Recommended as a good nuclear fixative. Remove mercury crystals before staining. <i>Note:</i> Good mordant for metachromatic staining. See <i>Notes on Fixation</i> (p. 66). See Russell's modified-Zenker (p. 64) as possible substitute. Mercury-based fixatives pose environmental and safety concerns. Use special caution in handling and disposing of mercury. Avoid using metal containers.
Acetic acid5.0 ml			
Add just before using			

C. Special Note on Seawater

When filtered seawater is not readily available, the following substitutes are recommended:

Saltwater, using Crystal Sea[®]:

Approx. 40 gm/L = 30 ppt (normal saline)

Approx. 20 gm/L = 15 ppt (normal saline)

Approx. 14 gm/L = 8.5 ppt (normal saline)

Note: For best results, check salinity of each batch of seawater with a salinometer. The sea salt is hygroscopic and readily takes on water (see p. 144 for dilution table).

Saltwater BSS (balanced salt solution) (Tripp et al. 1966):

Sodium chloride (NaCl) 23.50 gm/L

Potassium chloride (KCl) 0.67 gm/L

Calcium chloride (CaCl₂) (anhydrous) 1.10 gm/L

Magnesium chloride (MgCl₂) (anhydrous) 2.03 gm/L

Magnesium sulfate (MgSO₄) (anhydrous) 2.94 gm/L

Sodium bicarbonate (NaHCO₃) 0.02 gm/L

Potassium phosphate dibasic (K₂HPO₄)

(anhydrous) 0.19 gm/L

Glucose 0.50 gm/L

Trehalose 0.50 gm/L

Phenol red 0.05 gm/L

To make up 7 ppt seawater, use 7 gm of BSS in 1 L of tap or distilled water; adjust pH to 7.2 or 7.4 with buffers (see p. 96).

Note: This formula has been modified by deleting two sugars. Three percent of BSS solution will make equivalent of 30 ppt ocean seawater (C. A. Farley, NOAA, Oxford, MD, pers. commun. 1980).

D. Notes on Fixation

Mercury-based fixatives are used less frequently because of environmental regulations and disposal costs. Use mercury fixatives only when necessary. Zenker, Zenker acetic, and Helly's are excellent for penetration of tissue, protein fixation, and preservation of nuclear detail if fixation times are observed. The mercury must be removed prior to staining. Where permitted, the following procedure may be used to recover mercury from spent fixing fluids containing mercuric chloride, adopted from Sanders (1972).

- In fume hood: collect fixatives containing mercury.

- Add 20 ml of 13% thioacetamide/L of mercuric chloride waste. (Thioacetamide stored in a capped glass container is stable for approximately 1 yr.)
- Mix thoroughly, cap, and allow the solution to stand for 24 h.
- After 24 h, filter with fluted filter paper. Store residue containing mercuric salt in an appropriate container until properly disposed. The clear filtrate can be discarded.

Davidson's fixative is compatible with most stains recommended in Chapter 8 and penetrates most tissues within 48 h.

The 1% glutaraldehyde/4% formaldehyde (1G4F) fixative is suitable for conversion of paraffin-embedded tissue to plastic embedment for use in light and electron microscopy (EM). Penetration is slower and less predictable with 1G4F (see p. 63); therefore, care should be taken to cut tissues thin (2-3 mm) during initial necropsy.

For convenience in shipboard or field situations, 10% seawater formalin or Bouin's is recommended. No refrigeration is necessary and, once fixed, the tissues can be held in the fixative until returned to the laboratory. Bouin's, however, is not compatible with Feulgen-related stains.

For molecular profiling (using techniques such as LCM), fix tissues overnight in a 10X volume of 70% ethanol at 4°C. For best penetration of fixative, tissues should not be thicker than 3 mm.

E. Problems and Resolutions

In recent studies, pathogenic organisms have been cultured from paraffin-embedded tissues fixed in substitute fixatives (A. Downing, Armed Forces Institute of Pathology, Bethesda, MD, pers. commun. 2001). Caution should be taken in using some alternatives to traditional aldehyde-based fixatives since inferior quality of fixation as well as potential health risks may occur. These fixatives may fail to: (1) properly coagulate proteins, (2) protect against shrinkage that causes distortion, (3) prevent postmortem changes, (4) penetrate well, and (5) kill pathogens.

Table 5-3 includes some problems or artifacts resulting from fixation or inadequate fixation, as well as some suggestions for resolving them.

Table 5-3. Fixative problems and resolutions.

Problem or artifact	Possible causes	Solution, if any
Large irregular black deposits throughout tissue.	Mercuric chloride remains in tissue fixed with mercury-based solutions.	Wash tissue 6-24 h before processing. Treat with Lugol's iodine and 2% sodium thiosulfate when hydrating prior to staining (see p. 89).
Small black granular pigmentation in and around blood vessels.	Formalin pigment from stock formaldehyde becomes too acidic (age will decrease pH of formalin).	Once formalin is opened, add marble chips periodically to help neutralize fixative. Wash tissue ½-4 h, depending on size of tissue (Luna 1992).
Tissue swells when put in water-bath.	Soft tissues are more difficult to penetrate with fixing agents.	24 h after initial fixation, immerse tissue in fresh fixative and agitate periodically. Cut tissues thinly during initial necropsy (Yevich and Barszcz, unpubl. data) ^c .
Tissue too soft; not rigid in paraffin block.	Improper penetration of fixative. Fixation followed by possible improper infiltration.	For thorough fixation of soft tissue such as shellfish "gapers," immerse whole specimen in fixative of choice until firm, approx. ½-1 h. Wash thoroughly; process as usual. Immerse large molluscan tissues in fresh fixative after 24-h initial fixation. Agitate specimens periodically during day to maximize fixative penetration. When specimen has been adequately preserved, wash well and follow routine embedment process (Yevich and Barszcz, unpubl. data) ^c .

F. Footnotes

^aAnatech Ltd., 1020 Harts Lake Road, Battle Creek, MI 49015. (800) 262-8324. www.anatechltdusa.com

^bMarine Enterprises International, Inc., 8800 A. Kelso Drive, Baltimore, MD 21221-3125. (800) 200-7258. www.meisalt.com

^cYevich, P.P. and C.A. Barszcz. Preparation of aquatic animals for histopathological examination. Mimeograph DN 0543A (1981), U.S. Environmental Protection Agency, Cincinnati, OH 45268. 53 p.

G. References

Coolidge, B.J. and R.M. Howard. 1979. *Animal Histology Procedures of the Pathological Technology Section of the National Cancer Institute*. 2d ed. NIH Publ. No. 80-275, National Institutes of Health, Bethesda, MD. 209 p.

Feng, S.Y., J.S. Feng, C.N. Burke, and L.H. Khairallah. 1971. Light and electron microscopy of the leucocytes of *Crassostrea virginica* (Mollusca: Pelecypoda). *Z. Zellforsch.* 120: 222-245.

Lee, J.J., E.B. Small, D.H. Lynn, and E.C. Bovee. 1985. Some techniques for collecting, cultivating and observing protozoa, pp.1-7. *In*: J.J. Lee, S.H. Hutner, and E.C. Bovee (eds.), *An Illustrated Guide to the Protozoa*. Society of Protozoologists, Lawrence, KS.

Lillie, R.D. 1965. *Histopathologic Technic and Practical Histochemistry*. 3d ed. McGraw-Hill, New York. 715 p.

Luna, L.G. 1992. *Histopathologic Methods and Color Atlas of Special Stains and Tissue Artifacts*. American Histolabs, Inc., Gaithersburg, MD. 767 p.

McDowell, E.M. and B.F. Trump. 1976. Histologic fixatives suitable for diagnostic light and electron microscopy. *Arch. Pathol. Lab. Med.* 100: 405-414.

Russell, W.D. 1941. The substitution of zinc chloride for mercuric chloride in Zenker's fluid. *Bull. Int. Assoc. Med. Mus.* 21: 47-49.

Sanders, B.J. 1972. *Animal Histology Procedures of the Pathological Technology Section of the National Cancer Institute*. DHEW Publ. No. 72-275, National Institutes of Health, Bethesda, MD. 185 p.

Shaw, B.L. and H.I. Battle. 1957. The gross and microscopic anatomy of the digestive tract of the oyster *Crassostrea virginica* (Gmelin). *Can. J. Zool.* 35: 325-347.

Tripp, M.R., L.A. Bisignani, and M.T. Kenny. 1966. Oyster amoebocytes in vitro. *J. Invertebr. Pathol.* 8: 137-140.

CHAPTER 6. EMBEDDING

A. Introduction

Embedding is the process of placing tissue in a firm medium to keep it intact when cutting sections for histological examination. Embedding of marine animal tissues is comparable to that used for humans.

B. General Procedures

There are a variety of tissue processors available. Some are designed to use autopsy trays or baskets and, others, reusable tissue cassettes or disposable cassettes. Newer automatic tissue processors can be programmed from autopsy through fixation, dehydration, clearing, and infiltration into paraffin. Multiple options for processing tissues are available, including separate processing schedules with control of vacuum and temperature. Older tissue processors start dehydration after tissues have been hand-changed from fixative through 50% and 70% ethyl alcohol (ETOH). If an automatic processor is not available, each step of dehydration, clearing, and infiltration can be performed by hand in a fume hood with or without a vacuum oven. Time to complete each step will change depending on tissue size, amount of agitation, and whether a vacuum is used.

Paraffin with a melting point of 56.6°C is the most satisfactory product for year-round use and is kept ready for embedding in a paraffin dispenser. The processing basket, containing trays of tissues or tissues processed in disposable cassettes, is removed from the tissue processor and placed in a paraffin bath. A smaller paraffin bath is used for ease in handling individual trays of tissues. Embedding centers are available with built-in paraffin baths as well as cooling units. Commercially made molds and plastic embedding rings are employed. Molds come in all sizes to accommodate tissues; however, tissues too large for standard molds may be embedded utilizing commercially made cast lead *L's* and copper plates, and mounted on fiber blocks for sectioning. Rings or cassettes are labeled with a code corresponding to the tissues to be embedded. Heated forceps are used for transferring

tissues from the tray to the mold to prevent cooling of the paraffin and attachment of the forceps to the tissue.

Prior to embedment, a release dip (95 ml of 95% ETOH and 5 ml of glycerin) for ease in removing difficult blocks may be used to coat molds. Slowly remove one tray from the basket or several tissue cassettes and place in a small paraffin bath. With heated forceps, remove identification label from corresponding tissue in the tray. Find the matching embedding ring and choose a mold of appropriate size. Tissue cassettes allow the tissues to be transferred into molds (Fig. 6-1) and the labeled cassette becomes the top for each paraffin block. Hold the mold by its handles with thumb and middle finger and cover the bottom of the mold (no more than one-fourth full) with heated paraffin from the dispenser. With heated forceps, turn the tissue over and gently squeeze to release any trapped air bubbles. Quickly orient the tissue as desired (Fig. 6-2), place the embedding ring or cassette onto the base mold with the correct identification number (Fig. 6-3), and hold in place with index finger. Fill the mold to the top with paraffin (Fig. 6-4) and place onto the cooling unit of the embedding center or into a shallow container of ice water for approximately 10 min (Fig. 6-5). These steps should be completed as quickly as possible to prevent the paraffin from hardening, layering, and entrapping bubbles within the block. After the block has cooled, use gentle pressure to remove it from the mold for trimming and sectioning. Place blocks in a filing tray (Fig. 6-6) and refrigerate prior to sectioning. This embedding procedure yields perfectly shaped blocks cast into plastic mounting rings that can be quickly oriented in the microtome vise for sectioning.

Most automatic tissue processors have a purge cycle that will clean the paraffin and xylene from embedding baskets and cassettes. If this is not an option, the autopsy basket and trays should be placed in a covered bath of used xylene and soaked overnight inside a chemical fume hood to dissolve any attached paraffin. For cleaning, rinse in a 50:50 mixture of 100% ETOH and xylene, then in 100% ETOH, and place on paper toweling to dry. Trays will then be ready for use.

C. Infiltration Schedules

The schedules shown in Table 6-1 are recommended for specific types of tissue. The best results for dehydration, clearing, and infiltration are obtained only by allowing the tissue adequate exposure time to reagents, combined with frequent agitation of tissue.

Since molluscan tissues are soft and dense, a maximum of 5-mm thickness is recommended for complete infiltration of paraffin. Fresh reagents are used for each step of embedment to allow for solution evaporation and carryover. Paraffin baths should be routinely checked to prevent overheating and breakdown of paraffin. Temperature of paraffin should not exceed the recommended range.

D. Problems and Resolutions

Table 6-2 describes problems that could result from incomplete dehydration, clearing, or infiltration during the embedment process.

E. References

Luna, L.G. 1992. *Histopathologic Methods and Color Atlas of Special Stains and Tissue Artifacts*. American Histolabs, Inc., Gaithersburg, MD. 767 p.

Sheehan, D.C. and B.B. Hrapchak. 1973. *Theory and Practice of Histotechnology*. C.V. Mosby Co., St. Louis, MO. 218 p.

Table 6-1. Infiltration schedules for specific types of tissue.

19-h routine schedule from 70% ETOH for molluscan cross-sections or fish tissue approx. 5-mm thick

80% ETOH	1 h
1st 95% ETOH	2 h
2d 95% ETOH	2 h
1st 100% ETOH	2 h
2d 100% ETOH	2 h
3d 100% ETOH	1 h
1st xylene	1 h
2d xylene	2 h
Paraffin	2 h
Paraffin	2 h
Paraffin	2 h

7-h schedule from 70% ETOH for molecular analyses of tissue not to exceed 3-mm thick and small tissue such as hand-processed larvae (use vacuum oven for infiltration of paraffin)

80% ETOH	½ h
1st 95% ETOH	½ h
2d 95% ETOH	½ h
1st 100% ETOH	½ h
2d 100% ETOH	1 h
3d 100% ETOH	½ h
1st xylene	½ h
2d xylene	½ h
Paraffin	½ h
Paraffin	½ h
Paraffin	1½ h

4-h schedule (under vacuum) from 70% ETOH for molluscan and crustacean tissue not to exceed 5-mm thick

80% ETOH	5 min
1st 95% ETOH	10 min
2d 95% ETOH	20 min
1st 100% ETOH	15 min
2d 100% ETOH	20 min
3d 100% ETOH	20 min
4th 100% ETOH	30 min
1st xylene	15 min
2d xylene	20 min
Paraffin	30 min
Paraffin	20 min
Paraffin	35 min


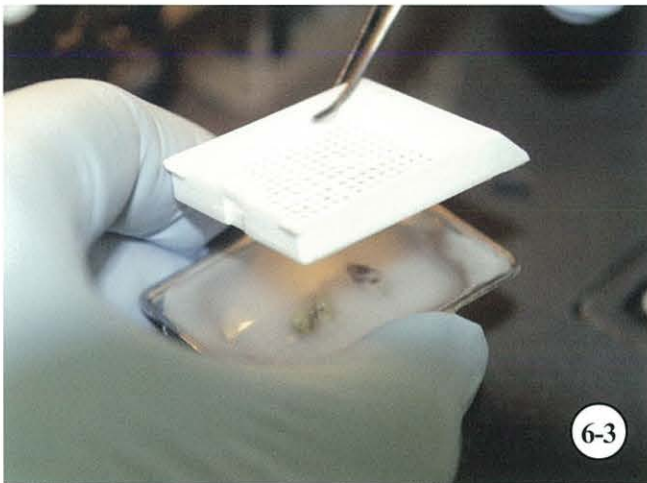


2-h schedule (under vacuum) from 70% ETOH for small specimens, such as crustacean organs

80% ETOH	5 min
1st 95% ETOH	5 min
2d 95% ETOH	5 min
1st 100% ETOH	10 min
2d 100% ETOH	10 min
3d 100% ETOH	10 min
4th 100% ETOH	10 min
1st xylene	10 min
2d xylene	10 min
Paraffin	10 min
Paraffin	20 min
Paraffin	15 min

For above schedules, hold tissue in fresh paraffin bath until embedment; maximum holding time, 3 h. If embedment cannot be completed within 3 h, allow paraffin to solidify until process can be completed. If ETOH is not available, isopropyl alcohol in combination with toluene (instead of xylene) may be used for processing tissues.

TABLE 6-2. Embedment problems and resolutions.

Problem or artifact	Possible causes	Solution, if any
Tissue pulls apart while sectioning and has large empty spaces. Loss of tissue orientation.	Improper infiltration, dehydration, clearing, and impregnation (usually large tissues, whole mollusks, or cross-sections too thick).	Large tissues should be processed on a longer embedment schedule, with aid of vacuum system (Sheehan and Hrapchak 1973).
Tissue too soft. Block smears rather than cutting cleanly.	Soft tissues are not only difficult to fix, but infiltration takes longer.	Soft tissues should be cut thin and processed quickly for complete fixation. Adequate time should be allowed for impregnation of paraffin.
Crumbling or tearing section.	Incomplete dehydration, clearing, and/or infiltration. Paraffin too hot during infiltration and/or embedding.	Consider size and tissue density when processing. Always check paraffin temp. (Luna 1992, Sheehan and Hrapchak 1973).
Tissue smells of xylene and is too soft.	Too much carryover of xylene; paraffin has not completely impregnated tissue.	Immerse tissue in clean paraffin bath, agitate, and extend processing time (Sheehan and Hrapchak 1973).
Round holes in tissue.	Air bubbles trapped under tissue while embedding in paraffin.	Once tissue is immersed in paraffin, roll it over once and orient as desired; this should permit air bubbles to escape. If bubbles remain, melt down and reembed.



Embedding.

Figure 6-1. Tissues ready to be taken from cassette and placed into mold (foreground) for embedding. **Figure 6-2.** Tissues oriented in mold and paraffin dispensed to cover tissues. **Figure 6-3.** Cassette used in fixation is placed onto embedding mold. **Figure 6-4.** Dispense paraffin to finish filling mold. **Figure 6-5.** Cool paraffin blocks for easy release from embedding mold. **Figure 6-6.** Block storage trays used to file embedded specimens.

CHAPTER 7. SECTIONING

A. Introduction

Successful sectioning of tissue for histological examination can only be accomplished with patience and acquired skill. Sheehan and Hrapchak (1973) in *Theory and Practice of Histotechnology* pose four major requirements for producing good histological slides: (1) a skilled technologist, (2) a sharp microtome knife, (3) a suitable microtome, and (4) properly prepared material. Additionally, practice, experience, and knowledge of the tissues are necessary to learn the art of microtomy.

B. General Procedures

Once tissues are embedded and paraffin is firm, align blocks in consecutive order according to their code. Rough cut at room temperature and precool to 5°C before sectioning (a warm block will not section properly). Precooling will prevent blocks from cracking when placed directly in an icebath. Carefully mount ring or cassette in microtome vise, orienting tissue gills or identification number to the right. Slight angling of the head of the microtome may be necessary to expose all of the tissue without cutting the block too thin. Rotate the block so that its bottom surface is parallel to the knife-edge. Since each microtome has a recommended knife angle for cutting, adjust microtome for the type of blade used. Trim block until tissue is fully exposed. Set the microtome for section thickness (typically 5-6 μm) and begin cutting sections. Lift the ribbon of paraffin sections that has been created by cutting with continual, even strokes (Fig. 7-1). Float the ribbon of sections on a heated waterbath (Fig. 7-2) adjusted to a temperature of approximately 42°C. Ribbons are preferred to individual sections since the thickness of the cut is more uniform throughout. The waterbath should be changed after each day's use, and kept clean and clear of air bubbles to avoid histological artifacts.

Before placing tissue on a slide, and to ensure accurate identity, scratch the code number of each tissue on the reverse side of a frosted, coated slide using a diamond pen. Separate and select the desired tissue section (Fig. 7-3). Dip the properly prepared and coded slide, frosted side up,

into the waterbath under the best tissue section on the ribbon (Fig. 7-4). Guide the section into place on the slide with a small camel-hair brush. Gently raise the slide from the water and roll the brush handle along the edge of the slide to cut the excess paraffin from each side. For slides coated with albumin, a brush or probe may be used to orient the tissue centrally on the slide. Leave at least one-eighth-inch clearance at the end of the slide to prevent the coverslip from coming in contact with the grooves in the storage box. Place the slides in a rack to drain excess water, then into a drying oven set at 42°C for approximately 12 h, or until the sections are completely dry.

The waterbath and oven temperature should not exceed 42°C for tissues embedded in paraffin. Melting tissues on the slides can cause distortion of cells in the tissue.

Remove the completely dry slides with affixed tissue sections from the drying oven. Place slides vertically in a staining holder, frosted end up and facing forward; load front to back in consecutive numerical order. The slides are now ready for staining.

C. Adhesives

Slide adhesives are a product of choice, depending on the type of sectioning planned and the staining procedure intended. This important decision can save time in future recutting and restaining due to lost tissues or poorly stained tissue sections.

1. Poly-L-Lysine (PLL)

Coating with this solution electrostatically charges the glass slides, resulting in a strong adhesion with the anionic sites of tissue sections. PLL is recommended for histological tissue sections as well as immunohistochemical procedures.

Procedure:

- 1) Clean slides in acid alcohol¹ - 5 min
- 2) Distilled water - 3 changes, 6 dips each
- 3) Immerse in dilute PLL working solution² - 5 min
- 4) Drain slides and dry in a dust-free environment - 1 h in 60°C oven, or overnight at room temp. 18-26°C
- 5) Store slides in boxes; use within 2-3 wk

Reagents:

¹Acid alcohol

70% ETOH (ethanol) 99.0 ml
Concentrated HCl, sp. gr. 1.19 1.0 ml

Handle HCl with care.

²PLL working solution

PLL (0.1% w/v in deionized water) 100.0 ml
Distilled or deionized water 900.0 ml

Prepare in plastic container. **Warning: Possible mutagen. Target organs: kidneys and nerves.**

Note: PLL available from Sigma^a cat. # P8920 or as ready-coated slides from Newcomer Supply^b cat. # 5010. Store PLL working solution in refrigerator; stable for 3 mo. Using Sigma product, a maximum of 900 slides/L can be coated in diluted solution. Before using, bring solution to room temp.

2. Mayer's Albumin (Gray 1954)

Recommended for serial sections or tissues to be removed from slides and restained (see pp. 184-185).

Procedure:

In-house preparation (Sanders 1972)

- 1) Break 1 egg and separate yolk from egg white
- 2) Cut strands of egg white as fine as possible with clean sharp scissors
- 3) Add a few crystals of thymol and cut in egg white (do not stir; this will cause bubbles)
- 4) Filter through 3 layers of gauze and measure quantity of egg white
- 5) Mix cut egg white and an equal amount of fresh glycerin; preparation may be refrigerated until used or stored in freezer

Ready-to-use product

- 1) Place 1 drop of Mayer's albumin fixative on a slide; **egg albumin must be kept refrigerated**
- 2) Place a second slide face down on the first and slide the two apart, evenly distributing adhesive on each slide
- 3) Continue thinning albumin with a new slide until a very light coat of albumin is evenly distributed on slide
- 4) Cover and store slides in refrigerator until use—to no longer than 1 wk—to prevent fungal contamination
- 5) Before sectioning, use either heated waterbath or warming tray at 42°C to activate adhesive quality of albumin

Note: Albumin is a good adhesive. Clean waterbath daily to prevent bacterial growth that can contaminate slides. Ready-to-use product is available from Newcomer Supply^b cat. # 1058A.

3. Haupt Gelatin

For best results, coated slides should be stained on the day prepared to avoid bacterial growth.

Procedure (S. Jones, pers. commun. 1999)^b:

- 1) Gelatin - approx. 1 ml
- 2) Dispense onto waterbath surface (42°C)
- 3) Completely immerse slide into waterbath and select tissue
- 4) Dry slides vertically in warm oven at 56°C - 20 min

Note: Haupt gelatin available from Newcomer Supply^b cat. # 1151A. Clean waterbath daily.

4. Aminoalkylsilane

Recommended for ciliate preparations as well as tissue sections for histology or immunohistochemistry.

Procedure:

- 1) Clean slides in acid alcohol (see PLL, pp. 75-76)
- 2) Soak slides in aminoalkylsilane solution - 2 min
- 3) Rinse in distilled water - 2 changes, 2 min each
- 4) Drain slides and dry in a dust-free environment - 30 min in 57°C oven, or overnight at room temp. 18-26°C

- 5) Store slides in dust-free box at room temp.; use within 2-3 wk

Notes:

- 1) Adhesive available in liquid form (cat. # 1007A) or as ready-coated slides (cat. # 5050) from Newcomer Supply^b. Newcomer Supply^b suggests 250 ml of aminoalkylsilane should treat 400 slides. Refrigerate leftover solution; reuse within 2-3 wk; store separately from unused product.
- 2) When affixing tissue to slide, position carefully; it will attach upon contact and be difficult to reposition. Avoid blisters of trapped water under sections.
- 3) To adhere paraffin sections and preserve antigenicity, do not exceed 60°C when drying tissues.
- 4) For frozen tissues, allow to dry on coated slide before fixation.

D. Preparation of Paraffin Tissue Sections

1. Blocks

- Chill blocks in refrigerator prior to sectioning to avoid thick compressed tissue sections (extreme cold will crack the paraffin). Keep blocks in an icebath in numerical sequence when cutting.
- Before rough trimming the tissue, evenly position the microtome chuck and adjust the block holder so that it is parallel to the knife-edge.
- Position block parallel to the knife-edge. Before cutting, the block can be trimmed for different slide requirements (example, serial sections) or for proper orientation of tissue.

2. Microtome

- Know your microtome; keep it properly lubricated, adjusted, and serviced for optimal operation. Some newer microtomes are teflon-coated and work on a forward-drive system that does not require routine lubrication. Check and set knife holder to the angle recommended by the microtome manufacturer. Tighten set screws on knife holder and block vise before cutting. Overtightening the paraffin block may cause it to crack.

3. Knives

Disposable blades are routinely used. Low profile disposable blades for most soft tissues are recommended. The newer microtomes can accommodate both high and low profile designs. Some microtomes need a blade holder adapter for disposable knives. The high profile blades are recommended for cutting hard tissues and the low profile blades are preferred for soft tissues. Each are less expensive and are preferred to hand-honed or reconditioned blades.

Most disposable blades are oil-coated to prevent corrosion. Before using, carefully immerse the knife blade in xylene to remove any oil from the cutting edge. This will keep your waterbath free from oil residue which can get under the tissue sections and disrupt proper staining. To best utilize the knife-edge, rough trim samples on the extreme left edge of the blade. Move to the right of the blade for a new and sharper edge, and cut a ribbon of 5- to 6- μ m sections for the permanent slide.

Tungsten carbide blades are also available for cutting extremely hard tissue (e.g., tissue with bone or eye lenses) but at thinner increments. These blades also need adapters, since they are thicker than disposable knives and thinner than traditional microtome knives. Special instructions are available on the use of these very expensive knives.

- Hand honing of traditional microtome knives usually gives great results for cutting tissue sections but can be very time-consuming. A combination of Ivory and Lava soaps is recommended on a Belgian honing stone. Figure 7-7 illustrates the proper honing action.
- An automatic knife sharpener is satisfactory for sharpening new or reconditioned knives. B. Coolidge and R. Howard (Animal Histology Unit, National Cancer Institute, Bethesda, MD, pers. commun. 1977) suggested the combination of a diamond abrasive (available from ThermoShandon^c cat. #9992000-9992006) and microsharp lubricating fluid (available from ThermoShandon^c cat. #9992007). Best results are attained by using only the coarse setting on the machine.
- Low profile disposable blades (available from Fisher^d cat. # 12-634-11) are consistently sharp and do a good job on most tissues. Harder, more brittle tissues may need a high profile knife. If using older microtomes, a different adapter may be necessary for both high and low profile blades.

4. Sectioning

For routine paraffin-embedded tissues:

- Rough trim the entire sample of paraffin blocks until tissue face is exposed, careful not to cut away too much tissue.
- Cut routine tissue sections at 5-6 μm , selecting the best section within a ribbon for uniform thickness. Never take the first sections after rough trimming since they are usually perforated with holes and are not uniformly cut.
- Cut and transfer tissue ribbons to a waterbath, not exceeding 42°C. The sections should be quickly picked up on slides to reduce the possibility of tissue breakdown. Clean the waterbath daily to eliminate albumin buildup and microbial growth in the water. Filling the waterbath with room temperature water will reduce the accumulation of air bubbles in the bottom of the bath when it has heated to 42°C.
- To easily separate sections of the ribbon, ice forceps prior to selecting individual sections.
- A warming tray set at 42°C is used to dry, adhere, and flatten serial sections of small or problem tissues that tend to split or break apart (see two techniques for special serial sections, pp. 78-79).

For molecular analyses using laser capture microdissection (LCM) from paraffin-embedded tissues (avoid cellular cross-contamination throughout slide preparation):

- Used clean uncoated slides. Clean all instruments and supplies before sectioning tissue blocks. Clean microtome between each specimen. Wear new gloves and use a new disposable blade for each tissue block.
- Cool individual blocks on clean ice.
- Cut and place section on center of slide in a pool of sterile or distilled water. Use clean brush or forceps to manipulate sections.
- Allow sections to expand on a warming tray at 42°C. Drain and place in warming oven at 37-42°C until dry, approximately 8 h.
- Store slides in clean containers until ready to be stained. Mayer's hematoxylin and eosin (MHE) is the stain of choice.

a. Tissue for Serial Sections (Fig. 7-5):

Serial sections may be requested to evaluate desired tissues. Albuminized slides allow manipulation of small tissue sections, whereas PLL or other electrostatically coated slides do not.

Procedure:

- 1) Chill blocks. Hand trim block as close to tissue as possible. Place block parallel to knife after trimming
- 2) Line up 24- x 60-mm albuminized slides with frosted ends, e.g., 10 at a time, and code consecutively. It is best to use albumin as an adhesive for serial sections. If immunostains are planned, use electrostatically charged slides
- 3) Cover slides with a small pool of distilled water
- 4) Using chilled block, trim paraffin to tissue with microtome and begin saving ribbons
- 5) Count, then cut, number of sections that will fit under intended coverslip; sequentially lay ribbon on slide. Provide investigator a key to arrangement of tissues for evaluating slides
- 6) Uniformly continue procedure for number of slides necessary to cut through tissue
- 7) Carefully align ribbon strips and drain excess water. Wipe back of slide dry
- 8) Place sections on warming tray at 42°C to allow to flatten. If possible, manipulate sections to line up evenly
- 9) Eliminate air bubbles, folds, or rolls by teasing out with gentle manipulation of two wet brushes
- 10) Remove slides from warming tray before sections develop air bubbles under tissue
- 11) Place slides onto racks, then into oven at 42°C to dry

Note: For problem tissues that tend to split or break apart, ice block between ribbons. Lay sections in sequence on black wax-coated waterproof paper (similar to that found in boxes of photographic paper), and pick up with a wet brush to transfer to consecutive slides. If problems persist, move to a new cutting edge of the knife and realign block face before continuing to section.

b. Special Blocks for Serial Sections (Fig. 7-6):

To fulfill study slide requests for instructional purposes, it may be necessary to produce a large number of slides from the same block. Since blocks may be valuable examples of a specific disease, parasite, or shellfish condition, cut a minimum of tissue from the block.

Procedure:

- 1) Coat slides with PLL or albumin and label desired number
- 2) Tape down black wax-coated waterproof paper (see *Note*, p. 78) to the counter top. Sections do not readily stick to this type of paper
- 3) Carefully align block in chuck of microtome
- 4) Line up slides consecutively, but not touching. Add a small pool of water to each slide (avoid overflowing). Counter surface should be flat for easy slide manipulation
- 5) Begin sectioning chilled block. Lay ribbons on paper in sequential order from bottom to top. Use a continuous cutting motion so that sections will be uniform in thickness
- 6) Separate sections by cutting between each with a sharp razor blade
- 7) With a wet brush, lift cut sections and float in sequence onto coded slides
- 8) Orient tissue properly and drain water from slides
- 9) Place slides on warming tray until sections expand to full size. **Warning:** For ripe oysters, clams, or very soft tissues, reduce time on warming tray. Breakdown of soft tissues may occur after lengthy exposure to heat
- 10) Place slides onto racks and into oven at 42°C to dry

E. Problems and Resolutions

Technicians often will encounter problems when sectioning tissues. The ability to recognize the source of the difficulty and to remedy the cause is important. A list of problems, causes, and solutions is shown in Table 7-1.

F. Footnotes

- ^aSigma, P.O. Box 14508, St. Louis, MO 63178-9916. (800) 325-3010. www.sigma-aldrich.com
- ^bNewcomer Supply, 2217b Parview Road, Middleton, WI 53562. (800) 383-7799. www.newcomersupply.com
- ^cThermoShandon, 171 Industry Drive, Pittsburgh, PA 15275. (800) 245-6212. www.thermoshandon.com
- ^dFisher Scientific, 3970 Johns Creek Court, Suwanee, GA 30024. (800) 766-7000. www.fishersci.com

G. References

- Gray, P. 1954. *The Microtome's Formulary and Guide*. Blakiston Co., New York. 794 p.
- Luna, L.G. 1992. *Histopathologic Methods and Color Atlas of Special Stains and Tissue Artifacts*. American Histolabs, Inc., Gaithersburg, MD. 767 p.
- Presnell, J.K. and M.P. Schreiber. 1997. *Humason's Animal Tissue Techniques*. 5th ed. Johns Hopkins Univ. Press, Baltimore, MD. 572 p.
- Sanders, B.J. 1972. *Animal Histology Procedures of the Pathological Technology Section of the National Cancer Institute*. DHEW Publ. No. 72-275, National Institutes of Health, Bethesda, MD. 185 p.
- Sheehan, D.C. and B.B. Hrapchak. 1973. *Theory and Practice of Histotechnology*. C.V. Mosby Co., St. Louis, MO. 218 p.

Table 7-1. Sectioning problems and resolutions.




Problem or artifact	Possible causes	Solution, if any
Grooves through tissue; tissue torn and separated.	Sand, shell, or miscellaneous debris left in tissue prior to fixation. Sources include: scallops—sensory eyes; mussels—byssus; clams—crystalline style; and various bivalves—pearls. Knives need reconditioning.	Inspect tissue before cutting cross-section. Check knives under dissecting scope for damage after sectioning problem tissue. Use disposable blades for problem tissue.
Grooves through tissue, continuing from one block to another.	Nick in knife blade.	Move to new area of knife; sharpen. If not removed by sharpening, recondition knives (Luna 1992).
Entire section splits, including paraffin matrix.	Dirty knife. Nick in knife blade. Lint, hair, or other debris.	Carefully clean back and front of knife; move to another area of knife or sharpen knife (Luna 1992).
Tissue rubbed, smudged, pulled apart or too thick.	Dirty knife; back probably coated with paraffin.	Clean back of knife after rough trimming of each block.
Compression (tissue section noticeably smaller than block).	Block too warm. Section too thin. Knife angle too close to vertical. Dull knife.	Sharpen knife. Strive to have tissue section comparable in size to exposed tissue in block. Keep block chilled before sectioning (Luna 1992).
Shearing (horizontal parallel folds in tissue sections).	Dull knife or wrong knife angle.	Sharpen knife. Check angle of knife.
Tissue has raised round areas.	Air bubbles trapped under tissue.	Waterbath should be bubble-free. Gently lay ribbon in bath to avoid formation of large bubbles or folds. If bubbles form, gently tease from tissue area by brush manipulation (Gray 1954).
Folds in tissue.	Dense tissue compresses less than surrounding paraffin.	Carefully break paraffin edge to tissue to accommodate stretching of tissue to full size (Presnell and Schreibman 1997).
Moth-eaten appearance.	Sections taken from rough cut tissue instead of a smooth block face.	Take several 6- μ m sections after rough trimming of block to avoid problem. Select tissue in middle of ribbon (Luna 1992).
Tissue separates quickly on surface of waterbath.	Waterbath too hot, breaking down paraffin and tissue. Tissue may not be properly infiltrated.	Maintain 42°C temp. in waterbath. Quickly transfer tissue to slide.

Table 7-1. Sectioning problems and resolutions (cont.).

Problem or artifact	Possible causes	Solution, if any
Sections alternately thick and thin, usually with compression of thin sections.	Set screws are loose on knife holder or block is not tight. Block of tissue is too hard or tilt of knife is insufficient to clear base. Block is too large or too warm. Knife adapter may need adjustment.	Check microtome before cutting. Adjust angle. Cool block for at least ½ h before sectioning (Gray 1954, Sheehan and Hrapchak 1973, Luna 1992). Change knife adapter.
Sections lift from knife on upstroke of microtome.	Knife angle too vertical. Dull or dirty knife.	Check knife angle. Sharpen knife (Sheehan and Hrapchak 1973).
Block lifts ribbon.	Ribbon charged by static electricity (check by testing adherence to other surfaces). No clearance angle. Wax fragments on upper edge of block. Wax fragments on edge of knife (either front or back).	Increase room humidity. Adjust clearance angle of knife. Scrape under surface of block with safety razor blade. Clean knife with xylene (Gray 1954).
Tissue with rows of round raised areas.	Shearing when section is put on waterbath or warming tray.	Avoid selecting sections with shearing lines that extend into tissue.
Tissue looks distorted. Paraffin and tissue appear melted.	Waterbath, warming tray, or slide oven too hot.	Routinely check paraffin temp. before tissue sample is processed. Maintain warming tray and waterbath temp. at 42°C.
Ribbon curved.	Edges of block not parallel to knife. Knife not uniformly sharp, causing more compression on one side of block than other.	Evenly trim block. Use another portion of knife-edge or resharpen knife. Let block cool (Gray 1954, Sheehan and Hrapchak 1973).
Sections distorted.	Blunt knife. Ribbon too stretched when placed on waterbath. Tissue not properly fixed before embedding.	Use suitable knife. Handle ribbons in short lengths; lay down gently. Use more suitable fixative or fix longer. Take extra care in dehydrating, clearing, and embedding (Gray 1954).
Sections bulge in middle.	Paraffin cool in center, periphery warm. Knife not uniformly sharp. Tissue may be too hard for paraffin embedment. Some clearing agent remains in tissue.	Let block cool evenly in icebath. Use another portion of knife-edge or resharpen knife. Reembed tissue in appropriate media or melt paraffin to remove excess clearing agent (Gray 1954).

Table 7-1. Sectioning problems and resolutions (cont.).

Problem or artifact	Possible causes	Solution, if any
Tissue breaks away from paraffin or is shattered by knife.	If tissue appears chalky and shatters under knife, it is not impregnated with paraffin. If tissue shatters under knife, but is not chalky, it is too hard for paraffin sectioning. If tissue pulls away from paraffin, but does not shatter, the wrong dehydrant, clearing agent, or paraffin has been used.	Discard block and start again. If tissue is irreplaceable, try dissolving paraffin, rehydrating, reclearing, and reembedding. Avoid xylene in clearing muscle tissue (Gray 1954).
No ribbon forms because paraffin crumbles. Sections, though individually perfect, do not adhere; or sections roll into cylinders.	Paraffin contaminated with clearing agent. Knife angle wrong. Dull or dirty knife. Block too warm.	Reembed tissue. <i>Note:</i> Paraffin readily absorbs hydrocarbon vapors (Gray 1954). If section is cut very slowly, and edge of section is held flat with a brush, ribbons may sometimes form. Adjust knife angle.
Sections appear wrinkled.	Knife too blunt for cutting. Waterbath too hot for flattening tissues, fusing folds in sections.	Prevent by sharpening or replacing knife, and cut new sections. Control waterbath temp. used for flattening tissues. Clean slide so water flows uniformly over it.
Distortion or imperfection of tissue section; chatter.	Occurs frequently with very ripe oyster tissues. Gonads are soft tissue and, therefore, difficult to infiltrate.	Allow block to warm to room temp. and begin a new ribbon. Knife should be sharp and tight in holder.
Sections attracted to microtome parts or curl around brush uncontrollably.	Static electricity may be a problem in dry and cool weather conditions.	Use room humidifier and two brushes while sectioning to control ribbons taken from microtome to be placed in waterbath.
Hard tissues chatter and do not section flat.	Soft and hard tissues in same block. Blood in tissues.	Soak tissues in dilute detergent solution or low concentration of ammonia water to soften. For bone or cartilage, soak in 50% water and glycerin or 10% versenate (see p. 184). Rechill and cut. <i>Note:</i> Do not oversoak tissues; they will swell and disintegrate when placed in waterbath, fall off during staining, and distort pathology.



Sectioning.

Figure 7-1. Cut ribbon of tissue from chilled paraffin block. **Figure 7-2.** Lay tissue sections onto heated waterbath. **Figure 7-3.** Separate paraffin sections to select desired tissue section. **Figure 7-4.** Direct chosen section onto coded slide (frosted side up). **Figure 7-5.** Serial sections of tissues on slides. **Figure 7-6.** Lay ribbon of serial sections on black wax-coated waterproof paper (foreground). Separate sections with razor blade and place onto slide flooded with water (background).

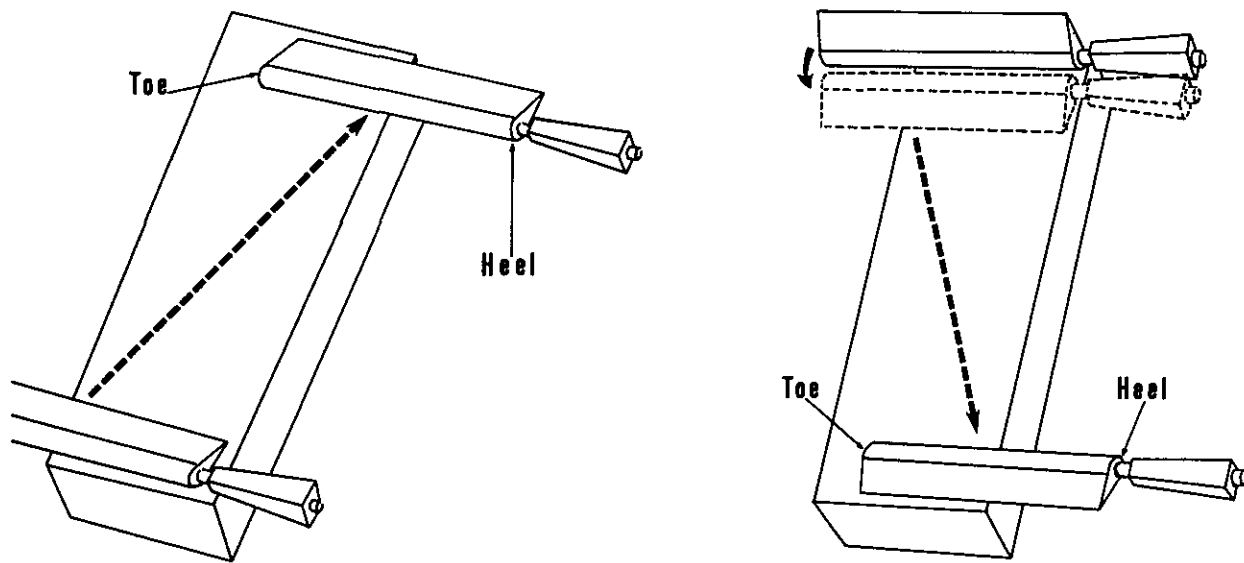


Figure 7-7. Action used in hand honing knife blades. (Illustration by R. Tolley, Cambridge, MD.)

CHAPTER 8. STAINING

A. Introduction

Staining is the artificial coloration of histological tissues to allow for the examination of condition, parasites, and disease. Methods, general tissue stains, and a variety of special stains for the demonstration of specific tissue elements are described. A fume hood and personal protective equipment (PPE) are essential in the preparation of chemicals and staining of slides. Footnotes and pertinent references for each stain appear on pages 125-126. Color plates of selected stains are included at the end of the chapter to show expected staining results on marine tissues.

B. Methods and Use

Each stain description includes the principal reference, staining procedure, results, necessary reagents, and additional information presented as "Notes." Table 8-1 gives a synoptic listing of these stains, keyed to the pages on which their descriptions occur, and Table 8-2 provides a synoptic listing of stains for specific tissues and tissue elements, keyed also to the appropriate pages.

Table 8-1. Synoptic listing of stains.

Name of stain	Acronym	Specific for	Approx. time	Page nos.
Alcian blue	AB	Acid mucopolysaccharides	3 h 20 min	92, 129
Alizarin red S	ARS	Calcium, chitin	1 h 45 min	93, 129
Azure-eosin/Giemsa ₁	AZE ₁	Blood fixed in methanol	1 h	94, 130
Azure-eosin/Giemsa ₂	AZE ₂	Fixed tissue, blood, gram-positive bacteria	1 h 30 min	95
Feulgen gram		Bacteria, gram-positive	1 h 50 min	97
Feulgen picromethyl blue	FPM	DNA, collagen, connective tissue, ciliates	1 h 35 min	98, 130
Gomori's		Connective tissue, reticulum	1 h	99, 131
Gram (Brown and Brenn 1931)		Bacteria, gram-positive and negative	1 h 10 min	101, 131
Gram (Brown and Hopps 1973)		Bacteria, gram-positive and negative	1 h	102, 131
Grocott's methenamine silver	GMS	Fungi	3 h 15 min	103, 132

Table 8-1. Synoptic listing of stains (cont.).

Name of stain	Acronym	Specific for	Approx. time	Page no.
Harris' hematoxylin and eosin ₁ (progressive)	HHE ₁	Tissues fixed in Zenker or Helly's	1 h 30 min	104
Harris' hematoxylin and eosin ₂ (regressive)	HHE ₂	Tissues fixed in formalin, Bouin's, or Davidson's	1 h 10 min	105
Harris' hematoxylin and eosin ₃	HHE ₃	Frozen tissue	10 min	106
Heidenhain's iron hematoxylin and eosin	IHE	Nuclear detail, ciliates	1 h 30 min	107
Mallory's hematein		Copper, metals	1 h	108, 132
Mallory's trichrome		Collagen, connective tissue	1 h	109, 132
Malt periodic acid Schiff	MPAS	Neutral mucopolysaccharides, PAS-positive substances other than glycogen	2 h 20 min	110, 133
Malt periodic acid Schiff-alcian blue	MPAS-AB	Neutral and acid mucopolysaccharides	5 h	111, 133
Mayer's hematoxylin and eosin	MHE	Formalin-fixed tissue	1 h 10 min	113, 133
Oil red O	ORO	Fat in frozen tissue	10 min	114, 134
Periodic acid Schiff ₁ (Weigert's hematoxylin)	PAS ₁	Neutral mucopolysaccharides, glycogen, fungi	1 h 15 min	115, 134
Periodic acid Schiff ₂ (Heidenhain's iron hematoxylin)	PAS ₂	Nuclear detail, fungi, glycogen, neutral mucopolysaccharides	1 h 45 min	116
Perls' Prussian blue		Ferric iron	2 h	117, 134
Protargol		Cilia, ciliate organelles	2 days	118, 135
Toluidine blue O ₁	TBO ₁	Hemocytes	30 min	120
Toluidine blue O ₂	TBO ₂	Frozen tissue	10 min	121, 135
Von Kossa		Calcium	2 h	122, 136
Ziehl-Neelsen and Harris' hematoxylin	ZHH	Acid-fast substances	1 h 45 min	123, 136
Ziehl-Neelsen and methylene blue		Acid-fast bacteria (AFB), acid-fast organisms	1 h 30 min	124, 136

Table 8-2. Synoptic listing of stains for diagnostic elements.

Diagnostic elements	Acronym	Name of stain	Approx. time	Page no.
Acid-fast:				
(a) Bacteria, organisms		Ziehl-Neelsen and methylene blue	1 h 30 min	124, 136
(b) Substances (e.g., haplosporidan spores, microsporida, and <i>Cryptosporidium</i>)	ZHH	Ziehl-Neelsen and Harris' hematoxylin	1 h 45 min	123, 136
Bacteria:				
(a) Acid-fast (see acid-fast)				
(b) Gram positive	AZE ₂	Feulgen gram	1 h 50 min	97
		Azure-eosin/Giemsa ₂	1 h 30 min	95
(c) Gram positive and negative		Gram (Brown and Brenn 1931)	1 h 10 min	101, 131
		Gram (Brown and Hopps 1973)	1 h	102, 131
Blood:				
(a) Hemocytes	TBO ₁	Toluidine blue O ₁	30 min	120
(b) Methanol-fixed	AZE ₁	Azure-eosin/Giemsa ₁	1 h	94, 130
(c) Fixed tissue	AZE ₂	Azure-eosin/Giemsa ₂	1 h 30 min	95
Calcium				
	ARS	Alizarin red S	1 h 45 min	93, 129
		Von Kossa	2 h	122, 136
Chitin				
	ARS	Alizarin red S	1 h 45 min	93, 129
Ciliates				
	FPM	Feulgen picromethyl blue	1 h 35 min	98, 130
	IHE	Heidenhain's iron hematoxylin and eosin	1 h 30 min	107
Ciliate organelles, cilia				
		Protargol	2 days	118, 135
Connective tissue:				
(a) Collagen	FPM	Mallory's trichrome	1 h	109, 132
		Feulgen picromethyl blue	1 h 35 min	98, 130
(b) Reticulum		Gomori's	1 h	99, 131
Copper, metals				
		Mallory's hematein	1 h	108, 132
DNA				
	FPM	Feulgen picromethyl blue	1 h 35 min	98, 130
Fats and phospholipids:				
(a) Fat in frozen tissue	ORO	Oil red O	10 min	114, 134

Table 8-2. Synoptic listing of stains for diagnostic elements (cont.).

Diagnostic elements	Acronym	Name of stain	Approx. time	Page no.
Fungi	GMS	Grocott's methenamine silver	3 h 15 min	103, 132
	PAS ₁	Periodic acid Schiff ₁ (Weigert's hematoxylin)	1 h 15 min	115, 134
	PAS ₂	Periodic acid Schiff ₂ (Heidenhain's iron hematoxylin)	1 h 45 min	116
General tissues:				
(a) Progressive hematoxylin	HHE ₁	Harris' hematoxylin and eosin ₁	1 h 30 min	104
(b) Regressive hematoxylin	HHE ₂	Harris' hematoxylin and eosin ₂	1 h 10 min	105
(c) Formalin-fixed	HHE ₂	Harris' hematoxylin and eosin ₂	1 h 10 min	105
	MHE	Mayer's hematoxylin and eosin	1 h 10 min	113, 133
Frozen tissues:				
(a) General	HHE ₃	Harris' hematoxylin and eosin ₃	10 min	106
(b) Fat	ORO	Oil red O	10 min	114, 134
(c) Metachromatic	TBO ₂	Toluidine blue O ₂	10 min	121, 135
Glycogen:				
(a) Digestion	PAS ₁	Periodic acid Schiff ₁ (Weigert's hematoxylin)	1 h 15 min	115, 134
	PAS ₂	Periodic acid Schiff ₂ (Heidenhain's iron hematoxylin)	1 h 45 min	116
	MPAS MPAS-AB	Malt periodic acid Schiff Malt periodic acid Schiff- alcian blue	2 h 20 min 5 h	110, 133 111, 133
Iron (ferric)		Perls' Prussian blue	2 h	117, 134
Mucopolysaccharides:				
(a) Acid	AB	Alcian blue	3 h 20 min	92, 129
(b) Neutral	PAS ₁	Periodic acid Schiff ₁ (Weigert's hematoxylin)	1 h 15 min	115, 134
	PAS ₂	Periodic acid Schiff ₂ (Heidenhain's iron hematoxylin)	1 h 45 min	116
(c) Neutral and acid	MPAS	Malt periodic acid Schiff	2 h 20 min	110, 133
	MPAS-AB	Malt periodic acid Schiff- alcian blue	5 h	111, 133
Nuclear detail	IHE	Heidenhain's iron hematoxylin and eosin	1 h 30 min	107
	PAS ₂	Periodic acid Schiff ₂ (Heidenhain's iron hematoxylin)	1 h 45 min	116

1. Standard Format for Paraffin-embedded Sections

To eliminate the repetitive solution and time cycles, stain protocols for most paraffin-embedded sections will read as follows: in a fume hood with PPE, deparaffinize, hydrate to water, stain, counterstain, dehydrate, clear, and mount. Blot slides after immersion in each solution to avoid solution carryover. Some stain protocols indicate a fixative of choice for best results; therefore, it is essential for the requestor to designate the fixative.

a. Deparaffinize

For sections cut from 5- to 6- μ m thickness, immerse slides in 2 changes of xylene for 5 min each. Change xylene regularly to ensure complete deparaffinization.

Thicker sections will require 3-4 changes of xylene and longer immersion times.

b. Hydrate to Water

Carry slides through descending concentrations of ethyl alcohol (ETOH) to water as follows:

100% ETOH	2 changes	5 min each
95% ETOH	1 change	3 min each
70% ETOH	1 change	3 min each
50% ETOH	1 change	3 min each
30% ETOH	1 change	3 min each
Distilled water	2 min

The 100% ETOH absorbs water and should be renewed frequently, depending on the number of slides involved, to avoid carryover of xylene. Obvious xylene contamination in 100% ETOH will leave an insoluble scum on slides when carried into diluted alcohols. The solutions should flow smoothly off slides before descending to the next alcohol.

c. Removal of Mercury (Mitchell 1966)

Tissues preserved in fixatives containing mercury (Zenker or Zenker formalin/Helly's) must be treated with Lugol's iodine and sodium thiosulfate before staining to prevent mercury crystal artifacts.

Procedure:

- 1) In fume hood, deparaffinize
- 2) Hydrate to 70% ETOH
- 3) Prepare Lugol's iodine stock¹ and working² solutions

- 4) Immerse in Lugol's iodine working solution² - 10 min
- 5) Rinse in 70% ETOH - 3 min
- 6) Change to 50% ETOH - 3 min
- 7) Follow in 30% ETOH - 3 min
- 8) Immerse in 2% sodium thiosulfate³ - 5 min
- 9) Wash in running tap water - 10 min
- 10) Distilled water

Reagents:

¹Lugol's iodine stock solution

Potassium iodide	6.0 gm
Iodine	4.0 gm
Distilled water	100.0 ml

²Lugol's iodine working solution

Lugol's iodine	10.0 ml
70% ETOH	90.0 ml

³2% sodium thiosulfate

Sodium thiosulfate	2.0 gm
Distilled water	100.0 ml

d. Dehydrate

When the stain and counterstain are complete, the slides are taken through an ascending series of ETOH:

95% ETOH	6 dips or 3 min
100% ETOH	1½ min
100% ETOH	3 min

e. Clear

Immerse slides in 2 changes of xylene for 5 min each. Change xylenes regularly to avoid dilution by alcohol carryover.

f. Mount

Slides are ready to coverslip with the mounting medium of choice (see pp. 137-138).

2. Pre-staining Techniques

a. Removal of Formaldehyde Fixation Artifacts Before Embedment

Depending on size of tissue, wash 30 min-4 h to remove excess formalin pigment if formalin has not been buffered or stock solution has not been neutralized with marble

chips. If tissues have been fixed in neutral buffered formalin, wash 5-30 min.

b. Remove Bouin's Fluid Before Staining

Most Bouin's is removed during hydration to water; however, if tissue still appears yellow, wash until coloration disappears. Check staining dishes for Bouin's contamination. Picric acid can brown the hematoxylin and yellow the eosin. Bouin's will interfere with other staining results.

c. Aldehyde Blocking Technique (Feder and O'Brien 1968)

This technique precedes Schiff-type stains where nonspecific aldehyde staining has occurred.

Procedure:

- 1) In fume hood, deparaffinize
- 2) Hydrate to water
- 3) Place slides in saturated solution of dimedone¹ - overnight
- 4) Rinse thoroughly in running tap water - ½ h
- 5) Proceed with desired Schiff-type stain

Reagent:

¹Dimedone (5,5-dimethyl-1,3-cyclonexanedione) saturated solution

Dimedone 0.5 gm
Distilled water 100.0 ml
Stir or shake intermittently for at least 5 h and filter before use.

Note: "Completeness of blockade can be tested by transferring a treated, rinsed slide directly to the Schiff reagent, followed by the usual metabisulfite and water rinses. There should be no staining if the blockade of aldehyde groups is complete" (Feder and O'Brien 1968).

d. Collodion Coating for Slides (Coolidge and Howard 1979)

Technique is recommended when tissues tend to separate from slides.

Procedure:

- 1) In fume hood, prepare collodion stock¹ and working² solutions
- 2) Deparaffinize
- 3) 100% ETOH - 2 changes, 5 min each
- 4) Place in 0.5% collodion working solution² - 1 min
- 5) Drain
- 6) Place in 70% ETOH
- 7) Hydrate to water
- 8) Stain as usual

Reagents:

¹2% collodion stock solution

Parlodion (=collodion, celloidin, nitrocellulose, cellulose nitrate, pyroxylin) 1.0 gm
100% ETOH 50.0 ml

Let solution stand until parlodion is dissolved. **Handle parlodion with extreme caution; avoid strong impacts.**

²0.5% collodion working solution

2% collodion stock 12.5 ml
100% ETOH 25.0 ml
Ethyl ether (anhydrous) 12.5 ml

Danger: Solution highly flammable; use extreme caution when handling or storing collodion; avoid open flame or electrical discharges.

Notes:

- 1) Collodion (4%) may be purchased as a ready-made solution from Sigma^a cat. # 27694. Collodion working solution may be prepared with methanol instead of ether. Hydrate in graduated strengths of methanol after enrobing in collodion (E.B. Small, University of Maryland, College Park, MD, pers. commun. 1997).
- 2) Do not use collodion with alcian blue staining; collodion will pick up alcian blue and mask entire slide.
- 3) For Feulgen picromethyl blue (FPM), remove collodion after Schiff reagent in 1 change of 70% ETOH and 2 changes of 100% ETOH, then hydrate to 70% ETOH and to water, and continue staining with picromethyl as usual. (Butanol will not remove collodion; therefore, collodion must be removed in 100% ETOH before completing stain.)

e. Acid Clean Glassware (Coolidge and Howard 1979)

Potassium dichromate is preferred for cleaning laboratory glassware; however, alternative products are available that are less hazardous.

Procedure:

- 1) In fume hood, immerse clean glassware in dichromate acid cleaning solution¹ - 2 h or more
- 2) Rinse well in running water and several changes of distilled water
- 3) Dry in dust-free cabinet
- 4) Cover with aluminum foil and store in designated acid-cleaned area
- 5) Properly dispose of used acid bath

Reagent:

¹Dichromate acid cleaning solution
Potassium dichromate 200.0 gm
Distilled water 2000.0 ml

Potassium dichromate is hazardous and should be handled with care.

Dissolve with low heat, cool, then add:

Sulfuric acid 200.0 ml

Caution: Add sulfuric acid slowly. Use extreme care in preparation and use of this solution.

Notes:

- 1) Wear protective face mask, acid-resistant apron, and gloves (check gloves for holes).
- 2) Store potassium dichromate in acid-proof container and approved acid cabinet; fumes will corrode metal cabinets. Properly label dichromate solution; include appropriate warnings.
- 3) Solution may be reused.

3. Deactivation of Ammoniacal Silver Solutions

(<http://www.northwestern.edu/research-safety/chem/deactam.htm>)

Ammoniacal silver staining solutions are hazardous because explosive silver salts may form. Mix only the amount of silver nitrate solution necessary to complete procedure. Keep prepared solutions of silver nitrate and ammonium hydroxide separate. **Handle as an explosive material.** Where permitted, the following procedure may be used to deactivate silver/ammonium solutions:

Procedure:

- 1) In fume hood, dilute 1 part of silver/ammonium solution to 15 parts of distilled water
- 2) In another container, prepare 5% hydrochloric acid (HCl)
- 3) Slowly add HCl solution to silver/ammonium solution until pH reaches 2; stir frequently
- 4) If there is evidence of heat generation, add ice to cool process
- 5) When pH reaches 2, silver chloride should begin to precipitate out. Filter precipitate with Buchner funnel
- 6) Adjust pH of liquid waste to 4-5 with addition of sodium bicarbonate
- 7) Dispose of wastes by approved facility practices

Reagent:

¹5% HCl
HCl 5.0 ml
Distilled water 95.0 ml

Handle HCl with care.

4. Staining Methods

(1) Alcian Blue (AB) (3 h 20 min) (Pearse 1960)

Specific for acid mucopolysaccharides.

Procedure:

- 1) Deparaffinize
- 2) Hydrate to water
- 3) Stain in alcian blue¹ (fixative specific; check expiration date of stain) - 30 min
- 4) Rinse in running water - 4-6 dips
- 5) 0.5% alcoholic ammonium hydroxide² - 2 h
- 6) Rinse in running tap water - 4-6 dips
- 7) Stain in nuclear fast red (Kernechtrot)³ - 5 min
- 8) Rinse well in distilled water - 6 dips (to prevent formation of white precipitate)
- 9) Dehydrate
- 10) Clear
- 11) Mount

Results (Fig. 8-1):

Acid mucopolysaccharides - brilliant blue
Nuclei - bright red or shades of blue
Other basophilic substances - various shades of blue or purple
Background - pink to red
Other cytoplasmic elements - shades of pink

Reagents:

For tissues fixed in Zenker or Helly's (Johnson 1980)

¹0.1% alcian blue in 0.01 M HCl (pH 2.2)
Alcian blue 8GX 1.0 gm
1 N HCl 10.0 ml
Distilled water 990.0 ml

Handle HCl with care.

For tissues fixed in formalin or Davidson's (Johnson 1980)

¹0.1% alcian blue in 3% acetic acid
Alcian blue 8GX 0.1 gm
Distilled water 97.0 ml
Glacial acetic acid 3.0 ml

²0.5% alcoholic ammonium hydroxide (Johnson 1980)
28-30% ammonium hydroxide 3.0 ml
95% ETOH 597.0 ml

Handle ammonium hydroxide with care.

³Nuclear fast red (Kernechtrot)

5% aluminum sulfate (Al₂(SO₄)₃):
Al₂(SO₄)₃ 25.0 gm
Distilled water 500.0 ml

0.1% nuclear fast red:

Nuclear fast red 0.5 gm
5% Al₂(SO₄)₃ 500.0 ml

Note: Nuclear fast red (Kernechtrot) available as a ready to use 0.1% solution from Poly Scientific^b cat. # S248 or in powder form from J.T.Baker^c cat. # S635-01. Refrigerate solution; discard when stain loses color.

(2) Alizarin Red S (ARS) (1 h 45 min) (Luna 1968)

Specific for calcium and chitin. Use a positive control test slide.

Procedure:

- 1) Deparaffinize
- 2) Hydrate to water
- 3) Stain in 0.1% alizarin red S¹ - 1 h
- 4) Rinse in several dips of tap water
- 5) Counterstain in 1% light green SF yellowish²
(prepare fresh before use; tends to overstain)
- 5 sec
- 6) Rinse in distilled water - 6-10 dips
- 7) Dehydrate
- 8) Clear
- 9) Mount

Results (Figs. 8-2, 8-3):

Calcium salts and chitin - intense reddish-orange
Background - pale green

Reagents:

¹0.1% alizarin red S

Alizarin red S 0.1 gm
Distilled water 100.0 ml

²1% light green SF yellowish (Dahl and Dole 1952)

Light green SF yellowish 1.0 gm
Distilled water 100.0 ml
Glacial acetic acid 1.0 ml

(3) Azure-Eosin/Giemsa, (AZE₁) (1 h) (Lillie 1965)

Specific for blood (e.g., smears) fixed in methanol.

Procedure:

Fresh blood

- 1) Stain in Giemsa¹, pH 6.8-7.1 - 1 h
- 2) Rinse in buffered distilled water; buffer to pH of stain
- 3) Blot individual slides to prevent water spots
- 4) Air-dry; coverslip if required
- 5) Xylene - 2 dips
- 6) Mount

Old blood (Presnell and Schreiber 1997)

- 1) Immerse for 5-10 min in:
100% ETOH 60.0 ml
Glacial acetic acid 10 drops
- 2) Rinse in distilled water and continue with above Giemsa stain procedure

Results (Fig. 8-4):

Nuclei and basophilic substances - blue
Cytoplasm and acidophilic substances - pink

Reagent:

¹Giemsa

Giemsa (azure B type) 5.0 ml
Buffer (will vary with blood species; see
McIlvaine-Lillie table, p. 96) 10.0 ml
Distilled water 185.0 ml

Note: Giemsa azure B type available from EMD Chemicals^d cat. # 619.

(4) Azure-Eosin/Giemsa₂ (AZE₂) (1 h 30 min) (Lillie 1965)

Metachromatic stain for fixed tissues. Specific for blood studies and gram-positive bacteria.

Procedure:

- 1) Deparaffinize
- 2) Hydrate to water
- 3) Stain in Giemsa¹ (see pH table, p. 96) - 1 h
(use fresh Giemsa stain for each set of slides; stain deteriorates after 1 h)
- 4) Drain - 20 sec
- 5) Acetone - 1½ min
- 6) Acetone - 3 min
- 7) 50:50 acetone/xylene - 1½ min
- 8) Clear
- 9) Mount

Results:

Nuclei - blue to violet
Cytoplasm - varying shades of light blue or pale pink
Muscle - bright pink
Bacteria - blue

Reagent:

¹Giemsa

Giemsa (azure B type).....	5.0 ml
Buffer (see McIlvaine-Lillie table, p. 96)	10.0 ml
Acetone	25.0 ml
Distilled water	160.0 ml

Note: Giemsa azure B type available from EMD Chemicals^d cat. # 619.

(5) Fixative Guide for Giemsa Stain

The following developed by M.W. Newman (NOAA, Oxford, MD, pers. commun. 1970) provides the recommended pH for buffers to be used with various fixatives. After the preferred pH has been determined, one should consult the McIlvaine-Lillie buffer table shown below.

Fixative	pH
Formalin	4.50
Hollande	4.75
Formalin, followed by decalcifier	4.80
Davidson's	4.95
Susa	4.95
Helly's (Zenker formalin)	5.10
Bouin's	5.50

McIlvaine-Lillie buffers (Lillie 1954)

Stock solutions

M/10 citric acid:

Citric acid	2.1 gm
25% methanol (25 ml methanol + 75 ml distilled water)	100.0 ml

M/5 disodium phosphate (sodium phosphate dibasic):

Disodium phosphate	2.84 gm
25% methanol	100.0 ml

pH	M/10 citric acid (ml)	M/5 disodium phosphate (ml)
3.95 ...	12.5	7.5
4.1 ...	12.0	8.0
4.3 ...	11.5	8.5
4.5 ...	11.0	9.0
4.75 ...	10.5	9.5
4.95 ...	10.0	10.0
5.3 ...	9.5	10.5
5.5 ...	9.0	11.0
5.7 ...	8.5	11.5
6.0 ...	8.0	12.0
6.1 ...	7.5	12.5
6.3 ...	7.0	13.0
6.4 ...	6.5	13.5
6.5 ...	6.0	14.0
6.6 ...	5.5	14.5
6.8 ...	5.0	15.0
6.9 ...	4.5	15.5
7.0 ...	4.0	16.0
7.1 ...	3.5	16.5
7.2 ...	3.0	17.0
7.3 ...	2.5	17.5
7.4 ...	2.0	18.0
7.5 ...	1.5	18.5
7.7 ...	1.0	19.0
8.0 ...	0.5	19.5
8.3 ...	0.0	20.0

Table 8-3. McIlvaine-Lillie buffer stock solutions. M/10 and M/5 solutions are made in 25% methanol; pH values are for final aqueous dilution of 1:25.

pH	M/10 citric acid (ml)	M/5 disodium phosphate (ml)
2.5 ...	20.0	0.0
2.6 ...	19.5	0.5
2.65 ...	19.0	1.0
2.7 ...	18.5	1.5
2.75 ...	18.0	2.0
2.8 ...	17.5	2.5
2.9 ...	17.0	3.0
3.0 ...	16.5	3.5
3.05 ...	16.0	4.0
3.1 ...	15.5	4.5
3.2 ...	15.0	5.0
3.3 ...	14.5	5.5
3.45 ...	14.0	6.0
3.6 ...	13.5	6.5
3.75 ...	13.0	7.0

(6) Feulgen Gram (1 h 50 min) (Brown and Brenn 1931)

Specific for gram-positive bacteria. Test Schiff reaction before staining process. Use a positive control test slide.

Procedure:

- 1) Deparaffinize
- 2) Hydrate to water
- 3) Hydrolyze in 5 N HCl¹ - 30 min
- 4) Rinse in distilled water - 1 min (change frequently to reduce HCl carryover)
- 5) Distilled water - 1 min (**tap water will contaminate and cause discoloration of Schiff**)
- 6) Blot well, stain in refrigerated Schiff reagent² - 15 min
- 7) Rinse in distilled water - 2 changes, 1 min each
- 8) Rinse in running tap water - 2 min
- 9) Stain in crystal violet³ (**prepare fresh before use**) - 2 min
- 10) Wash in running water - 2 min
- 11) Lugol's iodine⁴ - 2 min
- 12) Wash in running water - 2 min
- 13) Decolorize in 95% ETOH until "blue" does not bleed off slide
- 14) Wash in running water - 2 min
- 15) Counterstain in 0.03% picromethyl blue⁵ - 3 min
- 16) Destain in 1 part 100% ETOH to 9 parts butanol - 6 dips (change for each rack)
- 17) Butanol - 1½ min
- 18) Butanol - 3 min
- 19) Xylene
- 20) Mount

Results:

Gram positive - blue
Nuclei - red
Muscle - yellow
Collagen - light blue
Background - green

Reagents:

¹5 N HCl (Lillie 1965)

Distilled water 583.5 ml
Concentrated HCl sp. gr. 1.19 416.5 ml

Handle HCl with care.

²Schiff (Sanders 1972)

- 1) Boil 200 ml of distilled water
- 2) Add 1.0 gm of basic fuchsin and stir
- 3) Cool to 50°C (filter optional)
- 4) Add 20 ml of normal HCl (916.5 ml of distilled water and 83.5 ml of concentrated HCl sp. gr. 1.19; **handle HCl with care**)
- 5) Cool to 25°C (room temp.)
- 6) Add 1.0 gm of sodium metabisulfite (Na₂S₂O₅)
- 7) Shake vigorously
- 8) Store in dark until reagent turns a straw color - approx. 2 days
- 9) Add approx. ½ gm/200 ml charcoal; shake and filter
- 10) Keep refrigerated at all times, even during staining process, to prevent breakdown of Schiff

Note: Schiff reagent available ready-made from Poly Scientific[®] cat. # S-272 very reliable. To make Schiff reagent, we suggest using basic fuchsin (pararosaniline) available from Fisher Scientific[®] cat. # F-98-10. It is important to get a good "lot" of basic fuchsin. Discard Schiff when it takes on purple tone; it will no longer stain effectively. For best results, make separate 200-ml portions and store in separate containers.

³Crystal violet

Crystal violet 0.8 gm
Sodium bicarbonate 1.0 gm
Distilled water 100.0 ml

⁴Lugol's iodine (Sanders 1972)

Iodine 1.0 gm
Potassium iodide 2.0 gm
Distilled water 100.0 ml

⁵0.03% picromethyl blue (Farley 1969)

Methyl blue 0.15 gm
Saturated aqueous picric acid 500.0 ml

Note: Methyl blue available from Sigma[®] cat. # M-5528. Saturated solution of picric acid available from Fisher Scientific[®] cat. # CS-311-1.

(7) Feulgen Picromethyl Blue (FPM) (1 h 35 min)
(Farley 1969)

Specific for DNA, collagen, and connective tissue. Good stain for ciliates. Test Schiff reaction before staining process.

Procedure:

- 1) Deparaffinize
- 2) Hydrate to water
- 3) Hydrolyze in 5 N HCl¹ at room temp. - 30 min
- 4) Rinse in distilled water - 1 min (change frequently to reduce HCl carryover)
- 5) Rinse in distilled water - 1 min (**tap water will contaminate and cause discoloration of Schiff**)
- 6) Blot well, stain in refrigerated Schiff reagent² - 15 min
- 7) Rinse in distilled water - 2 changes, 1 min each
- 8) Rinse in running tap water - 5-10 min
- 9) Rinse in distilled water - 1 min
- 10) Counterstain in 0.03% picromethyl blue³ - 3 min
- 11) Destain in 1 part 100% ETOH to 9 parts butanol - 6 dips (change for each rack)
- 12) Butanol - 1½ min
- 13) Butanol - 3 min
- 14) Clear
- 15) Mount

Results (Figs. 8-5, 8-6):

DNA - red
Nucleoli, muscle, and other acidophilic substances - yellow
Connective tissue, collagen - blue
Cytoplasmic protein - green

Reagents:

¹5 N HCl (Lillie 1965)
Distilled water 583.5 ml
Concentrated HCl sp. gr. 1.19 416.5 ml
Handle HCl with care.

²Schiff (Sanders 1972)

- 1) Boil 200 ml of distilled water
- 2) Add 1.0 gm of basic fuchsin and stir
- 3) Cool to 50°C (filter optional)
- 4) Add 20 ml of normal HCl (916.5 ml of distilled

water and 83.5 ml of concentrated HCl sp. gr. 1.19; **handle HCl with care**)

- 5) Cool to 25°C (room temp.)
- 6) Add 1.0 gm of sodium metabisulfite (Na₂S₂O₅)
- 7) Shake vigorously
- 8) Store in dark until reagent turns a straw color - approx. 2 days
- 9) Add approx. ½ gm/200 ml charcoal; shake and filter
- 10) Keep refrigerated at all times, even during staining process, to prevent breakdown of Schiff

Note: Schiff reagent available ready-made from Poly Scientific^b cat. # S-272 very reliable. To make Schiff reagent, we suggest using basic fuchsin (pararosaniline) available from Fisher Scientific^c cat. # F-98-10. It is important to get a good "lot" of basic fuchsin. Discard Schiff when it takes on purple tone; it will no longer stain effectively. For best results, make separate 200-ml portions and store in separate containers.

³0.03% picromethyl blue (Farley 1969)

Methyl blue 0.15 gm
Saturated aqueous picric acid 500.0 ml

Note: Methyl blue available through Sigma^a cat. # M-5528. Saturated solution of picric acid available from Fisher Scientific^c cat. # CS-311-1.

(8) Gomori's (1 h) (Carson 1990)

Specific for connective tissue, reticulum. Use acid-cleaned glassware.

Procedure:

- 1) Deparaffinize
- 2) Hydrate to water
- 3) Oxidize in 0.5% potassium permanganate¹ - 1 min
- 4) Wash in running tap water - 2 min
- 5) Differentiate in 2% potassium metabisulfite² - 1 min
- 6) Wash in running tap water - 2 min
- 7) Sensitize in 2% ferric ammonium sulfate³ - 1 min
- 8) Wash in running tap water - 2 min
- 9) Rinse in distilled water - 2 changes
- 10) Impregnate with ammoniacal silver⁴ - 1 min
- 11) Rinse in distilled water - 20 sec
- 12) Reduce in 20% formalin⁵ - 3 min
- 13) Wash in running tap water - 3 min
- 14) Tone in 0.2% gold chloride⁶ - 10 min
- 15) Rinse in distilled water - 2 min
- 16) Reduce in 2% potassium metabisulfite² - 1 min
- 17) Fix in 2% sodium thiosulfate⁷ - 1 min
- 18) Wash in running tap water - 2 min
- 19) Stain in nuclear fast red (Kernechtrot)⁸ - 1-4 min
- 20) Rinse well in distilled water - 6 dips (to prevent formation of white precipitate)
- 21) Dehydrate
- 22) Clear
- 23) Mount

Results (Fig. 8-7):

Reticulum fibers - black
Collagen - rose
Other tissue elements - pink to red

Reagents:

- ¹0.5% potassium permanganate
Potassium permanganate 0.5 gm
Distilled water 100.0 ml
- ²2% potassium metabisulfite
Potassium metabisulfite 2.0 gm
Distilled water 100.0 ml

- ³2% ferric ammonium sulfate
Ferric ammonium sulfate 2.0 gm
Distilled water 100.0 ml

- ⁴Ammoniacal silver
10% silver nitrate:
Silver nitrate 1.0 gm
Distilled water 10.0 ml
- 10% aqueous potassium hydroxide:
Potassium hydroxide 1.0 gm
Distilled water 10.0 ml
- 3% sodium hydroxide:
Sodium hydroxide 0.3 gm
Distilled water 10.0 ml

- 1) To each 10 ml of 10% silver nitrate, add 2.5 ml of 10% aqueous potassium hydroxide
- 2) Add 28% ammonium hydroxide drop by drop and swirl container until white precipitate completely dissolves
- 3) Cautiously add 5 ml of 3% sodium hydroxide
- 4) Redissolve precipitate with 28% ammonium hydroxide until only a faint cloudiness remains
- 5) Dilute resulting solution with equal amount of distilled water

Note: Do not store silver solution for long periods of time after addition of ammonium hydroxide. See *Deactivation of Ammoniacal Silver Solutions* (p. 91).

- ⁵20% formalin
37-40% formaldehyde 20.0 ml
Distilled water 80.0 ml

- ⁶0.2% gold chloride
1% stock gold chloride 20.0 ml
Distilled water 80.0 ml

Note: 1% stock gold chloride available from Sigma^a cat. # G-4022.

- ⁷2% sodium thiosulfate
Sodium thiosulfate 2.0 gm
Distilled water 100.0 ml

⁸Nuclear fast red (Kernechtrot)

5% aluminum sulfate ($\text{Al}_2(\text{SO}_4)_3$):

$\text{Al}_2(\text{SO}_4)_3$ 25.0 gm

Distilled water 500.0 ml

0.1% nuclear fast red:

Nuclear fast red (Kernechtrot) 0.5 gm

5% $\text{Al}_2(\text{SO}_4)_3$ 500.0 ml

Note: Nuclear fast red (Kernechtrot) available as a ready to use 0.1% solution from Poly Scientific^b cat. # S248 or in powder form from J.T.Baker^c cat. # S635-01. Refrigerate; stain is good until it loses color.

(9) Gram (1 h 10 min) (Brown and Brenn 1931)

Specific for gram-positive and gram-negative bacteria.
Use positive and negative control test slides.

Procedure:

- 1) Deparaffinize
- 2) Hydrate to water
- 3) Prepare crystal violet stock¹ and working² solutions
- 4) Stain in crystal violet working solution² (**prepare fresh before use**) - 2 min
- 5) Wash in running water - 2 min
- 6) Lugol's iodine³ - 2 min
- 7) Wash in running water - 2 min
- 8) Decolorize in 95% ETOH until "blue" does not bleed off slide
- 9) Wash in running tap water - 2 min
- 10) Stain in safranin O⁴ - 2 min
- 11) Wash in running tap water - 2 min
- 12) Counterstain in 0.03% picromethyl blue⁵ or picric acid⁶ (optional) - 3 min
- 13) Differentiate in 1 part 100% ETOH to 9 parts butanol - 6 dips (or until safranin O does not bleed off slide)
- 14) Butanol - 1½ min
- 15) Butanol - 3 min
- 16) Clear
- 17) Mount

Results (Fig. 8-8):

Gram positive - blue
Gram negative - red
Nuclei - red
Background - yellow to green (depending on counterstain)

Reagents:

¹1% crystal violet stock solution (Sanders 1972)
Crystal violet 1.0 gm
Distilled water 100.0 ml

²Crystal violet working solution
1% crystal violet stock solution 40.0 ml
5% sodium bicarbonate 10.0 ml

5% sodium bicarbonate:
Sodium bicarbonate 0.5 gm
Distilled water 10.0 ml

³Lugol's iodine (Sanders 1972)
Iodine 1.0 gm
Potassium iodide 2.0 gm
Distilled water 100.0 ml

⁴Safranin O (Conn et al. 1962)
Dissolve safranin O in 10 ml of:
95% ETOH 0.25 gm
Distilled water 90.0 ml

⁵0.03% picromethyl blue (Farley 1969)
Methyl blue 0.15 gm
Saturated aqueous picric acid 500.0 ml

Note: Methyl blue available from Sigma^a cat. # M-5528.

⁶Picric acid (saturated aqueous)
Distilled water 20.0 ml
Picric acid 2.0 gm

Note: Saturated aqueous picric acid available from Fisher Scientific^c cat. # CS-311-1. Fresh preparations stain well with Brown and Brenn's gram; gram-negative stain is not always accurate for fixed tissues

(10) Gram (1 h) (Brown and Hopps 1973)

Specific for gram-positive and gram-negative bacteria.
Use positive and negative control test slides.

Procedure:

- 1) Deparaffinize
- 2) Hydrate to water
- 3) Stain in 1% crystal violet¹ (**prepare fresh before use**) - 1 min
- 4) Wash in tap water - 1 min
- 5) Place in Gram's iodine² - 1 min
- 6) Wash in tap water - 1 min
- 7) Decolorize in acetone until background is clear
- 8) Immediately wash in tap water - 1 min
- 9) Prepare basic fuchsin stock³ and working⁴ solutions
- 10) Stain in basic fuchsin working solution⁴ - 5 min (fixative specific)
- 11) Wash in tap water - 1 min
- 12) Place in Gallego's differentiating solution⁵ - 2 changes, 1 min each
- 13) Wash in tap water - 1 min
- 14) Treat with acetone - 30 sec
- 15) Counterstain in picric acid/acetone⁶ - 2-3 min
- 16) Place in acetone/xylene⁷ - 2 changes, 1-2 min
- 17) Clear
- 18) Mount

Results (Fig. 8-9):

Gram-positive bacteria - blue
Gram-negative bacteria - red to purple
Background - yellow to green (depending on counterstain)

Reagents:

¹1% crystal violet
Crystal violet 1.0 gm
Distilled water 100.0 ml

²Gram's iodine
Iodine 1.0 gm
Potassium iodide 2.0 gm
Distilled water 300.0 ml

³0.25% basic fuchsin stock solution
Basic fuchsin 0.25 gm
Distilled water 100.0 ml
Filter through No. 40 Whatman filter paper.

For tissues fixed in formalin, glutaraldehyde, and Bouin's

⁴Basic fuchsin working solution
Basic fuchsin stock 1.0 ml
Distilled water 25.0 ml

For tissues fixed in Zenker formalin

⁴Basic fuchsin working solution
Basic fuchsin stock 5.0 ml
Distilled water 25.0 ml

⁵Gallego's differentiating solution
37-40% formaldehyde 2.0 ml
Glacial acetic acid 1.0 ml
Distilled water 100.0 ml

Note: Gallego's solution tends to stain gram-negative bacteria pinkish-purple.

⁶Picric acid/acetone
Picric acid 0.1 gm
Acetone 100.0 ml

⁷Acetone/xylene
Acetone 50.0 ml
Xylene 50.0 ml

(11) Grocott's Methenamine Silver (GMS) (3 h 15 min) (Luna 1968)

Specific for fungi. Use a positive control slide and acid-cleaned glassware.

Procedure:

- 1) Deparaffinize
- 2) Hydrate to water
- 3) Oxidize in 4% chromic acid¹ - 1 h
- 4) Wash in tap water - few seconds
- 5) Place in 1% sodium bisulfite² - 1 min (to remove any residual chromic acid)
- 6) Wash in running water - 5-10 min
- 7) Rinse in distilled water - 3-4 changes
- 8) Prepare methenamine silver nitrate stock³ and working⁴ solutions
- 9) Impregnate with freshly mixed methenamine silver nitrate working solution⁴ in incubator or waterbath - 60 min at 58°-60°C or until section turns yellowish-brown
- 10) Rinse in distilled water - 6 changes
- 11) Tone in 0.1% gold chloride⁵ - 2-5 min
- 12) Rinse in distilled water - 2 min
- 13) Remove unreduced silver with 2% sodium thiosulfate (hypo)⁶ - 2-5 min
- 14) Wash thoroughly in tap water - 5 min
- 15) Counterstain in 0.2% light green SF yellowish⁷ (**prepare fresh before use; tends to overstain**) - 30-45 sec
- 16) Dehydrate
- 17) Clear
- 18) Mount

Results (Fig. 8-10):

Fungi - sharply delineated in black
Mucin - taupe to dark gray
Inner parts of mycelia and hyphae - grayish rose
Background - pale green

Reagents:

¹4% chromic acid
Chromic acid 4.0 gm
Distilled water 100.0 ml

Handle chromic acid with care.

²1% sodium bisulfite
Sodium bisulfite 1.0 gm
Distilled water 100.0 ml

³Methenamine silver nitrate stock solution
5% silver nitrate 5.0 ml
3% methenamine 100.0 ml

5% silver nitrate:
Silver nitrate 0.25 gm
Distilled water 5.0 ml

3% methenamine:
Methenamine 3.0 gm
Distilled water 100.0 ml

Refrigerate; clear solution remains usable for months.

Note: A white precipitate forms in the methenamine silver nitrate stock solution, but immediately dissolves upon swirling.

⁴Methenamine silver nitrate working solution
Methenamine silver nitrate stock 25.0 ml
Distilled water 25.0 ml
5% borax 2.0 ml

5% borax (sodium borate):
Borax 5.0 gm
Distilled water 100.0 ml

Note: Silver easily precipitates on slides. Keep all solutions away from metal, and coat forceps with paraffin before immersing in silver solution.

⁵0.1% gold chloride
1% gold chloride 10.0 ml
Distilled water 90.0 ml
Refrigerate after preparation. Filter solution after use if precipitate visible.

Note: Gold chloride available from Sigma^a cat. # G-4022. Solution may be used repeatedly if clear yellow after filtering.

⁶2% sodium thiosulfate (hypo)
Sodium thiosulfate 2.0 gm
Distilled water 100.0 ml

⁷0.2% light green SF yellowish
Light green SF yellowish 0.2 gm
Distilled water 100.0 ml

**(12) Harris' Hematoxylin and Eosin₁ (HHE₁)
(Progressive) (1 h 30 min) (Johnson 1980)**

General stain for tissues fixed in Zenker or Helly's.

Procedure:

- 1) Deparaffinize
- 2) Hydrate to water
- 3) Stain in Harris' hematoxylin¹ - 2 min
- 4) Rinse in distilled water - 6 dips
- 5) 0.5% lithium carbonate² - 3 dips, approx. 30 sec,
or until sections turn blue (sections may turn blue
in slightly alkaline tap water without lithium
carbonate)
- 6) Rinse well in distilled water to eliminate lithium
carbonate - 2 min
- 7) 70% ETOH - 2 min
- 8) Counterstain in aged eosin B³ - 20 sec-2 min (may
vary with tissue and fixative used)
- 9) Dehydrate
- 10) Clear
- 11) Mount

Results:

Basophilic substances - blue
Acidophilic substances - pink

Reagents:

¹Harris' hematoxylin

Note: Harris' hematoxylin available from Newcomer
Supply^f cat. # 1201A.

²0.5% lithium carbonate

Lithium carbonate 0.5 gm
Distilled water 100.0 ml

³Eosin B

Eosin B 1.0 gm
95% ETOH 100.0 ml

Age 1 mo.

Note: May use eosin Y (see p. 105) or eosin Y +
phyloxine B (see MHE stain, p. 113). Eosin B available
from Fisher Scientific^c cat. # E-514-25.

**(13) Harris' Hematoxylin and Eosin₂ (HHE₂)
(Regressive) (1 h 10 min) (Johnson 1980)**

General stain for tissues fixed in formalin, Bouin's, or Davidson's.

Procedure:

- 1) Deparaffinize
- 2) Hydrate to water
- 3) Stain in Harris' hematoxylin¹ - 8 min
- 4) Rinse in distilled water - 2 min (use fresh distilled water for each rack)
- 5) Acid alcohol² - 1 dip
- 6) 0.5% lithium carbonate³ - 3 dips, approx. 30 sec, or until sections turn blue (sections may turn blue in slightly alkaline tap water without lithium carbonate)
- 7) Rinse in distilled water - 3 min
- 8) 70% ETOH - 3 min
- 9) Counterstain in eosin Y⁴ - 3 min
- 10) 95% ETOH - 6 dips
- 11) Dehydrate
- 12) Clear
- 13) Mount

Results:

Basophilic substances - blue
Acidophilic substances - pink

Reagents:

¹Harris' hematoxylin

Note: Harris' hematoxylin available from Newcomer Supply^f cat. # 1201A.

²Acid alcohol

70% ETOH 99.0 ml
Concentrated HCl sp. gr. 1.19 1.0 ml

Handle HCl with care.

³0.5% lithium carbonate

Lithium carbonate 0.5 gm
Distilled water 100.0 ml

⁴Eosin Y

Eosin Y 1.0 gm
Distilled water 75.0 ml
100% ETOH 25.0 ml

Just before use, add 1 drop concentrated HCl sp. gr. 1.19/200 ml of eosin Y. **Handle HCl with care.**

Note: If precipitate forms and does not disappear with stirring, eosin may stain too orange.

(14) Harris' Hematoxylin and Eosin₃ (HHE₃) (10 min)
(Prophet et al. 1992)

Rapid hematoxylin and eosin procedure for frozen tissue.

Procedure:

- 1) Place freshly cut frozen tissues in alcoholic formalin¹ - 15 sec
- 2) 70% ETOH - 10 dips
- 3) Rinse well in distilled water - 1 min
- 4) Stain in Harris' hematoxylin² - 45 sec-1 min
- 5) Rinse well in distilled water - 1 min
- 6) 0.5% lithium carbonate³ - 3 dips, approx. 30 sec, or until sections turn blue (sections may turn blue in slightly alkaline tap water without lithium carbonate)
- 7) Rinse well in distilled water to eliminate lithium carbonate - 1 min
- 8) Prepare stock^{4,5} and working⁶ solutions
- 9) Counterstain in eosin Y-phloxine B working solution⁶ - 30 sec
- 10) Dehydrate
- 11) Clear
- 12) Mount

Results:

Basophilic substances - blue
Acidophilic substances - pink

Reagents:

¹Alcoholic formalin
37-40% formaldehyde 10.0 ml
80% ethyl alcohol 90.0 ml

²Harris' hematoxylin

Note: Harris' hematoxylin available from Newcomer Supply^f cat. # 1201A.

³0.5% lithium carbonate
Lithium carbonate 0.5 gm
Distilled water 100.0 ml

⁴1% eosin Y stock solution
Eosin Y 1.0 gm
Distilled water 100.0 ml

⁵1% phloxine B stock solution
Phloxine B 1.0 gm
Distilled water 100 ml

⁶Eosin Y-phloxine B working solution
1% eosin Y 100.0 ml
1% phloxine B 10.0 ml
95% ETOH 780.0 ml
Glacial acetic acid 4.0 ml

(15) Heidenhain's Iron Hematoxylin and Eosin (IHE) (1 h 30 min) (Conn et al. 1962)

Specific for nuclear detail. Good for ciliates.

Procedure:

- 1) Deparaffinize
- 2) Hydrate to water
- 3) Prepare Lang's mordant stock¹ and working² solutions
- 4) Place in Lang's mordant working solution² - 10 min
- 5) Wash in running water - 5 min
- 6) Rinse in distilled water- 1 min
- 7) Prepare hematein stock³ and working⁴ solutions *or* hematoxylin stock⁵ and working⁶ solutions
- 8) Stain in hematein working solution⁴ *or* aged hematoxylin working solution⁶ - 10 min
- 9) Rinse in distilled water- 1 min
- 10) Destain in picric acid⁷ until only nuclei remain stained - 10-20 min (check with microscope)
- 11) Wash in running tap water - 5 min
- 12) Dehydrate in alcohols through 95% ETOH as usual
- 13) Counterstain in aged eosin B⁸ - 20 sec-2 min
- 14) Dehydrate
- 15) Clear
- 16) Mount

Results:

Nuclei - black
Muscle - pink
Background - gray

Reagents:

¹Lang's mordant stock solution

Distilled water 1000.0 ml
Glacial acetic acid 10.0 ml
Sulfuric acid 1.2 ml
Ferric ammonium sulfate 30.0 gm

²Lang's mordant working solution

Lang's mordant stock 200.0 ml
Dimethyl sulfoxide (DMSO) (Mitchell 1966) 20.0 ml

Avoid DMSO contact with skin.

³0.5% hematein stock solution (Farley 1988)

Hematein 1.0 gm
Distilled water 200.0 ml

⁴Hematein working solution (Mitchell 1966)

0.5% hematein stock 10 parts
Dimethyl sulfoxide (DMSO) 1 part

Avoid DMSO contact with skin.

⁵Hematoxylin stock solution (Lillie 1965)

100% ETOH 100.0 ml
Hematoxylin 10.0 gm
Age 4-6 wk before use.

⁶Hematoxylin working solution

Distilled water 190.0 ml
Hematoxylin stock 10.0 ml
DMSO 20.0 ml

Avoid DMSO contact with skin.

Note: Both hematein and hematoxylin are included for above procedure for Heidenhain's iron hematoxylin. Hematoxylin stock takes 4-6 wk to ripen, while hematein may be used immediately. Do not contaminate hematoxylin with mordant; stain will become ineffective. **DMSO is a carrier that will allow other chemicals to penetrate skin.**

⁷Picric acid (saturated aqueous)

Distilled water 20.0 ml
Picric acid 2.0 gm

Note: Saturated solution of picric acid available from Fisher Scientific[®] cat. # CS-311-1.

⁸Eosin B

Eosin B 1.0 gm
95% ETOH 100.0 ml
Age 1 mo.

Note: Eosin B available from Fisher Scientific[®] cat. # E-514-25.

(16) Mallory's Hematein (1 h) (Lillie 1965)

Specific for copper and other metals. Use a positive control test slide.

Procedure:

- 1) Deparaffinize
- 2) Hydrate to water, but do not permit slides to remain in water (**may interfere with copper reaction**)
- 3) Prepare hematein stock¹ and working² solutions
- 4) Stain in hematein working solution² - 5 min
- 5) 0.5% lithium carbonate³ - 3 dips, approx. 30 sec, or until sections turn blue (sections may turn blue in slightly alkaline tap water without lithium carbonate)
- 6) Rinse in distilled water- 1 min
- 7) Counterstain in 1% safranin O⁴ - 2 min
- 8) Wash in running tap water - 2 min
- 9) Destain in 1 part 100% ETOH to 9 parts butanol - 1-6 dips (C.A. Farley, NOAA, Oxford, MD, pers. commun. 1980)
- 10) Butanol - 2 min
- 11) Butanol - 5 min
- 12) Clear
- 13) Mount

Results (Fig. 8-11):

Heavy metals, e.g., copper - blue-black
Background - bright red

Reagents:

¹0.5% hematein stock solution (Farley 1988)

Hematein 1.0 gm
Distilled water 200.0 ml

²Hematein working solution (Mitchell 1966)

0.5% hematein stock 10 parts
Dimethyl sulfoxide (DMSO) 1 part

Prepare immediately prior to use. Will not keep after DMSO is added. **Avoid DMSO contact with skin.**

Note: Do not contaminate hematein; a dark color change will indicate stain is no longer usable. **DMSO is a carrier that will allow other chemicals to penetrate skin.**

³0.5% lithium carbonate

Lithium carbonate 0.5 gm
Distilled water 100.0 ml

⁴1% safranin O (Conn et al. 1962)

Safranin O 1.0 gm
Distilled water 100.0 ml

(17) Mallory's Trichrome (1 h) (Pauley 1967)

Specific for collagen and connective tissue. Use a positive control test slide.

Procedure:

- 1) Deparaffinize
- 2) Hydrate to water
- 3) Stain in 0.5% acid fuchsin¹ - 7 min
- 4) Wash in tap water - 2 dips
- 5) Blot slide well
- 6) Stain in aniline blue-orange G² - 15 min (fixative specific)
- 7) Wash in tap water - 2 quick dips
- 8) Transfer to several changes of 95% ETOH - quick dips
- 9) Dehydrate quickly to prevent loss of aniline blue
- 10) Clear
- 11) Mount

Results (Fig. 8-12):

Collagen fibers - intense blue (also reticulum - pale blue)
Elastic fibers - pale pink, pale yellow, or unstained
Muscle - red, purple, or blue (depending on specimen)
Erythrocytes and myelin - yellow
Nuclei - red

Reagents:

¹0.5% acid fuchsin
Acid fuchsin 0.5 gm
Distilled water 100.0 ml
For best results, age several days.

For tissues fixed in formalin or Davidson's (Johnson 1980)

²Aniline blue-orange G
Dissolve in order:
Aniline blue 0.5 gm
Orange G 2.0 gm
Phosphomolybdic acid 1.0 gm
Distilled water 100.0 ml

For tissues fixed in Zenker or Helly's (Johnson 1980)

²Aniline blue-orange G
Dissolve in order:
Aniline blue 0.5 gm
Orange G 2.0 gm
Phosphotungstic acid 2.0 gm
Distilled water 100.0 ml
Glacial acetic acid 2 drops

(18) Malt Periodic Acid Schiff (MPAS) (2 h 20 min)
(Lillie 1965)

Specific for digestion of glycogen, neutral mucopolysaccharides and PAS-positive substances other than glycogen. Test Schiff reaction before staining process.

Procedure:

- 1) Deparaffinize
- 2) Hydrate to water
- 3) Immerse in 0.1% diastase malt¹ - 1 h at 40°C
- 4) Wash well in running tap water - 10 min
- 5) Rinse in distilled water - 1 min
- 6) Oxidize in 1% periodic acid² at room temp. - 5 min
- 7) Wash in running tap water - 5 min
- 8) Rinse in distilled water - 1 min (**tap water will contaminate and cause discoloration of Schiff**)
- 9) Blot well, stain in refrigerated Schiff reagent³ - 5 min
- 10) Wash well in running tap water - 10 min
- 11) Stain in Harris' hematoxylin⁴ - 2 min
- 12) 0.5% lithium carbonate⁵ - 3 dips, approx. 30 sec, or until sections turn blue (sections may turn blue in slightly alkaline tap water without lithium carbonate)
- 13) Rinse well in distilled water to eliminate lithium carbonate - 2 min
- 14) Dehydrate
- 15) Clear
- 16) Mount

Results (Fig. 8-13):

Glycogen - digested
Neutral mucopolysaccharides - magenta
Other PAS-positive substances - pink to magenta
Nuclei and other basophilic substances - blue

Reagents:

¹ 0.1% diastase malt	
Diastase malt	0.2 gm
Buffer, pH 5.5-6.0	20.0 ml
Distilled water	180.0 ml

Buffer for malt	
Boiling distilled water	1000.0 ml
Sodium phosphate monobasic (NaH ₂ PO ₄ · H ₂ O)	1.97 gm
Sodium phosphate dibasic (Na ₂ HPO ₄)	0.28 gm

Note: pH 5.5 to 6.0. Add 1 thymol crystal when cool to prevent mold, and refrigerate.

² 1% periodic acid (Drury and Wallington 1967)	
Periodic acid	1.0 gm
Distilled water	100.0 ml

- ³Schiff (Sanders 1972)
- 1) Boil 200 ml of distilled water
 - 2) Add 1.0 gm of basic fuchsin and stir
 - 3) Cool to 50°C (filter optional)
 - 4) Add 20 ml of normal HCl (916.5 ml of distilled water and 83.5 ml of concentrated HCl sp. gr. 1.19; **handle HCl with care**)
 - 5) Cool to 25°C (room temp.)
 - 6) Add 1.0 gm of sodium metabisulfite (Na₂S₂O₅)
 - 7) Shake vigorously
 - 8) Store in dark until reagent turns a straw color - approx. 2 days
 - 9) Add approx. ½ gm/200 ml charcoal; shake and filter
 - 10) Keep refrigerated at all times, even during staining process, to prevent breakdown of Schiff

Note: Schiff reagent available ready-made from Poly Scientific^b cat. # S-272 very reliable. To make Schiff reagent, we suggest using basic fuchsin (pararosaniline) available from Fisher Scientific^c cat. # F-98-10. It is important to get a good "lot" of basic fuchsin. Discard Schiff when it takes on purple tone; it will no longer stain effectively. For best results, make separate 200-ml portions and store in separate containers.

⁴Harris' hematoxylin

Note: Harris' hematoxylin available from Newcomer Supply^f cat. # 1201A.

⁵ 0.5% lithium carbonate	
Lithium carbonate	0.5 gm
Distilled water	100.0 ml

(19) Malt Periodic Acid Schiff-Alcian Blue (MPAS-AB) (5 h) (McManus and Mowry 1960)

Specific for differentiation of acid and neutral mucopolysaccharides. Test Schiff reaction before staining process. Use a positive control test slide.

Procedure:

- 1) Deparaffinize
- 2) Hydrate to water
- 3) Immerse in 0.1% diastase malt¹ - 1 h at 40°C
- 4) Wash well in running tap water - 10 min
- 5) Rinse in distilled water - 1 min
- 6) Oxidize in 1% periodic acid² at room temp. - 5 min
- 7) Wash in running water - 5 min
- 8) Distilled water - 1 min (**tap water will contaminate and cause discoloration of Schiff**)
- 9) Blot well, stain in refrigerated Schiff reagent³ - 5 min
- 10) Wash well in running tap water - 10 min
- 11) Stain in Harris' hematoxylin⁴ - 2 min
- 12) 0.5% lithium carbonate⁵ - 3 dips, approx. 30 sec, or until sections turn blue (sections may turn blue in slightly alkaline tap water without lithium carbonate)
- 13) Rinse in distilled water - 2 min
- 14) Stain in 0.1% alcian blue⁶ (fixative specific; check expiration date of stain) - 30 min
- 15) Wash in running tap water - 1 min
- 16) 0.5% alcoholic ammonium hydroxide⁷ - 2 h
- 17) Wash in running tap water - 1 min
- 18) Rinse in distilled water - 1 dip
- 19) Dehydrate
- 20) Clear
- 21) Mount

Results (Fig. 8-14):

Acid mucopolysaccharides - bright intense blue
Neutral mucopolysaccharides - magenta
PAS-positive tissue - pink to magenta
Glycogen - digested
Nuclei - blue

Reagents:

¹0.1% diastase malt
Diastase malt 0.2 gm
Buffer, pH 5.5-6.0 20.0 ml
Distilled water 180.0 ml

Buffer for malt (Lillie 1965)

Boiling distilled water 1000.0 ml
Sodium phosphate monobasic
(NaH₂PO₄ · H₂O) 1.97 gm
Sodium phosphate dibasic (Na₂HPO₄) 0.28 gm

Note: pH 5.5 to 6.0. Add 1 thymol crystal when cool to prevent mold, and refrigerate.

²1% periodic acid (Drury and Wallington 1967)

Periodic acid 1.0 gm
Distilled water 100.0 ml

³Schiff (Sanders 1972)

- 1) Boil 200 ml of distilled water
- 2) Add 1.0 gm of basic fuchsin and stir
- 3) Cool to 50°C (filter optional)
- 4) Add 20 ml of normal HCl (916.5 ml of distilled water and 83.5 ml of concentrated HCl sp. gr. 1.19; **handle HCl with care**)
- 5) Cool to 25°C (room temp.)
- 6) Add 1.0 gm of sodium metabisulfite (Na₂S₂O₅)
- 7) Shake vigorously
- 8) Store in dark until reagent turns a straw color, approx. 2 days
- 9) Add approx. ½ gm/200 ml charcoal; shake and filter
- 10) Keep refrigerated at all times, even during staining process, to prevent breakdown of Schiff

Note: Schiff reagent available ready-made from Poly Scientific^b cat. # S-272 very reliable. To make Schiff reagent, we suggest using basic fuchsin (pararosaniline) available from Fisher Scientific^c cat. # F-98-10. It is important to get a good "lot" of basic fuchsin. Discard Schiff when it takes on purple tone; it will no longer stain effectively. For best results, make separate 200-ml portions and store in separate containers.

⁴Harris' hematoxylin

Note: Harris' hematoxylin available from Newcomer Supply^f cat. # 1201A.

⁵0.5% lithium carbonate

Lithium carbonate 0.5 gm
Distilled water 100.0 ml

For tissues fixed in Zenker or Helly's (Johnson 1980)

⁶0.1% alcian blue in 0.01 M HCl (pH 2.2)

- Alcian blue 8GX 1.0 gm
- 1 N HCl 10.0 ml
- Distilled water 990.0 ml

Handle HCl with care.

For tissues fixed in formalin or Davidson's (Johnson 1980)

⁶0.1% alcian blue in 3% acetic acid

- Alcian blue 8GX 0.1 gm
- Distilled water 97.0 ml
- Glacial acetic acid 3.0 ml

⁷0.5% alcoholic ammonium hydroxide (Johnson 1980)

- Ammonium hydroxide 3.0 ml
- 95% ETOH 597.0 ml

(20) Mayer's Hematoxylin and Eosin (MHE) (1h 10 min)
(Luna 1968)

General stain for formalin-fixed tissue.

Procedure:

Routine histology

- 1) Deparaffinize
- 2) Hydrate to water
- 3) Stain in aged Mayer's hematoxylin¹ - 5 min
- 4) Rinse in distilled water - 2 min
- 5) 0.5% lithium carbonate² - 3 dips, approx. 30 sec, or until sections turn blue (sections may turn blue in slightly alkaline tap water without lithium carbonate)
- 6) Rinse well in distilled water to eliminate lithium carbonate - 2 min
- 7) 70% ETOH - 3 min
- 8) Prepare eosin Y-phloxine B stock³ and working⁴ solutions
- 9) Counterstain in eosin Y-phloxine B working solution⁴ - 3 min
- 10) 95% ETOH - 6 dips
- 11) Dehydrate
- 12) Clear
- 13) Mount

Laser capture microdissection (LCM) (V. Espina, NIH, Bethesda, MD, pers. commun. 2004)

- 1) Deparaffinize
- 2) Hydrate to water
- 3) Stain in aged Mayer's hematoxylin¹ - 30 sec
- 4) Rinse in distilled water - 2 changes, 15 sec each
- 5) 70% ETOH - 15 sec
- 6) 95% ETOH - 2 changes, 15 sec each
- 7) 100% ETOH - 2 changes, 15 sec each
- 8) Clear
- 9) Air dry and examine

Results (Fig. 8-15):

Basophilic substances - blue
Acidophilic substances - pink

Reagents:

¹Mayer's hematoxylin

Dissolve in order:

Distilled water	1000.0 ml
Aluminum ammonium sulfate	50.0 gm
Hematoxylin	1.0 gm
Citric acid	1.0 gm
Chloral hydrate (see <i>Note</i>)	50.0 gm
Sodium iodate	0.2 gm

Age minimum of 1 wk. Filter before use. Stores well for months.

Note: Chloral hydrate in the USA is a controlled substance that requires a special permit issued by the U.S. Department of Justice, Drug Enforcement Administration. A modified version of Mayer's hematoxylin available from Poly Scientific^b cat. # S-216.

²0.5% lithium carbonate

Lithium carbonate	0.5 gm
Distilled water	100.0 ml

³Eosin Y-phloxine B stock solution

95% ETOH	877.5 ml
1% eosin Y	112.5 ml
1% phloxine B	11.25 ml

1% eosin Y:

Eosin Y	1.0 gm
Distilled water	100.0 ml

1% phloxine B:

Phloxine B	1.0 gm
Distilled water	100.0 ml

⁴Eosin Y-phloxine B working solution

Stock solution	200.0 ml
Glacial acetic acid	0.9 ml

(21) Oil Red O (ORO) (10 min) (Thompson 1966)

Specific for fat in frozen tissue.

Procedure:

- 1) Frozen sections, air-dried or fixed (if fixed, wash out fixative)
- 2) Rinse in 49.5% isopropyl alcohol¹ - 2 dips
- 3) Prepare oil red O stock² and working³ solutions
- 4) Stain in oil red O working solution³ - 5 min
- 5) Rinse in 49.5% isopropyl alcohol¹ - 2 dips
- 6) Rinse in distilled water - 2 min
- 7) Stain in Harris' hematoxylin⁴ - 5 min
- 8) Wash in running tap water - 5 min
- 9) Mount in glycerin jelly⁵ or Advantage mounting medium (see *Note*)

Results (Fig. 8-16):

Fat - bright orange to red
Nuclei - blue

Reagents:

¹49.5% isopropyl alcohol
99% isopropyl alcohol 50.0 ml
Distilled water 50.0 ml

²Oil red O stock solution (supersaturated)
Oil red O 0.5 gm
99% isopropyl alcohol 125.0 ml

³Oil red O working solution (saturated)
Oil red O stock 12.0 ml
Distilled water 8.0 ml
Mix, allow solution to stand for 5 min, and filter. Discard when precipitate forms.

⁴Harris' hematoxylin

Note: Harris' hematoxylin available from Newcomer Supply^f cat. # 1201A.

⁵Glycerin jelly (Prophet et al. 1992)

Gelatin 10.0 gm
Distilled water 60.0 ml

Heat until gelatin is dissolved, then add:

Glycerin 70.0 ml
Thymol Several crystals

Note: Advantage mounting medium available ready to use from Innovex Biosciences^g cat. # NB 300.

(22) Periodic Acid Schiff₁ (PAS₁) with Weigert's Hematoxylin (1 h 15 min) (Lillie 1965)

Specific for neutral mucopolysaccharides, glycogen, and fungi. Test Schiff reaction before staining process.

Procedure:

- 1) Deparaffinize
- 2) Hydrate to water
- 3) Oxidize in 1% periodic acid¹ at room temp. - 5 min
- 4) Wash in running tap water - 5 min
- 5) Rinse in distilled water - 1 min (**tap water will contaminate and cause discoloration of Schiff**)
- 6) Blot well, stain in refrigerated Schiff reagent² - 5 min
- 7) Wash immediately in running tap water - 10 min
- 8) Rinse in distilled water - 6 dips
- 9) Stain in Weigert's hematoxylin³ - 30 sec
- 10) Wash in running tap water - 6 dips
- 11) Rinse in distilled water - 6 dips
- 12) Dehydrate
- 13) Clear
- 14) Mount

Results (Fig. 8-17):

Neutral mucopolysaccharides - magenta
Fungi walls - magenta
Glycogen - magenta
PAS-positive substances - pink to magenta
Nuclei and other basophilic substances - blue-black

Reagents:

¹1% periodic acid (Drury and Wallington 1967)
Periodic acid 1.0 gm
Distilled water 100.0 ml

²Schiff (Sanders 1972)
1) Boil 200 ml of distilled water
2) Add 1.0 gm of basic fuchsin and stir
3) Cool to 50°C (filter optional)
4) Add 20 ml of normal HCl (916.5 ml of distilled water and 83.5 ml of concentrated HCl sp. gr. 1.19; **handle HCl with care**)
5) Cool to 25°C (room temp.)
6) Add 1.0 gm of sodium metabisulfite (Na₂S₂O₅)
7) Shake vigorously

- 8) Store in dark until reagent turns a straw color - approx. 2 days
- 9) Add approx. ½ gm/200 ml of charcoal; shake and filter
- 10) Keep refrigerated at all times, even during staining process, to prevent breakdown of Schiff

Note: Schiff reagent available ready-made from Poly Scientific^b cat. # S-272 very reliable. To make Schiff reagent, we suggest using basic fuchsin (pararosaniline) available from Fisher Scientific^c cat. # F-98-10. It is important to get a good "lot" of basic fuchsin. Discard Schiff when it takes on purple tone; it will no longer stain effectively. For best results, make separate 200-ml portions and store in separate containers..

³Weigert's hematoxylin

Solution a:

Hematoxylin 1.0 gm
95% ETOH 100.0 ml

Solution b:

Ferric chloride (FeCl₃ · 6H₂O) 2.5 gm
Distilled water 99.0 ml
HCl 1.0 ml

Prepare fresh before use, mixing equal parts of solutions a and b immediately beforehand (stain does not keep well). **Handle HCl with care.**

Note: In this procedure, work quickly; rinse slides in running water to avoid overstaining and precipitation of stain; acid-cleaned slides will prevent stain precipitation.

(23) Periodic Acid Schiff₂ (PAS₂) with Heidenhain's Hematoxylin (1 h 45 min) (Lillie 1965)

Specific for nuclear detail, fungi, glycogen, and neutral mucopolysaccharides. Test Schiff reaction before staining process.

Procedure:

- 1) Deparaffinize
- 2) Hydrate to water
- 3) Oxidize in 1% periodic acid¹ at room temp. - 5 min
- 4) Wash in running tap water - 5 min
- 5) Rinse in distilled water - 1 min (**tap water will contaminate and cause discoloration of Schiff**)
- 6) Blot well, stain in refrigerated Schiff reagent² - 5 min
- 7) Rinse immediately in running tap water - 10 min
- 8) Rinse in distilled water - 6 dips
- 9) Mordant in 3% ferric ammonium sulfate³ - 5 min
- 10) Wash in running tap water - 2 min
- 11) Prepare Heidenhain's hematoxylin stock⁴ and working⁵ solutions
- 12) Stain in aged Heidenhain's hematoxylin working solution⁴ - 2-5 min at room temp. (according to intensity desired)
- 13) Differentiate in picric acid⁶ until only nuclei remain stained - 10-20 min (check with microscope)
- 14) Wash in running tap water - 2 min
- 15) Dehydrate
- 16) Clear
- 17) Mount

Results:

Neutral mucopolysaccharides - magenta
Nuclei and other basophilic substances - blue-black
PAS-positive substances - pink to magenta
Glycogen, collagen, reticulum, mucin - magenta

Reagents:

¹1% periodic acid (Drury and Wallington 1967)
Periodic acid..... 1.0 gm
Distilled water..... 100.0 ml

²Schiff (Sanders 1972)

- 1) Boil 200 ml of distilled water
- 2) Add 1.0 gm of basic fuchsin and stir

- 3) Cool to 50°C (filter optional)
- 4) Add 20 ml of normal HCl (916.5 ml of distilled water and 83.5 ml of concentrated HCl sp. gr. 1.19; **handle HCl with care**)
- 5) Cool to 25°C (room temp.)
- 6) Add 1.0 gm of sodium metabisulfite (Na₂S₂O₅)
- 7) Shake vigorously
- 8) Store in dark until reagent turns a straw color - approx. 2 days
- 9) Add approx. ½ gm/200 ml of charcoal; shake and filter
- 10) Keep refrigerated at all times, even during staining process, to prevent breakdown of Schiff

Note: Schiff reagent available ready-made from Poly Scientific^b cat. #S-272 very reliable. To make Schiff reagent, we suggest using basic fuchsin (pararosaniline) available from Fisher Scientific^c cat. # F-98-10. It is important to get a good "lot" of basic fuchsin. Discard Schiff when it takes on purple tone; it will no longer stain effectively. For best results, make separate 200-ml portions and store in separate containers.

³3% ferric ammonium sulfate
Ferric ammonium sulfate 3.0 gm
Distilled water 100.0 ml

⁴Heidenhain's hematoxylin stock solution (Lillie 1965)
100% ETOH 100.0 ml
Hematoxylin 10.0 gm
Age 4-6 wk before use.

⁵Heidenhain's hematoxylin working solution
Distilled water 190.0 ml
Hematoxylin stock 10.0 ml
Dimethyl sulfoxide (DMSO) 20.0 ml

Avoid DMSO contact with skin.

Note: Do not contaminate hematoxylin with mordant; stain will become ineffective. **DMSO is a carrier that will allow other chemicals to penetrate skin.**

⁶Picric acid (saturated aqueous)
Distilled water 20.0 ml
Picric acid 2.0 gm

Note: Saturated solution of picric acid available from Fisher Scientific^c cat. # CS-311-1.

(24) Perls' Prussian Blue (2 h) (Drury and Wallington 1967)

Specific for ferric iron. Use a positive control test slide and acid-cleaned glassware.

Note: Keep solutions away from metal to avoid contamination. Acid fixatives and versenate decalcification interfere with staining of iron (Drury and Wallington 1967).

Procedure:

- 1) Deparaffinize
- 2) Hydrate to water
- 3) Stain sections in fresh mixture of equal parts of 2% potassium ferrocyanide¹ or 2% sodium ferrocyanide² and 2% HCl³ - 30-60 min (if longer period is used, change solution after first 30 min)
- 4) Rinse in distilled water - 1 min
- 5) Stain nuclei in 1% neutral red⁴ - 3 min
- 6) Wash in running tap water - 2 min
- 7) Dehydrate
- 8) Clear
- 9) Mount in Canada balsam (neutral mounting medium)

Results (Fig. 8-18):

Ferric iron - deep blue to green
Nuclei - red
Background - pink

Reagents:

¹2% potassium ferrocyanide
Potassium ferrocyanide 2.0 gm
Distilled water 100.0 ml

²2% sodium ferrocyanide
Sodium ferrocyanide 2.0 gm
Distilled water 100.0 ml

³2% HCl
Concentrated HCl sp. gr. 1.19 2.0 ml
Distilled water 98.0 ml

Handle HCl with care.

⁴1% neutral red
Neutral red 1.0 gm
Distilled water 100.0 ml

(25) Protargol (2 days) (Lee et al. 1985)

Specific for cilia and ciliate organelles. Reproducible results are difficult to attain. Use multiple control slides with ciliates and acid-cleaned glassware.

Procedure:

- 1) Place 1 drop of fresh culture medium containing live ciliates directly onto slide coated with poly-L-lysine or aminoalkylsilane adhesive (see pp. 75-76)
- 2) In fume hood, place 1 drop of fixative on each slide and fix overnight in double strength 1% glutaraldehyde/4% formaldehyde (1G4F)¹ made with artificial seawater adjusted to ambient salinity of ciliates (place slides in ziplock bag to prevent dehydration)
- 3) Drain 1G4F fixative from slides and postfix in Bouin's/ Davidson's fixative² - 2 h (for paraffin sections, deparaffinize, hydrate, then postfix as above)
- 4) Drain and gently rinse until all yellow Bouin's residue is removed
- 5) 50% ETOH - 1 min
- 6) 70% " - 1 min
- 7) 95% " - 1 min
- 8) 100% " - 1 min
- 9) Prepare collodion stock³ and working⁴ solutions
- 10) 0.5% collodion working solution⁴ - 1-2 dips
- 11) Drain
- 12) 70% ETOH - 5 dips
- 13) 50% ETOH - 3 dips
- 14) Rinse in distilled water - 2 min
- 15) Immerse in 0.5% potassium permanganate⁵ - 5 min
- 16) Rinse in distilled water - several changes
- 17) Immerse in 5% oxalic acid⁶ - 5 min
- 18) Rinse in distilled water - several changes
- 19) Thoroughly clean copper strips using emery cloth or other abrasive, **or** by flaming until red hot and dropping into 95% ETOH; do not overheat ETOH (**very dangerous, could ignite**; be ready to cover). Place clean copper strips diagonally between slides
- 20) Cover slides with 1% protargol⁷; pH should be 7.9-8.6 (approx. 50 ml will cover slides placed in a 100-ml coplin jar with slides placed back to back and copper strips evenly dispersed). Impregnate overnight at room temp.
- 21) Drain and immediately place in 4% hydroquinone⁸ - 5 min
- 22) Rinse in distilled water - 3 min
- 23) Tone in 1% gold chloride⁹ - 30 sec-1 min
- 24) Immediately place in 2% oxalic acid¹⁰ - 2 min
- 25) Rinse in distilled water - 5 min

- 26) 5% sodium thiosulfate¹¹ - 5 min
- 27) Rinse in distilled water - 2 min
- 28) Dehydrate
- 29) Clear
- 30) Mount

Note: Sheets of copper may be found in craft stores and cut to desired size. Copper strips must be thoroughly cleaned.

Results (Figs. 8-19, 8-20a, b):

Cilia - may stain black
Kinetids - black
Nuclei - black
Cytoplasm - clear to lavender

Reagents:

¹1G4F double strength (see p. 63)

²Bouin's/Davidson's fixative (see p. 60)

³1% collodion stock solution

Parlodion (=collodion, celloidin, nitrocellulose, cellulose nitrate, pyroxylin) 1.0 gm
100% methanol 100.0 ml

Let stand until parlodion dissolves. **Handle parlodion with extreme caution; avoid strong impacts.**

⁴0.5% collodion working solution

1% collodion stock solution 20.0 ml
Methanol 20.0 ml

⁵0.5% potassium permanganate

Potassium permanganate 0.5 gm
Distilled water 100.0 ml

⁶5% oxalic acid

Oxalic acid 5.0 gm
Distilled water 100.0 ml

⁷1% protargol (strong silver protein)

Protargol 1.0 gm
Distilled water 100.0 ml

Sprinkle silver on surface of distilled water; let stand until completely dissolved, about 1-2 h. Use fresh or refrigerate. **Never stir solution.**

Note: Protargol available from Cell Point^h cat. #30906 yields consistent results.

⁸4% hydroquinone

Hydroquinone 4.0 gm

Distilled water 100.0 ml

Make fresh just before use; 4% is saturated solution.

Do not inhale hydroquinone powder.

⁹1% gold chloride

Gold chloride 1.0 gm

Distilled water 100.0 ml

Keep refrigerated. Bring to room temp. before use.

Filter solution after use if precipitate visible.

Note: Gold chloride available from Sigma^a cat. # G-4022.

Solution may be used repeatedly if clear yellow after filtering.

¹⁰2% oxalic acid

Oxalic acid 2.0 gm

Distilled water 100.0 ml

¹¹5% sodium thiosulfate

Sodium thiosulfate 5.0 gm

Distilled water 100.0 ml

(28) Von Kossa (2 h) (Sanders 1972)

powder form from J.T.Baker^c cat. # S635-01. Refrigerate; stain is good until it loses color.

Specific for calcium. Use a positive control test slide and acid-cleaned glassware.

Procedure:

- 1) Deparaffinize
- 2) Hydrate to water
- 3) Impregnate slides in 5% silver nitrate¹ - 30-60 min, exposed to direct sunlight (hi-intensity lamps not as effective as natural sunlight)
- 4) Rinse in distilled water - 2-3 changes
- 5) 5% sodium thiosulfate² - 2-3 min
- 6) Rinse in distilled water - 2 min
- 7) Stain nuclei in nuclear fast red (Kernechtrot)³ - 5 min
- 8) Rinse well in distilled water - 6 dips (to prevent formation of white precipitate)
- 9) Dehydrate
- 10) Clear
- 11) Mount

Results (Fig. 8-22):

Calcium salts - black

Nuclei - red

Cytoplasm - pink to rose

Reagents:

¹5% silver nitrate

Silver nitrate 5.0 gm
Distilled water 100.0 ml

²5% sodium thiosulfate

Sodium thiosulfate 5.0 gm
Distilled water 100.0 ml

³Nuclear fast red (Kernechtrot)

5% aluminum sulfate ($\text{Al}_2(\text{SO}_4)_3$):

$\text{Al}_2(\text{SO}_4)_3$ 25.0 gm
Distilled water 500.0 ml

0.1% nuclear fast red:

Nuclear fast red 0.5 gm
5% $\text{Al}_2(\text{SO}_4)_3$ 500.0 ml

Note: Nuclear fast red (Kernechtrot) available as a ready to use 0.1% solution from Poly Scientific^b cat. # S248 or in

(29) Ziehl-Neelsen and Harris' Hematoxylin (ZHH)
(1 h 45 min) (Farley 1965)

Note: Basic fuchsin (pararosaniline) available from Fisher Scientific^c cat. # F-98-10.

Specific for acid-fast substances (e.g., haplosporidan spores, microsporida, and *Cryptosporidium* oocysts). Use a positive control test slide.

²0.1 N sulfuric acid (H₂SO₄)

Distilled water 997.2 ml

H₂SO₄ sp. gr. 1.84 2.8 ml

³Harris' hematoxylin

Procedure:

Note: Harris' hematoxylin available from Newcomer Supply^f cat. # 1201A.

- 1) Deparaffinize
- 2) Hydrate to water
- 3) Stain in Ziehl-Neelsen fuchsin¹ - 15 min
- 4) Rinse in distilled water - 6 dips
- 5) Destain in 0.1 N sulfuric acid² - 10-15 min (time varies with specific tissue)
- 6) Wash in running tap water - 10 min
- 7) Stain in Harris' hematoxylin³ - 2 min
- 8) Rinse in distilled water - 6 dips
- 9) 0.5% lithium carbonate⁴ - 3 dips, approx. 30 sec, or until sections turn blue (sections may turn blue in slightly alkaline tap water without lithium carbonate)
- 10) Rinse well in distilled water to eliminate lithium carbonate - 5 min
- 11) Dehydrate
- 12) Clear
- 13) Mount

⁴0.5% lithium carbonate

Lithium carbonate 0.5 gm

Distilled water 100.0 ml

Results (Fig. 8-23):

Basophilic substances - blue

Acid-fast substances, including mature haplosporidan sporoplasms, lipofuscins, acid-fast bacteria, and *Cryptosporidium* oocysts - bright red

Reagents:

¹Ziehl-Neelsen fuchsin (Gray 1954)

Basic fuchsin (magenta) 1.0 gm

Phenol (liquefied) 5.0 ml

90% ETOH 10.0 ml

Distilled water 100.0 ml

- 1) In fume hood, grind fuchsin with phenol in a mortar
- 2) When dissolved, add alcohol in 10 successive lots while grinding
- 3) Wash stain from mortar with ten 10-ml washings of distilled water
- 4) Save and filter accumulated washings

(30) Ziehl-Neelsen and Methylene Blue (1 h 30 min)
(Luna 1968)

Specific for acid-fast organisms and acid-fast bacteria (AFB). Use a positive control test slide.

Procedure:

- 1) Deparaffinize
- 2) Hydrate to water
- 3) Stain in Ziehl-Neelsen fuchsin¹ - 15 min
- 4) Rinse in distilled water - several dips - (approx. time) 1 min
- 5) Destain in 0.1 N sulfuric acid² - 10-15 min (time varies with specific tissue)
- 6) Wash in running tap water - 10 min
- 7) Rinse in distilled water - 3 dips
- 8) Prepare methylene blue stock³ and working⁴ solutions
- 9) Counterstain in methylene blue working solution⁴ - dip quickly (stains quickly, depending on tissue)
- 10) Wash in running tap water - 5 min
- 11) Dehydrate
- 12) Clear
- 13) Mount

Results (Fig. 8-24):

Background - pale blue

Acid-fast substances, including mature haplosporidan sporoplasms, lipofuscins, and acid-fast bacteria - bright red

Reagents:

¹Ziehl-Neelsen fuchsin (Gray 1954)

Basic fuchsin (magenta)	1.0 gm
Phenol (liquefied)	5.0 ml
90% ETOH	10.0 ml
Distilled water	100.0 ml

- 1) In fume hood, grind fuchsin with phenol in a mortar
- 2) When dissolved, add alcohol in 10 successive lots while grinding
- 3) Wash stain from mortar with ten 10-ml washings of distilled water
- 4) Save and filter accumulated washings

Note: Basic fuchsin (pararosaniline) available from Fisher Scientific® cat. # F-98-10.

²0.1 N sulfuric acid (H₂SO₄)

Distilled water	997.2 ml
H ₂ SO ₄ sp. gr. 1.84	2.8 ml

³Methylene blue stock solution

Methylene blue	1.4 gm
95% ETOH	100.0 ml

⁴Methylene blue working solution

Methylene blue stock	10.0 ml
Distilled water	90.0 ml

C. Problems and Resolutions

Table 8-4 (pp. 127-128) includes some problems or artifacts resulting from staining, as well as some means of resolving them.

D. Footnotes

^aSigma, P.O. Box 14508, St. Louis, MO 63178-9916. (800) 325-3010. www.sigma-aldrich.com

^bPoly Scientific R&D Corp., 70 Cleveland Ave., Bay Shore, NY 11706. (516) 586-0400. www.polyrnd.com

^cJ.T. Baker, 222 Red School Lane, Phillipsburg, NJ 08865. (800) 582-2537. www.jtbaker.com

^dEMD Chemicals Inc., 480 S. Democrat Road, Gibbstown, NJ 08027. (800) 222-0342. www.emdchemicals.com

^eFisher Scientific, 3970 Johns Creek Court, Suwanee, GA 30024. (800) 766-7000. www.fishersci.com

^fNewcomer Supply, 2217b Parview Road, Middleton, WI 53562. (800) 383-7799. www.newcomersupply.com

^gInnovex Biosciences, 4505 MacDonald Ave., Richmond, CA 94805. (800) 622-7208. www.innvx.com

^hCell Point Scientific, 9210 Corporate Blvd. Suite 220, Rockville, MD 20850. (800) 999-9734. www.cellpointscientific.com

E. References

Brown, J.H. and L. Brenn. 1931. A method for the differential staining of gram-positive and gram-negative bacteria in tissue sections. *Bull. Johns Hopkins Hosp.* 48: 69-73.

Brown, R.C. and H.C. Hopps. 1973. Staining of bacteria in tissue sections: a reliable Gram stain method. *Am. J. Clin. Pathol.* 60: 234-240.

Carson, F.L. 1990. *Histotechnology - A Self-instructional Text*. American Society of Clinical Pathologists, Chicago, IL. 294 p.

Conn, H.J., M.A. Darrow, and V.M. Emmel. 1962. *Staining Procedures Used by the Biological Stain Commission*. 2d ed. Williams and Wilkins Co., Baltimore, MD. 289 p.

Coolidge, B.J. and R.M. Howard. 1979. *Animal Histology Procedures of the Pathological Technology Section of the National Cancer Institute*. 2d ed. NIH Publ. No. 80-275, National Institutes of Health, Bethesda, MD. 209 p.

Dahl, L.K. and V.P. Dole. 1952. The biphasic nature of renal calcification. *J. Exp. Med.* 95: 341-346.

Drury, R.A.B. and E.A. Wallington. 1967. *Carleton's Histological Technique*. 4th ed. Oxford Univ. Press, New York. 432 p.

Farley, C.A. 1965. Acid-fast staining of haplosporidian spores in relation to oyster pathology. *J. Invertebr. Pathol.* 7: 144-147.

Farley, C.A. 1969. Probable neoplastic disease of the hematopoietic system in oysters, *Crassostrea virginica* and *Crassostrea gigas*, pp. 541-555. *In: C.J. Dawe and J.C. Harshbarger (eds.), Neoplasms and Related Disorders of Invertebrate and Lower Vertebrate Animals*. Natl. Cancer Inst. Monogr. 31.

Farley, C.A. 1988. Histochemistry as a tool for examining possible pathologic cause-and-effect relationships between heavy metal and inflammatory lesions in oysters, *Crassostrea virginica*. *Mar. Environ. Res.* 24: 271-275.

Feder, N. and T.P. O'Brien. 1968. Plant microtechnique: some principles and new methods. *Am. J. Bot.* 55: 123-142.

Gray, P. 1954. *The Microtome's Formulary and Guide*. Blakiston Co., New York. 794 p.

Johnson, P.T. 1980. *Histology of the Blue Crab, Callinectes sapidus. A Model for the Decapoda*. Praeger, New York. 440 p.

Lee, J.J., E.B. Small, D.H. Lynn, and E.C. Bovee. 1985. Some techniques for collecting, cultivating, and observing protozoa, pp.1-7. *In: J.J. Lee, S.H. Hutner, and E.C. Bovee (eds.), An Illustrated Guide to the Protozoa*. Society of Protozoologists, Lawrence, KS.

Liddell, V.A. 1967. Frozen-section technique in shellfish research. *J. Invertebr. Pathol.* 9: 283-284.

Lillie, R.D. 1954. *Histopathologic Technic and Practical Histochemistry*. McGraw-Hill, New York. 501 p.

Lillie, R.D. 1965. *Histopathologic Technic and Practical Histochemistry*. 3d ed. McGraw-Hill, New York. 715 p.

Luna, L.G., Editor. 1968. *Manual of Histologic Staining Methods of the Armed Forces Institute of Pathology*. 3d ed. McGraw-Hill, New York. 258 p.

McManus, J.F.A. and R.W. Mowry. 1960. Staining Methods - Histologic and Histochemical. Harper & Row, New York. 423 p.

Mitchell, H.L. 1966. A simple method of permanent staining of intestinal parasites, using dimethyl sulfoxide. Tech. Bull. Regist. Med. Technol. 36: 45-46.

Pauley, G.B. 1967. A modification of Mallory's aniline blue collagen stain for oyster tissue. J. Invertebr. Pathol. 9: 268-269.

Pearse, A.G.E. 1960. Histochemistry. Theoretical and Applied. 2d ed. Little, Brown and Co., Boston, MA. 998 p.

Presnell, J.K. and M.P. Schreiber. 1997. Humason's Animal Tissue Techniques. 5th ed. Johns Hopkins Univ. Press, Baltimore, MD. 572 p.

Prophet, E.B., B. Mills, J.B. Arrington, and L.H. Sobin, Editors. 1992. Armed Forces Institute of Pathology - Laboratory Methods in Histotechnology. American Registry of Pathology, AFIP, Washington, DC. 279 p.

Sanders, B.J. 1972. Animal Histology Procedures of the Pathological Technology Section of the National Cancer Institute. DHEW Publ. No. 72-275, National Institutes of Health, Bethesda, MD. 185 p.

Thompson, S.W. 1966. Selected Histochemical and Histopathological Methods. Charles C. Thomas Publ., Springfield, IL. 1639 p.

Trump, B.F., E.A. Smucker, and E.P. Benditt. 1961. A method for staining epoxy sections for light microscopy. J. Ultrastruct. Res. 5: 343.

TABLE 8-4. Staining problems and resolutions.

Problem or artifact	Possible causes	Solution, if any
Tissues have greasy, oily appearance.	Tissues not completely dehydrated. Water not miscible with xylene; therefore, tissues will not accept xylene. Large amounts of water cause whitish scum on tissues.	Take tissues back to 100% ETOH (or dehydrant used in staining protocol) and rehydrate; use new reagents to clear before trying to coverslip.
Tissues appear dull and whitish after using nuclear fast red.	Excess nuclear fast red remains in tissue.	Rinse slides well in distilled water before dehydration.
Iron reaction does not work on control slide.	Solutions contaminated.	Avoid metal racks or forceps. Use acid-cleaned glassware.
Silver precipitates on slides.	Dirty slides or contaminated solutions.	Use acid-cleaned slides and glassware (critical) and change solutions frequently; avoid metal contamination.
Reactions faded on selected special stains.	Slides left in water for extended time.	Occasionally check and adjust pH of distilled and tap water to requirements of special stains.
Sections will not take stain, or stain irregularly.	Paraffin not completely removed before staining. Section not uniform in thickness. Tissue "old" (long storage in alcohol or, worse, in fixative). Fixative not suitable for staining technique. Fixative not fully removed.	Return sections through proper sequence of reagents; leave in xylene until paraffin is removed. Restain. Change xylene frequently. Return sections through proper sequence of reagents to water. Wash overnight and restain. Store tissues in paraffin blocks—never store in liquids for extended time. Mordant sections in recommended fixative.
Alcian blue not distinct.	Date of stain expired.	Check pH of stain and adjust if necessary. Use test slide before main staining run.
Schiff reagent nonspecific on tissues fixed in 1% glutaraldehyde/4% formaldehyde (1G4F).	If fixed with glutaraldehyde base, fixative was inadequately removed before processing tissue.	Wash tissues well to remove excess glutaraldehyde before processing. May try an aldehyde blocking agent.
	Schiff has become inactive or taken on too much moisture.	Make or purchase new reagent; color is often indicative of stain's potency. Best results are obtained with a peach-straw color. <i>Note:</i> A slight purple tint indicates stain to be ineffective. Always use test slide.

TABLE 8-4. Staining problems and resolutions (cont.).

Problem or artifact	Possible causes	Solution, if any
Hematein in Heidenhain's iron hematoxylin cloudy, not clear.	Contamination with the mordant.	Take care not to expose hematein directly to mordant. If using solution more than once, color change from brown to brown-black will indicate contamination.
Yellow, water-spotted appearance of stain on slide after using picromethyl blue.	Too much butanol carryover into xylene.	Change xylene frequently if staining a large number of slides.
Loss of picric acid in picromethyl blue.	Too much ETOH used in dehydration.	Use 1:9 ratio of 100% ETOH to butanol; tissues can be destained with acid alcohol and restained with picromethyl blue if color not green enough.
Protargol does not stain cilia and ciliate organelles. Protargol-stained tissues fall off slides.	The pH can affect slides. Make sure that slides are coated with collodion before staining.	Common complaint. Reproducible results are difficult to attain with protargol; however, most effective pH for strong silver solutions is 7.9-8.6. Many strong silver stains are not reliable. Protargol is recommended. Gold chloride must be clear of precipitate; filter if necessary.
Tissue falls off slide.	(1) Moisture left under tissue. (2) Tissue did not dry flat. (3) Swollen tissue; does not hold together well. (4) Tissues difficult to cut (hard, brittle); do not hold together well. (5) Effect of stain too harsh on tissue. (6) Alkaline reagents dissolve albumin adhesive; sections start to work loose in course of staining or dehydrating. (7) Using heat to speed reaction time is usually hard on tissue. (8) Slide dirty or greasy.	(1) Dry slides adequately before staining. (2) Spread tissue folds before drying tissue. (3) Coat suspected loose tissue slides with collodion after second 100% ETOH (except when using alcian blue). (4) For hard or brittle tissues, use extended staining time. (5) Use alternative stain. (6) Coat slides with poly-L-lysine; dry completely before staining. (7) Stain overnight in solution instead of 1 h at 60°C. (8) Clean slides before coating with adhesive.
Hematoxylin and eosin stain takes on a brown or yellow appearance.	Picric acid contamination in alcohol or xylene containers.	Hydrate tissues and restain. Refresh dehydrating and clearing agents.
Feulgen reaction overstains.	Tissue fixed in glutaraldehyde-based fixatives.	Wash tissues for extended period of time (at least 4-6 h) before embedding and use aldehyde blocker before staining.

Figure 8-1. Alcian Blue (AB).

Specific for acid mucopolysaccharides.

Tissue: Acid mucopolysaccharides in epidermis of blue crab *Callinectes sapidus* fixed in Bouin's.

Results:

- Acid mucopolysaccharides - brilliant blue
- Nuclei - bright red or shades of blue
- Background - pink to red
- Other basophilic substances - various shades of blue or purple
- Other cytoplasmic elements - shades of pink

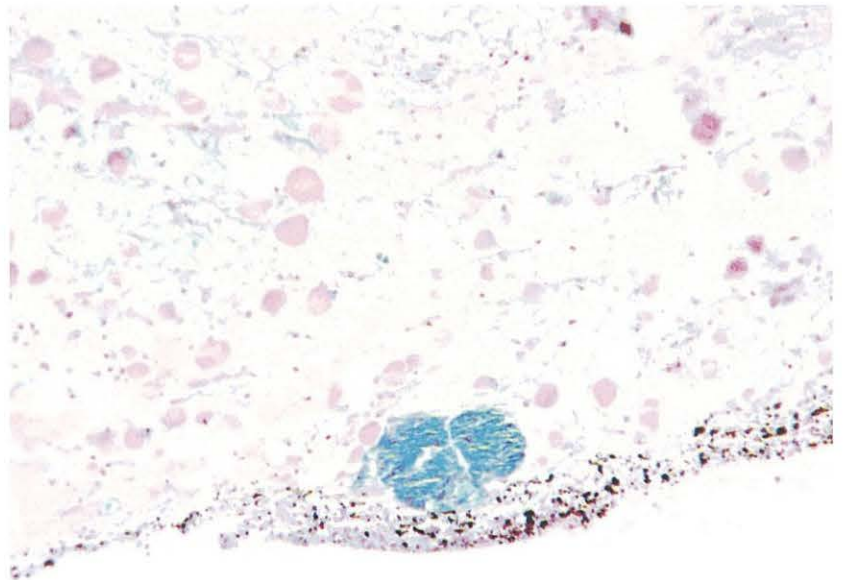


Figure 8-2. Alizarin Red S (ARS).

Specific for calcium and chitin.

Tissue: Chitin from mud crab fixed in Davidson's.

Results:

- Calcium salts and chitin - intense reddish-orange

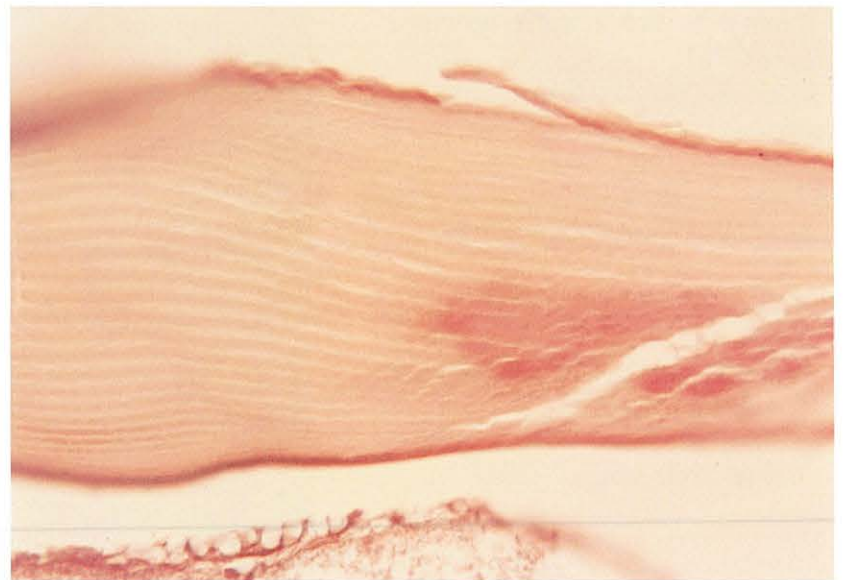


Figure 8-3. Alizarin Red S (ARS).

Specific for calcium and chitin.

Tissue: Partially decalcified shell from soft clam *Mya arenaria* fixed in Davidson's and embedded in glycol methacrylate.

Results:

- Calcium salts - intense reddish-orange
- Background - pale green (when counterstained with light green SF yellowish)

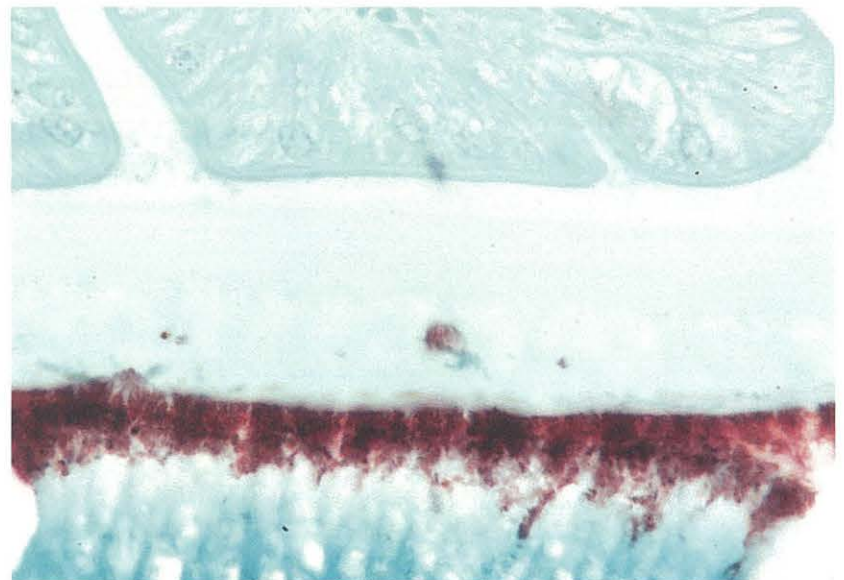


Figure 8-4. Azure-eosin/Giemsa₁ (AZE₁).

Specific for blood smears fixed in methanol.

Tissue: Fish blood smear (erythrocytes and leukocytes) fixed in methanol.

Results:

- Nuclei and basophilic substances - blue
- Cytoplasm and acidophilic substances - pink

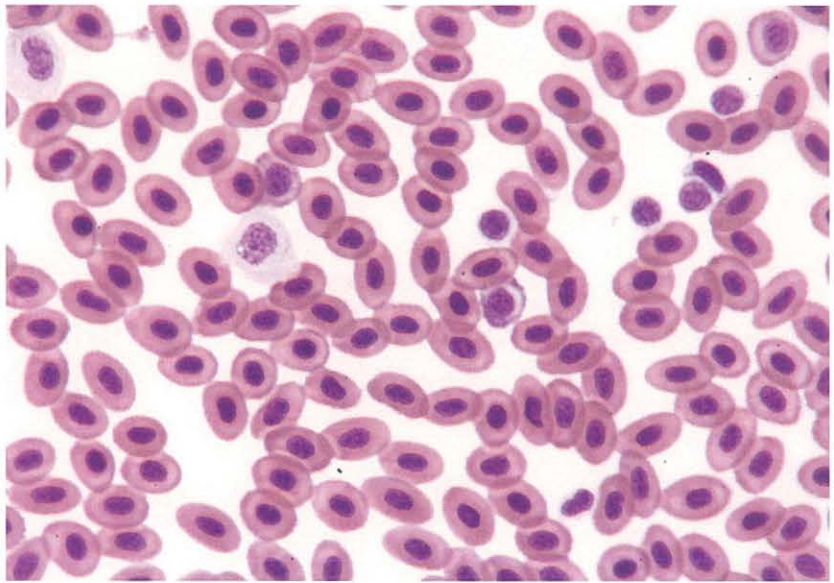


Figure 8-5. Feulgen Picromethyl Blue (FPM).

Specific for DNA, collagen, and connective tissue.

Tissue: Connective tissue of oyster *Crassostrea virginica* fixed in 1G4F.

Results:

- DNA - red
- Nucleoli, muscle, and other acidophilic substances - yellow
- Connective tissue, collagen - blue
- Cytoplasmic protein - green

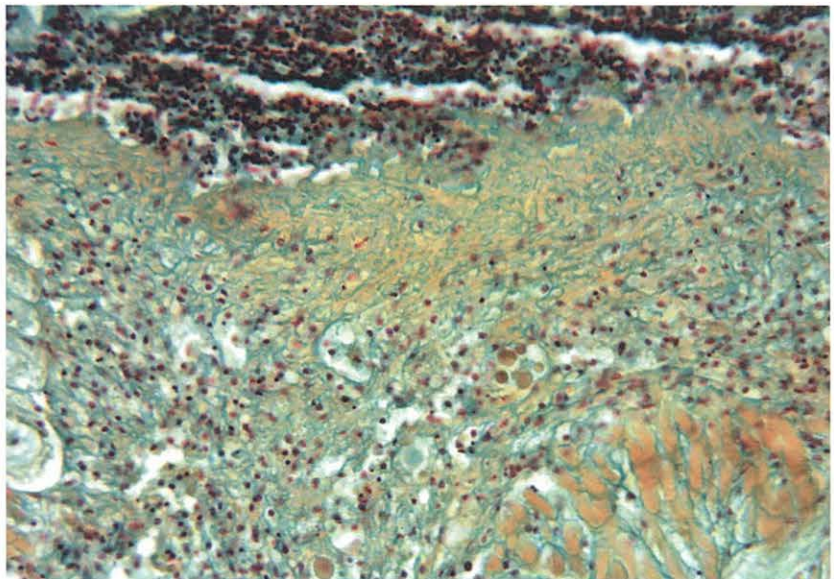


Figure 8-6. Feulgen Picromethyl Blue (FPM).

Specific for DNA, collagen, and connective tissue.

Tissue: Gill of oyster *Crassostrea virginica* fixed in 1G4F.

Results:

- DNA - red
- Nucleoli, muscle, and other acidophilic substances - yellow
- Connective tissue, collagen - blue
- Cytoplasmic protein - green

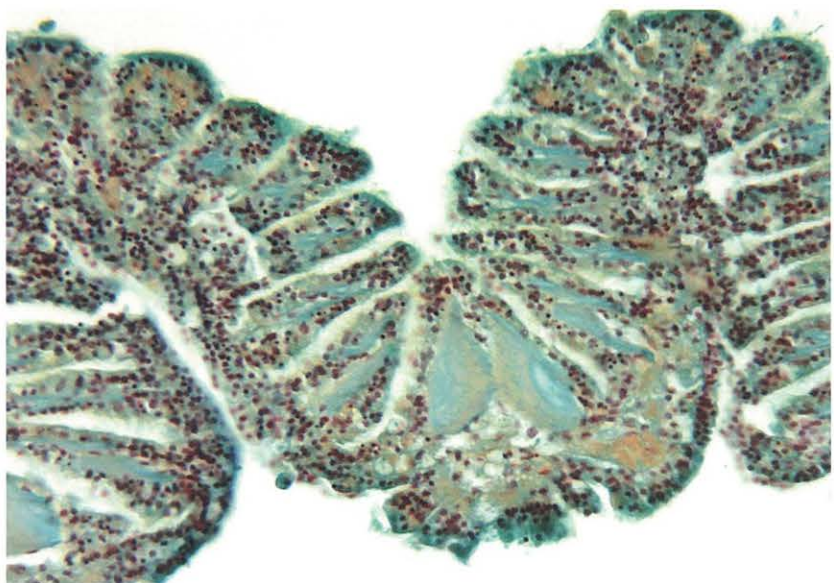


Figure 8-1. Alcian Blue (AB).

Specific for acid mucopolysaccharides.

Tissue: Acid mucopolysaccharides in epidermis of blue crab *Callinectes sapidus* fixed in Bouin's.

Results:

- Acid mucopolysaccharides - brilliant blue
- Nuclei - bright red or shades of blue
- Background - pink to red
- Other basophilic substances - various shades of blue or purple
- Other cytoplasmic elements - shades of pink

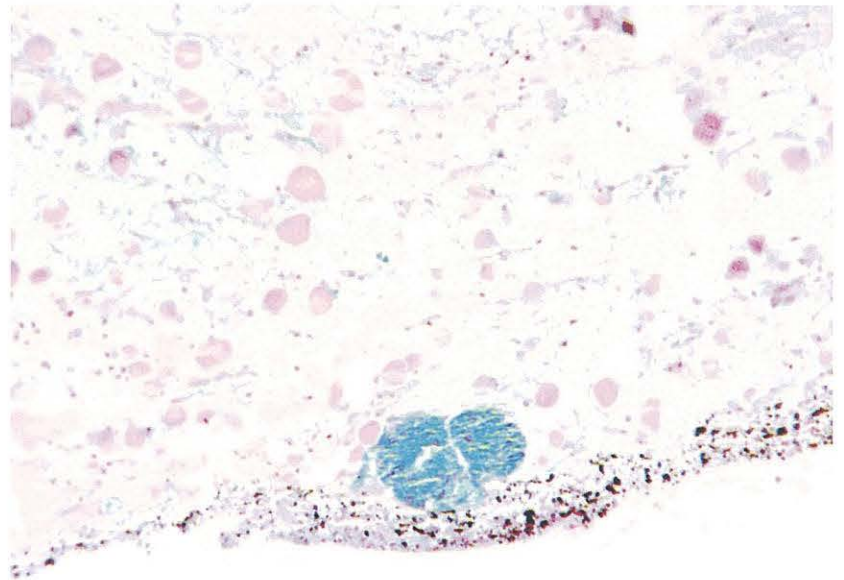


Figure 8-2. Alizarin Red S (ARS).

Specific for calcium and chitin.

Tissue: Chitin from mud crab fixed in Davidson's.

Results:

- Calcium salts and chitin - intense reddish-orange

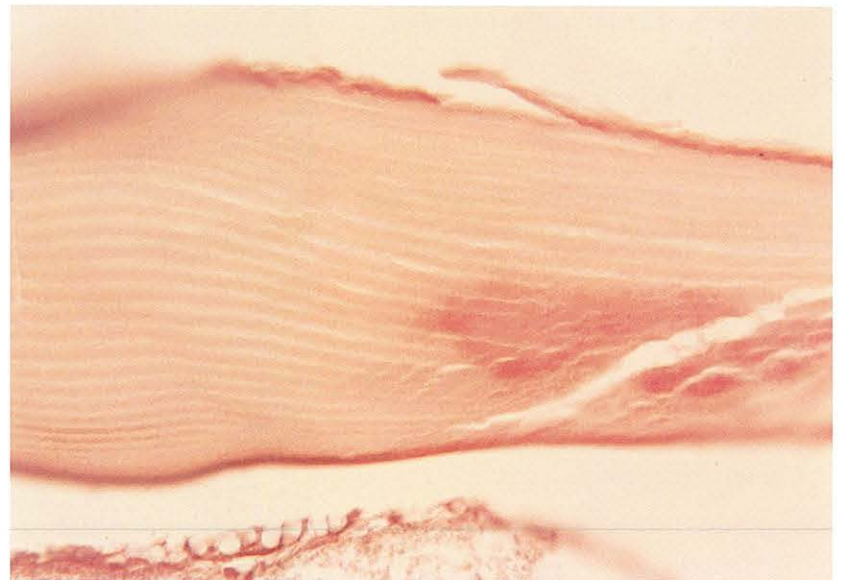


Figure 8-3. Alizarin Red S (ARS).

Specific for calcium and chitin.

Tissue: Partially decalcified shell from soft clam *Mya arenaria* fixed in Davidson's and embedded in glycol methacrylate.

Results:

- Calcium salts - intense reddish-orange
- Background - pale green (when counterstained with light green SF yellowish)

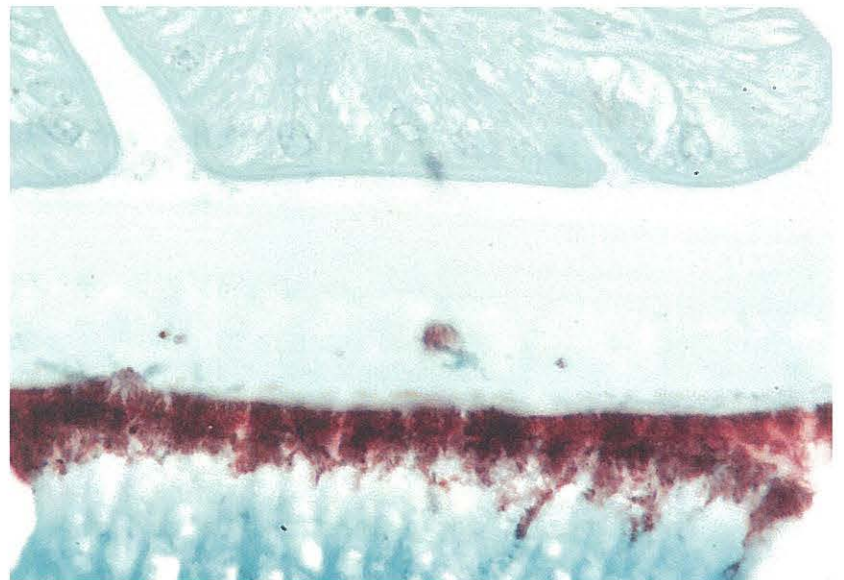


Figure 8-4. Azure-eosin/Giemsa₁ (AZE₁).

Specific for blood smears fixed in methanol.

Tissue: Fish blood smear (erythrocytes and leukocytes) fixed in methanol.

Results:

- Nuclei and basophilic substances - blue
- Cytoplasm and acidophilic substances - pink

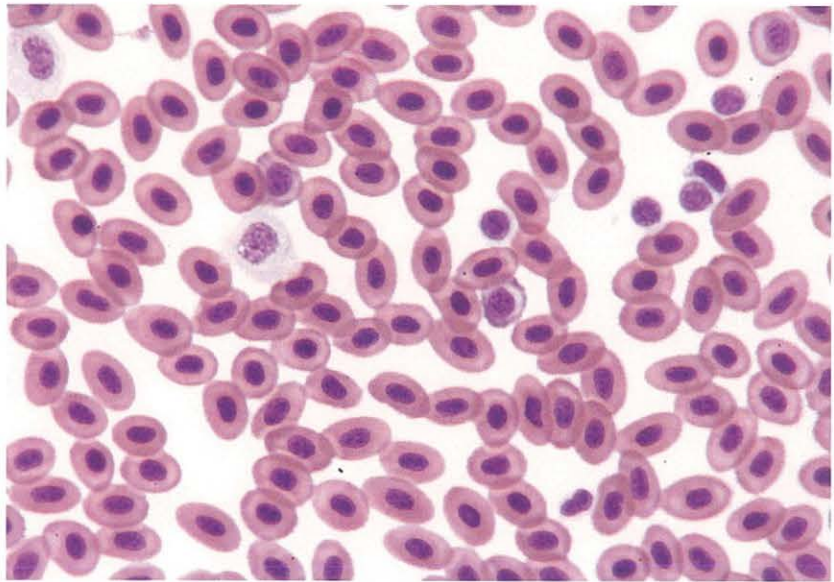


Figure 8-5. Feulgen Picromethyl Blue (FPM).

Specific for DNA, collagen, and connective tissue.

Tissue: Connective tissue of oyster *Crassostrea virginica* fixed in 1G4F.

Results:

- DNA - red
- Nucleoli, muscle, and other acidophilic substances - yellow
- Connective tissue, collagen - blue
- Cytoplasmic protein - green

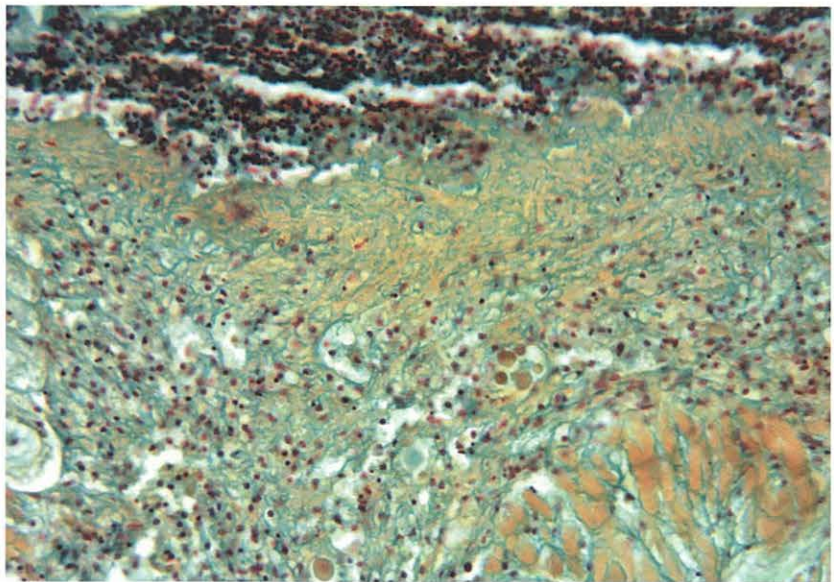


Figure 8-6. Feulgen Picromethyl Blue (FPM).

Specific for DNA, collagen, and connective tissue.

Tissue: Gill of oyster *Crassostrea virginica* fixed in 1G4F.

Results:

- DNA - red
- Nucleoli, muscle, and other acidophilic substances - yellow
- Connective tissue, collagen - blue
- Cytoplasmic protein - green

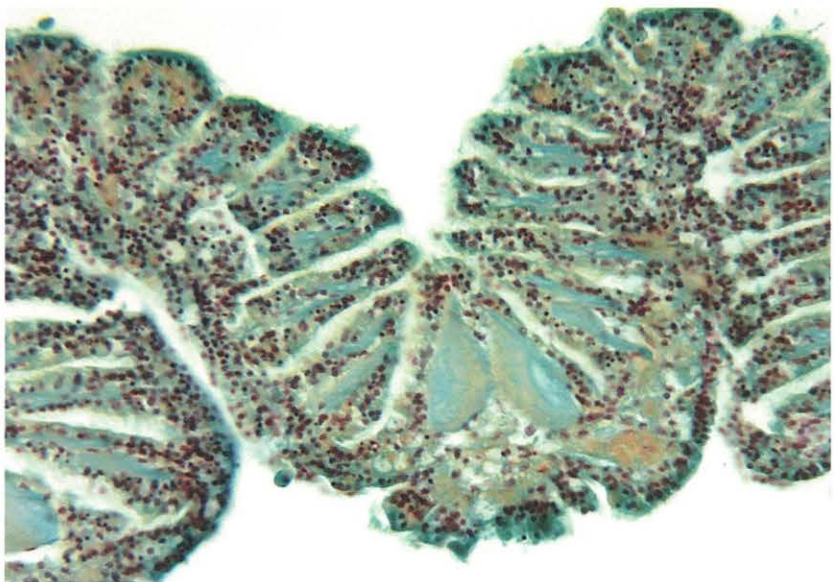


Figure 8-7. Gomori's.

Specific for connective tissue, reticulum.

Tissue: Tubules and ducts of digestive gland of oyster *Crassostrea virginica* fixed in Davidson's.

Results:

- Reticulum fibers - black
- Collagen - rose
- Other tissue elements - pink to red

(Slide courtesy of Sue Tyler, Maryland Dept. Natural Resources, Oxford, MD.)

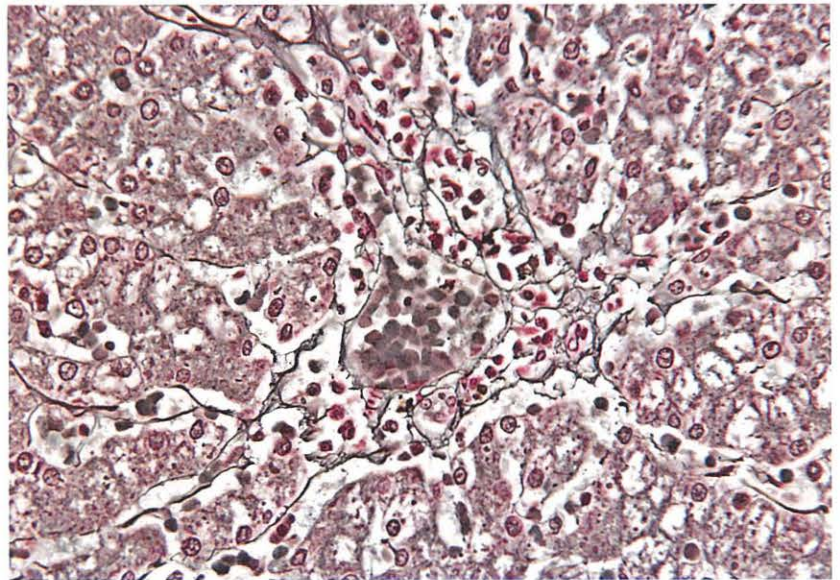


Figure 8-8. Gram (Brown and Brenn 1931).

Specific for gram-positive and gram-negative bacteria.

Tissue: Crab hepatopancreas injected with *Aerococcus viridans* (gaffkemia)

Results:

- Gram-positive - blue
- Gram-negative - red
- Nuclei - red
- Background - yellow to green (depending on counterstain)

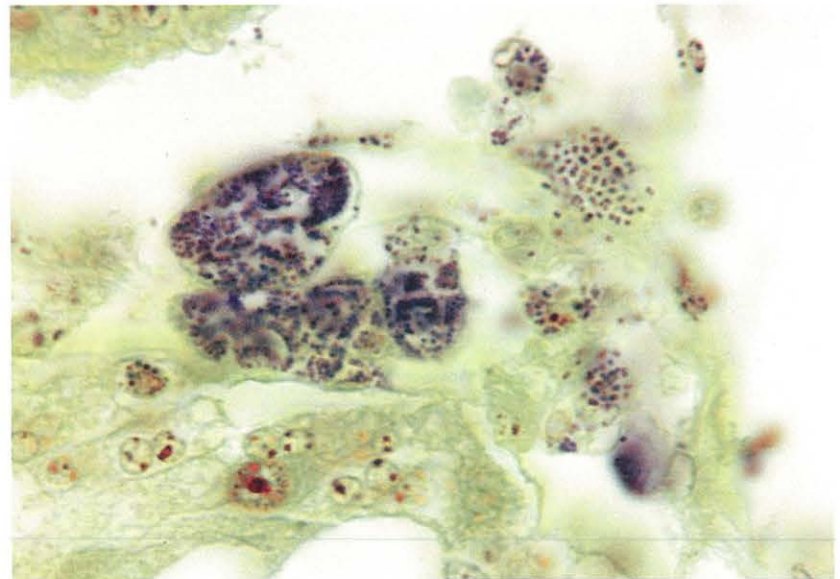


Figure 8-9. Gram (Brown and Hopps 1973).

Specific for gram-positive and gram-negative bacteria.

Tissue: Rickettsia-like organisms (RLOs) in GI tract of oyster *Crassostrea virginica* fixed in Davidson's.

Results:

- Gram positive - blue
- Gram negative - red to purple
- Background - yellow to green (depending on counterstain)

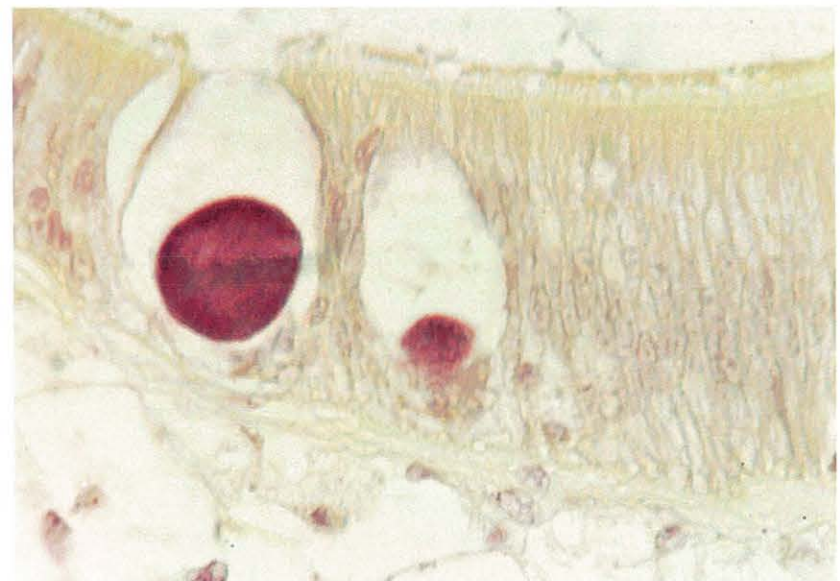

Figure 8-10. Grocott's Methenamine Silver (GMS).

Specific for fungi.

Tissue: Fungi in muscle of fish fixed in 10% neutral buffered formalin.

Results:

- Fungi - sharply delineated in black
- Mucin - taupe to dark gray
- Inner parts of mycelia and hyphae - grayish rose
- Background - pale green

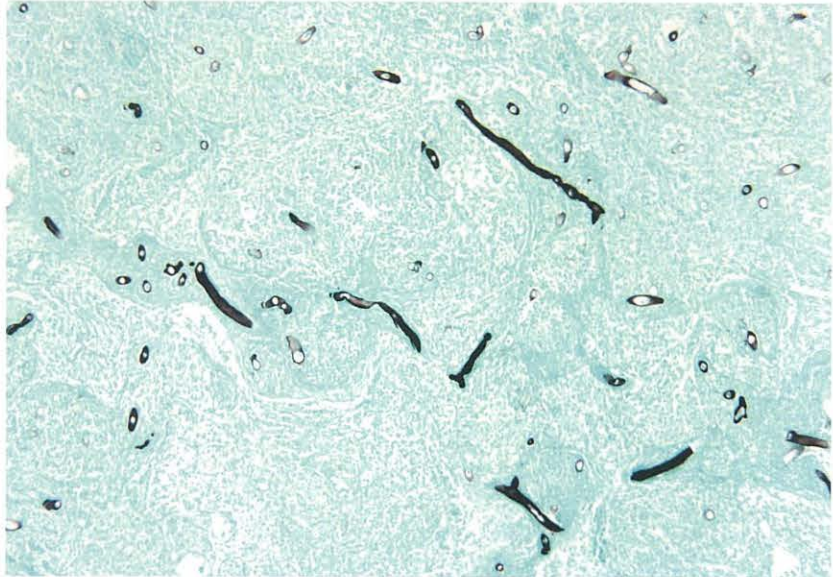


Figure 8-11. Mallory's Hematein.

Specific for copper and other metals.

Tissue: Digestive diverticula of oyster *Crassostrea virginica* fixed in Davidson's.

Results:

- Heavy metals, e.g., copper - blue-black
- Background - bright red

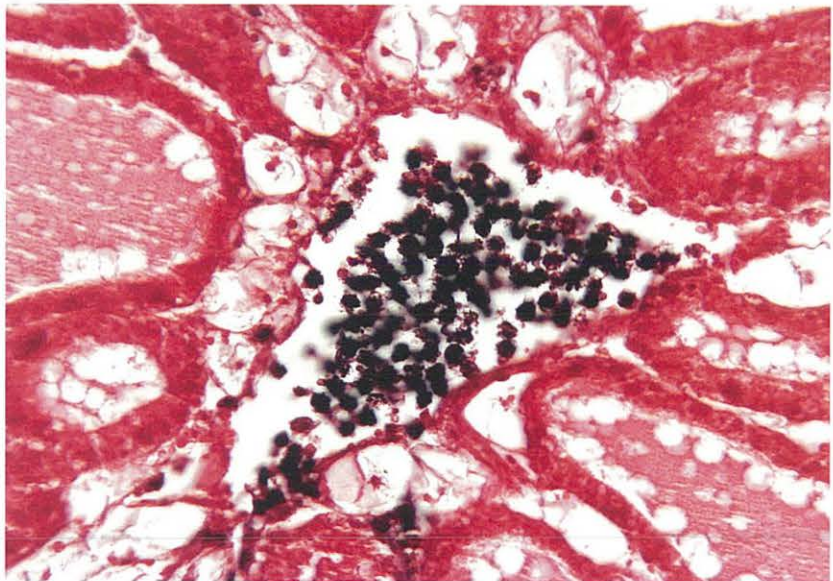


Figure 8-12. Mallory's Trichrome.

Specific for collagen and connective tissue.

Tissue: Mantle of oyster *Crassostrea virginica* fixed in Davidson's.

Results:

- Collagen fibers - intense blue (also reticulum - pale blue)
- Elastic fibers - pale pink, pale yellow, or unstained
- Muscle - red, purple, or blue (depending on specimen)
- Erythrocytes and myelin - yellow
- Nuclei - red

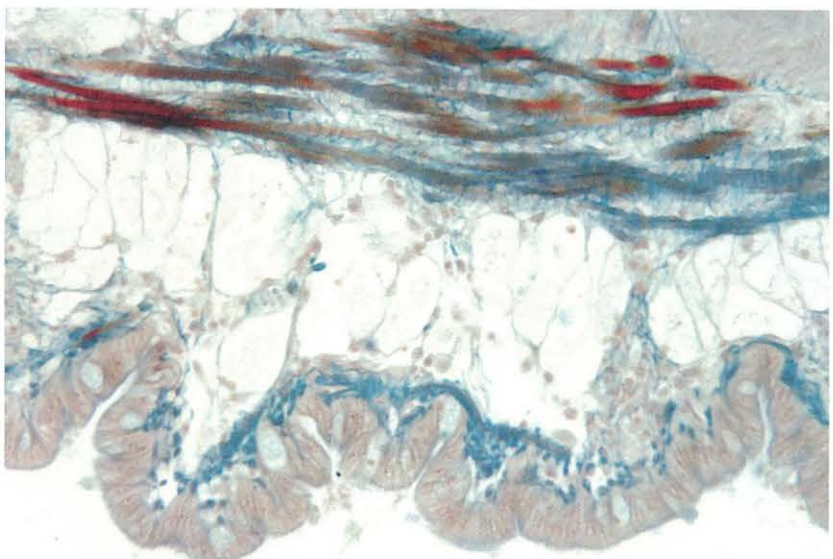


Figure 8-13. Malt Periodic Acid Schiff (MPAS).

Specific for digestion of glycogen, neutral mucopolysaccharides, and PAS-positive substances other than glycogen.

Tissue: Gut of blue crab *Callinectes sapidus* fixed in Bouin's.

Results:

- Glycogen - digested
- Neutral mucopolysaccharides - magenta
- Other PAS-positive substances - pink to magenta
- Nuclei and other basophilic substances - blue

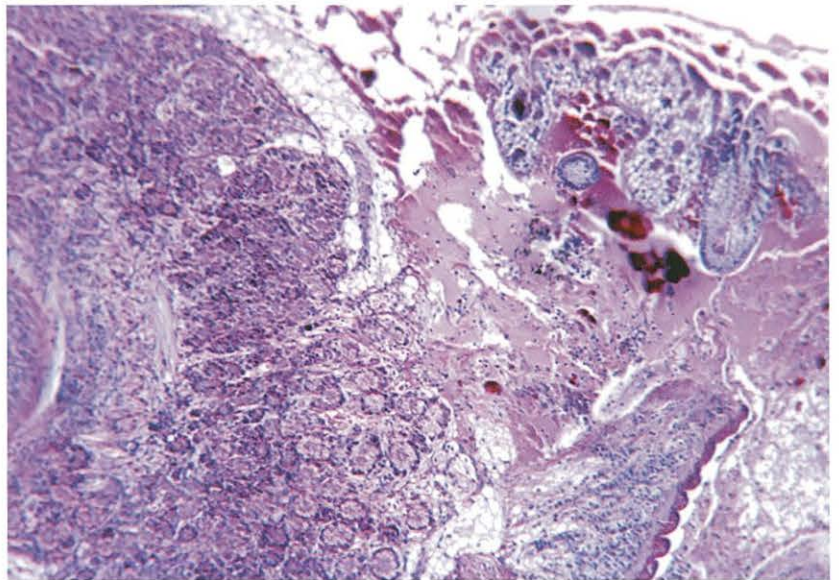


Figure 8-14. Malt Periodic Acid Schiff-Alcian Blue (MPAS-AB).

Specific for differentiation of acid and neutral mucopolysaccharides.

Tissue: Gut of blue crab *Callinectes sapidus* fixed in Bouin's.

Results:

- Acid mucopolysaccharides - bright intense blue
- Neutral mucopolysaccharides - magenta
- PAS-positive tissue - pink to magenta
- Nuclei - blue
- Glycogen - digested

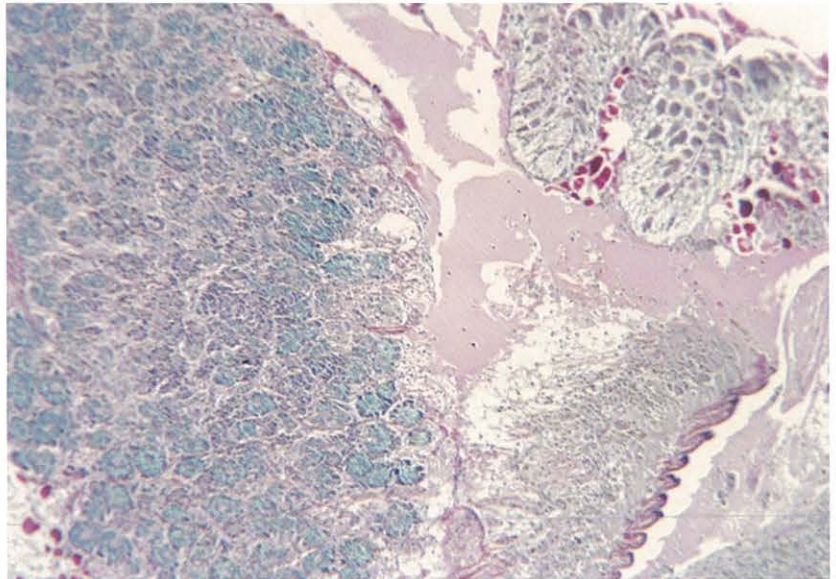


Figure 8-15. Mayer's Hematoxylin and Eosin (MHE).

General stain for formalin-fixed tissues.

Tissue: Gonad and digestive diverticula of oyster *Crassostrea virginica* fixed in 1G4F.

Results:

- Basophilic substances - blue
- Acidophilic substances - pink

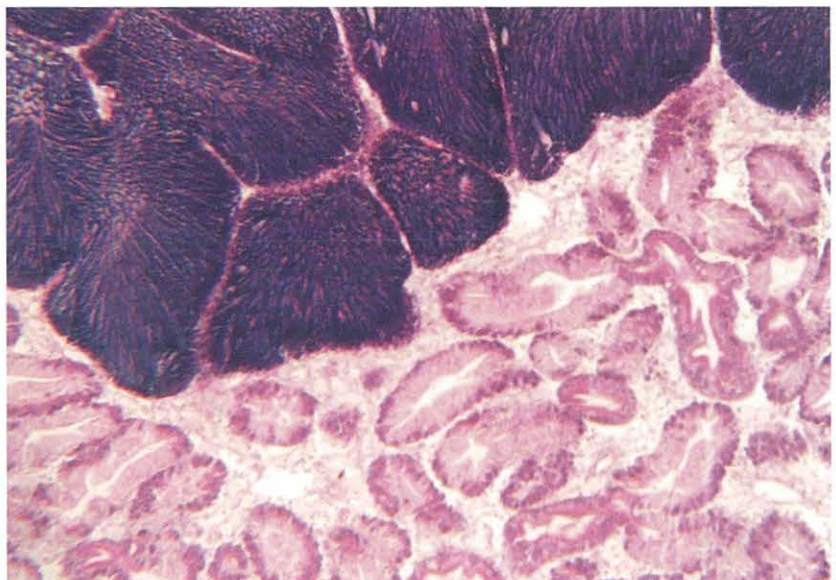


Figure 8-16. Oil Red O (ORO).

Specific for fat in frozen tissue.

Tissue: Frozen tissue of soft clam *Mya arenaria* fixed in methanol.

Results:

- Fat - bright orange to red
- Nuclei - blue

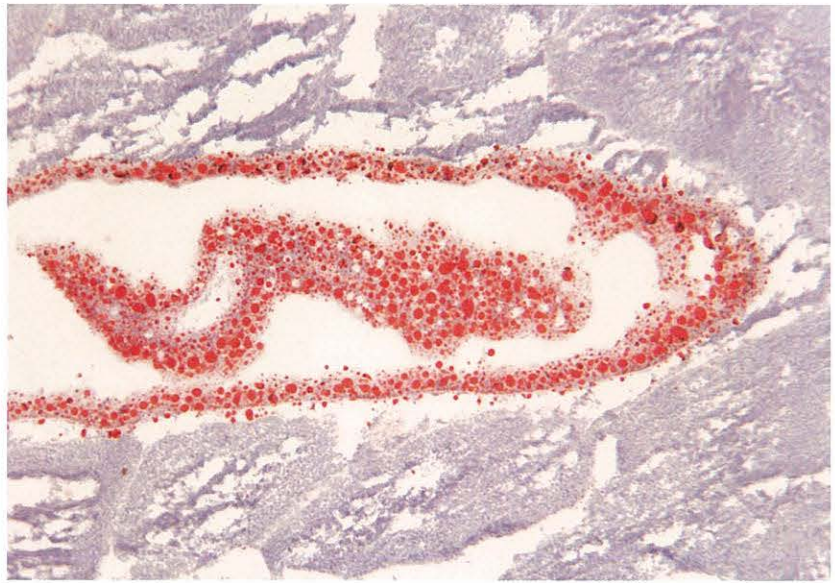

Figure 8-17. Periodic Acid Schiff (PAS₁) with Weigert's Hematoxylin.

Specific for neutral mucopolysaccharides, glycogen, and fungi.

Tissue: Gut of blue crab *Callinectes sapidus* fixed in Bouin's.

Results:

- Neutral mucopolysaccharides - magenta
- Fungi walls - magenta
- Glycogen - magenta
- PAS-positive substances - pink to magenta
- Nuclei and other basophilic substances - blue-black

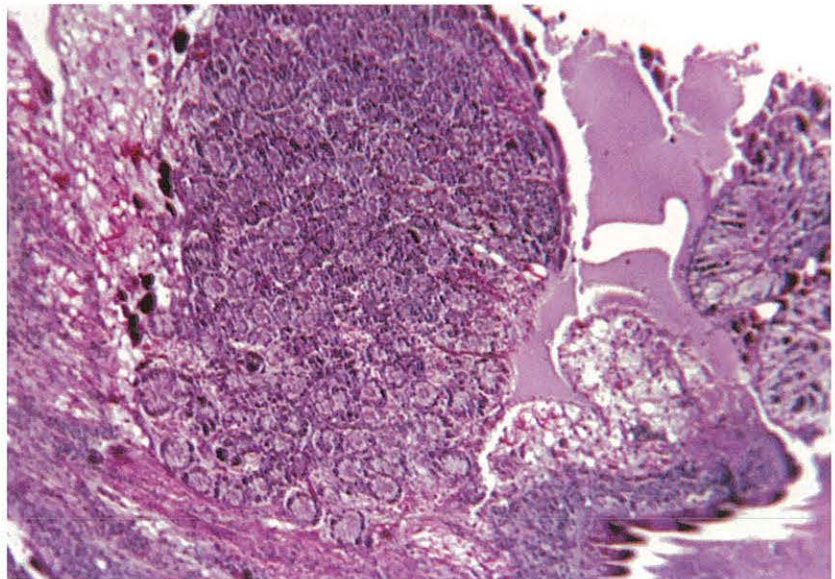


Figure 8-18. Perls' Prussian Blue.

Specific for ferric iron.

Tissue: Fish spleen fixed in 10% neutral buffered formalin.

Results:

- Ferric iron - deep blue to green
- Nuclei - red
- Background - pink

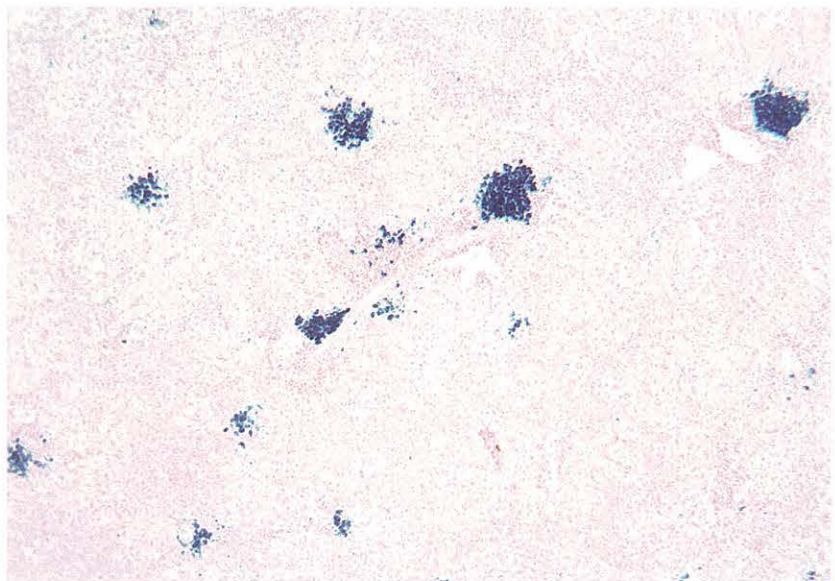


Figure 8-19. Protargol.

Specific for cilia and ciliate organelles.

Tissue: Sections of ciliate xenoma from gill of oyster *Crassostrea virginica* fixed in 1G4F and postfixed in Bouin's.

Results:

- Kinetids - black
- Nuclei - black
- Cilia - may stain black
- Cytoplasm - clear to lavender

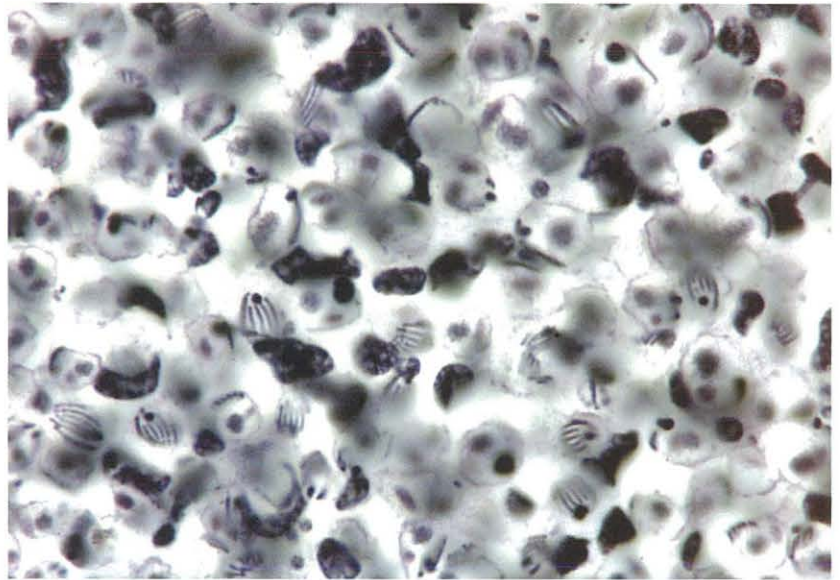


Figure 8-20a, b. Protargol.

Specific for cilia and ciliate organelles.

Tissue: Live ciliates fixed in 1G4F and postfixed in Bouin's.

Results:

- Kinetids - black
- Nuclei - black
- Cilia - may stain black
- Cytoplasm - clear to lavender

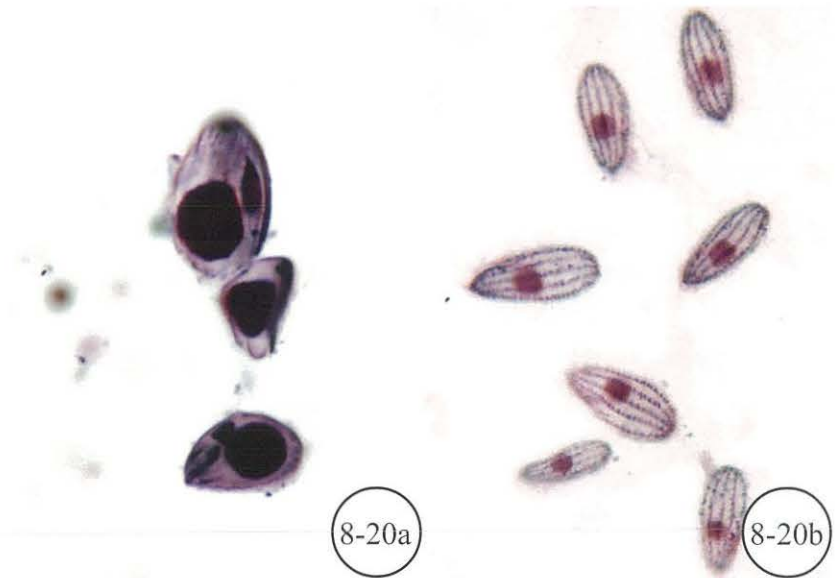


Figure 8-21. Toluidine Blue O₂ (TBO₂).

General metachromatic stain for frozen tissues.

Tissue: Cross-section of frozen menhaden.

Results:

- Nuclei - dark blue
- Cytoplasm - pink to blue

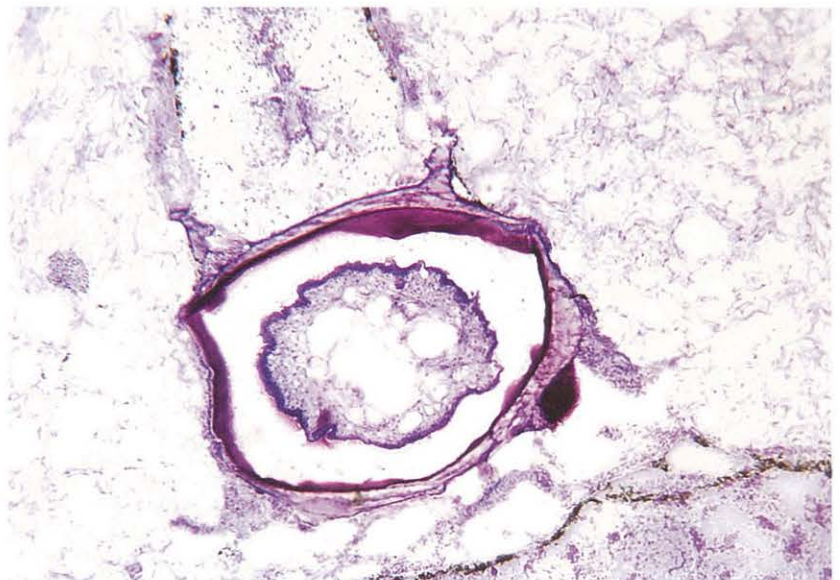


Figure 8-22. Von Kossa.

Specific for calcium.

Tissue: Decalcified shell of soft clam *Mya arenaria* fixed in Davidson's and embedded in glycol methacrylate.

Results:

- Calcium salts - black
- Nuclei - red
- Cytoplasm - pink to rose

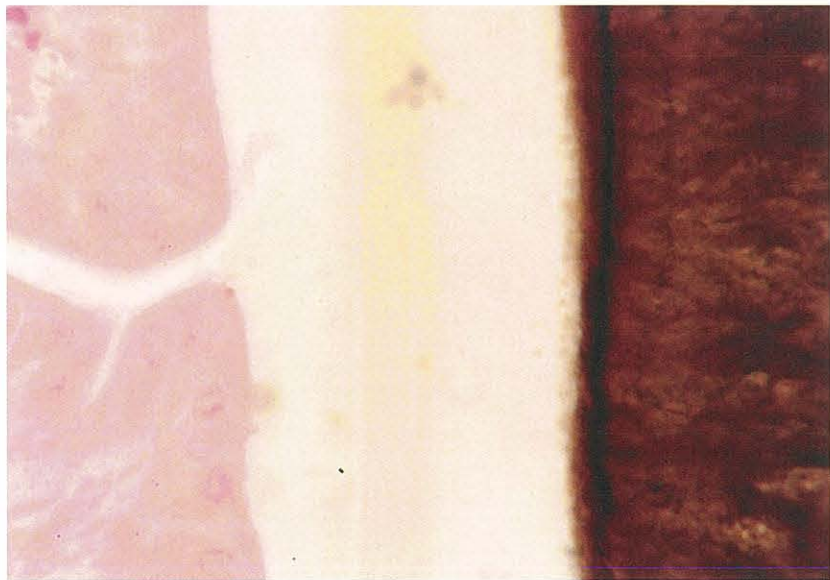


Figure 8-23. Ziehl-Neelsen and Harris' Hematoxylin (ZHH).

Specific for acid-fast substances (e.g., haplosporidan spores, microsporida, and *Cryptosporidium* oocysts).

Tissue: Seaside organism (SSO) spores in connective tissue of oyster *Crassostrea virginica* fixed in Davidson's.

Results:

- Basophilic substances - blue
- Acid-fast substances, including mature haplosporidan sporoplasms, lipofuscins, acid-fast bacteria, and *Cryptosporidium* oocysts - bright red

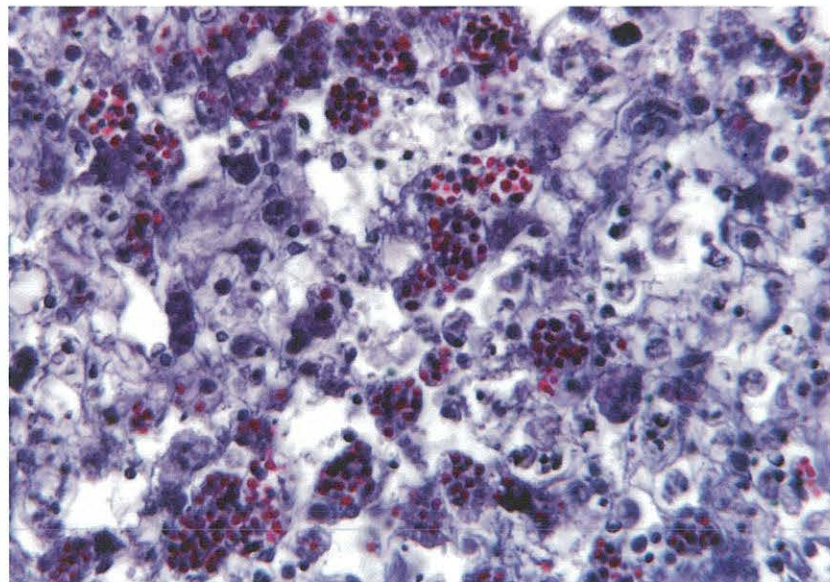


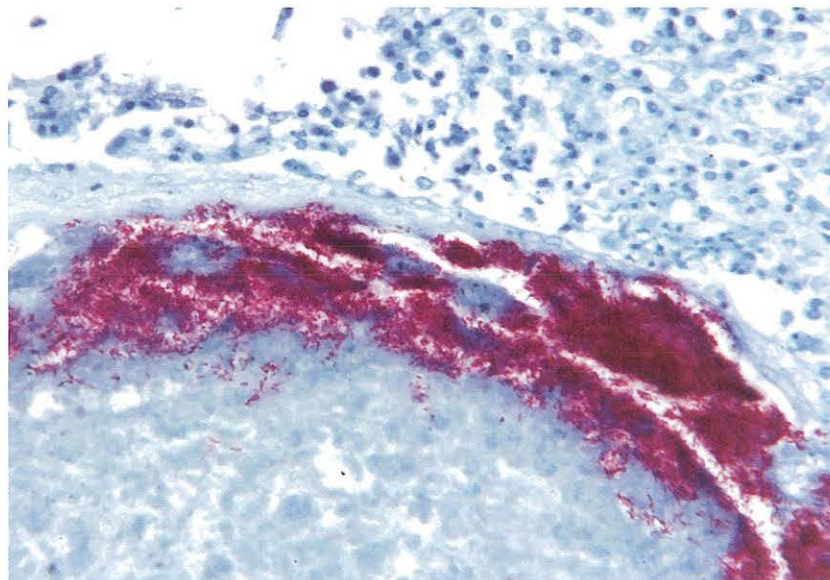
Figure 8-24. Ziehl-Neelsen and Methylene Blue.

Specific for acid-fast organisms and acid-fast bacteria (AFB).

Tissue: AFB in muscle of striped bass *Morone saxatilis*. (Specimen courtesy of John Jacobs, NOAA, Oxford, MD.)

Results:

- Background - pale blue
- Acid-fast substances, including mature haplosporidan sporoplasms, lipofuscins, and acid-fast bacteria - bright red



CHAPTER 9. COVERSLIPPING

A. Introduction

Individual techniques of coverslipping tissues may vary from technician to technician. Exactly how to hold the slide or coverslip will vary with one's dexterity and comfort. However, the basic procedure is simple. Once tissues have been stained, dehydrated, and placed in xylene, they are ready to be coverslipped for permanence. Coverslip and clean all slides under a fume hood.

B. Tools and Techniques

Materials needed are: (1) fume hood, (2) good light, (3) coverslip, (4) probe (straight), (5) paper towels, (6) large Kimwipes (available from Fisher Scientific^a cat. # 06-666C), and (7) mounting medium.

Begin by removing slides singly in numerical order. The frosted, coded side of the slide should face up. With a lint-free tissue (Kimwipes^a), remove excess xylene from front and back of slide (Fig. 9-1), and place one drop of mounting fluid on the tissue on slide (Fig. 9-2). Choose the proper size coverslip, place edge of coverslip at an angle to the bottom edge of slide, and gradually lower onto the slide so that the mounting fluid flows evenly from bottom to top (Fig. 9-3). Do not drop the coverslip onto the slide because this will usually trap air bubbles under the coverslip. Work swiftly; tissues that dry out will take on a dark burnt appearance.

Once the coverslip is attached, blot edges of slide on a paper towel and examine for occasional air bubbles. If present, gently lead bubble to the edge, out from under coverslip, using a probe (Fig. 9-4). This procedure should be done quickly, precisely, and with care to prevent damage to the tissue. Place the slide on a flat tray (Fig. 9-5) with a temporary label showing code, stain, and date of coverslipping. Slides are then placed in a drying oven set at 38-42°C for 2-5 days to allow mounting medium to harden (Fig. 9-6).

After mounting medium hardens, slide can be cleaned, labeled, and filed for examination. Using a single-edged razor blade, gently but firmly remove all excess mounting medium from around the coverslip (careful not to nick coverslip with razor blade). Brush off loosened mounting medium and, in fume hood, dip slide in xylene and gently wipe clean. When all slides have been cleaned, they should be arranged in the correct series and numerical order.

Label slides on etched/frosted end with pertinent codes, including stain and date fixed, with a fine tip water- and solvent-resistant pen or permanent marker.

C. Problems and Resolutions

Table 9-1 includes some problems or artifacts resulting from coverslipping, as well as some means of resolving them.

- Coverslips range in size, shape, and thickness. For general purpose, use 24 x 40 mm or 24 x 50 mm at a #1 thickness. Whole mounts should use a #2 thickness.
- Once opened, keep the coverslips out of high humidity areas since they will stick together and the moisture will interfere with the xylene during mounting.

D. Mounting Media

1. Resins

a. Canada Balsam

Canada balsam is a natural resin. It preserves stain color but takes longer to dry and has a very strong odor. This mountant is recommended for some stains, such as Perls' Prussian blue or basic aniline dyes, because they tend to fade quickly.

b. Synthetic Resins

These resins are routinely used for most stains. Although a variety is available, Permount (available from Fisher Scientific^a cat. # SP15-100) is recommended. Synthetic resins are easier to work with, since they dry more quickly and require less thinning.

2. Aqueous Media

Glycerin jelly or Advantage aqueous mounting media may be used to directly mount tissues from aqueous stains. However, these preparations are not permanent and will dry out. To preserve stained sections, seal edges of coverslip with clear fingernail polish once slides have dried.

a. Glycerin Jelly

Procedure:

- 1) In fume hood, warm glycerin jelly¹ before using (**do not overheat**)
- 2) Place 1 drop on tissue
- 3) Gently lower coverslip in place
- 4) Drain excess
- 5) Slide any trapped air bubbles to edge of coverslip
- 6) When glycerin jelly is dry, remove excess with razor blade and paint edge with clear fingernail polish to complete coverslip seal
- 7) Read slides as soon as possible

Note: Glycerin jelly may cause stain to fade.

Reagent:

¹Glycerin Jelly

Gelatin 10.0 gm
Distilled water 60.0 ml

Heat until gelatin is dissolved, then add:

Glycerin 70.0 ml
Phenol (liquefied) 1.0 ml

Note: Glycerin jelly mounting media is available ready-made. Store glycerin jelly in refrigerator and warm before use. Phenol is recommended by Prophet et al. (1992) to inhibit growth of molds.

b. Advantage

Procedure:

- 1) Apply 2-3 drops of Advantage over tissue
- 2) Coverslip
- 3) Quick set at 37°C - 15 min, or at room temp. - 30-45 min

Note: Advantage available ready-made from Innovex Biosciences^b cat. # NB 300. When used for immunostaining, store slides in a dark and dust-free environment until examination. To remove coverslip, soak in distilled water.

E. Footnotes

^aFisher Scientific, 3970 Johns Creek Court, Suwanee, GA 30024. (800) 766-7000. www.fishersci.com

^bInnovex Biosciences, 4505 MacDonald Ave., Richmond, CA 94805. (800) 622-7808. www.innvx.com

F. References

Luna, L.G., Editor. 1968. *Manual of Histologic Staining Methods of the Armed Forces Institute of Pathology*. 3d ed. McGraw-Hill, New York. 258 p.




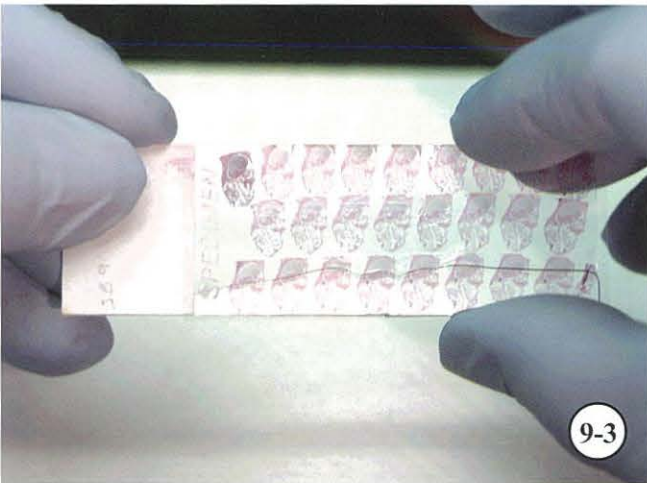
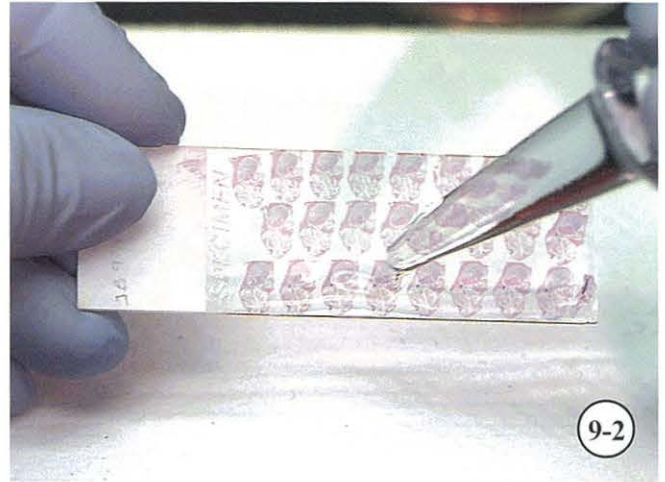
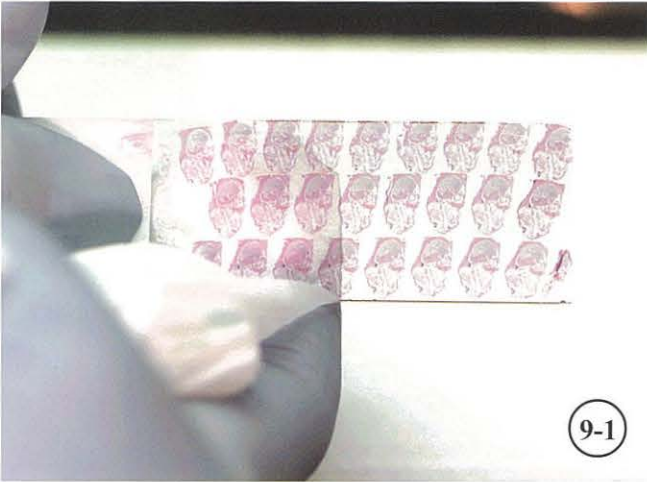
Prophet, E.B., B. Mills, J.B. Arrington, and L.H. Sobin, Editors. 1992. *Armed Forces Institute of Pathology - Laboratory Methods in Histotechnology*. American Registry of Pathology, AFIP, Washington, DC. 279 p.

TABLE 9-1. Coverslipping problems and resolutions.

Problem or artifact	Possible causes	Solution, if any
Mounting medium will not flow across tissue.	Slide has dried out. Mounting medium too thick; part of solvent may have evaporated.	Redip slide into xylene and start process again. Carefully thin medium with solvent or use new mounting medium.
Coverslip tends to slip out of place.	Slide too wet with xylene. Mounting medium too thin. Too much mounting medium.	Wipe excess xylene from around tissue and from back of slide before adding 1 drop of fresh mounting medium (should be free flowing). Blot edge of slide once coverslip is in place.
Air bubbles will not release from under slide.	Sand in tissues. Grit or loose debris under slide. Coverglasses may be old, warped, or dirty.	Remove coverslip by soaking in xylene and start process again. If trouble spot can be identified, remove it. However, if it lies within tissue, try mounting with thicker mounting medium. Re-coverslip with new coverglass.
Black, charred-looking, or parched tissue.	Tissue dried out before or during coverslipping, or large air pockets formed from warped coverslips.	Cover tissue with xylene before coverslipping; do not allow tissue to dry out after deparaffinizing (Luna 1968).
Sections appear opaque or have highly refractive lines outlining cells and tissues.	Clearing agent evaporated before mounting medium added. Sections insufficiently cleared. Clearing agent not miscible with mounting medium. More than one coverslip used.	Soak to remove coverglass. Clear properly. Ensure quality and compatibility of clearing agents and mounting medium (Luna 1968).
Cloudy slide.	Mounting medium too thick or too much applied to slide.	Mounting medium should be free flowing; use only amount necessary (1 drop) and blot edge of slide after coverslipping to remove excess.
Slide oily or cloudy.	Clearing agents contaminated by water.	Take slide back to 100% ETOH and repeat clearing steps with fresh xylene.

TABLE 9-1. Coverslipping problems and resolutions (cont.).

Problem or artifact	Possible causes	Solution, if any
Black air rings in tissue.	Air trapped during coverslipping.	Using probe, gently press coverslip to guide bubbles to outer edges (Luna 1968).
Tissues dislodged from place, layered, or unrecognizable.	Too much pressure on probe to remove air bubbles.	Do not force out large or multiple air bubbles. Instead, re-coverslip to avoid damaging tissue.
White precipitate forms on slides after using nuclear fast red (Kernechtrot).	Slides not rinsed well enough in distilled water before final dehydration.	Rinse well, at least 6 complete dips in distilled water.



Coverslipping.

Figure 9-1. Wipe excess xylene from back of slide. **Figure 9-2.** Place 1 drop of mounting medium over tissue section near bottom of slide. **Figure 9-3.** Place edge of coverslip at an angle to bottom edge of slide and lower coverglass over tissue. **Figure 9-4.** Blot bottom edge of slide on absorbent paper to drain excess mounting medium. Remove any air bubbles by tilting slide and, with probe, applying gentle pressure to coverglass. **Figure 9-5.** Place finished slide with temporary label on trays to dry. **Figure 9-6.** Place trays of freshly prepared slides on flat surface, preferably in drying oven at 38-42°C. Allow mounting medium to dry for 2-5 days before cleaning slides.

CHAPTER 10. HISTOCYTOLOGY: A DIAGNOSTIC METHOD FOR EXAMINING INVERTEBRATE HEMOLYMPH

C. Austin Farley

A. Introduction

The standard method of diagnosis for disease in invertebrate animals traditionally has been by histology and certainly will continue to be in the future, at least for comprehensive disease evaluations and tissue lesions that cannot be diagnosed any other way. Disadvantages of this method are that it is time-consuming, it requires special equipment not always readily available, and it is costly. Another clear drawback is that sacrificing specimens to produce histologic sections preclude the ability to do clinical studies on individual animals.

The methods to be described were developed and modified over a period of about 15 years as an alternative experimental approach to histology, using a variety of invertebrate animals that were available at the Woods Hole Marine Biological Laboratory in the course on *Comparative Pathology of Marine Invertebrate Animals* taught by F.B. Bang, B. Bang, and C.L. Reinisch from 1978 through 1983 (Farley et al. 1986, 1991a, b, Farley 1989, Farley and Plutchak 1991, Farley and Straight 1991). Successful preparations were produced from mollusks, crustaceans, sipunculids, and echinoderms. These methods depend upon being able to obtain cell suspensions (hemolymph) from the animal of interest, and have proven to be successful for the identification of parasites and pathogens carried by the hemolymph system of shellfish (Farley et al. 1991a, b). Suspensions are collected and a monolayer of cells is allowed to settle and attach to the surface of a microscope slide. The slide is then wet-fixed, stained by histologic methods, and mounted with synthetic mounting medium and a coverslip. The following protocol covers bivalve mollusks such as clams, mussels, and oysters, as well as crustaceans.

B. Preparation of Materials

Super frosted slides are recommended and should be cleaned with acid alcohol (see p. 76). If diagnosis of neoplastic disease is desired or if cells of interest are not normally adherent to glass, then it is necessary to coat

slides with poly-L-lysine (PLL) hydrobromide (molecular weight 90,000 to 120,000) (see pp. 75-76). PLL-coated slides may be purchased ready to use from many suppliers (e.g., Newcomer Supply^a cat. # 5010). For detection of *Perkinsus marinus* by hemanalysis, 24 well tissue culture plates, similar to those available at Corning^b (cat. # 3526), are used.

1. Suspension Chambers

- Use 25-mm² histologic embedding rings (available from Fisher^c cat. # 12-652-108) (30 per sample). Sand embedding rings with fine or extra fine emery cloth until smooth.
- Wash to remove plastic dust, and test on slide for water tightness.
- Attach to slide 5 mm from frosted end using a 13-mm circumference fabric-type (ponytail) elastic band.
- The metal clamp of band is placed under the lip of the chamber at the side, twisted one-half turn, and doubled over top of the lip. Continue to stretch the band under the slide and over the lip of the other side to secure the chamber in place on the slide.
- If properly attached, the chamber will hold 2 ml of liquid without leakage for hours.

Plastic chambers may be reused indefinitely. They should be washed in at least 10 changes of running tap water and placed on clean absorbent paper towels, covered with towels, and allowed to dry overnight at room temperature in a dust-free environment. For arthropod hemolymph preparations, materials must be free of endotoxin. Chambers can be rendered reasonably endotoxin-free by washing in 1:50 Lysol/pyrogen-free, sterile distilled water in pyrogen-free jars. Lysol solution is removed by rinsing the chambers in 6 changes of pyrogen-free, sterile distilled water and then in ethanol. Chambers are dried as above using pyrogen-free absorbent materials and stored in

pyrogen-free, sterile, tightly capped jars until used. A variety of teflon-coated slides are now commonly used in place of suspension chambers. Oxford slides (available from Erie Scientific^d cat. # 10-2197) are one choice; however, the dilution factor must be adjusted since the standard 20-mm-square area holds approximately 0.5 ml of fluid.

2. Preparation of Reagents

For bacterial endotoxin-free solutions, all glassware and the salt crystals must be baked at 190°C for 2 h and then reconstituted with endotoxin-free, sterile distilled water. *This procedure is absolutely necessary for arthropod hemolymph preparations but is optional for mollusks.* Sterile solutions are necessary for molluscan procedures to maintain good quality control. However, it is not necessary to maintain sterility during the bleeding process.

3. Artificial Seawater

A commercially available artificial sea salt is used to prepare a 15% saturated stock solution concentrate. These crystals often contain water (particularly in humid environments) which must be allowed for when weighed. The stock solution is made with 90 gm of salt crystals in 450 ml of sterile distilled water; pH estimations (6.8-8.4) can be accomplished by adding 0.2 gm phenol red to the mixture (this is very useful when preparing fixatives).

Ambient salinity seawater solutions are prepared using 450-ml sterile glass bottles, sterile reagents, and the dilutions in Table 10-1.

C. Hematological Procedures

This technique can be applied to any suspension of living cells provided they attach or can be induced to attach to glass. Preparations have been made from oysters, clams, mussels, scallops, horseshoe crabs, blue crabs, green crabs, lobsters, starfish, urchins, sipunculids, and mouse macrophages.

Disposable hypodermic syringes are used for extracting hemolymph from specimens. Three-cc syringes with 1½-inch No. 20 needles are used for softshell clams, mussels, and oysters. One-cc tuberculin or insulin syringes are used for smaller specimens such as duck clams or juveniles. Five- or 10-cc syringes have been used when standardized 1:10 or 1:20 hemolymph

Table 10-1. Artificial seawater dilution table.

Salinity (o/oo)	Stock (ml)	Water (ml)	Salinity (o/oo)	Stock (ml)	Water (ml)
1	3	: 447	19	57	: 393
2	6	: 444	20	60	: 390
3	9	: 441	21	63	: 387
4	12	: 438	22	66	: 384
5	15	: 435	23	69	: 381
6	18	: 432	24	72	: 378
7	21	: 429	25	75	: 375
8	24	: 426	26	78	: 372
9	27	: 423	27	81	: 369
10	30	: 420	28	84	: 366
11	33	: 417	29	87	: 363
12	36	: 414	30	90	: 360
13	39	: 411	31	93	: 357
14	42	: 408	32	96	: 354
15	45	: 405	33	99	: 351
16	48	: 402	34	102	: 348
17	51	: 399	35	105	: 345
18	54	: 396			

dilutions are desired, as in the case of oysters or horseshoe crabs.

Hemocyte membranes become adhesive when inflammatory activation is induced by removing them from the circulatory system, causing them to become amoeboid and to adhere to each other and most surfaces they contact. These effects can be reduced by: (1) minimizing physical trauma to cells; (2) diluting hemolymph in sterile seawater; (3) reducing temperature below 5°C; and (4) removing calcium. Cell-to-cell contact produces aggregates of cells that interfere with staining affinities and reduce the diagnostic effectiveness of the preparation.

D. Sampling Procedures

Animals are coded by collection date, site, and specimen number, and the length (mm) is recorded for each.

- Drill oyster shells posterior to the adductor muscle or notch with an autopsy saw. Oysters may be tagged with waterproof labeling tape marked with indelible ink and attached to the shell by an elastic band. Stretch the elastic band around the shell, careful not to restrict

opening of the valves.

- Dry clams by wiping the shell with absorbent towels and then alcohol. When the shell is completely dry, it can be marked with an indelible marker.
- Dry mussels as above and mark with fingernail polish or a quick-drying enamel. Notch posterior to the adductor muscle with a triangular file.
- Hold animals overnight in ambient seawater tanks (either running or recirculated systems), allowing them to stabilize and purge drilling residues that may interfere with bleeding.

Hemolymph can be withdrawn from adductor muscle sinuses of any bivalve mollusk. Prior to bleeding, one syringe per specimen is filled with an appropriate amount of chilled, sterile ambient seawater diluent and stored at 5°C until used.

E. Detection of Systemic Parasites and Pathogens by Histocytology

1. Oysters

Procedure:

- 1) Drill (Fig. 10-1) or notch oysters and purge overnight
- 2) Clean slides in acid alcohol (see p.76)
- 3) Prepare teflon-coated slides or suspension chambers with corresponding codes
- 4) Draw 2.5 ml of sterile ambient seawater into a 3-ml syringe and chill
- 5) Insert needle into adductor muscle (Stauber 1950) through drilled hole or notch in oyster valve (approx. 2-3 cm) and withdraw 2-3 drops of hemolymph from sinuses into chilled seawater diluent (Fig. 10-2). Gently invert syringe several times to thoroughly mix hemolymph and seawater
- 6) Place diluted hemolymph (dilution 1:10-1:25) into wells of teflon-coated slides or suspension chambers. Oxford slides hold approx. 0.5 ml of fluid; suspension chambers 1-2 ml
- 7) Allow cells to settle - 10-60 min (Fig. 10-3)
- 8) Examine slides in vivo with inverted microscope
- 9) Drain teflon-coated slides or remove chambers and drain. While wet, place slides (facing forward) in fixative of choice (Fig. 10-4)
- 10) Wash in running tap water - 5 min

- 11) Stain as desired
- 12) Add 1 drop of Permount or other mounting medium
- 13) Mount with coverslip; slides are now ready for examination (Fig. 10-5). See example of MSX (*Haplosporidium nelsoni*) stained with Mayer's hematoxylin and eosin (MHE) (Fig. 10-6). See Table 10-2 for staging criteria

Note: When using 1G4F (1% glutaraldehyde/4% formaldehyde), rinse slides thoroughly if planning to stain with Feulgen reaction, or use an aldehyde blocking agent, i.e., dimedone (see p. 90). Any fixative containing glutaraldehyde must be refrigerated to avoid spontaneous breakdown.

2. Clams

Procedure:

- 1) Draw 2.7 ml of sterile ambient seawater diluent into a 3-ml syringe
- 2) Insert needle between valves into anterior or posterior adductor muscle (4- to 7-mm penetration)
- 3) Withdraw 0.3 ml hemolymph into diluent seawater solution (dilution factor 1:10-1:30 hemolymph to seawater)
- 4) Remove needle from syringe and place 3 ml of diluted hemolymph into suspension chamber. For diagnosing sarcomas, coat slides with PLL (see pp. 75-76)
- 5) Allow cells to settle - 1 h
- 6) Remove chambers; while wet, place slides (facing forward) in fixative of choice
- 7) Wash well in running tap water - 5 min
- 8) Stain as desired
- 9) Mount with Permount and coverslip

3. Mussels

Procedure:

- 1) Follow same dilution outlined for clams
- 2) Insert needle into posterior adductor muscle through a filed notch (5-mm penetration)
- 3) Continue procedure noted for *clams* above
- 4) Place in fixative of choice.
- 5) Wash well in running tap water - 5 min
- 6) Stain as desired
- 7) Mount with Permount and coverslip

F. *Perkinsus marinus* Detection by Hemanalysis

1. Oysters

Procedure:

- 1) Drill a hole or cut a notch in shell of each oyster adjacent and posterior to adductor muscle (Fig. 10-1)
- 2) Insert needle into adductor muscle (about 2 cm) and withdraw 0.5 ml of hemolymph (Fig. 10-7)
- 3) Empty syringe into one of 24 wells (Fig. 10-8)
- 4) Let hemolymph settle - ½ h
- 5) Add thioglycolate medium (see p. 179) to fill well (Ray 1952) (Fig. 10-9)
- 6) Add 1 drop of nystatin (see p. 180)
- 7) Place in dark at room temp. - 2-5 days
- 8) Withdraw supernatant
- 9) Add 1-2 drops of Lugol's iodine working solution (see pp. 179-180) (Fig. 10-10)
- 10) Examine cells for *Perkinsus* (Figs. 10-11, 10-12); see Table 10-3 for staging criteria

G. Footnotes

^aNewcomer Supply, 2217b Parview Road, Middleton, WI 53562. (800) 383-7799. www.newcomersupply.com

^bCorning, Inc., Corning, NY 14831. (800) 492-1110. www.corning.com

^cFisher Scientific, 3970 Johns Creek Court, Suwanee, GA 30024. (800) 766-7000. www.fishersci.com

^dErie Scientific Co., 20 Post Road, Portsmouth, NH 03801. (800) 258-0834. www.eriesci.com

H. References

Farley, C.A. 1989. Selected aspects of neoplastic progression in mollusks, pp. 24-31. *In*: H.E. Kaiser (ed.), Comparative Aspects of Tumor Development. Cancer Growth and Progression, Vol 5. Kluwer Academic Publ., Dordrecht, The Netherlands.

Farley, C.A. and D.L. Plutschak. 1991. Hemolymph thioglycollate diagnosis for *Perkinsus* disease and application to three years of oyster disease surveys in Maryland. Atlantic Estuarine Research Society, St. Michaels, MD. (Abstract)

Farley, C.A. and B. Straight. 1991. An *in vivo* clinical study of *Perkinsus marinus* disease in the American oyster, *Crassostrea virginica*, using hemolymph thioglycolate diagnosis. Society for Invertebrate Pathology, Flagstaff, AZ. p. 40 (abstract)

Farley, C.A., S.V. Otto, and C.L. Reinisch. 1986. New occurrence of epizootic sarcoma in Chesapeake Bay softshell clams, *Mya arenaria*. U.S. Fish. Wildl. Serv., Fish. Bull. 84: 851-857.

Farley, C.A., D.L. Plutschak, and G. Messick. 1991a. Hemanalysis methods for systemic disease diagnosis of invertebrate animals. Atlantic Estuarine Research Society, St. Michaels, MD. (Abstract)

Farley, C.A., D.L. Plutschak, and R.F. Scott. 1991b. Epizootiology and distribution of transmissible sarcoma in Maryland softshell clams, *Mya arenaria*, 1984-1988. Environ. Health Persp. 90: 35-41.

Ray, S.M. 1952. A culture technique for the diagnosis of infections with *Dermocystidium marinum* Mackin, Owen, and Collier in oysters. Science 116: 360-361.

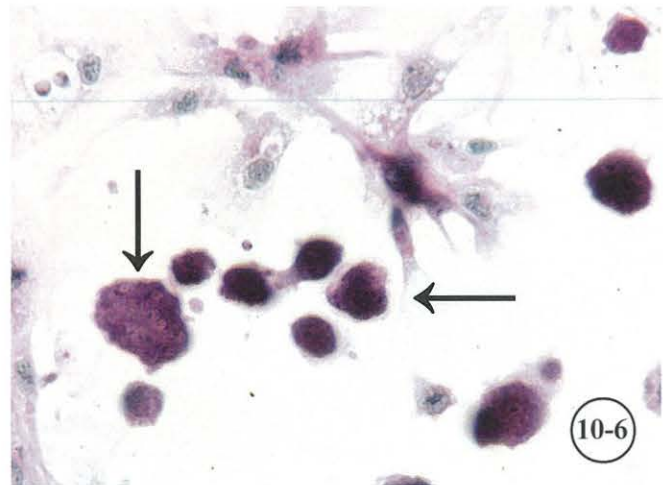
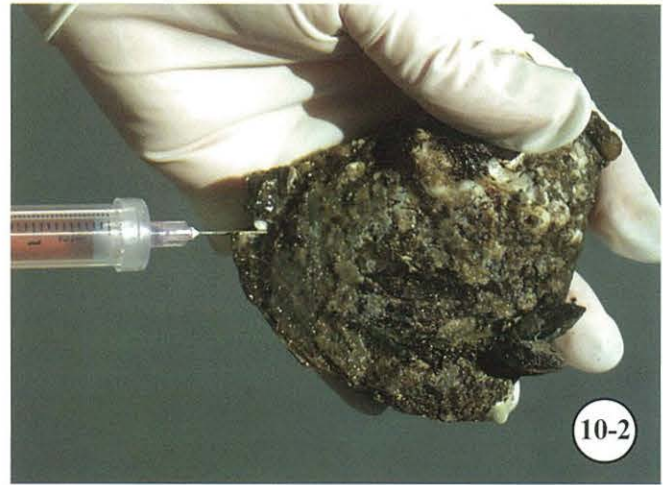
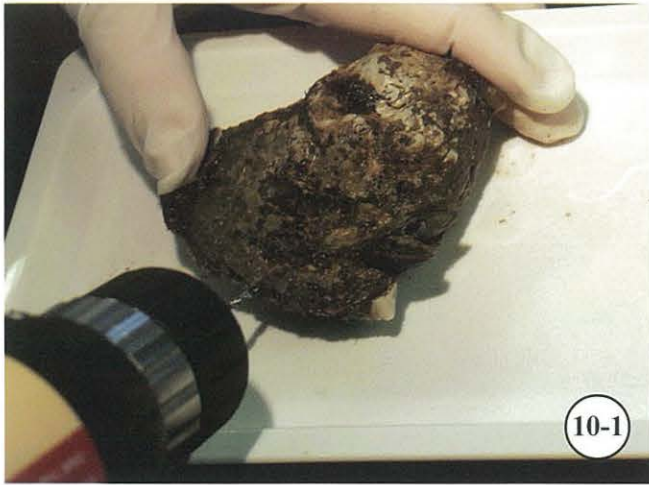

Stauber, L.A. 1950. The fate of India ink injected intracardially into the oyster, *Ostrea virginica* (Gmelin). Biol. Bull. (Woods Hole) 98: 227-241.

Table 10-2. Histocytology staging criteria for *Haplosporidium nelsoni* and *Perkinsus marinus*. Stages were determined using an organism per hemocyte ratio in suspension chambers.

Stage	Plasmodia (<i>H. nelsoni</i>) or aplanospores (<i>P. marinus</i>)
1	1-9 organisms/slide
2	10-99 organisms/slide, but less than 1 organism/200X field
3	1-3 organisms/200X field (1-9 organisms/1000 cells = 0.1-0.9%)
4	1-9% organisms/200X field
5	10-49% organisms/200X field
6	>50% organisms/200X field

Table 10-3. Staging criteria for *Perkinsus marinus* by hemanalysis using tissue culture plates.

Stage	Aplanospores (<i>P. marinus</i>)		
	Cells/well	Cells/field	No. cells on diameter
1	1-4		
2	5-49	1 - 4 (40X)	1 - 2 (40X)
3		7 - 38 (40X) 1 - 7 (100X)	3 - 7 (40X) 1 - 3 (100X)
4		13 - 63 (100X) 3 - 12 (200X) 1 - 2 (400X)	4 - 9 (100X) 2 - 4 (200X) 1 - 2 (400X)
5		7 - 38 (400X)	5 - 14 (200X)
6		>50 (400X)	22 - 73 (400X)

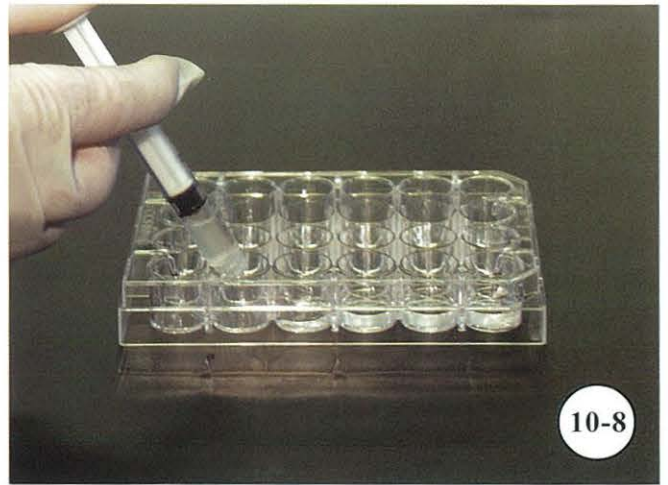


Examination of oyster hemolymph.

Figure 10-1. Drill oyster for bleeding. **Figure 10-2.** Withdraw 2-3 drops of hemolymph from oyster into syringe containing chilled sterile seawater. **Figure 10-3.** Allow diluted hemolymph to settle on slides for 10-60 min. Comparison of teflon-ringed slides (lower row) with Farley slide chambers (upper row); both methods may be used for blood diagnostics. **Figure 10-4.** Remove Farley chamber, drain, and place slides in fixative. **Figure 10-5.** Blood slides stained with MHE ready for examination. Comparison of teflon-ringed slides (lower row) with Farley slide chambers (upper row). **Figure 10-6.** Example of *Haplosporidium nelsoni* (arrows) and oyster blood hemocytes stained with MHE.



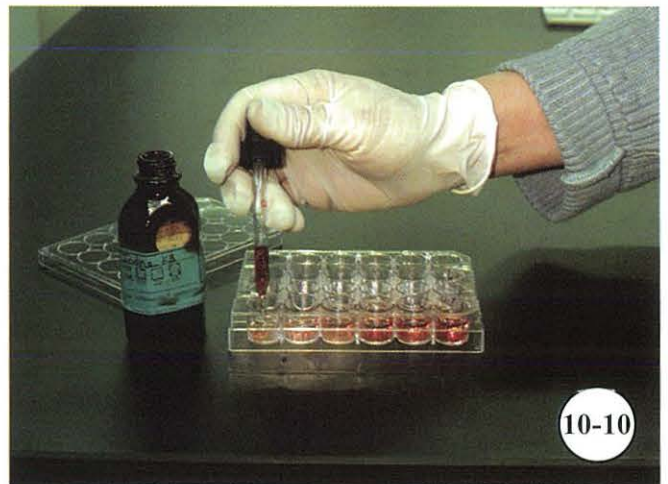10-7



10-8



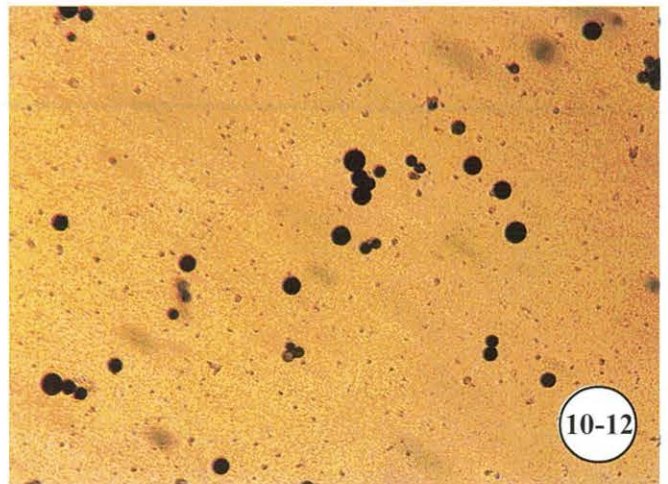
10-9



10-10



10-11



10-12

Detection of *Perkinsus marinus* (Dermo) by hemanalysis.

Figure 10-7. Withdraw 0.5 ml of hemolymph from oyster. **Figure 10-8.** Empty hemolymph into cell well culture dish and let settle for ½ h. **Figure 10-9.** Add thioglycolate medium to each well of culture dish. Withdraw thioglycolate from cell wells after 2-5 days' incubation. **Figure 10-10.** Add 1-2 drops of Lugol's iodine solution. **Figure 10-11.** Examine cell wells with inverted microscope. **Figure 10-12.** Example of *P. marinus* stained with Lugol's iodine.

CHAPTER 11. DIAGNOSTIC TECHNIQUES FOR BLUE CRABS

Gretchen A. Messick

A. Introduction

Blue crabs *Callinectes sapidus* support valuable commercial and recreational fisheries along the eastern seaboard and Gulf of Mexico, USA. Cytology and histology allow for the examination of live and preserved tissues for parasites and host histopathology. Although more specific or sensitive immunoassays and molecular probes have been developed for some disease conditions, cytological and histological analyses of tissues are often the preferred techniques. This chapter outlines various techniques that have been used for disease studies in blue crabs; these techniques easily can be altered to accommodate other crustacean species. A noninvasive method that demonstrates parasites within circulating hemolymph is also described.

To prepare for histological examination, see dissection of blue crabs in Chapter 3 (pp. 20, 55-56).

1. Macroscopic Manifestations

Several parasites exhibit signs that can be putatively identified by looking for abnormal conditions such as shell abnormalities, external parasites, or abnormal physiology. Table 11-1 lists signs of disease, agents that induce the response, and references.

2. Cytological Techniques

Observing crab hemolymph is a quick inexpensive method to ascertain the presence of parasites and conduct clinical studies without sacrificing animals. Hemolymph smears can provide an immediate and inexpensive assay for the presence of parasites. A drop of hemolymph on a hemocytometer can provide a quantitative assay of parasites or hemocytes. To have a permanent assay for the presence of parasites, smears can be fixed and stained and read later, or, if a permanent quantitative assay is required, endotoxin-free chambers can be prepared.

a. Smear Method for Hemolymph

A quick assay recommended for bloodborne parasites in hemolymph.

Procedure:

- 1) Disinfect joint of carapace and 5th pleopod by swabbing with 70% ETOH
- 2) Withdraw 1 drop of hemolymph from hemal sinus at joint of carapace and 5th pleopod into a sterile 1-cc insulin syringe fitted with a 28-ga needle (Fig. 11-1)
- 3) Dispense 1 drop of hemolymph onto acid-cleaned, poly-L-lysine (PLL)-coated microscope slide, and spread using shaft of needle (Fig. 11-2)
- 4) Observe slides promptly with inverted microscope to establish that hemolymph was obtained and to ascertain presence of parasites. Do not allow smear to dry, as alterations in cell morphology will result
- 5) Place in Bouin's, Davidson's, or other fixative of choice - 5 min (Fig. 11-3)
- 6) Prior to staining, wash slides for 20 min in running tap water to thoroughly remove fixative

b. Hemocytometer Method for Hemolymph

A hemocytometer can be used to obtain an accurate count of cells/ml of hemolymph.

Procedure:

- 1) Remove a small quantity of hemolymph from crab following steps 1-2 in (a) above
- 2) Dispense 0.02 ml of hemolymph onto a square of Parafilm®
- 3) Stain and dilute hemolymph 1:1 with 0.02 ml of vital stain of choice
- 4) Mix this solution thoroughly by drawing into and expelling from syringe
- 5) Center a clean hemocytometer coverslip between

Table 11-1. Manifestations of some disease agents of the blue crab.

Signs	Causative agent	Reference
Inactivity; milky hemolymph	Bi-facies virus (BFV)	Johnson 1978a, b, 1983, 1984, 1988
Milky hemolymph; opaque ventral carapace	<i>Hematodinium</i> sp.	Newman and Johnson 1975, Messick 1994
Sluggishness or paralysis; withdrawn hemolymph slow to clot	Reo-like virus (RLV)	Johnson 1977a, b, 1983, 1984, 1986
Blindness and abnormal behavior; erratic swimming	Chesapeake Bay virus (CBV)	Johnson 1978a, b, 1983, 1984, 1986
Pitted or blackened exoskeleton; shell disease	Ubiquitous chitinoclastic bacteria	Rosen 1967, Cook and Lofton 1973, Engel and Noga 1989, Sindermann 1989, Messick and Sindermann 1992
Sluggishness, gray ventral carapace; slowed clotting	<i>Paramoeba pernicioso</i>	Sprague and Beckett 1966, 1968, Sawyer 1969, Sprague et al. 1969, Newman and Ward 1973, Pauley et al. 1975, Johnson 1977c, Couch 1983
Ventral muscle tissue opaque; crabs sluggish; withdrawn hemolymph clots slowly	Various species of microsporidans	Sprague 1950, 1965, 1966, 1970, 1977, Overstreet and Whatley 1975, Overstreet 1977, 1978, Couch 1983
Egg masses appear brown or gray	Fungus <i>Lagenidium callinectes</i>	Couch 1942, Sandoz et al. 1944, Newcombe and Rogers 1947, Rogers-Talbert 1948, Bland and Amerson 1973, 1974
Destruction of egg masses; 1.5-cm orange worms between gill lamellae	Nemertean <i>Carcinonemertes carcinophila</i>	Humes 1942, Hopkins 1947, Pyle and Cronin 1950, Overstreet 1978, 1982
2- to 3-cm black cocoon attached to carapace	Leech <i>Myzobdella lugubris</i>	Moore 1946, Hutton and Sogandares-Bernal 1959, Sawyer et al. 1975, Overstreet 1978
Protrusion under apron of infected crabs; infected males acquire secondary adult female sexual qualities	Parasitic barnacle <i>Loxothylacus texanus</i>	Reinhard 1950, 1956, Adkins 1972, Ragan and Matherne 1974, Overstreet 1978

the outside railings over the two counting grids of hemocytometer

- 6) Place 1 drop (10-20 μ l) of well-mixed cell suspension in each notch
- 7) Count cells using 200X magnification (20X objective lens)

For dilute solutions, count number of cells in 1-mm square (= 0.1 μ l). Count eight 1-mm squares. Select 4 corner squares on 2 grids of hemocytometer. Calculate average. Multiply by 1×10^4 to determine number of cells/ml

For concentrated solutions, count 10 of the 1/16-sq-mm squares. Calculate average value. Multiply by 1.6×10^5 to determine number of cells/ml

For ultra-concentrated solutions, count 10 of the smallest squares in middle section of hemocytometer. These squares are 1/400 sq mm (1/25 x 1/16 sq mm). Calculate average value. Multiply by 4.0×10^6 to determine number of cells/ml.

c. Endotoxin-free Chamber Method for Crabs

Method for quantitative assay of bloodborne parasites. Solutions and equipment coming in contact with hemolymph must be free of endotoxins that trigger clotting mechanisms in crustaceans. Preparation of solutions and chambers is described in Chapter 10.

Procedure:

- 1) Fill a 3-cc syringe fitted with a 25-ga needle with 2.5 ml of endotoxin-free 28 ppt seawater diluent
- 2) Disinfect joint of carapace and 5th pleopod by swabbing with 70% ETOH
- 3) Withdraw 1 drop of hemolymph into a seawater-filled syringe (only use syringes once)
- 4) Mix hemolymph and seawater by inverting syringe several times, and dispense suspension into chamber(s)
- 5) Observe live cells with inverted microscope to verify presence of hemocytes and possible parasites *in vivo*
- 6) Allow cells to settle - approx. 12 min
- 7) Remove chambers and drain excess fluid from slides
- 8) Place slides with attached hemocytes immediately into Bouin's, Davidson's, or other fixative of choice - 5 min
- 9) Stain with Mayer's hematoxylin and eosin (Luna 1968) or other stain of choice

Note: Dilution of crab hemolymph reduces the likelihood

of hemolymph clotting. Precise volumes of hemolymph must be taken from specimens to ensure standardization.

3. *In vivo* Microscope Technique (modified Field technique-MFT)

This microscope technique avoids invasion of tissues and allows for continuous monitoring of parasites *in vivo*. It is modified from Field et al. (1992), thus the acronym MFT. Parasites that inhabit the hemolymph of juvenile (5- to 30-mm) blue crabs are visualized by light transmitted through the thin exoskeleton and tissue in the flattened portion of the 5th pleopod (Messick 1994). This technique has been used to observe normal activity and morphology of internal tissues, parasitic dinoflagellates, and ciliates in hemal sinuses of juvenile crabs. Other large internal parasites can be identified using this method. Additionally, external parasites and symbionts are easily detected.

Procedure:

- 1) Position small crab (5- to 30-mm carapace width) in petri dish on the stage of inverted microscope so that flattened portion of 5th pleopod lies flat
- 2) Using either Hoffman modulation or phase-contrast optics, transmit light through exoskeleton to visualize internal tissues. Focus through carapace to internal tissues and hemal sinuses of pleopod to observe for presence of parasites

B. Discussion

Techniques described in this chapter are but a few of the available means for studying diseases and parasites of crabs. Described methods were established by researchers and technicians at COL and can be easily adapted to other crustacean and invertebrate species. External indicators of disease in blue crabs can be used as a quick, nonspecific method to survey large numbers of crabs for disease. This method can be used to reduce the number of crabs to be bled or dissected when searching for a particular parasite or disease, although it cannot be relied upon to detect all infected crabs since parasites do not always present themselves with external manifestations.

Many parasites can be found in crab hemolymph, including viruses; a parasitic dinoflagellate *Hematodinium* sp. (Fig. 11-4); microsporidians *Ameson* sp., *Nosema* sp., and *Pleistophora* sp. (Fig. 11-5); an amoeba *Paramoeba pernicioso* (Fig. 11-6); and occasionally a ciliate and a

haplosporidan. Most systemic infections can be detected by sampling a small quantity of hemolymph, but not all infected crabs will have parasites in the hemolymph.

When hemocytes are removed from the circulatory system, an inflammatory response causes their membranes to become sticky and to adhere to each other and surfaces such as glass slides and plastic tissue culture flasks. Dilution with sterile seawater minimizes clumping of cells. By diluting hemolymph and allowing cells to settle onto PLL-coated slides, a monolayer of hemocytes and other cells is formed which can be analyzed. The chamber technique is useful for quantitative studies of parasites or cells since precise volumes of hemolymph are removed from specimens and mixed with known quantities of diluent.

The advantage of the smear method is that it is quick, inexpensive, and an uncomplicated method to sample large numbers of crabs with little time spent in preparation. Both techniques cause little harm to animals and provide a permanent preparation of cells from the hemolymph. These techniques also can be used to follow disease progression by sequentially sampling hemolymph from an infected crab over time.

Histological preparations of tissues provide the investigator with permanent tissue sections that show normal tissue structure, parasites, and changes that occur in tissues during disease that may cause physiological dysfunction. Dr. Phyllis T. Johnson's (1980) book on the histology of the blue crab is highly recommended to anyone interested in normal histology or pathology of blue crabs or other decapods. Numerous histochemical and cytochemical staining methods useful or modified for crab tissues are included in Johnson's (1980) book.

The MFT provides researchers with a noninvasive observation of live internal tissue morphology and behavior of certain parasites in vivo. This technique can be used to continuously monitor hemolymph-infesting organisms in small crabs (4- to 30-mm carapace width) which are stressed from multiple bleeding using invasive smear or chamber techniques. This technique also provides an image of cells as they actually appear in vivo, rather than as they appear once removed from the body, often with altered morphology. A video camera attached to an inverted microscope can be used to record phenomena that transpire over time, such as hemocytes spreading and degranulating on microscope slides, hemocytes being pumped throughout tissues and within blood vessels and capillaries, the slowed or clogging effect parasites may have on circulation of hemolymph within tissues, or

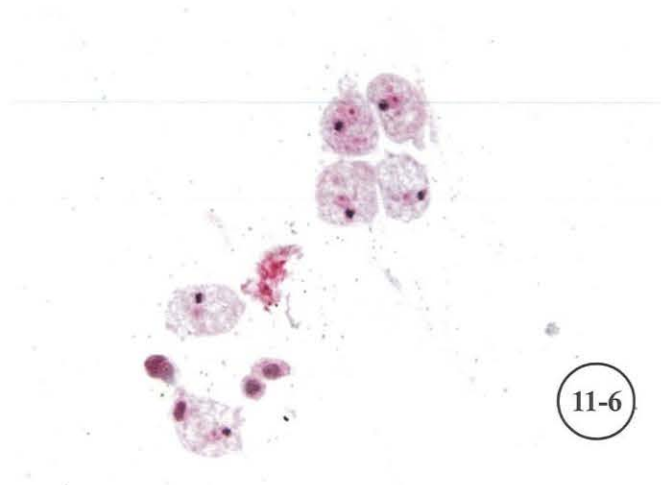
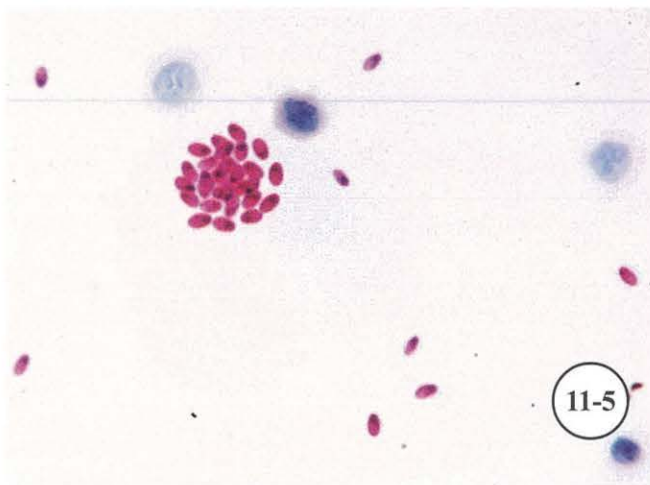
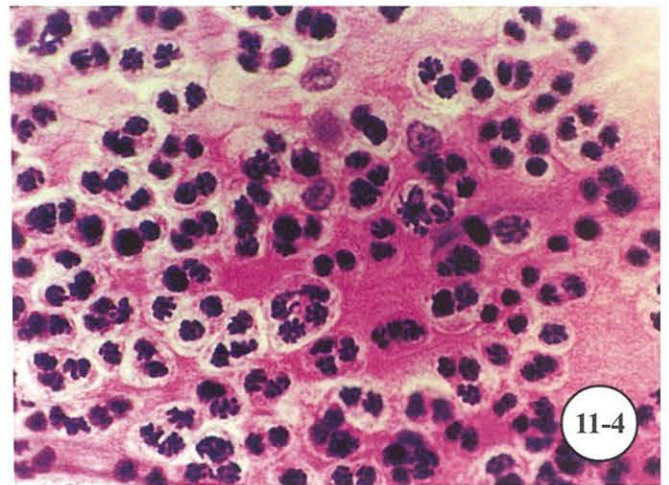
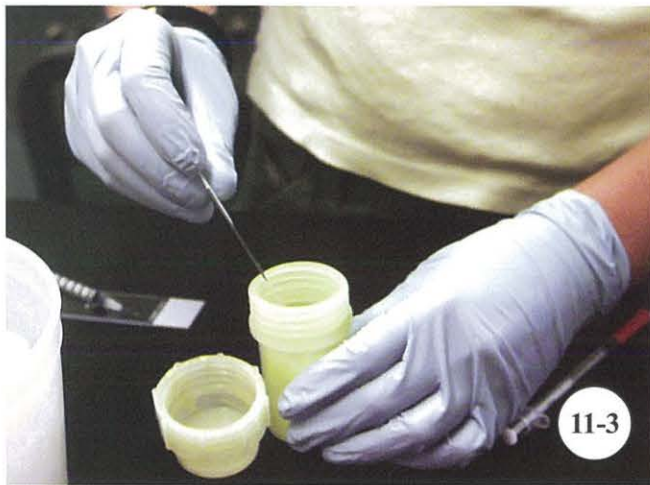
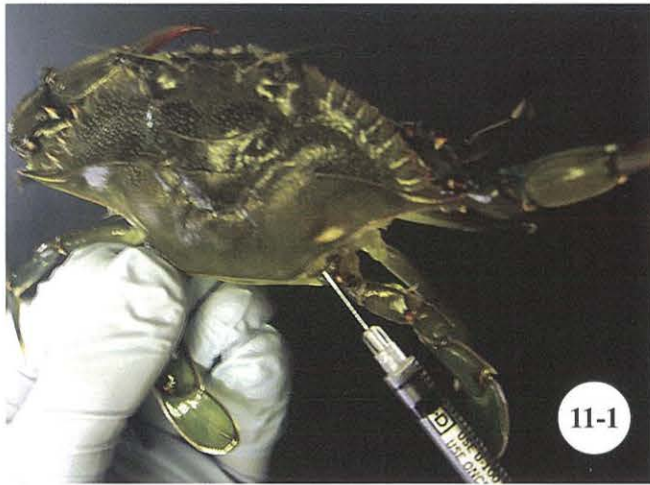interactions between tissues and external parasites such as ciliates in gills and other tissues. Video recorded images provide a permanent record that can then be analyzed with computer software, or shown to audiences to demonstrate certain phenomena that are best viewed over time rather than as a photomicrograph.

C. References

- Adkins, G. 1972. Notes on the occurrence and distribution of the rhizocephalan parasite (*Loxothylacus texanus* Boschma) of blue crabs (*Callinectes sapidus*) in Louisiana estuaries. La. Wildl. Fish. Comm., Tech. Bull. No. 12, 13 pp.
- Bland, C.E. and H.V. Amerson. 1973. Observations on *Lagenidium callinectes*: isolation and sporangial development. *Mycologia* 65: 310-320.
- Bland, C. E. and H.V. Amerson. 1974. Occurrence and distribution in North Carolina waters of *Lagenidium callinectes* Couch, a fungal parasite of blue crab ova. *Chesapeake Sci.* 15: 232-235.
- Cook, D.W. and S.R. Lofton. 1973. Chitinoclastic bacteria associated with shell disease in *Penaeus* shrimp and the blue crab. *J. Wildl. Dis.* 9: 154-159.
- Couch, J.A. 1983. Diseases caused by Protozoa, pp. 79-111. In: A.J. Provenzano (ed.), *The Biology of Crustacea*. Vol. 6. Pathobiology. Academic Press, New York.
- Couch, J. N. 1942. A new fungus on crab eggs. *J. Elisha Mitchell Sci. Soc.* 58: 158-162.
- Engel, D.W. and E.J. Noga. 1989. Shell disease in the blue crabs of the Pamlico River. *Enviroins* (Feb.), pp. 3-5.
- Field, R.H., C.J. Chapman, A.C. Taylor, D.M. Neil, and K. Vickerman. 1992. Infection of the Norway lobster *Nephrops norvegicus* by a *Hematodinium*-like species of dinoflagellate on the west coast of Scotland. *Dis. Aquat. Org.* 13: 1-15.
- Hopkins, S.H. 1947. The nemertean *Carcinonemertes* as an indicator of the spawning history of the host, *Callinectes sapidus*. *J. Parasitol.* 33: 146-150.
- Humes, A.G. 1942. The morphology, taxonomy and bionomics of the nemertean genus *Carcinonemertes*. III. *Biol. Monogr.* 18(4): 1-105.

- Hutton, R.F. and F. Sogandares-Bernal. 1959. Notes on the distribution of the leech, *Myzobdella lugubris* Leidy, and its association with mortality of the blue crab, *Callinectes sapidus* Rathbun. J. Parasitol. 45: 384, 404, 430.
- Johnson, P.T. 1977a. A viral disease of the blue crab, *Callinectes sapidus*: histopathology and differential diagnosis. J. Invertebr. Pathol. 29: 201-209.
- Johnson, P.T. 1977b. Reovirus-like virus of blue crabs, pp. 103-105. In: C.J. Sindermann (ed.), Disease Diagnosis and Control in North American Marine Aquaculture. Elsevier, New York.
- Johnson, P.T. 1977c. Paramoebiasis in the blue crab, *Callinectes sapidus*. J. Invertebr. Pathol. 29: 308-320.
- Johnson, P.T. 1978a. New information on viral diseases of the blue crab, *Callinectes sapidus*. Proceedings of 2d International Colloquium on Invertebrate Pathology and XIth Annual Society for Invertebrate Pathology, Prague, Czechoslovakia. 3 pp.
- Johnson, P.T. 1978b. Viral diseases of the blue crab, *Callinectes sapidus*. Mar. Fish. Rev. 40(10): 13-15.
- Johnson, P.T. 1980. Histology of the Blue Crab, *Callinectes sapidus*: A Model for the Decapoda. Praeger, New York. 440 p.
- Johnson, P.T. 1983. Diseases caused by viruses, rickettsiae, bacteria, and fungi, pp. 1-78. In: A.J. Provenzano, Jr. (ed.), The Biology of Crustacea. Vol. 6. Pathobiology. Academic Press, New York.
- Johnson, P.T. 1984. Viral diseases of marine invertebrates, pp. 65-98. In: O. Kinne and H.P. Bulnheim (eds.), Diseases of Marine Organisms. Helgol. Meeresunters. 37.
- Johnson, P.T. 1986. Blue crab (*Callinectes sapidus* Rathbun) viruses and the diseases they cause, pp. 13-19. In: H.M. Perry and R.F. Malone (eds.), Proceedings of the National Symposium on the Soft-shelled Blue Crab Fishery. Gulf Coast Research Lab., Ocean Springs, MS.
- Johnson, P.T. 1988. Development and morphology of an unusual nuclear virus of the blue crab *Callinectes sapidus*. Dis. Aquat. Org. 4: 67-75.
- Luna, L.G., Editor. 1968. Manual of Histologic Staining Methods of the Armed Forces Institute of Pathology. 3d ed. McGraw-Hill, New York. 258 p.
- Messick, G.A. 1994. *Hematodinium perezii* infections in adult and juvenile blue crabs *Callinectes sapidus* from coastal bays of Maryland and Virginia, USA. Dis. Aquat. Org. 19: 77-82.
- Messick G.A. and C.J. Sindermann. 1992. Synopsis of principal diseases of the blue crab, *Callinectes sapidus*. U.S. Dept. Commerce, NOAA Tech. Memo. NMFS-F/NEC-88, 24 pp.
- Moore, J.P. 1946. The anatomy and systematic position of *Myzobdella lugubris* Leidy (Hirudinea). Not. Nat. (Phila.) 184: 1-12.
- Newcombe, C.L. and M.R. Rogers. 1947. Studies of a fungus parasite that infects blue crab eggs. Turtox News 25(9): 1-7.
- Newman, M. W. and C.A. Johnson, III. 1975. A disease of blue crabs (*Callinectes sapidus*) caused by a parasitic dinoflagellate *Hematodinium* sp. J. Parasitol. 61: 554-557.
- Newman, M.W. and G.E. Ward, Jr. 1973. An epizootic of blue crabs, *Callinectes sapidus*, caused by *Paramoeba pernicioso*. J. Invertebr. Pathol. 22: 329-334.
- Overstreet, R.M. 1977. Microsporidiosis of blue crabs, pp. 200-203. In: C.J. Sindermann and D.V. Lightner (eds.), Disease Diagnosis and Control in North American Marine Aquaculture. Elsevier, New York.
- Overstreet, R.M. 1978. Marine Maladies? Worms, Germs, and Other Symbionts from the Northern Gulf of Mexico. Blossman Printing, Ocean Springs, MS. 140 p.
- Overstreet, R.M. 1982. Metazoan symbionts of the blue crab, pp. 81-87. In: H.M. Perry and W.A. Van Engel (eds.), Proceedings of Blue Crab Colloquium. Gulf Coast Research Lab., Ocean Springs, MS.
- Overstreet, R.M. and E.C. Whatley, Jr. 1975. Prevention of microsporidiosis in the blue crab, with notes on natural infections. Proc. World Maricult. Soc. 6: 335-345.
- Pauley, G.B., M.W. Newman, and E. Gould. 1975. Serum changes in the blue crab, *Callinectes sapidus*, associated with *Paramoeba pernicioso*, the causative agent of grey crab disease. Mar. Fish. Rev. 37(5-6): 34-38.
- Pyle, R.W. and L.E. Cronin. 1950. The general anatomy of the blue crab *Callinectes sapidus* Rathbun. Publ. 87, Chesapeake Biological Lab., Solomons, MD. 40 pp.

- Ragan, J.G. and B.A. Matherne. 1974. Studies of *Loxothylacus texanus*, pp. 185-203. In: R.L. Amborski, M.A. Hood, and R.R. Miller (eds.), Proceedings of Gulf Coast Regional Symposium on Diseases of Aquatic Animals. Publ. No. LSU-SG-74-05, Louisiana State Univ., Baton Rouge.
- Reinhard, E.G. 1950. An analysis of the effects of a sacculinid parasite on the external morphology of *Callinectes sapidus* Rathbun. Biol. Bull. (Woods Hole) 98: 277-288.
- Reinhard, E.G. 1956. Parasitic castration of Crustacea. Exp. Parasitol. 5: 79-107.
- Rogers-Talbert, R. 1948. The fungus *Lagenidium callinectes* Couch (1942) on eggs of the blue crab in Chesapeake Bay. Biol. Bull. (Woods Hole) 95: 214-228.
- Rosen, B. 1967. Shell disease of the blue crab, *Callinectes sapidus*. J. Invertebr. Pathol. 9: 348-353.
- Sandoz, M.D., M.R. Rogers, and C.L. Newcombe. 1944. Fungus infection of eggs of the blue crab, *Callinectes sapidus* Rathbun. Science 99: 124-125.
- Sawyer, T.K. 1969. Preliminary study on the epizootiology and host-parasite relationship of *Paramoeba* sp. in the blue crab, *Callinectes sapidus*. Proc. Natl. Shellfish. Assoc. 59: 60-64.
- Sawyer, R.T., A.R. Lawler, and R.M. Overstreet. 1975. Marine leeches of the eastern United States and the Gulf of Mexico with a key to the species. J. Nat. Hist. 9: 633-667.
- Sindermann, C.J. 1989. The shell disease syndrome in marine crustaceans. Mar. Fish. Rev. 40(10): 32-35.
- Sprague, V. 1950. Notes on three microsporidian parasites of decapod Crustacea of Louisiana coastal waters. La. State Univ., Occas. Pap. Mar. Lab. No. 5: 1-8.
- Sprague, V. 1965. *Nosema* sp. (Microsporida, Nosematidae) in the musculature of the crab *Callinectes sapidus*. J. Protozool. 12: 66-70.
- Sprague, V. 1966. Two new species of *Pleistophora* (Microsporida, Nosematidae) in decapods, with particular reference to one in the blue crab. J. Protozool. 13: 196-199.
- Sprague, V. 1970. Some protozoan parasites and hyperparasites in marine decapod Crustacea, pp. 416-430. In: S.F. Snieszko (ed.), A Symposium on Diseases of Fishes and Shellfishes. Special Publ. No. 5, American Fisheries Society, Bethesda, MD.
- Sprague, V. 1977. Systematics of microsporidia, pp. 1-30. In: L.A. Bulla and T.C. Cheng (eds.), Comparative Pathobiology, Vol. 2. Plenum, New York.
- Sprague, V. and R.L. Beckett. 1966. A disease of blue crabs (*Callinectes sapidus*) in Maryland and Virginia. J. Invertebr. Pathol. 8: 287-289.
- Sprague, V. and R.L. Beckett. 1968. The nature of the etiological agent of gray crab disease. J. Invertebr. Pathol. 11: 503.
- Sprague, V., R.L. Beckett, and T.K. Sawyer. 1969. A new species of *Paramoeba* (Amoebida, Paramoebidae) parasitic in the crab, *Callinectes sapidus*. J. Invertebr. Pathol. 14: 167-174.



Diagnostic techniques for blue crabs.

Figure 11-1. Withdraw hemolymph from crab. **Figure 11-2.** Dispense and spread hemolymph onto poly-L-lysine-coated slide. **Figure 11-3.** Place slides in fixative. **Figure 11-4.** Example of *Hematodinium* in crab hemolymph stained with Mayer's hematoxylin and eosin (MHE). **Figure 11-5.** Microsporidian in hemolymph stained with Ziehl-Neelsen and methylene blue. **Figure 11-6.** *Paramoeba perniciososa* in hemolymph stained with MHE.

CHAPTER 12. MISCELLANEOUS TECHNIQUES AND METHODS FOR MOLLUSKS

Earl J. Lewis

A. Introduction

Three predominant east coast parasites—*Haplosporidium nelsoni* (MSX), *H. costale* (SSO), and *Perkinsus marinus* (Dermo)—have been the focus of oyster disease research for decades. However, other diseases and conditions have appeared with varying degrees of consequences to the oyster industry. For example, juvenile oyster disease is a malady that affects cultured oysters grown in waters of the northeastern United States. *Cryptosporidium* is a fecal contaminant of the aquatic environment, but not a disease agent of shellfish. Several species of *Cryptosporidium* are human pathogens filtered from the water column or sediments and harbored by shellfish. Although cryptosporidiosis has not been reported from the consumption of shellfish, it is believed to be a potential health issue that needs further investigation.

B. Juvenile Oyster Disease (JOD)

Since 1984, a disease of unknown etiology has caused serious mortalities of cultured oysters in the northeastern United States (Farley and Lewis 1997). Juvenile oyster disease (JOD) has a number of specific characteristics that collectively comprise the syndrome (Lewis et al. 1996, Lewis 2001). Mortalities of 60-80% commonly occur over a short period of time in juvenile oysters up to approximately 25-30 mm in size (Bricelj et al. 1992, Davis and Barber 1994, Lewis et al. 1996, Lewis 2001). Mortalities approaching 100% have been observed. Research has been conducted on this disease since 1990 and much has been learned without determining a definitive causative agent. The disease occurs in high salinity areas from Long Island, NY to Maine during summer and early autumn after water temperatures reach and maintain approximately 18-20°C or higher. The first indication of JOD is reduction or cessation of growth in previously healthy and fast growing oysters, followed soon after by mortality. Normal oysters exhibit a clean interior shell (Fig. 12-1a) compared to development of conchiolinous lesions on the interior surfaces of JOD-infected oysters (Fig. 12-1b). Prevalence and intensity

of conchiolin varies, but it is not unusual to see conchiolin in 30-70% of live oysters during a disease outbreak. Mantle recession, or uneven valve margins, is another common sign of the syndrome (Fig. 12-1b). Cupping and directional growth change of the valves also may be observed in some infected oysters. Gross examination of JOD survivors may show exaggerated shell checks, or growth checks, occurring where oysters ceased growth with onset of JOD and began regrowth after successfully combating the disease (Figs. 12-2, 12-3). Some oysters show multiple shell checks which may indicate more than one bout with the disease. Oysters larger than 30 mm may display signs of JOD, but are much less likely to suffer mortality. Histological examination of JOD-infected oysters reveals mantle lesions with small round bodies approximately 2-6 μm in diameter (Fig. 12-4a, b), having a small (1.0- to 1.5- μm) dense-staining nucleus that is Feulgen-positive and often a second Feulgen-positive body similar to a micronucleus. Experimental and field studies have shown that mantle lesions develop 1-2 wk before onset of mortalities (Ford 1994, Lewis 2001). Recommended stains for histological examination of mantle lesions are Feulgen picromethyl blue (FPM) or Mayer's hematoxylin and eosin (MHE). A *Roseobacter* bacterium has been associated with JOD-infected oysters from some areas, but Koch's postulate has not been fulfilled with this agent (Boettcher et al. 1999, 2000). Table 12.1 provides criteria for evaluating oysters for JOD.

C. *Cryptosporidium* and *Giardia* in Shellfish

Cryptosporidium and *Giardia* are protozoan parasites that cause intestinal illnesses in humans (Wolfe 1992, Fayer et al. 1997a). Infections are spread strictly by the fecal-oral route through consumption of contaminated food or water, or by close contact with infected humans or animals. Two species, *C. hominis* and *C. parvum*, have been found to cause most human infections. Oocysts, the infectious stage of the parasite, are resistant to most chemical and antimicrobial treatments, as well as harsh and fluctuating conditions that occur in the aquatic environment. Exposure to high temperatures, freezing temperatures, and drying

Table 12.1. Criteria for evaluation of JOD.

Observation	Time of occurrence	Appearance
Gross criteria		
Drastic slowing or cessation of growth in fast growing juvenile oysters	At disease onset	Normal growth of juveniles slows or stops abruptly. Little or no weekly increase in oyster volume (oysters measured in graduated cylinder wet-packed in water).
Mortality	3-7 wk after exposure to disease agent, depending on water temperature	The first mortalities of 1-4% may be missed, but quickly increase to noticeable levels. Dead oysters may not gape; a dissecting probe may be used to check muscle function prior to opening shells to assess mortality. Oysters 5 to 25-30 mm in size are most likely to die from JOD.
Conchiolin	Concurrent with or soon after first mortalities	A key gross diagnostic feature appears as a thin golden conchiolinous deposit covering some to all of inner shell surfaces and may be present on one or both valves. In advanced cases, conchiolin completely envelops oyster (see Fig. 12-1b). Conchiolin often present after cessation of mortality. May be rare or difficult to observe in oysters less than 12-15 mm in length, but common in 15-30 mm oysters and occasionally those to 50 mm in length.
Mantle recession	As disease progresses	Disappearance of thin growing edge of oyster shell and recession of right valve several mm behind left valve (see Fig. 12-3). Present in animals to approx. 25-30 mm.
Shell checks	On recovery of surviving oysters (after growth resumes)	A thickening, raised ridge, growth band, or overgrowth of exterior shell, most noticeable on left valve of affected oyster and to a lesser extent on right valve. On recovery, oyster may grow vertically before regrowth in normal horizontal direction, causing shell check. Oyster may have one or more shell checks formed at growing edge of shell margin when oyster begins shell regrowth upon recovery from disease. First shell checks correlate to size of oyster at disease onset (see Figs. 12-2, 12-3).
Histological and staining criteria		
Lesions in mantle epithelium	1-2 wk prior to onset of mortalities	FPM is the preferred stain to evaluate JOD histologically. Presence of 2- to 6- μ m intracellular bodies with FPM-positive nuclei are observed in vacuoles of mantle epithelium. These bodies are first found as single cells in vacuoles of healthy mantle epithelium, then as multiple cells in epithelial vacuoles as disease progresses. MHE is a good second choice for staining tissues suspected to be infected by JOD if FPM is not available. See Chapter 8 for FPM and MHE stains.

are three ways to render oocysts noninfectious. Fayer et al. (1997b) and Graczyk et al. (1997) published the first field and laboratory studies in the United States showing that oysters can filter oocysts of *Cryptosporidium* from the water column and retain them in their tissues. Further research has shown that other shellfish, such as clams and mussels, also harbor *Cryptosporidium* and *Giardia* in their tissues (Fayer et al. 1998, 1999, Graczyk et al. 1999a, b, c, 2000). These parasites enter the water column from fecal contamination by humans and other mammals, thus raising a potential public health issue. Although no cases of cryptosporidiosis have yet been reported from eating raw shellfish, the disease is believed to be underreported. Since it may take a week or more to develop, the actual source of infection can be difficult to determine (Fayer et al. 1997a, Mead et al. 1999, PSR 2001). Diagnostic techniques for oocysts include the examination of shellfish tissues stained with Ziehl-Neelsen acid-fast stains or the anti-*Cryptosporidium* and *Giardia* MerIFluor test kit (available from Meridian Bioscience^a cat. # 250050). Results are shown in Table 12.2. Oyster hemolymph or gill wash stained by the MerIFluor^a technique is a quick test that yields reliable results for diagnosis of *C. parvum* (Fayer et al. 1997b).

1. Techniques for Processing and Evaluating Oyster Gill Washes, Blood, and Water for *Cryptosporidium* and *Giardia*

A standard 30-animal sample from each site is used to assay an area. Oysters should be collected and processed the same day. If this is not possible, shellfish may be refrigerated overnight (see Chapter 2 for handling information). Storage of shellfish in aquaria or flow-through systems to assay for *Cryptosporidium* and *Giardia* is not recommended because of the potential to flush oocysts from the shellfish, thus yielding an inaccurate evaluation. Oysters are drilled along the posterior margin between the valves using a cordless drill with a 3/32-inch bit. Drilling on the dorsal side close to the adductor muscle is not recommended; the drill bit may slip and cause damage to the muscle and interfere with obtaining a good blood sample. The drill hole needs to be irrigated by wash bottle containing synthetic seawater of ambient salinity to purge the oysters of shell debris since the oysters cannot be purged in running seawater. This will prevent mechanical damage to the adductor muscle from shell debris when the needle is inserted. To avoid contamination and false results, use new sterile syringes for each oyster. In this procedure, syringes are not filled with sterile seawater before bleeding. Longer needles may be required for larger oysters, and the entry hole may have to be drilled closer to the adductor muscle.

Table 12.2. Criteria for stained *Cryptosporidium* and *Giardia* spp.

Stain	Results	Precautions	Reference page
Ziehl-Neelsen acid-fast stains	Oocyst wall stains red with light microscopy. <i>C. parvum</i> oocysts are round and 4.5-5.5 μm in size.	Only oocyst wall stains. Acid-fast staining allows one to differentiate between intact oocysts and oocyst shells. Oocyst shells are not viable; however, stain does not indicate viability of intact oocysts. Not all oocysts may stain.	123, 124
MerIFluor ^a <i>Cryptosporidium</i> and <i>Giardia</i> test kit	Distinct oocyst and cyst walls stain bright apple green by fluorescence microscopy. <i>Cryptosporidium</i> oocysts are round and 4.5-5.5 μm in size. Depending on <i>Giardia</i> sp., cysts are variable but generally oval and approx. 9x15 μm in size.	As with acid-fast staining, only oocyst wall stains. This procedure allows examination of oocyst morphology to determine if oocyst wall is broken and therefore not viable. Stain does not indicate viability of intact oocysts.	162, 168

a. Recovery of *Cryptosporidium* and *Giardia* from Shellfish

The following immunostain technique was adapted for oyster hemolymph and gill wash studies and tested by Fayer et al. (1997b, 2003) using MerIFluor^a kits specific for *Cryptosporidium* and *Giardia*. It is believed that examination of gill wash material provides information on recent exposures to *Cryptosporidium* while examination of hemolymph provides information on more lengthy exposures.

Procedure:

- 1) Label each disposable syringe (3-5 cc with 18- to 20-ga needles at least 1½-inches long) to correspond with oyster number (1-30)
 - 2) Label a duplicate set of three-well slides similar to Cel-Line (11-mm) heavy teflon-coated (HTC) autoclavable slides (available from Erie Scientific^b cat. # 10-31H) coded according to sample site and oyster number. When processing is done onboard a vessel, silicone sealant may be used to make a raised ring around each well to contain liquid sample within ring. Allow to dry approx. 24 h
 - 3) Add 5 ml of Hanks' balanced salt solution (BSS) (available from Invitrogen^c cat. # 14170) to a sterile 15-ml screw-top centrifuge tube for each oyster to be examined. Refrigerate until use. This formulation of Hanks' BSS contains no calcium chloride, magnesium chloride, or magnesium sulfate
 - 4) Measure oysters (Fig. 12-5) and arrange in numerical sequence for bleeding and necropsy (Fig. 12-6)
 - 5) Drill oysters and purge drill site well with sterile ambient seawater from a squeezable wash bottle (Fig. 12-7)
 - 6) Place numbered syringe next to corresponding oyster (Fig. 12-8)
 - 7) Withdraw hemolymph from oysters by aspiration with a syringe and chill (Fig. 12-9). If performing additional tests such as polymerase chain reaction (PCR) or mouse assays, remove as much hemolymph as possible, often 3-5 ml
 - 8) Place 200 µl of hemolymph from each oyster onto individual HTC slide wells and allow to dry overnight at room temp. (Fig. 12-10)
 - 9) Pool remaining hemolymph in groups of 6 consecutive oysters to yield 5 pools of oyster material for each 30-animal sample, and refrigerate for mouse infectivity assays or PCR analysis
 - 10) Shuck oyster, cut away mantle, and excise entire gill tissue from oyster (Figs. 12-11, 12-12). Place gills into individually labeled centrifuge tubes containing 5 ml of Hanks' BSS (Fig. 12-13). Wash scissors and forceps in distilled water between oysters to help prevent cross-contamination. Water should be changed as needed throughout necropsy
 - 11) With vortex mixer, or similar apparatus, mix tubes containing gill tissue thoroughly for 15 sec to dislodge oocysts. Remove gill tissue from tube and discard
 - 12) Onto a second set of labeled slides, pipet 200 µl of gill wash material from each oyster and allow to dry overnight. When working in field, dried hemolymph and gill wash slides may be transported to laboratory for staining
 - 13) Pool remaining gill wash material in groups of 6 consecutive oysters to yield 5 pools of oyster material for each 30-animal sample, and refrigerate for mouse infectivity assays or PCR analysis
 - 14) Prepare a positive *Cryptosporidium* control slide by drying 200 µl of a suspension of purified oocysts
 - 15) Stain slides with MerIFluor^a fluorescein-labeled anti-*Giardia* and anti-*Cryptosporidium* monoclonal antibodies according to manufacturer's instructions
 - 16) Examine with epifluorescence microscope equipped with a fluorescein isothiocyanate-Texas Red dual wavelength filter
 - 17) Examples of *Cryptosporidium* and *Giardia* stained with MerIFluor^a are shown in Figure 12-14. Typically, oocysts of *Cryptosporidium* spp. infective to humans meet the following criteria:
 - a) Size - 4.5-5.5 µm
 - b) Color - distinct green fluorescence
 - c) Shape - round to slightly ovoid
 - d) Distinct oocyst wall
- Giardia* cysts:
- a) Average size - 9x15 µm
 - b) Color - distinct green fluorescence
 - c) Shape - ovoid
 - d) Distinct cyst wall

b. Mouse Bioassay Technique to Confirm Viability of *Cryptosporidium*

A standard confirmation of viability and human infectivity of *C. parvum* is made through the use of a mouse bioassay. *C. hominis* is not typically transmitted to mice, thus viability cannot be tested by this procedure. Research using vertebrates must be conducted under protocols approved by an Institutional Animal Care and Use Committee in compliance with the Animal Welfare Act and other federal regulations. The following methods have been successfully used for testing viability and infectivity of *C. parvum* isolated from oysters *Crassostrea virginica* (Fayer et al. 1998, 2003):

Procedure:

- 1) Use previously combined gill wash and/or hemolymph pools from above procedure
- 2) Filter gill wash samples through a 45- μ m screen to remove small pieces of gill tissue
- 3) Centrifuge each pool of gill wash and/or hemolymph at 1500 g for 15 min; decant and resuspend in 5 ml of deionized water
- 4) Using a 26-ga, 1-inch, ball-tipped stainless steel inoculating needle attached to a pipet or 1-ml syringe, intubate 3- to 4-day-old BALB/c mice. Feed 4 mice a total of 300 μ l each by gastric intubation from resulting suspensions of pooled hemolymph and/or gill wash material over a 1-day period. Each mouse can be intubated with 150 μ l of material in morning and 150 μ l in afternoon. Twenty (20) mice are used for each 30-oyster sample
- 5) After 4 days, euthanize mice by suffocation with CO₂, followed by cervical dislocation. Dissect mice to remove the last 1 cm of ileum prior to junction of cecum and colon
- 6) Process tissue for histology, and stain tissue with MHE
- 7) Examine ileal epithelium by microscopy for presence and intensity of developmental stages of *C. parvum*. Alternatively, ileum may be processed and examined by PCR for *C. parvum*

c. Evaluating Water Samples for *Cryptosporidium* and *Giardia*

An ambient water sample can be filtered from near the benthic sediment and examined for *Cryptosporidium* using a membrane-filter technique modified by Fayer et al. (1999) and Ley et al. (2002). The following technique is not quantitative, but simply identifies the presence or absence of *Cryptosporidium*.

Procedure:

- 1) Using a Millipore^d YY3029316 filter system, disassemble filter holder and place a 293-mm-diameter, 3- μ m-pore-size white SSWP Millipore^d filter onto a stainless steel filter holder, and moisten with sterile water. Properly place filter onto holder on the first try when filter holder is wet (once filter contacts a moist filter bed, it is difficult to remove and reposition without tearing). Reassemble filter device and seal tightly to prevent leakage
- 2) Tie one end of intake filter hose to an anchor line at desired distance above anchor. A location 6-12 inches above a cement anchor works well to obtain

sample without prematurely clogging filter with sediment particles

- 3) Attach intake hose to filter and pump, then gently lower anchor to bottom to prevent disturbing benthic sediments. Secure line to prevent intake hose from falling into sediment
- 4) Connect another hose to discharge port to pump water overboard
- 5) Begin pumping water (Fig. 12-15). Note time taken to fill a known volume with discharge water, then calculate time to filter 25 L of water (our system pumps approx. 25L/10 min)
- 6) Pump 25 L of water, then change filter membrane (Fig. 12-16). Filter total of 50 L of bottom water at each station (during high rain events, turbidity may cause premature clogging of filter; thus a smaller quantity of water should be filtered through each membrane)
- 7) Carefully remove filter paper, fold to fit into a sterile 50-ml screw-top test tube, and return to laboratory for processing
- 8) Remove filter from test tube. Scrape and rinse particulates from filter into a beaker. Distribute into replicate 50-ml sterile centrifuge tubes (number of tubes used depends on amount of material flushed from filter)
- 9) Centrifuge at 1000X g - 15 min
- 10) Remove supernatant and resuspend pellet in distilled water to make a working solution from pellet (amount of water depends on size of pellet; use <1 ml)
- 11) Remove approx. 10-15 μ l and place on slide to dry
- 12) Premix 2 ml of MerIFluor^a fluorescein-labeled anti-*Giardia* and anti-*Cryptosporidium* monoclonal antibody detection solution with 1 ml of MerIFluor^a counterstain; then add 4 ml of phosphate buffer solution (PBS), pH 7.2
- 13) Mix equal volume of premixed MerIFluor^a solution and 3-10 μ l of an environmental sample in a sterile microcentrifuge tube (to conserve reagents, mix only enough material to be examined)
- 14) Using 3-well slides similar to Cel-Line (11-mm) heavy teflon-coated (HTC) autoclavable slides (available from Erie Scientific^b cat. # 10-31H), add 2 μ l of combined sample to each of 3-10 wells and cover with a 24- x 50-mm coverslip (minimally, 3 replicates are recommended for each water sample)
- 15) Scan at 40X and confirm suspected positives at 100X with epifluorescence microscope equipped with a fluorescein isothiocyanate-Texas Red dual wavelength filter
- 16) In addition to fluorescence microscopy, the sample may be evaluated using PCR techniques by adding DNA extraction buffer to remaining material

Note: When a pump is not available to obtain a bottom sample, a 10-L surface water sample may be substituted. Rinse and empty carboys 3 times at each station, then fill with surface water. Upon return to laboratory, filter water through a 3- μ m-pore-size white SSWP Millipore^d filter and process as above in steps 8-17.

D. Footnotes

^aMeridian Bioscience, 3471 River Hills Drive, Cincinnati, OH 45244. (800) 543-1980. www.meridianbioscience.com

^bErie Scientific Co., 20 Post Road, Portsmouth, NH 03801. (800) 258-0834. www.eriesci.com

^cInvitrogen, 1600 Faraday Ave., Carlsbad, CA 92008. (800) 955-6288. www.lifetech.com

^dMillipore Corp., 80 Ashby Road, Bedford, MA 01730. (800) 645-5476. www.millipore.com

E. References

- Boettcher, K.J., B.J. Barber, and J.T. Singer. 1999. Use of antibacterial agents to elucidate the etiology of juvenile oyster disease (JOD) in *Crassostrea virginica* and numerical dominance of an α -proteobacterium in JOD-affected animals. *Appl. Environ. Microbiol.* 65: 2534-2539.
- Boettcher, K.J., B.J. Barber, and J.T. Singer. 2000. Additional evidence that juvenile oyster disease is caused by a member of the *Roseobacter* group and colonization of nonaffected animals by *Stappia stellulata*-like strains. *Appl. Environ. Microbiol.* 66: 3924-3930.
- Bricelj, V. M., S. Ford, F.J. Borrero, F.O. Perkins, G. Rivara, R.E. Hillman, R.A. Elston, and J. Chang. 1992. Unexplained mortalities of hatchery-reared, juvenile oysters, *Crassostrea virginica* (Gmelin). *J. Shellfish Res.* 11: 331-347.
- Davis C.V. and B.J. Barber. 1994. Size-dependent mortality in hatchery-reared populations of oysters, *Crassostrea virginica*, Gmelin 1791, affected by juvenile oyster disease. *J. Shellfish Res.* 13: 137-142.
- Farley, C.A. and E.J. Lewis. 1997. Juvenile oyster disease fact sheet. U.S. Dept. Commerce, NOAA Tech. Memo. NMFS-SEFSC-404, 8 pp.
- Fayer, R., C.A. Speer, and J.P. Dubey. 1997a. General biology of *Cryptosporidium* and cryptosporidiosis, pp. 1-41. In: R. Fayer (ed.), *Cryptosporidium* and Cryptosporidiosis. CRC Press, Boca Raton, FL.
- Fayer, R., C.A. Farley, E.J. Lewis, J.M. Trout, and T.K. Graczyk. 1997b. Potential role of the eastern oyster, *Crassostrea virginica*, in the epidemiology of *Cryptosporidium parvum*. *Appl. Environ. Microbiol.* 63: 2086-2088.
- Fayer, R., T.K. Graczyk, E.J. Lewis, J.M. Trout, and C.A. Farley. 1998. Survival of infectious *Cryptosporidium parvum* oocysts in seawater and eastern oysters (*Crassostrea virginica*) in the Chesapeake Bay. *Appl. Environ. Microbiol.* 64: 1070-1074.
- Fayer, R., E.J. Lewis, J.M. Trout, T.K. Graczyk, M.C. Jenkins, J. Higgins, L. Xiao, and A.A. Lal. 1999. *Cryptosporidium parvum* identification in oysters from commercial harvesting sites in the Chesapeake Bay. *Emerg. Infect. Dis.* 5: 1-7.
- Fayer, R., J.M. Trout, E.J. Lewis, M. Santin, L. Zhou, A.A. Lal, and L. Xiao. 2003. Contamination of Atlantic coast commercial shellfish with *Cryptosporidium*. *Parasitol. Res.* 89: 141-145.
- Ford, S.E. 1994. Unexplained mortalities of hatchery-reared oysters, *Crassostrea virginica*, in the Northeast: a follow-up study. Final technical report to the Northeastern Regional Aquaculture Center (NRAC), Univ. Massachusetts Dartmouth, North Dartmouth, MA. 41 pp.
- Graczyk, T.K., R. Fayer, E.J. Lewis, C.A. Farley, and J.M. Trout. 1997. In vitro interactions between hemocytes of the Eastern oyster, *Crassostrea virginica* Gmelin, 1791 and *Cryptosporidium parvum* oocysts. *J. Parasitol.* 83: 949-952.
- Graczyk, T.K., R. Fayer, D.B. Conn, and E.J. Lewis. 1999a. Evaluation of the recovery of waterborne *Giardia* cysts by freshwater clams and cyst detection in clam tissue. *Parasitol. Res.* 85: 30-34.
- Graczyk, T.K., R. Fayer, E.J. Lewis, J.M. Trout, and C.A. Farley. 1999b. *Cryptosporidium* oocysts in bent mussels (*Ischadium recurvum*) in the Chesapeake Bay. *Parasitol. Res.* 85: 518-521.

Graczyk, T.K., R.C.A. Thompson, R. Fayer, U.M. Morgan, and E.J. Lewis. 1999c. *Giardia duodenalis* cysts of genotype A recovered from clams in the Chesapeake Bay subestuary, Rhode River. *Am. J. Trop. Med. Hyg.* 61: 526-529.

Graczyk T.K., R. Fayer, M.C. Jenkins, J.M. Trout, J. Higgins, E.J. Lewis, and C.A. Farley. 2000. Susceptibility of the Chesapeake Bay to environmental contamination with *Cryptosporidium parvum*. *Environ. Res.* 82: 106-112.

Lewis, E.J. 2001. Juvenile oyster disease (JOD) and management strategies: a review. *Bull. Natl. Res. Inst. Aquacult., Suppl.* 5: 101-109.

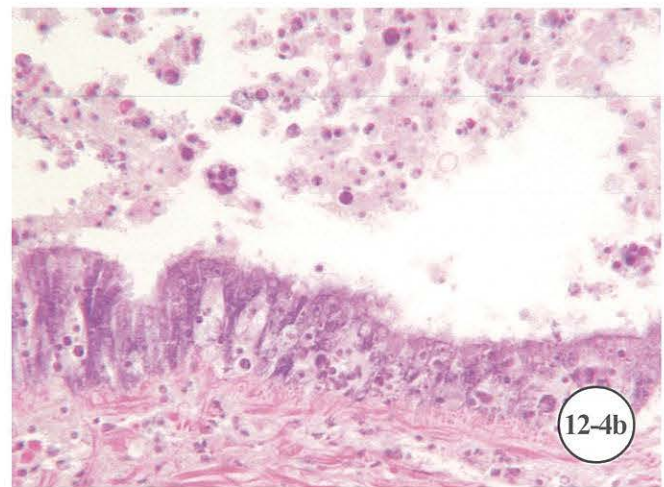
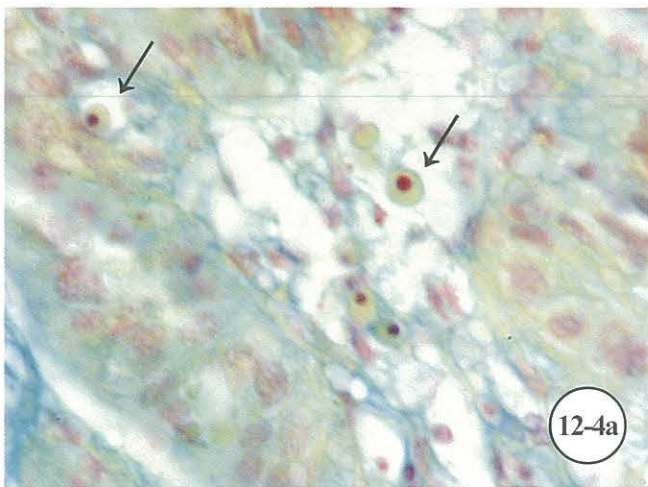
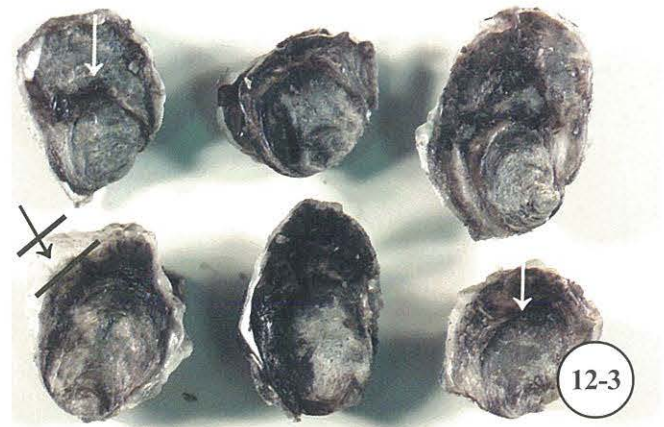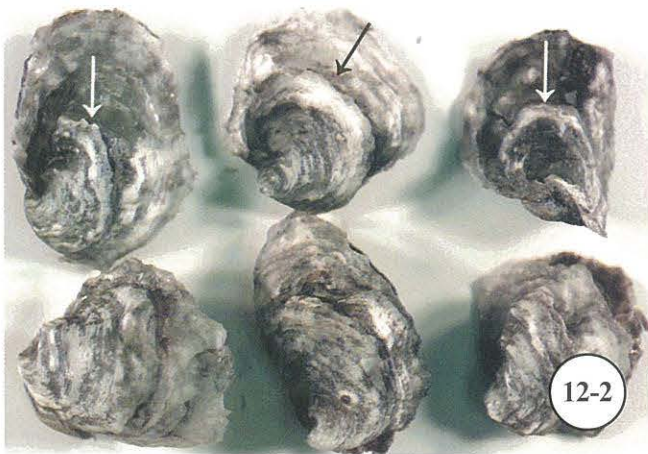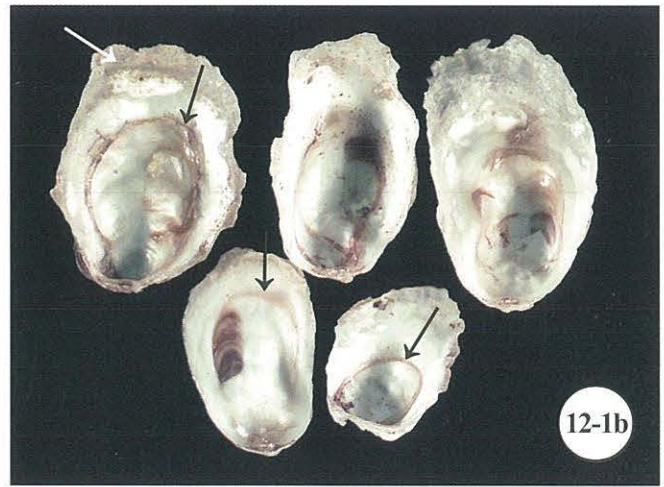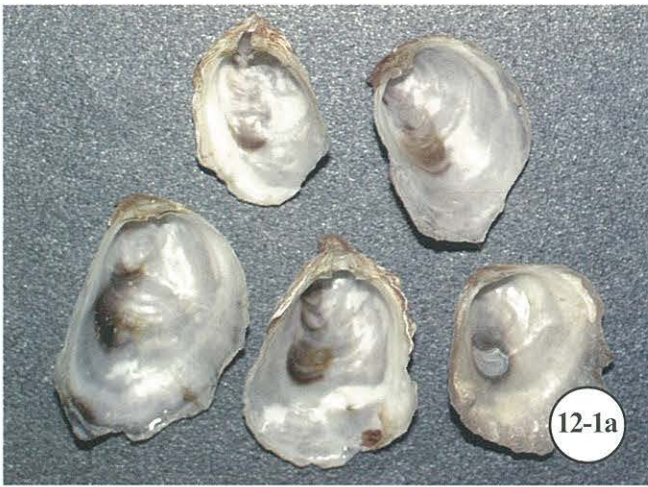Lewis, E.J., C.A. Farley, E.B. Small, and A.M. Baya. 1996. A synopsis of juvenile oyster disease (JOD) experimental studies in *Crassostrea virginica*. *Aquat. Living Resour.* 9: 169-178.

Ley, V., J. Higgins, and R. Fayer. 2002. Bovine enteroviruses as indicators of fecal contamination. *Appl. Environ. Microbiol.* 68: 3455-3461.

Mead, P.S., L. Slutsker, V. Dietz, L.F. McCaig, J.S. Bresee, C. Shapiro, P.M. Griffin, and R.V. Tauxe. 1999. Food-related illness and death in the United States. *Emerg. Infect. Dis.* 5: 607-625.

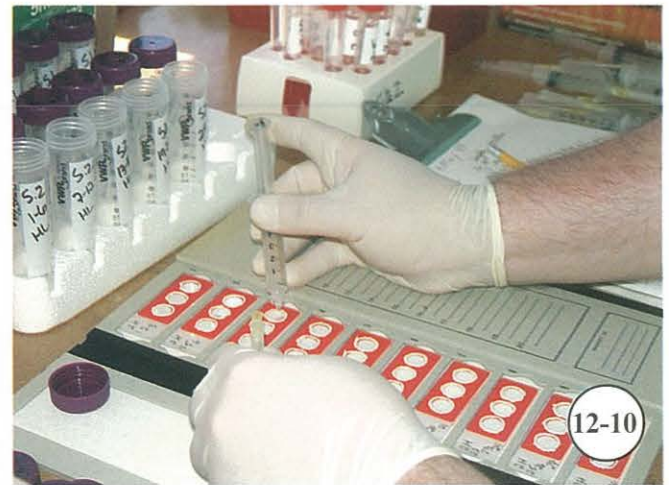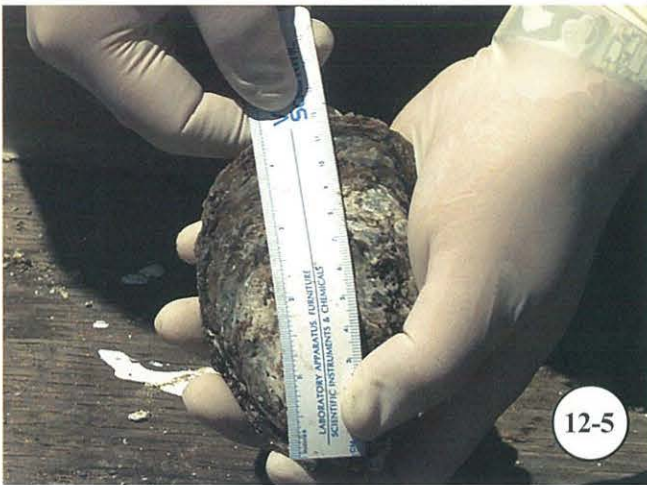
PSR (Physicians for Social Responsibility). 2001. *Cryptosporidium*. What health care providers should know. Drinking Water Fact Sheet # 1, Physicians for Social Responsibility, Washington, DC.

Wolfe, M.S. 1992. Giardiasis. *Clin. Microbiol. Rev.* 5: 93-100.




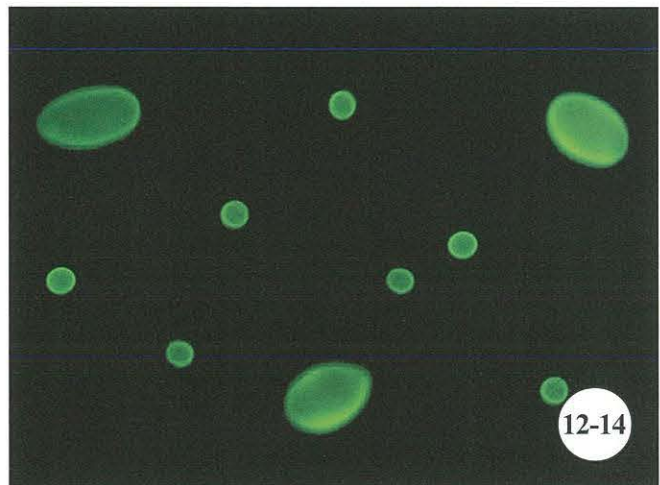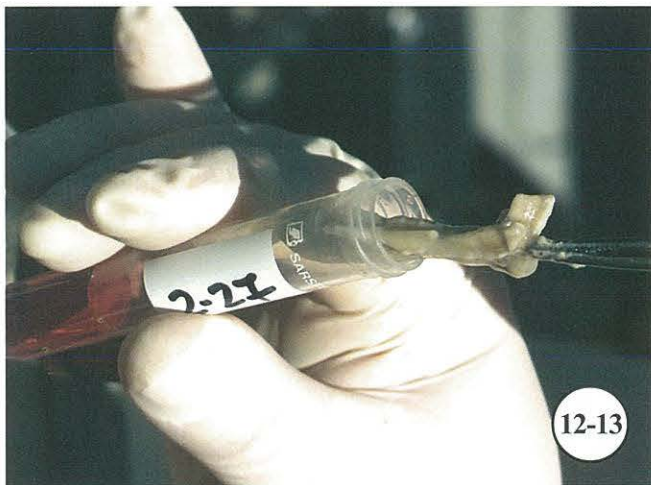
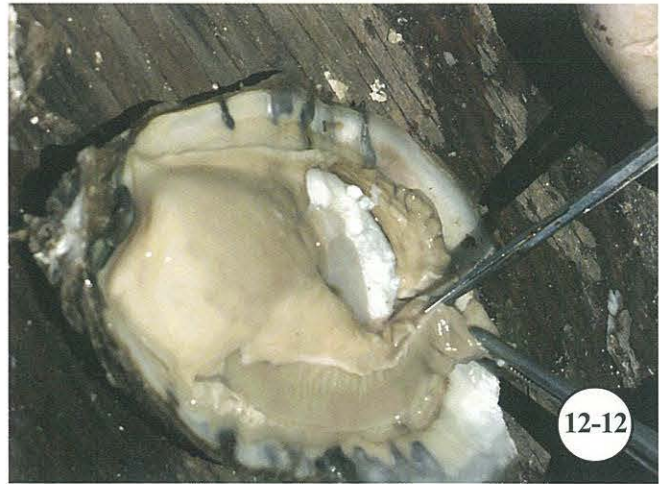Juvenile oyster disease (JOD).

Figure 12-1a. Shells of normal juvenile oysters. **Figure 12-1b.** Shells of JOD-infected oysters displaying conchiolinous shell lesions (black arrows); mantle recession (fouling of inside posterior margin of bottom shell) can be seen on shells of several JOD-infected oysters (white arrow). **Figure 12-2.** Shell checks on bottom valve (arrows). **Figure 12-3.** Shell checks on top valve (white arrows) and mantle recession (area between bars, black arrow). **Figure 12-4a.** Mantle lesion with small round bodies (arrows) indicative of JOD-infected oyster stained with FPM. **Figure 12-4b.** Mantle lesions stained with MHE.



Diagnosis of *Cryptosporidium* and *Giardia* from oysters and water.

Figure 12-5. Measure oysters prior to processing. **Figure 12-6.** Lay oysters in numerical sequence prior to bleeding and necropsy. **Figure 12-7.** Drill oysters in preparation for bleeding. **Figure 12-8.** Place numbered syringes next to corresponding oyster. **Figure 12-9.** Bleed oysters. **Figure 12-10.** Dispense hemolymph onto heavy teflon-coated (HTC) autoclavable ring slide to be stained by MerIFluor[®].



Diagnosis of *Cryptosporidium* and *Giardia* from oysters and water (cont.).

Figure 12-11. Shuck oysters. **Figure 12-12.** Cut away mantle tissue and excise gills for analysis. **Figure 12-13.** Place gills in buffer solution. **Figure 12-14.** Examples of *Cryptosporidium* oocysts (spherical) and *Giardia* cysts (large ovoid) stained by MeriFluor[®] (photomicrograph courtesy of Dr. J. Trout, USDA, Beltsville, MD). **Figure 12-15.** Pump benthic water through filter. **Figure 12-16.** Particles captured by filtering for *Cryptosporidium* spp.

CHAPTER 13. DIAGNOSTIC TECHNIQUES FOR THE SOFTSHELL CLAM *MYA ARENARIA* LINNAEUS, 1758

Shawn M. McLaughlin

A. Introduction

The softshell clam *Mya arenaria* belongs to the phylum Mollusca. This bivalve mollusk is also referred to as soft clam, squirt clam, softshell, manninose, longneck, steamer, and gaper. *Mya arenaria* is widely distributed in both North American and European coastal waters and survives in a broad range of salinities and temperatures. Large softshell clam abundances, located intertidally in New England and subtidally in the Chesapeake Bay, have supported valuable commercial and recreational fisheries; however, landings have steadily declined over the last two decades (NMFS 2003) due to natural and anthropogenic factors including mortalities caused by disease.

A number of parasites, diseases, and disorders have been reported with varying effects on the health of *M. arenaria* (Table 13-1). Disseminated sarcomas, also called hematopoietic neoplasms or clam leukemia, and gonadal neoplasms cause devastating softshell clam mortalities (Yevich and Barszcz 1977, Farley et al. 1986). *Perkinsus* spp. parasites have also been associated with disease and mortalities of softshell clams (Andrews 1955, McLaughlin and Faisal 1998a, 2001, Dungan et al. 2002). Rickettsia-like organisms (RLOs) have been described in digestive diverticula (Harshbarger et al. 1977) and gills (Fries et al. 1991) of softshell clams with undetermined host effects. Bacteria such as *Vibrio* spp. were isolated from softshell clams during natural mortality events in the Chesapeake Bay and caused death upon laboratory inoculation into softshell clams (Tubiash 1971, Kaneko et al. 1975). A strain of *V. anguillarum* isolated from the hemolymph of moribund softshell clams was not found in the hemolymph of healthy animals (McLaughlin 1991). Environmental conditions including poor water quality, sudden changes in temperature or salinity, and high temperatures may adversely affect softshell clams (Kennedy and Mihursky 1971). This chapter focuses on diagnostic techniques commonly used to identify disseminated sarcomas and *Perkinsus* spp. infections in softshell clams. Additional techniques for assessing the health of softshell clams are also described.

B. Health Assessment

1. Gross Examination

The overall health of softshell clams is determined by assessing the condition of the shell and body, and noting any obvious abnormalities.

a. Shell

The two valves of the shell are ovate-elongate in shape with a rounded anterior and slightly pointed posterior. The surface is usually chalky white and may be covered with a thin grayish-brown periostracum. Concentric annular marks or rings occur as rough striations on the shell. These rings result from different growth rates during the year and may be used to estimate clam age since cold winter temperatures restrict growth (Hanks 1963). The internal surface of the shell is smooth and light brown in color. Examine shells for holes, discoloration, and other abnormalities described in Chapter 3.

b. Siphons

The incurrent and excurrent siphons extrude from a gape located at the posterior portion of the shell. A healthy clam will respond to touch by rapidly retracting its siphon muscle. Clams stressed by high temperatures or poor water quality may extend their siphons several times the length of their bodies. Limp, nonresponsive siphons are indicative of moribund or dead clams.

c. Body Condition

Open the shell by inserting a knife into the gape beneath the siphon muscle and run the blade carefully along the edge. Sever the attachment of the anterior and posterior adductor muscles to remove the shell. Assess body condition and other physiological indicators described in Chapter 3. In a healthy clam, the visceral mass or “belly” is plump and creamy white, the kidney mass and digestive gland are brown, and the gills are usually beige.

Table 13-1. Examples of parasites, diseases, and disorders of softshell clams.

Organism or condition	Tissue	Original citation
Proliferative disorders		
Cauliflower-like papillary tumors	Rectum	Hueper (1963)
Benign tumor	Siphon	Pauley and Cheng (1968)
Supernumerary and bifurcated siphons	Siphon	Tubiash et al. (1968)
Hyperplasia	Gill filament, kidney	Barry et al. (1971)
Gonadal neoplasm	Gonads	Barry and Yevich (1975)
Disseminated neoplasia	Hemolymph	Yevich and Barszcz (1976)
Teratoid anomaly	Muscle, nerve, glandular epithelium	Harshbarger et al. (1979)
Viruses		
Virus-like inclusions (Papovaviridae)	Connective tissue, hemocytes, gill epithelium	Farley (1976)
Virus-like inclusions (Paramyxoviridae)	Teratomatous glandular tissue	Farley (1978)
Putative retrovirus	Tissue homogenate	Oprandy et al. (1981)
Bacteria		
Enterobacteriaceae	Tissue homogenate	Kaneko et al. (1975)
<i>Vibrio parahaemolyticus</i>	Tissue homogenate	Earle and Crisley (1975)
<i>V. anguillarum</i> strain	Hemolymph	McLaughlin (1991)
Rickettsia-like organisms	Digestive diverticula, gill epithelial cells	Harshbarger et al. (1977), Fries et al. (1991)
Protozoans		
<i>Parachaenia</i> (= <i>Ancistrocoma</i>) <i>myae</i>	Excurrent siphon, pericardial cavity	Kofoed and Bush (1936)
<i>Perkinsus</i> sp.	Unspecified	Andrews (1955)
<i>P. marinus</i> , <i>P. chesapeakei</i>	Hemolymph, gills, palps	McLaughlin and Faisal (1998b), Kotob et al. (1999), McLaughlin et al. (2000)
Larval trematodes		
<i>Himasthla quissetensis</i>	Gills, palps	Uzmann (1951)
<i>Cercaria myae</i>	Gonad, digestive gland, hemocoel	Uzmann (1952)
Copepods		
<i>Myicola metisiensis</i>	Gills	Wright (1885)
<i>Leptinogaster</i> (= <i>Myocheres</i>) <i>major</i>	Mantle cavity	Williams (1907)

2. Hemolymph Examination

Softshell clams have a two-chambered heart and circulate hemolymph in an open system. Suspended in the liquid or plasma component of the hemolymph are hemocytes including granulocytes and agranulocytes (Huffman and Tripp 1982). Bacteria, parasites, and disseminated sarcomas can be diagnosed by examining a few drops of hemolymph under the microscope. Further, the plasma component may be separated from the hemolymph in order to investigate hemolymph factors related to defense mechanisms.

a. Collection of Hemolymph

Healthy clams survive regular bleedings of 1 ml or less but several recovery days should be allowed between bleedings. Exsanguination usually results in rapid death of clams already stressed by disease or environmental conditions. Hemolymph collected from healthy clams is clear in color while hemolymph from clams with advanced disseminated sarcomas is often milky white.

Procedure:

- 1) With cotton swab moistened with 90% alcohol, wipe surface of anterior or posterior adductor muscle exposed on either side of shell hinge
- 2) Withdraw hemolymph by inserting needle of a sterile syringe 4-7 mm into posterior or anterior adductor muscle. Insertion of needle may be facilitated by gently rubbing the opposite adductor muscle to relax tightly closed shells
- 3) Retract plunger of syringe slowly to withdraw a few drops of hemolymph. A tuberculin syringe with a 27-ga needle is adequate for collecting small amounts

b. Wet mount

A nonquantitative technique that provides a preparation to rapidly identify and estimate stages of disseminated sarcoma in softshell clams for in vitro studies or other applications. Parasites and other microorganisms may also be observed in the hemolymph preparations.

Procedure:

- 1) Place 1-2 drops of hemolymph onto a clean microscope slide coated with poly-L-lysine (PLL) by gently pushing plunger of syringe; then coverslip

- 2) Examine wet mounts by phase or Hoffman modulation contrast to estimate ratio of normal hemocytes (Fig. 3) and sarcoma cells (Fig. 4), or for presence of microorganisms

Note: Normal hemocytes are amoeboid with extended pseudopodia and small round nuclei while sarcoma cells are round, refractile, and have a high nucleus to cytoplasmic ratio. Ratio of sarcoma cells to normal hemocytes increases as sarcomas progress in severity.

c. Stained Preparation of Hemolymph Cellular Component

A quantitative method developed by Farley et al. (1986) for identifying and staging disseminated sarcomas in softshell clam hemolymph. The permanent stained monolayer preparations are found to be more accurate than histology for detecting early stages of the disease (Farley 1989). The preparations may also reveal systemic infections by parasites and other microorganisms.

Procedure:

- 1) Prepare sterile artificial seawater diluent, suspension chambers, and/or teflon-coated slides according to Farley (see pp. 143-144). For diagnosing sarcomas, slides must be PLL-coated (see pp. 75-76)
- 2) Draw 2.7 ml of sterile ambient seawater diluent into a 3-ml syringe and refrigerate until cold
- 3) With cotton swab moistened with 90% alcohol, wipe surface of anterior or posterior adductor muscle exposed on either side of shell hinge
- 4) Insert needle between valves into anterior or posterior adductor muscle (5- to 10-mm penetration), avoiding the gonad and intestine
- 5) Withdraw 0.3 ml hemolymph into diluent seawater solution (dilution factor 1:10-1:30 hemolymph to seawater)
- 6) Remove needle from syringe and place 3 ml of diluted hemolymph into suspension chamber
- 7) Allow cells to settle – 1 h
- 8) Remove chambers; while wet, place slides (facing forward) in fixative of choice
- 9) Wash well in running tap water
- 10) Stain preparations with Feulgen picromethyl blue (FPM) or stain of choice
- 11) Mount with Permount and coverslip
- 12) Examine preparations with bright field microscopy to determine presence and stage of sarcoma (Table 13-2)

Note: Ratio of normal hemocytes (amoeboid with extended pseudopodia and smaller nuclei) (Fig. 13-5) to sarcoma cells (rounded hyperchromatic cells with high nucleus to cytoplasmic ratios) decreases as sarcomas progress in severity (Table 13-2). In advanced cases, the field will be dominated by sarcoma cells (Fig. 13-6).

d. Separation of Plasma from Hemolymph

A method for preparing cell-free hemolymph to analyze activities of hydrolytic enzymes, protease inhibitors, microbial peptides, and other factors found in plasma of softshell clams (Huffman and Tripp 1982, Elsayed et al. 1999).

- 1) Withdraw hemolymph into a 3- to 5-ml syringe
- 2) Remove needle and release contents of plunger into a sterile centrifuge tube held on ice
- 3) Cap tube and centrifuge at 400 rpm - 10 min at 4°C
- 4) Filter cell-free hemolymph using a 0.22-µm Millipore^a filter
- 5) Aliquot as needed into containers held on ice
- 6) Analyze plasma immediately or store at -20°C

C. Tissue Incubation and Special Media

Chapter 3 outlines the procedure for analyzing rectal tissues of softshell clams for *Perkinsus* infections using Ray's fluid thioglycolate medium (RFTM) (Ray 1952). General procedures for this technique are further described in Chapter 14. Additional information for the application of the technique to softshell clams is provided below. Further, a method for isolating and propagating *Perkinsus* spp. in vitro from softshell clams is described.

1. Formation of Hyphospores in Ray's Fluid Thioglycolate Medium (RFTM) (Ray 1952)

Diagnostic methods used for the detection of *Perkinsus* spp. in mollusks vary in complexity and efficacy; however, the relatively inexpensive, semiquantitative assay developed by Ray (1952) continues to be the assay of choice. In this technique, pieces of mantle, rectum or other tissues are incubated separately in Ray's fluid thioglycolate medium (RFTM) for several days. *Perkinsus* spp. cells become enlarged in RFTM and form hyphospores that stain blue-black with Lugol's iodine solution. It should be noted that some phytoplankton may stain with Lugol's iodine and produce false positives in RFTM assays (Almeida et al. 1999).

Table 13-2. Stages of softshell clam sarcomas. Criteria based on the ratio in suspension chambers of sarcoma cells to hemocytes in hemolymph of neoplastic clams (Farley et al. 1991).

Stage	Sarcoma cells	Hemocytes
1	1-9 cells	100,000
2	1-9 cells	10,000
3	1-9 cells	1,000
4	1-9%	91-99%
5	10-49%	51-90%
6	50-89%	11-50%
7	90-100%	1-10%

The selection of tissues for incubation in RFTM is an important consideration when attempting to diagnosis *Perkinsus* spp. infection in mollusks. Rectal and mantle tissues are used in RFTM assays for routine diagnosis of *P. marinus* infection in the eastern oyster *Crassostrea virginica* (Ray 1966) because early infections occur in the digestive epithelium and mantle connective tissues in this species (Mackin 1951). On the contrary, gill and labial palp tissues are more effective for diagnosing early *Perkinsus* spp. infections in clams. Rectal tissues are adequate for diagnosing moderate to advanced *Perkinsus* infections in clams; however, early infections are often undetected by this method (Rodriguez and Navas 1995, McLaughlin and Faisal 1999). The incubation of gill or labial palp tissues and rectal tissues in separate RFTM assays allows one to judge the intensity of infection and its progression in each clam.

The rapidly systemic nature of *P. marinus* infections in oysters affords the use of a less invasive assay that utilizes hemolymph withdrawn from live animals and incubated in RFTM (see Farley, Chapter 10; Gauthier and Fisher 1990). The hemolymph assay has limited value, however, for routine diagnosis of *Perkinsus* spp. in clams because the parasites can be detected in the hemolymph only in more advanced infections (McLaughlin and Faisal 1999). For both oysters and clams, the accuracy of RFTM in quantitation of parasite body burden may be improved by incubating the entire body in RFTM (Choi et al. 1989, Bushek et al. 1994) when tissues are not needed for histology or other applications.

Procedure:

- 1) Prepare RFTM and Lugol's iodine stock and working solutions (see pp. 179-180)

- 2) Measure clam shells longitudinally (see Fig. 3-59). Open clams with disposable scalpel (see Fig. 3-60)
- 3) Locate and, with sharp scissors, excise distal portion of each gill (approx. 3-5 mm in size depending upon size of clam) (Fig. 13-7) and labial palps (Fig. 13-8)
- 4) Place tissues on edge of culture tube and, with a hooked glass rod, immerse in RFTM (Fig. 13-9). Do not contaminate tubes with scissors; rinse scissors and glass rod thoroughly
- 5) Incubate tubes in dark – 72 h
- 6) Remove tissue from tube with a hooked glass rod and place on correspondingly coded slide with 1 drop of Lugol's iodine working solution (see Fig. 14-2)
- 7) Tease tissue apart with probes (Fig. 13-10); clean probes with distilled water between each specimen
- 8) Add another drop of Lugol's iodine working solution and place a coverslip on slide
- 9) Examine slides. Figure 13-11 shows *Perkinsus* sp. hypnospores stained with Lugol's; Figure 13-12 shows gill tissue infected with *Perkinsus* sp.

2. In Vitro Propagation

Perkinsus species may be isolated and cloned from softshell clams, and other mollusks, using special media. The ability to grow *Perkinsus* species in continuous culture was first demonstrated by La Peyre et al. (1993) using a medium closely resembling bivalve plasma composition. *Perkinsus chesapeaki* and *P. marinus* were isolated and cloned from softshell clams (McLaughlin and Faisal 1998b) using media and methodology developed for oyster *P. marinus* (La Peyre et al. 1993, La Peyre and Faisal 1995). A variety of culture media and methods shown to be successful in propagating *Perkinsus* species are reviewed by La Peyre (1996).

Procedure:

Follow the RFTM procedure outlined above, except place extra pieces of gill or palps into the sample tubes. When a sample with a moderate to advanced *Perkinsus* spp. infection is identified by Lugol's staining, the unstained extra pieces of tissues in the RFTM tubes may be used to initiate cultures.

- 1) Use aseptic techniques throughout procedure. Prepare JL-ODRP-1 (see La Peyre et al. 1993) or other *Perkinsus* growth media
- 2) Place 5 ml of growth media in 5-cm culture flasks with a sterile pipet
- 3) Transfer tissues from RFTM tube into culture flask

- 4) Mince tissues in flask with a sterile inoculating loop
- 5) Incubate at 28°C with 5% carbon dioxide tension - 2-3 wk, and subculture as needed
- 6) Using a microscope housed in a biological laminar flow hood, select cultures dominated by *Perkinsus* cells and serially dilute cells with fresh growth medium to 1 cell/200X microscopic field
- 7) Select a single cell from serially diluted cultures with a sterile micropipet
- 8) Place cloned cell into well of a 96-multiwell tissue culture plate containing fresh media
- 9) Incubate at 28°C with 5% carbon dioxide - 3 wk, and repeat cloning procedure
- 10) Subculture cloned isolates in fresh media - every 4-6 wk

D. Bacteriology

A variety of selective and nonselective media are available for the isolation of bacteria from the hemolymph of softshell clams. A presumptive diagnosis of *Vibrio* spp. may be made using a selective media called thiosulfate citrate bile salts sucrose (TCBS). Confirmation of the identity of isolates can be obtained using an API-20E^b identification system developed for Enterobacteriaceae and other nonfastidious gram-negative rods.

Procedure:

- 1) Throughout procedure, use aseptic techniques and appropriate handling precautions for bacterial group to be studied
- 2) With cotton swab moistened with 90% alcohol, wipe surface of anterior or posterior adductor muscle exposed on either side of shell hinge
- 3) Insert a 27-ga needle of a sterile tuberculin syringe into anterior or posterior adductor muscle (4- to 7-mm penetration)
- 4) Retract plunger of syringe slowly to withdraw a few drops of hemolymph
- 5) Lift lid of TCBS plate. Gently expel 1 drop of hemolymph onto plate and streak with a sterile inoculating loop to obtain isolated colonies
- 6) Replace lid and incubate - 48 h at 28°C
- 7) Examine plate for characteristic colonial morphology
- 8) Prepare API-20E^b biochemical test kit per manufacturer's instructions
- 9) Pick up a single well-isolated colony from plate with a sterile pipet
- 10) Place colony in 5 ml of 0.85% NaCl medium

provided with kit and carefully emulsify to achieve a homogeneous bacterial suspension

- 11) With same pipet, apply bacterial suspension to test strip following manufacturer's instructions
- 12) Incubate - 18-24 h at 35-37°C
- 13) Record reactions and identify species using the provided Analytical Profile Index

E. Histology

The most common method for assessing softshell clam health is by microscopic examination of tissues. Tissues from softshell clams are processed following routine histology protocols described in previous chapters. Davidson's fixative and 1% glutaraldehyde/4% formaldehyde (1G4F) fixative prepared in half ambient seawater provide adequate tissue preservation. Paraffin-embedded sections are routinely stained with Mayer's hematoxylin and eosin (MHE) or special stains, as needed. Figures 13-1, 13-2, and 13-12 show the histology of disseminated sarcomas, RLOs, and *Perkinsus* spp. infections in softshell clams. It should be noted that histology preparations are inadequate for the detection of early *Perkinsus* infections in oysters and clams (Mackin 1962, Rodriguez and Navas 1995, McLaughlin and Faisal 1999) or for detecting early stages of disseminated sarcomas (Farley 1989).

F. Electron Microscopy (EM)

Tissues fixed in 1G4F may also be processed for examination by EM. Chapter 14 provides additional details for preparing tissues for ultrastructural examination. EM is the method of choice for identifying viruses and RLOs.

G. Footnotes

^aMillipore Corp., 80 Ashby Road, Bedford, MA 01730. (800) 645-5476. www.millipore.com

^bbioMérieux, Inc. 100 Rodolphe St., Durham, NC 27712. (800) 682-2666. www.biomerieux-usa.com

H. References

Almeida, M., F. Berthe, A. Thébault, and M.T. Dinis. 1999. Whole clam culture as a quantitative diagnostic procedure of *Perkinsus atlanticus* (Apicomplexa,

Perkinsea) in clams *Ruditapes decussatus*. *Aquaculture* 177: 325-332.

Andrews, J.D. 1955. Notes on fungus parasites of bivalve mollusks in Chesapeake Bay. *Proc. Natl. Shellfish. Assoc.* 45: 157-163.

Barry, M. and P.P. Yevich. 1975. The ecological, chemical and histopathological evaluation of an oil spill site. Part III. Histopathological studies. *Mar. Pollut. Bull.* 6: 171-173.

Barry, M.M., P.P. Yevich, and N.H. Turner. 1971. Atypical hyperplasia in the soft-shell clam *Mya arenaria*. *J. Invertebr. Pathol.* 17: 17-27.

Bushek, D., S.E. Ford, and S.K. Allen, Jr. 1994. Evaluation of methods using Ray's fluid thioglycollate medium for diagnosis of *Perkinsus marinus* infection in the eastern oyster, *Crassostrea virginica*. *Annu. Rev. Fish Dis.* 4: 201-217.

Choi, K.-S., E.A. Wilson, D.H. Lewis, E.N. Powell, and S.M. Ray. 1989. The energetic cost of *Perkinsus marinus* parasitism in oysters: quantification of the thioglycollate method. *J. Shellfish Res.* 8: 125-131.

Dungan, C.F., R.M. Hamilton, K.L. Hudson, C.B. McCollough, and K.S. Reece. 2002. Two epizootic diseases in Chesapeake Bay commercial clams, *Mya arenaria* and *Tagelus plebeius*. *Dis. Aquat. Org.* 50: 67-78.

Earle, P.M. and F.D. Crisley. 1975. Isolation and characterization of *Vibrio parahaemolyticus* from Cape Cod soft-shell clams (*Mya arenaria*). *Appl. Microbiol.* 29: 635-640.

Elsayed, E.E., S.M. McLaughlin, and M. Faisal. 1999. Protease inhibitors in plasma of the softshell clam *Mya arenaria*: identification and effects of disseminated sarcoma. *Comp. Biochem. Physiol.* B123: 427-435.

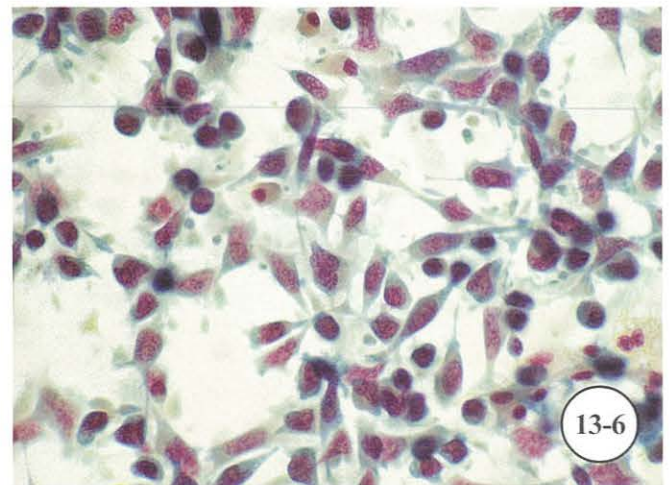
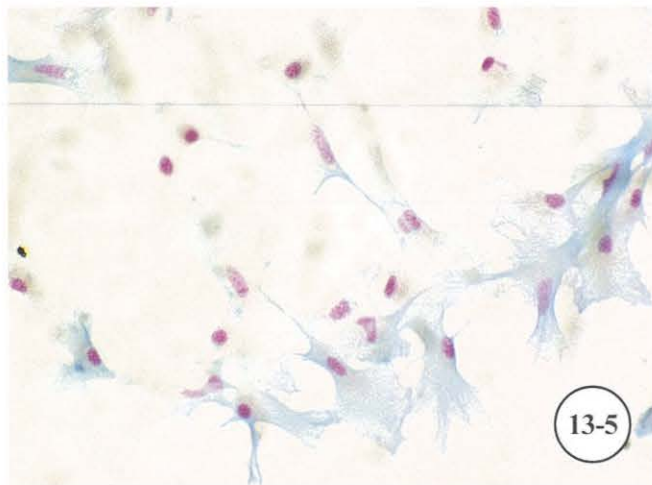

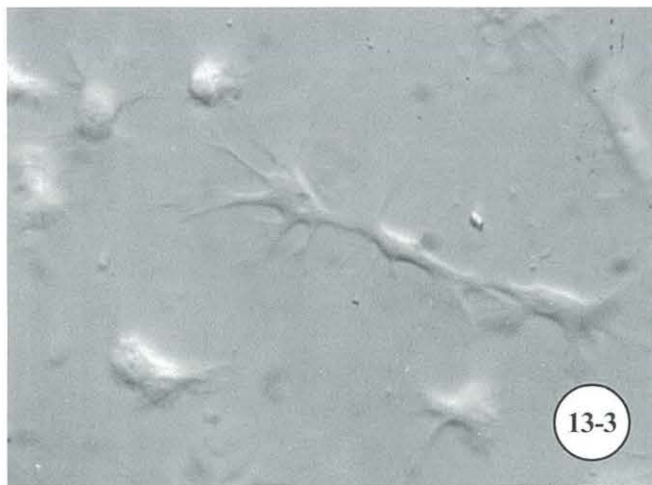
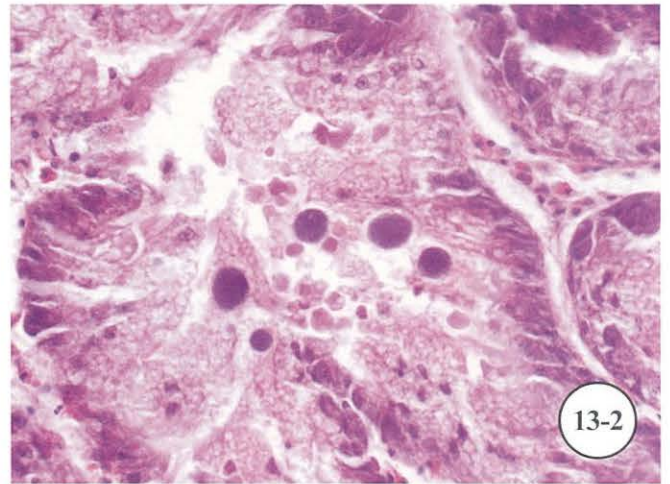
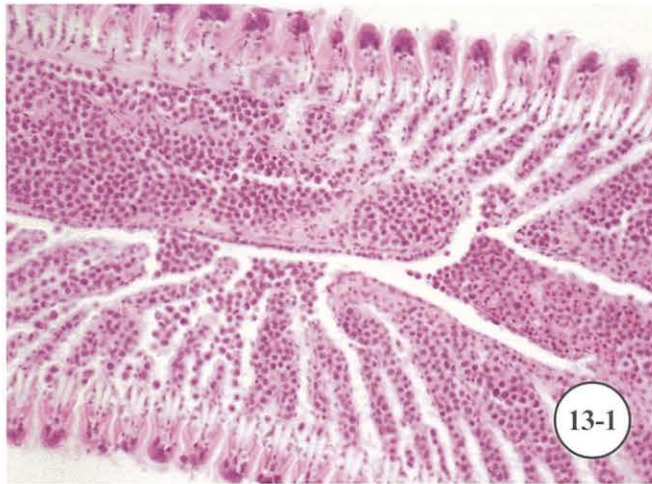
Farley, C.A. 1976. Proliferative disorders in bivalve mollusks. *Mar. Fish. Rev.* 38(10): 30-33.

Farley, C.A. 1978. Viruses and viruslike lesions in marine mollusks. *Mar. Fish. Rev.* 40(10): 18-20.

Farley, C.A. 1989. Selected aspects of neoplastic progression in mollusks, pp. 24-31. *In*: H.E. Kaiser (ed.), *Cancer Growth and Progression*. Vol. 5. *Comparative Aspects of Tumor Development*. Kluwer Acad. Publ., The Netherlands.

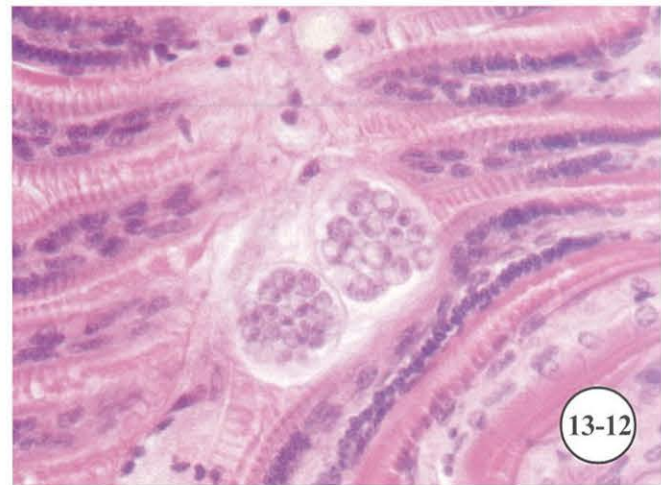
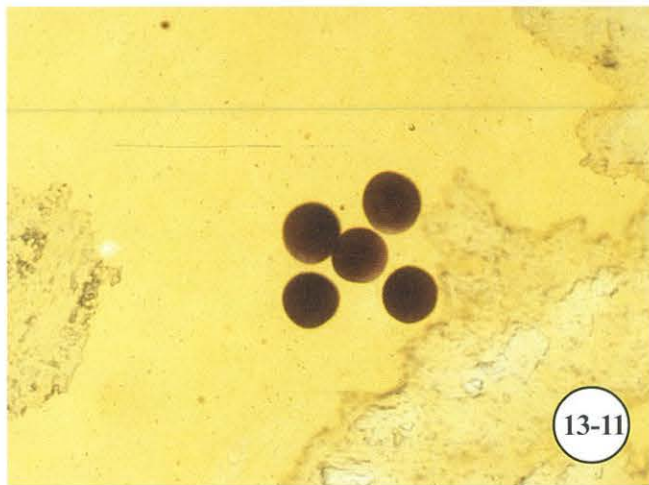
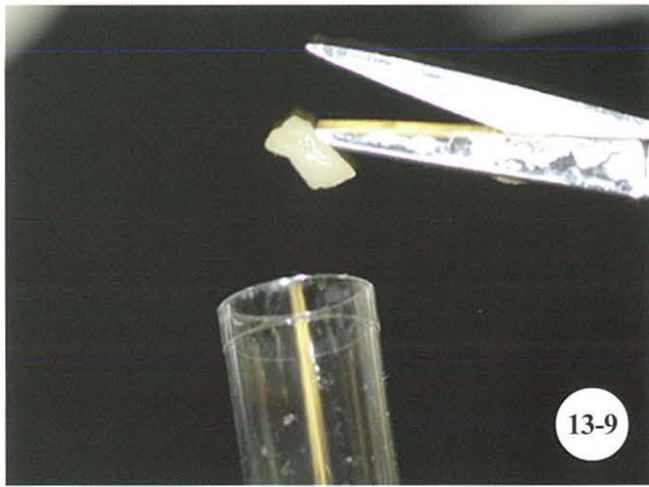
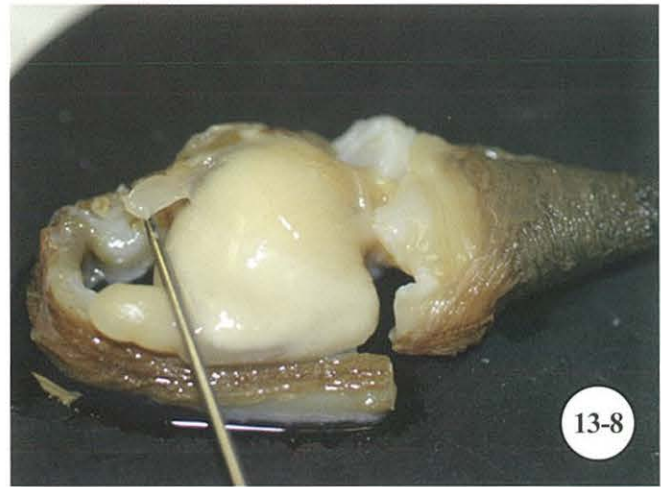
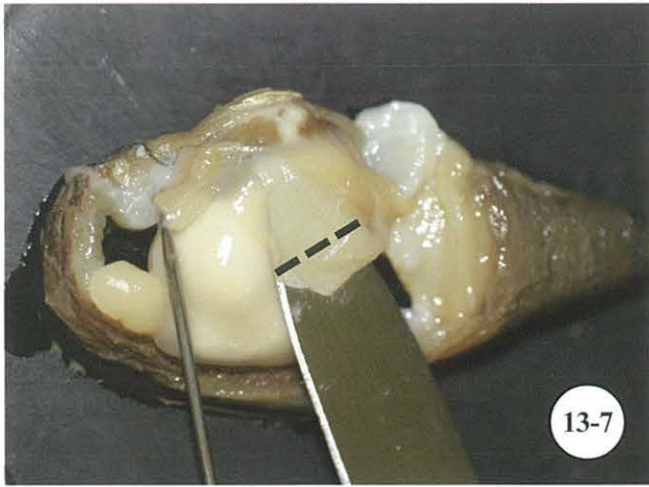- Farley, C.A., S.V. Otto, and C.L. Reinisch. 1986. New occurrence of epizootic sarcoma in Chesapeake Bay softshell clams, *Mya arenaria*. U.S. Fish Wildl. Serv., Fish. Bull. 84: 851-857.
- Farley, C.A., D.L. Plutschak, and R.F. Scott. 1991. Epizootiology and distribution of transmissible sarcoma in Maryland softshell clams, *Mya arenaria*, 1984-1988. Environ. Health Persp. 90: 35-41.
- Fries, C.R., S.B. Grau, and M.R. Tripp. 1991. Rickettsiae in the cytoplasm of gill epithelial cells of the soft-shelled clam, *Mya arenaria*. J. Invertebr. Pathol. 57: 443-445.
- Gauthier, J.D. and W.S. Fisher. 1990. Hemolymph assay for diagnosis of *Perkinsus marinus* in oysters *Crassostrea virginica*. J. Shellfish Res. 9: 367-371.
- Hanks, R.W. 1963. The soft-shell clam. U.S. Dept. Interior, Fish Wildl. Serv., Bur. Commer. Fish. Circ. 162, 16 pp.
- Harshbarger, J.C., S.C. Chang, and S.V. Otto. 1977. Chlamydiae (with phages), mycoplasmas, and rickettsiae in Chesapeake Bay bivalves. Science 196: 666-668.
- Harshbarger, J.C., S.V. Otto, and S.C. Chang. 1979. Proliferative disorders in *Crassostrea virginica* and *Mya arenaria* from the Chesapeake Bay and intranuclear virus-like inclusions in *Mya arenaria* with germinomas from a Maine oil spill site. Haliotis 8: 243-248.
- Hueper, W.C. 1963. Environmental carcinogenesis in man and animals. Ann. N.Y. Acad. Sci. 108: 963-1038.
- Huffman J.E. and M.R. Tripp. 1982. Cell types and hydrolytic enzymes of soft shell clam (*Mya arenaria*) hemocytes. J. Invertebr. Pathol. 40: 68-74.
- Kaneko, T., R.R. Colwell, and F. Hamons. 1975. Bacteriological studies of Wicomico River soft-shell clam (*Mya arenaria*) mortalities. Chesapeake Sci. 16: 3-13.
- Kennedy, V.S. and J.A. Mihursky. 1971. Upper temperature tolerances of some estuarine bivalves. Chesapeake Sci. 12: 193-204.
- Kofoed, C.A. and M. Bush. 1936. The life cycle of *Parachaenia myae* gen. nov., sp. nov., a ciliate parasitic in *Mya arenaria* Linn. from San Francisco Bay, California. Bull. Mus. R. Hist. Nat. Belgique 12: 1-15.
- Kotob, S.I., S.M. McLaughlin, P. van Berkum, and M. Faisal. 1999. Discrimination between two *Perkinsus* spp. isolated from the softshell clam, *Mya arenaria*, by sequence analysis of two internal transcribed spacer regions and the 5-8S ribosomal RNA gene. Parasitology 119: 363-368.
- La Peyre, J.F. 1996. Propagation and *in vitro* studies of *Perkinsus marinus*. J. Shellfish Res. 15: 89-101.
- La Peyre, J.F. and M. Faisal. 1995. Improved method for the initiation of continuous cultures of the oyster pathogen *Perkinsus marinus* (Apicomplexa). Trans. Am. Fish. Soc. 124: 144-146.
- La Peyre, J.F., M. Faisal, and E.M. Bureson. 1993. *In vitro* propagation of the protozoan *Perkinsus marinus*, a pathogen of the eastern oyster, *Crassostrea virginica*. J. Euk. Microbiol. 40: 304-310.
- Mackin, J.G. 1951. Histopathology of infection of *Crassostrea virginica* (Gmelin) by *Dermocystidium marinum* Mackin, Owen, and Collier. Bull. Mar. Sci. Gulf Caribb. 1: 72-87.
- Mackin, J.G. 1962. Oyster disease caused by *Dermocystidium marinum* and other microorganisms in Louisiana. Publ. Inst. Mar. Sci. Univ. Tex. 7: 132-229.
- McLaughlin, S.M. 1991. Transmission studies of sarcoma disease in the softshell clam, *Mya arenaria*. M.S. thesis, Univ. Maryland, College Park, MD. 82 pp.
- McLaughlin, S.M. and M. Faisal. 1998a. Histopathological alterations associated with *Perkinsus* spp. infection in the softshell clam *Mya arenaria*. Parasite 5: 263-271.
- McLaughlin, S.M. and M. Faisal. 1998b. *In vitro* propagation of two *Perkinsus* species from the soft-shell clam *Mya arenaria*. Parasite 5: 341-348.
- McLaughlin, S.M. and M. Faisal. 1999. A comparison of diagnostic assays for detection of *Perkinsus* spp. in the softshell clam *Mya arenaria*. Aquaculture 172: 197-204.
- McLaughlin, S.M. and M. Faisal. 2001. Pathogenesis of *Perkinsus* spp. in bivalve mollusks. Bull. Natl. Res. Inst. Aquacult., Suppl. 5: 111-117.
- McLaughlin, S.M., B.D. Tall, A. Shaheen, E.E. Elsayed, and M. Faisal. 2000. Zoosporulation of a new *Perkinsus* species isolated from the gills of the softshell clam *Mya arenaria*. Parasite 7: 115-122.

- NMFS (National Marine Fisheries Service). 2003. Fisheries of the United States, 2002. U.S. Dept. Commerce, NMFS Current Fishery Statistics No. 2002, 126 pp.
- Oprandy, J.J., P.W. Chang, A.D. Pronovost, K.R. Cooper, R.S. Brown, and V.J. Yates. 1981. Isolation of a viral agent causing hematopoietic neoplasia in the soft-shell clam, *Mya arenaria*. J. Invertebr. Pathol. 38: 45-51.
- Pauley, G.B. and T.C. Cheng. 1968. A tumor on the siphons of a soft-shell clam, *Mya arenaria*. J. Invertebr. Pathol. 11: 504-506.
- Ray, S.M. 1952. A culture technique for the diagnosis of infections with *Dermocystidium marinum*, Mackin, Owen, and Collier in oysters. Science 116: 360-361.
- Ray, S.M. 1966. A review of the culture method for detecting *Dermocystidium marinum*, with suggested modifications and precautions. Proc. Natl. Shellfish. Assoc. 54: 55-69.
- Rodriguez, F. and J.I. Navas. 1995. A comparison of gill and hemolymph assays for the thioglycollate diagnosis of *Perkinsus atlanticus* (Apicomplexa, Perkinsea) in clams, *Ruditapes decussatus* (L.) and *Ruditapes philippinarum* (Adams et Reeve). Aquaculture 132: 145-152.
- Tubiash, H.S. 1971. Soft-shell clam, *Mya arenaria*, a convenient laboratory animal for screening pathogens of bivalve mollusks. Appl. Microbiol. 22: 321-324.
- Tubiash, H.S., C.N. Shuster, Jr., and J.A. Couch. 1968. Anomalous siphons in two species of bivalve mollusks. Nautilus 81: 120-125.
- Uzmann, J.R. 1951. Record of the larval trematode *Himasthla quissetensis* (Miller and Northup, 1926) Stunkard, 1934 in the clam, *Mya arenaria*. J. Parasitol. 37: 327-328.
- Uzmann, J.R. 1952. *Cercaria myae* sp. nov., a fork-tailed larva from the marine bivalve, *Mya arenaria*. J. Parasitol. 38: 161-164.
- Williams, L.W. 1907. A list of the Rhode Island Copepoda, Phyllopoda, and Ostracoda, with new species of Copepoda. 37th Annu. Rep. Comm. Inland Fish. Rhode Island, Special Pap. No. 30: 69-79.
- Wright, R.R. 1885. On a parasitic copepod of the clam. Am. Nat. 19: 118-124.
- Yevich, P.P. and C.A. Barszcz. 1976. Gonadal and hematopoietic neoplasms in *Mya arenaria*. Mar. Fish Rev. 38(10): 42-43.
- Yevich, P.P. and C.A. Barszcz. 1977. Neoplasia in softshell clams (*Mya arenaria*) collected from oil-impacted areas. Ann. N.Y. Acad. Sci. 298: 409-426.



Diagnosis of sarcoma and rickettsia-like organisms in the softshell clam *Mya arenaria*.

Fig. 13-1. Sarcoma in gill tissue stained with MHE. **Fig. 13-2.** Rickettsia-like organisms (RLOs) in digestive gland tissue stained with MHE. **Fig. 13-3.** Suspensions of hemolymph showing normal amoeboid hemocytes (Hoffman modulation contrast). **Fig. 13-4.** Suspensions of sarcoma cells (Hoffman modulation contrast). **Fig. 13-5.** FPM-stained histocytology preparations of hemolymph showing normal amoeboid hemocytes. **Fig. 13-6.** FPM-stained histocytology preparations of sarcoma cells.



Diagnosis of *Perkinsus* spp. in the softshell clam *M. arenaria*.

Fig. 13-7. Locate and excise gill tissue to test for *Perkinsus* sp. **Fig. 13-8.** Locate and excise palps from body of clam. **Fig. 13-9.** Insert tissue into marked tube containing thioglycolate medium. **Fig. 13-10.** Tease tissue apart for examination of *Perkinsus* sp. **Fig. 13-11.** *Perkinsus* sp. stained with Lugol's in RFTM assay. **Fig. 13-12.** *Perkinsus* sp. in gill tissue stained with MHE.

CHAPTER 14. SPECIAL TECHNIQUES

A. Introduction

In the course of histological and disease studies, there are many special techniques that may be adapted, developed, or otherwise employed to aid in particular areas of studies. Special techniques include media for diagnosis of *Perkinsus marinus* which often are more reliable than histological diagnosis, methods to culture ciliates from oysters, and preparation of tissues for specialized electron microscopy (EM), including use of histological specimens for EM. In addition, methods are provided for decalcification of specimens for histology, preparation of very tiny organisms or cell suspension in agar for sectioning, and the transfer of tissue sections from broken slides. Use a fume hood and personal protective equipment (PPE) in the preparation of chemicals.

B. Detection of *Perkinsus* spp.

The thioglycolate test is used on many fresh shellfish specimens. The technique described below was devised by Ray (1966) and is routinely used for detection of *Perkinsus marinus* (Levine 1978). This method is effective in discerning both light and heavy infections, but does not distinguish among species of *Perkinsus*. Also see *P. marinus* detection by hemanalysis (p. 146).

Procedure:

- 1) Heat distilled water to a boil
- 2) In fume hood, stir in fluid thioglycolate medium¹ (containing dextrose) and NaCl (salt) until both are dissolved
- 3) Remove from heat and add chloramphenicol²
- 4) Dispense media into 250- or 500-ml culture bottles
- 5) Autoclave - 15 min at 15-17 lb pressure
- 6) Store in dark at room temp. until needed. Before use, dispense into 2-ml sterile disposable tubes
- 7) Add 2-3 drops of nystatin³ into each 2-ml tube

immediately before using. **Do not shake tubes**

- 8) With scissors, excise target tissue (rectal, gill, or palp) of each mollusk during initial necropsy and place in separately labeled tubes (Fig. 14-1); do not contaminate tubes with scissors.
- 9) In distilled water, rinse scissors and glass rod to avoid carryover contamination - 5-10 sec
- 10) Once samples have been processed, return tubes to dark for at least 72 h before examination
- 11) Prepare Lugol's iodine stock⁴ and working⁵ solutions
- 12) Remove tissue from tube with hooked end of a thin glass rod and place on correspondingly coded slide
- 13) Add 1 drop of Lugol's iodine working solution⁵ (Fig. 14-2). Tease tissue apart with probes (Fig. 14-3); clean probes with distilled water between each specimen
- 14) Add another drop of Lugol's iodine working solution⁵ and place a coverslip on slide (Fig. 14-4)
- 15) Examine slides (Fig. 14-5). Figure 14-6 shows a moderate infection (intensity level 5) of *P. marinus*

Results:

A positive infection of *P. marinus* will show symmetrically round blue-black to solid black spheres with the use of a dissecting or standard microscope.

Reagents:

¹Fluid thioglycolate medium (+ dextrose)

Thioglycolate medium.....	14.6 gm
NaCl	10.0 gm
Distilled water	485.0 ml

Note: Fluid thioglycolate medium available from Becton Dickinson^a cat. # 4311260.

²Chloramphenicol

Chloramphenicol	0.25 gm
Distilled water	10.0 ml

Note: Chloramphenicol available from Sigma^b cat. # C-0376.

³Nystatin
 Nystatin 500,000 usp units
 Sterile distilled water 125.0 ml
 Shake well before using; refrigerate unused portion.

Note: Nystatin available from Sigma^b cat. # N6261.

⁴Lugol's iodine stock solution
 Potassium iodide 6.0 gm
 Iodine 4.0 gm
 Distilled water 100.0 ml

⁵Lugol's iodine working solution
 Distilled water 30.0 ml
 Lugol's stock 15.0 ml

C. Ciliate Culture Preparation from Oysters

Sterile 24-well cell culture plates are recommended for oysters up to 15 mm in size. For larger oysters, use 6-well plates or large sterile culture containers.

Procedure:

- 1) Select a 12-oyster sample and correspondingly label culture container with histology code
- 2) Wash in tap water to remove excess debris or fouling organisms
- 3) Soak oysters in 50% solution of bleach - 2 min
- 4) Wash thoroughly in tap water - 6 times, or until bleach smell is not detected
- 5) Rinse in sterile synthetic seawater - 1 min
- 6) Place in sterile cell wells with 2 ml of sterile synthetic seawater - 24 h
- 7) Draw off 2 ml of liquid and fix in Bouin's/Davidson's fixative (see p. 60)
- 8) Immerse oysters in another set of sterile cell wells with sterile synthetic seawater - 24 h
- 9) Remove, discard, or process oysters for histology from cell wells; add 1 grain of rice to cell wells
- 10) Check wells next day for viable ciliates
- 11) Subculture to make clonal cultures

Note: Culture until a significant number of animals can be harvested onto a slide for fixation, staining, and identification.

D. Electron Microscopy (Dr. Joel Bodammer, NOAA, pers. commun. 1971)

In addition to light microscopy, some cells, tissues, or samples may be examined by electron microscopy (EM). Whole or partial specimens may be examined by scanning electron microscopy (SEM) or thin sections by transmission electron microscopy (TEM).

Preparation of marine invertebrate animals can be more difficult than mammalian tissues to yield good material for examination by EM. There are occasions when tissues fixed for histology may need to be further examined by EM or fresh samples may need to be processed. Many combinations of fixatives and buffers are available for the preservation of fine structure. Microwavable methods allow rapid fixation and processing of fresh samples (Giberson and Demaree 2001). We recommend different procedures for osmoregulating animals, such as fish and crustaceans, vs. non-osmoregulating animals, such as mollusks. We provide a selection of fixatives that have yielded good results over years of disease work on a broad range of marine animals. These fixatives include a combination of glutaraldehyde and phosphate buffer for preservation of tissues from osmoregulating species to a glutaraldehyde and seawater mix for non-osmoregulating species. Advantages of using a phosphate buffer include:

- Stock reagents are easily prepared and have a lengthy shelf life when refrigerated.
- Appropriate pH (usually 7.2-7.4) can be readily attained by careful volumetric combinations of stock reagents instead of by titration. A more alkaline pH (8.0-8.4) is often used for marine invertebrates and protists (Hayat 1989).
- Specimens can be stored in refrigerator for reasonable period of time in fixative-buffer solution without noticeable loss of buffer effectiveness provided a purified glutaraldehyde was used.

Many chemicals used in processing tissues for EM are hazardous. A fume hood and personal protective equipment (PPE) should be employed. Proper disposal of chemicals is necessary.

1. Preparation of Fresh Tissues for Transmission Electron Microscopy (TEM)

Temperature, pH, osmolarity, fixation time, and specific buffers are known to affect the quality of EM fixation.

Thickness of tissues should be limited to allow quick and uniform penetration of fixative. Investigators must decide between fixation at warmer temperatures that may allow a higher rate of autolysis but quicker penetration and more rapid fixation of tissues, and fixation at colder temperatures that reduces autolysis but also decreases fixative rate and penetration. We recommend fixatives made with Sorenson phosphate buffer and Spurr epoxy resin for embedding most specimens. The fixative should be slightly hyperosmotic since it will be diluted by the addition of tissues. It is better to have a slight shrinkage of tissue than swelling.

a. Osmoregulating species

Procedure:

- 1) In fume hood, prepare 30 ml of primary fixative¹ and refrigerate; prepare and refrigerate Sorensen phosphate buffer² and rinse³ solutions
- 2) Prepare small printed specimen identification labels to insert into embedding capsules
- 3) Perform necropsy to excise desired fresh tissue; keep immediate work area flooded with primary fixative
- 4) In enough fixative to cover tissue, mince tissue with one quick motion into smaller cubes not exceeding 0.5-1 cu mm
- 5) Place minced tissue in vial of primary fixative¹ - 1-1½ h at room temp., or minimum of 12 h at 0-4°C (for fixation at 0-4°C, fixative should be chilled to 4°C before use)
- 6) Rinse in Sorenson buffer solution³; buffer should be isotonic with that of primary fixative¹ - 4 changes, 5 min each at room temp., or 15 min each at 0-4°C
- 7) Postfix in 1% osmium tetroxide⁴ - 1 h at room temp., or 2-4 h at 0-4°C. **Osmium tetroxide fumes are hazardous to eyes, nose, and throat; use only in hood and wear proper PPE**
- 8) Rinse in filtered distilled water at room temp. to prevent formation of crystals - 3 changes, 10 min each
- 9) Prepare resin mixtures to be used in infiltration step. Since resins are hygroscopic, minimize time before use (allow at least 15 min mixing time)
- 10) Dehydrate at room temp. in graded series of ETOH, then propylene oxide (PO). **PO is hygroscopic and extremely flammable. Store in flammables refrigerator**
 - 50% ETOH - 10 min
 - 70% ETOH - 10 min
 - 95% ETOH - 2 changes, 5 min each

- 100% ETOH - 3 changes, 10 min each
 - PO - 4 changes, 5 min each
- 11) Using rotary mixer, infiltrate tissues in mixture of PO and embedding resin
 - PO/Spurr resin mixed 1:1 - 1 h
 - PO/Spurr resin mixed 1:2 - 1 h
 - PO/Spurr resin mixed 1:3 - 2 h
 - PO /Spurr resin mixed 1:3 - overnight
 - 100% Spurr resin - 2 changes, 2 h each
 - 12) Roll individual identification labels around pencil or similar object and place label into each embedding capsule with print facing outward
 - 13) Fill each capsule with Spurr resin
 - 14) Remove individual pieces of tissue from infiltration vial and place into embedding capsule; orient tissue as desired
 - 15) Polymerize in vacuum oven - 8-12 h at 60-65°C
 - 16) Allow to cool and remove capsule
 - 17) Trim and section block

Note: Above procedure for multiple pieces of tissue from same animal can be carried out in same screw-cap glass vial until placed into individual embedding capsule in step 14. To prevent PO from extracting moisture from atmosphere, aliquot into small brown bottles that are kept tightly sealed and refrigerate until use. If PO becomes moisture-laden, small holes will develop in polymerized embedding media. Alternative fixatives for EM include 1G4F (see p. 63) which can be used for histology if EM sections are needed.

Reagents:

- ¹Primary fixative
 - 0.2 M Sorensen phosphate buffer solution, pH 7.4 15.0 ml
 - 8% ultrapure EM grade glutaraldehyde 7.5 ml
 - Distilled water 7.5 ml

Note: Yields a 2% glutaraldehyde fixative with pH of 7.4. Purchase glutaraldehyde in 10-ml ampoules.

- ²Sorensen phosphate buffer solution (Hayat 1989)
 - Solution A:
 - Sodium phosphate, dibasic (Na₂HPO₄·2H₂O) 11.876 gm
 - Distilled water to make 1000.0 ml
 - Solution B:
 - Potassium phosphate, monobasic (KH₂PO₄) 9.08 gm
 - Distilled water to make 1000.0 ml

From chart below, obtain desired pH by adding solution B to the given amount of solution A to make 100 ml:

Solution A (ml)	Final pH of buffer
0.6	4.9
2.3	5.3
4.9	5.6
12.1	6.0
26.4	6.4
49.2	6.8
61.2	7.0
67.0	7.1
72.6	7.2
77.7	7.3
81.8	7.4
85.2	7.5
88.5	7.6
93.6	7.8
96.9	8.0

³Sorensen buffer rinse solution

0.2 M Sorensen phosphate buffer, pH 7.4 15.0 ml
 Distilled water 15.0 ml

⁴1% osmium tetroxide

2% aqueous solution of osmium mixed 1:1 with Sorensen buffer just prior to use

Note: For non-osmoregulating species, mix 2% aqueous solution of osmium tetroxide 1:1 with double strength seawater prior to use.

b. Non-osmoregulating species

Procedure:

Follow procedure as above for osmoregulating species, (see p. 181) with the following exceptions in steps 1-7: (1) For primary fix¹, mix glutaraldehyde with *artificial seawater* of same salinity and pH in which specimens resided; and (2) substitute *artificial seawater* for Sorensen buffer and buffer rinses. Maintain osmolarity of fixative and rinses at or slightly hyperosmotic to that of seawater used.

Reagents:

¹Primary fixative

50% ultrapure EM grade glutaraldehyde 1.2 ml
 Artificial ambient seawater (see p. 144) 28.8 ml
 Adjust pH to 7.4-8.4 using 1N NaOH (see p. 191)

2. Preparation of Hemolymph or Cell Suspensions for TEM

Recommended procedure to provide a block of cells in pellet form for TEM examination.

Procedure:

- 1) Mollusks can be bled at room temp., but crustaceans should be chilled in refrigerator before bleeding
- 2) In fume hood, prepare fixative to a final concentration of 4% glutaraldehyde in 0.1 M Sorensen phosphate buffer rinse solution (see pp. 181-182), buffered to physiological pH (7.4-8.4) of tissues at room temp., and chill to 4°C
- 3) Extract hemolymph from animals into a 5-cc syringe containing 3 cc of chilled fixative. Allow to fix in icebath - 20 min
- 4) Dispense hemolymph/fixative mixture into 1.5-ml clear PO-safe centrifuge tubes and centrifuge at 3300 rpm - approx. 2 min
- 5) Remove supernatant, replace with fresh cooled fixative, and disperse pellet into new fixative
- 6) Refrigerate and allow fixation to continue - 6-12 h
- 7) To remove fixative, rinse sample - 4 changes, 5 min each, with 0.1 M Sorensen phosphate buffer solution chilled to 4°C. With exception of last rinse, disperse pellet with each change of buffer
- 8) Pellet may be stored overnight in 0.1 M Sorensen phosphate buffer rinse solution at 4°C, or continue with embedding
- 9) Combine equal volumes of 2% osmium tetroxide with 0.2 M Sorensen phosphate buffer solution (see pp. 181-182). **Osmium tetroxide fumes are hazardous to eyes, nose, and throat; use only in hood and wear proper PPE**
- 10) Dispense 1.0 ml into each microcentrifuge tube; resuspend pellet and fix at room temp. - 1 h
- 11) Centrifuge as above and properly discard supernatant
- 12) Dehydrate at room temp. in following graded series of ETOH, then propylene oxide (PO). **PO is hygroscopic and extremely flammable. Store in flammables refrigerator**
 - 35% ETOH, resuspend pellet - 3 min; centrifuge as above and discard supernatant
 - 50% ETOH, resuspend pellet - 3 min; centrifuge as above and discard supernatant
 - 80% ETOH, resuspend pellet - 3 min; centrifuge as above and discard supernatant
 - 95% ETOH, resuspend pellet - 3 min; centrifuge as above and discard supernatant

100% ETOH, resuspend pellet, cap tube - 4 changes, 5 min each; centrifuge as above and discard supernatant. If PO-safe tubes have not been used in processing thus far, leave pellet suspended after third ETOH rinse and transfer to PO-safe microcentrifuge tube to finish processing

PO - 4 changes, 5 min each; centrifuge as above and discard supernatant

- 13) Using rotary mixer, infiltrate tissues in mixture of PO and Spurr embedding resin. Centrifuge at end of each time frame and discard supernatant
PO/resin mixed 1:1 - 1 h
PO/resin mixed 1:3 - 2 h
100% resin - 2 changes, 2 h each
- 14) Before last change of 100% resin, roll individual identification labels around pencil or similar object and place label with print facing outward into each embedding capsule
- 15) Polymerize in vacuum oven at 60-65°C - minimum of 72 h; allow to cool
- 16) If embedment in a flat mold is preferred, remove plastic tube and cut away resin behind pellet. Reembed in flat mold; do not touch polymerized block that is to be reembedded (oil from hands creates a film that prevents the development of a strong bond between reembedded block and new resin)
- 17) Trim and section

3. Preparation of Paraffin-embedded Tissues for TEM

When examination of slide by light microscopy reveals a parasite or an unknown anomaly, the matching tissue from the paraffin block may be processed for TEM as follows:

Procedure:

- 1) Cut 1-mm cubes of selected tissue from paraffin block
- 2) In fume hood, place cubes into xylene and cover - overnight
- 3) Xylene - 30 min
- 4) 100% ETOH - 2 changes, 15 min each
- 5) 95% ETOH - 15 min
- 6) 70% ETOH - 15 min
- 7) Fix in glutaraldehyde primary fixative (see p. 181) - 1 h
- 8) Phosphate buffer rinse solution (see p. 182) - 2 changes, 15 min each

- 9) Postfix in 1% osmium tetroxide (see p. 182) - 30 min. **Osmium tetroxide fumes are hazardous to eyes, nose, and throat; use only in hood and wear proper PPE**
- 10) Infiltrate and embed as in *Osmoregulating species* (pp. 181-182)

Note: Thick sections of tissue from paraffin block may also be cut by microtome and processed as above. Procedure should be carried out at room temp.; cover between steps.

4. Transfer of Tissues from Histological Slides for TEM (Phil Rutledge, University of Maryland Baltimore County, Baltimore, MD, pers. commun. 1991)

Once an area on a slide has been identified for further examination, that specific area can be transferred, postfixed, and prepared for TEM as follows:

Procedure:

- 1) Cut conical tip from embedding capsule. Remove cap and place onto uncut end of capsule. Fill with resin of choice, allow to harden, and remove block from capsule
- 2) With etching or permanent pen, mark area of slide to be used in transfer of tissue
- 3) Remove coverslip (see *Transfer from Broken Slides or Serial Sections*, pp. 184-185)
- 4) Mix small amount of embedding resin used in step 1
- 5) Place 1-2 drops onto selected area of tissue
- 6) Place block onto embedding medium on slide and allow to completely cure
- 7) Place cured slide on dry ice or in a -80°C freezer - 1-3 min. Gently "pop" block from slide to remove it with attached tissue

Note: It is important that block face is level and mounted perpendicular to slide since there may be only 5-6 µm of tissue available to section. Cut thin sections in normal manner.

5. Scanning Electron Microscopy (SEM) Procedure (Small and Mangel 1982)

Morphological detail not visible with the light microscope can be accomplished in backscatter mode by SEM. SEM is effectively used as a tool to further magnify and identify

many metal-stained structures that are visible after protargol staining. Ciliates in oysters have been identified by this process (Cooper 1982).

Procedure:

- 1) In fume hood, stain whole specimens or tissue sections with protargol (see p. 118)
- 2) Examine for clear results of stained kinetics and mark area of interest with indelible permanent pen on underside of slide (cilia and paired kinetosomes are aligned in rows termed kinetics)
- 3) Soak slide in xylene to remove coverslip
- 4) Air dry
- 5) Cut section of glass slide with care
- 6) Remove adhesive from double-sided sticky tape by rubbing with Q-tip dipped in acetone
- 7) Mount cut portion of slide on EM stub with solubilized adhesive from Q-tip; edges of slide should not overhang stub. To reduce moisture buildup, keep in airtight container until viewed
- 8) Lightly coat tissue specimens on stubs with aluminum (30 nm) in vacuum evaporator
- 9) Examine by SEM

Note: If possible, take pictures of specimens by light microscopy to confirm area of interest in tissue sections. This will facilitate locating the same area on the SEM image.

E. Decalcification

Decalcification is not often utilized with molluscan tissues. In special circumstances, for example when processing unshucked juvenile bivalves, the versenate method of decalcification yields excellent results. Versenate is a proprietary term for disodium ethylenediaminetetraacetate (EDTA). Although other decalcifiers are commercially available, this chelating method of decalcification is gradual and does not damage internal animal tissues.

Different time periods are necessary for decalcifying larvae, depending on species and sizes. Pearls found in oysters, mussels, and clams should be removed prior to embedment unless the investigator specifically requires their presence. If pearls or larval fish with bones are requested by the investigator, they can be decalcified by the versenate method.

Procedure (Birge and Imhoff 1952):

- 1) Use fixative of choice

- 2) Wash well in running water - 5 min-4 hr (depending on fixative used and size of tissue)
- 3) Place tissue in 10% versenate¹ until decalcification is complete; check daily
- 4) Wash well in running water - ½ - 1 h (depending on size of tissue)
- 5) Place in 70% ETOH until ready to process

Reagents:

¹10% versenate

Versenate 10.0 gm
Distilled water (pH 5.5-6.5) 100.0 ml

Warning: Versenate may remove iron and other metals in the process of decalcification, according to Drury and Wallington (1967).

Note: For the most efficient use of versenate as a decalcifier, change tissues to a fresh solution every 1-2 days. We have had success using versenate on bones found in fish tissue. According to Birge and Imhoff (1952), “. . . specimens may be left in the versenate solution for as long as 14 days without noticeable effect on the staining qualities of the cells.”

F. Transfer of Paraffin-embedded Tissues

Circumstances exist where the transfer of tissues may be desirable. Occasionally, slides become broken in the course of work or specific pathogens observed in tissues may need to be embedded directly from an existing slide for EM or restained with a special stain. The following techniques describe methods to accomplish such needs.

1. Transfer from Broken Slides or Serial Sections (Coolidge and Howard 1979)

Recommended for transfer of paraffin-embedded tissues, serial sections, or broken slides onto a new slide for light microscopy.

Procedure:

- 1) In fume hood, place tissue section, serial section, or broken slide into shallow petri dish, and add xylene to cover slide (Fig. 14-7)
- 2) Soak until all pieces of coverslip can be easily removed - 5 min-24 h (depending on age of slide)
- 3) While slide or broken pieces are still moist with

- xylene, cover entire slide with Rapid Mount[®] or other liquid plastic coverslip medium
- 4) Dry overnight at room temp., or in 60°C oven - 2 h (plastic will be hard)
 - 5) Cover slide with paper towel and soak in tap water - 1-2 h (Fig. 14-8)
 - 6) Cut around edge of slide with razor blade and carefully peel acrylic resin from slide (Fig. 14-9)
 - 7) Trim complete section, or selected sections from serial ribbon, and place on albuminized slides (Fig. 14-10). Cover plastic film with damp paper towel. Place clean slide on top to hold in place
 - 8) Dry at room temp., or place in 37°C oven overnight
 - 9) Remove towel and soak slide in xylene until new plastic is removed (Fig. 14-11)
 - 10) Coverslip (Fig. 14-12)

Note: Rapid Mount (one of many liquid coverslips) available from Histology Control Systems[®]. This does not work well with tissues mounted on poly-L-lysine or aminoalkylsilane slide adhesives.

2. Transfer from Paraffin to Plastic (D. Howard and J. Wade, NOAA, Oxford, MD, pers. commun. 1976)

A modification of the tissue transfer process from *Animal Histology Procedures of the Pathological Technology Section of the National Cancer Institute* (Coolidge and Howard 1979) is used to reembed a cut and stained section of tissue from paraffin to resin without loss of orientation.

Procedure:

- 1) At room temp., begin cutting a practice block at 30-50 μm of same type of tissue as specimen. The goal is to cut evenly through tissue without breaking section
- 2) Align block of interest in chuck of microtome. Cut two 6- μm sections before changing cutting gauge to desired thickness (30-50 μm). The thicker the tissue can be cut without damage, the greater the prospect of finding the desired areas
- 3) Moisten block and cut through whole face with even motion. Section will generally come off microtome knife in a thick roll
- 4) With aid of brushes, gently and carefully raise tissue roll to an albuminized slide moistened with a small pool of distilled water
- 5) Drain excess water and place slide on warming tray at 42°C
- 6) Unroll tissue section; gently flatten onto slide and

- place in oven at 42°C
- 7) Rechill block which is still in the chuck with a piece of ice and cut another 6- μm slide section
- 8) Once slides are thoroughly dry, deparaffinize and stain the 6- μm sections in Harris' hematoxylin and eosin (HHE)
- 9) View with microscope to confirm presence of desired area.
- 10) Proceed with thick section. Deparaffinize and stain with hematoxylin (1 min), eosin (30 sec), and mount with Rapid Mount[®] synthetic liquid coverglass
- 11) Dry overnight at room temp., or in slide oven at 42°C until plastic is hard; check under microscope
- 12) Cover slide with paper towel and soak with tap water (about 2 h) until plastic is pliable and can be gently peeled away from slide (spatula may be used for thicker sections to keep from damaging tissue)
- 13) Compare plastic section with 6- μm slides where area of interest has been located and marked
- 14) Cut as indicated in marked 6- μm sections; use a specific shape (e.g., triangle or truncate pyramid) to ensure proper orientation of tissue
- 15) In fume hood, place tissue in porcelain spot plate or small shallow glass dish. Add several changes of xylene until tissue is free of all Rapid Mount[®]. Pipet new xylene on and off, trying not to disorient tissue
- 16) Follow steps 10 through 16 on page 181, including *Note*

G. Agar-enrobing for Embedment and Sectioning (Presnell and Schreiber 1997)

Recommended as a supporting matrix around cells and small organisms to allow easy manipulation while processing for light microscopy.

Procedure:

- 1) Collect cells, ciliates, or other material in conical-bottom centrifuge tubes and add fixative (see Chapter 5) - 1 h to overnight. Agitate occasionally
- 2) Concentrate cells by centrifuging (settings may vary depending on cell type and size). Decant and add water, seawater, buffer, or alcohol, depending on requirement of fixative
- 3) Resuspend pellet, rinse, mix, and centrifuge. Decant supernatant. Repeat 2-3 times to remove fixative
- 4) Dispense small amount of melted agar¹ into Eppendorf pipet tip sealed at one end. Chill until hardened and set aside

- 5) Resuspend cells from step 3 in warm agar and mix well
- 6) Add eosin Y² to agar mixture. Pipet onto hardened agar plug and chill
- 7) Cut Eppendorf tip and flush water down side of agar plug to dislodge
- 8) Dehydrate, clear, and embed agar plug. Eosin will remain to show where cells are located when sectioning

Reagents:

¹LGT agarose
 LGT agarose 1.5 gm
 Ambient seawater 100.0 ml
 Boil seawater to dissolve agarose.

²Eosin Y
 Eosin Y 1.0 gm
 Distilled water 75.0 ml
 100% ETOH 25.0 ml
 Just before use, add concentrated
 HCl 1 drop/200.0 ml

Handle HCl with care.

Note: If precipitate forms and does not disappear with stirring, eosin may stain too orange.

H. Footnotes

- ^aBecton, Dickinson Diagnostic Systems, 7 Loveton Circle, Sparks, MD 21152. (800) 675-0908. www.bd.com
^bSigma, P.O. Box 14508, St. Louis, MO 63178-9916. (800) 325-3010. www.sigma-aldrich.com.
^cHistology Control Systems, P.O. Box 142, Glen Head, NY 11545. (800) 253-2768. www.histologycontrolsystems.homestead.com

I. References

Birge, E.A. and C.E. Imhoff. 1952. Versenate as a decalcifying agent for bone. *Am. J. Clin. Pathol.* 22: 192-193.

Coolidge, B.J. and R.M. Howard. 1979. *Animal Histology Procedures of the Pathological Technology Section of the National Cancer Institute.* 2d ed. NIH Publ. No. 80-275, National Institutes of Health, Bethesda, MD. 209 p.

Cooper, S.P. 1982. The description of a new species of rhynchodid ciliate and its occurrence in gill tissue of the American oyster *Crassostrea virginica*. Master's thesis, Univ. Maryland, College Park. 63 pp.

Drury, R.A.B. and E.A. Wallington. 1967. *Carleton's Histological Technique.* 4th ed. Oxford Univ. Press, New York. 432 p.

Giberson, R.T. and R.S. Demaree, Jr., Editors. 2001. *Microwave Techniques and Protocols.* Humana Press, Totowa, NJ. 300 p.

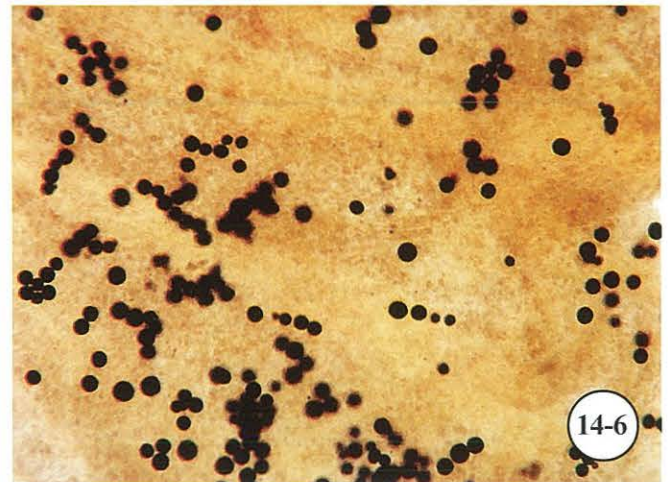

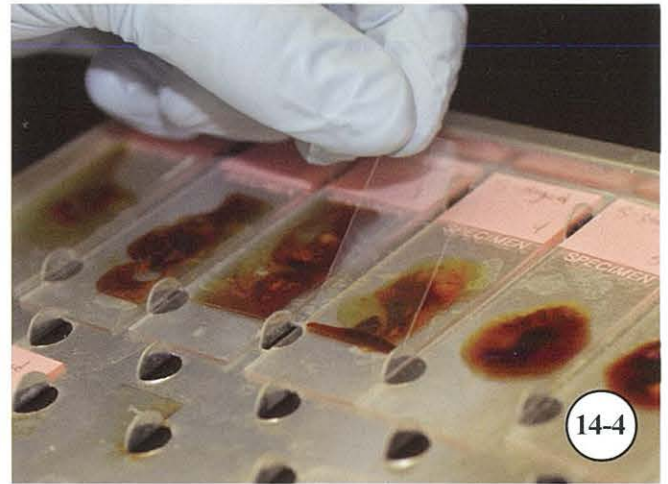

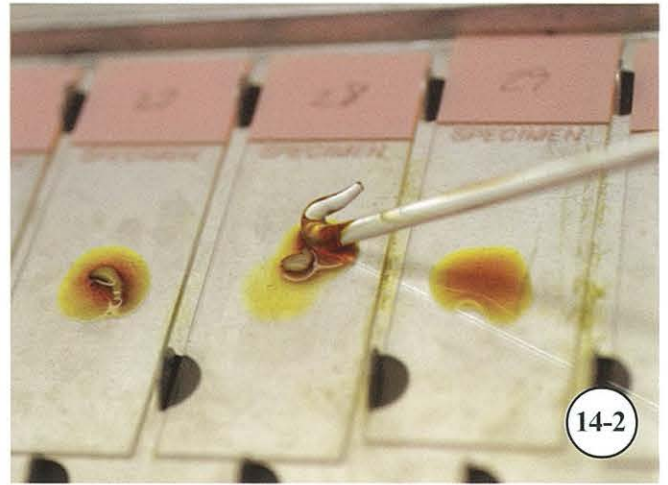

Hayat, M.A. 1989. *Principles and Techniques of Electron Microscopy.* 3d ed. CRC Press, Boca Raton, FL. 469 p.

Levine, N.D. 1978. *Perkinsus* gen. n. and other new taxa in the protozoan phylum Apicomplexa. *J. Parasitol.* 64: 549.

Presnell, J.K. and M.P. Schreiber. 1997. *Humason's Animal Tissue Techniques.* 5th ed. Johns Hopkins Univ. Press, Baltimore, MD. 572 p.

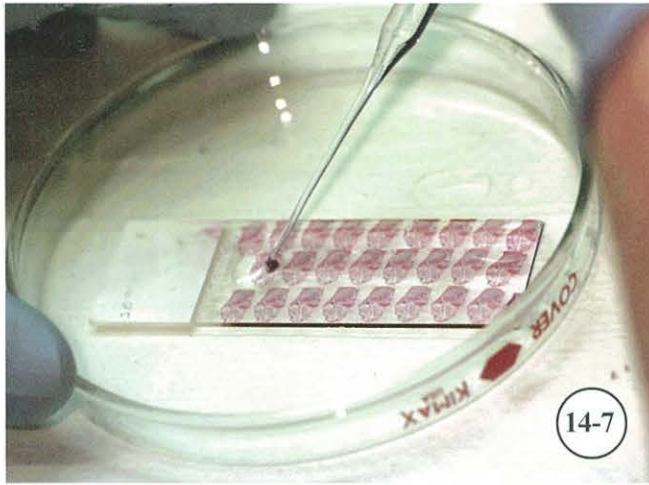
Ray, S.M. 1966. A review of the culture method for detecting *Dermocystidium marinum*, with suggested modifications and precautions. *Proc. Natl. Shellfish. Assoc.* 54: 55-69.

Small, E.B. and T. Mangel. 1982. The ultrastructure of specimens of *Paramecium multimicronucleatum* impregnated with silver by Fernandez-Galiano method. *J. Protozool.* 29: 627-634.

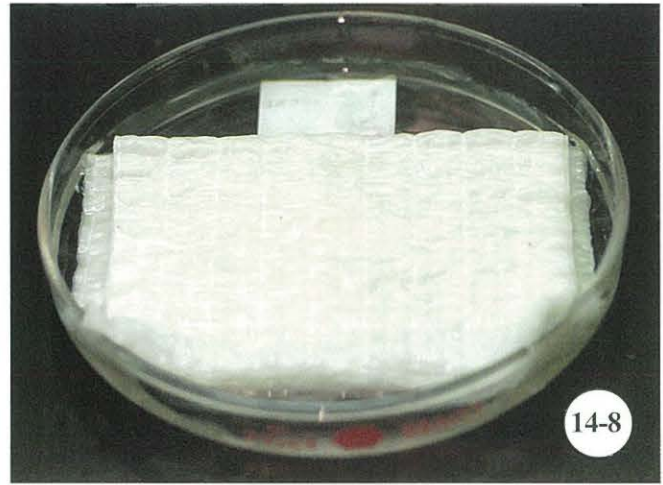


Detection of *Perkinsus marinus* (Dermo) in rectal tissue.


Figure 14-1. Place excised rectal tissue into tube containing thioglycolate media for 3-7 days' incubation. **Figure 14-2.** Using a hooked glass rod, place rectal tissue onto slide containing 1 drop of Lugol's iodine solution. **Figure 14-3.** Tease apart rectal tissue to make thin layer of tissue and expose *Perkinsus* cells. **Figure 14-4.** Add 1-2 drops of Lugol's iodine solution and coverslip. **Figure 14-5.** Prepared tissues on glass slides ready for examination. **Figure 14-6.** Moderate infection (intensity level 5) of *P. marinus*.



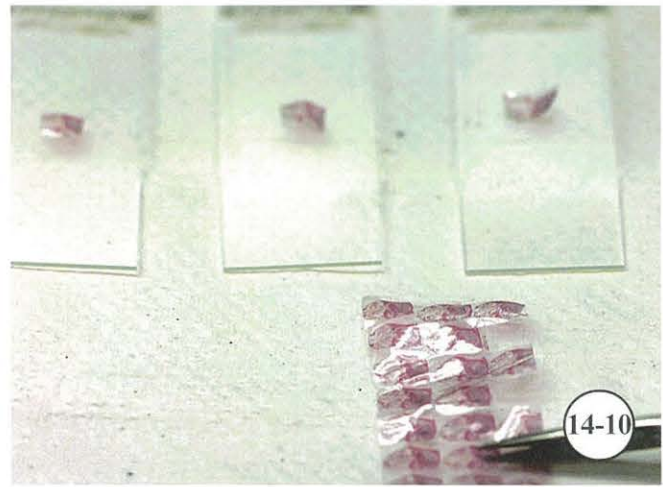
14-7



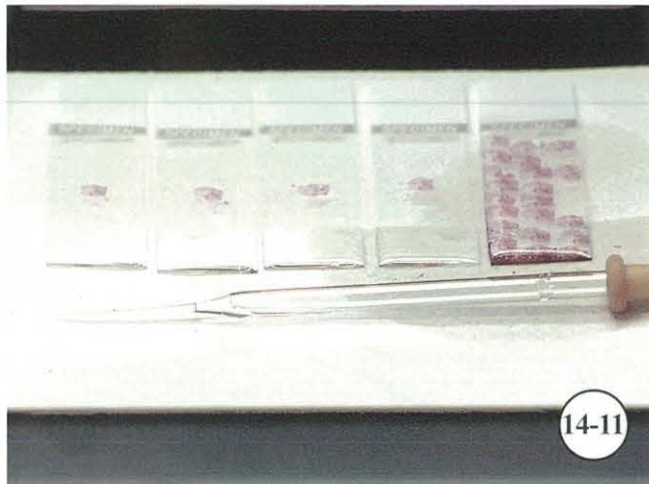
14-8




14-9



14-10



14-11



14-12

Transfer of paraffin-embedded tissue, serial sections, or broken slides onto new slide.

Figure 14-7. Place broken slide into shallow petri dish, add xylene to cover slide, and soak until coverslip pieces can be easily removed. While tissue is still wet with xylene, pipet liquid coverslip medium onto entire slide and dry overnight at room temp., or 2 h in 60°C oven. **Figure 14-8.** Cover slide with paper towel and soak in tap water 1-2 h. **Figure 14-9.** Carefully peel acrylic resin and tissue from slide. **Figure 14-10.** Trim desired tissue from plastic with scissors and place section(s) onto albuminized slide(s). **Figure 14-11.** Cover section with xylene until plastic is completely dissolved. **Figure 14-12.** Coverslip new slide.

APPENDIX

U.S./METRIC CONVERSIONS^a

To convert:	Multiply by:	To obtain:
celsius (degrees)	$(^{\circ}\text{C} \times 9/5) + 32$	fahrenheit (degrees)
celsius (degrees)	$^{\circ}\text{C} + 273.18$	kelvin (degrees)
centimeters	3.281×10^{-2}	feet
centimeters	3.937×10^{-1}	inches
cubic centimeters	6.102×10^{-2}	cubic inches
cubic inches	1.639×10^1	cubic centimeters
fahrenheit (degrees)	$(^{\circ}\text{F} - 32) \times 5/9$	celsius (degrees)
feet	3.048×10^1	centimeters
feet	3.048×10^{-4}	kilometers
feet	3.048×10^{-1}	meters
feet	3.048×10^2	millimeters
gallons	3.785×10^3	cubic centimeters
gallons	3.785	liters
grams	3.527×10^{-2}	ounces (avdp.)
grams	3.215×10^{-2}	ounces (troy)
grams	2.205×10^{-3}	pounds
inches	2.540	centimeters
inches	2.54×10^1	millimeters
kilograms	2.2046	pounds
kilograms	3.5274×10^1	ounces (avdp.)
liters	1.0×10^3	cubic centimeters
liters	1.057	quarts (US liquid)
meters	3.281	feet
meters	3.937×10^1	inches
miles (nautical)	1.852	kilometers
miles (nautical)	1.852×10^3	meters
millimeters	3.281×10^{-3}	feet
millimeters	3.937×10^{-2}	inches
ounces (avdp.)	2.83495×10^1	grams
pints (US liquid)	4.732×10^2	cubic centimeters
pounds	4.5359×10^2	grams
quarts (US liquid)	9.464×10^2	cubic centimeters
quarts (US liquid)	9.464×10^{-1}	liters
temp. ($^{\circ}\text{C}$) +17.78	1.8	temp. ($^{\circ}\text{F}$)
temp. ($^{\circ}\text{F}$) -32°	5/9	temp. ($^{\circ}\text{C}$)

^aFisher Scientific, 3970 Johns Creek Court, Suwanee, GA 30024. (800) 766-7000. www.fishersci.com

LABORATORY CALCULATIONS (Prophet et al. 1992)

A. Introduction

An important role of a histology technician is to accurately prepare and dilute normal (N) and molar (M) solutions, convert chemical recipes, and ensure fixatives and stains contain specified amounts of chemicals.

B. Percent Solutions

Volume/Volume:

Percent solutions are prepared based on parts per 100 ml of the liquid.

$$1\% = 1 \text{ part per } 100 \text{ ml} = 0.01$$

To prepare 200 ml of a 1% acetic acid solution, convert the 1% to a decimal value as illustrated above. Multiply the final volume required (200 ml) by the decimal value to obtain the amount of acid needed to make the diluted solution:

$$\begin{array}{r} 200 \text{ ml} = \text{final volume} \\ \times 0.01 = \text{required percentage} \\ \hline 2.00 \text{ ml} = \text{amount of concentrated acid} \end{array}$$

Add 2 ml of concentrated acetic acid to 198 ml of distilled water to obtain 200 ml of a 1% solution.

Weight/Volume:

For dry, crystalline, or powdered chemicals, percentages are based on weight to volume. A 1% solution is 1 gm of the chemical per 100 ml of solution and is calculated as described above.

To prepare 100 ml of a 5% borax solution:

$$\begin{array}{r} 100 \text{ ml} = \text{final volume} \\ \times 0.05 = \text{required percentage} \\ \hline 5.00 \text{ gm} = \text{amount of borax} \end{array}$$

Weigh 5 gm of borax and add distilled water in a quantity sufficient to bring the final volume to 100 ml.

Dilutions:

The formula is: $V_1 \times C_1 = V_2 \times C_2$

where V_1 is the unknown quantity, C_1 is the concentration of the stock solution, V_2 is the final volume required, and C_2 is the diluted concentration to prepare.

To prepare 300 ml of 70% alcohol from a 95% stock alcohol solution:

$$\begin{array}{r} V_1 \times C_1 = V_2 \times C_2 \\ V_1 \times 95 = 300 \times 70 \\ V_1 \times 95 = 21000 \\ \hline V_1 = 21000/95 \\ \hline V_1 = 221 \text{ ml (rounded)} \end{array}$$

To 221 ml of 95% alcohol, add 79 ml of distilled water to obtain 300 ml of a 70% alcohol solution.

Be sure that the units used for each volume and for each concentration are the same on both sides of the equation.

Dilution as Ratios:

Some formulas state dilutions as a ratio such as 1:2 or 1:4.

A 1:4 ratio may be expressed as 1 part in a total of 4 parts. To dilute a stock solution for a 1:4 working solution:

$$\begin{array}{r} \text{Required volume} = 100 \text{ ml} \\ 100 \text{ ml}/4 = 25 \text{ ml (each of the 4 parts is 25 ml)} \\ 1 \text{ part stock solution} = 25 \text{ ml} \\ + 3 \text{ parts distilled water} = 75 \text{ ml} \\ \hline 4 \text{ parts (required volume)} = 100 \text{ ml} \end{array}$$

C. Molar Solutions

Molar solutions prepared from solid materials are defined as 1 gm molecular weight of a substance dissolved in 1 L of a liquid.

To prepare 500 ml of a 1.5 M sodium hydroxide solution, perform the following calculations:

1. Find the molecular weight of sodium hydroxide (NaOH)

From the periodic chart, add atomic weights:

sodium (Na) = 22.99

oxygen (O) = 16.00

hydrogen (H) = 1.01

molecular weight = 40.00

A 1-M solution of NaOH contains 40 gm of NaOH per 1L of water.

2. Gram molecular weight x molarity x volume in liters

$$40 \text{ gm} \times 1.5 \text{ M} \times 0.5 \text{ L} = 30 \text{ gm}$$

Slowly add 30 gm of NaOH to enough water to bring the final solution volume to 500 ml.

Dilution Factors for Liquids:

In addition to the above formula, calculations for molarity of liquids such as some acids and bases require the use of a dilution factor based on the actual concentration of the substance and the specific gravity of the substance.

To prepare 200 ml of 0.5 M hydrochloric acid, perform the following calculations:

HCl has a gram molecular weight of 36.46

1) $36.5 \text{ gm} \times 0.5 \text{ M} \times 0.2 \text{ L} = 3.65 \text{ gm}$

Each milliliter of hydrochloric acid weighs 1.19 gm (specific gravity), and pure hydrochloric acid accounts for 37% of the 1.19 gm (concentration as provided by the manufacturer). To find the dilution factor:

2) Specific gravity x concentration (as a decimal value)

$$1.19 \times 0.37 = 0.44$$

$$3.65 \text{ gm} / 0.44 = 8.3 \text{ ml}$$

To 191.7 ml of water, slowly add 8.3 ml of HCl to obtain 200 ml of a 0.5 M solution.

Note: Handle HCl with care. As a safety precaution, always add acid slowly to the water. Never add water to concentrated acids.

D. Normal Solutions

A normal solution is defined as 1 gm equivalent weight of solute dissolved in 1 L of solution (total oxidation number of cations or anions).

Prepare 3 L of a 0.5 normal solution of sulfuric acid (H_2SO_4)

molecular weight of $\text{H}_2\text{SO}_4 = 98.08$

specific gravity of $\text{H}_2\text{SO}_4 = 1.84$

% of pure of $\text{H}_2\text{SO}_4/\text{gm} = 98\%$

of replaceable hydrogens in $\text{H}_2\text{SO}_4 = 2$

Gram equivalent weight = molecular weight/# of replaceable hydrogens

$$98/2 = 49 \text{ gm}$$

Required substance weight = gram equivalent weight x normality (expressed as a decimal) x volume (expressed in liters)

$$49 \text{ gm} \times 0.5 \text{ normal} \times 3 \text{ L} = 73.5 \text{ gm required}$$

This is an acid; thus the dilution factor must be used
Dilution factor = specific gravity x concentration of pure acid

$$1.84 \times 0.98 = 1.8 \text{ gm}$$

There are 1.8 gm of pure acid in each milliliter of stock acid solution

Grams required/dilution factor = volume required.

$$73.5 \text{ gm} / 1.8 \text{ gm/ml} = 40.8 \text{ ml}$$

Slowly add 40.8 ml of concentrated H_2SO_4 to 2959.2 ml of water to obtain 3 L of a 0.5 normal acid solution.

E. Reference

Prophet, E.B., B. Mills, J.B. Arrington, and L.H. Sobin, Editors. 1992. Armed Forces Institute of Pathology - Laboratory Methods in Histotechnology. American Registry of Pathology, AFIP, Washington, DC. 279 p.

RECORDKEEPING

A. Introduction

An equally important role of a histology technician is to accurately record all tissues received, administer a code, and ensure the code remains with the specimen throughout processing, slide preparation, and block storage. Data forms shown in the Appendix cover a wide range of information. Each form follows the sample through a specific step from arrival and code designation through the final histological examination. A summary of all information is statistically presented on the *Molluscan Pathology Report* (p. 196) and entered into a computer database for permanent record.

B. Filing and Slide Storage

All samples are kept in permanent files. Once the sample is coded, either in the field or after arrival, it is recorded with its historical data. Investigators are responsible for keeping their own records. The information provided is then stored in a central location. It is recorded in a master file and entered into a database containing the source and code number; specimen or identification type; dates of arrival, fixation, embedment, sectioning, and staining; and

identity of requestor. A ledger is kept to record daily work activities performed in the laboratory. Maintaining up-to-date records is imperative.

Once permanent slides have been completed and issued to the requestor, tissue blocks are filed consecutively in trays and stored. A record book or computer program can be used to identify the location of all blocks in storage for retrieval by code numbers. The block storage area is analogous to a library. Study projects with consecutive code numbers are filed together. Samples from similar geographic areas are also consolidated when possible. A record guide specifies block location by aisle, row, and cabinet. If study blocks have been removed, this is so indicated, and their current location is recorded. This system enables us to keep an orderly collection of blocks which is of value for retrieval and future retrospective study.

Our block archives, which date back to the early 1960s, are computerized, enabling investigators to recall historical information and examine original blocks to compare with current samples.

FIELD DATA ON SHELLFISH SAMPLES

NOAA/NOS, Oxford, MD Date sample collected _____

Comparative Invertebrate Pathology Date sample received _____

Purpose of sample _____ Species _____

Source state: _____ No. specimens _____

Estuary _____ Bar _____

Code designation _____ Water depth _____ ft

Surface water temp. _____ °C Surface salinity _____ ppt

Bottom water temp. _____ °C Bottom salinity _____ ppt

Nature of bottom: hard, medium, soft, sandy, mud, shell,
other _____

Additional comments on field collection and condition of specimens:

GROSS EXAMINATION OF INDIVIDUAL OYSTERS IN LABORATORY

BY _____

Date _____ Time _____ oysters examined and fixed

Fixative _____

GROSS MACROSCOPIC EXAM

CODE:	LENGTH in MM	CONDITION	POLYDORA	CLONIA	MANTLE RECESSION	RECOVERY	DRILL HOLES / CASES	SHELL / MUD BLISTERS	PERIOSTRACUM PRESENT	MALADIE DU PIED / PEARL	PUSTULES / CONCHOLIN DEPOSIT	MUSCLE DETACHED / PINNACLES	BARNACLES / MUSSELS	STABBED / DRY	PALE DIGESTIVE GLAND	ABNORMAL COLOR / TUMOR	ABSCESS in MUSCLE / OTHER	SWOLLEN HEART / EDEMA	GILL LESIONS / DIRTY or MUDDY GILLS	OBVIOUS GONAD / STYLE	ABNORMAL COLOR	OTHER	OTHER	SPAT ON SHELL (#/yr)	OTHER COMMENTS
1																									
2																									
3																									
4																									
5																									
6																									
7																									
8																									
9																									
10																									
11																									
12																									
13																									
14																									
15																									
16																									
17																									
18																									
19																									
20																									
21																									
22																									
23																									
24																									
25																									
26																									
27																									
28																									
29																									
30																									
#T																									
%																									
INT / SZ																									

KEY: INTENSITY SCALE - 0/BLANK = ABSENT, 1 = EXTREMELY LIGHT, 2 = VERY LIGHT, 3 = LIGHT, 4 = MODERATE, 5 = HEAVY, 6 = VERY HEAVY, 7 = EXTREMELY HEAVY

CONDITION SCALE: G = GAPER, M = MORIBUND, 1 = WATERY -, 2 = WATERY, 3 = WATERY +, 4 = MEDIUM -, 5 = MEDIUM, 6 = MEDIUM +, 7 = FAT -, 8 = FAT, 9 = FAT +

EXAMINED BY: _____

DATE: _____

DERMO REPORT

SAMPLE TYPE _____

TRIB _____ BAR _____ CODE _____

N= _____ TEMPERATURE _____ °C SALINITY _____ ‰ OTHER _____

COLLECTED ____ / ____ / ____ RECEIVED ____ / ____ / ____ DRILLED ____ / ____ / ____ BLED ____ / ____ / ____

#	DIAGNOSED	DIAGNOSED	DIAGNOSED	COMMENTS			
	HEMOLYMPH HISTOCYTOLOGY	HEMOLYMPH RFTM	RECTAL RFTM	GILL / WHOLE BODY RFTM	GONAD	TOTAL DERMO	COMMENTS
1							
2							
3							
4							
5							
6							
7							
8							
9							
10							
11							
12							
13							
14							
15							
16							
17							
18							
19							
20							
21							
22							
23							
24							
25							
26							
27							
28							
29							
30							
TOT							
%							
INT							
NDX							

0 = ABSENT, 1 = EXTREMELY LIGHT, 2 = VERY LIGHT, 3 = LIGHT, 4 = MODERATE, 5 = HEAVY, 6 = VERY HEAVY, 7 = EXTREMELY HEAVY

% PREVALENCE = INFECTED N / SAMPLE N

INTENSITY = (N1*1)+(N2*2) (N7*7) / SAMPLE N

INDEX = (N1*1)+(N2*2) (N7*7) / INFECTED N

MOLLUSCAN PATHOLOGY REPORT

Purpose: _____
 Requested by: _____
 Send report to: _____

Date sample shipped: _____
 Date sample received: _____
 Phone no.: _____
 E-mail address: _____

ENVIRONMENTAL DATA

Temperature _____ °C Salinity _____ ppt pH _____ Oxygen _____ ppm Other _____
 Species _____ Stock _____
 Origin _____
 History _____

 Location sample came from _____
 No. in sample _____ Date collected _____ Date fixed _____ Code _____
 Fixative _____ Other histologic data _____

GROSS PATHOLOGY

Condition			Mantle	Pale Digestive	Mean		
Fat	Medium	Watery	Recession	Gland	Cliona	Polydora	Size (mm)
_____ %	_____ %	_____ %	_____ %	_____ %	_____ %	_____ %	_____ %

HISTOPATHOLOGY

Pathologic Lesions			Parasites			
Category and Type of Lesion	Prevalence	Degree (0-9)	Group	Species	Prevalence	Degree (0-9)
Inflammation _____	_____ %	_____	Viruses	_____	_____ %	_____
_____	_____ %	_____	_____	_____	_____ %	_____
_____	_____ %	_____	Chlamydia	_____	_____ %	_____
_____	_____ %	_____	_____	_____	_____ %	_____
_____	_____ %	_____	Bacteria	_____	_____ %	_____
_____	_____ %	_____	_____	_____	_____ %	_____
Degeneration _____	_____ %	_____	Fungi	_____	_____ %	_____
_____	_____ %	_____	_____	_____	_____ %	_____
_____	_____ %	_____	Protozoa	_____	_____ %	_____
_____	_____ %	_____	_____	_____	_____ %	_____
Repair _____	_____ %	_____	_____	_____	_____ %	_____
_____	_____ %	_____	Metazoa	_____	_____ %	_____
_____	_____ %	_____	_____	_____	_____ %	_____

SUMMARY

LIST OF SCIENTIFIC AND COMMON NAMES

<i>Aerococcus viridans</i> - gaffkemia	<i>Molgula</i> sp. - sea squirt
<i>Argopecten irradians</i> - bay scallop	<i>Molgula manhattensis</i> - sea squirt or sea grape
<i>Arctica</i> - clam	<i>Morone saxatilis</i> - striped bass or rockfish
<i>Asteria forbesi</i> - starfish	<i>Mya arenaria</i> - soft clam
<i>Busycon carica</i> - conch, whelk	<i>Mytilicola</i> sp. - copepod
<i>Callinassa</i> sp. - mud prawn	<i>Mytilus</i> - mussel
<i>Callinectes sapidus</i> - blue crab	<i>Mytilus edulis</i> - blue mussel
<i>Carcinonemertes carcinophila</i> - nemertean	<i>Myzobdella lugubris</i> - leech
<i>Cliona</i> sp. - boring sponge	<i>Nephrops norvegicus</i> - Norway lobster
<i>Crassostrea angulata</i> - Portugese oyster	<i>Opsanus tau</i> - toadfish
<i>Crassostrea virginica</i> - American oyster	<i>Ostrea</i> sp. - European oyster
<i>Crepidula fornicata</i> - slipper shell	<i>Paramoeba pernicioso</i> - gray crab
<i>Cryptosporidium parvum</i> - protist	<i>Perkinsus chesapeaki</i> - Dermo in soft clam
<i>Diadumene leucolea</i> - white anemone	<i>Perkinsus marinus</i> - Dermo in eastern oyster
<i>Diplothyra smithii</i> - oyster piddock	<i>Pinnotheres ostreum</i> - pea crab
<i>Giardia</i> - protist	<i>Placopecten</i> - scallop
<i>Gukensia</i> - mussel	<i>Pleistophora</i> - microsporidan
<i>Haliplanella luciae</i> - green striped anemone	<i>Pleistophora nosematidae</i> - microsporidan
<i>Haplosporidium nelsoni</i> - MSX	<i>Polydora</i> sp. - mud worm
<i>Hematodinium perezii</i> - parasitic dinoflagellate	<i>Polydora websteri</i> - mud worm
<i>Hypocomella</i> sp. - ciliate	<i>Rhithropanopeus depressus</i> - mud crab
<i>Ischadium recurvum</i> - hooked mussel	<i>Sphenophrya</i> sp. - ciliate
<i>Lagenidium callinectes</i> - fungus	<i>Spisula solidissima</i> - surf clam
<i>Loxothylacus texanus</i> - parasitic barnacle	<i>Stylochus ellipticus</i> - flatworm
<i>Macoma balthica</i> - duck clam, Baltic clam	<i>Urosalpinx cinerea</i> - oyster drill
<i>Mercenaria mercenaria</i> - hard clam	<i>Vibrio anguillarum</i> - bacterium
<i>Modiolus (=Gukensia)</i> - mussel	

LIST OF ACRONYMS

1G4F - 1% glutaraldehyde/4% formalin	MFT - modified Field technique
AB - alcian blue	MHE - Mayer's hematoxylin and eosin
ANSI - American National Standards Institute	MPAS - malt periodic acid Schiff
API - Analytical Profile Index	MSDS - Material Safety Data Sheet
ARS - alizarin red S	MSX - multinucleate sphere unknown (= <i>Minchinia nelsoni/Haplosporidium nelsoni</i>)
ASCP - American Society of Clinical Pathologists	NBF - neutral buffered formalin
AZE - azure-eosin	NCCOS - National Centers for Coastal Ocean Science
BCF - Bureau of Commercial Fisheries	NFPA - National Fire Protection Association
BSS - balanced salt solution	NIH - National Institutes of Health
BFV - bi-facies virus	NIOSH - National Institute for Occupational Safety and Health
CBV - Chesapeake Bay virus	NMFS - National Marine Fisheries Service
COL - Cooperative Oxford Laboratory	NOAA - National Oceanic and Atmospheric Administration
CFR - Code of Federal Regulations	NOS - National Ocean Service
CHP - Chemical Hygiene Plan	NRC - National Research Council
CRW - Chemical Reactivity Worksheet	OCT - (product name)
DMSO - dimethyl sulfoxide	ORO - oil red O
DNA - deoxyribonucleic acid	OSHA - Occupational Safety and Health Administration
DOT - U.S. Department of Transportation	PAS - periodic acid Schiff
ECDIN - Environmental Chemical Data and Information Network	PBS - phosphate buffer solution
EDTA - ethylenediaminetetraacetate	PCR - polymerase chain reaction
EM - electron microscopy	PLL - poly-L-lysine
EPA - U.S. Environmental Protection Agency	PO - propylene oxide
ETOH - ethyl alcohol	PPE - personal protective equipment
FPM - Feulgen picromethyl blue	ppm - parts per million
GI - gastrointestinal	ppt - parts per thousand
GPO - U.S. Government Printing Office	PSR - Physicians for Social Responsibility
GMS - Grocott's methenamine silver	RFTM - Ray's fluid thioglycolate medium
HAZCOM - Hazard Communication Standard	rpm - revolutions per minute
HHE - Harris' hematoxylin and eosin	RLO - rickettsia-like organism
HTC - heavy teflon-coated	RLV - reo-like virus
IATA - International Air Transportation Association	SEM - scanning electron microscopy
IHE - Heidenhain's iron hematoxylin	SSO - seaside organism (<i>Haplosporidium costale</i>)
JLODRP - Jerome Le Peyre oyster disease reaseach program	TBO - toluidine blue O
JOD - juvenile oyster disease	TCBS - thiosulfate citrate bile salts sucrose
LCM - laser capture microdissection	TEM - transmission electron microscopy
LGT - low gel temperature	USDA - U.S. Department of Agriculture
MDNR - Maryland Department of Natural Resources	USDI - U.S. Department of the Interior
	ZHH - Ziehl-Neelsen/Harris' hematoxylin

LIST OF ABBREVIATIONS AND DEFINITIONS

= - equals	μl - microliter
* - multiply	μm - micrometer
# - number	min - minute
‰ - parts per thousand	ml - milliliter
% - percent	mm - millimeter
: - ratio	mo - month
Al ₂ (SO ₄) ₃ - aluminum sulfate	N - number
approx. - approximately	Na - sodium
avdp - avoirdupois (English measurement of weight)	Na ₂ HPO ₄ - sodium phosphate dibasic
c - concentration	Na ₂ S ₂ O ₅ - sodium metabisulfite
C - degree celsius	NaCl - sodium chloride
CaCl ₂ - calcium chloride	NaHCO ₃ - sodium bicarbonate
cat. - catalog	NaH ₂ PO ₄ · H ₂ O - sodium phosphate monobasic
CO ₂ - carbon dioxide	NaOH - sodium hydroxide
cont. - continued	no. - number
e.g. - example	O - oxygen
et al. - and others	oz - ounce
F - fahrenheit	p./pp. - page/pages
FeCl ₃ · 6H ₂ O - ferric chloride	pers. commun. - personal communication
Fig. - figure	pH - logarithm of reciprocal of hydrogen ion concentration (7 is neutral; more than 7 is alkaline; less than 7 is acid)
ft/min - foot per minute	sec - second
ga - gauge	sp. - species
gal - gallon	spp. - more than one species
gm - gram	sp. gr. - specific gravity
H - hydrogen	temp. - temperature
h - hour	trib - tributary
HCl - hydrochloric acid	troy - unit of weight in which the grain is the same as in the avoirdupois system and the pound contains 12 oz, 240 pennyweights, or 5760 grains
H ₂ SO ₄ - sulfuric acid	U.S. - United States
hypo - sodium thiosulfate	v - volume
i.e. - that is	v/v - volume to volume
in vitro - outside the living body (in test tube)	wk - week
in vivo - within the living body of plants/animals	x - multiply
K ₂ HPO ₄ - potassium phosphate dibasic	X - times magnification
KCl - potassium chloride	
L - liter	
M - mole	
MgCl ₂ - magnesium chloride	
MgSO ₄ - magnesium sulfate	

U.S STATE ABBREVIATIONS

AL - Alabama	NH - New Hampshire
AK - Alaska	NJ - New Jersey
AZ - Arizona	NM - New Mexico
AR - Arkansas	NY - New York
CA - California	NC - North Carolina
CO - Colorado	ND - North Dakota
CT - Connecticut	OH - Ohio
DE - Delaware	OK - Oklahoma
FL - Florida	OR - Oregon
GA - Georgia	PA - Pennsylvania
HI - Hawaii	RI - Rhode Island
ID - Idaho	SC - South Carolina
IL - Illinois	SD - South Dakota
IN - Indiana	TN - Tennessee
IA - Iowa	TX - Texas
KS - Kansas	UT - Utah
KY - Kentucky	VT - Vermont
LA - Louisiana	VA - Virginia
ME - Maine	WA - Washington
MD - Maryland	WV - West Virginia
MA - Massachusetts	WI - Wisconsin
MI - Michigan	WY - Wyoming
MN - Minnesota	CZ - Canal Zone
MS - Mississippi	DC - District of Columbia
MO - Missouri	GU - Guam
MT - Montana	PR - Puerto Rico
NE - Nebraska	VI - Virgin Islands
NV - Nevada	

GENERAL REFERENCES AND RECOMMENDED READING

- Adkins, G. 1972. Notes on the occurrence and distribution of the rhizocephalan parasite (*Loxothylacus texanus* Boschma) of blue crabs (*Callinectes sapidus*) in Louisiana estuaries. La. Wildl. Fish. Comm., Tech. Bull. No. 12, 13 pp.
- Almeida, M., F. Berthe, A. Thébault, and M.T. Dinis. 1999. Whole clam culture as a quantitative diagnostic procedure of *Perkinsus atlanticus* (Apicomplexa, Perkinsea) in clams *Ruditapes decussatus*. *Aquaculture* 177: 325-332.
- Andrews, J.D. 1955. Notes on fungus parasites of bivalve mollusks in Chesapeake Bay. *Proc. Natl. Shellfish. Assoc.* 45: 157-163.
- Anonymous. 1965. New parasite disease under study. *U.S. Bur. Commer. Fish., Commer. Fish. Rev.* 27(6): 44.
- ANSI (American National Standards Institute). 1998. American National Standard for Emergency Eyewash and Shower Equipment. ANSI Z358.1-1998, American National Standards Institute, New York. 29 p.
- Barry, M. and P.P. Yevich. 1975. The ecological, chemical and histopathological evaluation of an oil spill site: Part III. Histopathological studies. *Mar. Pollut. Bull.* 6: 171-173.
- Barry, M.M., P.P. Yevich, and N.H. Turner. 1971. Atypical hyperplasia in the soft-shell clam *Mya arenaria*. *J. Invertebr. Pathol.* 17: 17-27.
- Birge, E.A. and C.E. Imhoff. 1952. Versenate as a decalcifying agent for bone. *Am. J. Clin. Pathol.* 22: 192-193.
- Bland, C.E. and H.V. Amerson. 1973. Observations on *Lagenidium callinectes*: isolation and sporangial development. *Mycologia* 65: 310-320.
- Bland, C.E. and H.V. Amerson. 1974. Occurrence and distribution in North Carolina waters of *Lagenidium callinectes* Couch, a fungal parasite of blue crab ova. *Chesapeake Sci.* 15: 232-235.
- Boettcher, K.J., B.J. Barber, and J.T. Singer. 1999. Use of antibacterial agents to elucidate the etiology of juvenile oyster disease (JOD) in *Crassostrea virginica* and numerical dominance of an α -proteobacterium in JOD-affected animals. *Appl. Environ. Microbiol.* 65: 2534-2539.
- Boettcher, K.J., B.J. Barber, and J.T. Singer. 2000. Additional evidence that juvenile oyster disease is caused by a member of the *Roseobacter* group and colonization of nonaffected animals by *Stappia stellulata*-like strains. *Appl. Environ. Microbiol.* 66: 3924-3930.
- Bondad-Reantaso, M.G., S.E. McGladdery, I. East, and R.P. Subasinghe, Editors. 2001. *Asia Diagnostic Guide to Aquatic Animal Diseases*. FAO Fish. Tech. Pap. 402/2, 240 p.
- Boon, D.B. 1972. The red pigment in discolored oysters and soft-shelled clams from the Chesapeake Bay. *Chesapeake Sci.* 13: 334-335.
- Bricelj, V.M., S. Ford, F.J. Borrero, F.O. Perkins, G. Rivara, R.E. Hillman, R.A. Elston, and J. Chang. 1992. Unexplained mortalities of hatchery-reared, juvenile oysters, *Crassostrea virginica* (Gmelin). *J. Shellfish Res.* 11: 331-347.
- Brown, J.H. and L. Brenn. 1931. A method for the differential staining of gram-positive and gram-negative bacteria in tissue sections. *Bull. Johns Hopkins Hosp.* 48: 69-73.
- Brown, R.C. and H.C. Hopps. 1973. Staining of bacteria in tissue sections: a reliable Gram stain method. *Am. J. Clin. Pathol.* 60: 234-240.
- Bushek, D., S.E. Ford, and S.K. Allen, Jr. 1994. Evaluation of methods using Ray's fluid thioglycollate medium for diagnosis of *Perkinsus marinus* infection in the eastern oyster, *Crassostrea virginica*. *Annu. Rev. Fish Dis.* 4: 201-217.
- Bushek, D., R. Holley, and M. Kelly. 1997a. Chlorine tolerance of *Perkinsus marinus*. *J. Shellfish Res.* 16: 260 (abstract).
- Bushek, D., R. Holley, and M. Kelly. 1997b. Treatment of *Perkinsus marinus*-contaminated materials. *J. Shellfish Res.* 16: 330 (abstract).
- Carson, F.L. 1990. *Histotechnology - A Self-instructional Text*. American Society of Clinical Pathologists, Chicago, IL. 294 p.

- Cheng, T.C. 1981. Hemocytes: forms and functions, pp. 299-333. In: V.S. Kennedy, R.I.E. Newell, and A.F. Eble (eds.), *The Eastern Oyster, Crassostrea virginica*. Publ. UM-SG-TS-96-01, Maryland Sea Grant College, College Park, MD.
- Choi, K.-S., E.A. Wilson, D.H. Lewis, E.N. Powell, and S.M. Ray. 1989. The energetic cost of *Perkinsus marinus* parasitism in oysters: quantification of the thioglycollate method. *J. Shellfish Res.* 8: 125-131.
- Conn, H.J., M.A. Darow, and V.M. Emmel. 1962. *Staining Procedures Used by the Biological Stain Commission*. 2d ed. Williams and Wilkins Co., Baltimore, MD. 289 p.
- Cook, D.W. and S.R. Lofton. 1973. Chitinoclastic bacteria associated with shell disease in *Penaeus* shrimp and the blue crab. *J. Wildl. Dis.* 9: 154-159.
- Coolidge, B.J. and R.M. Howard. 1979. *Animal Histology Procedures of the Pathological Technology Section of the National Cancer Institute*. 2d ed. NIH Publ. No. 80-275, National Institutes of Health, Bethesda, MD. 209 p.
- Cooper, S.P. 1982. The description of a new species of rynchodid ciliate and its occurrence in gill tissue of the American oyster *Crassostrea virginica*. Master's thesis, Univ. Maryland, College Park. 63 p.
- Couch, J.A. 1983. Diseases caused by Protozoa, pp. 79-111. In: A.J. Provenzano (ed.), *The Biology of Crustacea*. Vol. 6. Pathobiology. Academic Press, New York.
- Couch, J.N. 1942. A new fungus on crab eggs. *J. Elisha Mitchell Sci. Soc.* 58: 158-162.
- Dahl, L.K. and V.P. Dole. 1952. The biphasic nature of renal calcification. *J. Exp. Med.* 95: 341-346.
- Dapson, J.C. and R.W. Dapson. 1995. *Hazardous Materials in the Histopathology Laboratory. Regulations, Risks, Handling and Disposal*. 3d ed. Anatech Ltd., Battle Creek, MI. 255 p.
- Davis, C.V. and B.J. Barber. 1994. Size-dependent mortality in hatchery-reared populations of oysters, *Crassostrea virginica*, Gmelin 1791, affected by juvenile oyster disease. *J. Shellfish Res.* 13: 137-142.
- Drury, R.A.B. and E.A. Wallington. 1967. *Carleton's Histological Technique*. 4th ed. Oxford Univ. Press, New York. 432 p.
- Dungan, C.F., R.M. Hamilton, K.L. Hudson, C.B. McCollough, and K.S. Reece. 2002. Two epizootic diseases in Chesapeake Bay commercial clams, *Mya arenaria* and *Tagelus plebeius*. *Dis. Aquat. Org.* 50: 67-78.
- Earle, P.M. and F.D. Crisley. 1975. Isolation and characterization of *Vibrio parahaemolyticus* from Cape Cod soft-shell clams (*Mya arenaria*). *Appl. Microbiol.* 29: 635-640.
- Elsayed, E.E., S.M. McLaughlin, and M. Faisal. 1999. Protease inhibitors in plasma of the softshell clam *Mya arenaria*: identification and effects of disseminated sarcoma. *Comp. Biochem. Physiol.* B123: 427-435.
- Engel, D.W. and E.J. Noga. 1989. Shell disease in the blue crabs of the Pamlico River. *Environ. (Feb.)*, pp. 3-5.
- EPA (U.S. Environmental Protection Agency). 2000. *Environmental Management Guide for Small Laboratories*. EPA 233-B-00-001, U.S. Environmental Protection Agency, Washington, DC. 139 p.
- Farley, C.A. 1965. Acid-fast staining of haplosporidian spores in relation to oyster pathology. *J. Invertebr. Pathol.* 7: 144-147.
- Farley, C.A. 1968. *Minchinia nelsoni* (Haplosporida) disease syndrome in the American oyster *Crassostrea virginica*. *J. Protozool.* 15: 585-599.
- Farley, C.A. 1969. Probable neoplastic disease of the hematopoietic system in oysters, *Crassostrea virginica* and *Crassostrea gigas*, pp. 541-555. In: C.J. Dawe and J.C. Harshbarger (eds.), *Neoplasms and Related Disorders of Invertebrate and Lower Vertebrate Animals*. Natl. Cancer Inst. Monogr. 31.
- Farley, C.A. 1976. Proliferative disorders in bivalve mollusks. *Mar. Fish. Rev.* 38(10): 30-33.
- Farley, C.A. 1978. Viruses and viruslike lesions in marine mollusks. *Mar. Fish. Rev.* 40(10): 18-20.
- Farley, C.A. 1988. Histochemistry as a tool for examining possible pathologic cause-and-effect relationships between heavy metal and inflammatory lesions in oysters, *Crassostrea virginica*. *Mar. Environ. Res.* 24: 271-275.

- Farley, C.A. 1989. Selected aspects of neoplastic progression in mollusks, pp. 24-31. *In*: H.E. Kaiser (ed.), Comparative Aspects of Tumor Development. Cancer Growth and Progression, Vol 5. Kluwer Academic Publ., Dordrecht, The Netherlands.
- Farley, C.A. and E.J. Lewis. 1997. Juvenile oyster disease fact sheet. U.S. Dept. Commerce, NOAA Tech. Memo. NMFS-SEFSC-404, 8 pp.
- Farley, C.A. and D.L. Plutschak. 1991. Hemolymph thioglycollate diagnosis for *Perkinsus* disease and application to three years of oyster disease surveys in Maryland. Atlantic Estuarine Research Society, St. Michaels, MD. (Abstract)
- Farley, C.A. and B. Straight. 1991. An *in vivo* clinical study of *Perkinsus marinus* disease in the American oyster, *Crassostrea virginica*, using hemolymph thioglycolate diagnosis. Society for Invertebrate Pathology, Flagstaff, AZ. p. 40 (abstract).
- Farley, C.A., S.V. Otto, and C.L. Reinisch. 1986. New occurrence of epizootic sarcoma in Chesapeake Bay softshell clams, *Mya arenaria*. U.S. Fish Wildl. Serv., Fish. Bull. 84: 851-857.
- Farley, C.A., D.L. Plutschak, and G. Messick. 1991a. Hemanalysis methods for systemic disease diagnosis of invertebrate animals. Atlantic Estuarine Research Society, St. Michaels, MD. (Abstract)
- Farley, C.A., D.L. Plutschak, and R.F. Scott. 1991b. Epizootiology and distribution of transmissible sarcoma in Maryland softshell clams, *Mya arenaria*, 1984-1988. Environ. Health Persp. 90: 35-41.
- Fayer, R., C.A. Speer, and J.P. Dubey. 1997a. General biology of *Cryptosporidium* and cryptosporidiosis, pp. 1-41. *In*: R. Fayer (ed.), *Cryptosporidium* and Cryptosporidiosis. CRC Press, Boca Raton, FL.
- Fayer, R., C.A. Farley, E.J. Lewis, J.M. Trout, and T.K. Graczyk. 1997b. Potential role of the eastern oyster, *Crassostrea virginica*, in the epidemiology of *Cryptosporidium parvum*. Appl. Environ. Microbiol. 63: 2086-2088.
- Fayer, R., T.K. Graczyk, E.J. Lewis, J.M. Trout, and C.A. Farley. 1998. Survival of infectious *Cryptosporidium parvum* oocysts in seawater and eastern oysters (*Crassostrea virginica*) in the Chesapeake Bay. Appl. Environ. Microbiol. 64: 1070-1074.
- Fayer, R., E.J. Lewis, J.M. Trout, T.K. Graczyk, M.C. Jenkins, J. Higgins, L. Xiao, and A.A. Lal. 1999. *Cryptosporidium parvum* identification in oysters from commercial harvesting sites in the Chesapeake Bay. Emerg. Infect. Dis. 5: 1-7.
- Fayer, R., J.M. Trout, E.J. Lewis, M. Santin, L. Zhou, A.A. Lal, and L. Xiao. 2003. Contamination of Atlantic coast commercial shellfish with *Cryptosporidium*. Parasitol. Res. 89: 141-145.
- Feder, N. and T.P. O'Brien. 1968. Plant microtechnique: some principles and new methods. Am. J. Bot. 55: 123-142.
- Feng, S.Y., J.S. Feng, C.N. Burke, and L.H. Khairallah. 1971. Light and electron microscopy of the leucocytes of *Crassostrea virginica* (Mollusca: Pelecypoda). Z. Zellforsch. 120: 222-245.
- Field, R.H., C.J. Chapman, A.C. Taylor, D.M. Neil, and K. Vickerman. 1992. Infection of the Norway lobster *Nephrops norvegicus* by a *Hematodinium*-like species of dinoflagellate on the west coast of Scotland. Dis. Aquat. Org. 13: 1-15.
- Ford, S.E. 1994. Unexplained mortalities of hatchery-reared oysters, *Crassostrea virginica*, in the Northeast: a follow-up study. Final technical report to the Northeastern Regional Aquaculture Center (NRAC), Univ. Massachusetts Dartmouth, North Dartmouth, MA. 41 pp.
- Fries, C.R., S.B. Grau, and M.R. Tripp. 1991. Rickettsiae in the cytoplasm of gill epithelial cells of the soft-shelled clam, *Mya arenaria*. J. Invertebr. Pathol. 57: 443-445.
- Galtsoff, P.S. 1964. The American oyster *Crassostrea virginica* Gmelin. U.S. Fish Wildl. Serv., Fish. Bull. 64, 480 pp.
- Galtsoff, P.S. 1969. Anomalies and malformations in the shells of *Crassostrea virginica*, pp. 575-580. *In*: C.J. Dawe and J.C. Harshbarger (eds.), Neoplasms and Related Disorders of Invertebrate and Lower Vertebrate Animals. Natl. Cancer Inst. Monogr. 31.
- Gauthier, J.D. and W.S. Fisher. 1990. Hemolymph assay for diagnosis of *Perkinsus marinus* in oysters *Crassostrea virginica*. J. Shellfish Res. 9: 367-371.
- Giberson, R.T. and R.S. Demaree, Jr., Editors. 2001. Microwave Techniques and Protocols. Humana Press, Totowa, NJ. 300 p.

- Graczyk, T.K., R. Fayer, E.J. Lewis, C.A. Farley, and J.M. Trout. 1997. In vitro interactions between hemocytes of the Eastern oyster, *Crassostrea virginica* Gmelin, 1791 and *Cryptosporidium parvum* oocysts. *J. Parasitol.* 83: 949-952.
- Graczyk, T.K., R. Fayer, D.B. Conn, and E.J. Lewis. 1999a. Evaluation of the recovery of waterborne *Giardia* cysts by freshwater clams and cyst detection in clam tissue. *Parasitol. Res.* 85: 30-34.
- Graczyk, T.K., R. Fayer, E.J. Lewis, J.M. Trout, and C.A. Farley. 1999b. *Cryptosporidium* oocysts in bent mussels (*Ischadium recurvum*) in the Chesapeake Bay. *Parasitol. Res.* 85: 518-521.
- Graczyk, T.K., R.C.A. Thompson, R. Fayer, U.M. Morgan, and E.J. Lewis. 1999c. *Giardia duodenalis* cysts of genotype A recovered from clams in the Chesapeake Bay subestuary, Rhode River. *Am. J. Trop. Med. Hyg.* 61: 526-529.
- Graczyk, T.K., R. Fayer, M.C. Jenkins, J.M. Trout, J. Higgins, E.J. Lewis, and C.A. Farley. 2000. Susceptibility of the Chesapeake Bay to environmental contamination with *Cryptosporidium parvum*. *Environ. Res.* 82: 106-112.
- Gray, P. 1954. *The Microtome's Formulary and Guide*. Blakiston Co., New York. 794 p.
- Haefner, P.A., Jr. and D. Garten. 1974. Methods of handling and shedding blue crab, *Callinectes sapidus*. *Va. Inst. Mar. Sci., Mar. Resour. Advis. Ser.* 8: 1-14.
- Hanks, R.W. 1963. *The soft-shell clam*. U.S. Dept. Interior, Fish Wildl. Serv., Bur. Commer. Fish. Circ. 162, 16 pp.
- Harshbarger, J.C., S.C. Chang, and S.V. Otto. 1977. Chlamydiae (with phages), mycoplasmas, and rickettsiae in Chesapeake Bay bivalves. *Science* 196: 666-668.
- Harshbarger, J.C., S.V. Otto, and S.C. Chang. 1979. Proliferative disorders in *Crassostrea virginica* and *Mya arenaria* from the Chesapeake Bay and intranuclear virus-like inclusions in *Mya arenaria* with germinomas from a Maine oil spill site. *Haliotis* 8: 243-248.
- Hayat, M.A. 1989. *Principles and Techniques of Electron Microscopy*. 3d ed. CRC Press, Boca Raton, FL. 469 p.
- Hochheimer, J. 1986. Water quality in crab shedding. *The Shedder*, Vol. 2. Univ. Maryland Sea Grant Extension Program, Cambridge, MD.
- Hopkins, S.H. 1947. The nemertean *Carcinonemertes* as an indicator of the spawning history of the host, *Callinectes sapidus*. *J. Parasitol.* 33: 146-150.
- Hueper, W.C. 1963. Environmental carcinogenesis in man and animals. *Ann. N.Y. Acad. Sci.* 108: 963-1038.
- Huffman J.E. and M.R. Tripp. 1982. Cell types and hydrolytic enzymes of soft shell clam (*Mya arenaria*) hemocytes. *J. Invertebr. Pathol.* 40: 68-74.
- Humes, A.G. 1942. The morphology, taxonomy and bionomics of the nemertean genus *Carcinonemertes*. III. *Biol. Monogr.* 18(4): 1-105.
- Hutton, R.F. and F. Sogandares-Bernal. 1959. Notes on the distribution of the leech, *Myzobdella lugubris* Leidy, and its association with mortality of the blue crab, *Callinectes sapidus* Rathbun. *J. Parasitol.* 45: 384, 404, 430.
- Johnson, P.T. 1976. Bacterial infection in the blue crab, *Callinectes sapidus*: course of infection and histopathology. *J. Invertebr. Pathol.* 28: 25-36.
- Johnson, P.T. 1977a. A viral disease of the blue crab, *Callinectes sapidus*: histopathology and differential diagnosis. *J. Invertebr. Pathol.* 19: 201-209.
- Johnson, P.T. 1977b. Reovirus-like virus of blue crabs, pp. 103-105. *In: C.J. Sindermann (ed.), Disease Diagnosis and Control in North American Marine Aquaculture*. Elsevier, New York.
- Johnson, P.T. 1977c. Paramoebiasis in the blue crab, *Callinectes sapidus*. *J. Invertebr. Pathol.* 29: 308-320.
- Johnson, P.T. 1978a. New information on viral diseases of the blue crab, *Callinectes sapidus*. *Proceedings of 2d International Colloquium on Invertebrate Pathology and XIth Annual Society for Invertebrate Pathology, Prague, Czechoslovakia*. 3 pp.
- Johnson, P.T. 1978b. Viral diseases of the blue crab, *Callinectes sapidus*. *Mar. Fish. Rev.* 40(10): 13-15.
- Johnson, P.T. 1980. *Histology of the Blue Crab, Callinectes sapidus: A Model for the Decapoda*. Praeger, New York. 440 p.

- Johnson, P.T. 1983. Diseases caused by viruses, rickettsiae, bacteria, and fungi, pp. 1-78. *In*: A.J. Provenzano, Jr. (ed.), *The Biology of Crustacea*. Vol. 6. Pathobiology. Academic Press, New York.
- Johnson, P.T. 1984. Viral diseases of marine invertebrates, pp. 65-98. *In*: O. Kinne and H.P. Bulnheim (eds.), *Diseases of Marine Organisms*. Helgol. Meeresunters. 37.
- Johnson, P.T. 1986. Blue crab (*Callinectes sapidus* Rathbun) viruses and the diseases they cause, pp. 13-19. *In*: H.M. Perry and R.F. Malone (eds.), *Proceedings of the National Symposium on the Soft-shelled Blue Crab Fishery*. Gulf Coast Research Lab., Ocean Springs, MS.
- Johnson, P.T. 1988. Development and morphology of an unusual nuclear virus of the blue crab *Callinectes sapidus*. *Dis. Aquat. Org.* 4: 67-75.
- Kaneko, T., R.R. Colwell, and F. Hamons. 1975. Bacteriological studies of Wicomico River soft-shell clam (*Mya arenaria*) mortalities. *Chesapeake Sci.* 16: 3-13.
- Kennedy, V.S. and J.A. Mihursky. 1971. Upper temperature tolerances of some estuarine bivalves. *Chesapeake Sci.* 12: 193-204.
- Kinne, O., Editor. 1983. *Diseases of Marine Animals*. Vol. II, Introduction, Bivalvia to Scaphopoda. Biologische Anstalt Helgoland, Hamburg, FRG. 1038 p.
- Kofoid, C.A. and M. Bush. 1936. The life cycle of *Parachaenia myae* gen. nov., sp. nov., a ciliate parasitic in *Mya arenaria* Linn. from San Francisco Bay, California. *Bull. Mus. R. Hist. Nat. Belgique* 12: 1-15.
- Kotob, S.I., S.M. McLaughlin, P. van Berkum, and M. Faisal. 1999. Discrimination between two *Perkinsus* spp. isolated from the softshell clam, *Mya arenaria*, by sequence analysis of two internal transcribed spacer regions and the 5-8S ribosomal RNA gene. *Parasitology* 119: 363-368.
- La Peyre, J.F. 1996. Propagation and *in vitro* studies of *Perkinsus marinus*. *J. Shellfish Res.* 15: 89-101.
- La Peyre, J.F. and M. Faisal. 1995. Improved method for the initiation of continuous cultures of the oyster pathogen *Perkinsus marinus* (Apicomplexa). *Trans. Am. Fish. Soc.* 124: 144-146.
- La Peyre, J.F., M. Faisal, and E.M. Burreson. 1993. *In vitro* propagation of the protozoan *Perkinsus marinus*, a pathogen of the eastern oyster, *Crassostrea virginica*. *J. Euk. Microbiol.* 40: 304-310.
- Laughlin, R.A. 1982. Feeding habits of the blue crab, *Callinectes sapidus* Rathbun, in the Apalachicola estuary, Florida. *Bull. Mar. Sci.* 32: 807-822.
- Lee, J.J., E.B. Small, D.H. Lynn, and E.C. Bovee. 1985. Some techniques for collecting, cultivating and observing protozoa, pp. 1-7. *In*: J.J. Lee, S.H. Hutner, and E.C. Bovee (eds.), *An Illustrated Guide to the Protozoa*. Society of Protozoologists, Lawrence, KS.
- Levine, N.D. 1978. *Perkinsus* gen. n. and other new taxa in the protozoan phylum Apicomplexa. *J. Parasitol.* 64: 549.
- Lewis, E.J. 2001. Juvenile oyster disease (JOD) and management strategies: a review. *Bull. Natl. Res. Inst. Aquacult., Suppl.* 5: 101-109.
- Lewis, E.J., C.A. Farley, E.B. Small, and A.M. Baya. 1996. A synopsis of juvenile oyster disease (JOD) experimental studies in *Crassostrea virginica*. *Aquat. Living Resour.* 9: 169-178.
- Ley, V., J. Higgins, and R. Fayer. 2002. Bovine enteroviruses as indicators of fecal contamination. *Appl. Environ. Microbiol.* 68: 3455-3461.
- Liddell, V.A. 1967. Frozen-section technique in shellfish research. *J. Invertebr. Pathol.* 9: 283-284.
- Lillie, R.D. 1954. *Histopathologic Technic and Practical Histochemistry*. McGraw-Hill, New York. 501 p.
- Lillie, R.D. 1965. *Histopathologic Technic and Practical Histochemistry*. 3d ed. McGraw-Hill, New York. 715 p.
- Lippson, A.J. and R.L. Lippson. 1997. *Life in the Chesapeake Bay*. 2d ed. Johns Hopkins Univ. Press, Baltimore, MD. 294 p.
- Luna, L.G., Editor. 1968. *Manual of Histologic Staining Methods of the Armed Forces Institute of Pathology*. 3d ed. McGraw-Hill, New York. 258 p.
- Luna, L.G. 1992. *Histopathologic Methods and Color Atlas of Special Stains and Tissue Artifacts*. American Histolabs., Inc., Gaithersburg, MD. 767 p.

- Mackin, J.G. 1951. Histopathology of infection of *Crassostrea virginica* (Gmelin) by *Dermocystidium marinum* Mackin, Owen, and Collier. Bull. Mar. Sci. Gulf Caribb. 1: 72-87.
- Mackin, J.G. 1962. Oyster disease caused by *Dermocystidium marinum* and other microorganisms in Louisiana. Publ. Inst. Mar. Sci. Univ. Tex. 7: 132-229.
- Malone, R.F. and D.P. Manthe. 1985. Chemical addition for accelerated nitrification of biological filter in closed blue crab shedding systems, pp. 41-47. In: H.M. Perry and R.F. Malone (eds.), Proceedings of the National Symposium on the Soft-Shell Blue Crab Fishery. Gulf Coast Research Lab., Ocean Springs, MS.
- Manthe, D.P., R.F. Malone, and H.M. Perry. 1983. Water quality fluctuations in response to variable loading in a commercial, closed shedding facility for blue crabs. J. Shellfish Res. 3: 175-182.
- McCormack, G. 1956. Growth characteristics of the pink yeast that causes discoloration of oysters. U.S. Bur. Commer. Fish., Commer. Fish. Rev. 18(11): 21-23.
- McDowell, E.M. and B.F. Trump. 1976. Histologic fixatives suitable for diagnostic light and electron microscopy. Arch. Pathol. Lab. Med. 100: 405-414.
- McLaughlin, S.M. 1991. Transmission studies of sarcoma disease in the softshell clam, *Mya arenaria*. M.S. thesis, Univ. Maryland, College Park, MD. 82 pp.
- McLaughlin, S.M. and M. Faisal. 1998a. Histopathological alterations associated with *Perkinsus* spp. infection in the softshell clam *Mya arenaria*. Parasite 5: 263-271.
- McLaughlin, S.M. and M. Faisal. 1998b. *In vitro* propagation of two *Perkinsus* species from the soft-shell clam *Mya arenaria*. Parasite 5: 341-348.
- McLaughlin, S.M. and M. Faisal. 1999. A comparison of diagnostic assays for detection of *Perkinsus* spp. in the softshell clam *Mya arenaria*. Aquaculture 172: 197-204.
- McLaughlin, S.M. and M. Faisal. 2001. Pathogenesis of *Perkinsus* spp. in bivalve mollusks. Bull. Natl. Res. Inst. Aquacult., Suppl. 5: 111-117.
- McLaughlin, S.M., C.A. Farley, and F.M. Hetrick. 1992. Transmission studies of sarcoma in the soft-shell clam, *Mya arenaria*. In Vivo 6: 367-370.
- McLaughlin, S.M., B.D. Tall, A. Shaheen, E.E. Elsayed, and M. Faisal. 2000. Zoosporulation of a new *Perkinsus* species isolated from the gills of the softshell clam *Mya arenaria*. Parasite 7: 115-122.
- McManus, J.F.A. and R.W. Mowry. 1960. Staining Methods - Histologic and Histochemical. Harper & Row, New York. 423 p.
- Mead, P.S., L. Slutsker, V. Dietz, L.F. McCaig, J.S. Bresee, C. Shapiro, P.M. Griffin, and R.V. Tauxe. 1999. Food-related illness and death in the United States. Emerg. Infect. Dis. 5: 607-625.
- Mercier, P. 1996. Laboratory Safety Pocket Handbook. Genium Publ. Corp., Schenectady, NY. 212 p.
- Messick, G.A. 1994. *Hematodinium perezii* infections in adult and juvenile blue crabs *Callinectes sapidus* from coastal bays of Maryland and Virginia, USA. Dis. Aquat. Org. 19: 77-82.
- Messick, G.A. 1995. Laboratory techniques for detecting parasites and diseases of blue crabs, *Callinectes sapidus*, pp. 187-200. In: J.S. Stolen, T.C. Fletcher, S.A. Smith, J.T. Zelikoff, S.L. Kaattari, R.S. Anderson, K. Söderhäll, and B.A. Weeks-Perkins (eds.), Techniques in Fish Immunology-4. SOS Publ., Fair Haven, NJ.
- Messick, G.A. and V.S. Kennedy. 1990. Putative bacterial and viral infections in blue crabs, *Callinectes sapidus* Rathbun, 1896 held in a flow-through or a recirculation system. J. Shellfish Res. 9: 33-40.
- Messick, G.A. and C.J. Sindermann. 1992. Synopsis of principal diseases of the blue crab, *Callinectes sapidus*. U.S. Dept. Commerce, NOAA Tech. Memo. NMFS-F/NEC-88, 24 pp.
- Mitchell, H.L. 1966. A simple method of permanent staining of intestinal parasites, using dimethyl sulfoxide. Tech. Bull. Regist. Med. Technol. 36: 45-46.
- Moore, J.P. 1946. The anatomy and systematic position of *Myzobdella lugubris* Leidy (Hirudinea). Not. Nat. (Phila.) 184: 1-12.
- National Research Council. 1995. Prudent Practices in the Laboratory - Handling and Disposal of Chemicals. National Academy Press, Washington, DC. 427 p.

- Newcombe, C.L. and M.R. Rogers. 1947. Studies of a fungus parasite that infects blue crab eggs. *Turttox News* 25(9): 1-7.
- Newman, M.W. and C.A. Johnson, III. 1975. A disease of blue crabs (*Callinectes sapidus*) caused by a parasitic dinoflagellate *Hematodinium* sp. *J. Parasitol.* 61: 554-557.
- Newman, M.W. and G.E. Ward, Jr. 1973. An epizootic of blue crabs, *Callinectes sapidus*, caused by *Paramoeba pernicioso*. *J. Invertebr. Pathol.* 22: 329-334.
- NMFS (National Marine Fisheries Service). 2003. Fisheries of the United States, 2002. U.S. Dept. Commerce, NMFS Current Fishery Statistics No. 2002, 126 pp.
- Oprandy, J.J., P.W. Chang, A.D. Pronovost, K.R. Cooper, R.S. Brown, and V.J. Yates. 1981. Isolation of a viral agent causing hematopoietic neoplasia in the soft-shell clam, *Mya arenaria*. *J. Invertebr. Pathol.* 38: 45-51.
- Ossiander, F.J. and G. Wedemeyer. 1973. Computer program for sample sizes required to determine disease incidence in fish populations. *J. Fish. Res. Board Can.* 30: 1383-1384.
- Overstreet, R.M. 1977. Microsporiosis of blue crabs, pp. 200-203. *In:* C.J. Sindermann and D.V. Lightner (eds.), *Disease Diagnosis and Control in North American Marine Aquaculture*. Elsevier, New York.
- Overstreet, R.M. 1978. Marine Maladies? Worms, Germs, and Other Symbionts from the Northern Gulf of Mexico. Blossman Printing, Ocean Springs, MS. 140 p.
- Overstreet, R.M. 1982. Metazoan symbionts of the blue crab, pp. 81-87. *In:* H.M. Perry and W.A. Van Engel (eds.), *Proceedings of Blue Crab Colloquium*, Gulf Coast Research Lab., Ocean Springs, MS.
- Overstreet, R.M. and E.C. Whatley, Jr. 1975. Prevention of microsporidiosis in the blue crab, with notes on natural infections. *Proc. World Maricult. Soc.* 6: 335-345.
- Paparella, M., Editor. 1973. Red oysters, pp. 2-3. *In:* *Information Tips*. Univ. Maryland Marine Products Lab., Crisfield, MD.
- Pauley, G.B. 1967. A modification of Mallory's aniline blue collagen stain for oyster tissue. *J. Invertebr. Pathol.* 9: 268-269.
- Pauley, G.B. and T.C. Cheng. 1968. A tumor on the siphons of a soft-shell clam, *Mya arenaria*. *J. Invertebr. Pathol.* 11: 504-506.
- Pauley, G.B., M.W. Newman, and E. Gould. 1975. Serum changes in the blue crab, *Callinectes sapidus*, associated with *Paramoeba pernicioso*, the causative agent of grey crab disease. *Mar. Fish. Rev.* 37(5-6): 34-38.
- Pearse, A.G.E. 1960. *Histochemistry: Theoretical and Applied*. 2d ed. Little, Brown and Co., Boston, MA. 998 p.
- Presnell, J.K. and M.P. Schreibman. 1997. *Humason's Animal Tissue Techniques*. 5th ed. Johns Hopkins Univ. Press, Baltimore, MD. 572 p.
- Prophet, E.B., B. Mills, J.B. Arrington, and L.H. Sobin, Editors. 1992. *Armed Forces Institute of Pathology - Laboratory Methods in Histotechnology*. American Registry of Pathology, AFIP, Washington, DC. 279 p.
- PSR (Physicians for Social Responsibility). 2001. *Cryptosporidium*. What health care providers should know. Drinking Water Fact Sheet # 1, Physicians for Social Responsibility, Washington, DC.
- Pyle, R.W. and L.E. Cronin. 1950. The general anatomy of the blue crab *Callinectes sapidus* Rathbun. Publ. 87, Chesapeake Biological Lab., Solomons, MD. 40 pp.
- Ragan, J.G. and B.A. Matherne. 1974. Studies of *Loxothylacus texanus*, pp. 185-203. *In:* R.L. Amborski, M.A. Hood, and R.R. Miller (eds.), *Proceedings of Gulf Coast Regional Symposium on Diseases of Aquatic Animals*. Publ. No. LSU-SG-74-05, Louisiana State Univ., Baton Rouge.
- Ray, S.M. 1952. A culture technique for the diagnosis of infections with *Dermocystidium marinum* Mackin, Owen, and Collier in oysters. *Science* 116: 360-361.
- Ray, S.M. 1966. A review of the culture method for detecting *Dermocystidium marinum*, with suggested modifications and precautions. *Proc. Natl. Shellfish. Assoc.* 54: 55-69.
- Reinhard, E.G. 1950. An analysis of the effects of a sacculinid parasite on the external morphology of *Callinectes sapidus* Rathbun. *Biol. Bull. (Woods Hole)* 98: 277-288.

- Reinhard, E.G. 1956. Parasitic castration of Crustacea. *Exp. Parasitol.* 5: 79-107.
- Rodriguez, F. and J.I. Navas. 1995. A comparison of gill and hemolymph assays for the thioglycollate diagnosis of *Perkinsus atlanticus* (Apicomplexa, Perkinsea) in clams, *Ruditapes decussatus* (L.) and *Ruditapes philippinarum* (Adams et Reeve). *Aquaculture* 132: 145-152.
- Rogers-Talbert, R. 1948. The fungus *Lagenidium callinectes* Couch (1942) on eggs of the blue crab in Chesapeake Bay. *Biol. Bull. (Woods Hole)* 95: 214-228.
- Rosen, B. 1967. Shell disease of the blue crab, *Callinectes sapidus*. *J. Invertebr. Pathol.* 9: 348-353.
- Russell, W.D. 1941. The substitution of zinc chloride for mercuric chloride in Zenker's fluid. *Bull. Int. Assoc. Med. Mus.* 21: 47-49.
- Sanders, B.J. 1972. Animal Histology Procedures of the Pathological Technology Section of the National Cancer Institute. DHEW Publ. No. 72-275, National Institutes of Health, Bethesda, MD. 185 p.
- Sandoz, M.D., M.R. Rogers, and C.L. Newcombe. 1944. Fungus infection of eggs of the blue crab, *Callinectes sapidus* Rathbun. *Science* 99: 124-125.
- Sawyer, T.K. 1969. Preliminary study on the epizootiology and host-parasite relationship of *Paramoeba* sp. in the blue crab, *Callinectes sapidus*. *Proc. Natl. Shellfish. Assoc.* 59: 60-64.
- Sawyer, R.T., A.R. Lawler, and R.M. Overstreet. 1975. Marine leeches of the eastern United States and the Gulf of Mexico with a key to the species. *J. Nat. Hist.* 9: 633-667.
- Sindermann, C.J. 1989. The shell disease syndrome in marine crustaceans. *Mar. Fish. Rev.* 40(10): 32-35.
- Shaw, B.L. and H.I. Battle. 1957. The gross and microscopic anatomy of the digestive tract of the oyster *Crassostrea virginica* (Gmelin). *Can. J. Zool.* 35: 325-347.
- Sheehan, D.C. and B.B. Hrapchak. 1973. Theory and Practice of Histotechnology. C.V. Mosby Co., St. Louis, MO. 218 p.
- Small, E.B. and T. Maugel. 1982. The ultrastructure of specimens of *Paramecium multimicronucleatum* impregnated with silver by Fernandez-Galiano method. *J. Protozool.* 29: 627-634.
- Sprague, V. 1950. Notes on three microsporidian parasites of decapod Crustacea of Louisiana coastal waters. *La. State Univ., Occas. Pap. Mar. Lab. No.* 5: 1-8.
- Sprague, V. 1965. *Nosema* sp. (Microsporida, Nosematidae) in the musculature of the crab *Callinectes sapidus*. *J. Protozool.* 12: 66-70.
- Sprague, V. 1966. Two new species of *Pleistophora* (Microsporida, Nosematidae) in decapods, with particular reference to one in the blue crab. *J. Protozool.* 13: 196-199.
- Sprague, V. 1970. Some protozoan parasites and hyperparasites in marine decapod Crustacea, pp. 416-430. *In: S.F. Snieszko (ed.), A Symposium on Diseases of Fishes and Shellfishes. Special Publ. No. 5, American Fisheries Society, Bethesda, MD.*
- Sprague, V. 1977. Systematics of microsporidia, pp. 1-30. *In: L.A. Bulla and T.C. Cheng (eds.), Comparative Pathobiology, Vol. 2. Plenum, New York.*
- Sprague, V. and R.L. Beckett. 1966. A disease of blue crabs (*Callinectes sapidus*) in Maryland and Virginia. *J. Invertebr. Pathol.* 8: 287-289.
- Sprague, V. and R.L. Beckett. 1968. The nature of the etiological agent of gray crab disease. *J. Invertebr. Pathol.* 11: 503.
- Sprague, V., R.L. Beckett, and T.K. Sawyer. 1969. A new species of *Paramoeba* (Amoebida, Paramoebidae) parasitic in the crab, *Callinectes sapidus*. *J. Invertebr. Pathol.* 14: 167-174.
- Stauber, L.A. 1950. The fate of India ink injected intracardially into the oyster, *Ostrea virginica* (Gmelin). *Biol. Bull. (Woods Hole)* 98: 227-241.
- Steere, N.V., Editor. 1971. Handbook of Laboratory Safety. 2d ed. CRC Press, Boca Raton, FL. 854 p.
- Steinberg, P.D. and V.S. Kennedy. 1979. Predation upon *Crassostrea virginica* (Gmelin) larvae by two invertebrate species common to Chesapeake Bay oyster bars. *Veliger* 22: 78-84.

Thompson, S.W. 1966. Selected Histochemical and Histopathological Methods. Charles C. Thomas Publ., Springfield, IL. 1639 p.

Tripp, M.R., L.A. Bisignani, and M.T. Kenny. 1966. Oyster amoebocytes in vitro. J. Invertebr. Pathol. 8: 137-140.

Trump, B.F., E.A. Smucker, and E.P. Benditt. 1961. A method for staining epoxy sections for light microscopy. J. Ultrastruct. Res. 5: 343.

Tubiash, H.S. 1971. Soft-shell clam, *Mya arenaria*, a convenient laboratory animal for screening pathogens of bivalve mollusks. Appl. Microbiol. 22: 321-324.

Tubiash, H.S., C.N. Shuster, Jr., and J.A. Couch. 1968. Anomalous siphons in two species of bivalve mollusks. Nautilus 81: 120-125.

Tubiash, H.S., S.V. Otto, and R. Hugh. 1971. Cardiac vibriosis, an infection of the American oyster, *Crassostrea virginica*. Bacteriol. Proc., p. 47.

U.S. Department of Labor, Occupational Safety and Health Administration. 2001. Code of Federal Regulations, No. 29, Parts 1910.1000-1450. National Archives and Records Administration, Washington DC. 572 p.

USDI (U.S. Department of the Interior). 1970. Black oyster found. News release, Fish Wildl. Serv., Bur. Commer. Fish., p. 2.

Uzmann, J.R. 1951. Record of the larval trematode *Himasthla quissetensis* (Miller and Northup, 1926) Stunkard, 1934 in the clam, *Mya arenaria*. J. Parasitol. 37: 327-328.

Uzmann, J.R. 1952. *Cercaria myae* sp. nov., a fork-tailed larva from the marine bivalve, *Mya arenaria*. J. Parasitol. 38: 161-164.

White, M.E. and E.A. Wilson. 1996. Predators, pests, and competitors, pp. 559-579. In: V.S. Kennedy, R.I.E. Newell, and A.F. Eble (eds.), The Eastern Oyster, *Crassostrea virginica*. Publ. UM-SG-TS-96-01, Maryland Sea Grant College, College Park, MD.

Williams, L.W. 1907. A list of the Rhode Island Copepoda, Phyllozoa, and Ostracoda, with new species of Copepoda. 37th Annu. Rep. Comm. Inland Fish. Rhode Island, Special Pap. No. 30: 69-79.

Wolfe, M.S. 1992. Giardiasis. Clin. Microbiol. Rev. 5: 93-100.

Wright, R.R. 1885. On a parasitic copepod of the clam. Am. Nat. 19: 118-124.

Yevich, P.P. and C.A. Barszcz. 1976. Gonadal and hematopoietic neoplasms in *Mya arenaria*. Mar. Fish Rev. 38(10): 42-43.

Yevich, P.P. and C.A. Barszcz. 1977. Neoplasia in softshell clams (*Mya arenaria*) collected from oil-impacted areas. Ann. N.Y. Acad. Sci. 298: 409-426.

Index

A

- Abbreviations
 abbreviations and definitions 199
 acronyms 198
 scientific 199
 U.S. state 200
- Abnormalities
 abscess 12, 16, 35
 edema 12, 15, 32
 gill lesions 12, 15, 30, 33
 pale digestive diverticulum 12, 15, 32
 pearls 12, 16, 35, 80
 pigmentations 12, 15, 33, 34
 watery cysts 12, 16, 35
- Acid alcohol 76, 105, 143
- Acid clean glassware 91, 143
- Acid fast
 acid-fast bacteria 86, 87, 124, 136
 acid-fast spores 87, 123, 136
 Cryptosporidium 161
 microsporidan 157
 stains for 87, 123, 124, 136
 substances 86, 123, 124, 136, 161
- Acronyms 198
- Adhesives 75, 76, 77, 118, 143, 151, 157, 184
 aminoalkylsilane 76, 118, 185
 Haupt gelatin 76
 Mayer's albumin fixative 76
 poly-L-lysine (PLL) 75, 118, 128, 143, 145, 151, 157, 185
 solubilized 184
- Agar-enrobing 185
- Alcian blue (AB) 85, 88, 92, 129
- Aldehyde blocking (dimedone) 63, 90, 127, 145
- Alizarin red S (ARS) 85, 87, 93, 129
- Anemones 11, 14, 28
- Argopecten irradians*
 cross-section 53
 gross anatomy 52
 processing 54
- Artificial seawater 60, 62, 63, 66, 144, 182
- Azure-eosin/Giemsa (AZE) 85, 87, 94, 95, 130

B

- Bacteria 169, 170, 171
 acid-fast 87, 124, 136
 chitinoclastic 152
 gram negative 85, 87, 101, 102, 131
 gram positive 85, 87, 97, 101, 102, 131
 Vibrio 169, 170
- Barnacles 11, 13, 28
- Blood
 bleeding procedures 144, 145
 systemic parasites 146, 147

- fixed tissue 85, 87, 94, 95
 fresh blood 87, 94, 120
 stains for 85, 87, 94, 95, 120, 130
- Blue crab 9, 12, 20, 36, 55, 56, 129, 133, 134, 151, 152, 153
 cytological technique 151
 in vivo technique 153
- Bryozoa 11, 14, 29
- Buffers
 Hanks' balanced salt solution 162
 McIlvaine-Lillie table 96
 Sorensen phosphate buffer 181, 182, 183

C

- Calcium, stains for 85, 86, 87, 93, 122, 129, 136
- Canada balsam resin 117, 137
- Ciliate culture 180
- Ciliates 15, 30, 59, 60, 63
 stains for 86, 87, 118, 135
- Clam leukemia. *See* Disseminated sarcoma
- Clams
 Arctica 18
 Baltic macoma clam 7, 17, 18
 processing 18, 45
 boring clam 11, 12, 24
 hematological procedures 145, 171
 histocytology 17, 145
 Mercenaria 17, 18, 46
 cross-section 47
 gross anatomy 46
 processing 18
 Mya 7, 17, 18, 129, 134, 136, 169
 care, handling, and maintaining 9
 collection 7
 cross-section 42
 gross anatomy 41
 processing 18, 43, 44
 parasites 30, 169, 170, 171, 172, 173, 174, 178
 Spisula 7, 17
 processing 17
 Cliona 11, 12, 23
- Collagen, stains for 85, 86, 87, 98, 109, 130, 132
- Collodion 90, 118, 128
- Conchiolin 11, 13, 27, 159, 160, 166
- Connective tissue 85, 86, 87, 98, 99, 109
 collagen 85, 86, 87, 97, 98, 109, 130, 132
 reticulum 85, 87, 99, 131
- Conversion tables 189
- Copepods 12, 14, 30, 170
- Copper 12, 15, 33
- Copper and other metals, stains for 86, 87, 108, 117, 132, 134
- Counterstains
 eosin B 104, 107
 eosin Y 104, 105, 106

eosin Y-phloxine B 104, 106, 113
light green SF yellowish 93, 103, 129
methylene blue 124, 136
picric acid/acetone 102
picromethyl blue 85, 97, 98, 101
safranin O 108
Coverslipping 89, 137, 141, 169
glycerin jelly 121
mounting media 121, 139, 141
 Advantage media 121, 138
 aqueous media 138
 glycerin jelly 121, 138
 natural resin 137
 synthetic resins 138, 185
problems and resolutions 139, 140
tools and techniques 137
Crabs 7, 9, 131
 blue crab 9, 12, 36, 129, 151
 disease agents 152, 153, 157
 dissection and histologic processing 20, 55, 56, 154
 hematological procedures 151, 153, 154, 157
 care, handling, and maintaining 9
 collection 7
 mud crab 12, 129
 Pinnotheres sp. 12, 14, 30
Crepidula 11, 14, 29
Cryosection technique 17, 57, 58
 stains 58, 86, 88, 106, 114, 121, 134, 135
Cryptosporidium 87, 123, 159, 161, 162, 163, 164, 167, 168
Crystalline style 17, 18, 19, 41, 44, 45, 46, 49, 50, 52, 53, 80

D
Decalcification 19, 82, 184
Diagnostic techniques 151, 179
 animal preparation 144, 145
 bivalve molluscs 143, 145, 169
 blue crab 157
 microscope technique (MFT) 153, 154
 ciliate culture 180
 Cryptosporidium 87, 123, 161, 162, 163, 164, 167, 168
 fluid thioglycolate medium ... 16, 18, 146, 148, 172, 173, 178, 179
 Haplosporidium nelsoni 145, 147, 148
 hematological 144, 145, 146, 147, 148, 151, 157, 161, 162, 171, 172, 173
 juvenile oyster disease (JOD) 159, 160
 Mer/Fluor 161, 162, 163, 167, 168
 Perkinsus marinus 148, 172, 173, 179
 softshell clam 169, 171, 172
Digestive diverticulum 12, 15, 32, 38, 39, 41, 42, 46, 47, 48, 50, 52, 53
Disease 12, 13, 15, 17, 20, 151
Disinfectants 7
Dissection 20, 55, 56
Disseminated neoplasia. *See* Disseminated sarcoma
Disseminated sarcoma 169, 171, 172, 174, 177
DNA extractions 61

DNA stain 85, 87, 98, 130
DNA techniques 57
Drill cases 27
Drill holes 27
Drills 12, 37

E

Edema 12, 15, 32
Electron microscopy (EM) 17, 59, 62, 63, 180, 181
 SEM 63, 183
 TEM 62, 63, 180, 181, 182
Embedding
 paraffin 69
 procedures 69, 73
 schedules 70
Endotoxin-free 143, 144, 153
Environmental compliance 2, 5

F

Fats, stains for 86, 87, 114, 134
Ferric iron 86, 88, 117, 134
Feulgen
 gram stain 60, 63, 85, 97
 picromethyl blue (FPM) stain 60, 63, 85, 87, 130
 reaction 97, 98, 111, 115, 116
Filing and slide storage 192
Fish 130, 132, 134, 135, 136
Fixation 11, 59, 153
 azure eosin 60, 94, 95, 96
 choice of fixative 59, 153
 ciliates 59, 60, 63
 Bouin's 60
 Bouin's/Davidson's 60
 glutaraldehyde (2%) 63
 cytologic detail 59, 65
 electron microscopy 59, 62, 63
Feulgen
 gram 60, 63, 97
 picromethyl blue (FPM) 60, 63, 98
 reaction 60, 63, 66, 145
field analyses 59
fixative guide for Giemsa 96
formulas 59, 60, 61, 62, 63, 64, 65
glycogen 59, 60
immunohistochemistry 59, 64
large tissues 60
light microscopy 59
malt periodic acid Schiff (MPAS) 60, 63
malt periodic acid Schiff-alcian blue (MPAS-AB) 60, 63
metachromatic staining 65
molecular analyses 59, 61, 64
nuclear detail 59, 65
periodic acid Schiff (PAS) 60, 63
problems and resolutions 66
protargol 60
protein 63, 65
protozoa 59, 60

trichrome stains	60	Hard clam	18, 46, 47, 48
Fixatives		Harris' hematoxylin and eosin (HHE)	
1% glutaraldehyde/4% formaldehyde .	63, 66, 135, 145, 181	(progressive stain)	86, 88, 104
applications	59	(regressive stain)	86, 88, 105
Bouin/Davidson's	60	frozen tissues	86, 88, 106
Bouin's	60	Heidenhain's iron hematoxylin (IHE)	86, 88, 107
cytological preps	59, 60, 61, 62, 63	Hemanalysis	
Davidson's	61, 66	staging criteria	147
ethanol	59, 61	Hematological procedures	144
glutaraldehyde (2%)	62	clams	171
glutaraldehyde for ciliates (2%)	63	<i>Cryptosporidium</i>	161, 167, 168
Helly's	64, 89	<i>Haplosporidium nelsoni</i>	148
mercury based	59, 64, 65, 66	<i>Perkinsus marinus</i>	146, 148
mercury substitute	59, 64	techniques for blue crab	157
methanol	59, 64	microscope technique	153
neutral buffered formalin	62	Hematopoietic neoplasm. See Disseminated sarcoma	
removal of mercury	89	Hemolymph	143, 153
Russell's modified-Zenker	64	examination by TEM	182
Z-Fix	64	examination of	148, 157, 167, 168
Zenker (acetic)	65, 89	parasites in crab hemolymph	153
Zenker (base)	64, 65, 89	<i>Hematodinium</i>	157
Zenker substitute	64	microsporidan	157
Fluid thioglycolate medium 16, 18, 146, 148, 172, 178, 179, 187		<i>Paramoeba</i>	157
Fouling organisms		Histocytology	143
anemone	11, 14, 28	clams	145, 172, 177
barnacles	11, 13, 28	endotoxin-free	144
bryozoa	11, 14, 29	mussels	145
<i>Crepidula</i>	11, 14, 29	oysters	145
<i>Molgula</i>	11, 14, 28	staging criteria	147
mussels	11, 13, 28	techniques for clams	171, 172, 177
sponges	11, 14, 29	teflon-coated slides	144, 145
tube worms	11, 14, 29	Histological techniques	
Frozen sections	17, 57	aldehyde blocking	63, 90, 127, 145
Fungi	152	clearing	89
stains for	85, 86, 88, 103, 115, 116, 132, 134	decalcification	19, 61, 82, 184
		dehydration	72, 89
		deparaffinize	89
		hydration	89
		mounting	89
		removal of mercury	89
G		I	
General tissue, stains for	86, 88, 104, 105, 113	Iodine solutions	
Gill lesions	12, 15, 30, 33	Gram's iodine	102
Glycogen	60	Lugol's iodine	66, 89, 97, 146, 148, 180, 187
stains for	86, 88, 110, 115, 116, 134	Iron, stains for	86, 88, 117, 134
Gomori's	85, 87, 99, 131		
Gonad	12, 15, 32, 38, 39, 41, 42, 46, 47, 52, 53	J	
Gonadal neoplasm. <i>See</i> Disseminated sarcoma		Juvenile oyster disease	22, 27, 159, 160, 166
Gram negative bacteria, stains for	85, 87, 101, 102, 131		
Gram positive bacteria, stains for	85, 87, 97, 101, 102, 131	K	
Gram stain (Brown and Brenn)	85, 101, 131	Knives	57, 77, 84
Gram stain (Brown and Hopps)	85, 87, 102, 131	cryostat	57
Grocott's methenamine silver stain (GMS)	85, 88, 103, 132	microtome	77
Gross examination. <i>See</i> Necropsy and examination of shellfish specimens		sharpening	77, 84
		tungsten carbide blades	77
H			
Handling live shellfish	7		
Hanks' balanced salt solution	162		
<i>Haplosporidium nelsoni</i>	13, 145, 147, 148		
staging criteria	147		

L	
Laboratory calculations	
molar solutions	190
normal solutions	191
percent solutions	190
temperature conversion	191
Larvae, shellfish	19
Laser capture microdissection	59, 61, 78, 113
Lugol's iodine. <i>See</i> Iodine solutions: Lugol's iodine	
M	
Maladie du pied	11, 13, 25
Mallory's hematein stain	86, 87, 108, 132
Mallory's trichrome stain	86, 87, 132
Malt periodic acid Schiff stain (MPAS)	63, 86, 88, 110, 133
Malt periodic acid Schiff-alcian blue stain	86, 88, 111, 133
Mantle recession	11, 12, 22, 23, 160
Mayer's hematoxylin and eosin stain (MHE)	86, 88, 113, 133, 153
McIlvaine-Lillie buffer table	96
<i>Mercenaria</i>	
cross-section	47
gross anatomy	46
processing	48
Mercury	
based fixative	64, 65
removal	89
substitute fixative	64
MerIFluor	161, 162, 163, 167, 168
Metal stains	
Mallory's hematein	86, 87, 108, 132
Perls' Prussian blue	86, 88, 117, 134
Molecular analyses	59, 61, 70, 78
<i>Molgula</i>	11, 14, 28
Mounting media	137, 138, 141
Advantage mounting media	121, 138
aqueous media	138
Canada balsam	117, 137
glycerin jelly	121, 138
natural resin	137
Permout	138, 145
Rapid Mount	185
synthetic resins	138, 185
Mucopolysaccharides, stains for	86, 88, 92, 110, 111, 115, 116, 133, 134
malt periodic acid Schiff (MPAS)	110, 133
malt periodic acid Schiff-alcian blue	86, 111, 133
periodic acid Schiff (PAS)	86, 88, 115, 134
periodic acid Schiff (PAS) with Heidenhain's	116
Mud worm	11, 13, 14, 15, 24
Mussels	
byssus	19, 80
cross-section	50
fouling organisms	13, 28
gross anatomy	48, 55
hematological procedures	145
histocytology	145
<i>Mytilus</i>	19
processing	19–21, 51, 145
<i>Mya</i>	7, 9, 18, 42, 169
cross-section	42
gross anatomy	41
processing	43, 44
<i>Mytilicola</i> sp.	12, 14, 30
<i>Mytilus edulis</i>	
cross-section	50
gross anatomy	48, 55
processing	19, 51
N	
Necropsy and examination of shellfish specimens	11–21
fouling organisms	11
gross abnormalities	12
obvious parasites	12
physiological indicators	12
predators	12
processing procedures	11
shell abnormalities	11
Nuclear detail	59, 65
stains for	86, 88, 107, 116
O	
Oil red O (ORO) stain	86, 87, 114, 134
Oxford slides	144, 145
Oysters	7, 16, 131, 132, 133, 136
abnormalities	22, 23, 24, 25, 26, 27, 28, 33, 34
collection	7
condition	12, 15, 31
cross-section	39
<i>Cryptosporidium</i>	87, 159, 161, 162, 163, 167, 168
drilling	17, 38, 145
fouling organisms	29
gill lesions	12, 30, 33
gross anatomy	38
<i>Haplosporidium costale</i>	136
<i>Haplosporidium nelsoni</i>	13, 147, 148
hematological procedures	145
histocytology	145
juvenile oyster disease (JOD)	27, 159, 160
mortality	160
parasites	11, 12, 13, 14, 27, 30, 60, 63, 131, 132, 135, 136, 143, 145, 147, 148, 159, 160, 166, 179, 180, 187
<i>Perkinsus marinus</i>	146, 179, 187
processing	16–21, 40, 144
P	
Pale digestive diverticulum	12, 15, 32
Parasites	11, 12, 151, 170, 171
bacteria	170
barnacle <i>Loxothylacus texanus</i>	152
bloodborne	151
chitinoclastic bacteria	152
ciliates	12, 15, 30, 59
copepods	12, 14, 30, 170

fungus <i>Lagenidium callinectes</i>	152	hard clam	46, 47, 48
<i>Haplosporidium costale</i>	136	juvenile oyster disease (JOD)	22, 27, 166
<i>Haplosporidium nelsoni</i>	13, 147, 148	maladie du pied	25
<i>Haplosporidium</i> sp.	154	Mallory's hematein	132
<i>Hematodinium</i>	152, 153, 157	Mallory's trichrome	132
leech <i>Myzobdella lugubris</i>	152	malt periodic acid Schiff (MPAS)	133
<i>Microsporidan</i>	152, 153, 157	malt periodic acid Schiff-alcian blue (MPAS-AB)	133
<i>Mytilicola</i> sp.	12, 14, 30	mantle recession	22, 23
nemertean <i>Carcinonemertes carcinophila</i>	152	Mayer's hematoxylin and eosin (MHE)	133
<i>Paramoeba</i>	152, 157	melanin in oyster	34
<i>Perkinsus marinus</i>	146, 147, 148, 187	mud crab	36
<i>Perkinsus</i> spp.	170, 178	<i>Mytilicola</i> sp.	30
<i>Pinnotheres</i> sp.	12, 14, 15, 30	obvious parasites	30
proliferative disorders	170	oil red O (ORO)	134
reo-like virus (RLV)	152	other gross abnormalities	35
rickettsia-like organisms	170, 177	oyster 22, 23, 24, 25, 26, 27, 28, 29, 30, 31, 32, 33, 34, 35, 38, 39, 40	
trematodes	170	oyster drill	37
viruses	153, 170	pale digestive diverticulum	32
bi-facies virus (BFV)	152	pearls	35
Chesapeake Bay virus (CBV)	152	periodic acid Schiff (PAS)	134
Pathogens		Perls' Prussian blue	134
<i>Cryptosporidium</i>	87, 123, 159, 161, 162, 163, 167, 168	physiological conditions	31, 32, 33, 34
<i>Giardia</i>	159, 161, 162, 163	<i>Pinnotheres</i> sp.	30
Pearls	12, 16, 35, 80	<i>Polydora</i> sp.	24
Periodic acid Schiff (PAS) stain	86, 88, 115, 134	predators	36, 37
Heidenhain's hematoxylin counterstain	86, 88, 116	processing	
<i>Perkinsus</i>	178	Baltic clam	45
tissues to test	178	bay scallop	54
<i>Perkinsus marinus</i>	146, 148, 179, 187	blue crab	56
staging criteria	147	blue mussel	51
Perls' Prussian blue stain	86, 88, 117, 134	hard clam	48
Phospholipids	87	oysters	40
Photographs		soft clam	43, 44
alcian blue	129	protargol	135
alizarin red S (ARS)	129	scallop	35, 52, 53, 54
azure-eosin/Giemsa	130	sectioning	82
Baltic clam	45	shell abnormalities	22, 23, 24, 25, 26, 27
blue crab	36, 54	soft clam	32, 41, 42, 43, 44
blue mussel	35, 48, 50, 51	starfish	37
boring clam	24	toadfish	36
ciliates	30, 135	toluidine blue O (TBO)	135
clam	30	transfer of paraffin-embedded tissue	188
<i>Cliona</i> sp.	23	Von Kossa	136
copper in oyster	33	Ziehl-Neelsen and Harris' hematoxylin (ZHH)	136
coverslipping	141	Ziehl-Neelsen and methylene blue	136
detection of <i>P. marinus</i> by hemanalysis	148	Physiological indicators	12
detection of <i>P. marinus</i> from rectal tissue	187	condition	12, 15, 31
diagnosis of <i>Cryptosporidium</i> from oysters	167, 168	edema	12, 15, 32
diagnostic techniques for blue crabs	157	gill lesions	15, 33
embedding	73	gonad	12, 15, 32
examination of oyster hemolymph	148	new shell growth	12, 16, 34
Feulgen picromethyl blue (FPM)	130	pale digestive diverticulum	12, 15, 32
flatworms	37	pigmentations	12, 15, 33, 34
fouling organisms	27, 28, 29	Pigmentation	
Gomori's	131	copper	12, 33
Gram stain	131	diapedesis	12, 34
Grocott's methenamine silver (GMS)	132		

melanin	12, 15, 34
<i>Polydora</i>	11, 13, 15, 24
Predators	12, 16
black drum	12
blue crab	12, 36
conchs, whelks	12
drills	12, 37
flatworms	12, 37
mud crabs	12, 36
starfish	12, 37
toadfish	12, 36
Processing	11, 16, 17, 18, 19, 20
bivalve larvae	19
blue crabs	20, 55, 56
clams	43, 44, 45, 48
hard clams	18, 46, 47, 48
mussels	19, 48, 50, 51, 55, 145
oysters	16, 17, 38, 39, 40, 144
procedures	11
scallops	19, 52, 53, 54
softshell clams	18, 41, 42, 43, 44
surf clams	17
Proliferative disorders	170
Protargol stain	86, 87, 118, 128, 135
Protein analyses	57
Protozoa	152, 153, 169, 170, 172, 173, 174

R

Recordkeeping	192
data sheets	193–196
Resins	
Canada balsam	137
Permout	138
Rapid Mount	185
Spurr	181, 183
Reticulum, stains for	85, 87, 99, 131
Rickettsia-like	170, 174, 177
RNA techniques	57

S

Safety	1, 5
chemical compatibility	2
chemical disposal	3
chemical fume hoods	3
chemical hygiene plan	1
chemical inventory	3
chemical labeling	2
code of federal regulations (CFR)	1
environmental compliance	1, 2, 3
Environmental Protection Agency (EPA)	1, 3
hazard assessment	1
hazard communication standard (HAZCOM)	1
health hazards	3, 4
laboratory standard	1
material safety data sheets (MSDSs)	2
Nat'l Institute for Occupational Safety and Health	1
Occupational Safety and Health Admin. (OSHA)	1, 5

personal protective equipment (PPE)	1
websites	5
Sarcoma. <i>See</i> Disseminated sarcoma	
Scallops	7, 19
<i>Argopecten</i>	19
cross-section	53
gross anatomy	52
<i>Placopecten</i>	19
processing	54
sensory eyes	19, 54, 80
Scanning electron microscopy	183
Scientific and common names	197
Seawater	
ambient	60, 61, 62, 63
artificial	60, 63, 66, 144, 182
Sectioning	
adhesives	
aminoalkylsilane	76, 118, 185
Haupt gelatin	76
Mayer's albumin	76, 78, 128, 185
poly-L-lysine (PLL)	75, 118, 128, 145, 151, 154
agar-enrobing	185
frozen sections	57
paraffin	75, 78
problems and resolutions	17, 80, 81, 82
procedures	73
requirements	75
serial sections	78, 184, 188
Shell abnormalities	11, 12
calcareous malformations	11, 13, 26
<i>Cliona</i>	11, 12, 23
conchiolin deposits	11, 13, 27, 160, 166
<i>Diplothyra smithii</i>	11, 12, 24
drill cases	11, 13, 27
drill holes	11, 13, 27
maladie du pied	11, 13, 25
mantle recession	11, 12, 22, 23
mud blisters	25
<i>Polydora</i> sp.	13, 24
shell and mud blisters	11, 13, 25
shell checks	11, 12, 22, 160, 166
shell pustules	11, 13, 26
Shell checks	11, 12, 22, 160, 166
Shellfish	
care, handling, and maintaining	8, 9
Shellfish larvae	19
Shipping instructions	8
Slides	143, 144
coatings for	
albumin	128, 185
aminoalkylsilane	76, 118, 185
collodion	90, 118, 128
Mayer's albumin	76
poly-L-lysine (PLL)	75, 118, 128, 143, 151, 154, 157, 185
storage	192
teflon coated	162, 163
Oxford	144

Softshell clams	7, 9, 18, 42, 43, 44, 129, 134, 136
Sorensen phosphate buffer	181, 182, 183
Special techniques	
agar enrobing	185
aldehyde blocking	90
deactivation of ammoniacal silver solutions	91
decalcification	184
pre-staining	89
removal of Bouin's fluid	90
removal of formaldehyde	89
removal of mercury	89
scanning electron microscopy	183
transfer of tissues	184
from broken slides	184
from paraffin to plastic	185
transmission electron microscopy	182, 183
Species	
anemones	
<i>Diadumene leucolena</i>	14
<i>Haliplanella luciae</i>	14
bacteria	170
chitinoclastic	152
<i>Vibrio anguillarum</i>	15
ciliates	
<i>Hypocomella</i>	15
<i>Sphenophrya</i>	15
clams	
<i>Arctica</i> sp.	18
<i>Diplothyra smithii</i>	12, 24
<i>Macoma</i>	18, 30, 45
<i>Mercenaria</i>	18, 46
<i>Mya arenaria</i>	18, 32, 43, 44
<i>Spisula</i> sp.	17
crabs	9
blue crab	12, 54
mud crab	12
<i>Pinnotheres</i> sp.	14, 15, 30
Crustacea	
<i>Callinectes sapidus</i>	12, 151
copepods	170
<i>Loxothylacus texanus</i>	152
<i>Mytilicola</i> sp.	12, 30
<i>Pinnotheres</i> sp.	12, 14, 15, 30
drills	
<i>Urosalpinx cinerea</i>	12
flatworms	
<i>Stylochus ellipticus</i>	12
trematodes	170
fungus	
<i>Lagenidium callinectes</i>	152
miscellaneous	
<i>Asterias forbesi</i>	12
<i>Busycon carica</i>	12
<i>Callianassa</i> sp.	12
<i>Crepidula fornicata</i>	11, 14
<i>Crepidula plana</i>	14
<i>Molgula</i> sp.	7, 11, 14, 28
<i>Opsanus tau</i>	12
<i>Polydora</i> sp.	13, 15, 24
sea squirts. <i>See</i> Species: miscellaneous: <i>Molgula</i> sp.	
mussels	
<i>Gukensia</i> sp.	7
<i>Ischadium recurvum</i>	28
<i>Modiolus</i> sp.	7
<i>Mytilus</i> sp.	13, 19, 35, 48, 51
oysters	
<i>Crassostrea</i> sp.	16
<i>Crassostrea virginica</i>	13, 22, 31, 38
<i>Ostrea</i> sp.	16
protozoa	170
<i>Cryptosporidium</i>	159, 161, 162, 163, 164
<i>Giardia</i>	159, 161
<i>Haplosporidium nelsoni</i>	13, 147
<i>Hematodinium</i>	152
microsporidan	152, 157
<i>Paramoeba pernicioso</i>	152
<i>Perkinsus marinus</i>	146, 147, 187
<i>Perkinsus</i> sp.	16, 18, 19
rickettsia-like organisms	170
scallops	
<i>Argopecten irradians</i>	35, 52, 53, 54
<i>Argopecten</i> sp.	19
<i>Placopecten</i> sp.	7, 19
sponges	
<i>Cliona</i> sp.	11, 12, 23
<i>Microciona prolifica</i>	14
viruses	170
bi-facies	152
Chesapeake Bay virus (CBV)	152
reo-like	152
worms	
leech	152
nematode	152
Specimen collection	7
Staining	85
acid clean glassware	91
aldehyde blocking technique	90
clear	89
collodion coating for slides	90, 118
dehydrate	89
deparaffinize	89
fixative guide for Giemsa stain	96
hydrate to water	89
laser capture microdissection	113
listing of stains, alphabetical	85
listing of stains, functional	87
methods and use	85
mount	89
paraffin-embedded sections	89
pre-staining techniques	89
removal of Bouin's fluid	90
removal of formaldehyde fixation artifacts	89
removal of mercury	89

Stains	
alcian blue	85, 88, 92, 129
alizarin red S (ARS)	85, 87, 93, 129
azure eosin	60
azure-eosin/Giemsa (AZE)	85, 87, 95, 130
counterstains	
eosin B	104
eosin Y	105
eosin Y-phloxine B	106, 113
light green SF yellowish	93, 103
methylene blue	124
picric acid/acetone	102
picromethyl blue	97, 98
safranin O	108
Feulgen	
gram	60, 63, 85, 97
picromethyl blue (FPM)	60, 63, 85, 130
reaction	60, 63, 66
Gomori's	85, 99, 131
Gram	
(Brown and Brenn)	85, 87, 101
(Brown and Hopps)	85, 87, 102, 131
Grocott's methenamine silver (GMS)	85, 88, 132
Harris' hematoxylin and eosin (HHE)	
for frozen tissue	86, 88, 106
progressive stain	86, 88, 104
regressive stain	86, 88, 105
Heidenhain's iron hematoxylin and eosin (IHE)	86, 88, 107
Mallory's hematein	86, 87, 108, 132
Mallory's trichrome	86, 87, 132
malt periodic acid Schiff	
(MPAS)	60, 63, 86, 88, 110, 133
alcian blue (MPAS-AB)	60, 63, 86, 88, 111, 133
Mayer's hematoxylin and eosin	86, 88, 113, 133
oil red O (ORO)	86, 114, 134
periodic acid Schiff (PAS)	60, 63, 86, 88, 115, 134
Heidenhain's hematoxylin	86, 88, 116
Perls' Prussian blue	86, 88, 117, 134
protargol	86, 87, 118, 135
toluidine blue O (TBO)	86, 87, 88, 120, 121, 135
Von Kossa	86, 87, 122, 136
Ziehl-Neelsen	
and Harris' hematoxylin (ZHH)	86, 87, 123, 136
and methylene blue (AFB)	86, 87, 124, 136
Stains for specific tissues and tissue elements	
acid-fast bacteria	86, 87, 124, 136
acid-fast spores	86, 87, 123, 136
acid-fast substances	87, 136, 161
blood	87, 94, 95, 120, 130
calcium	85, 86, 87, 93, 122, 129, 136
chitin	129
cilia	86, 87, 118
ciliates	98, 107, 118, 135
collagen	85, 86, 87, 98, 109, 130, 132
connective tissue	85, 86, 87, 98, 99, 109, 131
copper and other metals	86, 87, 108, 117, 132
<i>Cryptosporidium</i>	161
DNA	85, 87, 98, 130
fats and phospholipids	86, 87
ferric iron	86, 88, 117, 134
frozen tissue	86, 106, 121, 134, 135
fungi	85, 103, 115, 116, 132, 134
general tissue	86, 104, 105, 113, 133
glycogen	86, 88, 115, 116, 134
gram-negative bacteria	87, 101, 102, 131
gram-positive bacteria	87, 95, 101, 102, 131
microsporidan	157
mucopolysaccharides	88, 92, 110, 111, 115, 129, 133, 134
nuclear detail	86, 88, 107
PAS-positive substances	110, 111, 115, 116, 133
reticulum	87, 99, 131
<i>Stylochus</i>	12, 37
Suspension chambers	143, 148, 153, 171
T	
Toluidine blue O stain (TBO)	86, 87, 88, 120, 121, 135
Transfer of tissues	
transfer from broken slide or serial section	184, 188
transfer from histological slides for TEM	183
transfer from paraffin to plastic	185, 188
Trematodes	170
U	
<i>Urosalpinx cinerea</i>	12
US/metric conversion table	189
V	
Viruses	170
bi-facies	152
Chesapeake Bay	152
reo-like	152
Von Kossa stain	86, 87, 122, 136
W	
Water samples	
<i>Cryptosporidium</i>	163
X	
Xenoma	15, 30, 60, 135
Z	
Ziehl-Neelsen	
and Harris' hematoxylin stain (ZHH)	86, 87, 123, 136
and methylene blue stain (AFB)	86, 87, 124, 136
for <i>Cryptosporidium</i>	161