

# The Renal Parenchyma Evaluation: MAG3 vs. DMSA

Aleksandar Smokvina<sup>1</sup>, Svjetlana Grbac-Ivanković<sup>1</sup>, Neva Giroto<sup>1</sup>, Mirna Subat Dežulović<sup>2</sup>,  
Giordano Saina<sup>3</sup> and Marina Miletić Barković<sup>4</sup>

<sup>1</sup> Department of Nuclear Medicine, University Hospital Center Rijeka, Rijeka, Croatia

<sup>2</sup> Department of Pediatrics, University Hospital Center Rijeka, Rijeka, Croatia

<sup>3</sup> Department of Radiology, University Hospital Center Rijeka, Rijeka, Croatia

<sup>4</sup> Orthopedic Hospital, Lovran, Croatia

## ABSTRACT

*Scintigraphy with Tc-99m dimercaptosuccinic acid (DMSA) is considered a reference method for assessment of parenchymal lesions and estimation of differential kidney function. The aim of study was to evaluate Tc-99m mercaptoacetyltriglycine (MAG3) dynamic renal scintigraphy for the same purpose. 188 patients, submitted to both studies within three months, were divided in two groups. In the first, 83 DMSA images were compared to parenchymal phase of MAG3 scintigraphy. Kidney morphology was independently evaluated by four observers. In the second group (N=105), differential function was calculated in MAG3 and DMSA studies and the respective results were compared. Findings corresponded completely in 85% of patients. There were no statistically significant differences between calculated differential function on DMSA and MAG3 images. The results showed that most of parenchymal lesions detected on DMSA scans can be identified on MAG3 parenchymal scans. Both studies can be equally used for the calculation of differential kidney function.*

**Key words:** renal parenchyma, differential kidney function, mercaptoacetyltriglycine, MAG3, dimercaptosuccinic acid, DMSA

## Introduction

Functional and morphological investigations with radionuclides play a prominent role in the diagnostics and follow up of various kidney diseases<sup>1,2</sup>. Tc-99m mercaptoacetyltriglycine (MAG3) scintigraphy has been used for that purpose for more than ten years<sup>3–10</sup>. Tc-99m dimercaptosuccinic acid (DMSA) scintigraphy has been considered the investigation of choice in the assessment of renal cortical lesions<sup>11</sup> for almost 30 years. Other non-invasive procedures such as intravenous urography (IVU) and ultrasound (US) are considered less sensitive in detection of cortical lesions<sup>12–18</sup>, the former at the same time delivering higher radiation dose<sup>19</sup>. Computed tomography (CT) has sensitivity and specificity similar to those of cortical scintigraphy for the detection of acute pyelonephritis but, carries the risk of contrast reaction and has a considerably higher radiation exposure, as well. Magnetic resonance imaging is a promising but expensive and not widely available nonionizing method of visualizing pyelonephritis<sup>20</sup>.

Dynamic scintigraphy with MAG3 gives an insight in kidney function and morphology<sup>21–23</sup>. The initial part of the study, the parenchymal phase, reflects the distribution of functional parenchyma, allowing the detection of reversible or irreversible lesions. Some authors still consider the evaluation of the renal parenchyma with MAG3 in only one-posterior-projection less reliable than DMSA, where multiple projections are available<sup>24,25</sup>. On the other hand, DMSA provides no information about the collecting system and urodynamics, and in comparison with MAG3, delivers higher radiation dose.

DMSA scintigraphy is also generally accepted procedure for estimation of differential kidney function, but from recently, MAG3 has been introduced for the same purpose<sup>26,27</sup>.

The objective of this paper was to examine the reliability of renal parenchyma evaluation and calculation of differential renal function with MAG3 in comparison to DMSA.

## Patients and Methods

Between January 1988 and December 2002, 188 patients who had undergone DMSA and MAG3 scintigraphy within 3 months as part of their clinical workup at the University Hospital Centre Rijeka, were selected for this retrospective study. They were referred by nephrologists, urologists and/or pediatric nephrologists.

DMSA study had been requested first when cortical lesions were suspected in patients with urinary tract infection. MAG3 was additionally performed when findings were equivocal or when the need for more information on function and/or urodynamics appeared. When patients had been referred firstly to MAG3 dynamic scintigraphy and a parenchymal lesion was found, DMSA was performed to confirm or exclude the lesion.

The first group, where parenchymal images were analyzed, included 83 patients (57 females, 26 males, mean age 34.5 years, range 2–81 years), 34 of them were children (14 under 7 yrs, 20 between 7 and 15 yrs, mean age 7 years).

The second group, for purposes of differential function calculation, included another 105 patients, 55 of them children under 15 years of age (19 under 7 yrs., 36 between 7 and 15 yrs, mean age 6.5 yrs.) and 50 adults (mean age 38 yrs).

In the population of children (N=89) from both groups, 66 had urinary tract infection including acute and chronic pyelonephritis, half of them with proved vesico-urethral reflux. Obstructive or dilatative nephropathies were present in 9 and other diagnoses (mostly congenital anomalies) in 14 patients.

In the adult population (N=99) 30 patients had urinary tract infection and 13 obstructive or dilatative nephropathies. Hypertension was present in 26 and other diagnoses in 30 patients (tumors, cysts, and unilateral poor function).

All patients or their parents were informed about the diagnostic procedures and gave their written consent.

### Data acquisition

DMSA imaging started 2–3 hours after intravenous injection of 74–100 MBq Tc-99m DMSA. Dose activities for children were calculated according to the Pediatric Task Group recommendations<sup>28</sup>. The lowest activity used was 18 MBq. Subjects were imaged in standard projections (posterior, posterior oblique, anterior, and lateral) with a low-energy, all-purpose collimator, 200 seconds per view in a 256 x 256 matrix. Only the posterior views were used for differential function calculation and comparison with MAG3.

The dynamic study started immediately after administration of 2 MBq/kg of Tc-99m MAG3 to a well-hydrated subjects. Activities for children were calculated as mentioned above<sup>28</sup>; sedation was not used. The data were acquired with patients lying supine, in a posterior projection, for 30 min, 30 sec per frame, in a 128 x 128 matrix, using the same equipment. First 3 or 4 frames

summed in a composite parenchymal image were used for analysis. In cases of poor visualization of parenchyma, additional frames were included, thus enabling better definition of equivocal lesions.

### Data analysis

Images were analyzed from a high-resolution monitor capable for gray and eight color scale presentations, with positive and negative variant. The manual regions of interest (ROIs) were created tracing kidney contours, and each was divided in 6 sub regions to make analysis easier and more accurate (Figure 1).

The distribution of parenchymal activity and outlines were interpreted as normal (Figure 2), equivocal or as a clear lesion.

A renal contour defect with a corresponding photopenic area, or a clear »cold area« within renal parenchyma, with or without contour defect was defined as a clear parenchymal lesion (Figure 3). Lesions that did not meet those criteria were considered equivocal.

All studies were analyzed separately, by four observers. MAG3 parenchymal phase images were presented to each observer, for evaluation of parenchymal lesions. Some time later, posterior DMSA images were presented to all observers, blinded for the results of the first analysis and the respective clinical data. After that, DMSA and MAG3 images of the same subject were presented together for comparison. Two possibilities of interpretation were offered: no visual difference between the two scans, and substantial differences in parenchymal distribution of activity and/or edge definition.

In the second group of patients differential renal function was calculated according to the standard equation:

$$\text{LROI} / (\text{LROI} + \text{RROI}) \times 100\% = \text{DF}\% \text{ of left kidney}$$

Irregular regions of interest were manually drawn over the left (LROI) and right (RROI) kidney, on DMSA

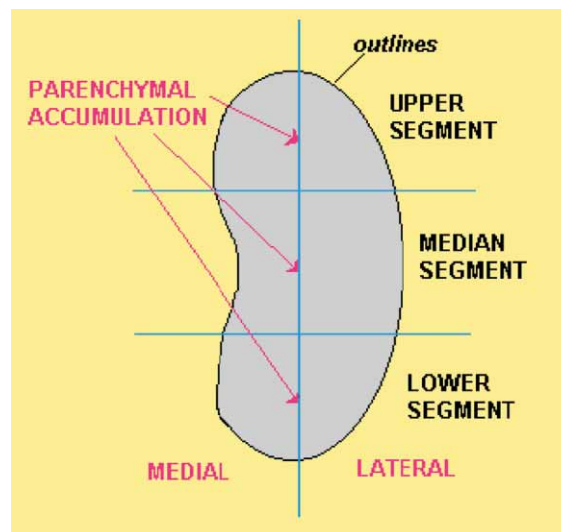


Fig. 1. Kidney segments for easier visual interpretation and localization of parenchymal lesions.




Fig. 2. Normal parenchymal accumulation in both kidneys on the DMSA (left) and MAG3 (right) scan in the same patient.

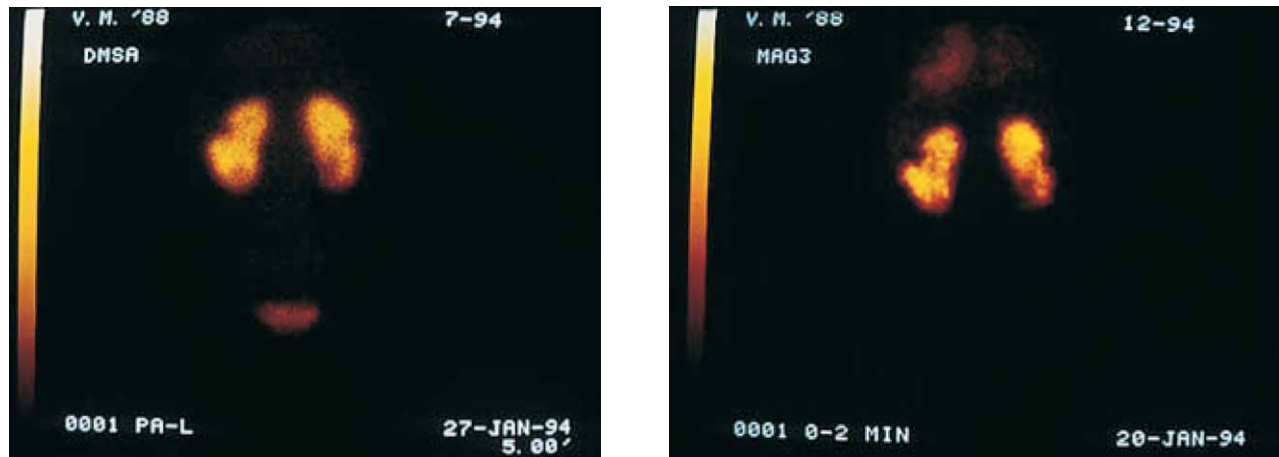


Fig. 3. Multiple clear parenchymal lesions and changes of contours on the DMSA (left) and MAG3 (right) scan in the same patient.

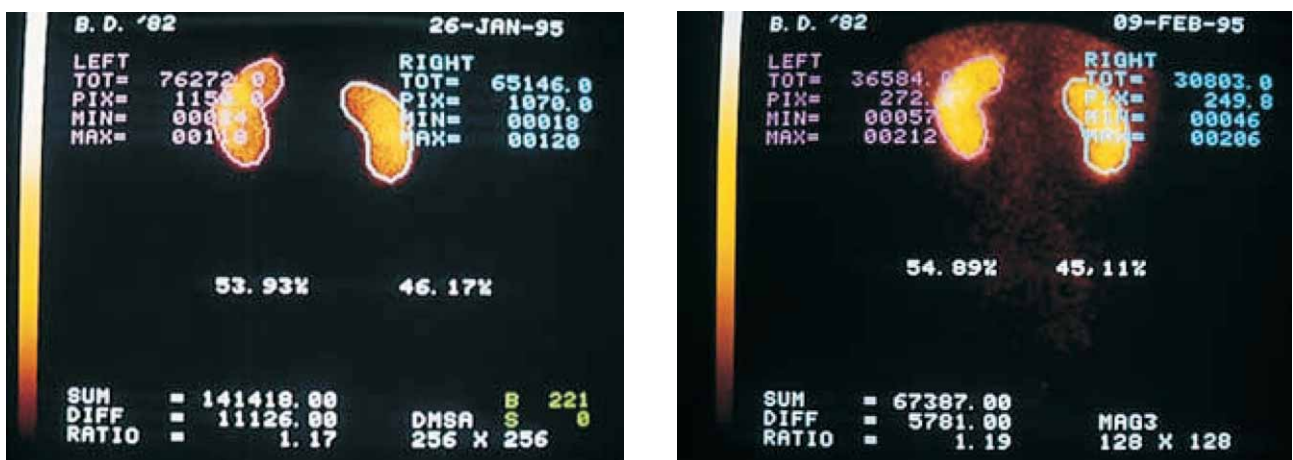

Fig. 4. Normal DMSA (left) and MAG3 (right) scans, regions of interest and calculated differential function in the same patient.

scan in posterior projection and parenchymal phase of MAG3 study. Summed counts were used for the calculation in the equation above (Figures 4 and 5).

For the evaluation of differential function (N=105) a paired t-test and  $\chi^2$  test were used.



Fig. 5. Parenchymal defects presented in DMSA (left) and MAG3 (right) scans, regions of interest and calculated differential function in the same patient.

**Results**

Correspondence in visual interpretation of parenchymal defects with MAG3 and DMSA was present in 85–89% of patients in group I (Table 1).

All observers identified the same 18 kidneys with clear parenchymal lesions on DMSA scans. Those were all detected on MAG3 parenchymal scan, as well. Furthermore, two observers detected a greater number of clear parenchymal lesions on MAG3 scans, which were interpreted as equivocal on DMSA scan (Table 2). When clear lesions were detected on MAG3 scan, findings were never interpreted as normal on DMSA.

**TABLE 1**  
COMPLETE VISUAL CORRESPONDENCE BETWEEN DMSA AND MAG3 SCANS IN THE GROUP I (N=83), INTERPRETED BY 4 OBSERVERS (A–D)

Observer	Patients with complete correspondence between DMSA and MAG3 scans (group I, N=83)	%
A	74	89
B	71	85
C	73	88
D	74	89

**TABLE 2**  
NUMBER OF PATIENTS WITH CLEAR PARENCHYMAL DEFECTS IN THE FIRST GROUP I, (N=83), DETECTED BY 4 OBSERVERS (A–D)

Observer	Patients with clear parenchymal lesions (group I, N=83)	
	DMSA	MAG3
A	18	18
B	18	23
C	18	18
D	18	19

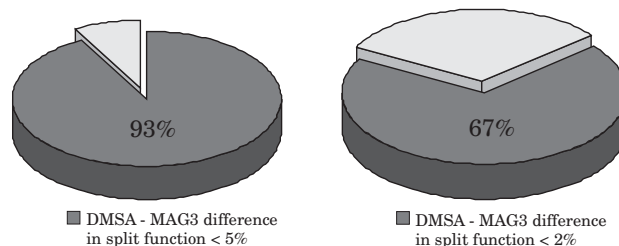


Fig. 6. Difference between differential kidney functions calculated by two methods (DMSA and MAG3), in the second group (N=105), in relation to percentage kidney function.

The estimated mean difference between split renal functions calculated from two studies (group II, N=105) was  $0.3 \pm 2.72\%$ , which was not statistically significant ( $p > 0.05$ ). In 69 patients (67%) the difference in estimation of differential function between the two procedures was  $< 2\%$ . Moreover, in 93% of patients individual kidney function differed less than 5%.

In the group of patients where the percentage function of one kidney was abnormal ( $< 45\%$ ) there were significantly more patients (chi-square = 7.92,  $p < 0.01$ ) with greater inter-method difference ( $> 2\%$ , Figure 6).

**Discussion**

This study showed that all clear parenchymal lesions seen on DMSA were detected on the parenchymal phase MAG3 image. There were no statistically significant differences between estimated differential kidney function on DMSA and MAG3, either.

This supports the idea of different approach to nuclear diagnostic procedures in the underlying field of indications. Replacing DMSA with MAG3 in initial assessment of a patient would provide simultaneous information on

kidney function, drainage and split function, at the same time lowering the radiation exposure<sup>24,30–32</sup>.

In clinical practice and treatment, especially during urinary tract infections, it is important to give an unequivocal answer whether clear renal focal lesions do or do not exist.

Although intravenous urography enables visualizing of collecting system, and together with ultrasound provides some information on kidney morphology, quantitative data on kidney function are missing. DMSA scintigraphy is considered the most sensitive method to prove existence of parenchymal damage due to acute or chronic pyelonephritis and provides data on differential kidney function<sup>25,29</sup>. However, the performances of MAG3 scintigraphy for the same purposes have not been investigated by many authors<sup>24,32</sup>.

The first part of study was based on visual interpretation of scans. The major problem of that kind of interpretation is partially due to non-existence of a recognized standard, which can be illustrated by the recent multicentric study. Among forty-two experienced nuclear medicine physicians, who were asked to read 49 DMSA kidney scans, there were even those who clear parenchymal lesion considered a normal finding<sup>33</sup>.

It is beyond question that kidney outlines are more clearly visualized on DMSA scan compared to MAG3, probably due to different matrices used in the acquisition of the two studies. However, the quality of MAG3 image can significantly approach DMSA by adding a few frames to compose the parenchymal phase image.

## REFERENCES

- GORDON, I., Pediatric aspects of radionuclides in nephrourology. In: MURRAY, I., P. ELL (Eds.): Nuclear medicine in clinical diagnosis and treatment. (Churchill Livingstone, London, 1998).
- VAN DE FLIERDT, E., H. R. LANGHAMMER, Static renal scintigraphy. In: HÖR, G., H. W. PABST (Eds.): Kidney / Niere. (Gustav Fischer Verlag, Stuttgart, Jena, New York, 1996).
- BLAHA, V., I. CIHAK, F. NICEK, Nucl. Med. Biol., 20 (1993) 89.
- FRITZBERG, A. R., S. KASINA, D. ESHIMA, D. L. JOHNSON, J. Nucl. Med., 27 (1986) 111.
- KABASAKAL, L., H. T. TUROGLU, C. ONSEL, K. OZKER, I. USLU, T. CANSIZ, K. SONMEZOGLU, E. ALTIOK, A. T. ISITMAN, J. Nucl. Med., 36 (1995) 224.
- RUSSELL, C. D., A. T. TAYLOR, E. V. DUBOVSKY, J. Nucl. Med., 37 (1996) 588.
- TAYLOR, A., J. NALLY, Am. J. Roentgenol., 164 (1995) 34.
- TAYLOR, A., Semin. Nucl. Med., 12 (1999) 102.
- WEISS, A., Semin. Nephrol., 18 (1998) 264.
- WOOLFSON, R., G. NEILD, Eur. J. Nucl. Med., 24 (1997) 557.
- PUSUWAN, P., L. REYES, I. GORDON, Eur. J. Nucl. Med., 26 (1999) 438.
- BAILEY, R., K. LYN, R. ROBSON, A. SMITH, T. MALING, J. TURNER, Clin. Nephrol., 46 (1996) 99.
- BJORGVINSON, E., M. MAJD, K. D. EGGLI, Am. J. Roentgenol., 157 (1991) 539.
- GOLDRAICH, N. P., O. L. RAMOS, I. H. GOLDRAICH, Pediatr. Nephrol., 3 (1989) 1.
- HANDMAKER, H., B. W. YOUNG, J. M. LOWENSTEIN, J. Nucl. Med., 16 (1975) 28.
- HANDMAKER, H., Semin. Nucl. Med., 12 (1982) 246.
- O'REILLY, P., D. OSBORN, H. TESTA, B. M. J., 282 (1981) 943.
- SMELLIE, J. M., S. P. A. RIGDEN, N. P. PRESCOD, Arch. Dis. Child., 72 (1995) 247.
- SMITH, T., I. GORDON, J. P. KELLY, Br. J. Radiol., 71 (1998) 314.
- MANDELL, G. A., D. F. EGGLI, D. L. GILDAY, S. HEYMAN, J. C. LEONARD, J. H. MILLER, H. R. NADEL, S. T. TREVES, Society of nuclear medicine procedure guideline for renal cortical scintigraphy in children. Society of Nuclear Medicine Procedure Guidelines Manual, (2003) 195. Available from: URL: <http://www.snm.org>
- HERTEL, A., G. HÖR, Use of Tc-99m-MAG3 for clinical evaluation of renal function and disorders. In: HÖR, G., H. W. PABST (Eds.): Kidney/Niere. (Gustav Fischer Verlag, Stuttgart, Jena, New York, 1996).
- HÖR, G., Der Nuklearmediziner, 14 (1991) 302.
- LOUTFI, I., K. AL-ZAABI, A. ELGAZZAR, Clin. Nucl. Med., 24 (1999) 931.
- GORDON, I., P. ANDERSON, M. LYTHGOE, M. ORTON, J. Nucl. Med., 33 (1992) 2090.
- PIEPSZ, A., P. COLARINHA, I. GORDON, K. HAHN, P. OLIVIER, I. ROCA, R. SIXT, J. VAN VELZEN, Guidelines on 99m Tc-DMSA scintigraphy in children. EANM guidelines-under the auspices of the Pediatric Committee of the European Association of Nuclear Medicine, 2000, Available from: URL: [http://www.eanm.org/glines/gl\\_dmsa\\_en.html](http://www.eanm.org/glines/gl_dmsa_en.html).
- LYTHGOE, M. F., I. GORDON, Z. KHADER, T. SMITH, P. J. ANDERSON, Eur. J. Nucl. Med., 26 (1999) 155.
- GUNGOR, F., P. ANDERSON, I. GORDON, Nucl. Med. Commun., 23 (2002) 147.
- PIEPSZ, A., K. HAHN, I. ROCA, Eur. J. Nucl. Med., 17 (1990) 127.
- PIEPSZ, A., M. BLAUFOX, I. GORDON, G. GRANERUS, M. MAJD, P. O'REILLY, A. R. ROSENBERG, M. A. ROSSLEIGH, R. SIXT, Semin. Nucl. Med., 12 (1999) 160.
- PICKWORTH, F. E., G. C. VIVIAN, K. FRANKLIN, E. F. BROWN, Br. J. Radiol., 65 (1992) 21.
- PIEPSZ, A., H. PINTELON, M. VERBOVEN, F. KEUPENNS, A. JACOBS, Nucl. Med. Commun., 13 (1992) 494.
- SFAKIANAKIS, G., G. ZILLERUELO, F. CAVAGNARO, C. GARGANO, M. GEORGIU, M. ALMANZAR, A prospective comparative DMSA and MAG3 study in acute pyelonephritis. In: TAYLOR, A., H. THOMPSON, J. NALLY (Eds.): Radionuclides in Nephrology. (DNLM/DLC for library of Congress, 1997).
- PIEPSZ, A., C. DEE SADELEER, K. MELIS, M. TONDEUR, M. B. VAN ESPEN, J. VERELST, H. R. HAM, Interobserver variability in reporting on Tc-99m DMSA planar images: A Belgian multicentric study. CD-ROM by DB-Disc. (Departments of Nuclear Medicine, CHU St Pierre and AZ VUB, Brussels, 1998).

A. Smokvina

*Department of Nuclear Medicine, University Hospital Center Rijeka, Krešimirova 42, 51000 Rijeka, Croatia  
e-mail: smokvina@medri.hr*

## **PROCJENA BUBREŽNOG PARENHIMA: MAG3 vs. DMSA**

### **S A Ž E T A K**

Scintigrafija tehnecijem obilježenom dimerkaptosukciničnom kiselinom (DMSA), smatra se referentnom metodom za otkrivanje parenhimskih lezija i određivanje diferencijalne funkcije bubrega. Cilj studije je bio da se istraži upotreba tehnecijem obilježenog merkaptacetiltriglicina (MAG3) u iste svrhe. Pacijenti, kojima su obje studije bile učinjene unutar 3 mjeseca (N=188), bili su podijeljeni u dvije grupe. U prvoj je 83 scintigrama učinjenih sa DMSA uspoređeno sa parenhimskom fazom studije sa MAG3. Morfologiju bubrega su procjenjivala četiri ispitivača. Nalazi su se podudarali u 85 % pacijenata. U drugoj grupi (N=105) su uspoređene vrijednosti diferencijalne funkcije bubrega dobivene pomoću dva radiofarmaka (DMSA i MAG3). Nisu nađene statistički značajne razlike između vrijednosti dobivenih pomoću dvije metode. Rezultati su pokazali da se većina lezija koje se otkriju na scintigrafiji sa DMSA, može vidjeti i na scintigramima parenhimske faze sa MAG3, te da se obje studije mogu jednako upotrijebiti za određivanje diferencijalne funkcije bubrega.