

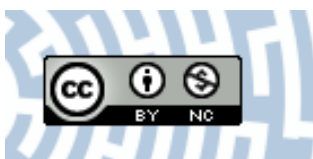


You have downloaded a document from
RE-BUŚ
repository of the University of Silesia in Katowice

Title: Can we use thermal imaging to evaluate the effects of carpal tunnel syndrome surgical decompression?

Author: Agnieszka Baic, Teresa Kasprzyk, Michał Rżany, Agata Stanek, Karolina Sieroń, Armand Cholewka i in.

Citation style: Baic Agnieszka, Kasprzyk Teresa, Rżany Michał, Stanek Agata, Sieroń Karolina, Cholewka Armand i in. (2017). Can we use thermal imaging to evaluate the effects of carpal tunnel syndrome surgical decompression?. "Medicine", (Vol. 96, Iss. 39, (2017), art. no. e7982), doi 10.1097/MD.0000000000007982



Uznanie autorstwa - Użycie niekomercyjne - Licencja ta pozwala na kopiowanie, zmienianie, remiksowanie, rozprowadzanie, przedstawienie i wykonywanie utworu jedynie w celach niekomercyjnych. Warunek ten nie obejmuje jednak utworów zależnych (mogą zostać objęte inną licencją).



Can we use thermal imaging to evaluate the effects of carpal tunnel syndrome surgical decompression?

Agnieszka Baic, MSc^a, Teresa Kasprzyk, MSc^{a,*}, Michał Rżany, MSc^d, Agata Stanek, MD, PhD^b, Karolina Sieroń, MD, PhD^c, Krzysztof Suszyński, MSc, PhD^e, Wiesław Marcol, MD, PhD^d, Armand Cholewka, MSc, PhD^a

Abstract

Research is intended to verify if thermal imaging can be used in diagnosing and monitoring the carpal tunnel syndrome (CTS).

This disease is not easy to diagnose using traditional methods. Also, the difficulties in monitoring carpal tunnel surgery effects necessitate new, noninvasive method, which gives more information.

The research group consists of 15 patients with CTS and control group of healthy people. All patients who were examined before surgery were also tested 4 weeks after surgery, to check the effects of treatment. In addition a lot of our patients had or will have open carpal tunnel release surgery. Diagnosis of CTS was performed by thermal imaging in both hands from phalanges to the area of the wrist on the external and palmar side of the palm.

Using infrared (IR) camera one can observe high temperature gradient on hand-tested areas and these differences prove the diagnosis. Moreover patients after surgery have better temperature distribution and it was closer to control group. Results prove that surgery is the best, and currently, the only method to treat CTS.

Thermal imaging may be helpful in diagnosing CTS.

Abbreviations: ΔT_1 = temperature gradient, BMI = body mass index, CT = carpal tunnel, CTS = carpal tunnel syndrome, EMG = electromyography, IR = infrared, IRT = infrared thermography, NCV = nerve conduction velocity, ROIs = regions of interest, SE = standard error.

Keywords: carpal tunnel syndrome, temperature, thermovision diagnostics

1. Introduction

Internal temperature is a one of the most important condition parameters of our body. There are a lot of methods to measure the thermal parameters. Most commonly the contact thermometers (mercury or electronic) are used by inserting under the arm or locating it in a body cavities such as the mouth, ears, or rectum. However, the contact method gives information about temperature from narrow-region. The problem for these methods appears

when the surface temperature is needed. The ultimate noninvasive and noncontact method to measure the temperature distribution from some surface is infrared thermography (IRT).

The changes of temperature gradient are well-known disease indicators. It allows assessing metabolism changes and local blood flow, especially in a superficial skin layer. Considering the aforementioned, thermal imaging method seems to be the best and easy solution, and it may also be helpful in medical diagnosis.^[1–6]

Changes (decrease and increase) in skin surface and body core temperature might be influenced by the presence of various kinds of diseases. Additionally it must be noticed that in medicine, there are physical factors, which can affect temperature changes in the human body. The application of alternative noninvasive diagnostic method is therefore fully justified.^[1–11]

Carpal tunnel syndrome (CTS) is one of the diseases in which using thermal imaging can greatly improve the medical diagnosis. At present, only palpation tests, such as Phalen test and Tinel test, and electromyography (EMG) allows diagnoses of CTS within a certain range. The median nerve, which is located in the human wrist, can be squeezed or pressed. In that situation the probability of CTS can exist. The nerve, which runs from the forearm into the palm of the hand, allows controlling feelings from palm side of the fingers without the little finger and thumb and the impulses from some hand muscles.^[12–17]

Carpal tunnel (CT) is a rigid, narrow place of transition from bones and ligament toward the base of the palm, in which the tendons and median nerve are located. The protuberance resulting from irritation of the tendons or other swelling can narrow isthmus and cause pressure on the median nerve. Consequently, it may cause weakness, numbness, and pain radiating to the arm. Keep in

Editor: Giovanni Tarantino.

The authors report no funding or conflicts of interest.

^a Department of Medical Physics, A. Chelkowski Institute of Physics, University of Silesia, Katowice, ^b Department and Clinic of Internal Diseases, School of Medicine with the Division of Dentistry in Zabrze, Angiology and Physical Medicine in Bytom, Medical University of Silesia, Bytom, ^c Department of Physical Medicine, School of Health Sciences in Katowice, Medical University of Silesia, Katowice, ^d Department of Physiology, Medical University of Silesia, Katowice, ^e Department of Sports Medicine and Physiology of Physical Effort, School of Health Sciences in Katowice, Medical University of Silesia, Katowice, Poland.

* Correspondence: Teresa Kasprzyk, Department of Medical Physics, A. Chelkowski Institute of Physics, University of Silesia, 75 Pułku Piechoty 1A Street, 41–500 Chorzów, Poland (e-mail: ter.kasprzyk@gmail.com).

Copyright © 2017 the Author(s). Published by Wolters Kluwer Health, Inc. This is an open access article distributed under the terms of the Creative Commons Attribution-Non Commercial License 4.0 (CCBY-NC), where it is permissible to download, share, remix, transform, and buildup the work provided it is properly cited. The work cannot be used commercially without permission from the journal.

Medicine (2017) 96:39(e7982)

Received: 10 April 2017 / Received in final form: 9 August 2017 / Accepted: 14 August 2017

<http://dx.doi.org/10.1097/MD.0000000000007982>

mind that pain can also be caused by other factors. However, today CTS is the most common and frequent cause of peripheral nerve neuropathy causing pressure.^[12–17]

2. Materials and methods

This study was conducted at the Department of Neurosurgery, Second Provincial Hospital, Jastrzębie Zdrój, Poland, in accordance with the Declaration of Helsinki and approval from the Ethics Committee of Medical University of Silesia in Katowice (0022/KB1/80/11/15). Each subject provided written informed consent prior to study participation. The study involved groups of 15 right-handed female volunteers each: group A, 15 patients (mean age 59 ± 10 years) suffering from idiopathic CTS before surgery operation; group B, 15 patients (mean age 59 ± 10 years) 4 weeks after surgery operation; and group C, 15 healthy volunteers (mean age 38 ± 19 years). There were no significant differences in body mass index (BMI) between studied groups. Before the study a physician, to exclude any coexisting diseases as well as any contraindications for cryotherapy procedures, examined each patient. All patients included in the study had no common diseases such as Raynaud phenomena, local blood flow disturbances, or Burger disease. Exclusion criteria for the study included any history of upper extremity disorders or peripheral nervous system pathologies. The diagnosis of CT was confirmed by positive EMG and nerve conduction velocity (NCV) tests. The latency of more than 4.5 ms was considered in NCV as the main criterion for diagnosing of idiopathic CT.

Patients from group B underwent open carpal tunnel release surgery (by the same surgeon; AG) and consecutive thermal imaging was used directly before operation and 4 weeks after. All measurements were performed by one and the same person, properly trained and having experience in conducting such research, in order to fully objectify research.

The patients were requested not to drink alcohol or hot drinks for 3 to 4 hours before the trial. To carry on the thermal imaging Thermovision Camera FLIR Systems E60 with sensitivity of 0.05 K was used. The emissivity was set at the range of 0.98 equivalent of human skin emissivity. The chosen region (Fig. 1, Table 1) was taken into consideration for all patients. All imaging were performed in a special room where the temperature was stabilized at $23.0 \pm 1.0^\circ\text{C}$. The distance between the camera and the body was about 0.5 ± 0.05 m (depending on the size of the inspected area). It was necessary to follow the standard protocol of IR imaging in medicine.^[10–11] Thermal images were analyzed using a ThermoCAM TM Researcher Pro 2.8 SR-3. Statistical analysis was done in Statistica 9.1. Differences with a $P < .05$ were regarded as significant.

3. Results and discussion

Thermal images and temperature parameters of the representative patient's hand obtained before and 4 weeks after surgical operation on CT as well as healthy hand are presented in Figures 2A–C, respectively.

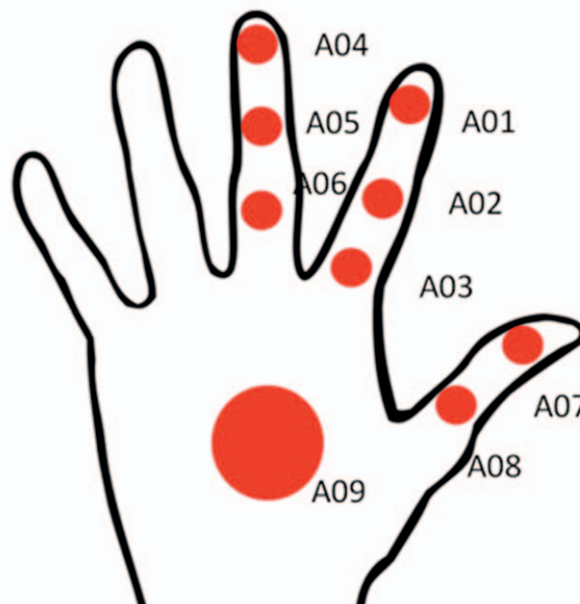


Figure 1. The scheme of temperature analysis performed on the subject's hands. All ROIs taken into analysis are marked on the figure, and temperature gradient (ΔT) is defined as $T_9 - T_i$. ROIs=regions of interest.

Moreover to make preliminary analysis easier temperature parameters of the patients as well as healthy hands volunteers derived from thermal images are collected as shown in Table 2.

CT is a rigid, narrow place of transition from bones and ligament toward the base of the palm, in which the tendons and median nerve are located. Protuberance resulting from irritation of the tendons or other swelling can narrow isthmus and cause pressure on the median nerve. Consequently, it may cause weakness, numbness, and pain radiating to the arm. Today CTS is the most common and frequent cause of peripheral nerve neuropathy causing pressure. Analyzing presented thermal images it may be said that thermovision may be found useful in CTS diagnosis as an additional noninvasive, cheap, and fast technique. The proofs are the thermal images, which completely differ between healthy controls and patients, as well as between hand thermal image performed before and after surgical operation. Moreover it should be noted that at present, only palpation tests, such as Phalen test and Tinel test, and EMG allow diagnosing CTS within a certain range. The median nerve, which is located in the human wrist, can be squeezed or pressed. In that situation, probability that we suffer from the CTS exists. The nerve, which runs from the forearm into the palm of the hand, allows controlling feelings from palm side of the fingers without the little finger and thumb, and the impulses from some hand muscles.^[12–17] So it seems that other objective and noninvasive test may be found as useful for physiotherapists and surgeons. However, to confirm this thesis, it is necessary to perform deeper statistical analysis on the obtained data, which was the main aim

Table 1

The chosen values of the temperature parameters obtained for representative patient and healthy controls.

$\Delta T_{1\text{before}}$	$\Delta T_{1\text{after}}$	$\Delta T_{1\text{healthy}}$	$\Delta T_{4\text{before}}$	$\Delta T_{4\text{after}}$	$\Delta T_{4\text{healthy}}$	$\Delta T_{7\text{before}}$	$\Delta T_{7\text{after}}$	$\Delta T_{7\text{healthy}}$
4.9°C	0.2°C	0.3°C	5.3°C	0.5°C	0.5°C	4.5°C	0.5°C	0.0°C

Where temperature gradient (ΔT) is defined as $T_9 - T_i$.

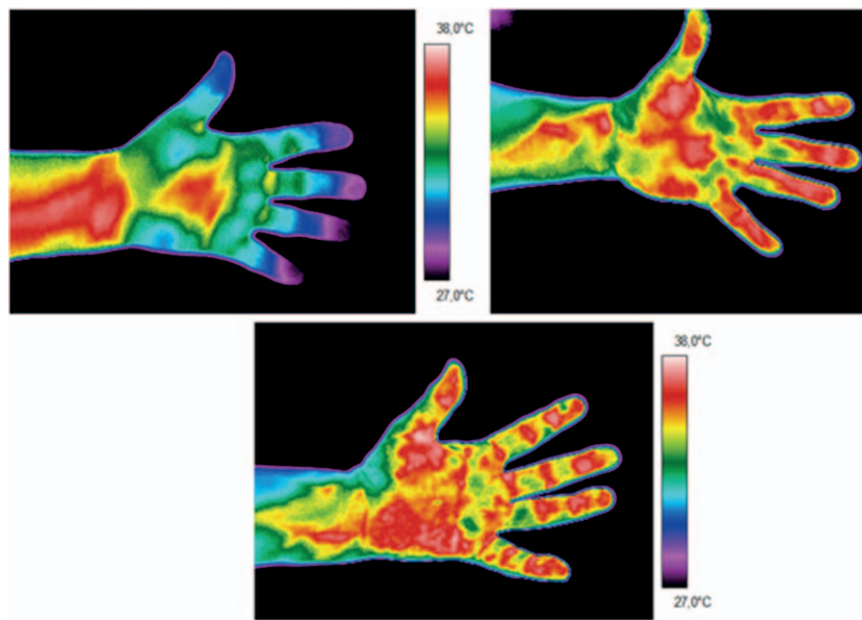


Figure 2. The thermal images of representative patient's hand suffering from CTS performed before (A) and after (B) surgical operation, and (C) thermal image of representative healthy volunteer hand. The temperature parameters are derived from the chosen ROIs marked on the thermograms, as given in the Table 1. CTS = carpal tunnel syndrome. ROIs = regions of interest

of this study and the results are presented and discussed as follows.

For deeper insight into the problem the statistical analysis were done. The differences between mean temperature derived from chosen region of interest (ROI) (from T_1 to T_9) and the region of inner part of the hand (T_9) were taken into consideration.

The mean differences between thermal parameters obtained for patients before and 4 weeks after surgical operation and the healthy volunteers in average for representative ROIs are presented in Figures 3–7. They almost all are statistically significant with $P < .05$.

The statistical significance was checked using the Student t test for dependent variables, for comparison of temperature gradient before and 4 weeks after the surgery. Also changes between temperature gradient (DT_i) 4 weeks after and DT_i control group, and between DT_i before and DT_i control group were analyzed by Student t test for independent variables.

It can be easily seen that surgical operation changes the thermal map of the hand's surface as well as the mean temperature difference between distal and closer parts of the examined areas. According to box graphs it also seems that generally the mean

temperature differences get smaller after surgical operation. However there were cases that showed quite big lowering of the mean temperature difference (DT_6 and DT_8). One way or another it should be seen that obtained after surgical operation mean temperature differences were smaller and got closer to values obtained for the healthy. This may suggest beneficial influence on patient's health. It should be also noted that statistical analysis confirmed described observations and in all cases relationship between before and 4 weeks after surgical operation is statistically significant. However, in 1 case (DT_8) the changes between 4 weeks after the surgery and healthy (control group) is not statistically significant but the tendency is the same.

In the analysis shown for those 4 weeks after the surgery, the temperature gradients for thumb (DT_8) are very close to control group value. The difference between control group and group after the surgery amounts to 0.06°C . The temperature changes 4 weeks after surgery for forefinger (DT_1 and DT_3) are closer to healthy than those before. The value of DT_1 after the surgery is -0.33°C and for healthy it is 0.13°C . In case of middle finger (DT_4 and DT_6) 4 weeks after surgery, the changes are higher than another fingers, although the temperature gradients are getting smaller.

Table 2
The average values of the temperature parameters obtained for patients before, 4 weeks after surgical operation, and for healthy controls.

Before surgical operation								
Patient	$DT_1, ^\circ\text{C}$	$DT_2, ^\circ\text{C}$	$DT_3, ^\circ\text{C}$	$DT_4, ^\circ\text{C}$	$DT_5, ^\circ\text{C}$	$DT_6, ^\circ\text{C}$	$DT_7, ^\circ\text{C}$	$DT_8, ^\circ\text{C}$
Average	0.95	2.85	3.09	3.73	4.81	0.95	2.85	3.73
SD	0.55	1.27	1.01	0.97	1.20	0.55	1.27	0.97
4 weeks after surgical operation								
Average	-0.33	-0.51	0.47	2.29	6.29	-1.07	5.39	0.71
SD	0.26	0.60	0.62	0.77	1.07	0.46	1.88	0.67
Control group (healthy)								
Average	0.13	-0.09	1.56	-0.48	0.03	0.15	0.49	0.65
SD	0.43	0.31	0.61	0.37	0.63	0.32	0.45	0.43

Where temperature gradient (ΔT_i) is defined as $T_9 - T_i$. SD = standard deviation.

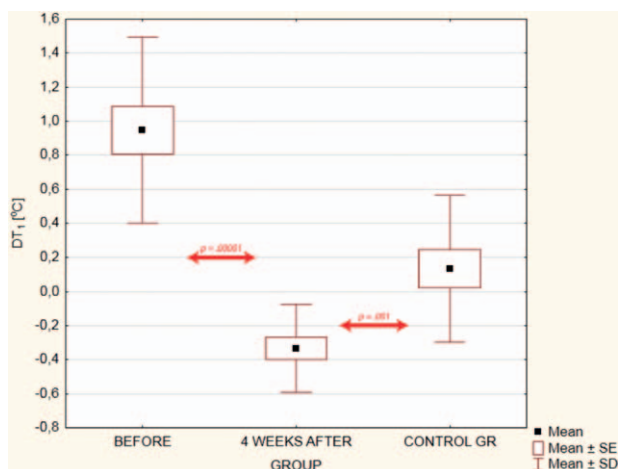


Figure 3. ΔT_1 defined as $T_0 - T_1$ mean differences between patients before and after surgical operation and the healthy (control group). Statistical values used: mean, SE, and SD. Mean=mean value of temperature, SE=standard error, SD=standard deviation.

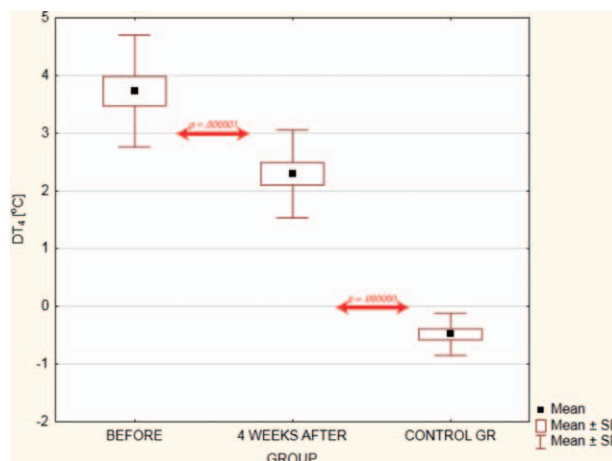


Figure 5. ΔT_4 defined as $T_9 - T_4$ mean differences between patients before and after surgical operation and the healthy (control group). Statistical values used: mean, SE, and SD. Mean=mean value of temperature, SD=standard deviation, SE=standard error.

It should be underlined that the average temperature difference between patients and control group for chosen ROIs mentioned in Figure 1 is significantly (where $P < 0.05$ was regarded as significant level) lower 4 weeks after the surgery than for group before surgery. It was confirmed by Student *t* test for independent variables. On the other hand obtained results from group of patients studied 4 weeks after surgery and control group showed no significant ($P = .20$) difference unlike the results of patients studied before the surgery where $P = .00002$.

It means that estimation of therapy correctness may be done by statistical analysis, where no statistical significance or increased *P* value as a result of difference group test (as Student *t* test or similar for independent variables) obtained between patients after surgery and control group point to good health prognosis. It also seems that the insignificant values of statistical analysis between mentioned groups classify therapy as a complete helpful medical therapy for CTS (such situation we can see in Figure 7

where *P* factor between group after surgery and control group is higher than 0.05 to 0.80.

However, CTS is very serious medical problem, and the surgery is also complicated and has a big influence on health. In case of CTS it should be rereflect, which fingers are most injured. Thermal analysis shows that thumb is getting healthy faster than others. This could be because of thenar, a very strong muscle, which can protect nerves and blood vessels. Also there is a possibility that surgery can bring back electric agitation, especially for thumb. In fact, the middle finger and forefinger are exposed to CTS effects more than thumb. According to this we may suppose that after surgery the healing is such a long-time process and also long rehabilitation is needed.

To check how the recovery process runs and how long it will take, further researches are needed, which include the measurements after term longer than only 4 weeks after the surgery. This will allow an objective evaluation of used procedures.

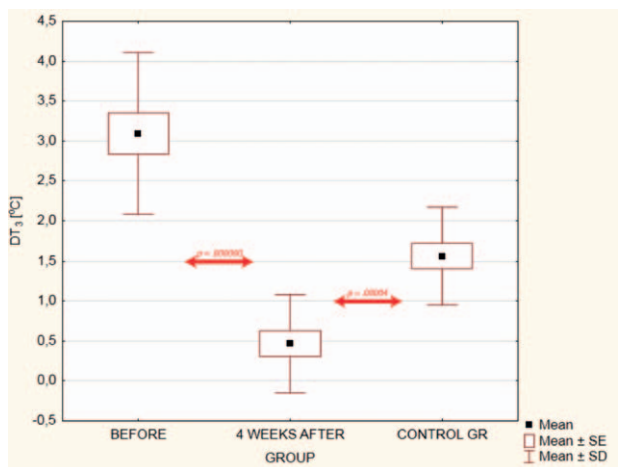


Figure 4. ΔT_3 defined as $T_9 - T_3$ mean differences between patients before and after surgical operation and the healthy (control group). Statistical values used: mean, SE, and SD. Mean=mean value of temperature, SD=standard deviation, SE=standard error.

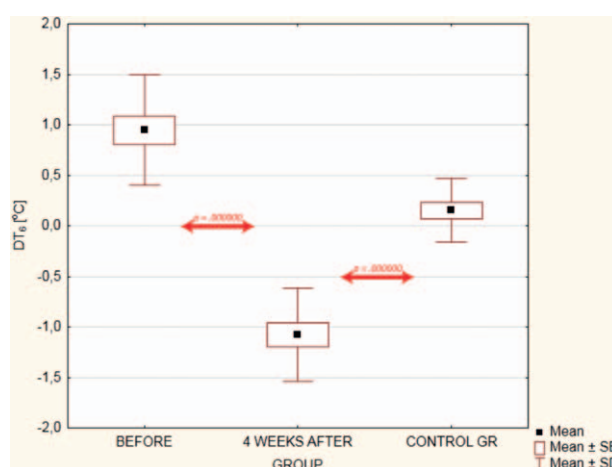


Figure 6. ΔT_6 defined as $T_9 - T_6$ mean differences between patients before and after surgical operation and the healthy (control group). Statistical values used: mean, SE, and SD. Mean=mean value of temperature, SD=standard deviation, SE=standard error.

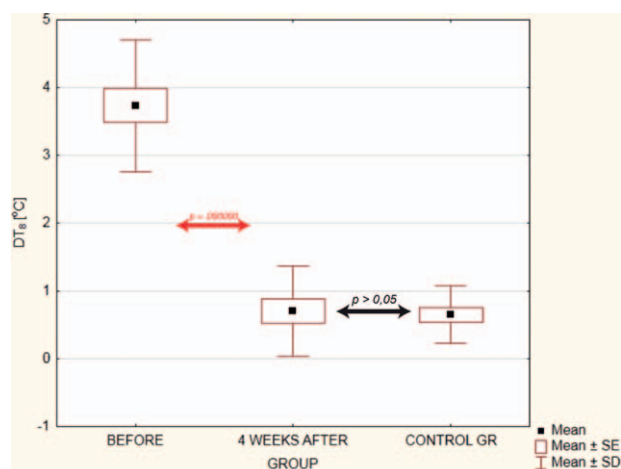


Figure 7. ΔT_g defined as $T_9 - T_8$ mean differences between patients before and after surgical operation and the healthy (control group). Statistical values used: mean, SE, and SD. Mean=mean value of temperature, SD=standard deviation, SE=standard error.

4. Conclusions

Mean temperature differences between distal and closer parts of the examined areas obtained after surgical operation were smaller and got closer to values obtained for the healthy what may suggest beneficial influence on patient's health.

Obtained results indicate the possibility of the use of thermal imaging in not only diagnostics but also monitoring the healing processes after the surgery in CTS surgical operation.

References

[1] Bauer J, Hurnik P, Zdziarski J, et al. Thermovision and its applications in medicine. *Acta Bio Opt Inf Med* 1997;3:121–31.
 [2] Bauer J, Hurnik P, Zdziarski J, et al. Thermovision evaluation of cryotherapy effects. *Acta Bio Opt Inf Med* 1997;3:133–40.

[3] Cholewka A, Drzazga Z, Sieroń A, et al. Thermovision diagnostics in chosen spine diseases treated by whole body cryotherapy. *J Therm Anal Calorim* 2010;102:113–9.
 [4] Cholewka A, Drzazga Z, Sieroń A, et al. Some applications of thermal imaging in medicine in some aspects of medical physics – in vivo and in vitro studies. Drzazga Z, Śłosarek K, eds. *Pol J Environ Stud*. 2010; 1:51–8.
 [5] Cholewka A, Knefel G, Stanek A, et al. Thermal imaging and TC oximetry measurements of hyperbaric oxygen therapy (HBO) effects on trophic ulceration of the crura. *J Therm Anal Calorim* 2012; 108:25–31.
 [6] Cholewka A, Drzazga Z, Michnik A, et al. Temperature effects of whole cryotherapy determined by thermography. *Thermol Int* 2004;14: 57–63.
 [7] Boerner E, Bauer J, Ratajczyk B, et al. Application of thermovision for analysis of superficial temperature distribution changes after physiotherapy. *J Therm Anal Calorim* 2015;120:261–7.
 [8] Boerner E, Bauer J, Kuczkowska M, et al. Comparison of the skin surface temperature on the front of thigh after application of combined red-IR radiation and diadynamic currents executed in different sequence. *J Therm Anal Calorim* 2015;120:921–8.
 [9] Mercer JB, Ring EFJ. Fever screening and infrared thermal imaging: concerns and guidelines. *Thermol Int* 2009;19:67–9.
 [10] Ammer K. The Glamorgan Protocol for recording and evaluation of thermal images of the human body. *Thermol Int* 2008;18:125–9.
 [11] Ring EFJ, Ammer K. The technique of infrared imaging in medicine. *Thermol Int* 2000;10:7–14.
 [12] Zanette G, Marani S, Tamburin S. Extra-median spread of sensory symptoms in carpal tunnel syndrome suggests the presence of pain-related mechanisms. *Pain* 2006;122:264–70.
 [13] Jesensek Papež B, Palfy M, Turk Z. Infrared thermography based on artificial intelligence for carpal tunnel syndrome diagnosis. *J Int Med Res* 2008;36:1363–70.
 [14] Jesensek Papež B, Palfy M, Mertik M, et al. Infrared thermography based on artificial intelligence as a screening method for carpal tunnel syndrome diagnosis. *J Int Med Res* 2009;37:779–90.
 [15] Ming Z, Siivola J, Pietikainen S, et al. Postoperative relieve of abnormal vasoregulation in carpal tunnel syndrome. *Clin Neurol Neurosurg* 2007; 109:413–7.
 [16] Ming Z, Zaproudina N, Siivola J, et al. Sympathetic pathology evidenced by hand thermal anomalies in carpal tunnel syndrome. *Pathophysiology* 2005;12:137–41.
 [17] Kiylioglu N, Akyol A, Guney E, et al. Sympathetic skin response in idiopathic and diabetic carpal tunnel syndrome. *Clin Neurol Neurosurg* 2005;108:1–7.