

Case Report

Open Access

Domenico Testa, Sergio Motta, Eva Aurora Massimilla*, Domenico Tafuri, Daniela Russo, Anna Russo, Pasquale Gianluca Landolfo, Massimo Mesoletta, Gaetano Motta

Cavernous hemangioma of rhinopharynx: our experience and review of literature

DOI: 10.1515/med-2015-0089

received October 24, 2015; accepted November 4, 2015.

Abstract: Hemangiomas are benign tumors originating in the vascular tissues of skin, mucosa, muscles, glands, and bones. Although these tumors are common lesions of the head and neck, they rarely occur in the nasal cavity and paranasal sinuses. Cavernous haemangioma of the lateral wall of the nasopharynx has not previously been reported. We examined the clinical, radiological and therapeutic management of cavernous haemangioma of nasopharynx starting from a clinical case of a 26-year-old woman with a history of recurrent and conspicuous epistaxis and left-sided nasal associated severe obstruction. Nasopharynx examination, by flexible endoscopy, showed a cystic mass borne by the left side wall of the nasopharynx, in contact with the soft palate, covered by intact and regular mucosa. Contrast-enhanced computed tomography (CT) scan, confirmed these findings and showed contextual lamellar calcifications and inhomogeneous enhancement. The nasal endoscopic approach (FESS), under general anesthesia, allowed removal of the mass, without complications, after careful hemostasis of arterial branches. It was possible to establish the precise site of origin of the tumor only

during the surgical procedure. Histopathological study showed mucosa with extensive vascular proliferation, with framework of lacunar/cavernous haemangioma, also present at lamellar bone tissue level. An unusual site and an unspecific clinical appearance can make diagnosis and treatment of a cavernous hemangioma of the nasopharynx difficult. The nasal endoscopic technique proved to be reliable in terms of adequate exposure and visualization of the lesion, control of bleeding, and complete removal of the mass.

Keywords: hemangioma, epistaxis, functional endoscopy sinus surgery (FESS)

1 Introduction

Hemangiomas are benign vascular tumors of skin, mucosa, muscles, glands, and bones [1], and, from a histopathological point of view, are divided into the more common capillary type, mixed types and the less common cavernous type [2-4].

Although these tumors are common lesions of the head and neck, they rarely occur in the nasal cavity and paranasal sinuses [1,3,5].

Hemangiomas account for about 20% of all benign tumors of the nasal cavity, mostly arising in the soft tissues and rarely in the bones [1].

The cavernous variety of haemangioma described arise from the inferior turbinate [1,4,6,7], middle turbinate [8], vomer [9], lamina perpendicularis ossi ethmoidalis [10] and sinus maxillaris [11]. To the best of our knowledge, cavernous haemangioma (CA) of the lateral wall of nasopharynx has not previously been reported in literature.

Clinical, radiological and therapeutic management of cavernous haemangioma of nasopharynx, starting from a clinical case that we treated, are herein described.

***Corresponding author: Eva Aurora Massimilla:** Department of Anesthesiologic, Surgical and Emergency Sciences; Otolaryngology - Head and Neck Surgery Unit; Second University of Naples, Italy, E-mail: evamassimilla@hotmail.it

Domenico Testa, Pasquale Gianluca Landolfo, Gaetano Motta: Department of Anesthesiologic, Surgical and Emergency Sciences; Otolaryngology - Head and Neck Surgery Unit; Second University of Naples - Italy

Sergio Motta, Massimo Mesoletta: Department of Neuroscience Reproductive and Dentistry Sciences, Otolaryngology Unit; University of Naples "Federico II", Naples - Italy

Domenico Tafuri: Department of Sport Sciences and Wellness, University of Naples "Parthenope", Naples, Italy

Daniela Russo: Department of Advanced Biomedical Sciences, University of Naples "Federico II", Naples - Italy

Anna Russo: Santa Maria delle Grazie Hospital, Pathology Unit, Pozzuoli, Naples, Italy

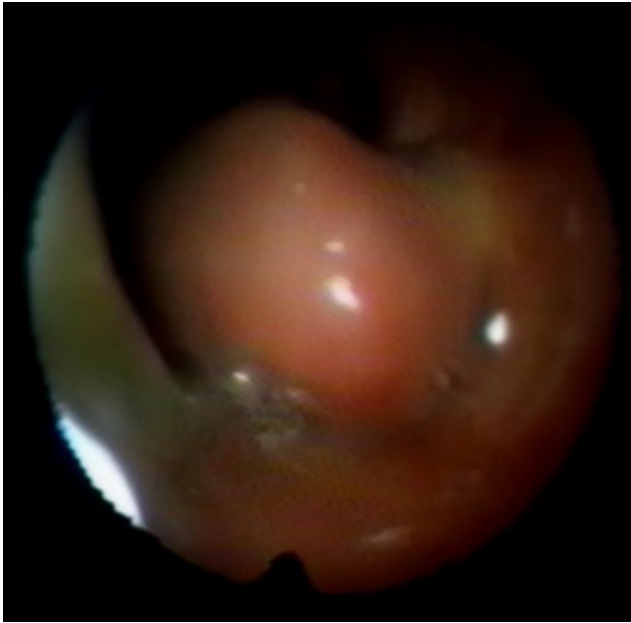


Figure 1: Nasal endoscopy.

2 Case report

A 26-year-old woman with a history of recurrent and conspicuous epistaxis and left-sided nasal associated unilateral severe obstruction. The patient underwent several ENT and maxillofacial specialist visits, and arrived to our attention in January 2012 with a diagnosis of “nasopharyngeal cyst polyp-like”.

Nasopharynx examination, by flexible endoscopy, showed a cystic mass originating from the left side wall of the nasopharynx. The lesion was in contact with the soft palate, with no other associated anomalies and covered by intact and regular mucosa (Fig.1).

Contrast-enhanced computed tomography (CT) showed a polyp-like mass, adjacent to the left side wall and the rear wall of the nasopharynx, with lamellar calcifications and inhomogeneous enhancement. The maximum transverse diameters of this mass were 22 mm x 12 mm in the axial plane and 27 mm in the sagittal plane; it occupied almost completely the nasopharyngeal lumen, reaching down the oropharynx and the soft palate (Fig.2).

The nasal surgical approach with Functional Endoscopic Sinus Surgery, under general anesthesia, allowed for removal of the mass, measuring 25 x 15 x 10 mm, with bone particles - after careful hemostasis of arterial branches, without complications (Fig.3). Because of the size and the clinical presentation, it was possible to establish the precise site of origin of the tumor at the time of the surgical procedure only.

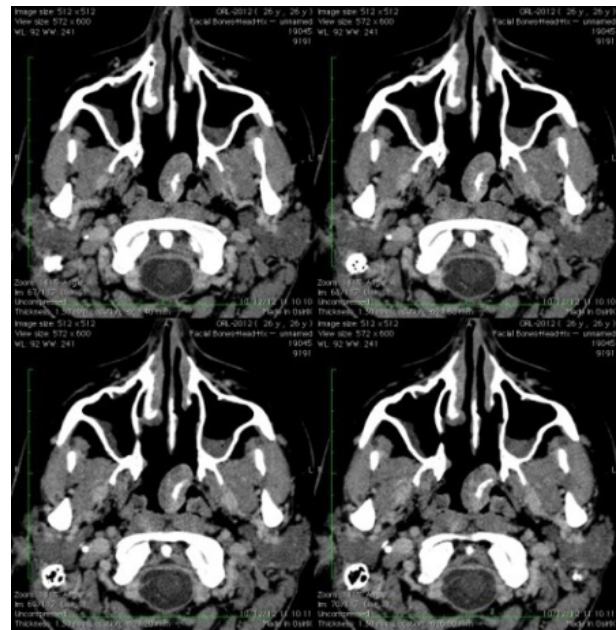


Figure 2: Contrast-enhanced computed tomography (CT) showed a polyp like mass adjacent to the left side wall of nasopharynx.

This procedure consisted of premedication with medicated tampon with xylocaine 1% and epinephrine 1/100000 that was kept in place for 15 minutes. After resection of the tail of the inferior turbinate, the base of the lesion was revealed. The bleeding was controlled by coagulation of the branch of the sphenopalatine artery; using straight scissors, we dissected the base of the tumor using 0° nasal fiber optic; with a Blakesley right clamp, we removed the purplish red mass and performed hemostasis and control of the surgical field.

Ethical approval: The research related to human use has been complied with all the relevant national regulations, institutional policies and in accordance the tenets of the Helsinki Declaration, and has been approved by the authors' institutional review board or equivalent committee.

Informed consent: Informed consent has been obtained from all individuals included in this study.

3 Results

Histopathological study showed mucosa with extensive vascular proliferation, with framework of lacunar / cavernous haemangioma, also present at lamellar bone tissue level (Fig. 4A, 4B). The patient followed a satisfactory post-operative course and was discharged within 2 days of hospitalization. No complications occurred during the postoperative period. There was no recurrence of the lesion at 24 months follow-up.

4 Discussion

Hemangiomas are benign endothelial lesions without degenerative potential [12]. Pathogenesis of these tumors is still unclear. Recently, their origin from late EPCs or differentiated endothelial cells was demonstrated [13]. EPCs are mobilized either from the bone marrow or the arterial area to replace dysfunctional endothelial cells and, using different molecular mechanisms, play a pivotal role in blood perfusion of ischemic and tumoral tissues [14-27]. Although haemangiomas are common lesions of the head and neck (over half of all hemangiomas are located in this region), in the nasal cavity and paranasal sinuses they are rare [1,3,5]. When they do not involve the soft tissues, but occur as solitary lesions in the bone, they account for less

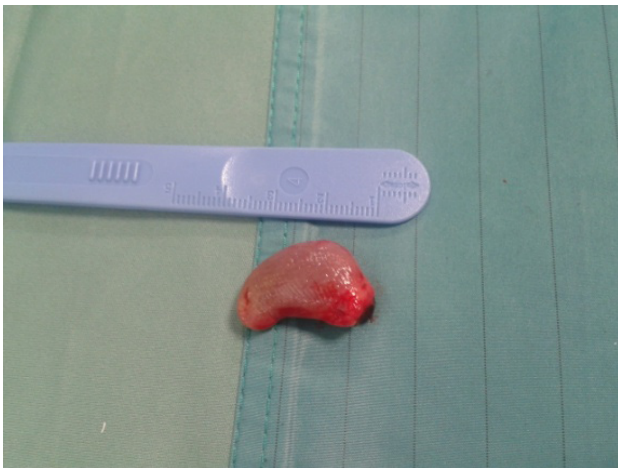


Figure 3: Surgical sample.

than 1% of all primary bone tumors, usually affecting the vertebral column and the skull bones [1,4].

Haemangiomas are classified histologically, depending on the dominant vessel size at microscopy, into capillary, mixed and cavernous types [2,3,4]. The latter are composed of large endothelium-lined vascular spaces [12]. Thrombi within the vascular spaces may occasionally calcify and are identified at CT as phlebolithes [28].

The frequency of the different histological types of hemangiomas is unknown in the literature [2]. The relatively broad study, by Osborn in 1959, reviewed 51 patients with haemangiomas of the nose. Of these 51 cases, only two were of the cavernous variety [29].

More recently, Iwata [30] described three cavernous hemangiomas studied, two having arisen from inferior turbinate.

When these neoplasms arise in the nasal cavity, they are predominantly capillary and arise from the nasal septum in about 80% of the cases, namely in the Little area or Kiesselbach triangle [29]. Nasal haemangiomas arise around the fourth decade, with an equal gender incidence [28]; moreover they are likely found in the lateral nasal wall and show peculiar histological features [3,19,31].

Cavernous haemangiomas have been described arising from the inferior turbinate [1,4,6,7], middle turbinate [8], vomer [9], *lamina perpendicularis ossi ethmoidalis* [10] and *sinus maxillaris* [11] but cavernous haemangioma of the lateral wall of the nasopharynx has not previously been reported in literature.

The cause of their intraosseous origin is unclear and a previous local trauma could play a role [1,29,32-34]; the most common symptoms are bleeding, sometimes substantial, and nasal obstruction, which are observed

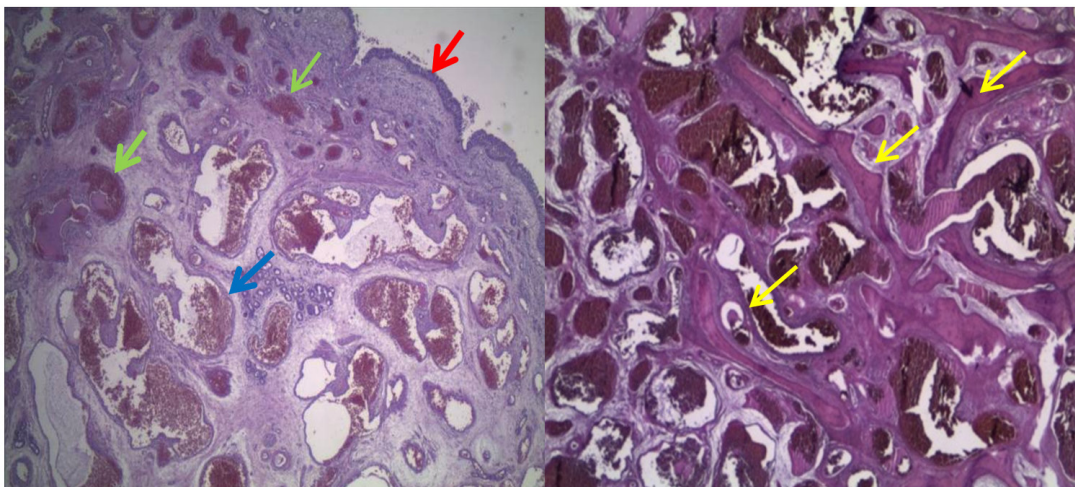


Figure 4: A, B. A: Overview: red arrow → respiratory epithelium; green arrow → small and medium caliber vessels; blue arrow → large caliber vessels. (hematoxylin-eosin 25x); B: intraosseous portion of the lesion (yellow arrows: bone lamellae) (hematoxylin-eosin 25x).

Table 1: Cavernous haemangiomas of the nasal cavity and paranasal sinuses reported in the literature.

Authors	Site of involvement	Treatment
<i>Takeda et al. 2010</i>	Inferior turbinate	Caldwell-Luc procedure
<i>Akiner et al. 2011</i>	Inferior turbinate	Endoscopic approach
<i>Webb et al. 2000</i>	Posterior ends of both inferior turbinates	Embolisation
<i>Archontaki et al. 2008</i>	Middle nasal meatus	Endoscopic approach
<i>Bakhos et al. 2008</i>	Middle turbinate	Endoscopic approach
<i>Nakahira et al. 1997</i>	Vomer	Le Fort 1 osteotomy

with the progressive growth of the mass. Pain is not characteristic of nasal hemangioma [7,12,29,32-38].

The tumor appears as a sessile or polypoid lesion [29], as occurred in our case. It usually does not present signs that suggest a vascular lesion [32-34].

The unspecific clinical appearance makes it difficult to distinguish hemangiomas from other nasal tumors and malformations, including antrochoanal polyp, inverted papilloma, fibroangioma and lymphangioma [2,29]. In the presence of irregular mucosa, necrotic tissue or history of previous malignancy, a malignant origin should be suspected (metastases, hemangiopericytoma, hemangiosarcoma) and biopsy should be performed, after clinical-radiological analysis, to exclude a vascular lesion [6,33,34]. In the present case, given the various episodes of epistaxis, no previous biopsy was performed.

Radiographic examination - contrast CT scanning - is useful in the definitive pre-operative diagnosis in defining calcifications, bone destruction adjacent to hemangioma, intense enhancement after injection of contrast, anatomical location and extension of the tumor [2,13,33,34].

The radiological features, however, do not always give the differential diagnosis with the most common epithelial tumors [33,34]. Evidence of phleboliths may suggest the presence of a cavernous hemangioma [34].

Management of nasal hemangioma involves complete resection of the tumor with a part of underlying mucosa and perichondrium and ligation or cautery to the feeding vessels [33-35,37]. Choice of the surgical approach depends on the exact site and extension of the tumour (Tab. 1).

An alternative form of management of these tumours, providing there is favourable anatomy, is embolization of the haemangiomas, which is, however, only possible if appropriate angiographic facilities are available [6].

The criteria that lead to embolization, to date, have not been established. According to some authors, embolization

would allow, in the case of large hemangiomas, reduced intraoperative bleeding and facilitate the endonasal approach [2]. Other authors have witnessed tumour regression following embolization [6]. Radiation therapy is reserved for arresting the progression of unresectable or inaccessible lesions [8].

Many surgical approaches have been suggested, including lateral rhinotomy, trans-palatal, trans-antral approach and the Le Fort I osteotomy procedure [35,37].

In the absence of risk of malignant transformation, the trans-nasal endoscopic approach (F.E.S.S.) has been proposed as the technique of choice for the complete removal of the tumor in cases of haemangiomas confined to the nasal cavity and extended into ethmoid to sphenoid sinus [2,35,37].

The choice of wide resection or other effective methods is proposed for the treatment of tumors extending into antrum, pterygomaxillary, infratemporal fossae, orbit, cheek, and cranial cavity [29].

The definitive diagnosis is histological. The presence of bone particle and irregular vessel size confirms the diagnosis of cavernous hemangioma [34-37]. Follow-up is necessary in order to identify recurrences, which may occur late [29-38]. In conclusion, an unusual site of origin and an unspecific clinical appearance can make the diagnosis and treatment of a cavernous hemangioma of the nasopharynx difficult. In the present case, the minimally invasive trans-nasal endoscopic technique has proven to be reliable in terms of adequate exposure and visualization of the lesion, control of bleeding and complete removal of the tumor.

Conflict of interest statement: Authors state no conflict of interest.

References

- [1] Takeda K, Takenaka Y, Hashimoto M. Intraosseous hemangioma of the inferior turbinate. *Case Reports in Medicine* 2010;3 pages. Article ID 409429.
- [2] Bakhos D, Lescanne E, Legeais M, Beutter P, Morinière S. Cavernous Hemangioma of the nasal cavity. *Ann Otolaryngol Chir Cervicofac.* 2008;125(2):94-7.
- [3] Batsakis JG, Rice DH. The pathology of head and neck tumors: vasoformative tumors, part 9A. *Head Neck Surg* 1981;3:231-9.
- [4] Akiner MN, Akturk MT, Demirtas M, Atmis EO. Intraosseous Cavernous Hemangioma of Inferior Turbinate: A Rare Case Report. *Case Report Otolaryngol.* 2011: 431365.
- [5] Okoje VN, Alonge TO, Olusanya AA. Intra-tumoral ligation and the injection of sclerosant in the treatment of lingual cavernous haemangioma. *Niger J Med.* 2011;20(1):172-5.
- [6] Webb CG, Porter G, Sissons GRJ. Cavernous hemangioma of the nasal bones: an alternative management option. *J Laryngol Otol* 2000;114:287-9.
- [7] Fahmy FF, Back G, Smith CE, Hosni A. Osseous hemangioma of inferior turbinate. *J Laryngol Otol* 2001;115:417-8.
- [8] Caylakli F, Çağici AC, Hürcan C, Bal N, Kizilkiliç O, Kiroglu F. Cavernous hemangioma of the middle turbinate: a case report. *Ear Nose Throat J.* 2008;87(7):391-3.
- [9] Nakahira M, Kishimoto S, Miura T, Saito H. Intraosseous hemangioma of the vomer: a case report. *Am J Rhinol* 1997;11:473-7.
- [10] Graumüller S, Terpe H, Hingst V, Dommerich S, Pau HW. Intraossäres Hämangiom der Lamina perpendicularis ossis ethmoidalis. *HNO* 2003;5:142-5.
- [11] Engels T, Schörner W, Felix R, Witt H, Jahnke V. Kavernöses Hämangiom des Sinus maxillaris. *HNO* 1990;38:342-4.
- [12] Gourin C, Donna JM, Burlington ET, Hosni A. *Diagnosis quiz case 3.* Arch Otolaryngol Head Neck Surg 2000; 126:902-7.
- [13] Liu L, Kakiuchi-Kiyota S, Arnold LL, Johansson SL, Wert D, Cohen SM. Pathogenesis of human hemangiosarcomas and hemangiomas. *Hum Pathol.* 2013;44(10):2302-11.
- [14] Berra-Romani R, Avelino-Cruz JE, Raqeeb A, Della Corte A, Cinelli M, Montagnani S *et al.* Ca²⁺-dependent nitric oxide release in the injured endothelium of excised rat aorta: a promising mechanism applying in vascular prosthetic devices in aging patients. *BMC Surg* 2013 Oct 8;13(Suppl 2):S40.
- [15] Moccia F, Dragoni S, Cinelli M, Montagnani S, Amato B, Rosti V *et al.* How to utilize Ca²⁺ signals to rejuvenate the reparative phenotype of senescent endothelial progenitor cells in elderly patients affected by cardiovascular diseases: a useful therapeutic support of surgical approach? *BMC Surg* 2013 Oct 8;13(Suppl 2):S46.
- [16] Moccia F, Lodola F, Dragoni S, Bonetti E, Bottino C, Guerra G *et al.* Ca²⁺ Signalling in Endothelial Progenitor Cells: A Novel Means to Improve Cell-Based Therapy and Impair Tumour Vascularisation. *Curr Vasc Pharmacol* 2014;12(1):87-105.
- [17] Dragoni S, Guerra G, Pla Af, Bertoni G, Rappa A, Poletto V, *et al.* A Functional Transient Receptor Potential Vanilloid 4 (Trpv4) Channel Is Expressed In Human Endothelial Progenitor Cells. *J Cell Physiol* 2015;230(1):95-104.
- [18] Potenza DM, Guerra G, Avanzato D, Poletto V, Pareek S, Guido D *et al.* Hydrogen sulphide triggers VEGF-induced intracellular Ca²⁺ signals in human endothelial cells but not in their immature progenitors. *Cell Calcium.* 2014; 56(3):225-34.
- [19] Sánchez-Hernández Y, Laforenza U, Bonetti E, Fontana J, Dragoni S, Russo M, Avelino-Cruz JE *et al.*, Store-operated Ca²⁺ entry is expressed in human endothelial progenitor cells. *Stem Cells Dev.* 2010; 19(12):1967-81.
- [20] Ronco V, Potenza DM, Denti F, Vullo S, Gagliano G, Tognolina M, Guerra G, Pinton P, Genazzani AA, Mapelli L, Lim D, Moccia F. A novel Ca²⁺-mediated cross-talk between endoplasmic reticulum and acidic organelles: implications for NAADP-dependent Ca²⁺ signalling. *Cell Calcium.* 2015;57(2):89-100.
- [21] Moccia F, Dragoni S, Lodola F, Bonetti E, Bottino C, Guerra G, Laforenza U, Rosti V, Tanzi F. Store-dependent Ca²⁺ entry in endothelial progenitor cells as a perspective tool to enhance cell-based therapy and adverse tumour vascularisation. *Curr Med Chem* 2012;19(34):5802-18.
- [22] Dragoni S, Laforenza U, Bonetti E, Lodola F, Bottino C, Guerra G, Borghesi A, Stronati M, Rosti V, Tanzi F, and Moccia F. Canonical Transient Receptor Potential 3 channel triggers VEGF-induced intracellular ca²⁺ oscillations in endothelial progenitor cells isolated from umbilical cord blood. *Stem Cells and Development* 2013;22(19):2561-80.
- [23] Dragoni S, Laforenza U, Bonetti E, Lodola F, Bottino C, Berra-Romani R, Carlo Bongio G, Cinelli MP, Guerra G, Pedrazzoli P, Rosti V, Tanzi F, Moccia F. Vascular endothelial growth factor stimulates endothelial colony forming cells proliferation and tubulogenesis by inducing oscillations in intracellular Ca²⁺ concentration. *Stem Cells.* 2011;29(11):1898-907.
- [24] Lodola F, Laforenza U, Bonetti E, Lim D, Dragoni S, Bottino C, Ong HL, Guerra G, Ganini C, Massa M, Manzoni M, Ambudkar IS, Genazzani AA, Rosti V, Pedrazzoli P, Tanzi F, Moccia F, Porta C. Store-operated ca(2+) entry is remodelled and controls in vitro angiogenesis in endothelial progenitor cells isolated from tumoral patients. *PLoS One* 2012 7(9):e42541
- [25] Dragoni S, Laforenza U, Bonetti E, Reforgiato M, Poletto V, Lodola F, Bottino C, Guido D, Rappa A, Pareek S, Tomasello M, Guarrera MR, Cinelli MP, Aronica A, Guerra G, Barosi G, Tanzi F, Rosti V, Moccia F. Enhanced Expression of Stim, Orai, and TRPC Transcripts and Proteins in Endothelial Progenitor Cells Isolated from Patients with Primary Myelofibrosis. *PLoS One* 2014;9(3):e91099
- [26] Berra-Romani R, Raqeeb A, Torres-Jácome J, Guzman-Silva A, Guerra G, Tanzi F, Moccia F. The mechanism of injury-induced intracellular calcium concentration oscillations in the endothelium of excised rat aorta. *J Vasc Res.* 2012;49(1):65-76.
- [27] Dragoni S, Turin I, Laforenza U, Potenza DM, Bottino C, Glasnov TN, Prestia M, Ferulli F, Saitta A, Mosca A, Guerra G, Rosti V, Luinetti O, Ganini C, Porta C, Pedrazzoli P, Tanzi F, Montagna D, Moccia F. Store-operated ca(2+) entry does not control proliferation in primary cultures of human metastatic renal cellular carcinoma. *Biomed Res Int.* 2014:739494.
- [28] Archontaki M, Stamou AK, Hajioannou JK, Kalomenopoulou M, Korkolis DP, Kyrmizakis DE. Cavernous haemangioma of the left nasal cavity. *Acta Otorhinolaryngol Ital.* 2008; 28(6): 309–311.
- [29] Amato B, Compagna R, Della Corte GA, Martino G, Bianco T, Coretti G, Rossi R, Braucci A, Aprea G, Zeppa P, Puzziello A, Terranova C. Peripheral blood mono-nuclear cells implantation in patients with peripheral arterial disease: a pilot study for clinical and biochemical outcome of neoangiogenesis. *BMC Surg.* 2012;12 Suppl 1:S1.

- [30] Niccoli Asabella A, Di Palo A, Rubini D, Zeppa P, Notaristefano A, Rubini G. [Distribution of 18F-FDG in a patient with evolving abdominal aortic aneurysm]. *Recenti Prog Med*. 2012;103(11):552-4.
- [31] Caranci F, Brunese L, Reginelli A, Napoli M, Fonio P, Briganti F. Neck neoplastic conditions in the emergency setting: role of multidetector computed tomography. *Semin Ultrasound CT MR*. 2012;33(5):443-8.
- [32] Lazar CC, Costentin B, François A, Marie JP, Dehesdin D. "Bleeding polyp" of the nasal septum: an uncommon lesion in adults. *Ann Otol Rhinol Laryngol*. 2004;113(8):652-4.
- [33] Hyung JK, Jung HK, Jae HK, Eui GH. Bone erosion caused by sinonasal cavernous hemangioma: CT finding in two patients. *Am Soc Neuroradiol* 1994;16:1176_ 8.
- [34] Ash JE, Old JW. Hemangiomas of the nasal septum. *Trans Am Acad Ophtalmol Otolaryngol* 1950;54:350-6.
- [35] Testa D, Motta G, Galli V, Iovine R, Guerra G, Marenzi G, Testa B. **Outcome assessment in patients with chronic obstructive rhinitis CO2 laser treated.** *Acta Otorhinolaryngol Ital*. 2006;26(1):32-7.
- [36] Mesolella M, Galli V, Testa D. Inferior turbinate osteoma: A rare cause of nasal obstruction. *Otolaryngol Head Neck Surg*. 2005;133(6):989-91.
- [37] Testa B, Mesolella M, Squeglia C, Testa D, Motta G. Carbon dioxide laser turbinate surgery for chronic obstructive rhinitis. *Lasers Surg Med*. 2000;27(1):49-54.
- [38] Tafuri D, Testa D, Guerra G, Iovine R, Lamarca S, Galera F, Marmo M, Di Iorio C, Di Minno RM, Iengo M. Barotraumatic sinusitis in underwater sporting activity: Physiopathological and clinical evaluations. *Med Sport* 2006, 59, 3:335-341.