

# Nonfatal Systemic Air Embolism: A Grave Complication of Computed Tomography-Guided Percutaneous Transthoracic Needle Biopsy

Melita Kukuljan<sup>1</sup>, Zlatko Kolić<sup>2</sup>, Duje Vukas<sup>3</sup>, David Bonifačić<sup>4</sup>, Kristina Vrbaneć<sup>4,5</sup>



*Cite this article as:* Kukuljan M, Kolić Z, Vukas D, Bonifačić D, Vrbaneć K. Nonfatal Systemic Air Embolism: A Grave Complication of Computed Tomography-Guided Percutaneous Transthoracic Needle Biopsy. *Eurasian J Med* 2018; 44-6.

<sup>1</sup>Department of Radiology, University Hospital Center Rijeka, Rijeka, Croatia

<sup>2</sup>Department of Neurosurgery, Polyclinic Medico, Rijeka, Croatia

<sup>3</sup>Department of Neurosurgery, University Hospital Center Rijeka, Rijeka, Croatia

<sup>4</sup>Department of Neurology, University Hospital Center Rijeka, Rijeka, Croatia

<sup>5</sup>University of Rijeka, School of Medicine, Rijeka, Croatia

Received: April 19, 2017

Accepted: November 5, 2017

Correspondence to: David Bonifačić

E-mail: [dbonifac@gmail.com](mailto:dbonifac@gmail.com)

DOI 10.5152/eurasianjmed.2018.17091

©Copyright 2018 by the Atatürk University School of Medicine - Available online at [www.eurasianjmed.com](http://www.eurasianjmed.com)

## ABSTRACT

Transthoracic computed tomography-guided core needle biopsy (TTNB) is a well-established method for diagnosing focal pulmonary lesions. However, the dangers associated with this method as well as the significant number of complications caused by it cannot be ignored. Systemic air embolism is a rare but potentially fatal complication that can accompany transthoracic needle biopsies of pulmonary lesions. In this study, we report nonfatal systemic air embolism as a complication of a transthoracic needle core biopsy of a subpleural nodule in the right upper pulmonary lobe of a patient with hemoptysis. Although extremely rare, the complication may result in a transient myocardial ischemia, which is presented with a transient depression of the ST segment.

**Keywords:** Air embolism, CT-guided biopsy, needle core lung biopsy

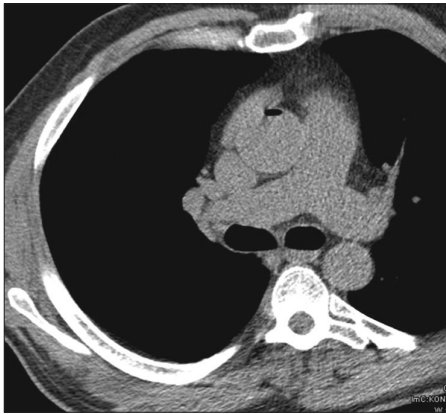
## Introduction

Transthoracic needle core biopsy (TTNB) is an essential diagnostic method for the evaluation of various thoracic lesions. It can safely and efficiently provide an accurate cytological or histological diagnosis and thus usually obviates the need for more invasive surgical procedures, decreases the duration of hospitalization, and provides substantial cost savings [1]. However, a wide variety of complications may occur during TTNB such as pneumothorax, perifocal intraparenchymal bleeding, hemoptysis, hemothorax, infection, massive pulmonary hemorrhage, and air embolism [2-7]. Among them, systemic air embolism is the least common but a serious complication because it may manifest in coronary and cerebral arteries resulting in myocardial infarction, dysrhythmias, cardiac arrest, and ischemic cerebral strokes, usually with a fatal outcome [6-9]. We herein present a nonfatal systemic air embolism as a rare complication of a TTNB of a subpleural nodule in the right upper pulmonary lobe of a patient with hemoptysis.

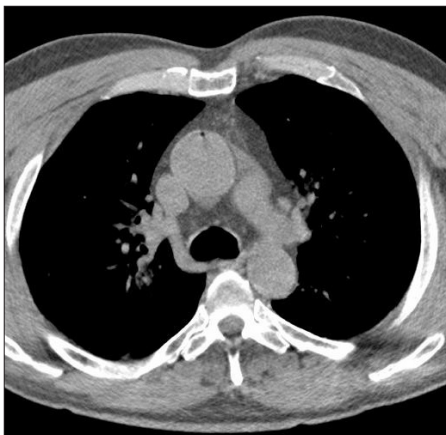
## Case Report

A 60-year-old patient was admitted to our hospital due to recurrent episodes of hemoptysis over the course a week. Computed tomography (CT) of the thorax was performed and revealed a nodular mass in the subpleural part of the anterior segment of the right upper pulmonary lobe, suspecting a peripheral malignant bronchial tumor. A transthoracic needle core biopsy was decided and performed with an 18-gauge cutting needle using a semi-automatic triggering mechanism.

The standard procedure followed at our institution is the non-coaxial technique with a semi-automatic 18-gauge cutting needle comprising an outer cutting cannula and an inner stylet with a notch for tissue specimens of 20 mm in length. After inserting the needle into the edge of the target lesion, the inner slotted stylet is extended and followed by the outer cutting cannula, which collects a piece of the tissue as a sample. The position of the inner slotted stylet was monitored using consecutive CT images of the biopsied area, which was followed by needle insertion into the edge of the target lesion, and then automatic triggering was initiated. CT images have shown that a part of the inner stylet had remained outside the lesion, but this was expected with lesions that are smaller than 20 mm in diameter, and, in our case, it was 15 mm. CT images obtained just before needle triggering showed no abnormalities, and the patient was asymptomatic. At the moment of needle triggering, when the pulmonary tissue was excised and the needle was



**Figure 1.** Control transverse CT scans shows air embolus in the ascending aorta and the left ventricle



**Figure 2.** Control transverse CT scans shows air embolus in the ascending aorta and the left ventricle

extracted from the chest, the patient exhibited chest pain with excessive sweating and pale skin. In addition, he behaved in an agitated and confused manner.

We immediately performed a control CT scan of the thorax that revealed air bubbles in the ascending aorta and a significant amount of air in the left ventricle (Figure 1, 2). Because the patient's state of awareness was altered, we also performed a CT brain scan but found no abnormalities.

Given the exhibited symptoms and the CT results, we assumed that a myocardial ischemia occurred owing to air embolism in the coronary arteries. We immediately measured the patient's blood pressure, which decreased from 140/70 to 70/40 mmHg and performed an electrocardiography, (ECG) which showed an ST depression. The patient was administered 0.9% NaCl infusion and 100% oxygen 10 L/min. The patient recovered quickly; his blood pressure normalized, a repeat ECG displayed a recovery of the ST depression, and the other symptoms disappeared. After approximately 20 min, we

performed an additional CT scan of thorax that showed no signs of air embolism. We kept the patient in the cardiology ward for another 24 h and thereafter released him in a good overall condition. Written informed consent was obtained from patient who participated in this study.

## Discussion

Transthoracic needle core biopsy is enormously important in diagnosing suspected thoracic lesions because it allows us to avoid exploratory thoracotomy. The most frequent and usually harmless complications associated with this procedure are pneumothorax, perifocal bleeding, and hemoptysis. Much less frequent complications include air embolism and massive pulmonary hemorrhage, which can be fatal. The clinical presentation is similar to that of thromboembolic stroke syndrome, ranging from focal neurological deficits of rapid onset such as hemiplegia, confusion, or convulsions. Coronary artery air embolism can induce ECG changes typical of ischemia and infarction, dysrhythmias, and cardiac arrest [5, 7-10]. Systemic air embolism is a rare but severe complication of TTNB. Of the 722 patients who underwent needle core biopsy at our hospital over the last 5 years, this was the first case of air embolism (0.13%). Mechanisms of air embolism during transthoracic needle core biopsy are not fully clarified. Two possible mechanisms of air embolism in the pulmonary venous system are frequently mentioned in literature. One of them is the direct entry of air into the pulmonary vein during fine-needle aspiration biopsy. This occurs after the stylus has been removed from the needle that was inserted directly into the pulmonary vein while the atmospheric pressure overcomes the pressure in the vein, which can occur during deep inspiration. During the non-coaxial cutting needle biopsy technique, used at our institution, the previously described mechanism is not possible because the cutting needle prevents the entry of atmospheric air. The other possible way of the entry of air is the formation of a communicating fistula [8, 10]. It is widely considered that the factors that lead to the increase of air pressure inside the airspace of the lungs, such as coughing, Valsalva maneuvers, or positive pressure ventilation, also increase the risk of air embolism. Air in the pulmonary vein system usually embolizes coronary or cerebral arteries. Diagnosis of systemic air embolism is not always simple and is based on clinical findings such as sudden deterioration of neurological or car-

diovascular status. The presence of air bubbles in the left atrium, ventricle, aorta, pulmonary veins, or cerebral arteries on the CT scans of the chest or brain are definitive confirmations of this state. In our case, clinical and electrocardiographic findings showed temporary myocardial ischemia probably caused by air embolism of the coronary arteries. Although our CT scans failed to prove direct signs of coronary air embolism, we considered the presence of air in the aorta and the left ventricle as an indirect confirmation of this condition. Three mechanisms of coronary air embolism leading to myocardial ischemia have been previously reported as follows: obstruction of the coronary flow, intense coronary vasospasm induced by air bubbles, and the formation of microthrombus.

Iatrogenically formed bronchial-venous fistula was most likely the cause of air embolism in our case owing to the absence of cysts or bullae in the lungs and of the cavernous nature of the biopsied lesion. In current literature, penetration with a bioptic needle into the lungs during the biopsy is considered to be the only risk factor for the occurrence of iatrogenic bronchial venous fistula, and the risk is relative to the distance between the pleura and the target lesion. In the present case, symptoms of air embolism manifested after automatic triggering. Therefore, we conclude the fistula was formed at the time of tissue sampling as a result of the stylet penetrating the healthy lung tissue outside the boundaries of the target lesion due to the length of the needle. Although there are many reported cases of air embolism caused by CT-guided TTNB, we did not find any described case of transient myocardial ischemia presented with a transient depression of the ST segment. Furthermore, up to this point, a higher incidence of iatrogenic bronchial-venous fistula was not associated with bioptic procedures involving small lesions due to penetration of healthy lung tissue [5, 7-10]. In summation, we presented a case of air embolism most likely caused by formation of the fistula. To the best of our knowledge, this is the first case to report air embolism causing transient myocardial ischemia presented with a transient depression of the ST segment and the incidence of iatrogenic bronchial-venous fistula associated with bioptic procedures involving small lesions.

**Informed Consent:** Written informed consent was obtained from patient who participated in this study.

**Peer-review:** Externally peer-reviewed.

**Author Contributions:** Concept - M.K.; Design - Z.K.; Supervision - D.B.; Data Collection and/or Processing - D.V.; Literature Search - K.V.; Writing Manuscript - K.V.; Critical Review - M.K.

**Conflict of Interest:** No conflict of interest was declared by the authors.

**Financial Disclosure:** The authors declared that this study has received no financial support.

## References

1. Birchard KR. Transthoracic Needle Biopsy. *Semin Intervent Radiol.* 2011; 28: 87-97. [\[CrossRef\]](#)
2. Vagn-Hansen C, Roland Pedersen M, Rafaelsen S.R. Diagnostic yield and complications of transthoracic computed tomography-guided biopsies. *Dan Med J* 2016; 63.
3. Brandén E, Wallgren S, Högberg H, Koyi H. Computer Tomography-Guided Core Biopsies in a County Hospital in Sweden: Complication Rate and Diagnostic Yield. *Ann Thorac Med* 2014; 9: 149-53. [\[CrossRef\]](#)
4. Mokhlesi B, Ansaarie I, Bader M, Tareen M, Boatman J. Coronary artery air embolism complicating a CT-guided transthoracic needle biopsy of the lung. *Chest* 2002; 121: 993-6. [\[CrossRef\]](#)
5. Mansour A, AbdelRaouf S, Qandeel M, Swaidan M. Acute coronary artery air embolism following CT-guided lung biopsy. *Cardiovasc Intervent Radiol* 2005; 28: 131-4. [\[CrossRef\]](#)
6. Arnold BW, Zwiebel WJ. Percutaneous transthoracic needle biopsy complicated by air embolism. *AJR Am J Roentgenol* 2002; 178: 1400-2. [\[CrossRef\]](#)
7. Khalil A, Prigent H, Parrot A, Carette MF. Systemic air embolism complicating percutaneous needle biopsy. *AJR Am J Roentgenol* 2006; 187: W242-3. [\[CrossRef\]](#)
8. Olgun DC, Samanci C, Ergin AS, Akman C. Life-Threatening Complication of Percutaneous Transthoracic Fine-Needle Aspiration Biopsy: Systemic Arterial Air Embolism. *Eurasian J Med* 2015; 47: 72-4. [\[CrossRef\]](#)
9. Hung WH, Chang CC, Ho SY, Liao CY, Wang BY. Systemic air embolism causing acute stroke and myocardial infarction after percutaneous transthoracic lung biopsy-a case report. *J Cardiothorac Surg* 2015; 10: 121. [\[CrossRef\]](#)
10. Bou-Assaly W, Pernicano P, Hoeffner E. Systemic air embolism after transthoracic lung biopsy: A case report and review of literature. *World J Radiol* 2010; 2: 193-6. [\[CrossRef\]](#)