

“Stormy” jaundice – an unusual presentation of thyrotoxic crisis

„Olujni” ikterus – neobična klinička prezentacija tireotoksične krize

Andrej Belančić^{1*}, Sanja Klobučar Majanović²

¹ Faculty of Medicine, University of Rijeka, Rijeka

² Department of Endocrinology, Diabetes and Metabolic Diseases, Clinical Hospital Centre Rijeka, Faculty of Medicine, University of Rijeka, Rijeka

Abstract. Aim: The aim was to present jaundice as the first and most remarkable presenting symptom of this extraordinary thyrotoxic crisis (TTC) case. Due to an unusual clinical presentation this case was a diagnostic dilemma and therapeutic challenge. **Case report:** A 34-year-old male was admitted to the Emergency Department due to fatigue, diarrhea, jaundice and subjective feeling of increased heart rate. Patient had previous history of hyperthyroidism and paroxysmal atrial fibrillation (AF), but he wasn't taking any medication. ECG revealed AF with rapid ventricular response and left ventricular hypertrophy. Laboratory findings spoke in favor of hepatocellular jaundice. Consequently, the patient was hospitalized at the Department of Gastroenterology. Subsequently arrived thyroid function test confirmed the presence of thyrotoxicosis. Thiamazole, bisoprolol, methylprednisolone, enoxaparin and metildigoxin were introduced into therapy. In further course of hospitalization patient was transferred to the Department of Cardiovascular Diseases due to development of global heart failure. The heart failure therapy was introduced. Significant clinical improvement was achieved and the patient was transferred to the Department of Endocrinology. The parameters of the liver function were improving. Doses of thiamazole were gradually decreasing during hospitalization and thyroid hormones were brought to normal values. **Conclusions:** TTC is extremely rare in clinical practice, but may occur in cases of unrecognized or inadequately treated hyperthyroidism. If left untreated, results with lethal outcome in 80-90% of the cases, but even if treated mortality rate exceeds 20%. Therefore, early recognition and treatment are of the utmost importance.

Key words: emergency; hyperthyroidism; jaundice; thyrotoxic crisis

Sažetak. Cilj: Prikazati nesvakidašnji slučaj tireotoksične krize (TTK) čiji je prvi i najupečatljiviji klinički simptom bio ikterus. Zbog neobične kliničke prezentacije ovaj slučaj bio je dijagnostički i terapijski izazov. **Prikaz slučaja:** 34-godišnji pacijent primljen je zbog malaksalosti, dijareje, ikterusa i osjećaja ubrzanog rada srca. Pacijent od ranije boluje od hipertireoze i paroksizmalne fibrilacije atrijske (FA), no kroničnu terapiju ne uzima. Snimljen je EKG i utvrđena je fibrilacija atrijske s brzim odgovorom klijetke te hipertrofija lijeve klijetke. U laboratorijskim nalazima bio je prisutan obrazac hepatocelularnog ikterusa. Posljedično se pacijenta hospitalizira na Zavodu za gastroenterologiju. Novopridošli nalaz hormona štitnjače potvrdio je tireotoksikozu. U terapiju se uvode tiamazol, bisoprolol, metilprednizolon, enoksaparin te metildigoksin. Zbog pogoršanja općeg stanja i razvoja globalnog srčanog zatajivanja (SZ) pacijenta se premješta na Zavod za kardiovaskularne bolesti. Primjenom standardne terapije SZ-a postignuto je značajno kliničko poboljšanje. Pacijenta se premješta na Zavod za endokrinologiju u svrhu nastavka liječenja. Parametri jetrene funkcije su u poboljšanju. Doza tireostatika postepeno se smanjuje, a vrijednosti hormona štitnjače dovedene su u normalu. **Zaključci:** Tireotoksična kriza izuzetno je rijetka u kliničkoj praksi, no može se javiti u slučaju neprepoznate ili neadekvatno medikamentozno liječene hipertireoze. Ako se ne liječi, TTK rezultira smrtnim ishodom u 80 – 90 % slučajeva. Kada se i liječi, smrtnost svejedno prelazi 20 %. Pravovremeno prepoznavanje i liječenje neizmjerljivo je važno.

Ključne riječi: hipertireoza; hitno stanje; tireotoksična kriza; žutica

***Corresponding author:**

Andrej Belančić

Faculty of Medicine, University of Rijeka
Braće Branchetta 20, 51 000 Rijeka
e-mail: a.belancic93@gmail.com

<http://hrcak.srce.hr/medicina>

INTRODUCTION

Thyrotoxic crisis (TTC) or thyroid storm is a rare life-threatening exacerbation of hyperthyroidism characterized by dysfunction of one or more organ systems due to an excessive hypermetabolic state. The most common cause of TTC is unrecognized or inadequately treated hyperthyroidism¹. There is usually some specific precipitating event such as infection, sepsis, severe emotional stress, trauma, surgery, withdrawal of antithyroid drug therapy, cerebrovascular accident etc². The exact prevalence of TTC is not precisely estimated, however it may account for <1-2% of thyrotoxicosis hospital admissions³.

Clinical manifestations include fever, tremor, abdominal pain, nausea, vomiting, diarrhea, dehydration, central nervous system disturbances (psychosis, agitation, somnolence, coma) and cardiovascular symptoms (tachycardia, atrial fibrillation and congestive heart failure)^{4,5}. However, it may also present as masked or apathetic thyrotoxicosis, in which signs and symptoms may be subtle and not previously connected with thyrotoxicosis². Sepsis, infections of the central nervous system, poisoning with anticholinergic/sympathomimetic drugs, endocrinopathies and acute psychosis should be an important part of TTC differential diagnosis due to similar clinical presentation⁵. In most emergency departments it is difficult to obtain rapid laboratory or nuclear medicine tests to confirm thyrotoxicosis. Moreover, suppressed levels of thyroid stimulating hormone (TSH) and elevated levels of free triiodothyronine (FT3) and thyroxine (FT4) are characteristic, but not very helpful to distinguish uncomplicated thyrotoxicosis from TTC, since they correlate poorly with the severity of condition^{2,3,6}. Laboratory findings are not specific, but may include liver function abnormalities, hypercalcemia, hypokalemia, hyponatremia, hyperglycemia and leukocytosis^{3,4}.

The most frequently used system to distinguish thyroid storm (score >45), impending storm (score 25-44) and uncomplicated thyrotoxicosis (score <25) is Burch and Warthofsky's scoring system (Table 1)⁷. To deduce, the diagnosis of thyroid storm is usually clinically based and if the patient's clinical picture is consistent for thyroid storm, medication should be introduced as soon as possible.

The diagnosis of thyroid storm is usually clinically based and if the patient's clinical picture is consistent for thyroid storm, medication should be introduced as soon as possible. Thyroid storm management is based on 3 principles: specific treatment, supportive care and treatment of the possible underlying precipitating event.

Table 1. Burch and Wartofsky's scoring system. Modified according to reference 7

Parameters	Scoring system
1. Thermoregulatory dysfunction	5 – 30
37.2 – 37.7 °C	5
37.8 – 38.3 °C	10
38.4 – 38.8 °C	15
38.9 – 39.4 °C	20
39.5 – 39.9 °C	25
≥ 40 °C	30
2. Cardiovascular dysfunction	
a) Tachycardia	5 – 25
90 – 109	5
110 – 119	10
120 – 129	15
130 – 139	20
≥ 140	25
b) Congestive heart failure	0 – 15
Absent	0
Mild (pedal edema)	5
Moderate (bibasal rales)	10
Severe (pulmonary edema)	15
c) Atrial fibrillation	0 – 10
Absent	0
Present	10
3. Central nervous system symptoms	0 – 30
Absent	0
Mild agitation	10
Moderate (delirium, psychosis, extreme lethargy)	20
Severe (seizure, coma)	30
4. Gastrointestinal-hepatic dysfunction	0 – 20
Absent	0
Moderate (diarrhea, nausea, vomiting, abdominal pain)	10
Severe (unexplained jaundice)	20
5. Precipitating event	0 – 10
Absent	0
Present	10

The management of TTC is based on 3 principles: specific treatment, supportive care (in order to reverse systemic decompensation) and treatment of the possible underlying precipitating event. Specific treatment include: antithyroid agents, beta adrenergic blockers and corticosteroids. Lowering the circulating level of thyroid hormones is achieved by preventing its synthesis or by blocking the release. The recommended dose for methimazole is 60-80 mg/day orally, via nasogastric tube or through rectal administration and for propylthiouracil 500-1000 mg initially and afterwards in a dose of 250 mg every 6 hours orally, via nasogastric tube or through rectal administration^{5,8}. However, initial effect is usually delayed in 3-4 days. Beta adrenergic blockers are used due to management of the associated sympathoadrenal activation (control of the heart rate, reduction of the cardiac output and workload, beneficial effects on the accompanying agitation and fever)³. Propranolol is the most frequently used beta blocker for TTC management. It is used in a dose of 60-80 mg orally every 4 hours^{5,8}. Corticosteroids inhibit peripheral conversion of T4 to T3, moreover they

also have beneficial effect such as correction of the relative adrenal insufficiency and inhibition of release of thyroid hormones when given at high doses. According to recommended regimens: dexamethasone 2 mg intravenously every 6 hours or hydrocortisone 300 mg intravenously initially and then 100 mg intravenously every 8 hours³.

We report an interesting, challenging case of a 34-year-old male patient with jaundice and tachyarrhythmia as the presenting manifestation of TTC.

CASE REPORT

A 34-year-old male was admitted to the Emergency Department due to fatigue, diarrhea, jaundice and subjective feeling of increased heart rate. In clinical status: afebrile (36.2 °C), eupnoeic, arrhythmic pulse with frequency of 140/min, blood pressure 140/80 mmHg, exophthalmos, hepatomegaly and fine tremor of arms and fingers. Patient had previous history of hyperthyroidism and paroxysmal atrial fibrillation (AF), but he wasn't taking any medication. ECG revealed AF with rapid ventricular response and left ventricular (LV) hypertrophy (Fig-

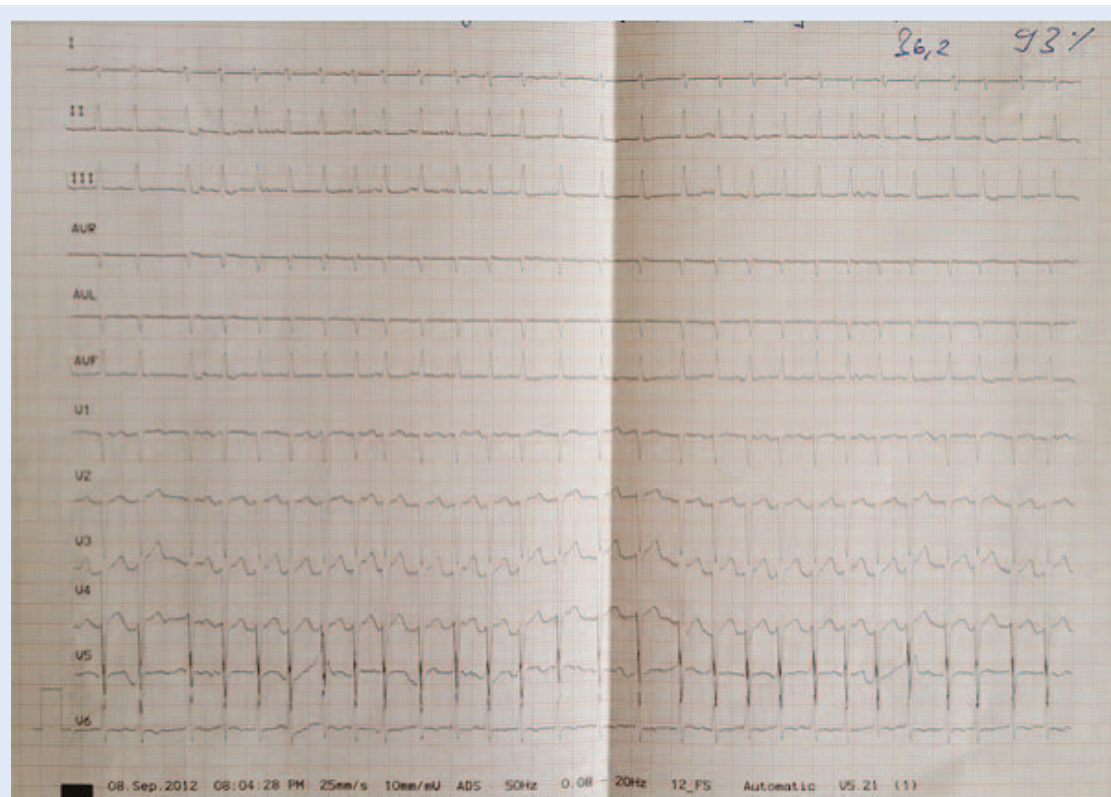


Figure 1. ECG: atrial fibrillation with rapid ventricular response (170/min) and left ventricular hypertrophy

ure 1). Chest x-ray showed: prominent right hilus, suspected right perihilar infiltrates, upper zone vessel prominence, slight blunting of the both costophrenic angles indicating a small bilateral pleural effusions, increased cardiothoracic ratio and flattened waist. Laboratory findings spoke in favor of hepatocellular jaundice: leukocytes (Lkc) $10.2 \times 10^9/L$ (normal range $3.4-9.7 \times 10^9/L$), lymphocytes $3.5 \times 10^9/L$ (normal range $1.19-3.35 \times 10^9/L$), total bilirubin (TBIL) $132 \mu\text{mol/L}$ (normal range $3-20 \mu\text{mol/L}$), conjugated (direct) bilirubin (DBIL) $61 \mu\text{mol/L}$ (normal range $<5 \mu\text{mol/L}$), aspartate aminotransferase (AST) 328 U/L (normal range $8-30 \text{ U/L}$), alanine aminotransferase (ALT) 311 U/L (normal range $10-36 \text{ U/L}$), alkaline phosphatase (ALP) 177 U/L (normal range $54-119 \text{ U/L}$), γ -glutamyl-transferase (γ GT) 40 U/L (normal range $9-35 \text{ U/L}$), c-reactive protein (CRP) 21.3 mg/L (normal range $<5.0 \text{ mg/L}$). Abdominal ultrasound examination showed the presence of medium abundant ascites and discrete bilateral pleural effusion. The patient was hospitalized at the Department of Gastroenterology due to processing of hepatocellular jaundice and diarrhea. Screening for causative agents of viral hepatitis was negative. Thyroid hormones test result confirmed the presence of thyrotoxicosis: TSH $<0.004 \text{ mU/L}$ (normal range $0.3-5 \text{ mU/L}$), FT4 31.0 pmol/L (normal range $11.5-22.7 \text{ pmol/L}$). The final diagnosis was TTC accompanied by AF with rapid ventricular response. Consequently, thiamazole, bisoprolol, methylprednisolone, enoxaparin and metildigoxin were introduced into therapy. Parameters of liver function started improving after introduced therapy (TBIL $110 \mu\text{mol/L}$, AST 67 U/L , ALT 122 U/L , ALP 139 U/L , γ GT 43 U/L). In further course of hospitalization the patient's general condition was deteriorating and he was transferred to the Department of Cardiovascular Diseases due to presence of dyspnea, hypotension and signs of global heart failure. Echocardiography (ECHO) revealed severe systolic dysfunction with ejection fraction (EF) 25%, mild dilatation of the LV (LV diameter in diastole-LVIDd 62 mm , LV diameter in systole-LVIDs 53 mm) and enlarged left atrium (LA 52 mm). The conclusion was dilated cardiomyopathy as a consequence of thyrotoxicosis. The heart failure therapy was introduced (furosemide, spironolactone, ramipril,

carvedilol). Diuresis was established and significant clinical improvement was achieved. Hence, the patient was transferred to the Department of Endocrinology due to continuing the treatment. The parameters of the liver function were improving (TBIL $19 \mu\text{mol/L}$, AST 30 U/L , ALT 61 U/L , ALP 99 U/L), and warfarin was introduced due to presence of persistent AF. Doses of thiamazole were gradually decreasing during hospitalization and thyroid hormones were brought to normal values (TSH 4.99 mU/L , FT4 15.75 pmol/L). After a month long hospitalization the patient was discharged.

Jaundice, in our case of thyrotoxic crisis, was the consequence of three hepatic injury patterns: hepatic tissue hypoxia, direct toxic effect of thyroid hormones on hepatocytes and passive liver congestion due to weakening of heart activity triggered by AF with rapid ventricular response.

DISCUSSION

The aim of this TTC report is to increase the awareness of this rare, but treatable emergency condition. Moreover, to present an extraordinary case in which jaundice was the first and most remarkable clinical manifestation of TTC. Due to an extraordinary clinical presentation of this endocrine emergency this case was a diagnostic dilemma and therapeutic challenge.

Self limited hepatitis with mild elevations in serum total bilirubin levels is seen in up to 5% of the patients with thyrotoxicosis⁹. However, it is less likely that a serum total bilirubin level reaches 132 U/L , as observed in our case. Moreover, aminotransferase levels exceed $\geq 250 \text{ U/L}$ in only 3% cases of hyperthyroidism¹⁰. Significantly elevated levels of conjugated bilirubin and hepatic enzymes, reported in our case, are evidences of severe hepatocellular injury. Hepatic dysfunction related to hyperthyroidism covers a broad diagnostic spectrum and may result from the effects of thyroid hormone excess, drug-induced liver injury and/or the presence of pre-existing or concomitant liver disease¹¹. Thyroid hormones have effects on cardiovascular hemodynamics; indirectly through their effect on the vasculature and body metabolism,

and directly through effect on the heart. Peripherally, T₃ decreases systemic vascular resistance by stimulating vasodilatation^{12,13}. Decrease in systemic vascular resistance activates the renin-angiotensin-aldosterone system, leading to retention of sodium and fluid and consequently to increase in total blood volume and preload¹⁴. T₃ also acts directly by entering the myocytes via specific transport proteins, which results in enhanced cardiac contractility and relaxation^{15,16}. To sum up, all these cardiac effects lead to high cardiac output, which is in hyperthyroidism 50% to 300% higher than in normal individuals¹⁷. However, latter increase in cardiac output is not adequately followed with an increase in hepatic blood flow, which consequently leads to increased oxygen demand in the hepatocytes. The combination of increased oxygen demand and decreased perfusion leads to tissue hypoxia and histologically necrosis^{18,19}. Moreover, the liver is the prime organ of thyroid hormone metabolism (synthesis of thyroid hormone-binding proteins, 85% of extrathyroidal deiodination of T₄ to T₃ and reverse T₃)⁹. Hence, another possible mechanism of TTC hepatic injury is the direct toxic effect of thyroid hormones on hepatocytes²⁰. Interestingly, preclinical studies demonstrated that high levels of thyroid hormones can also impair UDP glucuronosyltransferase activity and lead to elevated bilirubin levels and jaundice²¹. Exacerbations of previously described hemodynamic changes may be best seen during TTC, when direct effects of excess thyroid hormone are combined with a higher oxygen requirement by mitochondrial-based metabolism within the hepatocytes¹⁹. To set up this conclusion we have first rejected possibility of viral hepatitis, alcohol abuse, sepsis, cholangitis, Gilbert's syndrome, drug-induced and autoimmune diseases which are an important part of jaundice differential diagnosis²². In the present case, patient was afebrile and serologically negative for common hepatitis viruses B, C. Alcohol abuse and drug-induced (isoniazid, rifampicin, acetaminophen etc.) etiology were ruled out by anamnesis and clinical picture. What is more, γ GT (40 U/L) was not significantly elevated. In Gilbert's syndrome conjugated bilirubin is not significantly elevated and jaundice is a consequence of unconjugated hyperbilirubinaemia.

Thereafter, confirmation of autoimmune hepatitis and primary biliary cirrhosis require the presence of anti-nuclear antibodies, anti-smooth muscle antibodies and anti-mitochondrial antibodies. Moreover, in our case ALP and γ GT were only slightly elevated in comparison to AST and ALT levels. To deduce, the evidence of our conclusion validity is an obvious improvement in the liver function parameters immediately after introducing thiamazole, bisoprolol and methylprednisolone into therapy.

There are three possible explanations for the preferential involvement of the atria in hyperthyroidism: abundance of β receptors, difference of the atria and the ventricles in the autonomic input and difference in sensitivity to thyroid hormones¹⁶. Sinus tachycardia is the most common rhythm disturbance in hyperthyroidism, however it is AF that is most frequently identified with severe thyrotoxicosis. The prevalence of AF in hyperthyroidism ranges between 2% and 20%. Treatment of AF due to hyperthyroidism includes β -adrenergic blockade with β -selective or non-selective agents¹⁷. Digoxin is used in cases of AF with rapid ventricular response. Serum digoxin levels in thyrotoxicosis are low due to increased volume of distribution and metabolism, consequently higher than normal doses are required. Short-term anticoagulation may be used in severe cases and stopped when sinus rhythm has been achieved¹⁶. In a subset of patients with uncontrolled long-term AF, the development of hyperthyroid cardiomyopathy (dilated cardiomyopathy with superimposed LV dysfunction) is possible²³. Systolic heart failure could be the consequence of tachycardia-induced systolic LV dysfunction or the consequence of prolonged exposure to thyroid hormones, however it is completely reversible if treated adequately¹⁶. LV systolic dysfunction due to severe hyperthyroidism is not restricted to elderly patients, moreover it can develop in younger patients with untreated hyperthyroidism. The therapy for patients with thyrotoxic heart failure should be based on: management of thyrotoxicosis, cardioselective β -blockers (metoprolol, esmolol), ACE inhibitors and also on the use of diuretics and digoxin in case of overt heart failure involving pulmonary congestion^{16,17,24}.

Jaundice is a potential symptom of heart failure due to passive liver congestion or acute ischemic hepatitis²⁵. However, serum bilirubin and aminotransferase levels are usually just slightly elevated, on contrary to values reported in the present case. Hence, our opinion is that the jaundice occurred as a consequence of the combination of three hepatic injury patterns: hepatic tissue hypoxia, direct toxic effect of thyroid hormones on hepatocytes and passive liver congestion due to weakening of heart activity triggered by AF with rapid ventricular response.

CONCLUSION

TTC is extremely rare in clinical practice, but may occur in cases of unrecognized or inadequately treated hyperthyroidism. Moreover, this endocrine emergency is a life-threatening condition and it should be considered in differential diagnosis, especially in patients with previously diagnosed hyperthyroidism. TTC, if left untreated, results with lethal outcome in 80-90% of the cases, but even if treated mortality rate exceeds 20%⁵. Therefore, early recognition and treatment are of the utmost importance. In conclusion, jaundice can be the presenting symptom of hyperthyroidism/TTC and consequently create difficulties in differential diagnosis and management.

Conflicts of interest statement: the authors report no conflicts of interest.

REFERENCES

1. Bečejec B, Vrkljan M, Solter M, Sikirica N. Thyrotoxic crisis in a 75-year-old woman. *Acta Clin Croat* 2003;42: 229-31.
2. Tjokropawiro A. Thyroid storm: A Life-Threatening Thyrotoxicosis. *Folia Medica Indonesiana* 2006;42: 271-6.
3. Migneco A, Ojetti V, Testa A, De Lorenzo A, Gentiloni Silveri N. Management of thyrotoxic crisis. *European Review for Medical and Pharmacological Sciences* 2005;9: 69-74.
4. Tzemanakis E, Papanikolaou IS, Zervas A, Malachtari S, Dourakis SP. Acute icteric hepatitis as the main manifestation of hyperthyroidism. *Annals of Gastroenterology* 2000;13:54-7.
5. Goldberg PA, Inzucchi SE. Critical issues in endocrinology. *Clin Chest Med* 2003;24:583-606.
6. Ringel MD. Management of hypothyroidism and hyperthyroidism in the intensive care unit. *Crit Care Clin* 2001;17:59-74.
7. Burch HB, Wartofsky L. Life threatening thyrotoxicosis: thyroid storm. *Endocrinol Metab Clin North Am* 1993; 22:263-79.
8. Bahn RS, Burch HB, Cooper DS, Garber JR, Greenlee MC, Klein I et al. Hyperthyroidism and other causes of thyrotoxicosis: management guidelines of the American Thyroid Association and American Association of Clinical Endocrinologists. *Endocr Pract* 2011;17:456-520.
9. Krishna K, Pankaj M, Tuteja A, Jagtap V. Jaundice heralding the Onset of Thyrotoxic Crisis. *Journal of the Association of Physicians of India* 2016;64:94-5.
10. Fong TL, McHutchinson JG, Reynolds TB. Hyperthyroidism and hepatic dysfunction. A case series analysis. *J Clin Gastroenterol* 1992;14:240-4.
11. Khemician S, Fong TL. Hepatic dysfunction in hyperthyroidism. *Gastroenterol Hepatol (NY)* 2011;7:337-9.
12. Park KW, Dai HB, Ojamaa K, Lowenstein E, Klein I, Sellke FW. The direct vasomotor effect of thyroid hormones on rat skeletal muscle resistance arteries. *Anesth Analg* 1997;85:734-8.
13. Ojamaa K, Klemperer JD, Klein I. Acute effects of thyroid hormone on vascular smooth muscle. *Thyroid* 1996;6:505-12.
14. Resnick LM, Laragh JH. Plasma renin activity in syndromes of thyroid hormone excess and deficiency. *Life Sci* 1982;3:585-6.
15. Mintz G, Pizzarello R, Klein I. Enhanced left ventricular diastolic function in hyperthyroidism: non-invasive assessment and response to treatment. *J Clin Endocrinol Metab* 1991;73:146-50.
16. Riaz K, Forker AD, Isley WL, Hamburg MS, McCullough PA. Hyperthyroidism: a curable cause of congestive heart failure – three case reports and a review of the literature. *Congest Heart Fail* 2003;9:40-6.
17. Klein I, Danzi S. Thyroid Disease and the Heart. *Circulation* 2007;116:1725-35.
18. Oguntolu V. Severe thyrotoxicosis (thyroid storm) with liver failure. *Acute Med* 2007;6:30-2.
19. Campos Mazo DF, Vasconcelos GB, Pereira MA, Mello ES, Bacchella T, Carrilho FJ et al. Clinical spectrum and therapeutic approach to hepatocellular injury in patients with hyperparathyroidism. *Clinical and Experimental Gastroenterology* 2013;6:9-17.
20. Jain D, Aggarwal DK, Singla S, Pawar S, Jain P, Mittal A. Hyperthyroidism Manifesting as Clinical Jaundice: A Report of a Rare Case. *Turk Jem* 2015;19:76-8.
21. Soleimanpour SA. Fulminant liver failure associated with delayed identification of thyroid storm due to heterophile antibodies. *Clin Diabetes Endocrinol* 2015; Forthcoming.
22. Wickramasinghe RD, Luke WA, Sebastiampillai BS, Gunathilake MP, Premaratna R. Thyrotoxic crisis presenting with jaundice. *BMC Res Notes* 2016;9:320.
23. Forfar JC, Muir AL, Sawers SA, Toft AD. Abnormal left ventricular function in hyperthyroidism: evidence for possible reversible cardiomyopathy. *N Engl J Med* 1982;307:1165-70.
24. Danzi S, Klein I. Thyroid hormone and blood pressure regulation. *Curr Hypertens Rep* 2003;5:513-20.
25. Yamaguchi H, Takahashi A, Shirakami A, Kageyama N, Kitazoe K, Fujinaga H. A Case of Thyroid Crisis With Worsening Jaundice Despite Improvements in Heart Failure. *J Endocrinol Metab* 2016;6:59-63.