

Case Report

Pediatric Solid Pseudopapillary Neoplasm[Spn] of The Pancreas – Case Report and Literature Review

Jelena Roganovic*, Matijasic N and Jonjic N

School of Medicine, University of Rijeka and Department of Pediatrics, Croatia

*Corresponding author

School of Medicine, University of Rijeka and Department of Pediatrics, Croatia, Email: jelena.roganovic1@ri.t-com.hr

Submitted: 21 January 2015

Accepted: 14 February 2015

Published: 16 February 2015

ISSN: 2373-9282

Copyright

© 2015 Roganovic

OPEN ACCESS

Abstract

Background: Pediatric pancreatic malignancies are extremely rare with an age population-adjusted incidence of 0.018 cases per 100,000. In adolescent girls, they usually present as solid pseudopapillary neoplasms[SPNs], low-grade malignant tumors of the exocrine pancreas. Due to their rarity and nonspecific clinical presentation, SPNs are frequently misdiagnosed. The treatment of choice is a complete surgical resection with 5-year survival rate of 97%.

Case Report: We report a 17-year-old girl with SPN presenting with jaundice and itchy skin. She was initially misdiagnosed with hepatoblastoma, and treated with neoadjuvant chemotherapy. The girl later underwent surgical excision, and is in complete remission seven years after the diagnosis.

Conclusion: Although rare, SPNs need to be included in the differential diagnosis of abdominal masses in children. MRI detected, well-defined, encapsulated, heterogeneous mass, especially in adolescent females, should always be suspicious for SPN. Further prospective multi-institutional studies are required in order to standardize preoperative evaluation and reduce the high misdiagnosis rate.

INTRODUCTION

Solid pseudopapillary neoplasms[SPNs] are low-grade malignant tumors of the exocrine pancreas predominantly affecting young women [1,2]. They account for up to 57% of all pediatric pancreatic malignancies, which are altogether exceedingly rare [3,4]. Due to their rarity and unclear clinical presentation, misdiagnosis is frequent [5]. The treatment of choice is a radical surgical resection with clear margins [5,6], even in cases of metastatic or locally invasive disease [7,8]. The prognosis is excellent with an estimated 5-year survival rate of 97% [9]. Herein, we report a case of SPN in an adolescent girl with an atypical clinical presentation, initially misdiagnosed for hepatoblastoma.

CASE REPORT

A 17-year-old girl was admitted to the Department of Pediatrics, Clinical Hospital Center Rijeka, Croatia, due to an ultrasonographically verified liver lesion, detected in primary care during the treatment of jaundice. Three weeks prior to admission, she was icteric, complaining of generalized itching of the skin and frequent light-colored stools. On physical examination, there was a palpable firm painless mass 4 cm below the right costal margin.

On laboratory testing, lactate dehydrogenase was elevated, and liver function tests were altered confirming hepatic involvement: total and direct hyperbilirubinemia, elevated transaminases and gamma-glutamyltransferase. Abdominal ultrasound was suggestive of liver neoplasm, showing heterogeneous mass measuring 12 x 8 cm in size, with solid echogenic areas and small hypoechoic/anechoic areas indicating necrosis [Figure 1].

The mass was pressing on bile ducts and ductus choledocus causing their dilatation. The extrahepatic spread was described to be present, resulting in right kidney and pancreas dislocation. Computed tomography[CT] of the abdomen confirmed ultrasound findings [Figure 2]. Chest X-ray, thoracic CT and bone scintigraphy showed no signs of distant metastases.

Histopathological and immunohistochemical findings of the tissue, obtained by ultrasound-guided fine-needle biopsy of the lesion, led to the diagnosis of embryonal hepatoblastoma. According to SIOPEL [*International Childhood Liver Tumour Strategy Group*], the neoplasm was classified in the PRETEXT III [*Pretreatment Extent of Disease*] category. Due to the presumed presence of extrahepatic disease and low serum levels of alpha-fetoprotein [AFP], the tumor was classified as high risk.

Neoadjuvant chemotherapy according to SIOPEL 4 protocol was introduced, which the patient tolerated well. Abdominal CT showed no signs of tumor regression after two cycles of chemotherapy. Histological and immunohistochemical revision of tumor tissue was performed in a tertiary referral center, and another time the finding was suggestive for hepatoblastoma. The patient was presented to the multidisciplinary team, and the surgery was recommended as the best option for this patient. The girl underwent cephalic duodenopancreatectomy [Whipple

procedure] and cholecystectomy with lymphadenectomy of the hepatoduodenal and celiac region at Clinical Hospital Merkur, Zagreb. Well-encapsulated tumor of the head of the pancreas measuring 12 cm in diameter was removed with free margins. Histopathological findings set the diagnosis of the SPN of the pancreas [Figure 3]. No further therapy was administered.

The girl is regularly followed-up clinically and with imaging studies. Seven years after the diagnosis she is in complete

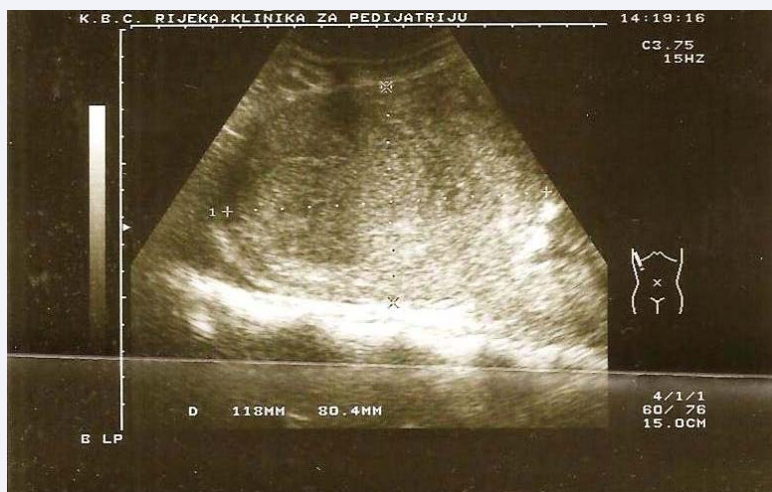

Figure 1 Abdominal ultrasound suggestive of heterogeneous liver lesion, measuring 12x8 cm.

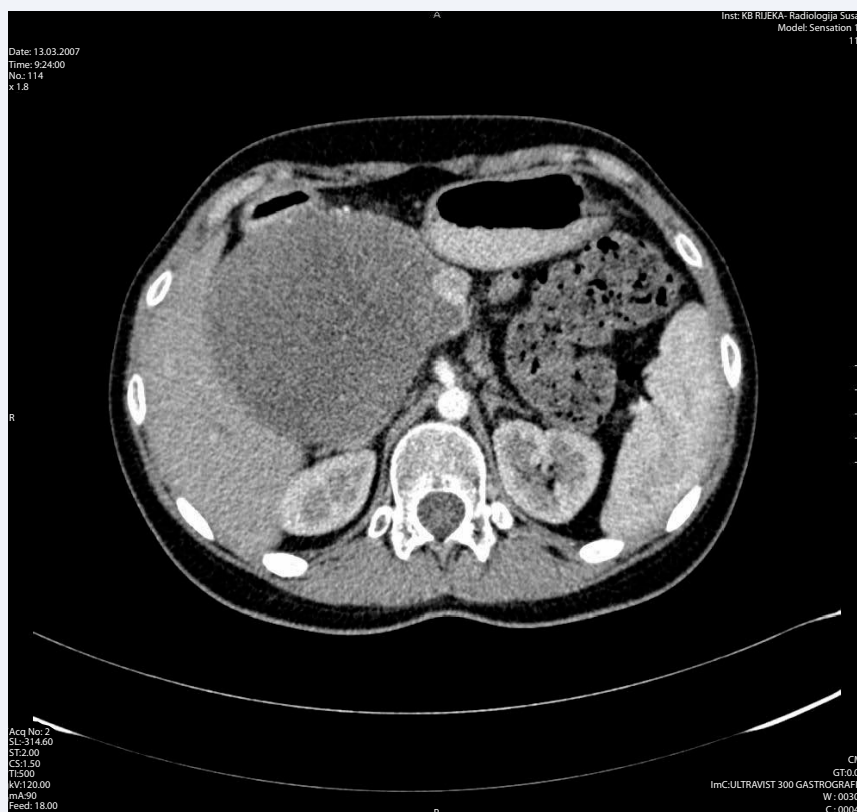

Figure 2 Abdominal computed tomography suggestive of liver lesion.

remission. She takes oral pancreatic enzyme substitution therapy. The presented case is the only pediatric pancreatic neoplasm diagnosed at University Children's Hospital Rijeka in a 10-year-period [2004 – 2013].

DISCUSSION

Malignant pancreatic neoplasms are exceedingly rare in childhood and adolescence with an age population-adjusted incidence of 0.018 cases per 100,000 [4]. The Italian TREP [*Tumori Rari in Età Pediatrica*] project reported 21 patients diagnosed with a pancreatic malignancy under the age of 18 within a 10-year period [2000 – 2009] [3], while Perez et al. identified in SEER [United States Surveillance, Epidemiology, and End Results] Registry 1973-2004 only 58 patients aged less than 20 [4]. Females outnumber males, and 70% of patients are white. Most of the neoplasms are exocrine and include pancreatoblastomas, SPNs, ductal adenocarcinomas and acinar cell carcinomas. Others are classified as endocrine tumors and sarcomas. While pancreatoblastomas are prevalent in younger children, SPNs are usually diagnosed in adolescents, especially females [4].

SPNs of the pancreas are rare entities of low malignant potential that were first described by Frantz in 1959 [1, 10]. They account for only 0.17-2.7% of all pancreatic tumors [2], while in the pediatric age group they form a significantly higher proportion [17-57%] [3,4]. The incidence rate of SPNs has been apparently rising over the last two decades, probably as a result of an increased awareness and use of advanced imaging modalities [11]. Due to their rarity, the data on SPNs is scarce, mainly arising from small series and case reports. The largest study ever conducted comprised 718 cases; majority of the reports originated from Europe, Japan, and the United States of America [2].

Until 1996, when the World Health Organization [WHO] defined them as solid-pseudopapillary tumors [SPTs], encompassing their two most distinct histological features, there was no consensus over a unique name [12]. SPNs were known under a spectrum of names such as papillary epithelial neoplasms, solid and cystic tumors, solid and papillary tumors, papillary cystic tumors, solid and papillary epithelial neoplasms, and Frantz tumors [5,13]. WHO reclassified them as solid-pseudopapillary neoplasms [SPNs] in 2010 [1].

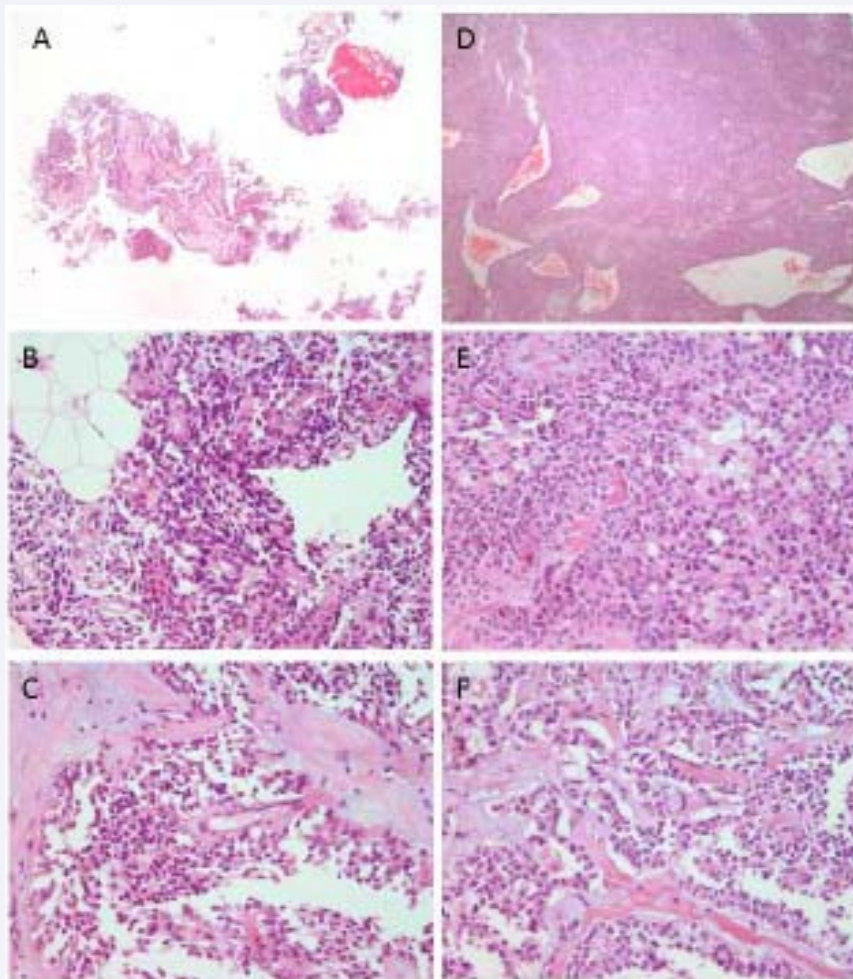


Figure 3 Histology of solid pseudopapillary neoplasm obtained by ultrasound-guided fine-needle biopsy [A-C] and after duodenopancreatectomy [D-F]. Note the heterogeneous growth pattern with combination of solid, pseudopapillary, and hemorrhagic pseudocystic structures.

SPNs predominantly affect young women with over 90% of cases reported in women under the age of 35. Papavramidis' study detected a tenfold women preponderance. The age range was 2 to 85 years, and the mean age at diagnosis was 21.97 years [6]. In another large retrospective study, Yu et al. reported similar results; female to male ratio was 8.37 to 1, and a median age of 27.2 years [9]. Machado et al. identified that at the time of diagnosis male patients were more than a decade older, and had more aggressive neoplasms compared to their female counterparts, even though there was no observed difference in tumor size among genders. Therefore, radical surgery was more frequently conducted in male patients [14].

SPNs have unique immunohistochemical patterns and molecular profiles distinguishing them from other primary pancreatic neoplasms [15,16]. They are classified as epithelial tumors, although many are reported to be negative for cytokeratin. The most consistent immunohistochemical markers are vimentin, alpha-1-antitrypsin[AAT], neuron-specific enolase[NSE] and the progesterone receptor, each found in more than 90% of SPNs [16]. Endocrine and pancreatic enzyme markers are absent [15]. In 95% of cases, SPNs show an alteration of the APC[adenomatous polyposis coli]/ β -catenin signaling pathway and loss of heterozygosity[LOH] on chromosome 5q22 [17]. Other mutations classically observed in pancreatic tumors, such as K-ras, p53, and SMAD4, are not present in SPNs, reinforcing their distinct nature [15,18,19]. The exact origin of SPNs is still enigmatic. Some theories advocate the origin from multipotent primordial cells since SPNs express epithelial, mesenchymal, exocrine and endocrine features [15,20,21]. Others favor ovarian anlage-related cells, which may be correct given the accentuated female predilection, high expression of progesterone receptors, and the fact that they were attached to the pancreatic tissue during early embryogenesis [16].

Histologically, SPNs are characterized by pseudorosettes formed of monomorphous, small to medium sized polygonal cells with eosinophilic and vacuolar cytoplasm surrounding an ovoid nucleus. The mitotic index and Ki67 are usually low which goes in favor of an indolent behavior [15,22]. Histological features of clinically more aggressive tumors include extensive necrosis, nuclear atypia, high mitotic rate, spindling of tumor cells, anaplastic giant cells, capsular invasion, lympho-vascular involvement, and sarcomatoid areas [15,23]. Hwang et al. identified an association between a higher proportion of solid component of the tumor and a greater chance of malignancy and recurrence in pediatric patients [24]. Macroscopically, SPNs are large, well-demarcated, encapsulated masses, with alternating solid and hemorrhagic/necrotic areas [15]. Due to slow growth and nonspecific clinical presentation, diagnosis may be delayed and tumors are often large in proportions, measuring even more than 30 cm at the time of identification [2]. The average diameter is 6.08 cm, but the tumor size tends to be smaller in patients treated in more recent years [2,14]. Pediatric SPNs are significantly larger compared to those in adults, and located mainly in the head of the pancreas [25]. Approximately 10-20% of patients have metastases, primarily hepatic [2,9].

SPNs produce a wide range of nonspecific symptoms. Nearly one third of adult patients are asymptomatic, while all pediatric patients have symptoms [9,25]. The most common are

abdominal pain, mass and discomfort. In children, coexistence of two or more symptoms is common [9]. Jaundice was one of the earliest and leading symptoms in our patient, resulting from the above-average size of the lesion and its location in the pancreas head causing therefore the obstruction and dilatation of bile ducts and ductus choledocus. Published studies suggest that it occurs rarely. In Papavramidis' series, only 1% of patients with pancreatic head tumors had jaundice [2], and Yu et al. reported a slightly higher occurrence of 3,59% [9].

Currently, there is no consensus about the optimal preoperative evaluation of SPNs, and their diagnosis remains a challenge. Due to their rarity and unclear clinical presentation, they are frequently misdiagnosed[in over 60% of patients], mainly for pancreatic adenocarcinomas [9,11]. SPNs are not associated with specific laboratory findings, including serum tumor markers [11]. The diagnosis is mostly based on radiological findings. Abdominal ultrasound with Doppler is useful for locating the lesions in the pancreas and detecting low blood flow around them [6]. The primary modality used to evaluate SPNs is the multiphase contrast-enhanced CT with an accuracy rate of 60% [26]. In general, SPNs show no enhancement of the cystic portions while the capsule and solid portions enhance in both arterial and portal venous phases. This differs them from pancreatic adenocarcinomas that are hypoattenuated in the venous phase, and neuroendocrine tumors that are hyperattenuated in the arterial phase [27,28]. Magnetic resonance imaging [MRI] is superior to CT in delineating pathological characteristics suggestive for SPNs due to its greater contrast resolution [6,29]. Endoscopic ultrasound-guided fine-needle aspiration[EUS-FNA] is highly accurate, and may be particularly useful in identifying rare pediatric patients [30].

In the presented case, the diagnosis was based on histopathological findings of the surgically obtained tissue as radiological findings[both repeated abdominal ultrasound and CT] were misleading and suggestive of a hepatic neoplasm. Therefore, radiologists should also consider this rare entity in the differential diagnosis of heterogeneous, well-defined, encapsulated abdominal masses.

The treatment of choice is a complete surgical resection with clear margins, even in case of hepatic involvement or local recurrence [6,7,8]. The most common surgical procedure in children is pancreaticoduodenectomy[PD] [pylorus preserving PD/Whipple procedure] [25]. The spleen should be preserved in childhood in order to avoid the overwhelming post-splenectomy infection syndrome [31]. Postoperative complications include pancreatic fistula, pancreatitis, steatorrhea, wound infection, biliary fistula, prolonged gastric emptying, gastrointestinal bleeding, diabetes mellitus, and ileus [9]. Even complications are more frequent in adults, postoperative hospital stay is longer in children, and so is the follow-up period [25]. The role of chemotherapy and radiotherapy is currently poorly defined. Rebhandl et al. reported successful adjuvant chemotherapy with ifosfamide, cisplatin and VP-16 in a pediatric patient with metastasized SPN [32]. The prognosis is excellent with an estimated 1-, 3- and 5-year survival rate of 99.4%, 97.5%, and 96.9%, respectively [9].

CONCLUSION

Although rare, SPNs need to be included in the differential diagnosis of palpable abdominal masses in children. An MRI

demonstrated, well-defined encapsulated heterogeneous mass, especially in adolescent females, should always be suspicious for SPN. Further prospective multi-institutional studies are required in order to standardize preoperative evaluation and reduce the high misdiagnosis rate.

REFERENCES

- Klöppel G, Hruban RH, Klimstra DS, Maitra A, Morohoshi T, Notohara K, et al. Solid-pseudopapillary tumor of pancreas. In: Bosman FT, Carneiro F, Hruban RH, Theise ND, editors. World Health Organization Classification of Tumours of the digestive system. Lyon: IARC; 2010; 327-30.
- Papavramidis T, Papavramidis S. Solid pseudopapillary tumors of the pancreas: review of 718 patients reported in English literature. *J Am Coll Surg.* 2005; 200: 965-972.
- Dall'igna P, Cecchetto G, Bisogno G, Conte M, Chiesa PL, D'Angelo P. Pancreatic tumors in children and adolescents: the Italian TREP project experience. *Pediatr Blood Cancer.* 2010; 54: 675-680.
- Perez EA, Gutierrez JC, Koniaris LG, Neville HL, Thompson WR, Sola JE. Malignant pancreatic tumors: incidence and outcome in 58 pediatric patients. *J Pediatr Surg.* 2009; 44: 197-203.
- Ren Z, Zhang P, Zhang X, Liu B. Solid pseudopapillary neoplasms of the pancreas: clinicopathologic features and surgical treatment of 19 cases. *Int J Clin Exp Pathol.* 2014; 15: 6889-6897.
- Guo N, Zhou QB, Chen RF, Zou SQ, Li ZH, Lin Q. Diagnosis and surgical treatment of solid pseudopapillary neoplasm of the pancreas: analysis of 24 cases. *Can J Surg.* 2011; 54: 368-374.
- Gedaly R, Toledano A, Millan G, Essenfeld H, Zambrano VJ. Treatment of liver metastases from a solid pseudopapillary tumor of the pancreas. *J Hepatobiliary Pancreat Surg.* 2006; 13: 587-590.
- Vollmer CM Jr, Dixon E, Grant DR. Management of a solid pseudopapillary tumor of the pancreas with liver metastases. *HPB (Oxford).* 2003; 5: 264-267.
- Yu PF, Hu ZH, Wang XB, Guo JM, Cheng XD, Zhang YL. Solid pseudopapillary tumor of the pancreas: a review of 553 cases in Chinese literature. *World J Gastroenterol.* 2010; 16: 1209-1214.
- Kobayashi G, Fujita N, Noda Y, Ito K, Horaguchi J, Takasawa O. Mode of progression of intraductal papillary-mucinous tumor of the pancreas: analysis of patients with follow-up by EUS. *J Gastroenterol.* 2005; 40: 744-751.
- Dan D, Rambally R, Cawich SO, Maharaj R, Naraynsingh V1. Solid pseudopapillary neoplasms of the pancreas: a report of two cases. *Case Rep Med.* 2014; 2014: 356379.
- Klöppel G, Solcia E, Longnecker DS, Capella C, Sobin L. Histological typing of tumors of the exocrine pancreas. In: World Health Organization, editor. WHO International Histological Classification of Tumors. 2nd ed. Berlin-Heidelberg-New York: Springer. 1996; 120-128.
- Mortenson MM, Katz MH, Tamm EP, Bhutani MS, Wang H, Evans DB. Current diagnosis and management of unusual pancreatic tumors. *Am J Surg.* 2008; 196: 100-113.
- Machado MC, Machado MA, Bacchella T, Jukemura J, Almeida JL, Cunha JE. Solid pseudopapillary neoplasm of the pancreas: distinct patterns of onset, diagnosis, and prognosis for male versus female patients. *Surgery.* 2008; 143: 29-34.
- Santini D, Poli F, Lega S. Solid-papillary tumors of the pancreas: histopathology. *JOP.* 2006; 7: 131-136.
- Kosmahl M, Seada LS, Jänig U, Harms D, Klöppel G. Solid-pseudopapillary tumor of the pancreas: its origin revisited. *Virchows Arch.* 2000; 436: 473-480.
- Antonello D, Gobbo S, Corbo V, Sipos B, Lemoine NR, Scarpa A. Update on the molecular pathogenesis of pancreatic tumors other than common ductal adenocarcinoma. *Pancreatology.* 2009; 9: 25-33.
- Müller-Höcker J, Zietz CH, Sendelhofert A. Deregulated expression of cell cycle-associated proteins in solid pseudopapillary tumor of the pancreas. *Mod Pathol.* 2001; 14: 47-53.
- Terris B, Cavard C2. Diagnosis and molecular aspects of solid-pseudopapillary neoplasms of the pancreas. *Semin Diagn Pathol.* 2014; 31: 484-490.
- Balercia G, Zamboni G, Bogina G, Mariuzzi GM. Solid-cystic tumor of the pancreas. An extensive ultrastructural study of fourteen cases. *J Submicrosc Cytol Pathol.* 1995; 27: 331-340.
- Mendelsohn G. Papillary cystic tumor of the pancreas. An enigma. *Am J Clin Pathol.* 1992; 98: 476-477.
- Klimstra DS, Wenig BM, Heffess CS. Solid-pseudopapillary tumor of the pancreas: a typically cystic carcinoma of low malignant potential. *Semin Diagn Pathol.* 2000; 17: 66-80.
- Tang LH, Aydin H, Brennan MF, Klimstra DS. Clinically aggressive solid Pseudopapillary tumor of the pancreas. A report of two cases with components of undifferentiated carcinoma and a comparative clinicopathologic analysis of 34 conventional cases. *Am J Surg Pathol.* 2005; 29: 512-519.
- Hwang J, Kim DY2, Kim SC, Namgoong JM, Hong SM3. Solid-pseudopapillary neoplasm of the pancreas in children: can we predict malignancy? *J Pediatr Surg.* 2014; 49: 1730-1733.
- Lee SE, Jang JY, Hwang DW, Park KW, Kim SW. Clinical features and outcome of solid pseudopapillary neoplasm: differences between adults and children. *Arch Surg.* 2008; 143: 1218-1221.
- Procacci C, Graziani R, Bicego E, Zicari M, Bergamo Andreis IA, Zamboni G, et al. Papillary cystic neoplasm of the pancreas: radiological findings. *Abdom Imaging.* 1996; 21: 554-558.
- Dong DJ, Zhang SZ. Solid-pseudopapillary tumor of the pancreas: CT and MRI features of 3 cases. *Hepatobiliary Pancreat Dis Int.* 2006; 5: 300-304.
- Butte JM, Brennan MF, Gönen M, Tang LH, D'Angelica MI, Fong Y, et al. Solid pseudopapillary tumours of the pancreas: clinical features, surgical outcomes, and long-term survival in 45 consecutive patients from a single center. *J Gastrointest Surg.* 2011; 15: 350-357.
- Kehagias D, Smyrniotis V, Gouliamos A, Vlahos L. Cystic pancreatic neoplasms: computed tomography and magnetic resonance imaging findings. *Int J Pancreatol.* 2000; 28: 223-230.
- Nadler EP, Novikov A, Landzberg BR, Pochapin MB, Centeno B, Fahey TJ. The use of endoscopic ultrasound in the diagnosis of solid pseudopapillary tumors of the pancreas in children. *J Pediatr Surg.* 2002; 37: 1370-1373.
- Schneider DT, Brecht IB, Olson TA, Ferrari A, editors. Rare Tumors in Children and Adolescents. London-New York: Springer. 2012.
- Rebhandl W, Felberbauer FX, Puig S, Paya K, Hochschorner S, Barlan M. Solid-pseudopapillary tumor of the pancreas (Frantz tumor) in children: report of four cases and review of the literature. *J Surg Oncol.* 2001; 76: 289-296.

Cite this article

Roganovic J, Matijasic N, Jonjic N (2015) Pediatric Solid Pseudopapillary Neoplasm[SPN] of The Pancreas –Case Report and Literature Review. *Ann Clin Pathol* 3(1): 1044.