

# IMMUNOPROLIFERATIVE SMALL INTESTINAL DISEASE PRESENTED WITH ASCITES AND EDEMA

Maryam Shoaran<sup>1</sup>, Ahmad Khodadad<sup>1</sup>, Fatemeh Mahjoub<sup>1</sup>, Mohammad-Ali Kiani<sup>2</sup> and Nima Rezaei<sup>1,3,4</sup>

<sup>1</sup>Department of Pediatrics, Division of Gastroenterology, Children's Hospital, Tabriz University of Medical Sciences, Tabriz, <sup>2</sup>Department of Pediatrics, Children's Medical Center, Pediatrics Center of Excellence, Tehran University of Medical Sciences, Tehran; <sup>3</sup>Department of Pediatrics, Mashhad University of Medical Sciences, Mashhad; <sup>4</sup>Research Center for Immunodeficiencies, Tehran University of Medical Sciences, Tehran; <sup>5</sup>Molecular Immunology Research Center and Department of Immunology, School of Medicine, Tehran University of Medical Sciences, Tehran, Iran

**SUMMARY** – Immunoproliferative small intestinal disease (IPSID) is a rare disorder, which can progress to malignancy and invasion. Herein, a male patient is presented with hypoalbuminemic ascites and a history of chronic diarrhea five years before. Small intestinal biopsy and immunohistochemical study suggested the diagnosis of IPSID; the patient was then successfully treated with antibiotics. Considering the favorable therapeutic response of IPSID to antibiotics during primary stages, clinicians should be aware of its various presentations in order to initiate treatment at an early stage.

**Key words:** *Immunoproliferative small intestinal disease; Hypoalbuminemia; Ascites; Edema*

## Introduction

Immunoproliferative small intestinal disease (IPSID) is a rare disorder presenting with chronic or intermittent diarrhea and weight loss as a nonspecific malabsorption syndrome<sup>1,2</sup>. Recurrent crampy abdominal pain seems to be the most common symptom, while some patients suffer from vomiting, clubbing, abdominal obstructive mass, ascites, edema, low-grade fever, anemia, organomegaly, and lymphadenopathy. The exact etiology and pathogenesis of the disease remain unknown, but could be related to chronic intestinal infestations triggering an immune proliferative response. Lymphoepithelial lesion is characteristic for the disease<sup>2-4</sup>.

In this report, we present a case of IPSID with the main complaint of limb edema, treated with antibiotics.

Correspondence to: *Maryam Shoaran, MD*, Department of Gastroenterology, Children's Hospital, Sheshgfan Street, Tabriz, Iran

E-mail: [maryamshoaran@yahoo.com](mailto:maryamshoaran@yahoo.com)

Received July 2, 2012, accepted November 21, 2012

## Case Report

A 16-year-old male adolescent was admitted to the Gastroenterology Ward of the Children's Medical Center, Pediatrics Center of Excellence, with a 5-year history of intermittent bouts of high-output diarrhea and crampy abdominal pain. In the last 6 months, he also suffered from edema in his lower extremities. Family history was unremarkable.

At the time of admission, his height and weight were 150 cm and 40 kg, respectively. On physical examination, the patient was ill, pale, and emaciated. He had painless pitting edema in both calves. Blood pressure was 100/60, and other vital signs were normal. Abdominal examination revealed a significant amount of ascites without hepatosplenomegaly and lymphadenopathy. Partial parenteral nutrition was started and he received mineral and vitamin supplements. Despite nutritional support, his weight gain was insignificant.

Echocardiography and chest x-ray ruled out heart failure and primary lung disease. Cultures of stool

specimens were negative for *Salmonella* and *Shigella*. His urinalysis revealed no proteinuria. Laboratory studies showed leukocytosis, but other parameters, including liver enzymes, were normal. Ascites fluid parameters showed leukocyte count 20/mm<sup>3</sup>, with 75% (15) lymphocytes and 5 polymorphonuclear cells, and negative culture. The serum-ascites albumin gradient was 0.9 g/dL. Lactate dehydrogenase (LDH) level was 110 IU/L (ascitic fluid LDH/serum LDH <0.6).

Serologic and bacteriologic studies for tuberculosis and human immunodeficiency virus (HIV) were negative.

Colonoscopic examination showed no significant findings, while rectal biopsy specimens showed non-specific colitis. The gross pattern of upper gastrointestinal tract was normal on endoscopy. Duodenal, gastric, and esophageal biopsies were performed, the histologic review of which was suggestive of IPSID (Figs. 1 and 2). There were overt lymphoid infiltrations rather completely replacing normal structure, mild to moderate villous atrophy without superficial epithelial changes, and few eosinophils in lamina propria. No *Giardia lamblia* parasites were seen. Rapid urease test and staining for *Helicobacter pylori* were negative. Immunohistochemical staining of the specimens showed that the infiltrated cells were CD20+ lymphocytes and negative for kappa chain, lambda chain, CD23 and CD5. Alpha heavy chain was negative in his blood sample. Administration of azithro-

mycin and metronidazole was introduced to be continued for 6 months. The patient was discharged after three weeks. His condition gradually improved in the first month of therapy introduction. Endoscopic biopsies of the duodenum after 6 months of antibiotic therapy showed healing of duodenal pathology. Now, the patient's general health is good after 10-month follow-up; the only complaint is his short stature that is under management by endocrinologists.

## Discussion

According to the World Health Organization classification, IPSID is listed among the heavy chain diseases, as a variant of mucosa-associated lymphoid tissue lymphoma<sup>5</sup>. IPSID is characterized by a diffuse plasma cell infiltrate, mainly in the lamina propria of the small intestine, which can transform to malignant forms of lymphoma. IPSID can be classified into three stages: stage A, the infiltrate is confined to the bowel mucosa with no visible tumor; stage B, nodular mucosal lymphoid infiltrates are present, with or without mesenteric node involvement; and stage C characterized by the presence of large masses and transformation to malignant lymphoma<sup>6-8</sup>.

Hara *et al.* report a case of IPSID with protein loss complicated with duodenal T cell lymphoma<sup>9</sup>. The main complaint in our patient was edema of lower extremities. His response to antibiotic was excellent

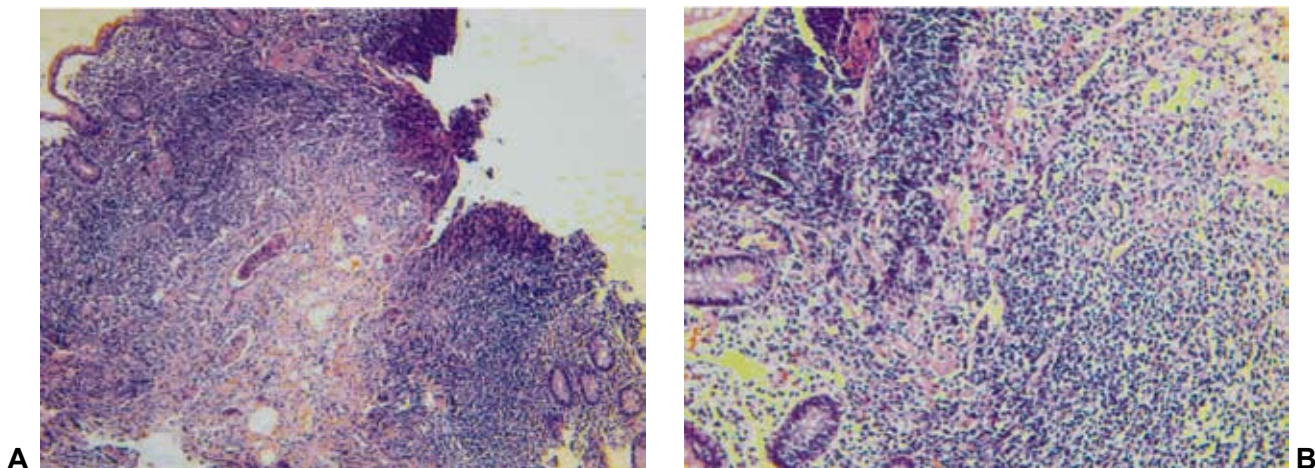


Fig. 1. (A) Duodenal mucosa with overt lymphoplasmacytic infiltration nearly replacing normal structure forming vague aggregates; (B) closer view of the heavy infiltrate in duodenal mucosa. The cells appear rather bland with no features of malignancy.

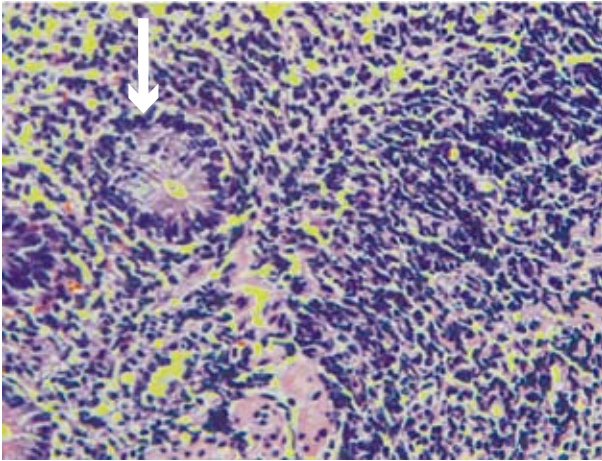


Fig. 2. Lymphoepithelial lesion; the remaining crypts are surrounded and invaded by infiltrating lymphoid cells (white arrow).

suggesting an early phase of the disease. The patient was treated with azithromycin and metronidazole due to the possible association between *Campylobacter* (*C. jejuni*) along with other microorganisms and IPSID<sup>4</sup>.

A number of laboratory tests have been proposed for IPSID, with a variable prevalence: an  $\alpha$ -heavy chain protein with no associated light chain (40%–100% of cases); hypoproteinemia, especially low serum albumin; fat in stool; high alkaline phosphatase; hypocalcemia and hypomagnesemia; and low hematocrit. Radiologic findings are usually not remarkable, except in advanced disease with obstructive and space occupying lesions. Although a combination of clinical and laboratory findings, especially if  $\alpha$ -heavy chain is present, may be highly suggestive, the definitive diagnosis is established based on upper endoscopy with small intestinal biopsies and occasionally open biopsies<sup>1,2,9,10</sup>.

A regional study in Tunis with a total of 21 cases revealed a cure rate of about 90% and 67% at 2 and 3 years, respectively. Six patients in this group were in an early stage and treated with an antibiotic regimen, including metronidazole, tetracycline and ampicillin/tetracycline, while the remaining 15 patients received chemotherapeutic agents<sup>3</sup>.

Various microorganisms have been reported to be associated with IPSID, but documented correlation with a specific factor has not yet been established. Infection with *C. jejuni* has been typically described as an underlying microbial factor in these patients. The

presence of this organism in intestinal tissue cultures and induction of remission with anti-campylobacter antibiotics has proposed *C. jejuni* as the most probable agent linked to IPSID<sup>4</sup>. A support to the relation between *C. jejuni* and IPSID is provided by a study where the analysis of frozen intestinal tissue specimens revealed campylobacter in five of seven patients diagnosed as IPSID<sup>10</sup>. *Vibrio cholerae*, *Ascaris lumbricoides*, *Giardia lamblia* and *Strongyloides stercoralis* are some of other microorganisms that may have a role in chronic antigenic stimulation<sup>11,12</sup>.

Based on the favorable therapeutic response of IPSID in early stages, clinicians should consider IPSID as a possible cause of unexplained chronic diarrhea, while biopsy of the duodenum could be suggested when exploring patients with chronic diarrhea, even if biopsies are not specifically required.

## References

1. AL-SALEEM T, AL-MONDHIRY H. Immunoproliferative small intestinal disease (IPSID): a model for mature B-cell neoplasms. *Blood* 2005;105:2274–80.
2. KHOJASTEH A, HAGHIGHI P. Immunoproliferative small intestinal disease: portrait of a potentially preventable cancer from the Third World. *Am J Med* 1990;89:483–90.
3. BEN-AYED F, HALPHEN M, NAJJAR T, BOUSSENE H, JAAFURA H, BOUGUERRA A, *et al.* Treatment of alpha chain disease. Results of a prospective study in 21 Tunisian patients by the Tunisian-French intestinal Lymphoma Study Group. *Cancer* 1989;63:1251–6.
4. PETERSON MC. Immunoproliferative small intestinal disease associated with *Campylobacter jejuni*. *N Engl J Med* 2004;350:1685–6.
5. ECONOMIDOU I, MANOUSOS ON, TRIANTAFILIDIS JK, VASLAMATZIS MM, ZAFIROPOULOU R, PAPADAKIS T. Immunoproliferative small intestinal disease in Greece: presentation of 13 cases including two from Albania. *Eur J Gastroenterol Hepatol* 2006;18:1029–38.
6. PERVEZ S, MUMTAZ K, ULLAH SS, AKHTAR N, ALI N, AAQIL H. Immunoproliferative small intestinal disease (IPSID). *J Coll Physicians Surg Pak* 2011;21:57–8.
7. Proceedings of the 21<sup>st</sup> Ljudevit Jurak International Symposium on Comparative Pathology, June 4–5, 2010, Zagreb, Croatia. *Acta Clin Croat* 2010;49:221–43.
8. Proceedings of the 22<sup>nd</sup> Ljudevit Jurak International Symposium on Comparative Pathology of the Skin, June 3–4, 2011, Zagreb, Croatia. *Acta Clin Croat* 2012;51:171–88.
9. HARA T, TSURUMI H, KATO T, IMAO Y, KOJIMA Y, KOJIMA K, KITAGAWA J, *et al.* Immunoproliferative small intestinal disease with protein loss complicated with

- duodenal T cell lymphoma during progression. *Intern Med* 2008;47:299-303.
10. FINE KD, STONE MJ. Alpha-heavy chain disease, Mediterranean lymphoma, and immunoproliferative small intestinal disease: a review of clinicopathological features, pathogenesis, and differential diagnosis. *Am J Gastroenterol* 1999;94:1139-52.
  11. GHOSHAL UC, SAHAJ, GHOSHAL U, RAY BK, SANTRA A, NAIK S, *et al.* Pigmented nails and *Strongyloides* *stercoralis* infestation causing clinical worsening in a patient treated for immunoproliferative small intestinal disease: two unusual observations. *J Diarrhoeal Dis Res* 1999;17:43-5.
  12. GHOSHAL UC, CHETRI K, BANERJEE PK, CHOUDHURI G, PAL BB, DABADGHAO S, *et al.* Is immunoproliferative small intestinal disease uncommon in India? *Trop Gastroenterol* 2001;22:14-7.

### Sažetak

## IMUNOPROLIFERACIJSKA BOLEST TANKOG CRIJEVA MANIFESTIRANA ASCITESOM I EDEMOM

*M. Shoaran, A. Khodadad, F. Mahjoub, M-A. Kiani i N. Rezaei*

Imunoproliferacijska bolest tankog crijeva je rijetka bolest koja može napredovati u malignu i invazivnu bolest. Prikazuje se slučaj bolesnika s hipoalbuminemičnim ascitesom i petogodišnjom anamnezom kroničnog proljeva. Biopsija tankog crijeva i imunohistokemijske pretrage upućivale su na dijagnozu imunoproliferacijske bolesti tankog crijeva, te je bolesnik uspješno liječen antibioticima. S obzirom na povoljan terapijski odgovor na antibiotike u ranim stadijima ove bolesti kliničari bi trebali poznavati njezine raznolike manifestacije kako bi pravodobno uveli primjerenu terapiju.

Ključne riječi: *Imunoproliferacijska bolest tankog crijeva; Hipoalbuminemija; Ascites; Edem*