

PDF hosted at the Radboud Repository of the Radboud University Nijmegen

The following full text is a publisher's version.

For additional information about this publication click this link.

<http://hdl.handle.net/2066/124310>

Please be advised that this information was generated on 2017-12-05 and may be subject to change.

Fatal Cerebral Phaeohyphomycosis in an Immunocompetent Individual Due to *Thielavia subthermophila*[∇]

Hamid Badali,^{1,2} Jagdish Chander,³ Ashish Gupta,⁴ Hena Rani,³ Rajpal Singh Punia,⁵
G. Sybren De Hoog,² and Jacques F. Meis^{6*}

Department of Medical Mycology and Parasitology, School of Medicine/Molecular and Cell Biology Research Centre, Mazandaran University of Medical Sciences, Sari, Iran¹; CBS-KNAW Fungal Biodiversity Centre, Utrecht, Netherlands²; Departments of Microbiology,³ General Surgery,⁴ and Pathology,⁵ Government Medical College Hospital, Chandigarh, India; and Department of Medical Microbiology and Infectious Diseases, Canisius Wilhelmina Hospital, Nijmegen, Netherlands⁶

Received 30 December 2010/Returned for modification 17 February 2011/Accepted 4 March 2011

We report the first case of fatal brain infection in an Indian farmer caused by *Thielavia subthermophila*, a dematiaceous thermophilic fungus in the order Sordariales, and present a review of previous infections from this order. The patient failed amphotericin B therapy combined with surgical excision despite the drug's low MICs *in vitro*.

CASE REPORT

A 39-year-old male presented in the Emergency Department of Government Medical College Hospital (GMCH), Chandigarh, India, with complaints of multiple episodes of generalized tonic-clonic seizures for the previous 10 days. He experienced, in addition to the seizures, uncontrolled movements of his limbs and rolling of his eyes, incontinence of urine, and production of foam from his mouth. There was a history of fever for 2 days, associated with an attack of seizures. He was a resident of Ambala (Haryana State, northern India) and a farmer by occupation, with a low socioeconomic status. He was first admitted to a local hospital in Ambala and was subsequently transported to the GMCH. In the past, he never had headaches or any other significant complaints. There was no history of any trauma, roadside accidents, near-drowning, or similar predisposing factors.

On examination, the patient was having an altered sensorium and was disoriented, with a Glasgow coma score of E2V2M4. On the basis of generalized tonic-clonic seizures, a presumptive diagnosis of meningioma was made. His chest X ray and electrocardiogram (ECG) were normal. A lumbar puncture was done, and cerebrospinal fluid (CSF) was sent for cytological, biochemical, and microbiological examination. Gram staining, Ziehl-Neelsen (ZN) staining, and fungal smears of CSF were negative, and there was no growth of either bacteria or fungi. The cytological and biochemical examination of CSF was noncontributory. The other laboratory investigations revealed that his hemogram, white blood cells, serum electrolytes, liver function, and glucose concentration were within normal ranges.

A magnetic resonance image (MRI) of his brain showed a large, supratentorial, intracranial, right-frontotemporal, space-

occupying lesion (7.0 by 7.5 by 8.6 cm) and also small components devoid of frank edema alongside the frontal part of the falx cerebri, suggestive of meningioma in the right sphenoidal wing (Fig. 1A and B). Therefore, right-frontotemporal craniotomy was done for excision of the intracranial mass, which intraoperatively showed a white, cheesy, and gelatinous substance, suggestive of infective pathology rather than of meningioma. The excised intracranial mass was sent for histopathological and microbiological examination. Direct microscopy revealed neither *Mycobacterium* nor other bacteria with Ziehl-Neelsen (ZN) staining or Gram staining, respectively, but KOH preparations showed septate, branched fungal hyphae (Fig. 2A). Histopathological examination with periodic acid-Schiff (PAS) staining showed fungal granulomas in the brain parenchyma centered around blood vessels. Granulomas were made up of epithelioid cells with giant cells and collections of neutrophils. These granulomas and giant cells contained septate fungal hyphae, and blood vessels showed evidence of vasculitis. There was also angioinvasion by the fungal hyphae; however, necrosis was not seen (Fig. 2B). Fungal culture was done with Sabouraud's dextrose agar (SDA; HiMedia, Mumbai, India) with and without antibiotics and incubated at both 37°C and 22°C. The bacterial and mycobacterial cultures remained sterile. On the second day of incubation, SDA plates showed mycelial growth at both 37°C and 22°C. Lactophenol cotton blue (LCB) mounts of the black fungal growth showed sterile, dematiaceous hyphae which did not allow morphological identification.

The patient was treated with intravenous amphotericin B deoxycholate (1 mg/kg of body weight/day), but his condition deteriorated rapidly and he developed respiratory distress, for which a tracheostomy was necessary. Despite antifungal therapy, the patient died 2 weeks later due to cardiac arrest and respiratory failure.

Mycology. The fungal culture was deposited in the reference collection of CBS-KNAW, Utrecht, Netherlands, under accession number CBS 125981. Stock cultures were maintained on slants of 2% malt extract agar (MEA; Difco, Leeuwarden,

* Corresponding author. Mailing address: Department of Medical Microbiology and Infectious Diseases, Canisius Wilhelmina Hospital, Weg door Jonkerbos 100, 6532 SZ Nijmegen, Netherlands. Phone: 00 312 43657514. Fax: 00 312 43657516. E-mail: j.meis@cwz.nl.

[∇] Published ahead of print on 16 March 2011.

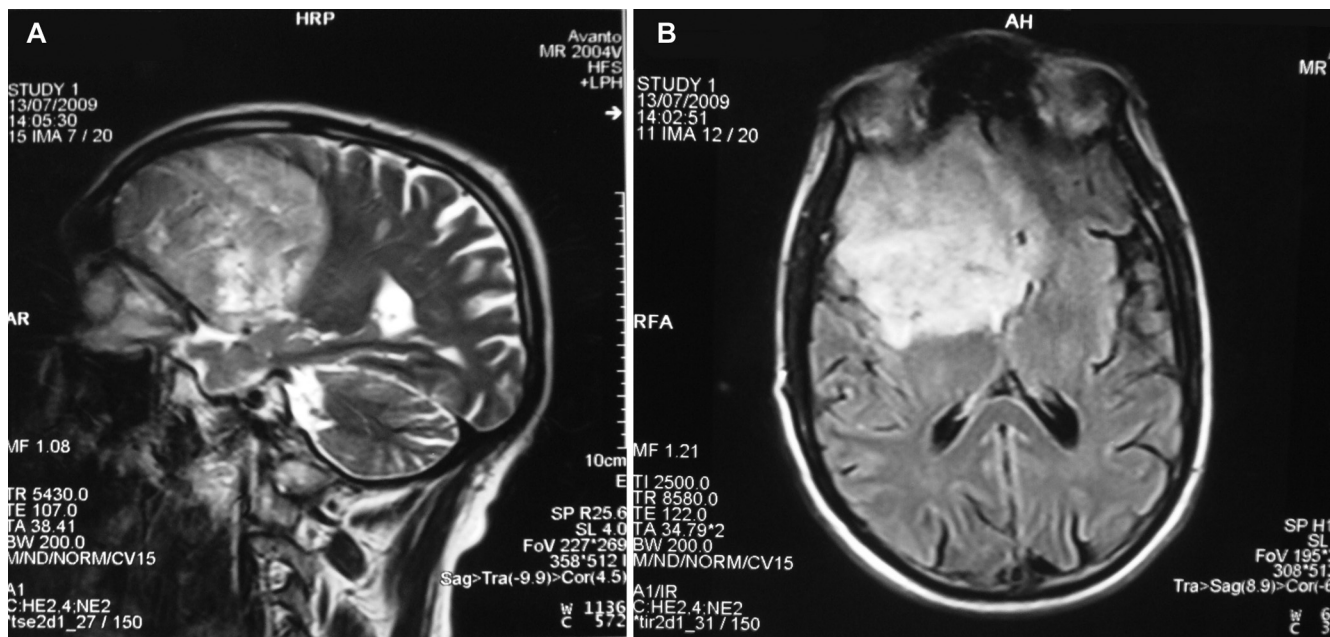


FIG. 1. Coronal (A) and axial (B) MRI images of the brain demonstrating a large, supratentorial, intracranial, right-frontotemporal, space-occupying lesion and also small, left-frontal components devoid of frank edema on both sides of the falx cerebri.

Netherlands) and oatmeal agar (OA) at 24°C (14). Colonies showed rapid growth and were flat and velvety to floccose, with an olivaceous-black reverse on OA (Fig. 3A). Smears from old cultures were prepared in lactic acid and in sterile water and examined with a Nikon Eclipse 80i microscope equipped with a Nikon digital-sight DS-Fi1 camera. Septate, branching, dark olivaceous hyphae were observed. Supplementary cultures were prepared on MEA, potato carrot agar (PCA; Difco), potato dextrose agar (PDA), and oatmeal agar (OA) with or without lupine stems and incubated at 25, 35, 42, 45, and 50°C for a period of 3 weeks under alternate near-UV light to suppress the growth of aerial hyphae and induce adequate ascoma formation (14). After 2 weeks of incubation, scattered

black ascomata were observed on all media tested (Fig. 3B). Walls of the ascomata consisted of textura epidermoidea (i.e., of jigsaw-shaped cells [14]) coated with dark hyphae. The brown, fusiform ascospores were single celled (10 to 12 by 7.5 to 8.5 μm) and had a characteristic subapical germ pore measuring 1 to 1.5 μm (Fig. 3C to E). Thermotolerance tests showed that the isolate grew rapidly at both 35°C and higher temperatures of 42°C, 45°C, and 50°C. Subsequently, the fungus was phenotypically identified as a *Thielavia* species. Sequencing was used to further identify it to the species level.

For molecular analyses, the fungus was grown on 2% MEA plates, and DNA was extracted using an UltraClean microbial DNA isolation kit (MO BIO, Carlsbad, CA) according to the

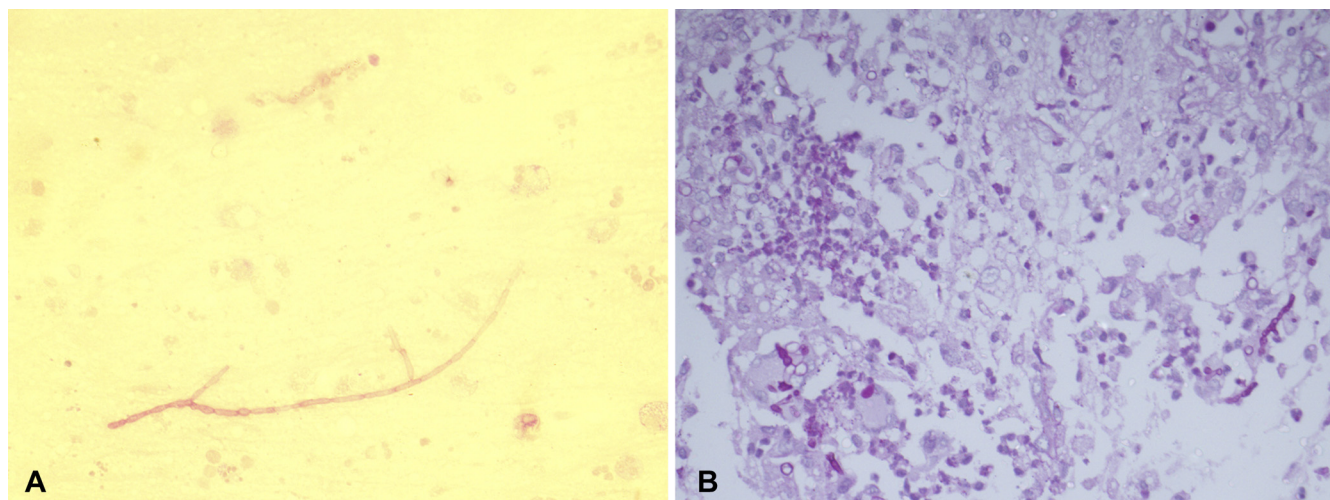


FIG. 2. (A) Septate hyphae observed in a KOH wet mount; (B) photomicrograph of brain parenchyma showing granuloma and septate hyphae (PAS staining; magnification, ×400).

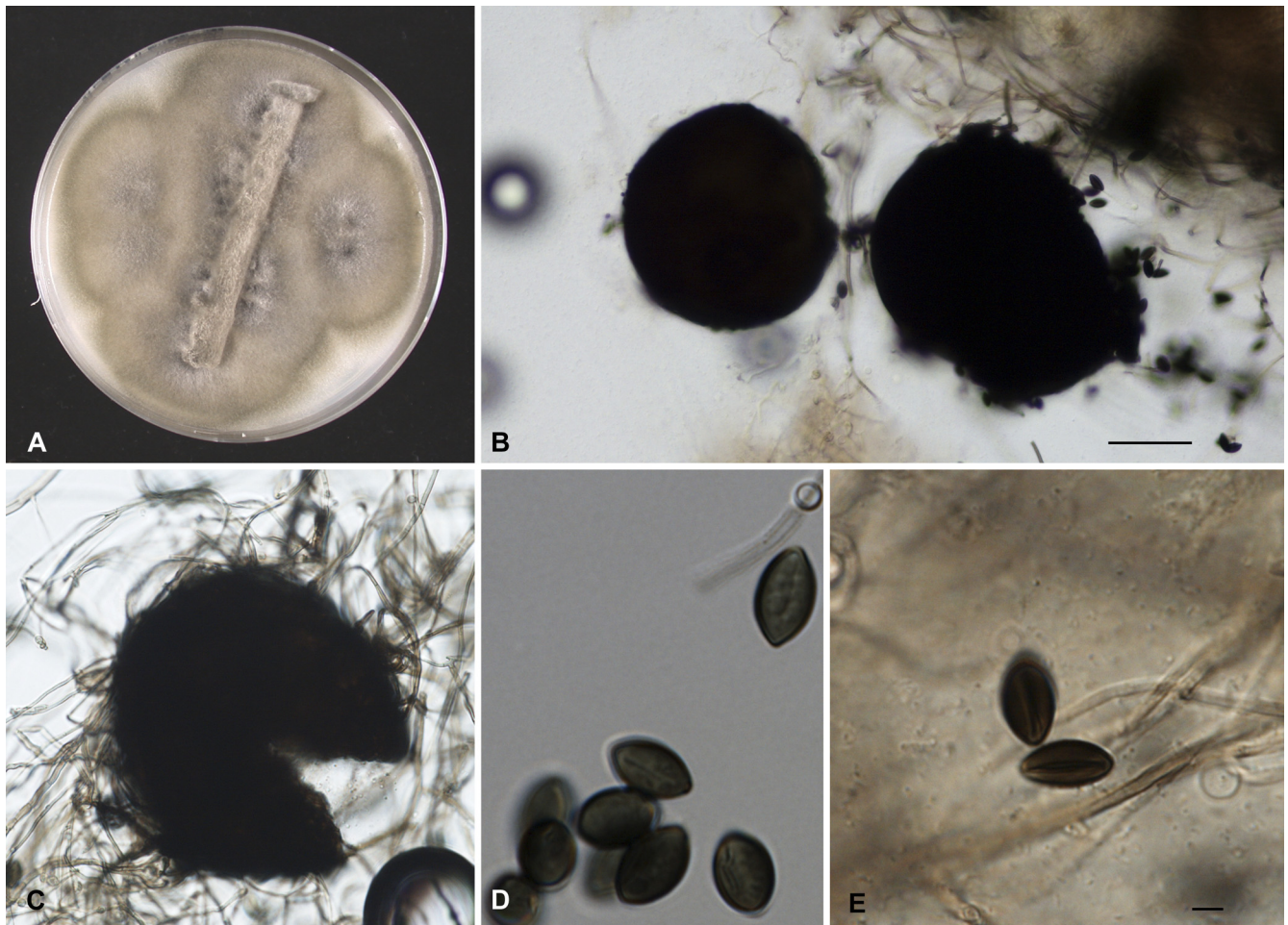


FIG. 3. *Thielavia subthermophila* (CBS 125981). (A) A culture on oatmeal agar at 42°C after 2 weeks in darkness with lupine stem grew rapidly and was flat and velvety or floccose, with an olivaceous-black reverse. (B and C) Scattered black ascomata developing within the hyphae. (D and E) The brown, fusiform ascospores are single celled (10 to 12 by 7.5 to 8.5 μm) and have a characteristic subapical germ pore measuring 1 to 1.5 μm . Scale bars, 10 μm .

manufacturer's instructions. PCR amplification and sequencing were carried out according to the method of Badali et al. (7). Briefly, the universal fungal primer pairs V9G (5'-TTACGTCCCTGCCCTTTGTA-3')/LS266 (5'-GCATTCCTCAAACAACTCGACTC-3') and LROR/LR7 were used for amplification of internal transcribed spacer (ITS) ribosomal DNA (rDNA) and 28S rRNA (nuLSU), respectively. PCRs were performed on a GeneAmp PCR system 9700 (Applied Biosystems, Foster City, CA) in 50- μl volumes containing 25 ng template DNA, 5 μl reaction buffer (0.1 M Tris-HCl, pH 8.0, 0.5 M KCl, 15 mM MgCl_2 , 0.1% gelatin, 1% Triton X-100), 0.2 mM each deoxynucleoside triphosphate (dNTP), and 2.0 U *Taq* DNA polymerase (ITK Diagnostics, Leiden, Netherlands). Amplification of ITS and nuLSU was performed with cycles of 2 min at 94°C for primary denaturation, followed by 35 cycles at 94°C (45 s), 52°C (30 s), and 72°C (120 s), with a final 7-min extension step at 72°C. Amplicons were purified using GFX PCR DNA and a gel band purification kit (GE Healthcare, Ltd., Buckinghamshire, United Kingdom). Sequencing was performed as follows: 95°C for 1 min, followed by 30 cycles consisting of 95°C for 10 s, 50°C for 5 s, and 60°C

for 2 min. Reaction mixtures were purified with Sephadex G-50 fine (GE Healthcare Bio-Sciences AB, Uppsala, Sweden), and sequencing was done on an ABI 3730xl automatic sequencer (Applied Biosystems, Foster City, CA). Sequence data obtained in this study were adjusted using Lasergene SeqMan software (DNASar, Inc., Madison, WI). Sequences were compared with entries in GenBank and by using local BLAST searching in a molecular database maintained at the CBS and validated by ex-type strains. Isolate CBS 125981 was identified as *Thielavia subthermophila* by 98.98% and 100% identities in its ITS rDNA and nuLSU regions, respectively, with GenBank submissions, which included accession number AJ271575.1 from the recent revision of *Thielavia* by Stchigel et al. (28), and by 99.6% identity with CBS 509.74, the ex-type strain of *T. subthermophila*. This led to the final diagnosis of the infection as a cerebral phaeohiphomycosis due to *Thielavia subthermophila*.

In vitro antifungal susceptibility testing was performed using the M38-A2 reference method of the Clinical and Laboratory Standards Institute (CLSI) by using a broth microdilution format (13, 16). Briefly, ascospore suspensions were prepared

from >3-week-old cultures on OA with lupine stems (14) at 37°C by gently scraping the surfaces of mature colonies with a sterile moistened cotton swab. If large aggregates existed, they were allowed to settle for several minutes, the homogenous suspension of asci and ascospores was then transferred to sterile tubes, and the asci and ascospores in the supernatants were counted with a hemocytometer. Broth dilutions were done in RPMI 1640 medium with L-glutamine, without bicarbonate, and buffered with 0.165 M morpholinepropanesulfonic acid (MOPS). *Paecilomyces variotii* (ATCC 22319), *Candida parapsilosis* (ATCC 22019), and *Candida krusei* (ATCC 6258) were used as quality control organisms (13). The isolate showed the following antifungal susceptibility profile: amphotericin B, 0.03 µg/ml; fluconazole, 8 µg/ml; itraconazole, 0.016 µg/ml; voriconazole, 0.016 µg/ml; posaconazole, 0.016 µg/ml; and isavuconazole, 0.016 µg/ml. The minimum effective concentrations of caspofungin and micafungin were 4 and 0.25 µg/ml, respectively.

Discussion. During recent decades, the diversity of fungal agents causing systemic disease has increased dramatically, especially in immunocompromised hosts, patients using broad-spectrum antibiotics, or patients with severe underlying diseases or undergoing solid organ transplantation. Melanized (dematiaceous) fungi are particularly significant because they infect not only debilitated hosts but also apparently healthy individuals, giving infections which range from mild cutaneous infections to fatal brain disease (12, 15, 19, 20, 22, 29). Primary cerebral phaeohyphomycosis is a rare disorder characterized by black necrotic tissue and the production of pus, frequently occurring in humans without known predisposing factors or immunodeficiency (19, 22, 26). The infection is recognized as a disease associated with high mortality and ultimately a poor prognosis despite the application of surgery and antifungal therapy (12, 22). If untreated, the infection may lead to death within weeks, months, or, occasionally, years. The majority of etiologic agents belong to a single order of known environmental fungi, the *Chaetothyriales* (e.g., *Cladophialophora*, *Exophiala*, *Rhinocladiella*, and *Fonsecaea*). Occasionally species from other orders are involved, such as *Sordariales* (*Chaetomium*), *Pleosporales* (*Bipolaris*, *Exserohilum*), *Xylariales* (*Nodulisporium*), and *Botryosphaeriales* (*Neoscytalidium*) (22).

Thielavia is a common genus of environmental ascomycetes belonging to the family *Chaetomiaceae* in the order *Sordariales*. The genus is characterized by spherical, nonstiolate ascomata with a thin peridium (ascoma wall), producing one-celled, darkly pigmented ascospores (14, 25, 31, 32). Taxonomy and phylogeny of *Thielavia* have been the subject of some confusion, because optimal markers for species distinction have not yet been established (28). A morphotaxonomic revision by von Arx et al. (31, 32) described 14 species, but developments in molecular techniques revolutionized species concepts. *Thielavia subthermophila* (not to be confused with *Thielavia thermophila* Fergus & Sinden) was introduced by Mouchacca (24) for a species from desert soil which showed good growth at 45°C. The species is further characterized by the presence of pigmented mycelium and brownish-black, hairy ascomata. *Thielavia gigaspora* (25), *Thielavia arenaria*, *Thielavia hyrcania*, and

Thielavia microspora (31) are distinguished by the criteria of ascospore size and position of germ pores (28). *Thielavia* species have rarely been proven to be involved in human infections. Bourbeau et al. (11) described a disseminated infection due to *Myceliophthora thermophila*, the anamorph of *Thielavia heterothallica*, and Theoulakis et al. (29) reported a keratitis due to *T. subthermophila* in a 10-year-old girl. Our patient is the first reported case of severe systemic infection due to *T. subthermophila*. Identification by a molecular approach like sequencing of ITS rDNA and comparison to sequences in GenBank is the best and most simple approach for the difficult identification of these sporulating fungi. This species is an addition to the list of potential agents of primary brain abscesses in apparently healthy individuals, which includes its black-yeast-like relatives *Cladophialophora bantiana*, *Exophiala dermatitidis*, *Fonsecaea monophora*, and *Rhinocladiella mackenziei* (7–9, 27). Primary or secondary brain infections are distinguished by their modes of infection, either by supposed hematogenous spread from an unrecognized pulmonary focus or through direct extension from an adjacent focus, e.g., in paranasal sinuses or after a penetrating trauma to the head (12, 19, 21, 27).

Thielavia is closely related to *Chaetomium* (*Sordariales*, *Chaetomiaceae*), a large genus of saprobic ascomycetes that are widespread in soil, in plant debris, and on wood. Both species have been recovered during air surveys in jute fields in India (30), suggesting that the probable source for our patient, a farmer, was airborne. *Chaetomium globosum*, *Chaetomium atrobrunneum*, *Chaetomium funicola*, and *Chaetomium strumarium* have occasionally been encountered in a wide variety of human infections, such as onychomycosis, sinusitis, pneumonia, and cerebral abscess. Fatal cerebral infection was repeatedly reported in intravenous drug users, with a high mortality despite the administration of antifungal combination therapy (1). The disorder may be underdiagnosed, because many ascomycetes in the *Sordariales* do not produce anamorphs and may appear as sterile mycelium. In addition, the correct identification of species described 20 years ago can be doubted, as these isolates have not been reexamined with molecular methods. We have the impression that members of the *Sordariales* target relatively frequently the cerebrum (22). The optimal temperature for most *Chaetomium* species lies between 25 and 35°C (10, 23, 28), while those that have been reported to cause invasive infection grow very well above 35°C to 45°C. The invasive infections due to *Thielavia* and *Chaetomium* species reported to date are summarized in Table 1.

Cases of brain infection due to *C. strumarium* have occurred in intravenous drug abusers and in patients with hematologic malignancies and solid organ transplantation (1). The outcome was generally poor. Al-Aidaros et al. (4) reported fatal invasive infections in two immunocompromised pediatric patients due to *C. atrobrunneum*. The present study adds another thermophilic member of the *Sordariales* (*T. subthermophila*) to the list of potential agents of phaeohyphomycotic brain infections.

The keratitis due to *T. subthermophila* reported by Theoulakis et al. (29) was successfully treated with topical amphotericin B and oral voriconazole. Treatment of cerebral phaeohyphomycosis generally includes surgical debridement, combined with antifungal therapy and/or immune enhancement. Although the etiologic agent in our case had a low *in*

TABLE 1. Overview of reported cases of systemic infections by members of the *Sordariales*^a

Agent	Age (yr)	Sex	Host status	Site of infection	Therapy	Outcome	Reference
<i>T. subthermophila</i>	39	M	Healthy	Brain	AmB	Died	This study 28
	10	F	Healthy	Cornea	Ciprofloxacin, tobramycin, AmB, cefazolin	Cured	
<i>C. strumarium</i>	20	M	IVDA	Brain	Ceftriaxone, penicillin, acyclovir	Died	1
	25	M	IVDA	Brain	Amoxicillin, acyclovir, AmB, rifampin, isoniazid	Died	1
	28	M	IVDA	Brain	Oxacillin, cefotaxime, metronidazole	Died	1
<i>C. atrobrunneum</i>	31	M	Multiple myeloma, allogeneic BMT	Brain, lung	AmB, ITC	Died	17
	32	M	Renal transplant	Brain	Unknown	Died	5
	12	M	AML	CSF, brain	AmB, itraconazole, L-AmB	Died	4
	<1	M	Anemia, pancytopenia	Lung	Piperacillin-tazobactam, gentamicin, AmB, L-AmB, ITC	Died	4
<i>C. globosum</i>	19	F	Lymphoma/autologous BMT	Lung pleura	Imipenem, vancomycin, amikacin, AmB	Died	21
	24	M	ALL	Lung	AmB	Died	18
<i>C. perlucidum</i>	78	F	Asthma, chronic bronchiectasis	Lung	RML lobectomy	Cured	10
	47	F	Leukemia, umbilical cord blood transplant	Multiple organs	L-AmB	Died	10
<i>Chaetomium</i> sp.	19	M	AML	Lung	L-AmB	Died	33
	73	F	None	Left maxillary sinus	Infundibulectomy	Cured	6

^a M, male; F, female; BMT, bone marrow transplant recipient; RML, right middle lobe; IVDA, intravenous drug abuser; AML, acute myelogenous leukemia patient; ALL, acute lymphocytic leukemia patient; AmB, amphotericin B; ITC, itraconazole; L-AmB, liposomal amphotericin B.

vitro MIC of amphotericin B, the patient died despite amphotericin B therapy. Murine studies showed no benefit from amphotericin B in cerebral phaeohyphomycosis due to poor penetration into the central nervous system (2), which may explain, in part, the treatment failure. Currently, there is no accepted standard therapy for brain infections by melanized fungi, but *in vitro* data (7, 8, 9) and one clinical study (3) suggest that posaconazole may be a potential choice.

Nucleotide sequence accession numbers. The ITS rDNA and nuLSU sequences from isolate CBS 125981 determined in this study have been deposited in GenBank under accession numbers HM448441 and HM448442, respectively.

This study was supported by a grant (no. 13081) to H. Badali from the Ministry of Health and Medical Education of the Islamic Republic of Iran and the School of Medicine, Mazandaran University of Medical Sciences, Sari, Iran. J. F. Meis received grants from Astellas, Merck, Basilea, and Schering-Plough. He has been a consultant to Astellas, Basilea, and Merck and received speaker's fees from Merck, Pfizer, Schering-Plough, and Janssen Pharmaceutica. All other authors report no conflicts of interest.

We are most grateful to Walter Gams for suggestions with respect to phenotypic identification.

REFERENCES

- Abbott, S. P., et al. 1995. Fatal cerebral mycoses caused by the ascomycete *Chaetomium strumarium*. J. Clin. Microbiol. 33:2692–2698.
- Al-Abdely, H. M., et al. 2000. SCH 56592, amphotericin B, or itraconazole therapy of experimental murine cerebral phaeohyphomycosis due to *Ramichloridium obovoideum* (“*Ramichloridium mackenziei*”). Antimicrob. Agents Chemother. 44:1159–1162.
- Al-Abdely, H. M., et al. 2005. Successful therapy of cerebral phaeohyphomycosis due to *Ramichloridium mackenziei* with the new triazole posaconazole. Med. Mycol. 43:91–95.
- Al-Aidaros, A., et al. 2007. Invasive *Chaetomium* infection in two immunocompromised paediatric patients. Pediatr. Infect. Dis. J. 26:456–458.
- Anandi, V., et al. 1989. Cerebral phaeohyphomycosis caused by *Chaetomium globosum* in a renal transplant recipient. J. Clin. Microbiol. 27:2226–2229.
- Aru, A., L. Munk-Nielsen, and B. H. Federspiel. 1997. The soil fungus *Chaetomium* in the human paranasal sinuses. Eur. Arch. Otorhinolaryngol. 254:350–352.
- Badali, H., G. S. De Hoog, I. Curfs-Breuker, C. H. W. Klaassen, and J. F. Meis. 2010. Use of amplified fragment length polymorphism to identify 42 *Cladophialophora* strains related to cerebral phaeohyphomycosis with *in vitro* antifungal susceptibility. J. Clin. Microbiol. 48:2350–2356.
- Badali, H., G. S. De Hoog, I. Curfs-Breuker, and J. F. Meis. 2010. *In vitro* activities of antifungal drugs against *Rhinoctadiella mackenziei*, an agent of fatal brain infection. J. Antimicrob. Chemother. 65:175–177.
- Badali, H., et al. 2010. First autochthonous case of *Rhinoctadiella mackenziei* cerebral abscess outside the Middle East. J. Clin. Microbiol. 48:646–649.
- Barron, M. A., et al. 2003. Invasive mycotic infections caused by *Chaetomium perlucidum*, a new agent of cerebral phaeohyphomycosis. J. Clin. Microbiol. 41:5302–5307.
- Bourbeau, P., D. A. McGough, H. Fraser, N. Shah, and M. G. Rinaldi. 1992. Fatal disseminated infection caused by *Myceliophthora thermophila*, a new agent of mycosis: case history and laboratory characteristics. J. Clin. Microbiol. 30:3019–3023.
- Chakrabarti, A. 2007. Epidemiology of central nervous system mycoses. Neurol. India 55:191–197.
- Clinical and Laboratory Standards Institute. 2008. Reference method for broth dilution antifungal susceptibility testing of filamentous fungi. Approved standard, 2nd ed. Document M38-A2. Clinical and Laboratory Standards Institute, Wayne, PA.

14. **De Hoog, G. S., J. Guarro, J. Gené, and M. J. Figueras.** 2000. Atlas of clinical fungi, 2nd ed. Centraalbureau voor Schimmelcultures, Utrecht, Netherlands.
15. **Guarro, J.** 1998. Comments on recent human infections caused by ascomycetes. *Med. Mycol.* **36**:349–350.
16. **Guarro, J., L. Soler, and M. G. Rinaldi.** 1995. Pathogenicity and antifungal susceptibility of *Chaetomium* species. *Eur. J. Clin. Microbiol. Infect. Dis.* **14**:613–618.
17. **Guppy, K. H., C. Thomas, K. Thomas, and D. Anderson.** 1998. Cerebral fungal infections in the immunocompromised host: a literature review and a new pathogen *Chaetomium atrobrunneum*: case report. *Neurosurgery* **43**:1463–1469.
18. **Hoppin, E. C., E. L. McCoy, and M. G. Rinaldi.** 1983. Opportunistic mycotic infection caused by *Chaetomium* in a patient with acute leukemia. *Cancer* **52**:555–556.
19. **Horré, R., and G. S. De Hoog.** 1999. Primary cerebral infections by melanized fungi: a review. *Stud. Mycol.* **43**:176–193.
20. **Kantarcioglu, A. S., and G. S. De Hoog.** 2004. Infections of the central nervous system by melanized fungi: a review of cases presented between 1999 and 2004. *Mycoses* **47**:4–13.
21. **Lesire, V., et al.** 1999. Possible role of *Chaetomium globosum* in infection after autologous bone marrow transplantation. *Intensive Care Med.* **25**:124–125.
22. **Li, D. M., and G. S. De Hoog.** 2009. Cerebral phaeohyphomycosis—a cure at what lengths? *Lancet Infect. Dis.* **9**:376–383.
23. **Malloch, D., and R. F. Cain.** 1973. The genus *Thielavia*. *Mycologia* **65**:1055–1077.
24. **Mouchacca, J.** 1973. Les *Thielavia* des sols arides: espèces nouvelles et analyse générique. *Bull. Trim. Soc. Fr. Mycol.* **89**:295–311.
25. **Moustafa, A.-W. F., and A. M. Abdel-Azeem.** 2008. *Thielavia gigaspora*, a new thermotolerant ascomycete from Egypt. *Microbiol. Res.* **163**:441–444.
26. **Revankar, S. G., D. A. Sutton, and M. G. Rinaldi.** 2004. Primary central nervous system phaeohyphomycosis: a review of 101 cases. *Clin. Infect. Dis.* **38**:206–216.
27. **Revankar, S. G., and D. A. Sutton.** 2010. Melanized fungi in human disease. *Clin. Microbiol. Rev.* **23**:884–928.
28. **Stchigel, A. M., L. Figueras, J. Cano, and J. Guarro.** 2002. New species of *Thielavia*, with a molecular study of representative species of the genus. *Mycol. Res.* **106**:975–983.
29. **Theoulakis, P., D. Goldblum, S. Zimmerli, K. Muehlethaler, and B. E. Frueh.** 2009. Keratitis resulting from *Thielavia subthermophila* Mouchacca. *Cornea* **28**:1067–1069.
30. **Uddin, N.** 2005. Estimation of aeromycoflora in jute fields. *Aerobiologia* **21**:75–80.
31. **von Arx, J. A.** 1975. On *Thielavia* and some similar genera of ascomycetes. *Stud. Mycol.* **8**:1–32.
32. **von Arx, J. A., J. Guarro, and M. J. Figueras.** 1988. Sordariaceous ascomycetes without ascospore ejection. *Beih. Nova Hedwigia* **94**:1–104.
33. **Yeghen, T., et al.** 1996. *Chaetomium* pneumonia in a patient with acute myeloid leukaemia. *J. Clin. Pathol.* **49**:184–186.