

Review

Basic research and clinical investigations of the neural basis of orofacial pain

Yoshizo Matsuka^a, Koichi Iwata^{b,c}, Ryuji Terayama^d, Yoshiki Imamura^e, Kotaro Maruhama^d, Masamichi Shinoda^{b,c}, Yoshiyuki Tsuboi^{b,c}, Masahiro Kondo^{b,c}, Kuniya Honda^b, Ayano Katagiri^{b,c}, and Tomosada Sugimoto^d

^a Department of Stomatognathic Function and Occlusal Reconstruction, Institute of Health Biosciences, Tokushima University Graduate School, 3-18-15 Kuamoto-cho, Tokushima, Japan. E-mail: matsuka@tokushima-u.ac.jp

^b Department of Physiology, Nihon University School of Dentistry, 1-8-13 Kanda Surugadai, Chiyoda-ku, Tokyo 101-8310, Japan. E-mail: iwata.kouichi@nihon-u.ac.jp

^c Division of Functional Morphology, Dental Research Center, Nihon University School of Dentistry, Tokyo, Japan

^d Department of Oral Function and Anatomy, Okayama University Graduate School of Medicine, Dentistry and Pharmaceutical Sciences, Okayama 700-8525, Japan. E-mail: ryujit@md.okayama-u.ac.jp, tsugi@md.okayama-u.ac.jp, maruhama@okayama-u.ac.jp

^e Department of Oral Diagnostic Sciences, Nihon University School of Dentistry, 1-8-13 Kanda Surugadai, Chiyoda-ku, Tokyo, 101-8310, Japan. E-mail: imamura.yoshiki@nihon-u.ac.jp

Corresponding author:

Tomosada Sugimoto, DDS, PhD

Department of Oral Function and Anatomy,

Okayama University Graduate School of Medicine, Dentistry and Pharmaceutical Sciences, Okayama 700-8525, Japan.

E-mail: tsugi@md.okayama-u.ac.jp,

Phone: +81-86-235-6637

Abstract

Background: Trigeminal nerve injury or orofacial inflammation causes severe pain in the orofacial regions innervated by uninjured nerves or uninflamed tissues as well as injured or inflamed tissues. Pathological orofacial pain associated with trigeminal nerve injury or inflammation is difficult to diagnose and treat.

Highlights: To develop appropriate treatments for patients with orofacial pathological pain, various animal models of trigeminal nerve injury or orofacial inflammation have been developed. Further, the possible mechanisms involving the trigeminal ganglion (TG), trigeminal spinal subnucleus caudalis (Vc), and upper cervical spinal cord (C1-C2) have been studied.

Conclusions: 1) Neurotransmitters released from the somata of TG neurons are involved in peripheral sensitization. 2) Neurotransmitter release from TG neurons is decreased by botulinum toxin-type A administration, suggesting that this toxin suppressed neurotransmitter release and alleviated the neuropathic pain-related behavior. 3) Altered states of glial cells and nociceptive neurons, in the Vc and C1-C2 are involved in pathological orofacial pain associated with trigeminal nerve injury or orofacial inflammation. 4) The trigeminal sensory nuclear complex, especially the trigeminal spinal subnucleus oralis, is involved in normal and pathological orofacial pain conditions after peripheral nerve injury. 5) Neuroimaging analyses have suggested functional changes in the central and peripheral nervous systems in neuropathic pain conditions.

Key words

orofacial pathological pain, nerve injury, glial cell, trigeminal sensory nuclear complex, neuroimaging

Abbreviations

ACSF: artificial cerebrospinal fluid

ATP: adenosine-5'-triphosphate

BoNT/A: botulinum toxin-type A

Cm: membrane capacitance

DRG: dorsal root ganglia

ES: electrical stimulation

FM4-64: N-(3-triethylammoniumpropyl)-4-(6-(4-(diethylamino)phenyl) exatrienyl pyridinium dibromide

Fos-LI: c-Fos protein-like immunoreactivity

FA: fractional anisotropy

HRP: horseradish peroxidase

IAN: inferior alveolar nerve

IANX: Inferior alveolar nerve transection
IB4: isolectin B4
ION-CCI: Chronic constriction injury of the infraorbital nerve
L/L: luciferin-luciferase
LN: lingual nerve
MAPKs: mitogen-activated protein kinases
NGF: nerve growth factor
NS: noxious specific
PrV: rostral-most trigeminal principal sensory nucleus
SNE: sciatic nerve entrapment
SP: substance P
TG: trigeminal ganglion
TMD: temporomandibular disorder
TSNC: trigeminal sensory nuclear complex
Vc: trigeminal spinal subnucleus caudalis
Vi: trigeminal spinal subnucleus interpolaris
Vo: trigeminal spinal subnucleus oralis
WDR: wide dynamic range

1. Introduction

Research on pain has been avoided in the past because of the technical difficulties in objectively analyzing data on the subjective sensation of pain. However, control of pain is one of the most important issues in the field of medicine that emphasizes on the patients quality of life. Only the pulp contains sensory receptors for pain. Thus, researchers have been actively targeting nociceptors. Here we discuss how the management of orofacial pain can be improved in the future. We describe the basic orofacial pain mechanisms and clinical approaches for such patients.

Allodynia and/or hyperalgesia frequently occur in the orofacial region following trigeminal nerve injury or orofacial inflammation [1,2]. Pathological pain associated with such injury/inflammation is severe and difficult to treat and occurs in wide areas innervated by injured as well as uninjured nerve fibers. Similar symptoms have been observed in the uninflamed as well as inflamed areas [3]. The extraterritorial orofacial pain that occurs in areas innervated by uninjured nerves or in uninflamed areas sometimes leads to misdiagnosis or inappropriate treatment [1,2]. It is very important to understand the mechanisms underlying extraterritorial orofacial pain associated with trigeminal nerve injury or orofacial inflammation in order to develop appropriate measures for treatment of patients with extraterritorial orofacial pain.

This review describes recent findings in animal models and the future directions of investigations of pathological pain mechanisms.

2. Mechanisms of orofacial pain transmission in the trigeminal ganglia (TG) and development of new treatment procedures: neurotransmitter release from the somata of sensory ganglia

Many patients with trigeminal neuropathy suffer from severe pain. Anticonvulsants or antidepressants prescribed for pain management induce adverse effects in the central nervous system, such as dizziness and drowsiness. Understanding the mechanisms that lead to trigeminal neuropathic pain is essential for development of new treatment modalities without adverse side effects. Animal models of peripheral nerve injuries have been used to mimic human neuropathic pain symptoms (e.g., tactile allodynia or thermal hyperalgesia) [4-8]. Neuropathic pain states are known to induce hyperexcitability in injured or neighboring primary sensory neurons in sensory ganglia [9-11]. Our research aimed at determining whether neuronal excitability induces neurotransmitter release from the somata of sensory ganglia and whether neurotransmitter release is related to the pain symptoms.

We investigated adenosine 5'-triphosphate (ATP) release from the rat dorsal root ganglia (DRG) after inducing peripheral neuropathic pain by unilateral sciatic nerve entrapment (SNE) [12]. Ipsilateral hind paw withdrawal threshold in response to mechanical or thermal stimulation was decreased in rats that underwent SNE [8]. The DRG was perfused with normal

artificial cerebrospinal fluid (ACSF) in a sample collection chamber, and the perfusate was analyzed for ATP contents with the firefly luciferin-luciferase (L/L) assay. The ipsilateral L4-L5 DRG showed significantly more basal extracellular ATP release after SNE than the control DRG. Because extracellular ATP is degraded to adenosine, we applied a selective adenosine 1 receptor (A1R) agonist, 2-chloro-N6-cyclopentyladenosine, and found a significant decrease in basal and evoked ATP release. This indicated that functional A1R activation reduced ATP release. Conversely, a selective A1R antagonist, 8-cyclopentyl-1,3-dipropylxanthine, increased basal ATP release and attenuated the blockade of KCl-evoked ATP release, suggesting that increased A1R activation reduced evoked ATP release in neurons ipsilateral to the SNE. In addition, we examined whether altered ATP release was related to DRG metabolism and measured O₂ consumption in control and neuropathic DRG. The neuropathic DRG consumed more O₂ than the control or contralateral DRG; suggesting that neuropathic pain states increase DRG metabolism and ATP release, which is modulated by increased A1R activation.

In addition, co-release of ATP and substance P (SP) was found within the TG [13]. The TG of anesthetized guinea pigs was perfused with ACSF using microdialysis probes. The perfusate was analyzed for ATP and SP contents with a L/L assay and radioimmunoassay, respectively. Significant reversible increases in ATP and SP were observed after neuronal stimulation with KCl or capsaicin (Fig. 1) [13]. Ca²⁺-free ACSF induced an eight-fold increase in ATP release, suggesting a reduction in the activity of Ca²⁺-dependent ectonucleotidases that degrade ATP. In contrast, KCl-induced ATP release under normal Ca²⁺ conditions was blocked by Cd²⁺, a voltage-gated Ca²⁺ channel blocker, indicating that ATP release was Ca²⁺ dependent. We tested ATP release from acutely dissociated TG neuron somata. Neuron-enriched dissociated TG cells were plated onto glass plates. The measured ATP release increased after the application of capsaicin, suggesting that ATP was concomitantly released with SP from the somata of TG.

Next, we investigated whether neurotransmitters were released directly from the somata of TG and if there were differences in neurotransmitter release between cells that did and did not contain neuropeptides. Neurotransmitter release from the dissociated neurons of rat TG was monitored using cell membrane capacitance (Cm) measurements and the fluorescent membrane-uptake marker N-(3-triethylammoniumpropyl)-4-(6-(4-(diethylamino)phenyl)hexatrienyl)pyridinium dibromide (FM4-64). Cm measurements were performed during whole-cell patch clamping with neurons depolarized from 75 mV to 10 mV to induce neurotransmitter release. TG cells were classified into two categories based on the binding of the plant isolectin B4 (IB4). Most of the nerve growth factor-responsive IB4-negative [IB4 (-)] nociceptors contain neuropeptides such as SP and calcitonin gene-related peptide, whereas the glial-derived neurotrophic factor-responsive IB4-positive [IB4 (+)] neurons lack such neuropeptides [14,15]. TG neurons show calcium-dependent increases in Cm, indicating neurotransmitter release upon electrical stimulation. Moreover, the peak Cm of IB4(+) neurons decays faster toward baseline

than that of the IB4(-) neurons. While IB4(+) neurons have stable Cm responses to repeated stimuli, IB4(-) neurons show reduced responses. These data suggest that the IB4(+) neurons show a faster rate of endocytosis and vesicle replenishment than to IB4(-) neurons. To test this, we measured vesicle trafficking with the fluorescent membrane dye FM4-64. Staining revealed that IB4(-) neurons contained a larger pool of endocytosed vesicles compared to IB4(+) neurons because the peak fluorescence increases in IB4(-) neurons were larger but slower compared to IB4(+) neurons. The recycled vesicles were released faster in IB4(+) than IB4(-) neurons. These data suggested that IB4(+) TG neurons have faster exocytosis and endocytosis than IB4(-) neurons [16].

Trigeminal neuropathies result in severe chronic pain that is inadequately alleviated by systemic drugs. New treatments should be developed to target peripheral sensory neurons because sensory neuron excitability and neurotransmitter release increase in neuropathic pain. These could include purified botulinum toxin-type A (BoNT/A), which reportedly blocks vesicular neurotransmitter release [17,18]. In rats, we tested whether trigeminal neuropathy induced by chronic constriction of the infraorbital nerve (ION-CCI) increased neurotransmitter release from the TG somata and whether it was decreased by BoNT/A. Therefore, we monitored the secretory activity of acutely dissociated TG neurons from ION-CCI rats by measuring the fluorescence intensity of the membrane-uptake marker FM4-64. FM4-64 staining showed that the neurons possessed a pool of recycled vesicles, which were released on application of high levels of KCl. BoNT/A pretreatment of acutely dissociated TG neurons from naïve rats significantly reduced the rate of FM4-64 dye release. TG neurons ipsilateral to the ION-CCI exhibited a significantly faster onset of FM4-64 release than those contralateral to the ION-CCI (sham surgery) (Fig. 2) [19]. ION-CCI induced long-lasting ipsilateral tactile allodynia, measured as large decreases in the withdrawal thresholds to mechanical and thermal stimulation. Intradermal injections of BoNT/A into the infraorbital branch of the trigeminal nerve decreased the ION-CCI-induced mechanical allodynia and reduced the exaggerated FM4-64 release from TG neurons (Fig. 3) [20], suggesting that BoNT/A decreases neuropathic pain behavior by decreasing neurotransmitter release from TG sensory neurons [19,20].

3. Glial cell involvement in extraterritorial pathological pain in orofacial regions

Developing an animal model of orofacial neuropathic pain is essential to develop methods for appropriate diagnosis and treatment of affected patients. Many studies have reported animal models of trigeminal nerve injury or orofacial inflammation [1,2]. The ION-CCI model is the first documented orofacial neuropathic pain model. Based on extra- or intra-oral approaches to the ION, two different methods exist for preparing the ION-CCI. These animals show hypersensitivity to non-noxious mechanical and/or thermal stimuli (allodynia) and hypersensitivity to noxious stimuli (hyperalgesia) in the orofacial region. The inferior alveolar nerve transection (IANX) model is also frequently used instead of the ION-CCI. In the

dentistry, lower molar tooth extraction sometimes causes severe pain in the facial skin innervated by the second branch of the trigeminal nerve and in the intraoral mucosa. The IANX model replicates these clinical problems [1,2]. Following the IANX or ION-CCI, facial skin becomes hypersensitive to mechanical and thermal stimuli and this could last for a month. The mechanical and thermal nocifensive behaviors observed in these models were very similar to those of patients with orofacial neuropathic pain [1,2].

Oral and craniofacial noxious inputs are conveyed to the trigeminal spinal subnucleus caudalis (Vc) or upper cervical spinal cord (C1-C2) [1,2]. Nociceptive neurons in the Vc and C1-C2 are classified as noxious-specific (NS) neurons or wide-dynamic-range (WDR) neurons according to their responses to mechanical stimuli. NS neurons dominantly respond to noxious but not to non-noxious mechanical stimuli, whereas WDR neurons respond to both noxious and non-noxious mechanical stimuli [21]. NS neurons have small receptive fields, and their spike frequency is not graded following an increase in stimulus intensity. However, WDR neurons have large receptive fields and steeper stimulus-response functions compared to NS neurons. Furthermore, WDR neurons respond to non-noxious stimuli that are applied to the center of the receptive field [1,2].

The Vc and C1-C2 regions have laminated structures that are similar to those of the spinal dorsal horn. Many NS and WDR neurons are located in the superficial laminae (laminae I-II) of the Vc and C1-C2, whereas WDR neurons are also distributed in the deep laminae (laminae IV-V). These distribution differences in the NS and WDR neurons are thought to reflect functional differences in these nociceptive neurons. NS neurons are involved in motivational and affective aspects of pain, whereas WDR neurons are involved in sensory discriminative aspects [1,2].

Following trigeminal nerve injury, TG neurons are strongly activated, resulting in the sensitization of TG neurons. High-frequency discharges in TG neurons are sent to Vc and C1-C2 nociceptive neurons, and various molecular changes occur in these nociceptive neurons. In particular, glutamate release from the presynaptic terminals and NMDA receptor expression are strongly enhanced following trigeminal nerve injury or orofacial inflammation. This synaptic transmission is also modulated by various molecules, such as ATP, nerve growth factor, brain-derived neurotrophic factor, or SP [1,2]. The hyperexcitation of Vc and C1-C2 nociceptive neurons further enhances the neuronal excitability of those neurons, resulting in the sensitization of Vc and C1-C2 nociceptive neurons.

Microglial and astroglial cells, which are known to be widely distributed in the Vc, are involved in the nutrition and support of neuronal structures. Recently, it has been reported that microglial and astroglial cells are activated and change their morphological features following trigeminal nerve injury or orofacial inflammation [22-24] (Fig. 4). Activated microglial and astroglial cells affect the excitability of nociceptive neurons in Vc and C1-C2. The glutamine-glutamate shuttle is known to be an important mechanism involved in the modulation of Vc and

C1-C2 nociceptive neurons through the astroglial cell activation associated with trigeminal nerve injury [22]. Glutamine is released from the astroglial cells, and it is taken up from the presynaptic terminals by the glutamine transporter, resulting in an increase in glutamate release from the presynaptic terminals and enhancement of the postsynaptic neuronal excitability. Microglial cells are activated very early after trigeminal nerve injury, and astroglial cells are then activated [23]. The activation of these glial cells occurs in a wide area over the Vc and C1-C2, and they are involved in the activation of nociceptive neurons over this wide area. The activation of nociceptive neurons in a wide area of the Vc and C1-C2 through glia-neuron interactions is thought to cause extraterritorial neuropathic pain in the orofacial region [23].

The primary afferent activity is significantly enhanced and a barrage of action potentials is sent to the Vc and C1-C2 regions following trigeminal nerve injury. Vc and C1-C2 nociceptive neurons are then strongly activated and sensitized. Microglial and astroglial cells in the wide areas of the Vc and C1-C2 are activated after that, and neuron-glia interactions are further enhanced through various molecules (Fig. 4). The activity of many nociceptive neurons that receive inputs from the uninjured trigeminal nerve fibers is also strongly enhanced, resulting in extraterritorial pain abnormalities in the orofacial regions. These observations suggest that neuron-glia interactions in the Vc and C1-C2 are a new therapeutic target for the development of appropriate treatments for patients with extraterritorial orofacial pain.

4. Mechanisms of orofacial nociception and neuropathic pain in the trigeminal sensory nuclear complex (TSNC)

The TSNC is involved in the transmission of the nociceptive and non-nociceptive sensory information of the orofacial region. The TSNC consists of the rostral-most trigeminal principal sensory nucleus (PrV) and three subdivisions of the trigeminal spinal tract nucleus, namely, the subnucleus oralis (Vo), the subnucleus interpolaris (Vi), and the subnucleus caudalis (Vc) (Fig. 5). The caudal-most component of the TSNC, the Vc, has been traditionally considered to play an essential role in orofacial pain transmission and to represent the trigeminal homolog of the spinal dorsal horn [25,26]. Indeed, the Vc has a laminated structure similar to the spinal dorsal horn, and it is often referred to as the medullary dorsal horn. Several lines of evidence, however, seem to implicate the rostral subdivisions of the TSNC in the processing of orofacial pain sensations. In humans, a trigeminal tractotomy just above the level of the Vc fails to produce complete orofacial and dental analgesia [27], and patients with caudal pontine lesions show diminished intraoral sensations [28]. In cats and monkeys, trigeminal tractotomy does not completely eliminate nociceptive responses, especially those that are evoked by intraoral and perioral stimuli [29,30].

Traumatic injuries and surgical insults to peripheral nerves often cause neuropathic pain [31]. In the search for the mechanisms underlying neuropathic pain, excitability changes in the neurons in the sensory spinal nervous system have been demonstrated. For example,

injured primary neurons become sensitive to mechanical and chemical stimuli that are applied to the neuroma [32-35]. In the spinal dorsal horn, the somatotopy map of second-order neurons is disrupted, and the neurons that are disconnected from their original receptive field's begin to respond to stimulation of the skin outside their original receptive field [36-39]. It has also been documented that trigeminal nerve injury induces the hyperexcitability of Vc neurons and is responsible for the development of neuropathic pain states [40-42]. Recently, the involvement of the rostral subdivisions of the TSNC has been suggested in the neuropathic pain state. In this section, we summarize the structure and function of the TSNC involved in orofacial pain sensations in normal conditions and in pathological pain conditions after peripheral nerve injuries.

The central projection of the trigeminal primary afferents has been clarified by histological studies that use horseradish peroxidase (HRP) as a neuroanatomical tracer [43-46]. This approach has been refined with the introduction of HRP-conjugated lectins, such as wheat germ agglutinin, and the sites of the central terminations of different branches of the trigeminal nerve in each subdivision of the TSNC were elucidated [47,48]. These studies have demonstrated that the central terminals of the primary afferent neurons comprising the individual peripheral nerve branches have their central terminal fields arranged in a somatotopic manner. The ophthalmic division is located in the ventral or ventrolateral part of the TSNC, while the mandibular division is located in the dorsal or dorsomedial part. The maxillary division is situated in between. It has been shown that the nociceptive primary neurons innervating oral structures terminate in the rostral nuclei in the TSNC as well as in the Vc, while those innervating facial structures terminate primarily in the Vc [46,49]. These characteristics are consistent with the electrophysiological and immunohistochemical findings showing that neurons in the Vo respond to stimulation of the primary nociceptors innervating the intraoral structures [50-52]. The Vo, as well as the Vc, receives dense central projections of trigeminal primary nociceptors containing calcitonin gene-related peptide and SP [53]. The neurons in the Vo project to pain-related brain sites, including the parabrachial nucleus, the ventral posteromedial thalamic nucleus, and the posterior thalamic nucleus [54-56]. Moreover, morphine injections into the Vo produce antinociceptive effects on perioral pain [57]. These studies have suggested that the facial nociceptive signals are primarily transmitted in the Vc, while the intra- or perioral nociceptive signals are processed in the Vo as well as in the Vc.

Injuries to peripheral nerves induce long-lasting pathological pain, which is referred to as neuropathic pain [31]. Neuropathic pain includes abnormal pain sensations, such as hyperalgesia and allodynia. In addition to the pain that occurs as a direct result of the injury itself, aberrant chronic pain manifests itself outside as well as within the peripheral territory of the injured nerve [58,59]. It has also been documented that trigeminal nerve injury induces the hyperexcitability of Vc neurons and that this hyperexcitability is responsible for development of the neuropathic pain state. Many Vc neurons express c-Fos protein-like immunoreactivity

(Fos-LI) in response to non-noxious mechanical stimulation of the whisker pad skin after injury to the infraorbital nerve [40]. A similar injury-induced hyperinducibility of Fos-LI has been reported for the Vc, and the number of Fos-LI neurons following noxious stimulation of the whisker pad skin was significantly increased in a rat with an inferior alveolar nerve (IAN) injury [41]. Our recent study that examined the double immunofluorescence labeling for c-Fos and phosphorylated extracellular signal-regulated kinase has revealed that convergent primary nociceptive inputs through neighboring intact nerves may contribute to the c-Fos hyperinducibility in the Vc following trigeminal nerve injury (unpublished observations). In addition, peripheral nerve injuries activate mitogen-activated protein kinases (MAPKs) and glial cells in the Vc, which contribute to the neuropathic pain state [22,60,61]. Peripherally axotomized primary neurons are thought to release neurotransmitters and/or neuromodulators by several different mechanisms. Axolemmal disruption certainly causes injury discharge immediately after the injury. In other instances, ectopic spike generation in the neuroma and ephaptic connections between the injured primary neurons may also induce transmitter release in the chronic injured state [62,63]. These neurotransmitters or neuromodulators may be responsible for the changes in the histological environment surrounding postsynaptic neurons, such as the activation of MAPKs and glial cells in the CNS. These changes might be involved in the neuronal plasticity of second-order neurons in the Vc and the neuropathic pain after peripheral nerve injury.

In the spinal sensory nervous system, the spinal dorsal horn transmits somatosensory information, including nociceptive information, while the dorsal column nuclei, including the medially placed gracile nucleus and the laterally placed cuneate nucleus, are the primary relay nuclei in which the thick myelinated primary sensory axons serving tactile modalities terminate. However, accumulating evidence has indicated that these nuclei are particularly important in the pathogenesis of the abnormal pain sensations that are caused by nerve injuries [64-66]. Excitability of the gracile nucleus neurons is enhanced after peripheral nerve injury [67,68]. The development of tactile allodynia and not thermal hyperalgesia is suppressed by blocking the signals to the gracile nucleus from injured primary afferents [64-66]. These previous studies have suggested that not only the spinal dorsal horn but also the dorsal column nuclei contribute to the development of nerve injury-induced tactile allodynia. Our previous study has showed that spinal nerve ligation induces marked phosphorylation of p38 MAPK and microglial activation in the gracile nucleus, which, in turn, contributes to the development of neuropathic pain [69]. In the trigeminal system, the involvement of the rostral subdivisions of the TSNC has been suggested in the neuropathic pain state. For example, intramuscular injections of mustard oil induce prolonged facilitation of Vo neurons [70]. Some Vo neurons transmit the somatosensory signals to other nociception-related brainstem areas, including the parabrachial nucleus and thalamus [55,56,71]. Our recent study has demonstrated MAPK phosphorylation and activation of microglia and astrocytes in the rostral subdivisions of the TSNC, especially

in the Vo. The magnitude of these changes was comparable to those in the Vc (Fig. 6). Furthermore, electrical stimulation (ES) at a non-noxious intensity induced Fos-LI in many neurons of the Vo when applied to the chronically injured lingual nerve (LN) but not when applied to the uninjured LN. This hyperinducibility of Fos-LI was not observed by ES at a non-noxious intensity of the uninjured LN after injury to the IAN (Fig. 7A, B). However, in rats with chronically injured IANs, the number of Fos-LI neurons induced by ES of the LN at a noxious intensity was significantly increased in the Vc but not in the Vo (Fig. 7C, D) [72]. These results suggested that nerve injury causes differential effects on neuronal excitability in the Vo and Vc. The excitability change in the Vc neurons may reflect anomalous pain responses, such as hyperalgesia, to normal noxious stimuli that are applied to the intraoral structures. The enhanced Vo neuronal activity, however, may be involved in pain originating in the neuroma.

In this section, we discussed the involvement of the TSNC, especially the Vo, in orofacial nociception and neuropathic pain. Further research on the exact role of the TSNC in orofacial pain will help to develop potential therapeutic targets for the prevention of neuropathic pain.

5. Clinical neurofunction in chronic orofacial pain

Recent advances in neuroimaging have allowed us to further understand the mechanisms of pain. Neuroimaging allows us to verify what we have learned from animal studies. During the past two decades, numerous animal studies have been conducted on pain chronicity, and they have suggested that chronic orofacial pain is induced by central/peripheral sensitization. Functional neuroimaging studies have implicated the central and peripheral nervous systems.

TG cells release some neurotransmitters (e.g., ATP, nitric oxide, and nerve growth factor), and the coupling of these neurotransmitters to their receptors results in the activation of glial cells and neighboring neurons [3,73]. Continuous noxious inputs from the temporomandibular joint induce satellite cell's activation in the TG, which leads to new connections between satellite cells forming neighboring envelopes [74,75]. Therefore, continuous excitation of TG neurons induces the activation of satellite cells and vice versa.

In the peripheral trigeminal system, a diffusion tensor imaging study has shown a significant decrease in fractional anisotropy (FA) and a significant increase in mean diffusivity in both the trigeminal roots in patients with temporomandibular joint disorder (TMD) compared to controls [76]. The decrease in FA and the increases in mean diffusivity and radial diffusivity are due to changes in the macro- and micro-structures of nerve fibers, such as those caused by neural edema or changes in the permeability of the membranes and crossings. Interestingly, FA decreases in accordance with the duration of TMD. These findings may reflect the plasticity of nerve structures and, probably, pain chronicity [76].

In the caudal medullary dorsal horn, the neuronal plasticity of nociceptive secondary

neurons is induced by repetitive noxious inputs [2,77]. Another important issue in the brainstem is descending pain modulation. In an imaging study, Younger et al. have reported a particular finding. They reported increased grey matter volume in bilateral spinal trigeminal nuclei in patients with myofascial TMD and decreased grey matter volume in various sites in the cerebral cortex in patients with chronic pain conditions [78]. Interestingly, Fallon et al. have reported a reduction in the total volume of the brain stem grey matter in patients with fibromyalgia [79]. The differences in these pain conditions include the site of the chief complaint. The brainstem plays a key role in pain transmission in TMD, whereas it mainly contributes to pain modulation in fibromyalgia. Although this imaging finding does not precisely explain the individual mechanisms of pain processing or pain modulation in the brainstem, it may reflect an important role of the brainstem as a hub of neural function in the integration of trigeminal pain processing and modulation.

The next region of interest is the thalamus. All somatosensory fibers make a relay in the thalamus. Fibers originating from the caudal medulla reach the ventrobasal complex, especially the ventral posterior medial nucleus, which mainly projects to the somatosensory cortex. In contrast, fibers that ascend through the medullary reticular formation make connections with the intralaminar nuclei, and, then, the neurons send fibers to the limbic system, cingulate cortex, and prefrontal cortex [80]. Three groups have reported a significant difference in the grey matter volume of the thalamus between patients with TMD and healthy controls [78,81,82]. The relationship between the thickness of the grey matter of the sensory nuclei of the thalamus and the duration of TMD exhibited a significant positive correlation [82]. This finding suggests that a barrage of noxious inputs from the trigeminal territory induces morphological changes in the thalamus. Younger et al. have further reported an increased volume of the basal ganglia, especially the striatum, in patients with myofascial TMD [78]. The striatum is involved in descending inhibitory control by activating D2 dopaminergic and alpha 2 adrenergic neurons, and it is considered that these areas are overstressed [83]. Several studies have investigated cortical function in patients with TMD patients with magnetic resonance imaging [76,78,81,82,84,85]. These studies were designed to study changes in cerebral blood flow, grey matter thickness, and actual active areas. Most of the studies have set a region of interest that covers the corresponding areas for orofacial pain.

In chronic pain conditions, repeated inputs from the periphery induce increases in cerebral blood flow in the responsible cortical area. In contrast to neuropathic pain conditions, once deafferentation occurs and inputs from the periphery are reduced, brain activity in the corresponding area is suppressed. As a result of these alterations, cortical reorganization is induced, and areas that show increased cerebral blood flow appear to be surrounding the original area that was responsible for the activation [81,86]. Moayed and colleagues have reported the cortical thickness in the primary somatosensory cortex in patients with TMD compared to healthy controls [87]. In contrast, Younger et al. have reported decreased thickness

of S1 in patients with myofascial TMD [78], and Gustin et al. have reported no statistical differences in the cortical thickness between patients with TMD and controls [84]. Some researchers have reported that morphological changes in the grey matter do not always indicate that the changes are irreversible. Discrepancies in the results of these studies appear to be due to differences in the statistical analyses and, more importantly, the actual subtypes of TMD and the duration of the TMD in the subjects. The frontal pole and prefrontal cortex are believed to be involved in cognitive function. In chronic pain states, pain is always there and when a patient has something to do, he or she has to decide to do it or avoid it. Therefore, these areas are always preloaded. In contrast, the primary motor cortex and midcingulate cortex are associated with descending inhibition. Negative correlations between cortical thickness and pain intensity probably represent impaired function of this inhibition [87].

6. Conclusions

Recent advances in basic and clinical research studies have given us an opportunity to understand the mechanisms of pathological orofacial pain and to develop various clinical approaches for patients with orofacial pain. In this review, we summarized the recent topics of orofacial pain mechanisms as follows. 1) Neurotransmitters are released from the somata of TG neurons that are involved in peripheral sensitization. 2) The neurotransmitters that are released from the TG neurons are depressed following BoNT/A administration, suggesting that BoNT/A decreases neurotransmitter release, and neuropathic pain behavior is decreased. 3) Glial cells are involved in the orofacial pathological pain associated with trigeminal nerve injury or orofacial inflammation as well as Vc and C1-C2 nociceptive neurons. 4) The structure and function of the TSNC, especially the trigeminal spinal subnucleus oralis (Vo), is involved in orofacial pain sensations in normal conditions and in pathological pain conditions after peripheral nerve injuries. 5) Functional neuroimaging studies have implicated changes in the central and peripheral nervous systems in neuropathic pain conditions.

Conflict of Interest

The authors declare no conflict of interest.

Ethical Approval

Ethical approvals are not required in this review.

References

- [1] Iwata K, Tsuboi Y, Kondo M, Kitagawa J, Ogawa A, Suzuki I. Neuronal mechanisms of neuropathic pain in the trigeminal system. In: Shyu BC, Chien CC, editors. *Nociceptive*

- and neuropathic pain: Mechanisms and treatments. Kerala, India: Research Signpost; 2009. p. 61-75.
- [2] Iwata K, Imamura Y, Honda K, Shinoda M. Physiological mechanisms of neuropathic pain: The orofacial region. *Int Rev Neurobiol* 2011;97:227–50.
- [3] Shinoda M, Asano M, Omagari D, Honda K, Hitomi S, Katagiri A, Iwata K. Nerve growth factor contribution via transient receptor potential vanilloid 1 to ectopic orofacial pain. *J Neurosci* 2011;31:7145–55.
- [4] Bennett GJ, Xie YK. A peripheral mononeuropathy in rat that produces disorders of pain sensation like those seen in man. *Pain* 1988;33:87–107.
- [5] Kim SH, Chung JM. An experimental model for peripheral neuropathy produced by segmental spinal nerve ligation in the rat. *Pain* 1992;50:355–63.
- [6] Seltzer Z, Dubner R, Shir Y. A novel behavioral model of neuropathic pain disorders produced in rats by partial sciatic nerve injury. *Pain* 1990;43:205–18.
- [7] Vos BP, Strassman AM, Maciewicz RJ. Behavioral evidence of trigeminal neuropathic pain following chronic constriction injury to the rat's infraorbital nerve. *J Neurosci* 1994;14:2708–23.
- [8] Mosconi T, Kruger L. Fixed-diameter polyethylene cuffs applied to the rat sciatic nerve induce a painful neuropathy: ultrastructural morphometric analysis of axonal alterations. *Pain* 1996;64:37–57.
- [9] Gold MS. Spinal nerve ligation: what to blame for the pain and why. *Pain* 2000;84:117–20.
- [10] Devor M. Sodium channels and mechanisms of neuropathic pain. *J Pain* 2006;7:S3–S12.
- [11] Dray A. Neuropathic pain: emerging treatments. *Br J Anaesth* 2008;101:48–58.
- [12] Matsuka Y, Ono T, Iwase H, Mitirattanakul S, Omoto KS, Cho T, Lam YY, Snyder B, Spigelman I. Altered ATP release and metabolism in dorsal root ganglia of neuropathic rats. *Mol Pain* 2008;4:66.
- [13] Matsuka Y, Neubert JK, Maidment NT, Spigelman I. Concurrent release of ATP and substance P within guinea pig trigeminal ganglia in vivo. *Brain Res* 2001;915:248–55.
- [14] Silverman JD, Kruger L. Selective neuronal glycoconjugate expression in sensory and autonomic ganglia: relation of lectin reactivity to peptide and enzyme markers. *J Neurocytol* 1990;19:789–801.
- [15] Bennett DL, Dmietrieva N, Priestley JV, Clary D, McMahon SB. trkA, CGRP and IB4 expression in retrogradely labelled cutaneous and visceral primary sensory neurones in the rat. *Neurosci Lett* 1996;206:33–6.
- [16] Matsuka Y, Edmonds B, Mitirattanakul S, Schweizer FE, Spigelman I. Two types of neurotransmitter release patterns in isolectin B4-positive and negative trigeminal ganglion neurons. *Neuroscience* 2007;144:665–74.
- [17] Niemann H, Blasi J, Jahn R. Clostridial neurotoxins: new tools for dissecting exocytosis. *Trends Cell Biol* 1994;4:179–85.

- [18] Schiavo G, Matteoli M, Montecucco C. Neurotoxins affecting neuroexocytosis. *Physiol Rev.* 2000;80:717–66.
- [19] Kitamura Y, Matsuka Y, Spigelman I, Ishihara Y, Yamamoto Y, Sonoyama W, Kamioka H, Yamashiro T, Kuboki T, Oguma K. Botulinum toxin type a (150 kDa) decreases exaggerated neurotransmitter release from trigeminal ganglion neurons and relieves neuropathy behaviors induced by infraorbital nerve constriction. *Neuroscience* 2009;159:1422–9.
- [20] Kumada A, Matsuka Y, Spigelman I, Maruhama K, Yamamoto Y, Neubert JK, Nolan TA, Watanabe K, Maekawa K, Kamioka H, Yamashiro T, Kuboki T, Oguma K. Intradermal injection of Botulinum toxin type A alleviates infraorbital nerve constriction-induced thermal hyperalgesia in an operant assay. *J Oral Rehabil* 2012;39:63–72.
- [21] Iwata K, Imai T, Tsuboi Y, Tashiro A, Ogawa A, Morimoto T, Masuda Y, Tachibana Y, Hu J. Alteration of medullary dorsal horn neuronal activity following inferior alveolar nerve transection in rats. *J Neurophysiol* 2001;86:2868–77.
- [22] Okada-Ogawa A, Suzuki I, Sessle BJ, Chiang CY, Salter MW, Dostrovsky JO, Tsuboi Y, Kondo M, Kitagawa J, Kobayashi A, Noma N, Imamura Y, Iwata K. Astroglia in medullary dorsal horn (trigeminal spinal subnucleus caudalis) are involved in trigeminal neuropathic pain mechanisms. *J Neurosci* 2009;29:11161–71.
- [23] Chiang CY, Dostrovsky JO, Iwata K, Sessle BJ. Role of glia in orofacial pain. *Neuroscientist* 2011;17:303–20.
- [24] Kiyomoto M, Shinoda M, Okada-Ogawa A, Noma N, Shibuta K, Tsuboi Y, Sessle BJ, Imamura Y, Iwata K. Fractalkine signaling in microglia contributes to ectopic orofacial pain following trapezius muscle inflammation. *J Neurosci* 2013;33:7667–80.
- [25] Dubner R, Bennett GJ. Spinal and trigeminal mechanisms of nociception. *Annu Rev Neurosci* 1983;6:381–418.
- [26] Sessle BJ. Acute and chronic craniofacial pain: brainstem mechanisms of nociceptive transmission and neuroplasticity, and their clinical correlates. *Crit Rev Oral Biol Med* 2000;11:57-91.
- [27] Young RF. Effect of trigeminal tractotomy on dental sensation in humans. *J Neurosurg* 1982;56:812–8.
- [28] Graham SH, Sharp FR, Dillon W. Intraoral sensation in patients with brainstem lesions: role of the rostral spinal trigeminal nuclei in pons. *Neurology* 1988;38:1529–33.
- [29] Vyklicky L, Keller O, Jastreboff P, Vyklicky L Jr., Butkhuzi SM. Spinal trigeminal tractotomy and nociceptive reactions evoked by tooth pulp stimulation in the cat. *J Physiol (Paris)* 1977;73:379–86.
- [30] Dallel R, Raboisson P, Auroy P, Woda A. The rostral part of the trigeminal sensory complex is involved in orofacial nociception. *Brain Res* 1988;448:7–19.
- [31] Zimmermann M. Pathobiology of neuropathic pain. *Eur J Pharmacol* 2001;429:23–37.

- [32] Wall PD, Waxman S, Basbaum AI. Ongoing activity in peripheral nerve: injury discharge. *Exp Neurol* 1974;45:576–89.
- [33] Govrin-Lippmann R, Devor M. Ongoing activity in severed nerves: source and variation with time. *Brain Res* 1978;159:406–10.
- [34] Korenman EM, Devor M. Ectopic adrenergic sensitivity in damaged peripheral nerve axons in the rat. *Exp Neurol* 1981;72:63–81.
- [35] Scadding JW. Development of ongoing activity, mechanosensitivity, and adrenaline sensitivity in severed peripheral nerve axons. *Exp Neurol* 1981;73:345–64.
- [36] Devor M, Wall PD. Reorganisation of spinal cord sensory map after peripheral nerve injury. *Nature* 1978;276:75–6.
- [37] Lisney SJ. Changes in the somatotopic organization of the cat lumbar spinal cord following peripheral nerve transection and regeneration. *Brain Res* 1983;259:31–9.
- [38] Markus H, Pomeranz B, Krushelnycky D. Spread of saphenous somatotopic projection map in spinal cord and hypersensitivity of the foot after chronic sciatic denervation in adult rat. *Brain Res* 1984;296:27–39.
- [39] Hylden JL, Nahin RL, Dubner R. Altered responses of nociceptive cat lamina I spinal dorsal horn neurons after chronic sciatic neuroma formation. *Brain Res* 1987;411:341–50.
- [40] Vos BP, Strassman AM. Fos expression in the medullary dorsal horn of the rat after chronic constriction injury to the infraorbital nerve. *J Comp Neurol* 1995;357:362–75.
- [41] Nomura H, Ogawa A, Tashiro A, Morimoto T, Hu JW, Iwata K. Induction of Fos protein-like immunoreactivity in the trigeminal spinal nucleus caudalis and upper cervical cord following noxious and non-noxious mechanical stimulation of the whisker pad of the rat with an inferior alveolar nerve transection. *Pain* 2002;95:225–38.
- [42] Yonehara N, Kudo C, Kamisaki Y. Involvement of NMDA-nitric oxide pathways in the development of tactile hypersensitivity evoked by the loose-ligation of inferior alveolar nerves in rats. *Brain Res* 2003;963:232–43.
- [43] Marfurt CF. The central projections of trigeminal primary afferent neurons in the cat as determined by the transganglionic transport of horseradish peroxidase. *J Comp Neurol* 1981;203:785–98.
- [44] Shigenaga Y, Chen IC, Suemune S, Nishimori T, Nasution ID, Yoshida A, Sato H, Okamoto T, Sera M, Hosoi M. Oral and facial representation within the medullary and upper cervical dorsal horns in the cat. *J Comp Neurol* 1986;243:388–408.
- [45] Shigenaga Y, Okamoto T, Nishimori T, Suemune S, Nasution ID, Chen IC, Tsuru K, Yoshida A, Tabuchi K, Hosoi M, et al. Oral and facial representation in the trigeminal principal and rostral spinal nuclei of the cat. *J Comp Neurol* 1986;244:1–18.
- [46] Takemura M, Sugimoto T, Sakai A. Topographic organization of central terminal region of different sensory branches of the rat mandibular nerve. *Exp Neurol* 1987;96:540–57.

- [47] Takemura M, Sugimoto T, Shigenaga Y. Difference in central projection of primary afferents innervating facial and intraoral structures in the rat. *Exp Neurol* 1991;111:324–31.
- [48] Takemura M, Nagase Y, Yoshida A, Yasuda K, Kitamura S, Shigenaga Y, Matano S. The central projections of the monkey tooth pulp afferent neurons. *Somatosens Mot Res* 1993;10:217–27.
- [49] Sugimoto T, Fujiyoshi Y, He YF, Xiao C, Ichikawa H. Trigeminal primary projection to the rat brain stem sensory trigeminal nuclear complex and surrounding structures revealed by anterograde transport of cholera toxin B subunit-conjugated and *Bandeiraea simplicifolia* isolectin B4-conjugated horseradish peroxidase. *Neurosci Res* 1997;28:361–71.
- [50] Raboisson P, Bourdiol P, Dallel R, Clavelou P, Woda A. Responses of trigeminal subnucleus oralis nociceptive neurones to subcutaneous formalin in the rat. *Neurosci Lett* 1991;125:179–82.
- [51] Sugimoto T, He YF, Funahashi M, Ichikawa H. Induction of immediate-early genes *c-fos* and *zif268* in the subnucleus oralis by noxious tooth pulp stimulation. *Brain Res* 1998;794:353–8.
- [52] Sugimoto T, He YF, Xiao C, Ichikawa H. *c-fos* induction in the subnucleus oralis following trigeminal nerve stimulation. *Brain Res* 1998;783:158–62.
- [53] Sugimoto T, Fujiyoshi Y, Xiao C, He YF, Ichikawa H. Central projection of calcitonin gene-related peptide (CGRP)- and substance P (SP)-immunoreactive trigeminal primary neurons in the rat. *J Comp Neurol* 1997;378:425–42.
- [54] DeLeo JA, Yezierski RP. The role of neuroinflammation and neuroimmune activation in persistent pain. *Pain* 2001;90:1–6.
- [55] Dallel R, Ricard O, Raboisson P. Organization of parabrachial projections from the spinal trigeminal nucleus oralis: an anterograde tracing study in the rat. *J Comp Neurol* 2004;470:181–91.
- [56] Guy N, Chalus M, Dallel R, Voisin DL. Both oral and caudal parts of the spinal trigeminal nucleus project to the somatosensory thalamus in the rat. *Eur J Neurosci* 2005;21:741–54.
- [57] Luccarini P, Cadet R, Saade M, Woda A. Antinociceptive effect of morphine microinjections into the spinal trigeminal subnucleus oralis. *Neuroreport* 1995;6:365–8.
- [58] Sugimoto T, Ichikawa H, Hijiya H, Mitani S, Nakago T. *c-Fos* expression by dorsal horn neurons chronically deafferented by peripheral nerve section in response to spared, somatotopically inappropriate nociceptive primary input. *Brain Res* 1993;621:161–6.
- [59] Sugimoto T, Ichikawa H, Mitani S, Hitsu A, Nakago T. Changes in *c-fos* induction in dorsal horn neurons by hindpaw formalin stimulation following tibial neurotomy. *Brain Res* 1994;642:348–54.
- [60] Piao ZG, Cho IH, Park CK, Hong JP, Choi SY, Lee SJ, Lee S, Park K, Kim JS, Oh SB.

- Activation of glia and microglial p38 MAPK in medullary dorsal horn contributes to tactile hypersensitivity following trigeminal sensory nerve injury. *Pain* 2006;121:219–31.
- [61] Terayama R, Fujisawa N, Yamaguchi D, Omura S, Ichikawa H, Sugimoto T. Differential activation of mitogen-activated protein kinases and glial cells in the trigeminal sensory nuclear complex following lingual nerve injury. *Neurosci Res* 2011;69:100–10.
- [62] Seltzer Z, Devor M. Ephaptic transmission in chronically damaged peripheral nerves. *Neurology* 1979;29:1061–4.
- [63] Lisney SJ, Devor M. Afterdischarge and interactions among fibers in damaged peripheral nerve in the rat. *Brain Res* 1987;415:122–36.
- [64] Bian D, Ossipov MH, Zhong C, Malan TP Jr., Porreca F. Tactile allodynia, but not thermal hyperalgesia, of the hindlimbs is blocked by spinal transection in rats with nerve injury. *Neurosci Lett* 1998;241:79–82.
- [65] Sung B, Na HS, Kim YI, Yoon YW, Han HC, Nahm SH, Hong SK. Supraspinal involvement in the production of mechanical allodynia by spinal nerve injury in rats. *Neurosci Lett* 1998;246:117–9.
- [66] Sun H, Ren K, Zhong CM, Ossipov MH, Malan TP, Lai J, Porreca F. Nerve injury-induced tactile allodynia is mediated via ascending spinal dorsal column projections. *Pain* 2001;90:105–11.
- [67] Noguchi K, Kawai Y, Fukuoka T, Senba E, Miki K. Substance P induced by peripheral nerve injury in primary afferent sensory neurons and its effect on dorsal column nucleus neurons. *J Neurosci* 1995;15:7633–43.
- [68] Tokunaga A, Kondo E, Fukuoka T, Miki K, Dai Y, Tsujino H, Noguchi K. Excitability of spinal cord and gracile nucleus neurons in rats with chronically injured sciatic nerve examined by c-fos expression. *Brain Res* 1999;847:321–31.
- [69] Terayama R, Omura S, Fujisawa N, Yamaai T, Ichikawa H, Sugimoto T. Activation of microglia and p38 mitogen-activated protein kinase in the dorsal column nucleus contributes to tactile allodynia following peripheral nerve injury. *Neuroscience* 2008;153:1245–55.
- [70] Hu JW, Sessle BJ, Raboisson P, Dallel R, Woda A. Stimulation of craniofacial muscle afferents induces prolonged facilitatory effects in trigeminal nociceptive brain-stem neurones. *Pain* 1992;48:53–60.
- [71] De Chazeron I, Raboisson P, Dallel R. Organization of diencephalic projections from the spinal trigeminal nucleus oralis: an anterograde tracing study in the rat. *Neuroscience* 2004;127:921–8.
- [72] Fujisawa N, Terayama R, Yamaguchi D, Omura S, Yamashiro T, Sugimoto T. Fos protein-like immunoreactive neurons induced by electrical stimulation in the trigeminal sensory nuclear complex of rats with chronically injured peripheral nerve. *Exp Brain Res* 2012;219:191–201.

- [73] Kushnir R, Cherkas PS, Hanani M. Peripheral inflammation upregulates P2X receptor expression in satellite glial cells of mouse trigeminal ganglia: a calcium imaging study. *Neuropharmacology* 2011;61:739–46.
- [74] Hanani M, Huang TY, Cherkas PS, Ledda M, Pannese E. Glial cell plasticity in sensory ganglia induced by nerve damage. *Neuroscience* 2002;114:279–83.
- [75] Villa G, Ceruti S, Zanardelli M, Magni G, Jasmin L, Ohara PT, Abbracchio MP. Temporomandibular joint inflammation activates glial and immune cells in both the trigeminal ganglia and in the spinal trigeminal nucleus. *Mol Pain* 2010;6:89.
- [76] Moayedi M, Weissman-Fogel I, Salomons TV, Crawley AP, Goldberg MB, Freeman BV, Tenenbaum HC, Davis KD. White matter brain and trigeminal nerve abnormalities in temporomandibular disorder. *Pain* 2012;153:1467–77.
- [77] Sessle BJ. Peripheral and central mechanisms of orofacial inflammatory pain. *Int Rev Neurobiol* 2011;97:179–206.
- [78] Younger JW, Shen YF, Goddard G, Mackey SC. Chronic myofascial temporomandibular pain is associated with neural abnormalities in the trigeminal and limbic systems. *Pain* 2010;149:222–8.
- [79] Fallon N, Alghamdi J, Chiu Y, Sluming V, Nurmikko T, Stancak A. Structural alterations in brainstem of fibromyalgia syndrome patients correlate with sensitivity to mechanical pressure. *Neuroimage Clin* 2013;3:163–70.
- [80] Bushnell MC, Ceko M, Low LA. Cognitive and emotional control of pain and its disruption in chronic pain. *Nat Rev Neurosci* 2013;14:502–11.
- [81] Gustin SM, Peck CC, Wilcox SL, Nash PG, Murray GM, Henderson LA. Different pain, different brain: thalamic anatomy in neuropathic and non-neuropathic chronic pain syndromes. *J Neurosci* 2011;31:5956–64.
- [82] Moayedi M, Weissman-Fogel I, Salomons TV, Crawley AP, Goldberg MB, Freeman BV, Tenenbaum HC, Davis KD. Abnormal gray matter aging in chronic pain patients. *Brain Res* 2012;1456:82–93.
- [83] Pertovaara A, Wei H. Dual influence of the striatum on neuropathic hypersensitivity. *Pain* 2008;137:50–9.
- [84] Gustin SM, Peck CC, Cheney LB, Macey PM, Murray GM, Henderson LA. Pain and plasticity: is chronic pain always associated with somatosensory cortex activity and reorganization? *J Neurosci* 2012;32:14874–84.
- [85] Metz AE, Yau HJ, Centeno MV, Apkarian AV, Martina M. Morphological and functional reorganization of rat medial prefrontal cortex in neuropathic pain. *Proc Natl Acad Sci U S A* 2009;106:2423–8.
- [86] Nebel MB, Folger S, Tommerdahl M, Hollins M, McGlone F, Essick G. Temporomandibular disorder modifies cortical response to tactile stimulation. *J Pain* 2010;11:1083–94.

[87] Moayedi M, Weissman-Fogel I, Crawley AP, Goldberg MB, Freeman BV, Tenenbaum HC, Davis KD. Contribution of chronic pain and neuroticism to abnormal forebrain gray matter in patients with temporomandibular disorder. *Neuroimage* 2011;55:277–86.

Figure legends

Fig. 1

KCl-evoked release of adenosine-5'-triphosphate (ATP) and substance P (SP) within guinea pig trigeminal ganglia in vivo. (A) Summary of seven experiments measuring ATP contents in microdialysis samples with a firefly luciferin–luciferase assay. The data is shown as the mean percentage of baseline and standard error of the mean (SEM) before and after the infusion of 100 mM of KCl. Actual baseline [ATP] was 232.36106.6 pM. (B) Summary graph of SP levels measured by radioimmunoassay in the same samples after the ATP analysis. Actual baseline [SP] was 65.6631.4 pM. The asterisks denote a significant difference ($P < 0.05$) from the last sample before the KCl infusion. The baseline for each experiment was measured as the average ATP or SP contents in the three samples starting 1 h prior to KCl infusion. This figure is modified from Ref. [13] with permission.

Fig. 2

Botulinum toxin-type A (BoNT/A) injections ipsilateral to the ION-CCI decreases vesicular release of N-(3-triethylammoniumpropyl)-4-(6-(4-(diethylamino)phenyl) exatrienyl pyridinium dibromide (FM4-64) from acutely isolated trigeminal ganglion (TG) neurons of IoNC rats. BoNT/A (100 pg in 0.1 mL of saline) was injected intradermally in the area of the ipsilateral whisker pad 3 days after the IoNC surgery (11 days prior to TG neuron dissociation). BoNT/A significantly slowed the onset of KCl-induced vesicular FM4-64 release and produced large decreases in the maximal release in both isolectin B4 [IB4(+)] (A) and [IB4(-)] (B) neurons compared to neurons from the saline-injected neurons ipsilateral to the IoNC. This figure is modified from Ref. [19] with permission.

Fig. 3

BoNT/A alleviates the IoNC-induced changes in the operant measures of thermal hyperalgesia. Intradermal BoNT/A injections in IoNC rats decreased the number of facial contacts at the 45°C thermode (A) and increased the ratio of contact duration/contact numbers (C). The total contact duration was not affected by BoNT/A (B). The behavior of the sham-surgery rats with the 45°C thermode changed during the study period, and all of the data for the IoNC rats were divided by the sham rat average data at the same time point. The BoNT/A effect was dose dependent and was statistically significant with 100 and 200 pg. The sham operation did not affect rat drinking behavior, and the BoNT/A (100 pg) injection had no discernible behavioral effects on the sham-operated rats. Intradermal BoNT/A injections into the neck, within the trigeminal innervation but outside of IoN innervation, did not relieve the thermal hyperalgesia symptoms. Moreover, the injection of a mixture of BoNT/A and its neutralizing antibody did not relieve the thermal hyperalgesia. The data are presented as mean \pm SEM. * $P < 0.05$ and ** $P < 0.01$ between the time point of 7 days after the IoNC and 7 days after the BoNT/A injection. This

figure is modified from Ref. [20] with permission.

Fig. 4

Schematic illustration of the mechanisms of extraterritorial neuropathic pain in the orofacial regions that was associated with trigeminal nerve injury. Following the trigeminal nerve injury, microglial and astroglial cells are strongly activated in the Vc and C1-C2, and the excitability of nociceptive neurons is enhanced by various molecular mechanisms. Glu: glutamate, FKN: Fractalkine, BDNF: brain-derived neurotrophic factor, ERK: extracellular signal-regulated kinase.

Fig. 5

Dorsal view of the brainstem with a schematic drawing of the trigeminal sensory nuclear complex (TSNC). The TSNC consists of the trigeminal principal sensory nucleus (PrV) and three subdivisions of the trigeminal spinal tract nucleus, namely, the subnucleus oralis (Vo), the subnucleus interpolaris (Vi), and the subnucleus caudalis (Vc). TG, trigeminal ganglion; V1, ophthalmic division; V2, maxillary division; V3, mandibular division.

Fig. 6

Immunohistochemistry for p-ERK, p-p38 mitogen-activated protein kinase (MAPK), OX-42 (a microglial marker), and glial fibrillary acidic protein (GFAP; an astrocytic marker) in the Vo (top) and Vc (bottom) 1, 3, 3, and 7 days after lingual nerve (LN) injury, respectively. Marked activation of MAPKs and glial cells can be seen in the areas corresponding to the terminal field of the LN primaries [46], and the magnitude of activation in the Vo was comparable with that in the Vc. Scale bar = 200 μm . This figure is modified from Ref. [61] with permission.

Fig. 7

The rat TSNC was examined for C-Fos protein-like immunoreactivity (Fos-LI) neurons that were induced by electrical stimulation (ES) of the LN 2 weeks after injury to the LN or the interior alveolar nerve (IAN). (A) Photomicrographs of immunohistochemistry for c-Fos in the Vo and Vc following ES at an A-fiber intensity (0.1 mA) of the LN 14 days after LN injury and sham surgery. (B) The number per section of Fos-LI neurons in the Vo and in the superficial laminae (Vc I/II) and deep laminae (Vc III/IV) of the Vc following ES (0, 0.1, and 10 mA) of the LN 14 days after LN injury and sham surgery. An intensity-dependent increase was found in all of the parts examined irrespective of the nerve injury. A significant increase in the number of Fos-LI neurons was found in the Vo following ES at 0.1 mA in the LN-injured group compared to that in the sham-operated group. The asterisks at each bar indicate a significant difference from respective sham ES [$*P < 0.05$, analysis of variance (ANOVA) with post-hoc Tukey-Kramer test]. Statistical comparisons were also made between nerve-injured and sham-

operated groups for each ES (#P < 0.05, Student's *t*-test). (C) Photomicrographs of immunohistochemistry for c-Fos in the Vo and Vc following ES at the C-fiber intensity (10 mA) of the LN 14 days after IAN injury and sham surgery. (D) The number per section of Fos-LI neurons in the Vo and in the superficial laminae (Vc I/II) and deep laminae (Vc III/IV) of the Vc following ES (0, 0.1, and 10 mA) of the LN 14 days after IAN injury and sham surgery. A significant increase in the number of Fos-LI neurons was found in the superficial laminae of the Vc following ES at 10 mA in the IAN-injured group compared to that in the sham-operated group. The asterisks at each bar indicate significant differences compared to the respective sham ES (*P < 0.05, ANOVA with post-hoc Tukey-Kramer test). Statistical comparisons were also made between the nerve-injured and sham-operated groups in each ES (#P < 0.05, Student's *t*-test). Scale bar = 200 μ m. This figure is modified from Ref. [72] with permission.

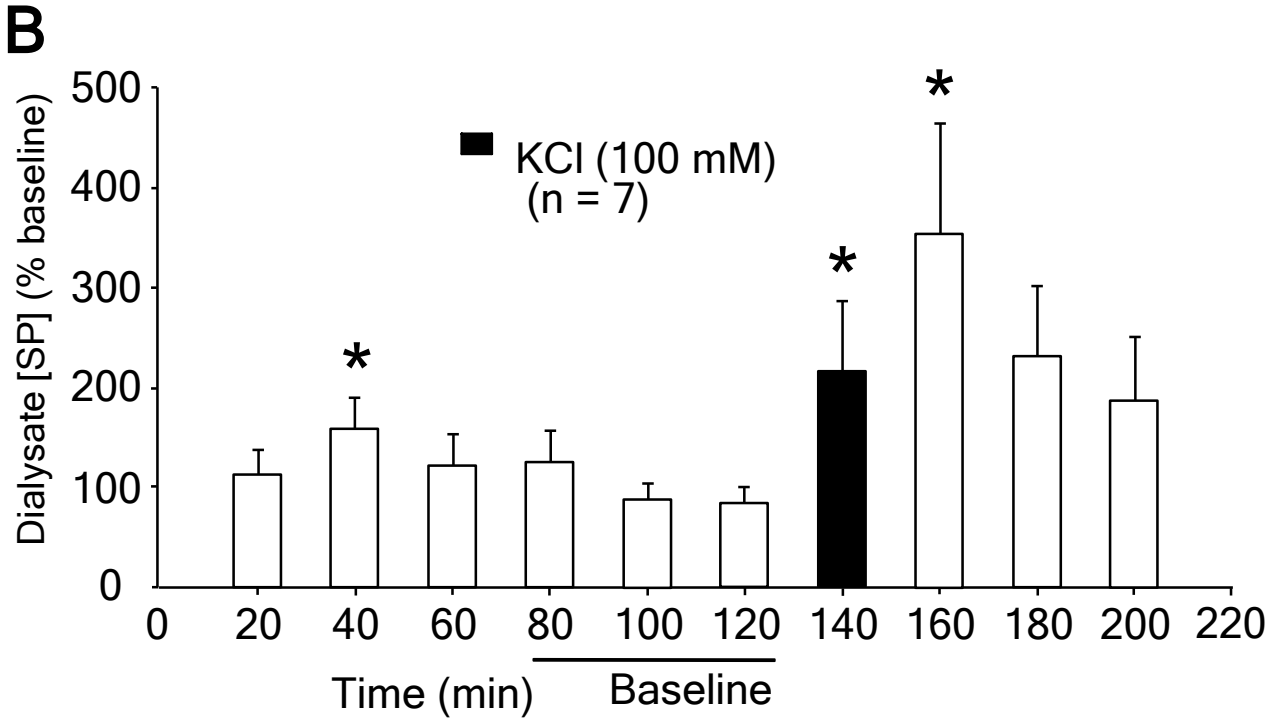
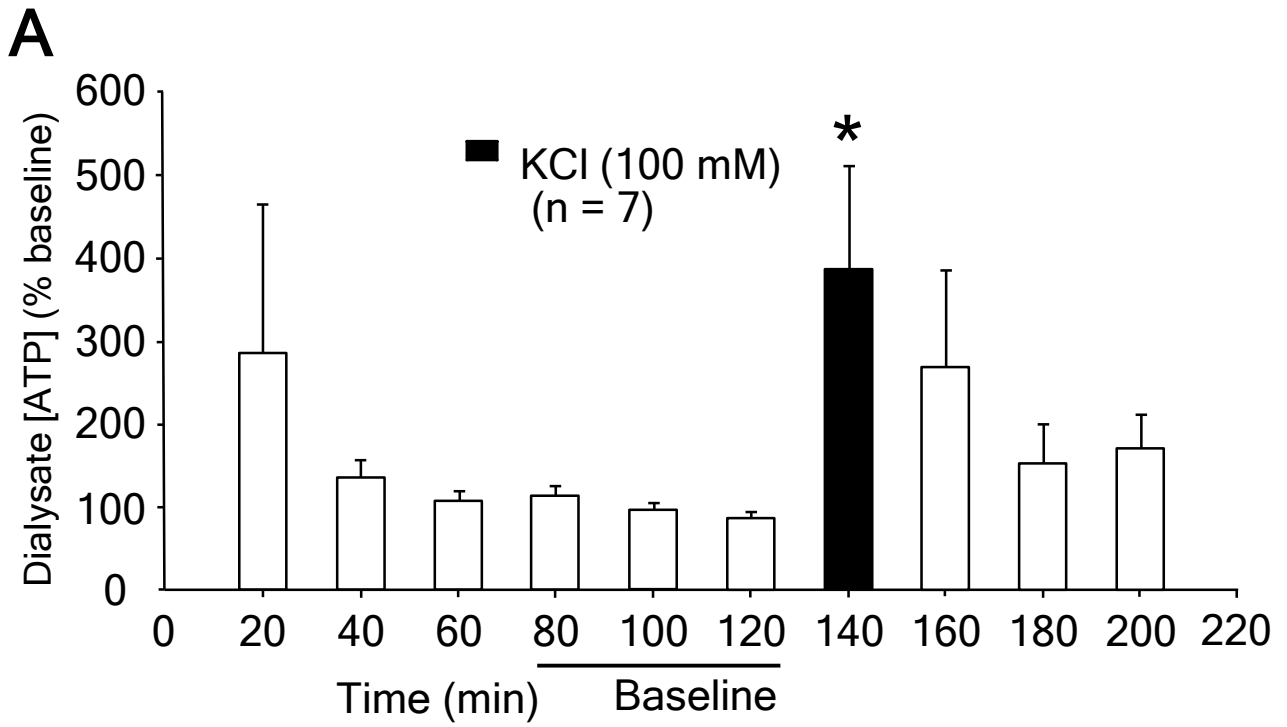


Fig.1

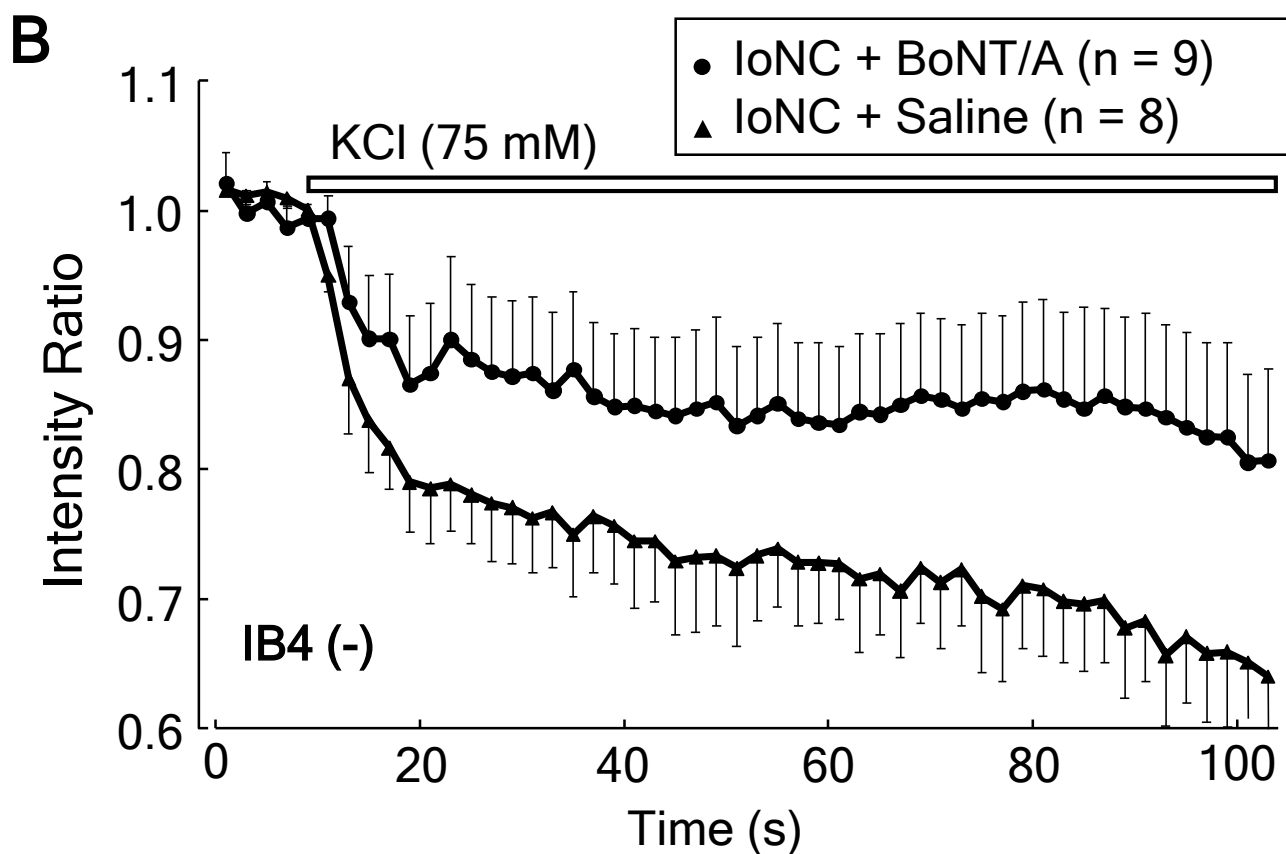
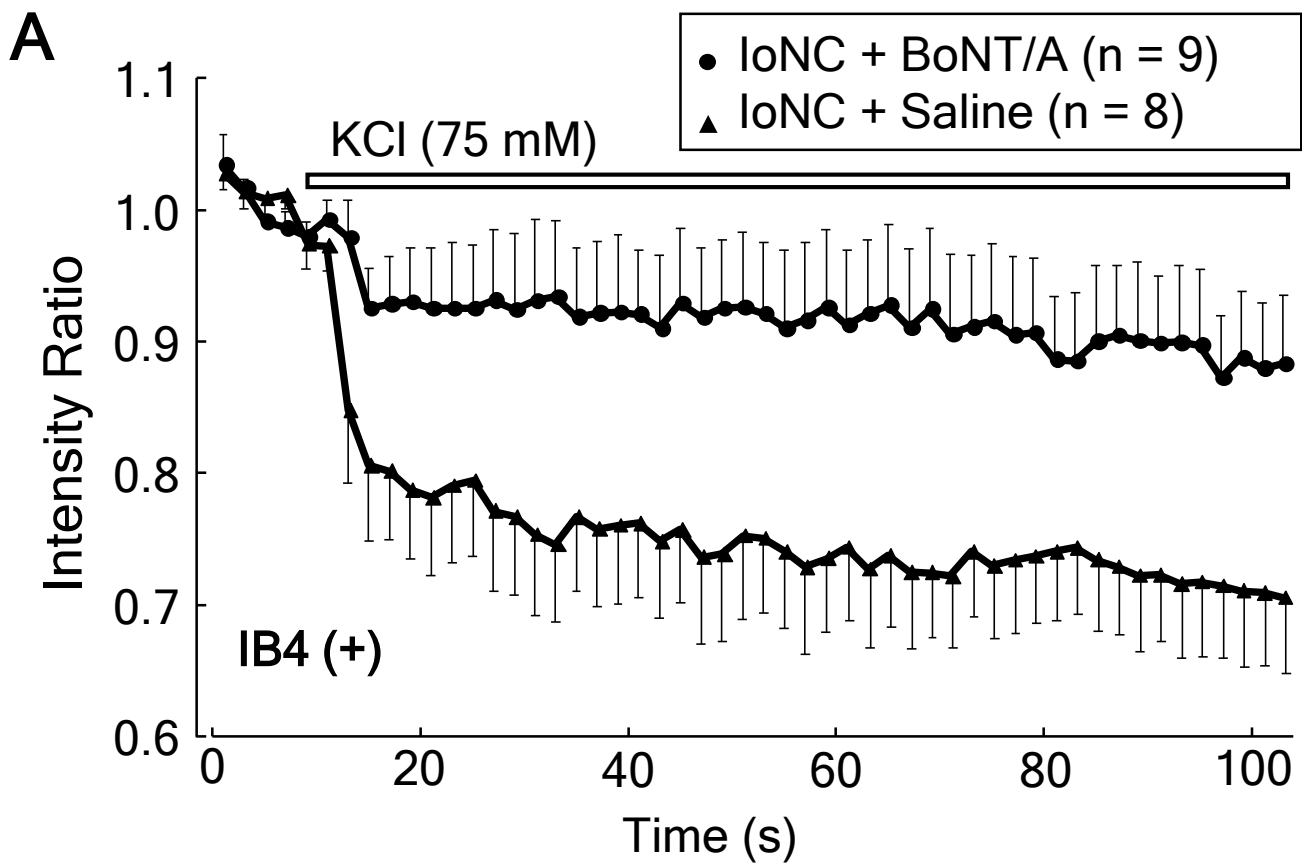


Fig. 2

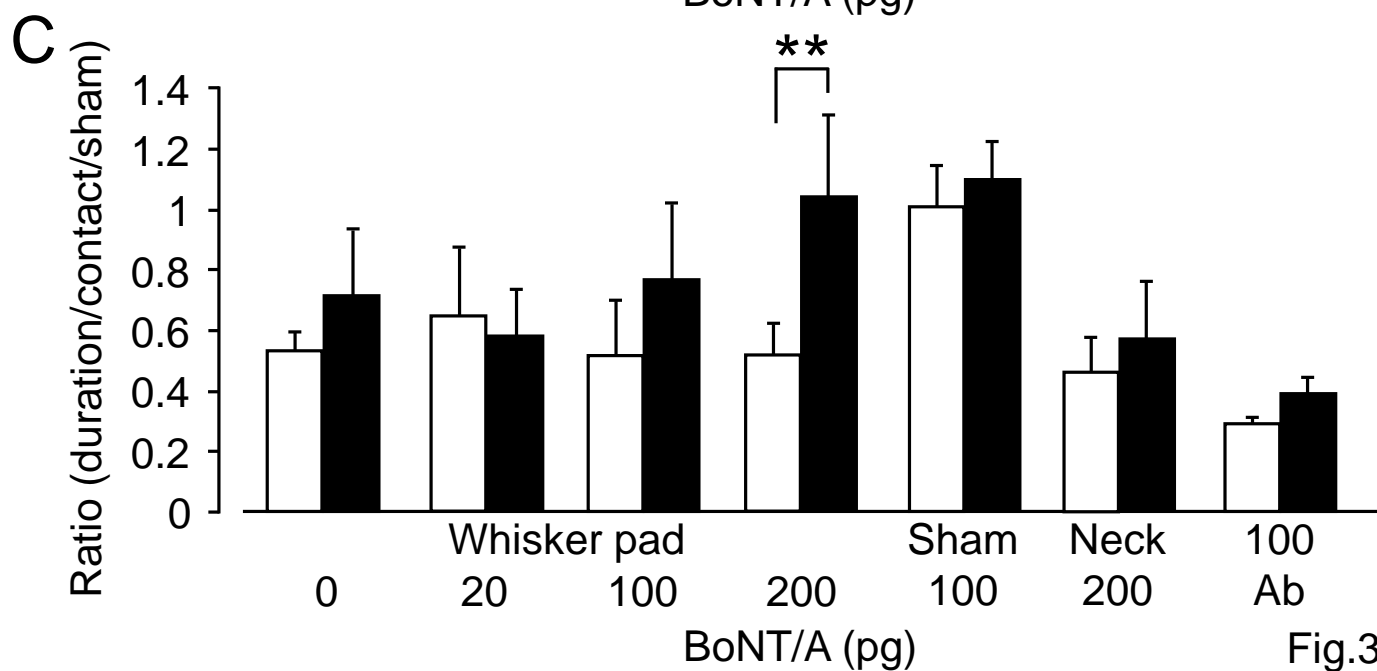
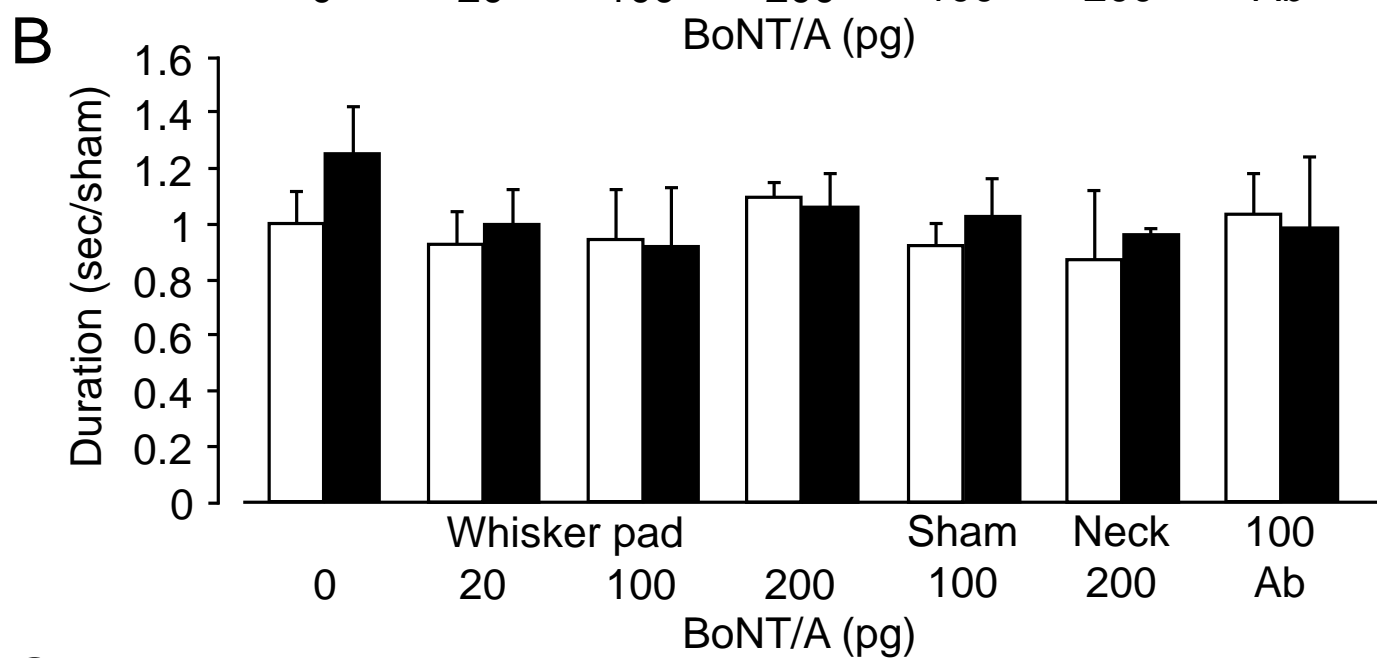
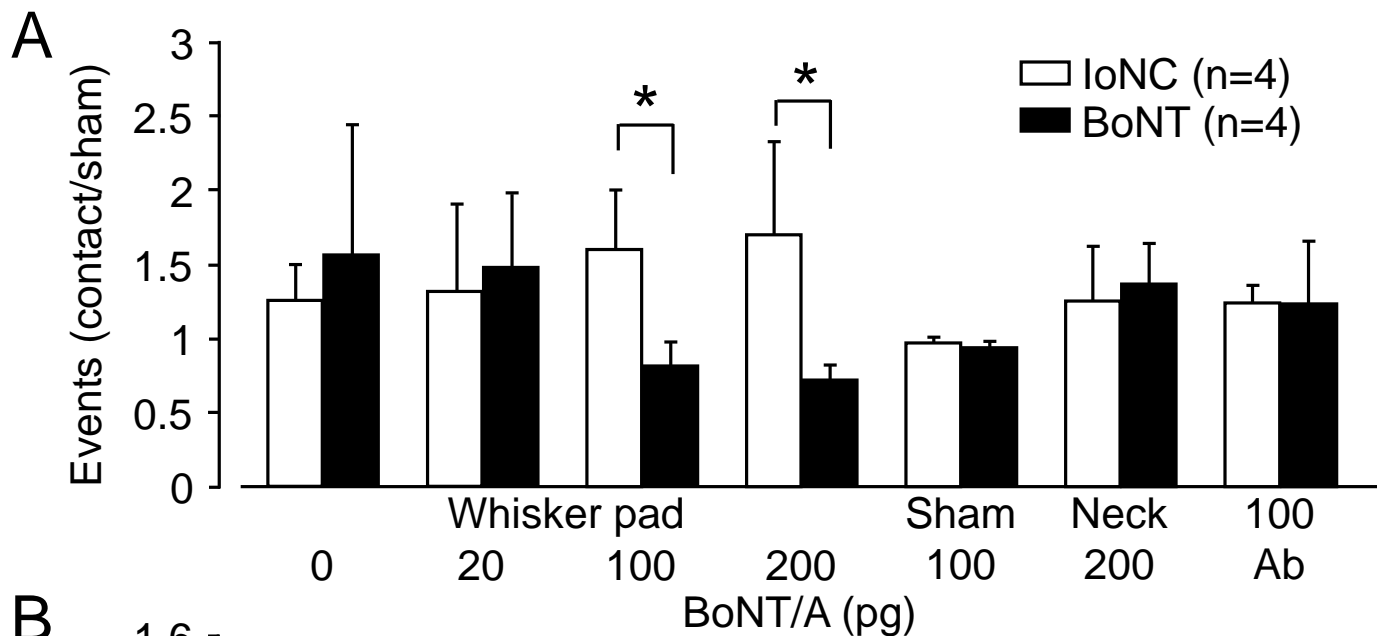
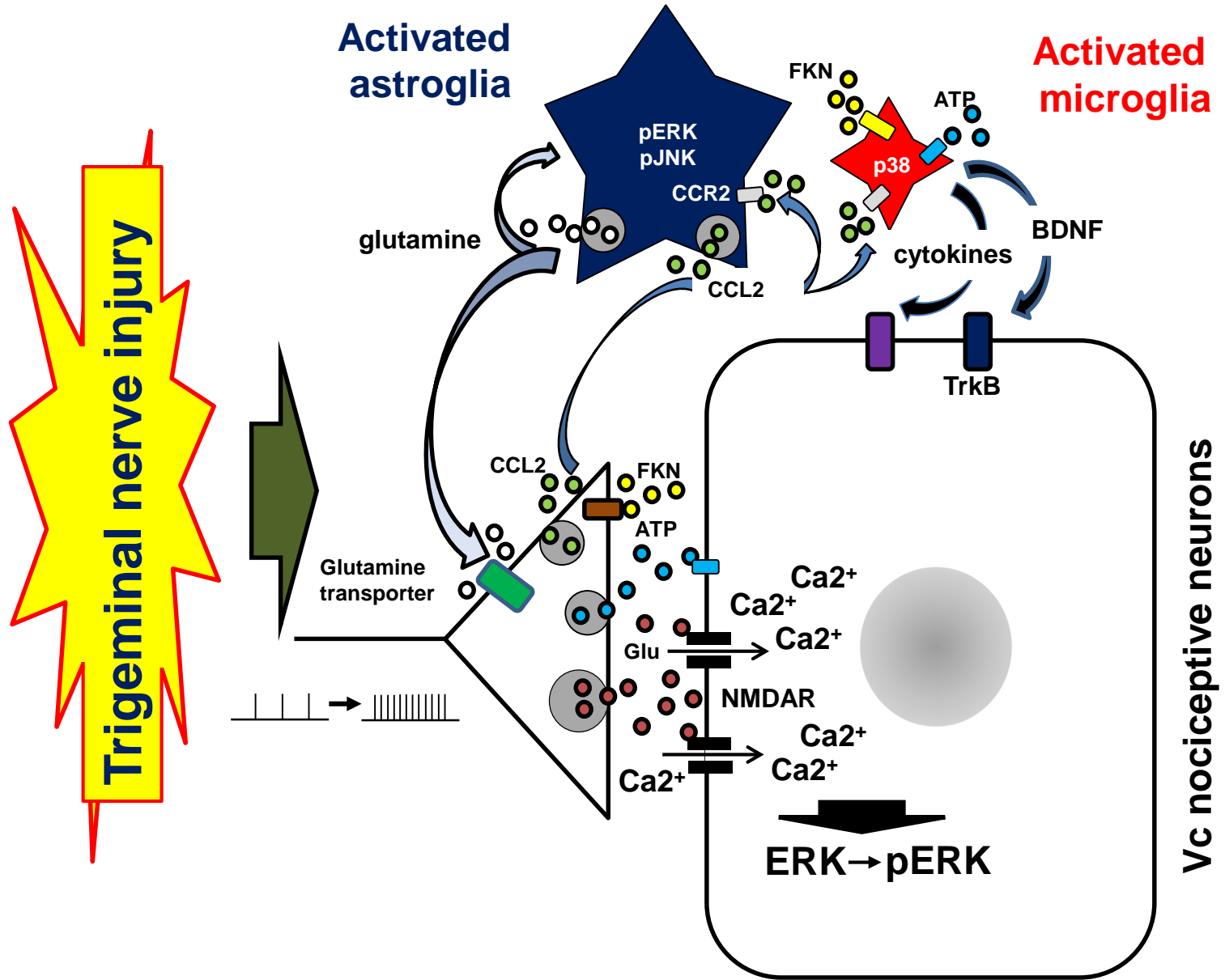


Fig.3

Fig. 4



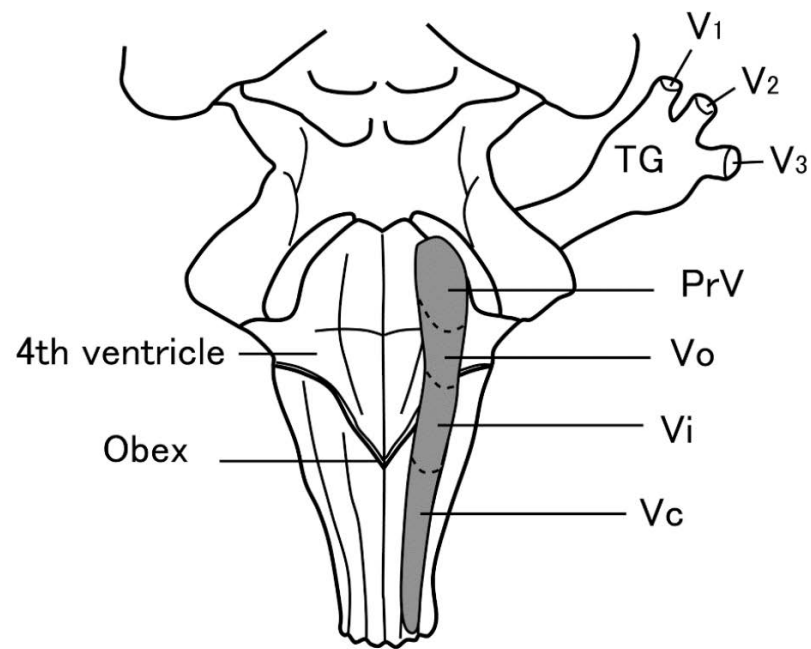


Fig. 5

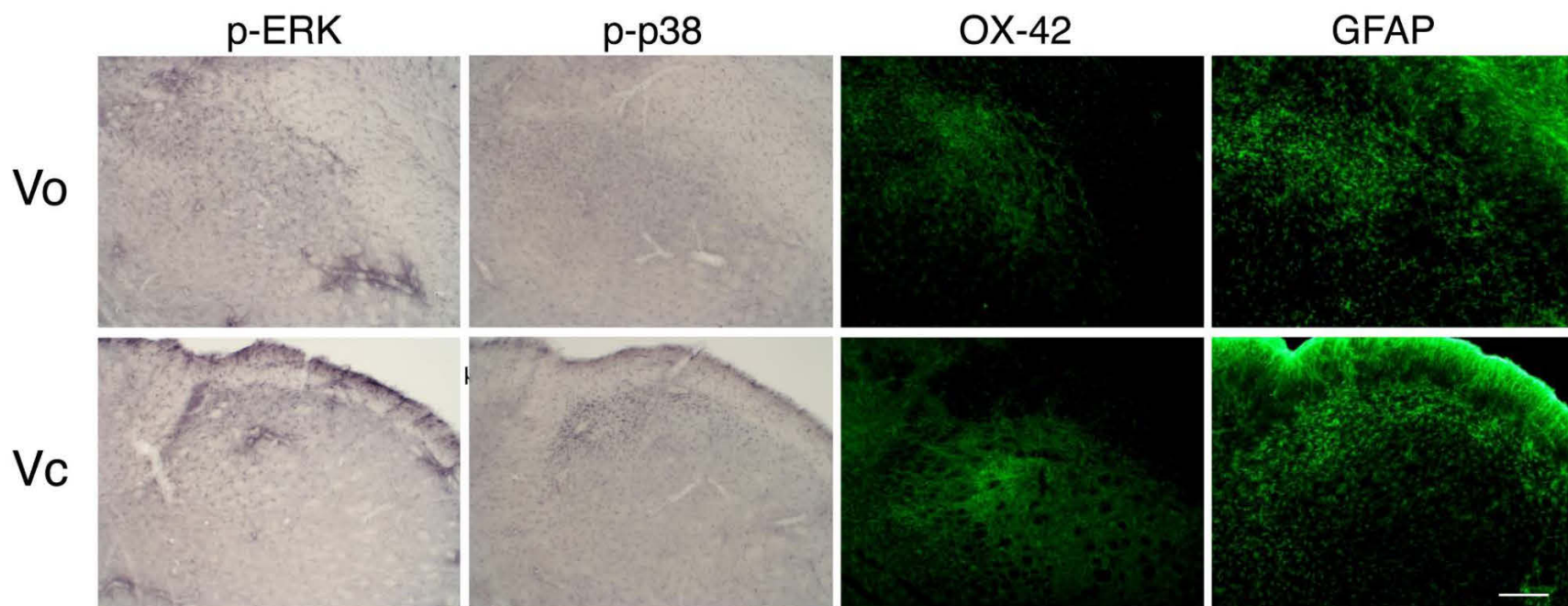


Fig. 6

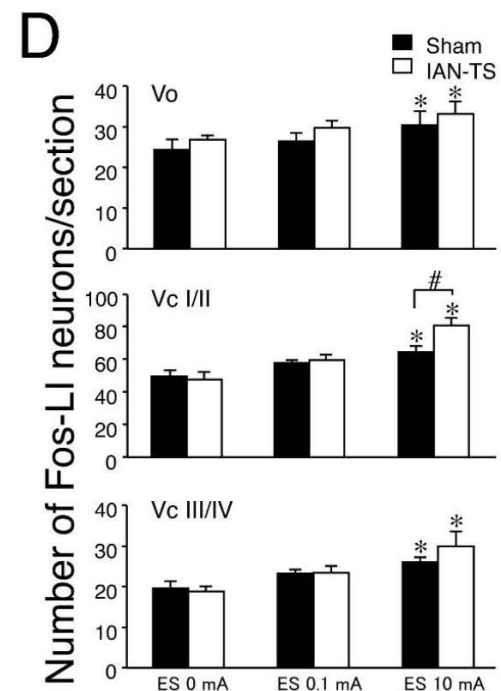
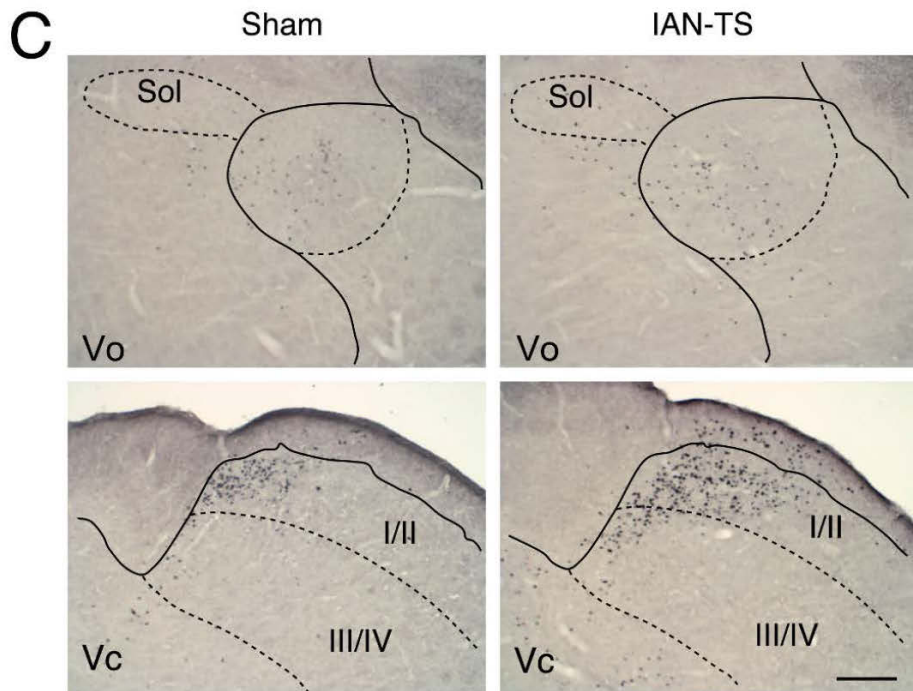
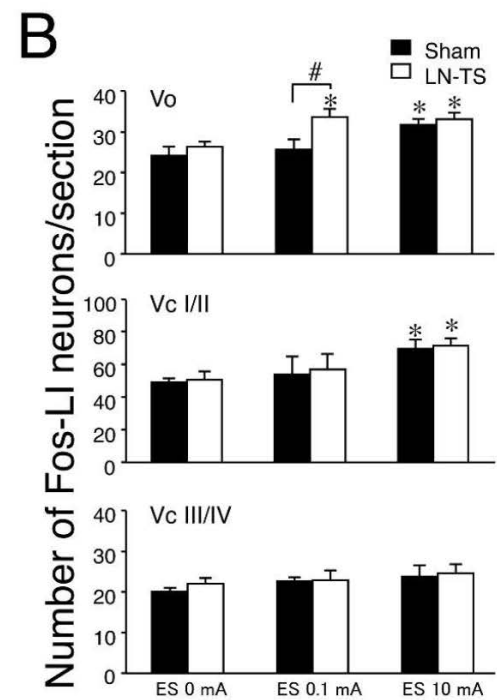
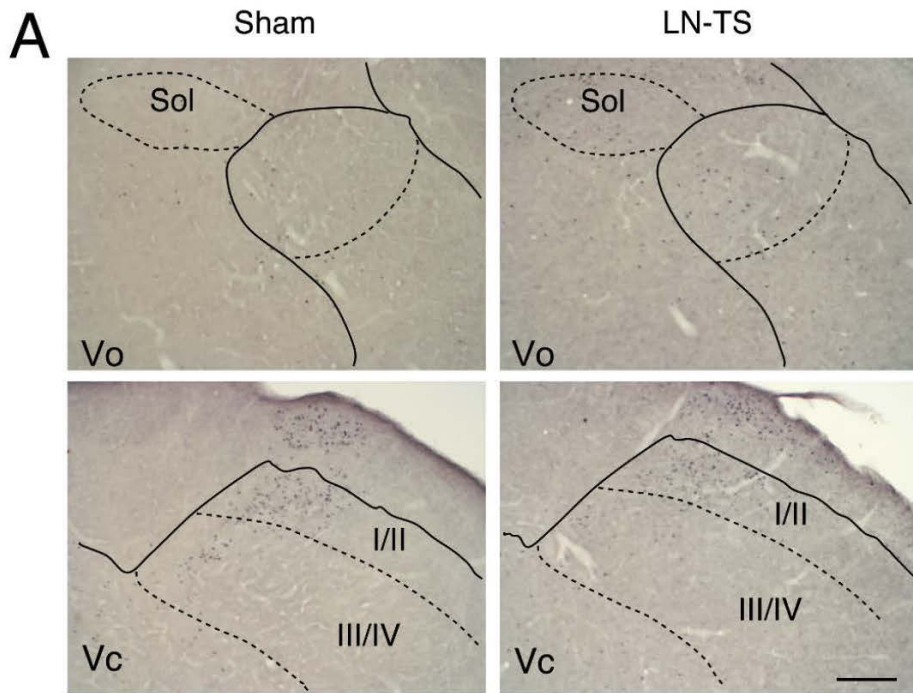


Fig. 7