

## CASE REPORT

# Repeated exacerbations of ocular inflammation with vitreous hemorrhage in a patient with HLA-B27 associated uveitis

Satoru Kase, Kenichi Namba, Yukihiro Horie, Satoshi Kotake, and Shigeaki Ohno

*Department of Ophthalmology and Visual Sciences, Hokkaido University Graduate School of Medicine, Sapporo, Japan*

**Abstract :** HLA-B27 associated uveitis is characterized by recurrent alternating acute unilateral attacks of intraocular inflammation in the anterior chamber. The aim of this study was to report an unusual case of repeated exacerbations with vitreous hemorrhage in HLA-B27 associated uveitis. Thirty four-year-old man was diagnosed as HLA-B27 associated uveitis in his right eye. He showed repeated exacerbation of ocular inflammation with retinal vein dilation and small retinal hemorrhage following vitreous hemorrhage. Fluorescein fundus angiography a week before the appearance of vitreous hemorrhage showed no neovascularization. Oral prednisolone administration was started from 40 mg/day with gradual tapering. About 3 weeks after the onset, most of the vitreous hemorrhage disappeared and visual acuity was improved to 20/20. Through the decreased vitreous hemorrhage, Weiss ring was detected later. The vitreous hemorrhage found in this patient is a severe exacerbation, and might be a consequence of the vitritis that leads to posterior vitreous detachment. *J. Med. Invest.* 54 : 350-353, August, 2007

**Keywords :** HLA-B27, uveitis, corticosteroid, vitreous hemorrhage

## INTRODUCTION

HLA-B27 associated uveitis is characterized by recurrent alternating acute unilateral attacks of intraocular inflammation in the anterior chamber (1, 2), and the intervals of them are a half year to several years. On the other hand, the reported frequencies of posterior segment involvement in HLA-B27 associated uveitis range between 0 to 25.1% (1, 3-5). The involvement was recognized as vitritis, cystoid macular edema, or papillitis. Treatment of HLA-B27 associated uveitis is mainly topical corticosteroids

and mydriatic agents, while systemic corticosteroid administration is required in 24% of the patients to control the inflammations (5).

Here we report a case of HLA-B27 associated uveitis that showed repeated exacerbations and developed retinal and vitreous hemorrhages.

## CASE REPORT

A 34-year-old man suffered from blurred vision and ocular pain in his right eye, and was treated with topical and systemic corticosteroids. However, his symptoms did not improve, and then, he was referred 2 weeks later to our hospital on December 16, 2002. His visual acuities were 14/20 OD and 20/20 OS. Intraocular pressures were 16 mmHg OD, and 14 mmHg OS. Biomicroscopy showed remarkable

---

Received for publication April 5, 2007 ; accepted June 8, 2007.

Address correspondence and reprint requests to Satoru Kase, MD, Ph.D., Department of Ophthalmology and Visual Sciences, Hokkaido University Graduate School of Medicine, N15 W7, Kita-ku, Sapporo 060-8638, Japan and Fax : +81-11-706-5948.

ciliary injection and severe inflammation in the anterior chamber with 3+ flare and 3+ cells, fibrin production and hypopyon in the right eye. Almost 360 degrees of posterior synechiae and pigmentation on the lens were noted. Fundus examination showed no particular findings at that time. The left eye was normal. Peripheral blood test detected positive for HLA-B27. From these clinical and serological findings, we diagnosed the case as HLA-B27 associated uveitis OD. Other systemic diseases associated with HLA-B27 such as ankylosing spondylitis, inflammatory bowel diseases or Reiter's syndrome (6) were not remarkable. In addition to eye drops of mydriasis and betamethazone, oral prednisolone of 40 mg/day for 3 days and 30 mg/day for 3 days was administrated. Since intraocular inflammation improved and posterior synechiae were dissolved, oral corticosteroid administration could be stopped. However, 1 week later, right fundus showed diffuse vitreous opacity and mild dilatation of retinal vessels (Fig. 1a). He was given oral prednisolone again from 40 mg/day. Fundus findings gradually improved and oral prednisolone was decreased. Hence right visual acuity was recovered to 14/20 on Janu-

ary 16, 2003. Gradually, remained vitreous opacity resolved, and the inflammation in his right eye disappeared for 2 months. However, he complained of blurred vision in his right eye again. Although inflammation in the anterior segment was minimal, fundus examination showed obvious irregular dilatation of retinal vein and several small retinal hemorrhages as well as hyperemic optic disc in the posterior pole in the right eye on March 11, 2003 (Fig. 1b). At that time although we performed fundus fluorescein angiography, leakage from vessels or neovascularization was not observed (Fig. 1c). After a week, his visual acuity suddenly decreased to 2/200 in OD, and fundus examination showed vitreous hemorrhage (Fig. 1d). In addition to topical corticosteroids, oral prednisolone was administrated again from 40 mg/day and was gradually decreased. As vitreous and retinal hemorrhages improved, visual acuity recovered to 20/20 OD on April 8, 2003. Through the decreased vitreous hemorrhage, Weiss ring upon the optic disc was detected. The summary of clinical course is shown in Fig. 2. He has had no recurrence and has kept good visual acuity until August 2006.

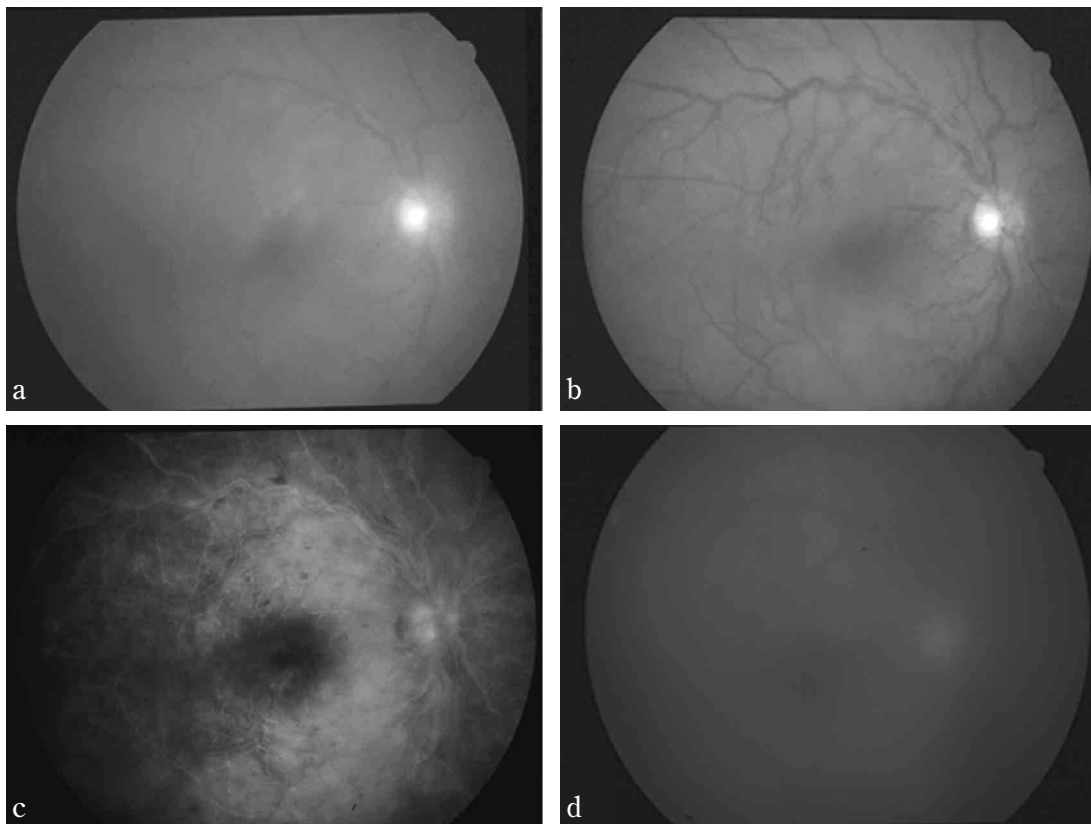


Fig. 1. Fundus examination (a, b, d) and fluorescein angiography (c) in the right eye. A week after the first discharge, diffuse vitreous opacity and mild dilatation of retinal vessels are observed on January 7, 2003 (a). Fundus examination shows obvious irregular dilatation of retinal veins, and small retinal hemorrhage as well as hyperemic optic disc in the posterior pole of right eye on March 11, 2003 : 1 week before the appearance of vitreous hemorrhage (b). At this time fundus fluorescein angiography demonstrated no leakage from vessels or neovascularization (c). Right fundus shows vitreous hemorrhage on March 17, 2003 (d).

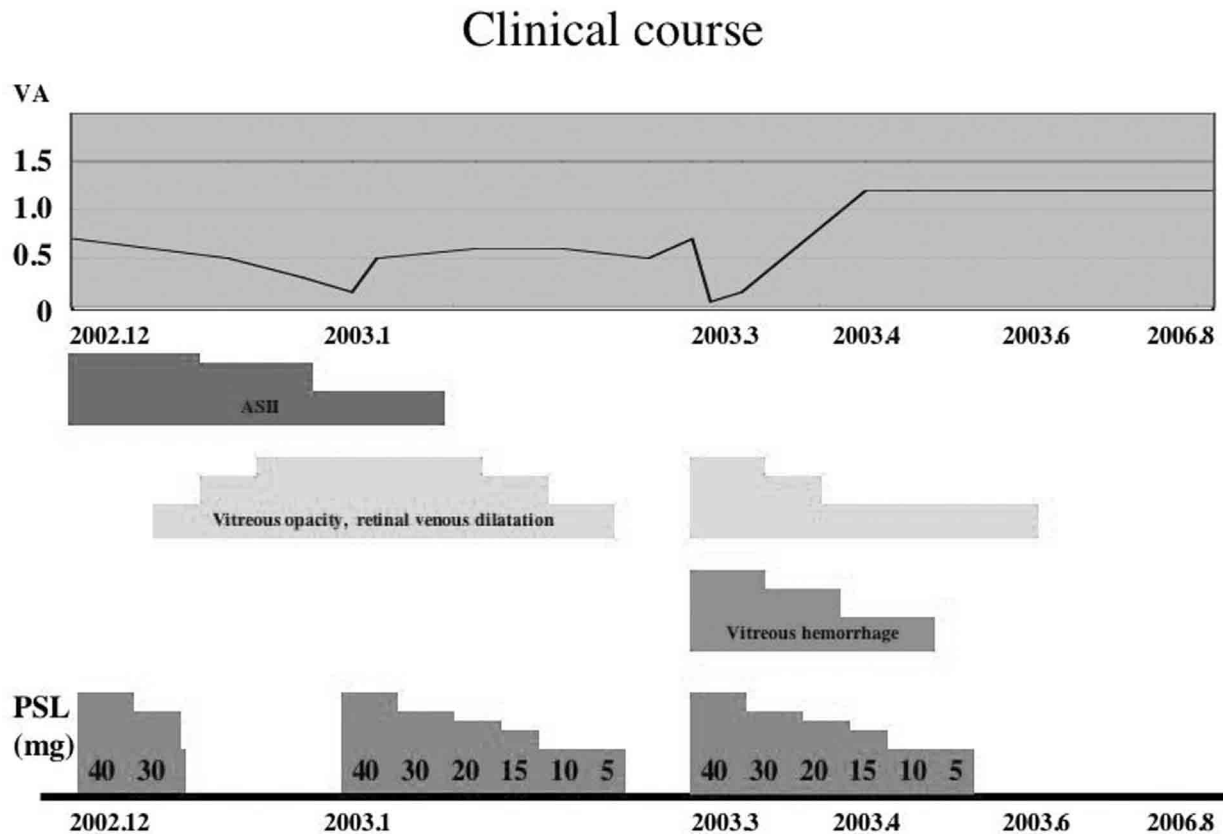


Fig. 2. Clinical course in alteration of visual acuity, anterior segment intraocular inflammation, fundus examination of his right eye, and administration of oral prednisolone is summarized. VA, visual acuity ; PSL, prednisolone ; ASII, anterior segment intraocular inflammation.

## DISCUSSION

HLA-B27 associated uveitis is characterized by younger age at onset, high male to female ratio, frequent unilateral altering eye involvement, severe ocular symptom during activity such as presence of fibrin in the anterior chamber (1). D'Alessandro, *et al.* demonstrated that HLA-B27 associated uveitis was the most common cause of hypopyon uveitis (7). Taken together, intraocular inflammation of this case showed at first visit to our hospital was consistent with previous reports in HLA-B27 associated uveitis.

HLA-B27 associated uveitis is one of the common forms in intraocular inflammation showing acute anterior uveitis (AAU) (8, 9). Recently, it is reported that the frequencies of posterior segment involvement in the uveitis rage between 0 to 25.1% (3, 5, 10, 11). It is reported that the involvement of posterior segment is recognized as vitritis, cystoid macular edema, papillitis and retinal vasculitis (5, 12) and it is suggested to occur secondary to anterior segment intraocular inflammation (3). In this case after improvement of AAU, diffuse vitreous opacity and

retinal vessel dilatation, and moreover retinal and vitreous hemorrhage were noted.

Vitreous hemorrhage is extravasated blood within the space bordered by the internal limiting membrane of the retina (13). Posterior vitreous detachment (PVD) is one of the common causes of vitreous hemorrhage (13). Weiss ring is a circular retinal grial adhesion to the optic disc, which has close association with PVD (14). In our case, before the onset of vitreous hemorrhage, right fundus showed prominent retinal vein dilatation and retinal hemorrhage, suggesting that severe exacerbation of inflammation occurred in the posterior segment. In addition, Weiss ring was detected through the vitreous hemorrhage, indicating PVD had constituted in exacerbation of inflammation. These clinical courses might have been correlated with onset of vitreous hemorrhage.

Usually recurrence happens after the intervals about a half to several years, and it must start with acute inflammation of the anterior segment. The inflammations observed during the treatments in our case involved minimal inflammations of anterior segment and severe inflammation of posterior

segment such as retinal vein dilatation, retinal hemorrhage, and hyperemic optic disc. This suggests that the repeated inflammations during the treatments in this case were exacerbation, but not recurrence. Treatment of HLA-B27 associated uveitis generally involves topical application of corticosteroid preparations to control the inflammation, and the treatment is generally effective. However, some patients with HLA-B27 associated uveitis are difficult to treat, and require systemic corticosteroid administration. In this case, systemic corticosteroid administrations were needed and repeated exacerbations occurred. Although this is not typical case of HLA-B27 associated uveitis, we should pay attention to the fact that severe exacerbation can occur even after resolving inflammation in HLA-B27 associated uveitis.

## REFERENCES

1. Rothova A, van Veenedaal WG, Linssen A, Glasius E, Kijlstra A, de Jong PT : Clinical features of acute anterior uveitis. *Am J Ophthalmol* 103 : 137-45, 1987
2. Wakefield D, Montanaro A, McCluskey P : Acute anterior uveitis and HLA-B27. *Surv Ophthalmol* 36 : 223-32, 1991
3. Rothova A : Comment on 'Posterior segment inflammation in HLA-B27+ acute anterior uveitis : clinical characteristics'. *Ocul Immunol Inflamm* 8 : 73-5, 2000
4. Tay-Kearney ML, Schwam BL, Lowder C, Dunn JP, Meisler DM, Vitale S, Jabs DA : Clinical features and associated systemic diseases of HLA-B27 uveitis. *Am J Ophthalmol* 121 : 47-56, 1996
5. Monnet D, Breban M, Hudry C, Dougados M, Brezin AP : Ophthalmic findings and frequency of extraocular manifestations in patients with HLA-B27 uveitis : a study of 175 cases. *Ophthalmology* 111 : 802-9, 2004
6. Kataria RK, Brent LH : Spondyloarthropathies. *Am Fam Physician* 69 : 2853-60, 2004
7. D'Alessandro LP, Forster DJ, Rao NA : Anterior uveitis and hypopyon. *Am J Ophthalmol* 112 : 317-21, 1991
8. Ohno S, Kimura SJ, O'Connor GR, Char DH : HLA antigens and uveitis. *Br J Ophthalmol* 61 : 62-4, 1977
9. Brewerton DA, Caffrey M, Nicholls A, Walters D, James DC : Acute anterior uveitis and HLA 27. *Lancet* 2 : 994-6, 1973
10. Dodds EM, Lowder CY, Meisler DM : Posterior segment inflammation in HLA-B27+ acute anterior uveitis : clinical characteristics. *Ocul Immunol Inflamm* 7 : 85-92, 1999
11. Rodriguez A, Akova YA, Pedroza-Seres M, Foster CS : Posterior segment ocular manifestations in patients with HLA-B27-associated uveitis. *Ophthalmology* 101 : 1267-74, 1994
12. Power WJ, Rodriguez A, Pedroza-Seres M, Foster CS : Outcomes in anterior uveitis associated with the HLA-B27 haplotype. *Ophthalmology* 105 : 1646-51, 1998
13. Spraul CW, Grossniklaus HE : Vitreous Hemorrhage. *Surv Ophthalmol* 42 : 3-39, 1997
14. Kakehashi A, Inoda S, Shimizu Y, Makino S, Shimizu H : Predictive value of floaters in the diagnosis of posterior vitreous detachment. *Am J Ophthalmol* 125 : 113-5, 1998