

REVIEW

Non-cardiac surgery applications of extracorporeal circulation

Shinji Kawahito¹, Hiroshi Kitahata¹, Tetsuya Kitagawa², Shuzo Oshita¹, and Yukihiko Nosé³

¹Department of Anesthesiology, ²Department of Cardiovascular Surgery, Institute of Health Biosciences, The University of Tokushima Graduate School, Tokushima, Japan; and ³Michael E. DeBakey, Department of Surgery, Baylor College of Medicine Houston, Texas 77030, USA

Abstract : Although the efficacy of extracorporeal circulation (ECC) is well established for open-heart surgery, application of ECC in other surgical areas has not been given much attention. Advances in the related surgical technique and anesthetic management combined with refinements in the ECC procedure itself have encouraged several institutions to use ECC for complex non-cardiac surgeries. ECC is beginning to be used for circulatory support or tissue oxygenation during surgery on the lung, brain, liver, and kidney as well as in emergency situations. With ECC, difficult and complex surgeries can be performed more safely, and the success rate of certain surgeries has been positively affected. It is important that the surgeon, anesthesiologist, and perfusionist are trained in non-cardiac surgery applications of ECC. Thus, we review here non-cardiac uses that have emerged and summarize the related procedures. *J. Med. Invest.* 54 : 200-210, August, 2007

Keywords : *extracorporeal circulation, non-cardiac surgery, lung surgery, percutaneous cardiopulmonary support system*

INTRODUCTION

The principal use of extracorporeal circulation (ECC) has been to facilitate operative procedures involving the heart. A pump and oxygenator replace the function of both the heart and lungs during surgery, and open-heart procedures usually require both. Although the efficacy of ECC in open-heart and aortic surgery is well established, application of ECC in other surgical areas has not been given much attention. Complications associated with ECC tempered the initial enthusiasm for non-cardiac appli-

cations. With time, however, a more reasoned approach to the use of ECC for noncardiovascular applications came about, and many of the early problems and complications have been overcome. ECC is beginning to be used for circulatory support or tissue oxygenation during surgery on the lung, brain, liver, and kidney as well as in emergency situations. Recent applications are shown on Table 1. This report outlines the current indications, technique, and outcome during these surgical endeavors.

APPLICATIONS IN LUNG SURGERY

Although ECC is used primarily to facilitate cardiac surgery, the lungs are also bypassed with ECC. In fact, Gibbons developed his pump oxygenator in 1937 primarily to operate on patients with pulmo-

Received for publication April 25, 2007 ; accepted May 30, 2007.

Address correspondence and reprint requests to Dr. Shinji Kawahito, Department of Anesthesiology, Institute of Health Biosciences, The University of Tokushima Graduate School, Kuramoto-cho, Tokushima 770-8503, Japan and Fax : +81-88-633-7182.

nary embolism (1). In general, ECC is not needed for lung surgery because one lung can support ventilation while the other undergoes repair. However, maintenance of ventilation may be inadequate during extensive resection of the trachea or in other special situations. When surgery is needed in this part of the pulmonary system, ECC can make it feasible. In addition, ECC is sometimes used for circulatory support during lung surgery. Applications of ECC during lung surgery are shown on Table 2.

Table 1 Applications of extracorporeal circulation

<ul style="list-style-type: none"> · Open-heart surgery · Aortic surgery · Lung surgery <ul style="list-style-type: none"> · For respiratory support · For circulatory support · Neurosurgery <ul style="list-style-type: none"> · Profound hypothermia and circulatory arrest · Liver surgery <ul style="list-style-type: none"> · Liver transplantation · Hepatectomy · Urologic surgery <ul style="list-style-type: none"> · Resection of renal cell carcinoma extending into the inferior vena cava · Other <ul style="list-style-type: none"> · Emergency use · Supported PTCA · Malignant hyperthermia · Accidental hypothermia

PTCA : percutaneous transluminal coronary angioplasty

Table 2 Applications of extracorporeal circulation during lung surgery

<ul style="list-style-type: none"> · Pulmonary embolectomy · Surgery on the lower trachea and carina <ul style="list-style-type: none"> (Tracheocarinal resection, bronchofiberscopic laser surgery, bronchial stenting, etc.) · Lung cancer, thyroid cancer, esophageal cancer, mediastinal tumor · Stenosis of the lower trachea due to old tuberculosis · Post tracheotomy stenosis, etc. · Lung transplantation · Descending aorta pathology (for circulatory support) · Severe respiratory dysfunction (for respiratory support) · Chest trauma <ul style="list-style-type: none"> · Tracheobronchial injury · Bilateral pneumothorax
--

Although midline sternotomy with cannulation of the right atrium and ascending aorta is the preferred protocol for ECC in cardiac surgery (2), certain circumstances require the institution of bypass with lower extremity access (3) - typically, femoro-femoral bypass (4, 5) (Figure 1). The access site depends primarily on the planned surgery, but femoro-femoral bypass is used more often for ECC in case of non-cardiac surgery (particularly lung surgery) than for ECC in cardiac cases.

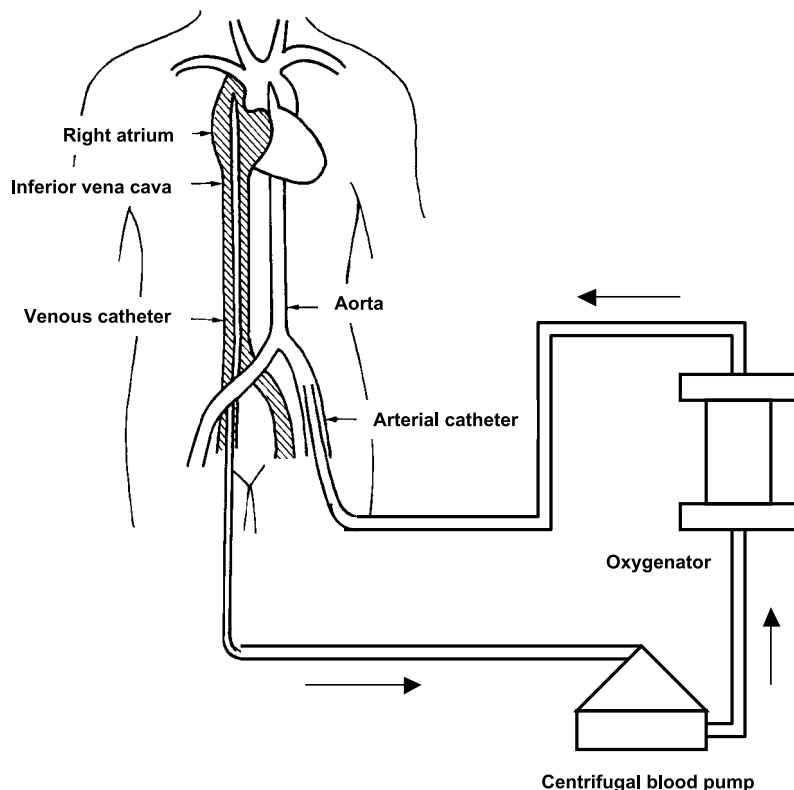


Figure 1. Veno-arterial bypass system consisting of a centrifugal blood pump and a hollow fiber membrane oxygenator. The venous catheter is inserted into the inferior vena cava through a femoral vein with the femoral artery serving as the inflow vessel.

Pulmonary embolectomy

A major contribution of ECC in the field of lung surgery has been in whole body perfusion during pulmonary embolectomy. It was the lack of a rapid effective treatment for moribund patients with pulmonary embolus that led Gibbons (1) to begin his pioneering work with ECC. Gibbons himself was never able to treat such patients, but in 1961, Cooley, *et al.* (6) performed emergency ECC in a patient with a massive pulmonary embolus. In 1966, Rosenberg, *et al.* (7) reviewed cases in which ECC was used for pulmonary embolectomy and made several recommendations. They concluded that if pulmonary embolectomy was to be successful, resection had to be attempted within 2 hours of embolization.

It has been reported that the success rate of embolectomy was only 33% for long-term survival (8). However, many researchers concluded ECC to be necessary because the mortality rate would otherwise have been 100% without it. Garcia, *et al.* (9), recognizing the importance of early ECC for resuscitating patients, advocated partial bypass for resuscitation, and in a combined approach, they used total bypass for resection of the pulmonary embolus. Some centers have later reported very good (84%) survival rates (10). Pulmonary catheter embolectomy without ECC is a new technique that has been advocated for managing critically ill pulmonary embolism patients, but its utility is still being investigated (11).

Surgery on the lower trachea and carina

Surgery on the lower trachea involving the carina presents special problems in maintaining a patient airway and airtight seal for adequate ventilation. Currently, use of ECC is not routine for carinal or tracheal lesions. Repairs can be performed in most cases without ECC. The current treatment strategy for tracheal and carinal pathologies was pioneered by Grillo, *et al.* at Massachusetts General Hospital. They reported in 1969, 31 patients who had undergone tracheal resection during a 7-year period in which bypass was not utilized (12). For tracheal lesions, anesthesia is induced, an oral endotracheal tube is placed, the chest is opened, and the trachea is transected distally; the distal tracheal segment is later intubated from within the operating field. The tracheal lesion can then be resected and the trachea reanastomosed. For more distal lesions, including lesions of the carina, Grillo, *et al.* advocated intubating one of the main bronchi from within

the operative field, with obstruction of the contralateral pulmonary artery to optimize ventilation and perfusion during resection of the carinal lesion. High frequency jet ventilation is also often used (13, 14). However, because distal airway obstruction can occur following induction of general anesthesia, ECC should be considered as a viable alternative for patients at increased risk for this complication.

Many researchers have reported ECC management of this complication (15-20). The first case in which ECC was used for resection of the carina and both main-stem bronchi for bronchial adenoma was reported by Woods, *et al.* in 1961 (15). ECC was considered the only means to achieve satisfactory plastic repair of the excised carina. This was also the first report of the use of ECC in lung surgery. Nissen (16) used bypass combined with hypothermia to aid in the resection of a malignant tracheal adenoma. In the third case, reported in 1964 by Adkins and Izawa (17), a cylindroma was resected under bypass. Soon after, Neville, *et al.* reported 14 surgeries under ECC that involved trachea, carina, or major bronchi (18). Depending on the location of the tumor, they used either a right, left, or anterior thoracotomy. They cannulated the superior vena cava from the right atrium, drained the inferior vena cava via femoral venous cannula, and returned the arterialized blood via cannula in the femoral artery. After these reports, several similar surgeries were performed (19, 20). In 1983, the first report was published on a percutaneous cannula, pump, and oxygenator system; the percutaneous cardiopulmonary support (PCPS) system (21). Almost all surgeons now use femoro-femoral ECC during surgery on the lower trachea and carina (22, 23). A right posterolateral or bilateral anterior thoracotomy is used for resection of the trachea and for removal of the carina. The tracheobronchial tree is completely mobilized, and the pulmonary vessels are divided prior to heparinization. Following mobilization of the lung and its intrinsic architecture or isolation of the descending aorta proximal and distal to the lesion, the patient is heparinized and connected to the oxygenator via catheter inserted into the femoral artery and into the inferior vena cava from the femoral vein.

A technically interesting report was provided in 1996 by Horita, *et al.* (24), who used veno-venous bypass with an oxygenator via a percutaneous femoral venous approach to undertake carinal reconstruction. These authors placed bilateral femoral venous cannulas and interposed a centrifugal pump and oxygenator. This was accomplished with partial heparini-

zation to maintain an activated clotting time of greater than 250 seconds.

ECC is also used when maintaining the upper airway is difficult. Two situations are call for ECC (especially PCPS) : difficulty in endotracheal intubation and difficulty in maintaining the upper respiratory tract after the intubation. Bronchial fiberoptic laser surgery and bronchial stenting for the treatment of tracheal stenosis or obstruction also sometimes require PCPS. Many researchers emphasize the importance of having the PCPS machine primed and readied and the patient's groin prepared before such procedures (15-17). If the patient's airway becomes obstructed during the induction of general anesthesia because of an intratracheal tumor, PCPS can be instituted immediately.

Lung transplantation

Single-lung transplantation is most frequently performed with the donor lung transplanted into the recipient's right chest. This can be achieved most of the time without ECC. During resection of the native lung, the contralateral lung is ventilated via endotracheal tube inserted from within the operative field while the donor lung is implanted in the chest and the pulmonary artery is anastomosed. In some patients, however, it is impossible to provide adequate gas exchange with one lung because of underlying disease in the nonoperative lung. Currently, no good preoperative test is available to predict which patients with obstructive lung disease will require ECC.

Preoperative prediction is possible, however, for patients with restrictive lung disease. On the basis of exercise tolerance and right ventricular ejection fraction, it is possible to know which patients will require intraoperative ECC (25). When ECC is used, insertion of the arterial and venous cannulas is usually through the groin, with the chest kept free of cannulas for the sake of the transplant surgeon (26) ; however, many surgeons prefer a standard approach with the cannulas in the vena cava and aortic root.

Descending aorta pathology : Lung cancer with extension into the heart and the great vessels

Surgery for lung cancer or mediastinal tumor that includes resection of the descending aorta is a good application for ECC circulatory support. Left pneumonectomy and resection of the descending aorta can be performed with ECC alone. There is also a report of removal of a lung sarcoma with extension

into the left atrium that was successfully managed with ECC (27).

Severe respiratory dysfunction during lung surgery

For the patient with severe preoperative respiratory dysfunction and the patient for whom severe respiratory failure is expected intraoperatively, ECC is sometimes used for respiratory support. Patients undergoing further lung surgery after contralateral total lung resection, patients undergoing lung surgery who have old tuberculosis in the opposite lung, and patients with severe emphysema are included in this category.

Chest trauma

Injuries to the various intrathoracic structures play a major role in morbidity and mortality related to chest trauma (28). Most chest injuries, including wounds to the heart and the aorta, can be repaired without the aid of ECC. However, a few injuries of the heart, the great vessels, and occasionally, the major airway call for some form of ECC support. Femoral ECC has been used for traumatic tracheal disruption (29). Patients requiring ECC are usually those who have suffered complex or extensive longitudinal tracheal rupture, and no other form of adequate ventilatory and/or circulatory support can be provided during the repair for them (30). In addition, bilateral pneumothorax, severe barotrauma, and severe air leak require ECC to avoid positive pressure ventilation. Therefore, when it is difficult to provide adequate ventilation or circulatory support to patients during repair of airway injury, ECC should be used.

APPLICATIONS IN NEUROSURGERY

The introduction of profound hypothermia and circulatory arrest into complex neurosurgical procedures coincided with the refinement of this procedure in patients undergoing congenital cardiac or aortic arch repair. ECC with profound hypothermia and circulatory arrest became the preferred approach to repairing a number of neurovascular abnormalities. ECC is used to induce profound hypothermia so that circulatory arrest can be instituted. This provides a bloodless surgical field for the repair of vascular abnormalities such as intracranial aneurysm and for resection of intracranial tumors. The use of profound hypothermia and circulatory arrest in a neurosurgery case was described initially in 1960

by Woodhall, *et al.* (31). Circulatory arrest of 10 minutes at 4°C was used to facilitate drainage of a large subcortical tumor cyst in a 39-year-old man with metastatic carcinoma of the lung. Cannulation for pulmonary bypass was via the femoral artery and jugular vein. The patient recovered uneventfully from the procedure yet succumbed to the pulmonary disease about 3 months later. Over the next several years, a number of studies evaluating this method for intracranial surgery were published (32-34).

The decrease in cerebral oxygen consumption afforded by profound hypothermia induced with pump oxygenator bloodstream cooling permits total circulatory arrest for removal of complicated intracerebral disease in bloodless field. Use of hypothermia in intracranial surgery is based upon the premise that lowering of the cerebral oxygen metabolism rate of neuronal tissue by decreasing body temperature confers a measure of protection against cerebral ischemia. The cerebral oxygen metabolism rate in humans is reduced to 50% of normal at 30°C, 15% of normal at 20°C and to less than 10% of normal at 15°C (35). Several studies have demonstrated the protective effect of profound hypothermia in the face of cerebral ischemia (32).

When further intracranial surgery is not feasible under conditions of spontaneous circulation, femoral venous and artery cannulations are performed. Partial bypass is initiated, and cooling is begun at a rate of 0.2°C/min. Ventricular fibrillation will occur when core temperature is between 23°C and 27°C. Potassium chloride may be given in 20 mEq boluses to achieve cardiac standstill. When the brain temperature reaches 16°C to 18°C, the pump is stopped. During circulatory arrest, mobilization of the aneurysm is completed, and ligation, clipping, or aneurysmectomy is performed.

Advances in the last decade in the anesthetic management of neurosurgery patients combined with refinements in ECC techniques have encouraged several centers to re-evaluate the use of deep hypothermia and circulatory arrest in the treatment of selected complex intracranial lesions. Williams (36) treated 10 patients with complex intracranial pathologies; i.e., aneurysm, arteriovenous malformation, glomus jugular tumor, and a cerebellar hemangioblastoma judged inoperable by conventional methods. Eight of the 10 patients achieved an excellent outcome. Solomon (37) reviewed 14 patients operated on for giant anterior or posterior circulation aneurysm. There were no operative deaths in this series. Later, many researchers have reported

good or excellent outcomes (38-40). The majority of the more recent reports suggest that a core temperature of 15°C will provide up to 60 min of safe ischemia time during circulatory arrest.

APPLICATIONS IN LIVER SURGERY

Veno-venous bypass can also be used in the management of some liver surgeries, most frequently liver transplantation during the anhepatic phase and combined resection of the liver or kidney and vena cava. Veno-venous bypass re-establishes blood return between the surgically obstructed vena cava and portal vein to the central venous circulation via the axillary vein. The circuit is composed of drainage cannula in the obstructed vessels (blood drained by gravity) and a centrifugal pump that pumps blood into the axillary vein via the return cannula.

Liver transplantation

Every year, many patients die of liver failure. For some patients, liver transplantation is a viable and life-saving option. The principal use of veno-venous bypass is in certain cases of hepatic transplantation; the majority of liver transplant centers have utilized veno-venous bypass for many years (41-48).

The phase of surgery during which mobilization and removal of the native liver occurs and the anhepatic phase remain the most crucial periods in the transplantation procedure. During these periods, surgical obstruction of the inferior vena cava and portal vein is necessary. The subsequent interruption of venous return to the heart is often associated with an up to 50% reduction in cardiac output and marked increase in systemic vascular resistance (41). In an attempt to maintain closer to normal hemodynamics during the anhepatic phase, Calne, *et al.* (42) first used partial ECC. Incorporation of veno-venous bypass during liver transplantation allows for maintenance of venous return and cardiac filling pressures during inferior vena cava occlusion. Additionally, veno-venous bypass may be especially useful in elderly patients with cholelithiasis and pulmonary hypertension, since this group is particularly prone to hemodynamic instability with caval occlusion (43).

Renal function is also compromised during the anhepatic phase of liver transplantation. Caval occlusion results in decreased systemic arterial blood pressure and in elevation of renal venous pressure (44). Because veno-venous bypass improves renal

blood flow by maintenance of an adequate preload, cardiac output, and normal renal vein pressure, some believe that the use of bypass will reduce the incidence of postoperative renal dysfunction (45). Further benefits of veno-venous bypass include safe extension of the venous occlusion period during more complicated procedures and in training situations. Veno-venous bypass has been suggested also to result in decreased intraoperative blood loss.

Hepatectomy

ECC is indicated for combined hepatic and vena caval resection (49-53). It is often impossible to isolate the liver and achieve acceptable cancer-free margins without resecting the inferior vena cava, and it is difficult to maintain arterial blood pressure without ECC. During combined liver and vena caval resection, decompression of the portal system is not necessary. Cross-clamp time is usually only 15 to 30 min, and it would be unusual for the bowel and mesentery not to tolerate venous outflow obstruction for this brief period. It is necessary, however, to shunt the lower systemic circulation. In these circumstances, the systemic circulation is drained via inferior vena cava catheter, and the venous effluent is returned to the patient by internal jugular cannula.

APPLICATIONS IN UROLOGIC SURGERY

The surgical treatment of renal cell tumors with intracardiac and intravenacaval tumor thrombi is very difficult and requires temporary adjuncts to prevent both ischemia of the visceral organs and pulmonary thrombi during tumor extirpation. For protecting of the visceral organs from ischemia, ECC is usually used. It has been recognized for some time that patients with renal cell carcinoma extending into the inferior vena cava have a poor prognosis, but if the tumor can be resected in its entirety, the prognosis is improved.

Tongaonker, *et al.* (54) reported 4 types of renal cell carcinoma extending into the inferior vena cava: the renal vein thrombus, the intrahepatic intravenacaval thrombus, the retrohepatic intravenacaval thrombus, and the suprahepatic intravenacaval thrombus. Surgery and ECC methods differ between these 4 types. The main indication for ECC in urologic surgery is resection of renal tumors, primarily renal cell carcinoma or hypernephroma that extends into the inferior vena cava superiorly past the dia-

phragm. Tumors not extending above the diaphragm or into the right atrium can frequently be resected by surgical methods not requiring bypass. Depending on the extent of the tumor, veno-venous bypass can occasionally be used to shunt blood from the inferior to the superior vena cava. Veno-venous bypass with a centrifugal pump or partial cardiopulmonary bypass with femoral arterial and venous cannulation is used. ECC is necessary to open the right atrium for the resection of intra-atrial tumor thrombi. Although a more conservative surgery is desirable for the removal of tumor thrombi, hepatic mobilization is necessary for venous clamping of the suprahepatic vena cava in cases requiring veno-venous bypass or partial cardiopulmonary bypass via femoro-femoral cannulation. Hepatic mobilization and taping of the inferior vena cava is very dangerous in cases with tumor thrombi in the intrahepatic or suprahepatic vena cava. Some institutions use deep hypothermia and circulatory arrest.

Marshall, *et al.* (55) in 1970 used passive veno-venous bypass to manage a patient with renal cell carcinoma extending into the inferior vena cava and right atrium. The need for a shunt that could drain blood from the lower extremities and portal system was obvious in the 1960s, but the first clinical trials of bypass without a pump for patients with liver disease were unsuccessful. The second report of bypass used in urologic surgery was of a patient with a right atrial tumor (56). After that, several instances were reported in which ECC was used during resection of renal cell carcinoma extending into the right atrium (57-60).

OTHER APPLICATIONS

There are a number of unusual conditions for which the use of bypass may be beneficial during treatment. Broad categories of use of emergency ECC (PCPS) include assisted interventions in the catheterization laboratory and resuscitation of patients with cardiac arrest, severe hypothermia, pulmonary embolism, or multiple trauma.

Emergency use

Emergency cardiopulmonary support has been used as a resuscitative adjunct in several reported groups of patients. Traditional ECC involves a well-planned major surgical intervention. Emergency supportive PCPS via the femoral artery and veins is also an accepted technique. Percutaneous cannulas can

be placed rapidly by the Seldinger technique, provide adequate systemic flow and venous drainage to decompress the heart. Commercial compact portable bypass systems (Figure 2) have been developed that use centrifugal pumps without venous reservoirs. The first percutaneous use of ECC was described by Phillips, *et al.* (21) in 1983. PCPS is now widely used for resuscitation (61, 62). Many indications, such as pulmonary embolism, multiple trauma (including cardiac wounds, aortic wounds, or major airway injuries), severe exposure hypothermia, and malignant hyperthermia, have been reported. Regarding pulmonary embolism and multiple trauma, they were described at the previous section in detail. Needless to say, earlier initiation of PCPS is the only way to rescue these patients.

Percutaneous transluminal coronary angioplasty (PTCA)

Kanter, *et al.* (63) incorporated PCPS as a resuscitative tool into the catheterization laboratory in 1988. After that, many researchers reported PCPS as an adjunct measure in interventional cardiology procedures such as cardiac catheterization and angioplasty. The National Registry for Supported Angioplasty began accumulating data in 1988 on patients undergoing elective supported angioplasty; the database now includes patients given standby supported PTCA (64), and data was published in 1994 for 801 enrolled patients (65).

Malignant hyperthermia

Before the clinical use of dantrolene, malignant hyperthermia was treated with support therapies including hyperventilation and systemic cooling of

the patient. In one case in which such maneuvers were unsuccessful, ECC with hypothermia was successfully instituted via a femoro-femoral approach (66).

Accidental hypothermia

ECC with active rewarming has been used to salvage patients with severe hypothermia secondary to environmental exposure. Because many of these patients die as a result of ventricular dysrhythmia or circulatory collapse, ECC is an attractive rewarming method. In 1967, Kugelberg, *et al.* (67) described the management of a patient who arrived at their hospital with a core body temperature of 21.7°C. Because of concerns about gradually warming the patient and the risk of cardiac arrest resulting from ventricular fibrillation, the authors rewarmed the patient rapidly under bypass in which a heart exchanger and oxygenator were used. Cannulation was via the left femoral artery and vein. The patient was successfully rewarmed without development of ventricular fibrillation.

Several reported studies have examined the use of ECC in accidental hypothermia. Hauty, *et al.* (68) reported 11 patients that were admitted to the hospital emergency department profoundly hypothermic; 10 were warmed via bypass, and there were 2 long-term survivors. The rapid femoral cannulation techniques should lead to greater utilization and easier application of ECC in this type of patient (69).

COMPLICATIONS

Patients undergoing ECC for non-cardiac appli-

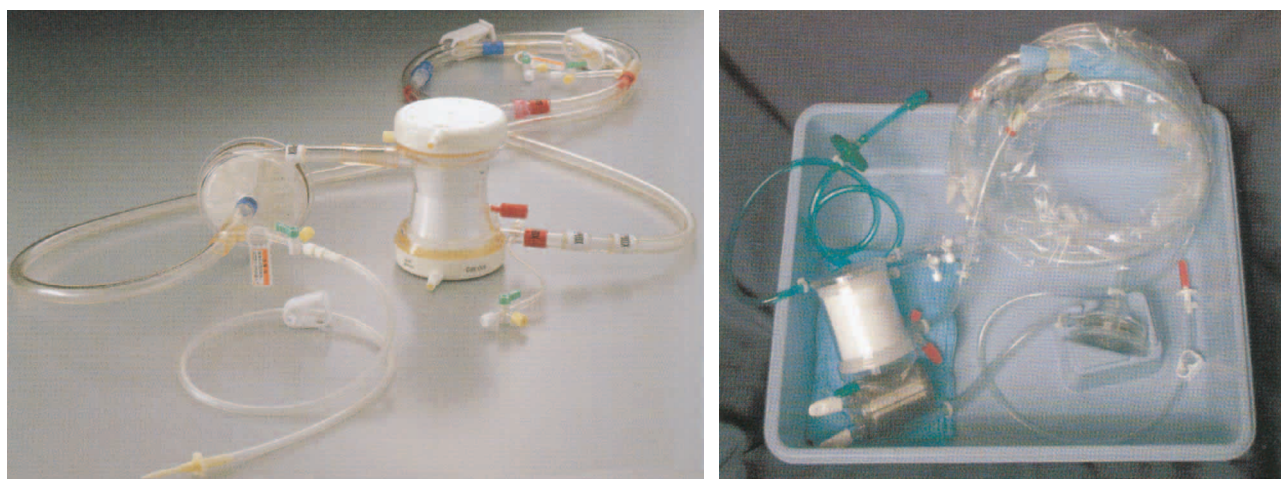

Figure 2. Commercial compact portable bypass systems
 Left : Capiox[®] Emergency Bypass System (EBS) (Terumo Inc., Tokyo, Japan)
 Right : Carmeda[®] Closed Chest Support System (CCSS) (Medtronic Cardiopulmonary Division, Anaheim, CA)

cations experience similar complications to those of cardiac surgical patients. Neurologic, pulmonary, renal, gastrointestinal, cardiac, bleeding, immunologic, and infectious complications are probably as prevalent in the non-cardiac populations as in the "traditional" patient population. Also, the use of femoral arterial cannulation adds the potential for hypoperfusion, dissection of the great arteries, and vascular or neurologic injury to the lower extremity (70).

CONCLUSION

Success with ECC for repair of cardiac anomalies has stimulated consideration of its potential for assisting with the surgical management of other disease conditions. The use of ECC in selected high-risk patients may provide for safe treatment of complex non-cardiac lesions that could not otherwise be approached. The use of ECC during non-cardiac surgery is expanding rapidly because of its increasing availability. Despite the fact that mortality rates have been high in non-cardiac surgery patients treated under ECC, all had conditions that would have been inevitably fatal without surgery. In no instance was the incorporation of ECC responsible for the death of a patient. In fact, without ECC adequate extirpation of the disease could not have been accomplished. It is important that the surgeon, anesthesiologist, and perfusionist have adequate experience in the use of these techniques, which is frequently gained in the application of ECC during non-cardiac procedures. A well-trained, experienced, and knowledgeable team significantly improves patient outcome.

REFERENCES

- Gibbons JH Jr : Artificial maintenance of circulation during experimental occlusion of pulmonary artery. *Arch Surg* 34 : 1105-1131, 1937
- Serry C, Najafi H, Dye WS, Javid H, Hunter JA, Goldin MD : Superiority of aortic over femoral cannulation for cardiopulmonary bypass, with specific attention to lower extremity neuropathy. *J Cardiovasc Surg* 19 : 277-279, 1978
- Berger RL, Barsamian EM : Iliac or femoral vein-to-artery total cardiopulmonary bypass. An experimental and clinical study. *Ann Thorac Surg* 2 : 281-289, 1966
- Berger RL, Saini VK, Dargan EL : Clinical applications of femoral vein-to-artery cannulation for mechanical cardiopulmonary support and bypass. *Ann Thorac Surg* 15 : 163-169, 1973
- Smith CR, Getrajdman GI, Hsu DT : Venous cannulation for high-flow femorofemoral bypass. *Ann Thorac Surg* 49 : 674-675, 1990
- Cooley DA, Beall AC Jr, Alexander JK : Acute massive pulmonary embolism : successful surgical treatment using temporary cardiopulmonary bypass. *JAMA* 177 : 283-286, 1961
- Rosenberg DML, Schmidt R, Warren S, Cohen S, Stern F : Partial circulatory support in massive pulmonary embolism. *Ann Thorac Surg* 2 : 217-225, 1966
- Beall AC Jr, Cooley DA : Use of cardiopulmonary bypass for resuscitation and treatment of acute massive pulmonary embolism. *Pacific Med Surg* 75 : 67-70, 1967
- Garcia JB, Barankay A, Grimshaw VA, Deac R, Ionescu MI, Wooler GH : Pulmonary embolectomy using heart-lung bypass. Report of successful case. *J Cardiovasc Surg* 10 : 165-171, 1969
- Kieny R, Charpentier A, Kieny MT : What is the place of pulmonary embolectomy today? *J Cardiovasc Surg* 32 : 549-554, 1991
- Schmitz-Rode T, Janssens U, Schild HH, Basche S, Hanrath P, Günther RW : Fragmentation of massive pulmonary embolism using a pigtail rotation catheter. *Chest* 114 : 1427-1436, 1998
- Geffin B, Bland J, Grillo HC : Anesthetic management of tracheal resection and reconstruction. *Anesth Analg* 48 : 884-890, 1969
- El-Baz N, Jensik R, Faber LP, Faro RS : One-lung high-frequency ventilation for tracheoplasty and bronchoplasty : a new technique. *Ann Thorac Surg* 34 : 564-571, 1982
- Kawahito S, Kitahata H, Tanaka K, Nozaki J, Oshita S : Transesophageal echocardiographic assessment of pulmonary arterial and venous flow during high-frequency jet ventilation. *J Clin Anesth* 12 : 308-314, 2000
- Woods FM, Neptune WB, Palatchi A : Resection of the carina and main-stem bronchi with the use of extracorporeal circulation. *N Eng J Med* 264 : 492-494, 1961
- Nissen VR : Extrakorporelle zirkulation für langdauernde (30 minuten) Atemunterbrechung zur operation bifurkationsnaher trachealgeschwülste. *Schweiz Med Wochenschr* 91 : 957-960, 1961

17. Adkins PC, Izawa EM : Resection of tracheal cylindroma using cardiopulmonary bypass. *Arch Surg* 88 : 405-409, 1964
18. Neville WE, Thomason RD, Peacock H, Colby C : Cardiopulmonary bypass during non cardiac surgery. *Arch Surg* 92 : 576-587, 1966
19. Aylward TD, Flege JB Jr : Primary papilloma of the trachea. *Ann Thorac Surg* 16 : 620-623, 1973
20. Lee P, English ICW : Management of anaesthesia during tracheal resection. *Anaesthesia* 29 : 305-306, 1974
21. Phillips SJ, Ballentine B, Slonine D, Hall J, Vandelaar J, Kongtahworn C, Reckmo K, Gray D : Percutaneous initiation of cardiopulmonary bypass. *Ann Thorac Surg* 36 : 223-225, 1983
22. Mathisen DJ, Grillo HC : Carinal resection for bronchogenic carcinoma. *J Thorac Cardiovasc Surg* 102 : 16-23, 1991
23. Jensen V, Milne B, Salerno T : Femoral-femoral cardiopulmonary bypass prior to induction of anaesthesia in the management of upper airway obstruction. *Can Anaesth Soc J* 30 : 270-272, 1983
24. Horita K, Itoh T, Furukawa K, Katayama Y, Ohnishi H, Natsuaki M : Carinal reconstruction under veno-venous bypass using a percutaneous cardiopulmonary bypass system. *Thorac Cardiovasc Surg* 44 : 46-49, 1996
25. de Hoyos A, Demajo W, Snell G, Miller J, Winton T, Maurer JR, Patterson GA : Preoperative prediction for the use of cardiopulmonary bypass in lung transplantation. *J Thorac Cardiovasc Surg* 106 : 787-796, 1993
26. Lee BS, Sarnquist FH, Starnes VA : Anesthesia for bilateral single-lung transplantation. *J Cardiothorac Vasc Anesth* 6 : 201-203, 1992
27. Shuman RL : Primary pulmonary sarcoma with left atrial extension via left superior pulmonary vein. En bloc resection and radial pneumonectomy on cardiopulmonary bypass. *J Thorac Cardiovasc Surg* 88 : 189-192, 1984
28. Kemmerer WT, Eckert WG, Gathright JB, Reemtsma K, Creech O Jr : Patterns of thoracic injuries in fatal traffic accidents. *J Trauma* 1 : 595-599, 1961
29. Yamazaki M, Sasaki R, Masuda A, Ito Y : Anesthetic management of complete tracheal disruption using percutaneous cardiopulmonary support system. *Anesth Analg* 86 : 998-1000, 1998
30. Symbas PN, Justicz AG, Ricketts RR : Rupture of the airways from blunt trauma : treatment of complex injuries. *Ann Thorac Surg* 54 : 177-183, 1992
31. Woodhall B, Sealy WC, Hall KD, Floyd WL : Craniotomy under conditions of quinidine-protected cardioplegia and profound hypothermia. *Ann Surg* 152 : 37-44, 1960
32. Patterson RH Jr, Ray BS : Profound hypothermia for intracranial surgery : laboratory and clinical experiences with extracorporeal circulation by peripheral cannulation. *Ann Surg* 156 : 377-393, 1962
33. Michenfelder JD, Kirklin JW, Uihlein A, Svien HJ, MacCarty CS : Clinical experience with a closed-chest method of producing profound hypothermia and total circulation arrest in neurosurgery. *Ann Surg* 159 : 125-130, 1964
34. Drake CG, Barr HWK, Coles JC, Gergely NF : The use of extracorporeal circulation and profound hypothermia in the treatment of ruptured intracranial aneurysm. *J Neurosurg* 21 : 575-581, 1954
35. Cucchiara RF, Black S, Steinkeler JA : Anesthesia for intracranial procedures. In : Barash PG, Gullen BF, Stoelting RK, eds. *Clinical Anesthesia*. JB Lippincott, Philadelphia, 1989, pp.867-868
36. Williams MD, Rainer WG, Fieger HG Jr, Murray IP, Sanchez ML : Cardiopulmonary bypass, profound hypothermia, and circulatory arrest for neurosurgery. *Ann Thorac Surg* 52 : 1069-1075, 1991
37. Solomon RA, Smith CR, Raps EC, Young WL, Stone JG, Fink ME : Deep hypothermic circulatory arrest for the management of complex anterior and posterior circulation aneurysms. *Neurosurgery* 29 : 732-738, 1991
38. MacDonald JL, Cleland AG, Mayer RL, Henderson MJ : Extracorporeal circuit design considerations for giant intracranial aneurysm repair. *Perfusion* 12 : 193-196, 1997
39. Aebert H, Brawanski A, Philipp A, Behr R, Ullrich OW, Keyl C, Birnbaum DE : Deep hypothermia and circulatory arrest for surgery of complex intracranial aneurysms. *Eur J Cardiothorac Surg* 13 : 223-229, 1998
40. Mesana T, Collart F, Caus T, Pomane C, Graziani N, Bruder N, Dufour H, Grisoli F, Montiès JR : Centrifugal pumps and heparin-coated circuit in surgical treatment of giant cerebral aneurysms. *Artif Organs* 24 : 431-436, 2000
41. Shaw BW Jr, Martin DJ, Marquez JM, Kang

- YG, Bugbee AC Jr, Iwatsuki S, Griffith BP, Hardesty RL, Bahnson HT, Starzl TE : Venous bypass in clinical liver transplantation. *Ann Surg* 200 : 524-534, 1984
42. Calne RY, McMaster P, Smith DP, Craddock GN, Rolles K, Farman JV, Bethune DW, Lindop M, Wheeldon D, Gill R, Williams R : Use of portal cardiopulmonary bypass during the anhepatic phase of orthotopic liver grafting. *Lancet* 2 : 612-614, 1979
 43. Shaw BW Jr : Some further notes on venous bypass for orthotopic transplantation of the liver. *Transplant Proc* 19(Suppl 3) ; 13-16, 1987
 44. Merritt WT, Beattie C, Peck R, Burdick JF, Klein AS, Dickstein R : Vena caval pressure gradients during liver transplantation. *Transplantation* 50 : 336-338, 1990
 45. Brown M, Gunning T, Roberts C, Swygert T, Klintmalm G, Ramsay MAE, Gonwa TA : Biochemical markers of renal perfusion are preserved during liver transplantation with venovenous bypass. *Transplant Proc* 23 : 1980-1981, 1991
 46. Griffith BP, Shaw BW Jr, Hardesty RL, Iwatsuki S, Bahnson HT, Starzl TE : Veno-venous bypass without systemic anticoagulation for transplantation of the human liver. *Surg Gynecol Obstet* 160 : 271-272, 1985
 47. Ringe B, Bornscheuer A, Blumhardt G, Bechstein WO, Wonigeit K, Pichlmayr R : Experience with veno-venous bypass in human liver transplantation. *Transplant Proc* 19 : 2416, 1987
 48. Persson NH, Brown M, Goldstein R, Husberg B, Paulsen A, Ramsay M, Klintmalm G : Inferior mesenteric vein cannulation for venovenous bypass during liver transplantation : alternative access in difficult hilar dissection. *Transplant Proc* 22 : 174, 1990
 49. Huguet C, Nordlinger B, Galopin JJ, Bloch P, Gallot D : Normothermic hepatic vascular exclusion for extensive hepatectomy. *Surg Gynecol Obstet* 147 : 689-693, 1978
 50. Miller CM, Schwartz ME, Nishizaki T : Combined hepatic and vena caval resection with autogenous caval graft replacement. *Arch Surg* 126 : 106-108, 1991
 51. Yanaga K, Kishikawa K, Shimada M, Kakizoe S, Higashi H, Nishizaki T, Matsumata T, Kanematsu T, Sugimachi K : Extracorporeal hepatic resection for previously unresectable neoplasms. *Surgery* 113 : 637-643, 1993
 52. Hamazaki K, Yagi T, Inagaki M, Inagaki M, Tanaka N, Mimura H, Orita K, Lygidakis NJ : Hepatectomy under extracorporeal circulation. *Surgery* 118 : 98-102, 1995
 53. Murakami T, Myojin K, Matano J, Kamikubo Y, Hatta E, Matsuzaki K : Resection of hepatoblastoma with right atrial extension using cardiopulmonary bypass. *J Cardiovasc Surg* 36 : 455-457, 1995
 54. Tongaonkar HB, Dandekar NP, Dalal AV, Kulkarni JN, Kamat MR : Renal cell carcinoma extending to the renal vein and inferior vena cava : results of surgical treatment and prognostic factors. *J Surg Oncol* 59 : 94-100, 1995
 55. Marshall VF, Middleton RG, Holswade GR, Goldsmith EI : Surgery for renal cell carcinoma in the vena cava. *J Urol* 103 : 414-420, 1970
 56. Ardekani RG, Hunter JA, Thomson A : Hidden hypernephroma simulating right atrial tumor. *Ann Thorac Surg* 11 : 371-375, 1971
 57. Wilkinson CJ, Kimovec MA, Uejima T : Cardiopulmonary bypass in patients with malignant renal neoplasms. *Br J Anaesth* 58 : 461-465, 1986
 58. Novick AC, Kaye MC, Cosgrove DM, Angermeier K, Pontes JE, Montie JE, Strem SB, Klein E, Stewart R, Goormastic M : Experience with cardiopulmonary bypass and deep hypothermic circulatory arrest in the management of retroperitoneal tumors with large vena caval thrombi. *Ann Surg* 212 : 472-477, 1990
 59. Swierzewski DJ, Swierzewski MJ, Libertino JA : Radical nephrectomy in patients with renal cell carcinoma with venous, vena caval, and atrial extension. *Am J Surg* 168 : 205-209, 1994
 60. Matthews PN, Evans C, Breckenridge IM : Involvement of the inferior vena cava by renal tumour : surgical excision using hypothermic circulatory arrest. *Br J Urol* 75 : 441-444, 1995
 61. Hill JG, Bruhn PS, Cohen SE, Gaallagher MW, Manart F, Moore CA, Seifert PE, Askari P, Banchieri C : Emergent applications of cardiopulmonary support : A multiinstitution experience. *Ann Thorac Surg* 54 : 699-704, 1992
 62. Overlie PA, Walter PD, Hurd HP II, Wells GA, Seger JJ, Zias J, Wey RJ, Jensen JB, Shoukfeh MF, Levine MJ, Moss JB III : Emergency cardiopulmonary support with circulatory support devices. *Cardiology* 84 : 231-237, 1994
 63. Kanter KR, Pennington DG, Vandormael M, Kern MJ, McBride LR, Naunheim KS, Braun P, Taub J, Willman VL : Emergency resuscitation with extracorporeal membrane oxygena-

- tion for failed angioplasty. *J Am Coll Cardiol* 11 : 149A (Abst), 1988
64. Vogel RA, Shawl F, Tommaso C, O'neill W, Overlie P, O'toole J, Vandormael M, Topol E, Tabari KK, Vogel J, Smith S Jr, Freedmann R Jr, White C, George B, Teirstein P : Initial report of the National Registry of Elective Cardiopulmonary Bypass Supported Coronary Angioplasty. *J Am Coll Cardiol* 15 : 23-29, 1990
 65. Tommaso CL, Vogel RA : National Registry for Supported Angioplasty : results and follow-up of three years of supported and standby supported angioplasty in high-risk patients. *Cardiology* 84 : 238-244, 1994
 66. Ryan JF, Donlon JV, Malt RA, Bland JH, Buckley MJ, Sreter FA, Lowenstein E : Cardiopulmonary bypass in the treatment of malignant hyperthermia. *N Engl J Med* 290 : 1121-1122, 1974
 67. Kugelberg J, Schüller H, Berg B, Kallum B : Treatment of accidental hypothermia. *Scand J Thorac Cardiovasc Surg* 1 : 142-146, 1967
 68. Hauty MG, Esrig BC, Hill JG, Long WB : Prognostic factors in severe accidental hypothermia : experience from the Mt. Hood tragedy. *J Trauma* 27 : 1107-1112, 1987
 69. Laub GW, Banaszak D, Kupferschmid J, Magovern GJ, Young JC : Percutaneous cardiopulmonary bypass for the treatment of hypothermic circulatory collapse. *Ann Thorac Surg* 47 : 608-611, 1989
 70. Sekela ME, Noon GP, Holland VA, Lawrence EC : Differential perfusion : potential complication of femoral-femoral bypass during single lung transplantation. *J Heart Lung Transplant* 10 : 322-324, 1991