

CASE REPORT

Peritoneal cecal cancer metastasis to a mesh-plug prosthesis : A case report

Itaru Shigeyoshi, Koji Komori, Takashi Kinoshita, Taihei Oshiro, Seiji Ito, Tetsuya Abe, Yoshiki Senda, Kazunari Misawa, Yuichi Ito, Norihisa Uemura, Seiji Natsume, Eiji Higaki, Byonggu An, Akira Ouchi, Masayuki Tsutsuyama, Takahiro Hosoi, Daisuke Hayashi, Hideharu Tanaka, Tairin Uchino, Aina Kunitomo, and Yasuhiro Shimizu

Department of Gastroenterological Surgery, Aichi Cancer Center Hospital, Aichi, Japan

Abstract : We report the case of a 77-year-old man who presented to our hospital with cecal cancer, lung metastasis, and liver metastasis in January 2013. After four courses of modified infusional intravenous fluorouracil and leovorin with oxaliplatin (mFOLFOX 6) + bevacizumab, there was no new metastatic lesion and lung metastasis reduction was observed. Ileocecal resection was performed in May, left lower lung lobectomy in August, and extended right posterior segmentectomy + S8 partial liver resection was performed in December. The tumor marker declined initially ; thereafter, it gradually increased. Computed tomography (CT) performed in April 2014 revealed right inguinal mass around the mesh-plug prosthesis. A positron emission tomography-CT (PET-CT) also revealed a high 2-fluoro-2-deoxy-D-glucose (FDG) uptake at the same site. Right inguinal tumor resection was performed in July. Cancer tissues were confirmed by performing intraoperative rapid pathological diagnosis, and R0 resection could be achieved. Previous studies have reported malignant tumor metastases to the mesh-plug prosthesis, and this was believed to one of the sites that cancer cells can easily engraft. In particular, in patients with a history of advanced malignant tumors, if mass formation around the artifact insertion site is observed, the possibility of peritoneal metastasis should be considered. *J. Med. Invest.* 65 : 142-146, February, 2018

Keywords : *peritoneal metastasis, colon cancer, mesh-plug prosthesis.*

INTRODUCTION

To our knowledge, there is currently no standard treatment for colorectal peritoneal dissemination, and its prognosis is poor. However, some reports show that there is a difference in prognosis depending on the seeding degree. Further, as per the Japanese Society for Cancer of the Colon and Rectum Guidelines 2016 for the treatment of colorectal cancer, "If it is possible to excise without excessive invasion, localized peritoneal dissemination should be resected" (1).

We report a case of peritoneal metastasis from cecal cancer in inguinal hernioplasty scar. To the best of our knowledge, five studies have assessed peritoneal metastasis in inguinal hernioplasty scars, and the relationship between peritoneal chronic inflammation and implantation of cancer cells is stated as a hypothesis.

We could clinically diagnose peritoneal metastasis to a mesh-plug prosthesis, and complete resection of the tumor could be achieved. There has been no case with a complete resection of peritoneal metastasis to a mesh-plug prosthesis and long-term survival.

CASE PRESENTATION

In January 2013, a 77-year-old man presented to the department of gastroenterology at Aichi Cancer Center Hospital (Nagoya,

Aichi Prefecture, Japan). A diagnosis of cecal carcinoma, liver metastasis (S5), and lung metastasis (left lung lower lobe, S10) was confirmed at a hospital that he previously visited. Although both metastatic lesions were considered resectable, the patient underwent neo-adjuvant chemotherapy according to his request. The specimen from the cecal tumor was found to be KRAS mutation type (G12x). After four courses of modified infusional intravenous fluorouracil and leovorin with oxaliplatin (mFOLFOX 6) + bevacizumab, there was no new metastatic lesion, liver metastasis was reduced, and pulmonary metastasis decreased (Figures 1 A, B).

At this time, he consented to undergo surgical resection.

First, ileocecal dissection with regional node dissection (D3) was performed in May 2013. The pathological diagnosis was moderately differentiated adenocarcinomas [T4a/SE, tub 2, ly 2, v 2, inf β, N 1 (3/30)] (Figures 2 A, B).

Imaging studies revealed that lung and liver metastases had increased and enlarged, respectively. Left lower lung lobectomy was performed in August in the same year, and three metastatic lesions were resected (Figure 3 A). Furthermore, in December of the same year, extended right posterior segmentectomy + S8 partial liver resection was performed to excise three metastatic lesions (Figure 4 A). Pathological findings showed tubular adenocarcinoma consistent with metastasis from cecal cancer (Figures 3 B, 4 B). Thus, all the metastatic lesions were excised at once.

Tumor markers initially declined after hepatectomy ; however, they rapidly increased during May-June 2014 (Figure 5).

In April 2014, computed tomography (CT) revealed a mass formation around the mesh-plug prosthesis of right inguinal hernioplasty performed in 2008 (Figure 6 A). Positron emission tomography-CT (PET-CT) confirmed accumulation at the same site (Figure 6 B). At the time of the follow-up CT, the inguinal mass had enlarged. There was no other obvious recurrence site on CT

Received for publication October 12, 2017 ; accepted December 28, 2017.

Address correspondence and reprint requests to Itaru Shigeyoshi, MD, Department of Gastroenterological Surgery, Aichi Cancer Center Hospital, Nagoya city, Chikusa-ku, Kanokoden 1-1 Aichi 464-8681, Japan and Fax : +81-52-763-5233.

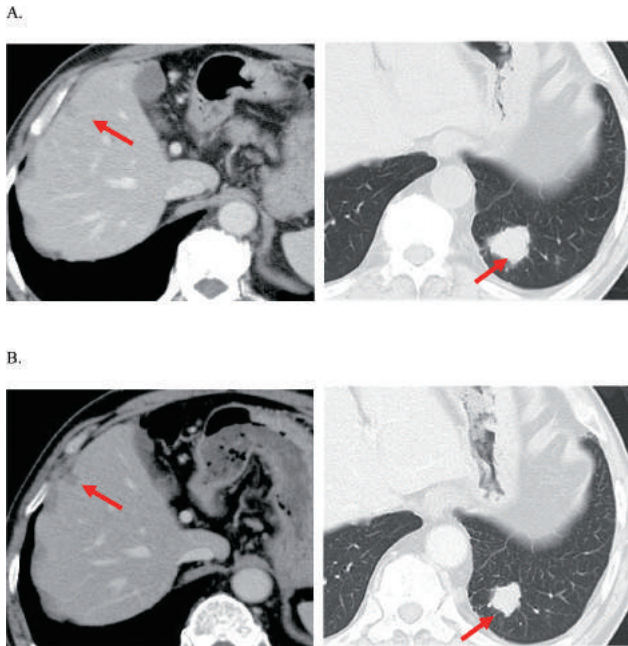


Figure 1 Liver and lung metastases before and after chemotherapy
 A. Liver and lung metastases before chemotherapy
 B. Liver and lung metastases after chemotherapy
 Liver metastasis was reduced, and pulmonary metastasis decreased.

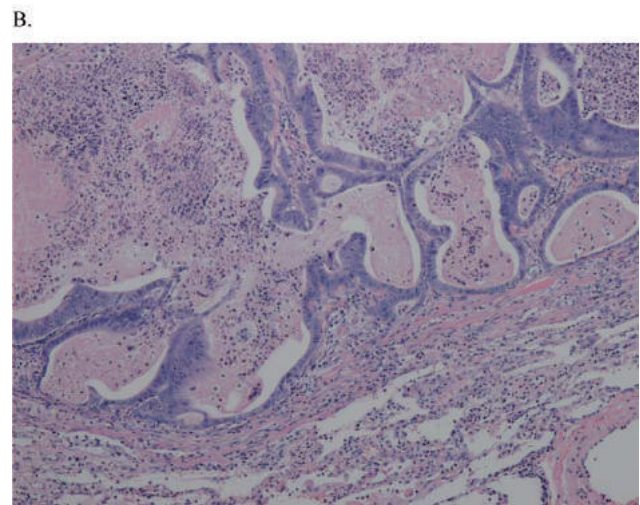
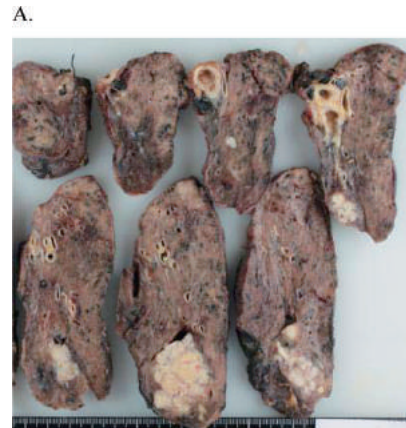

Figure 3 Resected specimen and histological findings of left lower lung lobectomy
 A. Macroscopic view of the lung metastasis (three tumors)
 B. Pathological findings showed tubular adenocarcinoma consistent with metastasis from cecal cancer

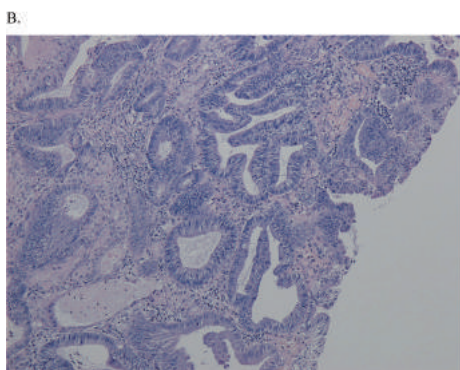
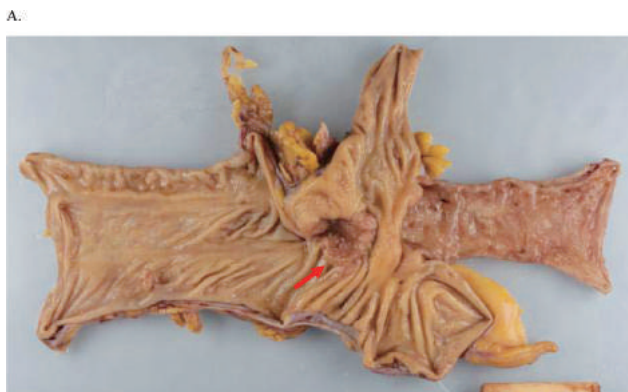

Figure 2 Resected specimen and histological findings of the first laparotomy
 A. Macroscopic view of the cecal cancer (arrow)
 B. Pathological diagnosis was moderately differentiated adenocarcinoma.

imaging.

In July, the third laparotomy was performed. There was no other disseminated nodule. After cancer tissue was confirmed by intraoperative rapid pathological diagnosis, the tumor, including the mesh-plug prosthesis was completely excised (Figure 7 A).

Pathological examination confirmed the presence of tubular adenocarcinoma and artificial fiber in the tissues. This was consistent with the diagnosis of colon cancer metastasis (Figure 7 B).

Twelve courses of mFOLFOX6 comprised the adjuvant chemotherapy. Peritoneal and liver recurrences were detected in September 2015 ; these were treated with infusional intravenous fluorouracil and levolefolinate with irinotecan (FOLFIRI) + bevacizumab. As of November 2017, tumor progression is being controlled.

DISCUSSION

Colorectal cancer has been reported to have a lower ability to adhere to and proliferate in the peritoneum than gastric cancer. Mochizuki *et al.* reported cytokines, such as TNF α , as a factor influencing the ability of peritoneal metastasis (2).

Although the mechanism underlying the peritoneal metastasis to

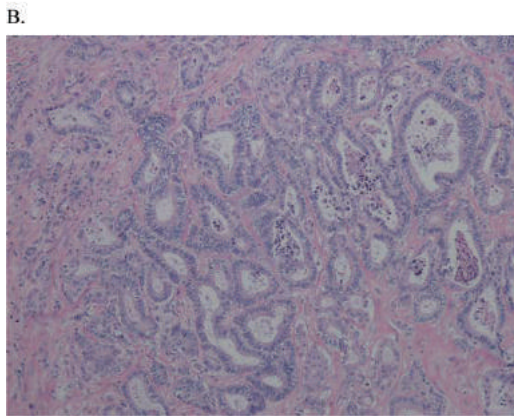
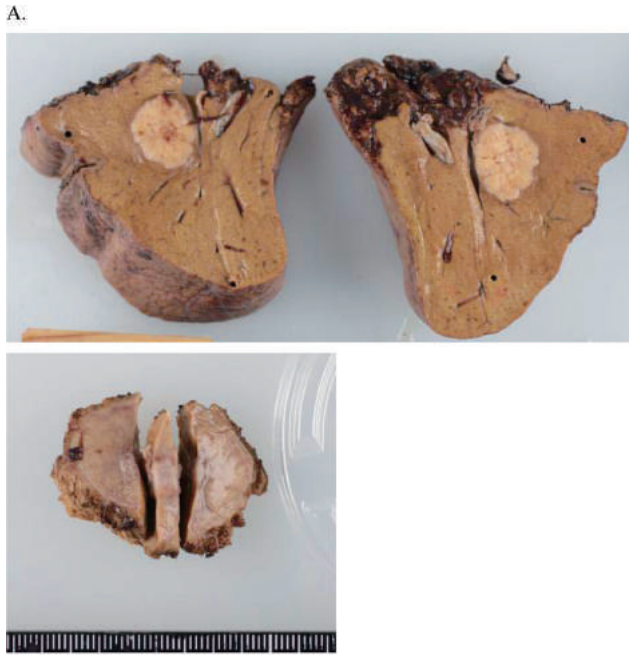


Figure 4 Resected specimen and histological findings of extended right posterior segmentectomy + S8 partial liver resection
 A. Macroscopic view of the liver metastasis (three tumors)
 B. Pathological findings showed tubular adenocarcinoma consistent with metastasis from cecal cancer

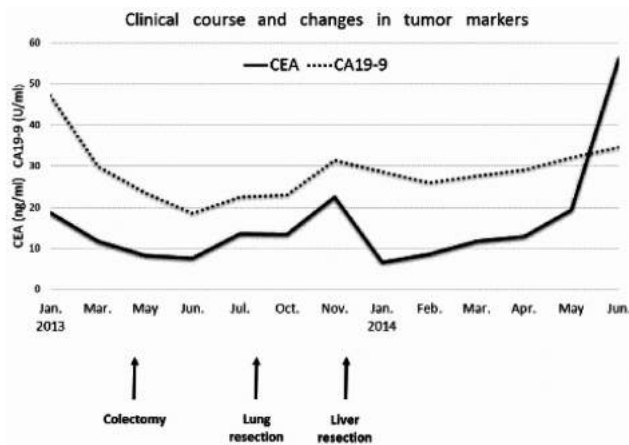


Figure 5 Changes in tumor markers
 CEA initially declined after hepatectomy ; however, it rapidly increased during May-June 2014.

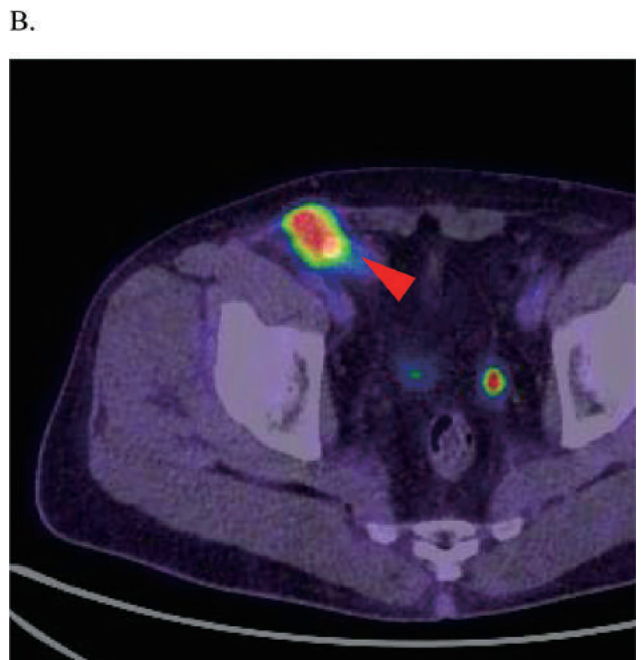
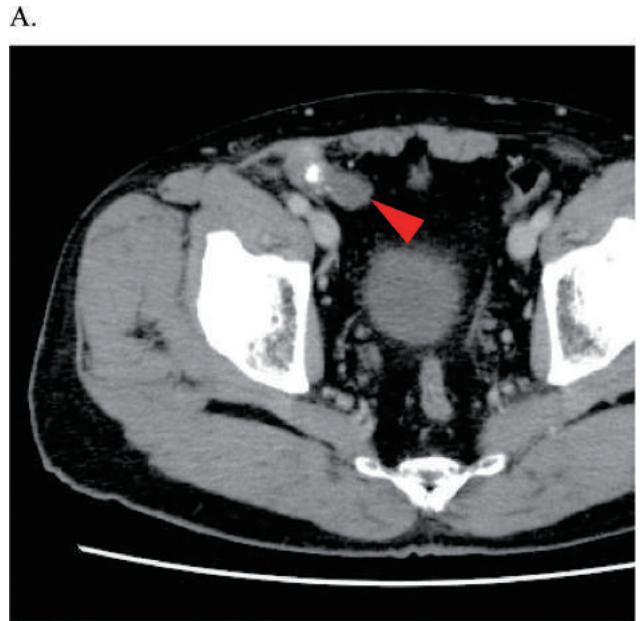


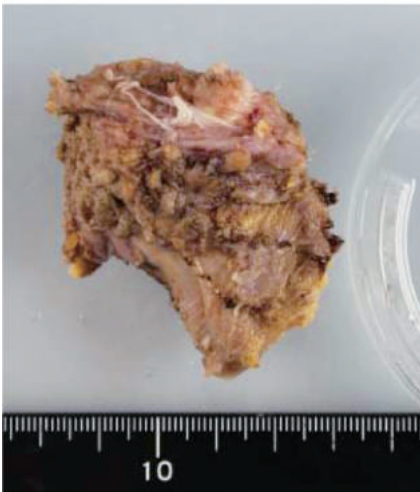
Figure 6 Preoperative image of right inguinal mass
 A. In April 2014, CT revealed a mass formation around the mesh-plug prosthesis of right inguinal hernioplasty (arrow).
 B. Same site was detected on PET-CT with a high FDG uptake (arrow).

the mesh-plug prosthesis is unknown, Kudou *et al.* have suggested that chronic inflammation due to artificial insertion may be related to cancer engraftment (3).

In the present case, the tumor was exposed to the peritoneum ; thereafter, multiple peritoneal metastases recurred. These processes may suggest that the floating cancer cells implanted and proliferated in the peritoneum of the mesh insertion site under the influence of the cytokine.

To the best of our knowledge, five studies have reported peritoneal metastasis in inguinal hernioplasty scar (3) (4) (5) (6) (7).

A.



B.

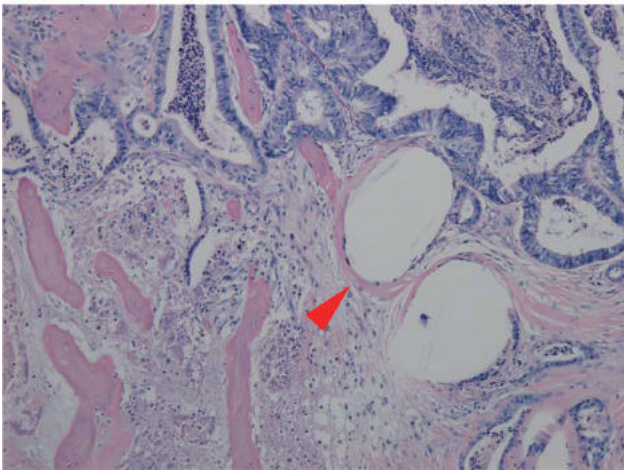


Figure 7 Resected specimen and histological findings of right inguinal tumor resection

A. Macroscopic view of the peritoneal metastasis to the mesh-plug prosthesis

B. Pathological findings showed tubular adenocarcinoma consistent with metastasis from cecal cancer. Many cavities are formed by artificial fiber (arrow).

Details of these five studies and those of our study are summarized in Table 1. In three cases, the primary disease was colon cancer. In the other three cases, the primary diseases were gastric cancer, lymphoma, and pancreatic cancer. The anterior approach was used in three cases, and the laparoscopic approach was used in two cases. No causal relationship existed between the type of surgical approach used and peritoneal metastasis to a mesh-plug prosthesis.

Resection of peritoneal metastasis to a mesh-plug prosthesis was performed in two cases, including our case.

In the case reported by Imai *et al.*, preoperative diagnosis was abscess and granulation of the plug part. The tumor was resected using the anterior approach and was diagnosed as peritoneal recurrence on pathological examination. He died 45 days after the surgery with surgical site recurrence and cancer peritonitis.

In our case, we considered the mass surrounding the mesh plug as peritoneal metastasis based on the preoperative image and the increase in the tumor marker, and tumorectomy was performed. Thus, a good field of view was obtained by laparotomy and complete resection could be achieved securing sufficient surgical margin.

In order to diagnose a mass formation around the mesh-plug prosthesis as peritoneal metastasis, a comprehensive judgment must be made, based on tumor enlargement, increase in the tumor markers, and PET-CT indications.

With respect to port-site metastasis, peritoneal metastasis to a mesh-plug prosthesis was detected on PET-CT with a high 2-fluoro-2-deoxy-D-glucose (FDG) uptake; however, it is noteworthy that the abdominal mesh can show increased FDG uptake even in the absence of any pathology (4).

Several studies have detected high FDG uptake in foreign body granulomas (FBG) using PET-CT. It is challenging to distinguish FBG from malignant metastases before surgery, and a confirmed diagnosis was established by performing tumor resection in most reported cases (8).

Therefore, the optimal methods of metastasis diagnosis are tumorectomy or biopsy. In particular, for diseases, such as pancreatic cancer and lymphoma, the treatment policy changes according to the pathological diagnosis of the inguinal mass. Therefore, laparoscopic biopsy should be considered, as in the past report. In case of colon cancer metastasis, laparoscopic biopsy can be simultaneously preformed. However, in metachronous metastasis, laparoscopic examination may be difficult due to the adhesion; thus, it is preferable to resect the tumor after the laparotomic biopsy, as in our case. For patients with peritoneal metastasis of colon cancer,

Table 1

| | Author/year | Age/sex | Primary tumor | Approach to inguinal hernias | Biopsy | Timing of metastasis | Other metastasis | Therapy | Outcome |
|---|---------------|---------|---------------------------|------------------------------|---------------------|----------------------|-----------------------------|----------------------------|---|
| 1 | Pocard/1999 | 72 M | Nodal mesenteric lymphoma | Laparoscopy | Yes. (laparotomy) | Synchronous | (-) | Chemotherapy | Alive (inguinal mass has disappeared by chemotherapy) |
| 2 | Imai/2003 | 88 M | Colon cancer | Open | No | Metachronous | (-) | Tumorectomy | Death, 45 days |
| 3 | Tsukao/2014 | 66 M | Gastric cancer | Open | Yes. (percutaneous) | Metachronous | (-) | Chemoradiotherapy | Death, 27 months |
| 4 | Kudou/2015 | 85 M | Colon cancer | Open | Yes. (laparoscopy) | Synchronous | Liver metastasis | Chemotherapy | Alive, 8 months |
| 5 | Vincenzo/2016 | 76 M | Pancreatic cancer | Laparoscopy | Yes. (laparoscopy) | Synchronous | Other peritoneal metastasis | Chemotherapy | (-) |
| 6 | Our case | 77 M | Colon cancer | Open | Yes. (laparotomy) | Metachronous | (-) | Tumorectomy + Chemotherapy | Alive, 30 months |

long-term survival is possible with resection ; therefore, radical resection should be considered for solitary peritoneal metastasis to a mesh-plug prosthesis. In our case, R0 resection was achieved, and no recurrence was observed will 14 months after the surgery.

CONCLUSION

We report a case of a peritoneal cecal cancer metastasis to a mesh-plug prosthesis. The achievement of R0 resection in our case was remarkable.

If mass formation around the inguinal mesh-plug prosthesis is confirmed using imaging studies during the postoperative follow-up for advanced cancer, peritoneal metastasis should be suspected.

In solitary peritoneal metastasis to a mesh-plug prosthesis from colorectal cancer, long-term survival may be achieved using tumorectomy.

CONFLICT OF INTEREST

The authors have no conflicts of interest to disclose and received no financial support for this report.

REFERENCES

1. Watanabe T, Muro K, Ajioka Y, Hashiguchi Y, Ito Y, Saito Y, *et al* : Japanese Society for Cancer of the Colon and Rectum (JSCCR) guidelines 2016 for the treatment of colorectal cancer. *International journal of clinical oncology* : 2017
2. Mochizuki Y, Nakanishi H, Kodera Y, Ito S, Yamamura Y, Kato T, *et al* : TNF-alpha promotes progression of peritoneal metastasis as demonstrated using a green fluorescence protein (GFP)-tagged human gastric cancer cell line. *Clinical & experimental metastasis* 21(1) : 39-47, 2004
3. Kudou M, Murayama Y, Konishi H, Morimura R, Komatsu S, Shiozaki A, *et al* : Peritoneal colon cancer metastasis to bilateral inguinal hernia repair sites : report of a case. *Surgery today* 45(8) : 1053-7, 2015
4. Simonelli V, Boven C, Loi P, El Nakadi I, Closset J : Intraperitoneal mesh prosthesis metastasis from pancreatic cancer, after laparoscopic hernia repair. *Acta chirurgica Belgica* 116(1) : 51-3, 2016
5. Imai M, Kondo Y, Masuko H, Okada K, Osawa S, Ishizu H, *et al* : Distant peritoneal metastasis to a mesh-plug prosthesis in a gastrointestinal cancer patient : report of a case. *Surgery today* 33(11) : 864-6, 2003
6. Pocard M, Vaillant JC, Fritsch S, Aoudjhane M, Najman A, Parc R : Possible first report of distant peritoneal metastases from a nodal mesenteric lymphoma after laparoscopic inguinal hernia repair. *European journal of surgical oncology : the journal of the European Society of Surgical Oncology and the British Association of Surgical Oncology* 25(6) : 635-6, 1999
7. Tsukao Y, Kobayashi K, Takachi K, Aoki T, Uemura Y : The Impact of Distant Metastasis to a Kugel-mesh Prosthesis in a Gastric Cancer Patient&mdash ; Report of a Case&mdash. *Nihon Rinsho Geka Gakkai Zasshi (Journal of Japan Surgical Association)* 75(4) : 963-7, 2014
8. Miyake K, Matsuda G, Oshi M, Kogure Y, Den K, Tsuchiya N, *et al* : Foreign Body Granuloma Caused by Surgical Suture Material Mimicking Lymph Node Recurrence Detected by Delayed Phase FDG-PET/CT Imaging. *The Japanese Journal of Gastroenterological Surgery* 49(1) : 58-65, 2016