

ORIGINAL

Efficacy of combined photodynamic therapy and sub-Tenon's capsule injection of triamcinolone acetonide for age-related macular degeneration

Takashi Katome, Takeshi Naito, Toshihiko Nagasawa, and Hiroshi Shiota

Department of Ophthalmology, Institute of Health Biosciences, the University of Tokushima Graduate School, Tokushima, Japan

Abstract : Purpose : To evaluate the efficacy of combined photodynamic therapy (PDT) and sub-Tenon's capsule injection of triamcinolone acetonide (TA) for the treatment of choroidal neovascularization (CNV) in age-related macular degeneration (AMD) at 1-year follow-up. **Methods :** A total of 117 eyes with subfoveal CNV caused by AMD were included. Sixty-eight eyes were treated with combined PDT and sub-tenon injection of 20 mg TA and compared with a control group of 49 eyes treated with PDT alone. All patients completed 1 year follow-up. The main outcome measures were best-corrected visual acuity (BCVA) and retreatment frequency. **Results :** There were no significant differences in age, sex, VA, lesion type, and greatest linear dimension between the two groups at baseline. BCVA analysis showed statistically no significant differences between the two groups. The PDT+TA group required a lower mean number of treatments (1.38 versus 1.67, $P=0.032$). **Conclusion :** Our study confirms that sub-Tenon's capsule injection of TA with PDT significantly reduces the retreatment frequency of PDT. *J. Med. Invest.* 56 : 116-119, August, 2009

Keywords : *age-related macular degeneration, photodynamic therapy, triamcinolone acetonide, combination therapy*

INTRODUCTION

Photodynamic therapy (PDT) with verteporfin has been shown to be an effective treatment for choroidal neovascularization (CNV) secondary to age-related macular degeneration (AMD) (1, 2). Triamcinolone acetonide (TA) is a commonly used steroid in treating ocular inflammation by sub-Tenon's capsule injection (3). TA has been shown to be an effective inhibitor of neovascularization, and also known to be one of the most potent anti-angiogenic drugs (4). Intravitreal injection of TA as an adjunct to PDT

seems to reduce the growth of CNV and, therefore, the need for retreatment (5), but it is associated with side effects of raised intraocular pressure (IOP), cataract, endophthalmitis and retinal detachment (6-8). The posterior juxtascleral injection of TA has been reported to have a much lower risk of endophthalmitis and retinal detachment. Indeed, a previous study has demonstrated the effectiveness of adjunct posterior juxtascleral TA injection in reducing the number of retreatments, with a follow-up period of 6 months (9).

This study included patients who completed at least 1 year follow-up after the initial PDT, and investigated the effect of sub-Tenon's injection of TA on CNV, focusing on changes of visual acuity and retreatment rates.

Received for publication January 13, 2009 ; accepted February 7, 2009.

Address correspondence and reprint requests to Takeshi Naito, MD, Ph.D., Department of Ophthalmology, Institute of Health Biosciences, the University of Tokushima Graduate School, Kuramoto-cho, Tokushima 770-8503, Japan and Fax : +81-88-631-4848.

MATERIALS AND METHODS

Patients

A total of 117 eyes of 117 patients (88 men, 29 women ; mean age 73.8 years) were included in this study. Between October 2004 and June 2008, 68 eyes of 68 patients underwent PDT with sub-Tenon's capsule injection of 20 mg TA (PDT+TA group) and 49 eyes of 49 patients underwent PDT alone (PDT-only group) at the Department of Ophthalmology of Tokushima University Hospital. All patients presented with subfoveal CNV caused by AMD. Between October 2004 and January 2006, all patients underwent PDT alone, and thereafter, all patients underwent adjunctive sub-Tenon's capsule injection prior to PDT. All these patients completed 1 year follow-up. The baseline characteristics of the two groups were not statistically significantly different. Institutional approval for the use of TA was obtained, and informed consent was received from each patient before treatment.

Baseline characteristics

At baseline, the two groups were comparable for the type of CNV (PDT-only group 49 eyes, PDT+TA group 68 eyes). All patients were followed up for 12 months or more. The characteristics of patients at baseline are summarized in Table 1. There were no significant differences in gender, age, lesion type, VA and greatest linear dimension (GLD) between

the two groups.

Follow-up examinations

All patients were scheduled for follow-up every 3 months after the treatment. At each of these examinations, the best-corrected visual acuity (BCVA) was measured with full subjective refraction using a Landolt ring chart at 5 m. Fundus photography and angiography were also performed before treatment or retreatment, using an Imagenet camera (TRC50 IA, Topcon, Tokyo, Japan). Fundus photographs and angiograms were obtained at baseline and follow-up from nearly all subjects, and were evaluated and graded by one of the authors (TN).

PDT with verteporfin

The treatment protocol of PDT followed the Japanese Age-Related Macular Degeneration Trial (JAT) study (10). Patients received an infusion of verteporfin (Visudyne™ ; Novartis AG, Basel, Switzerland) diluted to a volume of 30 ml with 5% dextrose in water, followed by laser light exposure. A 10-min infusion of verteporfin was followed 15 min later by exposure to red diode laser light (689 nm) for exactly 83 s to produce 50 J/cm². Additional therapy for eligible patients was given if fluorescein leakage from the CNV was observed as often as every 3 months during the 12-month follow-up.

Statistical Analysis

Statistical analysis was performed using SPSS v11.5 software (SPSS, Chicago, IL, USA). Fisher's exact tests were used to compare the proportion of patients between the two groups. Serial changes in the logarithm of the minimum angle of resolution (logMAR BCVA) were compared using Wilcoxon signed ranks test. The mean number of treatments and lines of BCVA changes in the two groups were compared using Mann-Whitney *U* test. We considered *P* < 0.05 as statistically significant.

Table 1. Characteristics of patients at baseline

		PDT-only group	PDT+TA group	<i>P</i> value
Gender	Men	38 (77.6%)	50 (73.5%)	0.956
	Women	11 (22.4%)	18 (26.5%)	
Age (years old)		74.1	73.6	0.988
Diagnosis	AMD	39 (79.6%)	45 (66.2%)	0.370
	PCV	8 (16.3%)	19 (27.9%)	
	RAP	2 (4.1%)	4 (5.9%)	
BCVA (logMAR)		0.87	0.86	0.969
GLD (μm)		3525	3586	0.973

PDT : photodynamic therapy

AMD : age-related macular degeneration

PCV : polypoidal choroidal vasculopathy

RAP : retinal angiomatous proliferation

BCVA : best-corrected visual acuity

logMAR : logarithm of the minimum angle of resolution

GLD : greatest linear dimension

RESULTS

Number of treatments in both groups

In the PDT+TA group, 48 patients (70.6%) needed only one treatment, and 20 patients (29.4%) received two or more treatments. In the PDT-only group, 29 patients (59.2%) received two or more treatments (Table 2). The PDT+TA group required a lower mean number of treatments (1.38 versus 1.67, χ^2 test *P*=0.032).

Table 2. Number of treatments

Study group	No. of patients	No. (%) of patients			mean
		1	2	3	
PDT-only	49	20(40.8%)	25(51.0%)	4(8.2%)	1.67*
PDT+TA	68	48(70.6%)	14(20.6%)	6(8.8%)	1.38*

PDT : photodynamic therapy

TA : triamcinolone acetonide

* : $P=0.032$, Mann-Whitney U test

Change in VA after treatment

BCVA analysis showed statistically no significant differences between the two groups during the 1-year follow-up period (Fig. 1).

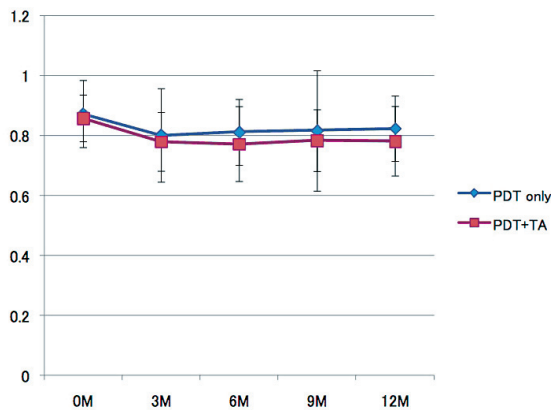


Fig. 1. Changes of logMAR BCVA in two groups
There was no significant difference between the two groups.

Complications

Although no side effects related to PDT were noted, there were side effects related to TA. Medical therapy was required to control elevated IOP during the first year in eight (12%) of 68 patients in the PDT+TA group.

DISCUSSION

Although PDT has been shown to be effective and has become a major therapeutic option for exudative AMD, some cases are resistant and require repeated PDT application. In addition, the possibility that repeated PDT may cause retinal damage and result in progressive thinning of the neurosensory retina has been investigated in an animal model (11), and it may be that less PDT has a greater benefit. Our

study confirms that the combination of PDT with TA significantly reduces the number of retreatments of PDT.

The most expected complication related to the use of TA is increased IOP. In the present study, the rate was lower than that of with intravitreal injection of TA reported previously (12). This supports the results of a previous study that sub-Tenon's capsule injection of TA is associated with a lower risk of increased IOP than that with intravitreal injection (9). Other complications of intravitreal injection of TA, such as conjunctivitis, endophthalmitis and retinal detachment, did not occur in the present study.

In conclusion, the combination of PDT and sub-Tenon's capsule injection of TA was more effective than PDT alone. The side effects related to this treatment were tolerable. Future treatments are likely to include combinations of PDT with corticosteroids and anti-VEGF drugs. Prospective, randomized and controlled studies are needed for further evaluation of the benefits of combination therapy.

REFERENCES

1. Bressler NM : Photodynamic therapy of subfoveal choroidal neovascularization in age-related macular degeneration with verteporfin : two year results of 2 randomized clinical trials-TAP report 2. Arch Ophthalmol 119 : 198-207, 2001
2. Verteporfin In Photodynamic Therapy Study Group : Verteporfin in Photodynamic Therapy Report 2. Verteporfin therapy of subfoveal choroidal neovascularization in age-related macular degeneration : two-year results of a randomized clinical trial including lesions with occult with no classic choroidal neovascularisation. Am J Ophthalmol 131 : 541-560, 2001
3. Ranson NT, Danis RP, Ciulla TA, Pratt L : Intravitreal triamcinolone in subfoveal recurrence of choroidal neovascularisation after laser treatment in macular degeneration. Br J Ophthalmol 86 : 527-529, 2002
4. Folkman J, Ingber DE : Angiostatic steroids. Method of discovery and mechanism of action. Ann Surg 206 : 374-383, 1987
5. Augustin AJ, Schmidt-Erfurth U : Verteporfin therapy and triamcinolone acetonide : convergent modes of action for treatment of neovascular age-related macular degeneration. Eur J Ophthalmol 16 : 824-834, 2006

6. Augustin AJ, Schmidt-Erfurth U : Verteporfin and intravitreal triamcinolone acetonide combination therapy for occult choroidal neovascularization in age-related macular degeneration. *Am J Ophthalmol* 141 : 638-645, 2006
7. Chan WM, Lai TY, Wong AL, Tong JP, Liu DT, Lam DS : Combined photodynamic therapy and intravitreal triamcinolone injection for the treatment of subfoveal choroidal neovascularisation in age related macular degeneration : a comparative study. *Br J Ophthalmol* 90 : 337-341, 2006
8. Spaide RF, Sorenson J, Maranan L : Combined photodynamic therapy with verteporfin and intravitreal triamcinolone acetonide for choroidal neovascularization. *Ophthalmology* 110 : 1517-1525, 2003
9. Van de Moere A, Sandhu SS, Kak R, Mitchell KW, Talks SJ : Effect of posterior juxtасlеral triamcinolone acetonide on choroidal neovascular growth after photodynamic therapy with verteporfin. *Ophthalmology* 112 : 1896-1903, 2005
10. Japanese Age-Related Macular Degeneration Trial (JAT) Study Group : Japanese age-related macular degeneration trial : 1-year results of photodynamic therapy with verteporfin in Japanese patients with subfoveal choroidal neovascularization secondary to age-related macular degeneration. *Am J Ophthalmol* 136 : 1049-1461, 2003
11. Reinke MH, Canakis C, Husain D, Michaud N, Flotte TJ, Gragoudas ES, Miller JW : Verteporfin photodynamic therapy retreatment of normal retina and choroid in the cynomolgus monkey. *Ophthalmology* 106 : 1915-23, 1999
12. Rechtman E, Danis RP, Pratt LM, Harris A : Intravitreal triamcinolone with photodynamic therapy for subfoveal choroidal neovascularisation in age related macular degeneration. *Br J Ophthalmol* 88 : 344-347, 2004