

## CASE REPORT

# Meralgia paresthetica caused by entrapment of the lateral femoral subcutaneous nerve at the fascia lata of the thigh : a case report and literature review

Yasuyuki Omichi<sup>1</sup>, Ichiro Tonogai<sup>2</sup>, Shinsuke Kaji<sup>1</sup>, Teruaki Sangawa<sup>1</sup>, and Koichi Sairyo<sup>2</sup>

<sup>1</sup>Department of Orthopedics, Shikokuchuo Hospital, Ehime, Japan, <sup>2</sup>Department of Orthopedics, Tokushima University, Tokushima, Japan

**Abstract :** Meralgia paresthetica (MP) causes tingling, stinging or a burning sensation in the anterolateral part of the thigh, usually as a result of entrapment of the lateral femoral cutaneous nerve (LFCN) at the inguinal ligament (IL) due to mechanical or iatrogenic injury. However, there are few reports on MP caused by entrapment of the LFCN at a more distal site from the IL. We report here a rare case of MP caused by entrapment of the LFCN at the fascia lata of the thigh level. A 23-year-old man felt numbness and sharp pain at the anterolateral aspects of both thighs soon after direct repair surgery for L5 isthmic spondylolisthesis. Although his symptoms were relieved a few days later, numbness and sharp pain in the right thigh recurred 6 months after the surgery. A diagnosis of MP was made, and decompression of the LFCN was performed because conservative treatment for MP was inadequate. Intraoperatively, it was noted that the LFCN was entrapped underneath the fascia lata of the thigh, not at the IL level. His symptoms disappeared after LFCN was released. This case demonstrates that it is necessary to consider the possibility of entrapment of the LFCN at the fascia lata at the thigh level in MP. *J. Med. Invest.* 62 : 248-250, August, 2015

**Keywords :** meralgia paresthetica, lateral femoral subcutaneous nerve, surgical treatment

## INTRODUCTION

Meralgia paresthetica (MP), which is a mononeuropathy of the lateral femoral cutaneous nerve (LFCN), is characterized by symptoms of pain, numbness, itching and paresthesia at the anterolateral thigh (1-3). Hager *et al.* first reported its symptoms (4), and Bernhardt *et al.* presumed that the symptoms were caused by compression of the LFCN (5). MP has an incidence of 4-10/10,000 people and usually occurs in those aged 30-40 years (6-8). It is commonly caused by mechanical pressure exerted on the LFCN, such as pressure from wearing tight underwear or a lumbar brace and from prone positioning (9, 10). The incidence of MP in posterior spine surgery was reported to be 23.8% by Yang *et al.*, 20% by Mirovsky *et al.* and 12% by Gupta *et al.* (11-13). Entrapment of the LFCN at the inguinal ligament (IL) level is common (14). Surgical intervention such as neurolysis is indicated only if intractable pain persists because approximately 60-90% of MP improves with conservative treatment (15-18). We report here a rare case of refractory MP caused by entrapment of the LFCN at the fascia lata of the thigh, which is more distal than the IL, and successful treatment with neurolysis.

## CASE REPORT

A 22-year-old man underwent direct repair surgery for L5 isthmic spondylolisthesis. Numbness and pain at the anterolateral aspects of both thighs occurred soon after surgery but the symptoms improved after a few days. However, he felt numbness, pain and dysesthesia in the right anterolateral thigh 6 months after surgery.

The symptoms were aggravated in a sitting position and by hip flexion. He felt radiating pain to the right anterolateral thigh on pressing a site 5 cm distal to the right anterior superior iliac spine (ASIS). Muscle strength and deep tendon reflex of the right leg were normal. There were no specific findings in the right hip. Magnetic resonance imaging did not show a herniated disk or a lesion in the lumbar spine or pelvic cavity. Somatosensory evoked potentials of the LFCN did not exhibit latency on the affected side. His symptoms were only temporarily relieved by local injection with mepivacaine and dexamethasone into the site 5 cm distal to the right ASIS. A diagnosis of MP was made and neurolysis of the LFCN was performed.

An oblique 5 cm incision was made distally starting from the site 1 cm medial to the right ASIS. Intraoperatively, it was noted that the LFCN passed under the IL and was not compressed at the IL level (Fig. 1a). The LFCN was then exposed by cutting the fascia lata of the thigh distally. The LFCN ran over sartorius and it was entrapped underneath the fascia lata of the thigh, where it was 5 cm distal to the ASIS (Fig. 1b). The LFCN insertion site of the fascia lata of the thigh could not be found, but it seemed to be more distal than usual. Complete decompression of the LFCN was performed at the level of the fascia lata of the thigh (Fig. 1c).

Numbness, pain and dysesthesia in the right anterolateral thigh disappeared soon after surgery and he could sit without experiencing symptoms. There was no recurrence of MP 1 year after surgery.

## DISCUSSION

The LFCN, which is a sensory nerve, arises from the L2-L3 vertebrae nerve roots and runs on the lateral aspect of the iliopsoas muscle. It passes under the IL and runs over the sartorius. It then emerges through the fascia lata of the thigh and is distributed over the skin of the bottom to innervate the anterolateral aspect of the thigh. MP caused by compression of the LFCN at the IL level is common because the LFCN bends at an angle of about 90 degrees

Received for publication March 20, 2015 ; accepted April 6, 2015.

Address correspondence and reprint requests to Koichi Sairyo, MD, PhD, Department of Orthopedics, Tokushima University 3-18-15 Kuramoto, Tokushima 770-8503, Japan and Fax : +81-88-633-0178.

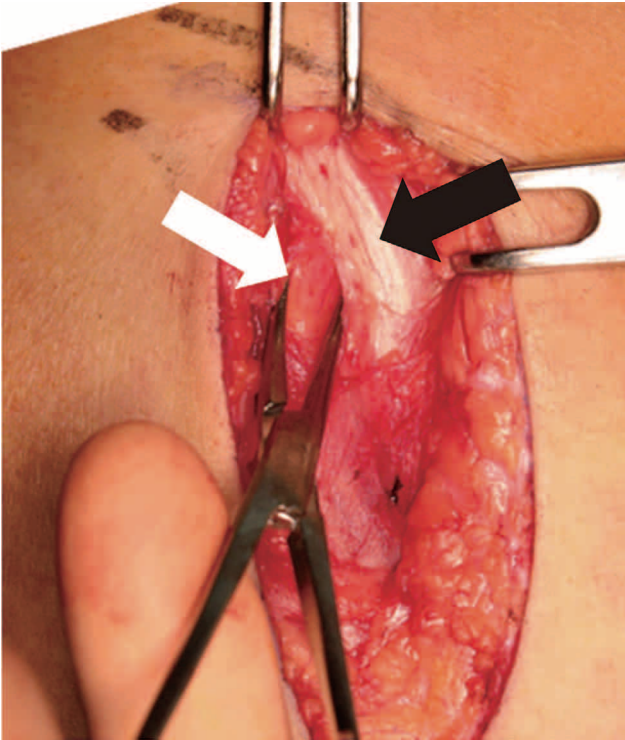


Fig. 1a : Intraoperative photograph showing exploration of the lateral femoral cutaneous nerve (white arrow) and the inguinal ligament (black arrow). The lateral femoral cutaneous nerve was not compressed at the inguinal ligament level.

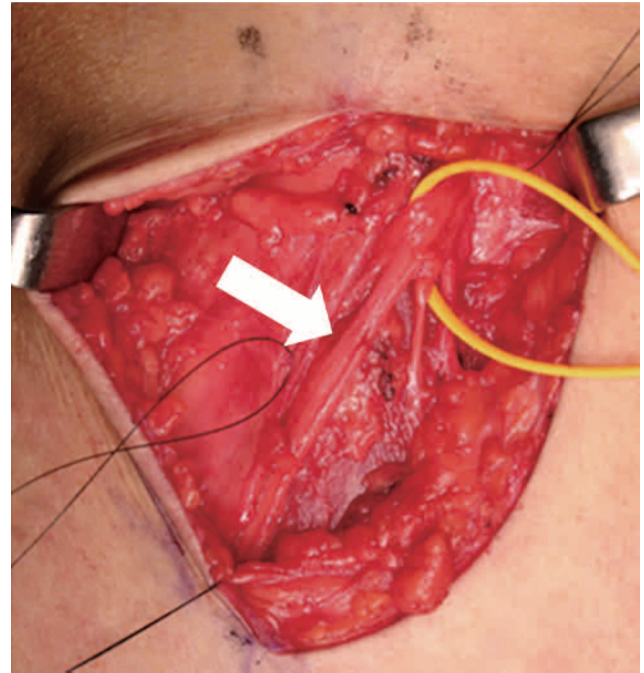


Fig. 1c : The lateral femoral cutaneous nerve was completely released. White arrow showed the entrapment site of the nerve.

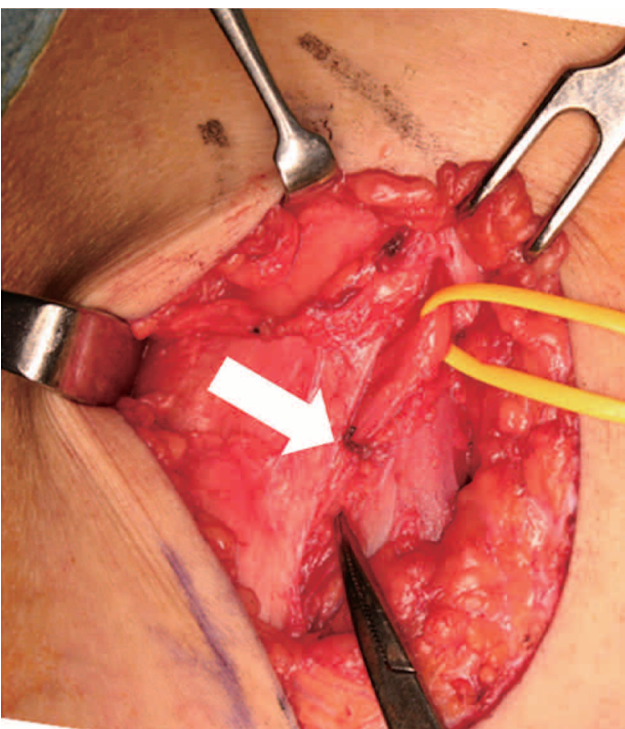


Fig. 1b : The lateral femoral cutaneous nerve was entrapped at the fascia lata of the thigh (white arrow).

to pass from the pelvis through the inguinal ligament to the thigh (14). The LFCN usually penetrates the fascia lata of the thigh at a site 2-3 cm distal to the ASIS and is distributed subcutaneously (2).

However, in this case, entrapment of the LFCN occurred at the site 5 cm distal to the ASIS, underneath the fascia lata at the thigh level, not at the IL level. LFCN entrapment at a site distal to the IL level is rare, although there are many anomalies of the LFCN (19, 20). To our knowledge, it is reported in only 4 reports with 6 cases that entrapment site of the LFCN is distal to the IL (Table 1). Sato *et al.* reported that the LCN was entrapped at the insertion site of the thigh (21), and Edelson *et al.* reported that it was entrapped by the fascia in the region of the insertion of sartorius (22). Siu *et al.* reported that the entrapment site of the LFCN was more than 5 cm inferomedial to the ASIS, (23) and Carai *et al.* reported that the entrapment site of the LFCN was where it pierced the fascia at the medial margin of sartorius to reach the lateral side of the thigh (24). If an anomalous LFCN emerges through the fascia lata of the thigh more distally than usual, it may be entrapped easily because the LFCN is fixed at a more superficial subcutaneous tissue level. Therefore, the prone position during direct repair surgery for L5 isthmic spondylolisthesis might be a trigger for MP in this case.

Symptoms of MP are usually exacerbated by hip extension because the LFCN experiences tension at the IL level (18, 25-27). However, our patient experienced exacerbation with hip flexion. Aggravated symptoms with hip flexion may suggest entrapment of the LFCN at the fascia lata at the thigh level because the above-mentioned anomaly, as observed in the present case, leads to impingement between the LFCN and the fascia lata of the thigh with hip flexion.

In summary, we reported a rare case of MP caused by the entrapment of the LFCN at the fascia lata of the thigh where it was distal to the IL. Physicians should be aware that the more distal site at the fascia lata of the thigh could be responsible for MP.

**Table 1** : Summary of case reports of meralgia paresthetica caused by entrapment of the lateral femoral cutaneous nerve at a level distal to the inguinal ligament.

Author and year	Age (years old)	Sex	Side	Duration of symptom (months)	Entrapment site of LFCN	Surgery	Result	Duration of follow-up (months)
Sato K <i>et al.</i> , 1988	13	Female	Right	5	Insertion site of the fascia lata of the thigh	Neurolysis	Persistent relief	4
Edelson R <i>et al.</i> , 1994	15	Male	Left	18	Insertion site of sartorius	Neurolysis	Good	35
	4	Male	Left	84	Insertion site of sartorius	Neurolysis	Excellent	33
Siu TL <i>et al.</i> , 2005	Middle age (1 in 42 patients)	N/A	N/A	N/A	5 cm inferomedial site from ASIS	Neurolysis	Persistent relief	N/A
Cari A <i>et al.</i> , 2009	N/A (2 in 148 patients)	N/A	N/A	N/A	The site where LFCN pierces the fascia at the medial margin of sartorius to reach the thigh	Neurolysis	N/A	N/A
This case, 2015	22	Male	Right	6	Underneath the fascia lata of the thigh where is 5 cm distal from ASIS	Neurolysis	Persistent relief	12

LFCN ; lateral femoral cutaneous nerve, ASIS ; anterior superior iliac spine, N/A ; not available.

## CONFLICT OF INTEREST

There are no conflicts of interest to disclose.

## REFERENCES

- Grossman MG, Ducey SA, Nadler SS, Levy AS : Meralgia paresthetica : diagnosis and treatment. *J Am Acad Orthop Surg* 9(5) : 336-344, 2001
- Ivins GK : Meralgia paresthetica, the elusive diagnosis : clinical experience with 14 adult patients. *Ann Surg* 232(2) : 281-286, 2000
- de Ridder VA, de Lange S, Popta JV : Anatomical variations of the lateral femoral cutaneous nerve and the consequences for surgery. *J Orthop Trauma* 13(3) : 207-211, 1999
- Heger W : Neuralgia femoris : Resection des Nervus cutaneus femoris anterior externus. *Heilung. Deutsche med Wochenshr* 11 : 218, 1885
- Bernhardt M : Uber isolirt im Gebiete des Nervus cutaneus femoris externus vorkommende parasthesien. *Neurol Centralbl* 14 : 242-244, 1895
- van Slobbe AM, Bohnen AM, Bernsen RM, Koes BW, Bierma-Zeinstra SM : Incidence rates and determinants in meralgia paresthetica in general practice. *J Neurol* 251(3) : 294-297, 2004
- Latinovic R, Gulliford MC, Hughes RA : Incidence of common compressive neuropathies in primary care. *J Neurol Neurosurg Psychiatry* 77(2) : 263-265, 2006
- Ecker AD : Diagnosis of meralgia paresthetica. *JAMA* 253(7) : 976, 1985
- Boyce JR : Meralgia paresthetica and tight trousers. *JAMA* 251(12) : 1553, 1984
- Baldini M, Raimondi PL, Princi L : Meralgia paraesthetica following weight loss. Case report. *Neurosurg Rev* 5(2) : 45-47, 1982
- Yang SH, Wu CC, Chen PQ : Postoperative meralgia paresthetica after posterior spine surgery : incidence, risk factors, and clinical outcomes. *Spine (Phila Pa 1976)* 30(18) : E547-550, 2005
- Mirovsky Y, Neuwirth M : Injuries to the lateral femoral cutaneous nerve during spine surgery. *Spine (Phila Pa 1976)* 25(10) : 1266-1269, 2000
- Gupta A, Muzumdar D, Ramani PS : Meralgia paraesthetica following lumbar spine surgery : a study in 110 consecutive surgically treated cases. *Neurol India* 52(1) : 64-66, 2004
- Ghent WR : Further studies on meralgia paresthetica. *Can Med Assoc J* 85 : 871-875, 1961
- Ducic I, Dellon AL, Taylor NS : Decompression of the lateral femoral cutaneous nerve in the treatment of meralgia paresthetica. *J Reconstr Microsurg* 22(2) : 113-118, 2006
- Nahabedian MY, Dellon AL : Meralgia paresthetica : etiology, diagnosis, and outcome of surgical decompression. *Ann Plast Surg* 35(6) : 590-594, 1995
- Haim A, Pritsch T, Ben-Galim P, Dekel S : Meralgia paresthetica : A retrospective analysis of 79 patients evaluated and treated according to a standard algorithm. *Acta Orthop* 77(3) : 482-486, 2006
- Williams PH, Trzil KP : Management of meralgia paresthetica. *J Neurosurg* 74(1) : 76-80, 1991
- Aszmann OC, Dellon ES, Dellon AL : Anatomical course of the lateral femoral cutaneous nerve and its susceptibility to compression and injury. *Plast Reconstr Surg* 100(3) : 600-604, 1997
- Keegan JJ, Holyoke EA : Meralgia paresthetica. An anatomical and surgical study. *J Neurosurg* 19 : 341-345, 1962
- Sato K, Terauchi M, Yano S, Kanehara H : Superficial peroneal nerve entrapment : a case followed by entrapment neuropathy of the lateral femoral cutaneous nerve. *Rinsyo Seikeigeka* 23(6) : 795-798, 1988
- Edelson R, Stevens P : Meralgia paresthetica in children. *J Bone Joint Surg Am* 76(7) : 993-999, 1994
- Siu TL, Chandran KN : Neurolysis for meralgia paresthetica : an operative series of 45 cases. *Surg Neurol* 63(1) : 19-23, 2005
- Carai A, Fenu G, Sechi E, Crotti FM, Montella A : Anatomical variability of the lateral femoral cutaneous nerve : findings from a surgical series. *Clin Anat* 22(3) : 365-370, 2009
- Cheatham SW, Kolber MJ, Salamh PA : Meralgia paresthetica : a review of the literature. *Int J Sports Phys Ther* 8(6) : 883-893, 2013
- de Ruyter GC, Wurzer JA, Kloet A : Decision making in the surgical treatment of meralgia paresthetica : neurolysis versus neurectomy. *Acta Neurochir (Wien)* 154(10) : 1765-1772, 2012
- Chen CK, Phui VE, Saman MA : Alcohol neurolysis of lateral femoral cutaneous nerve for recurrent meralgia paresthetica. *Agri* 24(1) : 42-44, 2012