

ORIGINAL

Forearm lengthening by distraction osteogenesis : A report on 5 limbs in 3 cases

Ichiro Tonogai, Mitsuhiro Takahashi, Takahiko Tsutsui, Tomohiro Goto, Daisuke Hamada, Naoto Suzue, Tetsuya Matsuura, Natsuo Yasui, and Koichi Sairyo

Department of Orthopedics, Tokushima University, Tokushima, Japan

Abstract : Radioulnar length discrepancy causes pain and decreases function of the wrist, forearm, and elbow. Limb lengthening, which has been used in the treatment of various deformities of the forearm, is necessary to restore balance between the ulna and radius. We treated 5 limbs in 3 patients (2 boys, 1 girl ; mean age 9.3 years old) with radioulnar length discrepancy by distraction osteogenesis of either the ulna or radius using external fixators. We dissected the interosseous membrane between the ulna and radius in 3 limbs in 2 cases and did not do so in 2 limbs of 1 case. These cases include 2 cases with hereditary multiple exostoses, and 1 case with multiple epiphyseal dysplasia. The results were investigated and evaluated in this study, using appropriate clinical and radiographic parameters, noting the state of the interosseous membrane, which has an important role in forearm stability. The mean fixation period was 113 days. The mean distraction distance was 22.8 mm. The mean follow-up period was 637.7 days. The mean ulnar shortening and radial articular angle respectively improved from 7.4 mm and 30.2° preoperatively to -0.1 mm and 34.8° postoperatively. Balance between the ulna and radius was restored, and the results showed significant improvements in range of motion of the joints. However, 2 unintended radial head subluxations occurred in 2 limbs without dissection of the interosseous membrane. In addition, a keloid remained in 1 limb due to pin site infection. Forearm lengthening by distraction osteogenesis was useful in our cases. It is important to recognize the function of the interosseous membrane when lengthening is performed by osteotomy of the proximal ulna by gradual distraction with an external fixator. *J. Med. Invest.* 62 : 219-222, August, 2015

Keywords : distraction osteogenesis, forearm, lengthening, interosseous membrane, external fixator

INTRODUCTION

Radioulnar length discrepancy occurs in conditions such as multiple exostoses, skeletal dysplasia, and posttraumatic epiphyseal arrest (1) and can cause aesthetic and functional problems.

Limb lengthening by distraction osteogenesis is useful for treating limb length discrepancy and can be applied to correct the relationship between the ulna and radius. However, little has been published on upper limb lengthening, particularly in the forearm (2), although the upper limb has different alignment requirements from those in the lower limb and moderate discrepancies in forearm length do not usually produce a significant functional deficit (3).

The interosseous membrane contributes to the longitudinal stiffness of the forearm, stabilization of the radius and ulna, transmission of force from the hand to the humerus, and load transfer (4-7). In spite of the importance of the interosseous membrane, few reports have considered it in limb lengthening of the forearm (8-10).

The aims of this study were to analyze the results of treatment for short ulna or radius by limb lengthening in our hospital and to report outcomes, noting whether the interosseous membrane should be dissected, especially in proximal ulnar lengthening.

MATERIALS AND METHODS

The results of forearm lengthening in 5 forearms of 3 patients between 2002 and 2013 are reported. The indication for lengthening was symptomatic loss of movement of the joints in all cases. All patients were evaluated clinically by radiography, physical examination, and functional outcome assessments. Parameters that were assessed preoperatively and postoperatively included range of motion (ROM) of the wrist, forearm, and elbow ; complications ; duration of external fixation ; distraction length ; external fixation index, ulnar shortening (US), and radial articular angle (RAA). RAA is the angle between a line running along the articular surface of the distal radius and another line joining the center of the radial head to the radial border of the distal radial epiphysis. The normal range of RAA is 15-30°.

The patients were 2 boys and 1 girl aged 8 to 11 (mean, 9.3) years old. The original diseases were multiple epiphyseal dysplasia (2 limbs in 1 case) and hereditary multiple exostoses (3 limbs in 2 cases). Preoperatively, 4 had varus deviation of the hands due to a short ulna, and 1 had valgus hand deviation due to a short radius with a limited range of radial or ulna deviation. The ulna was lengthened in 4 limbs and the radius in 1 limb. Orthofix was used for 3 limbs and an Ilizarov apparatus for 2 limbs. Dissection of the interosseous membrane was performed in 3 limbs in 2 cases and it was not performed in 2 limbs in 1 case. Lengthening proceeded until reaching the target length. The external fixator was removed when good cortical union was seen. The follow-up period ranged from 358 to 1011 (mean, 637.7) days.

Received for publication April 21, 2015 ; accepted June 19, 2015.

Address correspondence and reprint requests to Koichi Sairyo, MD, PhD, Department of Orthopedics, Tokushima University 3-18-15 Kuramoto, Tokushima 770-8503, Japan and Fax : +81-88-633-0178.

RESULTS

Patient details, including preoperative and postoperative values of parameters, are shown in Table 1. The duration of distraction was between 93 and 129 (mean, 113) days. The lengthening obtained in the forearm bone ranged 17-28 (mean, 22.8) mm. The external fixation index ranged from 44.3 to 52.1 (mean, 49.8) days/cm. Mean US was improved from 7.4 mm to -0.1 mm, and mean RAA was improved from 30.2° to 34.8°.

The deformities were corrected on schedule and values of parameters were normalized in all cases. In all patients the appearance was improved. In the 4 varus hands, the range of ulnar deviation improved. We have encountered no neurovascular problems, but 2 cases were complicated by radial head subluxation, both in the absence of interosseous membrane dissection, and 1 patient developed a keloid due to a pin site infection in 1 limb.

We show two representative cases : one without interosseous membrane dissection and another with dissection of the interosseous membrane in proximal ulnar lengthening.

Case 1.

A 9-year-old boy presented with bilateral varus hands due to

epiphyseal dysplasia in the distal ulna. Multiple epiphyseal dysplasia is a common form of skeletal dysplasia characterized by a delay in the appearance of the epiphyses, irregular epiphyseal formation, short stature, and early-onset osteoarthritis (11).

Physical examination revealed that radial deviation of the wrists was restricted to -20° on the right and -15° on the left, whereas ulnar deviation was extended to 70° on the right and 65° on the left. Radiographs showed a US of 13 mm on the left and 12 mm on the right, associated with epiphyseal dysplasia in the distal end (Fig. 1a).

To correct these, we performed lengthening of both ulnae using Orthofix external fixators without dissection of the interosseous membrane. The malalignments of his wrists were successfully treated with limb lengthening procedures. Both ulnas were gradually lengthened 24 mm to offset subsequent recurrence of shortening, which was expected because of his bony immaturity. US improved from 13 mm on the right and 12 mm on the left preoperatively to -3 on the right and -2 mm on the left postoperatively (Fig. 1b). Bone formation and remodeling were normal during the treatment course. The external fixators were removed 125 days after osteotomy on both sides.

At 544 days after osteotomy, the ulnas showed appropriate length

Table 1. Demographic data and results for the patients treated with external fixator.

Case	Age (years)	Sex	Side	Lengthened bone	Underlying disease	Preoperative condition	Additional procedure	Type of external fixator	Duration of fixator treatment (days)	Follow-up Period (days)	Distraction distance (mm)	External fixation index (days/cm)	Complication
1	9	male	Right	Ulna	Multiple epiphyseal dysplasia	Varus hand		Orthofix	125	544	24	52.1	Subluxation of radial head
			Left	Ulna		Varus hand	Orthofix	125	24		52.1	Subluxation of radial head	
2	8	Female	Right	Ulna	Hereditary multiple exostoses	Varus hand	Partial resection of exocitosis Dissection of interosseous membrane	Orthofix	93	358	21	44.3	
			Left	Radius		Valgus hand	Partial resection of exocitosis Dissection of interosseous membrane	Ilizarov	93		17	54.7	Keloid
3	11	male	Right	Ulna	Hereditary multiple exostoses	Varus hand	Partial resection of exocitosis Dissection of interosseous membrane	Ilizarov	129	1011	28	46.1	
Mean	9.3								113	637.7	22.8	49.8	

Case	US (mm)		RAA (degrees)		Elbow		Forearm		Wrist			
	Preop	Postop	Preop	Postop	Extension/Flexion (degrees)		Supination/Pronation (degrees)		Dorsal/Palmar flexion (degrees)		Radial/Ulnar deviation (degrees)	
					Preop	Postop	Preop	Postop	Preop	Postop	Preop	Postop
1	13	-3	38	46	0/130	0/130	100/90	100/90	90/90	90/90	-20/70	10/50
	12	-2	39	41	0/130	0/130	100/90	100/90	90/90	90/90	-15/65	10/50
2	6	-2	32	24	0/140	0/140	90/80	90/90	90/90	90/90	5/65	25/50
	-8	2	8	27	0/140	0/140	90/80	90/90	80/85	90/90	35/35	25/50
3	14	4.5	34	36	0/130	0/130	85/60	85/75	90/90	90/90	5/65	10/60
Mean	7.4	-0.1	30.2	34.8	0/134	0/134	93/80	93/87	88/89	90/90	2/60	16/52

US ; ulnar shortening, RAA ; radial articular angle

with improved appearance and function in the wrists. However, radial deviation of the wrists was slightly limited to 5°. The radial heads developed subluxation following distraction osteogenesis, which gradually decreased following periods (Fig. 1c). He had no functional problems and no complaint in daily life at the final follow-up.

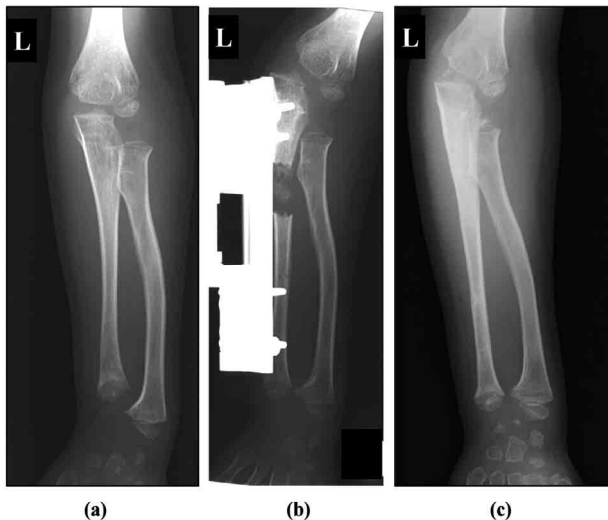


Fig. 1. Case 1 : (a) A radiograph of the left forearm of a 9-year-old boy, showing his shortened ulna before osteotomy. (b) A radiograph showing distraction osteogenesis of the left ulna with an Orthofix at the end of the distraction procedure. (c) A radiograph at 544 days after osteotomy, showing appropriate distal joint alignment of the left radius and ulna at 544 days after osteotomy, though the left radial head tended to subluxate.

Case 2.

An 8-year-old girl gradually developed left valgus hand and right varus hand due to multiple exostoses, the most common benign osseous tumors of childhood. They are attended by growth disturbance, limb length discrepancies, and various deformities (12, 13).

The radial deviation of the right wrist was restricted to 5° and the ulnar deviation of the left wrist was restricted to 35°. Preoperative radiographs showed right ulnar and left radial shortening. US was 6 mm on the right and -8 mm on the left. The RAA was 32° on the right and 8° on the left (Fig. 2a).

An Orthofix fixator was used on the right ulna. An Ilizarov apparatus was used on the left radius for the additional purpose of correction of the deformity. On the right, an osteotomy was made in the right proximal ulna and the distal right ulnar exostosis was partially removed without dissection of the interosseous membrane. The right ulna and left radius were gradually lengthened by 21 and 17 mm, respectively, to offset subsequent recurrence of shortening expected due to her bony immaturity, with a postoperative US of -2 at the right side and 2 mm at the left side (Fig. 2b). RAA was improved to 24° on the right and 27° on the left (Fig. 2b). The deformities of the distal forearms were corrected. Bone formation and remodeling were normal during the treatment course. The external fixators were removed 93 days after osteotomy.

At 358 days after osteotomy, the left ulna and right radius showed appropriate length with improved appearance (Fig. 2c) and function in the wrists. Radial deviation was 25° bilaterally and ulnar deviation was 50° bilaterally, but a pin site keloid remained in the left forearm due to a superficial pin site infection.

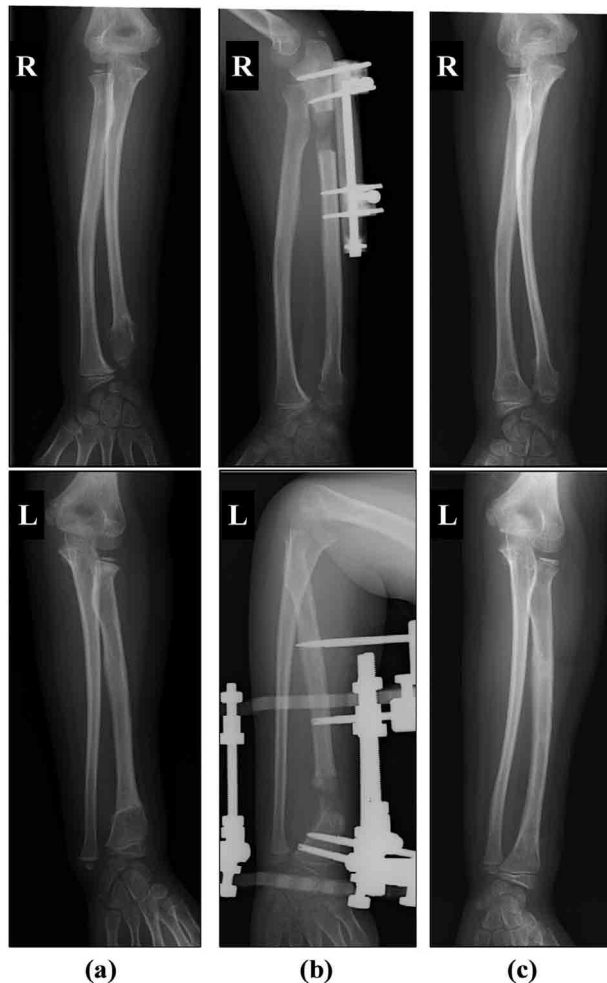

Fig. 2. Case 2 : (a) Radiographs of the forearms of an 8-year-old girl, showing hypoplastic left distal radius and right distal ulna with large distal exostoses, before osteotomy. (b) Radiographs showing distraction osteogenesis of the right ulna with Orthofix and the left radius with Ilizarov frame immediately after the completion of the lengthening. (c) At 358 days after osteotomy, radiographs showed no radial head subluxation and the angular deformity of the right radius was corrected.

DISCUSSION

There is consensus on the need to correct radioulnar length discrepancy by the time of growth plate arrest (13, 14), because it causes limited ROM in the wrist, forearm, and elbow. We reported results of 5 forearms in 3 cases of deformity and shortening of the forearm with multiple epiphyseal dysplasia or hereditary multiple exostoses by bone lengthening using an Orthofix or Ilizarov apparatus. In all our cases, the discrepancy between radius and ulna was corrected and the range of wrist joint motion improved.

In our cases, as the mean length of elongation was 22.8 mm and the achieved US ranged from a preoperative 7.4 mm to postoperative 0.1 mm, approximately 10 mm of overlengthening tend to disappear in the treatment course. Many investigators have recommended ulnar overlengthening of 0.5 to 1.0 cm in immature patients to reduce the risk of significant recurrence (1, 15, 16). As they have reported, initial overcorrection may be tolerated to reduce recurrence of the ulnar or radial shortening.

The normal contribution of the distal physes to longitudinal growth is 75% in the radius and 85% in the ulna (17), while the ulnar physis is one quarter of the diameter of that of the radius and

is therefore more vulnerable to growth impairment (18-21). In our cases, we had more short ulnas than radia. The distal ulna seems to be more commonly involved in the impairment than the distal radius. This may be why it has been reported that the best ulnar osteotomy is as proximal as possible in ulna (22). In addition, this may provide better bone union in the distracted callus. On the other hand, angular deformity may be easily accompanied by partial prevention of growth, because the epiphyseal plate of the distal radius is wider than that of the ulna. This may be the reason the radius shows a tendency toward angular deformity, as seen in the preoperative RAA of 8° on the left side in case 2.

Radial head subluxation occurred in 2 limbs in 1 case without dissection of the interosseous membrane, and the potential for a valgus deformity of the elbow and joint instability is a concern. This might be caused by use of an external fixator, which causes the interosseous membrane to drag the radius distally. This indicates that the character of the interosseous membrane and change of tension are important factors. Mori *et al.* reported that subluxation of the radial head was reduced by dissecting the interosseous membrane (8). Masada *et al.* reported that temporary radial head subluxation and resultant radial nerve palsy during ulnar distraction osteotomy was relieved by dissection of the interosseous membrane (9). Kawanishi *et al.* reported that the dissection was important in order to protect from radial head subluxation in lengthening of the ulna (10). When there is concern for potential radial head subluxation, resection of the interosseous membrane may be taken into consideration as we did in cases 2 and 3.

On the other hand, the interosseous membrane contributes to longitudinal stiffness of the forearm, stabilization of the radius and ulna, transmission of force from the hand to the humerus, and load transfer (4-7). In cases 2 and 3, the patients had no complaint at the final follow-up, but we are worried about long-term loss of transverse stability from the interosseous membrane, which prevents splaying of the ulna and radius during forearm compression. To avoid radial head subluxation during limb lengthening in the forearm, a more distal osteotomy site may be preferable. However, it should be kept in mind that any interruption can lead to severe deformity if the distal ulnar growth plate is injured during distal ulnar distraction, because the distal ulna is more commonly involved in the impairment than the distal radius. In distal ulnar lengthening, attention should also be given to the prevention of distal ulna fracture, the shortage of distal pin insertion space, and the disadvantage for bone union, because the distal ulna has smaller cross-sectional area than the distal radius.

Forearm lengthening by distraction osteogenesis was useful in our cases. In lengthening > 20 mm in the proximal ulna, dissection of interosseous membrane may be preferable but careful follow-up is necessary because the function of interosseous membrane is lost to some extent.

ACKNOWLEDGEMENTS

There are no conflicts of interest to disclose.

REFERENCES

- Cheng JC : Distraction lengthening of the forearm. *J Hand Surg Br* 16(4) : 441-445, 1991
- Hill RA, Ibrahim T, Mann HA, Siapkara A : Forearm lengthening by distraction osteogenesis in children : a report of 22 cases. *J Bone Joint Surg Br* 93(11) : 1550-1555, 2011
- Mader K, Gausepohl T, Pennig D : Shortening and deformity of radius and ulna in children : correction of axis and length by callus distraction. *J Pediatr Orthop B* 12(3) : 183-191, 2003
- Hotchkiss RN, An KN, Sowa DT, Basta S, Weiland AJ : An anatomic and mechanical study of the interosseous membrane of the forearm : pathomechanics of proximal migration of the radius. *J Hand Surg Am* 14(2 Pt 1) : 256-261, 1989
- Rabinowitz RS, Light TR, Havey RM, Gourineni P, Patwardhan AG, Sartori MJ, Vrboš L : The role of the interosseous membrane and triangular fibrocartilage complex in forearm stability. *J Hand Surg Am* 19(3) : 385-393, 1994
- Birkbeck DP, Failla JM, Hoshaw SJ, Fyhrie DP, Schaffler M : The interosseous membrane affects load distribution in the forearm. *J Hand Surg Am* 22(6) : 975-980, 1997
- Pfaeffle HJ, Fischer KJ, Manson TT, Tomaino MM, Woo SL, Herndon JH : Role of the forearm interosseous ligament : is it more than just longitudinal load transfer? *J Hand Surg Am* 25(4) : 683-688, 2000
- Mori K : Experimental study on rotation of the forearm : functional anatomy of the interosseous membrane. *J Jpn Orthop Assoc* 59 : 611-622, 1985
- Masada K, Tsuyuguchi Y, Kawai H, Kawabata H, Noguchi K, Ono K : Operations for forearm deformity caused by multiple osteochondromas. *J Bone Joint Surg Br* 71(1) : 24-29, 1989
- Kawanishi H : Pronation limitation caused by forearm lengthening. *J Jpn Soc Surg Hand* 10 : 75-79, 1993
- Takahashi M, Matsui Y, Goto T, Nishimura G, Ikegawa S, Ohashi H, Yasui N : Intrafamilial phenotypic diversity in multiple epiphyseal dysplasia associated with a COL9A2 mutation (EDM2). *Clin Rheumatol* 25(4) : 591-595, 2006
- Schmale GA, Conrad EU 3rd, Raskind WH : The natural history of hereditary multiple exostoses. *J Bone Joint Surg Am* 76(7) : 986-992, 1994
- Matsubara H, Tsuchiya H, Sakurakichi K, Yamashiro T, Watanabe K, Tomita K : Correction and lengthening for deformities of the forearm in multiple cartilaginous exostoses. *J Orthop Sci* 11(5) : 459-466, 2006
- Ettl V, Wild A, Thorey F, Kirschner S, Krauspe R, Raab P : Correction of forearm deformities in children with multiple cartilaginous osteochondromas. *Z Orthop Ihre Grenzgeb* 143(1) : 106-111, 2005
- Pritchett JW : Lengthening the ulna in patients with hereditary multiple exostoses. *J Bone Joint Surg Br* 68(4) : 561-565, 1986
- Abe M, Shirai H, Okamoto M, Onomura T : Lengthening of the forearm by callus distraction. *J Hand Surg Br* 21(2) : 151-163, 1996
- Noonan KJ, Price CT : Forearm and distal radius fractures in children. *J Am Acad Orthop Surg* 6(3) : 146-156, 1998
- Shapiro F, Simon S, Glimcher MJ : Hereditary multiple exostoses. Anthropometric, roentgenographic, and clinical aspects. *J Bone Joint Surg Am* 61(6A) : 815-824, 1979
- Fogel GR, McElfresh EC, Peterson HA, Wicklund PT : Management of deformities of the forearm in multiple hereditary osteochondromas. *J Bone Joint Surg Am* 66(5) : 670-680, 1984
- Wood VE, Sauser D, Mudge D : The treatment of hereditary multiple exostosis of the upper extremity. *J Hand Surg Am* 10(4) : 505-513, 1985
- Pritchett JW : Lengthening the ulna in patients with hereditary multiple exostoses. *J Bone Joint Surg Br* 68(4) : 561-565, 1986
- Fujita M : An Anatomical Study on the Interosseous Membrane of the Forearm. *J Jpn Orthop Assoc* 69 : 938-950, 1995