

## REVIEW

# State-of-the-art ultrasonographic findings in lower extremity sports injuries

Naoto Suzue<sup>(1)</sup>, Tetsuya Matsuura<sup>(1)</sup>, Toshiyuki Iwame<sup>(2)</sup>, Kosaku Higashino<sup>(1)</sup>, Toshinori Sakai<sup>(1)</sup>, Daisuke Hamada<sup>(1)</sup>, Tomohiro Goto<sup>(1)</sup>, Yoichiro Takata<sup>(1)</sup>, Toshihiko Nishisho<sup>(1)</sup>, Yuichiro Goda<sup>(1)</sup>, Takahiko Tsutsui<sup>(1)</sup>, Ichiro Tonogai<sup>(1)</sup>, Ryo Miyagi<sup>(1)</sup>, Mitsunobu Abe<sup>(1)</sup>, Masatoshi Morimoto<sup>(1)</sup>, Kazuaki Mineta<sup>(1)</sup>, Tetsuya Kimura<sup>(1)</sup>, Akihiro Nitta<sup>(1)</sup>, Tadahiro Higuchi<sup>(1)</sup>, Shingo Hama<sup>(1)</sup>, Subash C. Jha<sup>(1)</sup>, Rui Takahashi<sup>(1)</sup>, Shoji Fukuta<sup>(1)</sup>, and Koichi Sairoy<sup>(1)</sup>

<sup>(1)</sup>Department of Orthopedics, the University of Tokushima, Tokushima, Japan, <sup>(2)</sup>Department of Orthopaedic Surgery, Tokushima Prefectural Central Hospital, Tokushima, Japan

**Abstract :** Athletes sometimes experience overuse injuries. To diagnose these injuries, ultrasonography is often more useful than plain radiography, computed tomography (CT), or magnetic resonance imaging (MRI). Ultrasonography can show both bone and soft tissue from various angles as needed, providing great detail in many cases. In conditions such as osteochondrosis or enthesopathies such as Osgood-Schlatter disease, Sinding-Larsen-Johansson disease, bipartite patella, osteochondritis dissecans of the knee, painful accessory navicular, and jumper's knee, ultrasonography can reveal certain types of bony irregularities or neovascularization of the surrounding tissue. In patients of enthesopathy, ultrasonography can show the degenerative changes at the insertion of the tendon. Given its usefulness in treatment, ultrasonography is expected to become essential in the management of overuse injuries affecting the lower limb in athletes. *J. Med. Invest.* 62 : 109-113, August, 2015

**Keywords :** ultrasonography, sports injury, over use, osteochondrosis, enthesopathy

## INTRODUCTION

The three major imaging modalities used for the diagnosis of musculoskeletal disorders are plain radiography, computed tomography (CT), and magnetic resonance imaging (MRI). Ultrasonography has recently become a notable fourth imaging modality as a result of various technical advances such as the improvement of linear high-frequency probe. Generally, plain radiographs and CT are useful for bone injuries such as fractures, while MRI is useful for bone and soft tissue disorders. Each of these examinations has its merits and demerits and they are often used to complement each other. However, ultrasonography can show both bone and soft tissue from various angles as needed, providing greater detail in many cases compared with other imaging modalities.

Athletes often experience overuse injuries. Pain typically occurs in the joints under high load in a particular sport, such as the elbow joint in baseball players and the ankle and foot in soccer players. To diagnose these injuries, ultrasonography is often more useful than plain radiography, CT, or MRI.

In this report, we introduce some characteristic ultrasonographic findings in sports injuries affecting the lower extremity.

## OSGOOD-SCHLATTER DISEASE

Osgood-Schlatter disease was first described by Robert Osgood and Carl Schlatter in 1903 (1, 2). The main cause of this injury is repetitive traumatic traction at the tibial tuberosity by the quadriceps muscle. The traction force causes destruction of the apophysis. Onset of Osgood-Schlatter disease typically occurs in

adolescents aged 10 to 14 years, and affects mainly boys involved in sports such as soccer, basketball, and volleyball (3). Characteristic symptoms include pain on motion and tenderness and swelling of the tibial tuberosity.

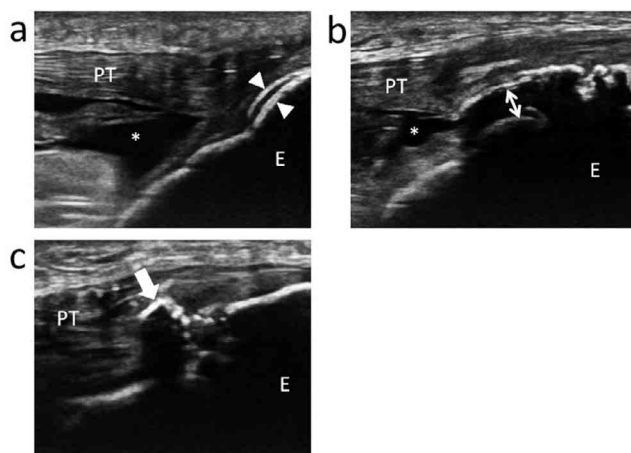
Diagnosis is generally made based on clinical symptoms, but imaging methods can show certain characteristic findings. Plain radiography or CT images show an abnormality in the secondary ossification center, ranging from irregularity of the apophysis with separation from the tibial tuberosity to fragmentation. On the other hand, ultrasonography can show greater detail for the area surrounding the attachment of the patellar tendon. It can detect every pathological feature in the clinical course including cartilage swelling, fragmentation of the tuberosity ossification center, patellar tendon lesions, and reactive bursitis (3-5). Using these ultrasonographic findings, Czyrny classified Osgood-Schlatter disease in three types (2) (Fig. 1) : type 1, delamination of the internal ossification center ; type 2, delamination tear or fracture of the epiphyseal part of the tibial tuberosity ; and type 3, delamination tear of the ossification center resulting in irregular deformation of the tuberosity. The presence of bursitis is also considered a characteristic finding. In many cases of Osgood-Schlatter disease, neovascularization at the insertion of the tibial tuberosity is noted. The amount of the blood flow tends to correlate to the degree of pain (6) (Fig. 2). These types and findings sometimes affect the strategy of treatment of this injury.

## PATELLAR TENDINOPATHY (JUMPER'S KNEE)

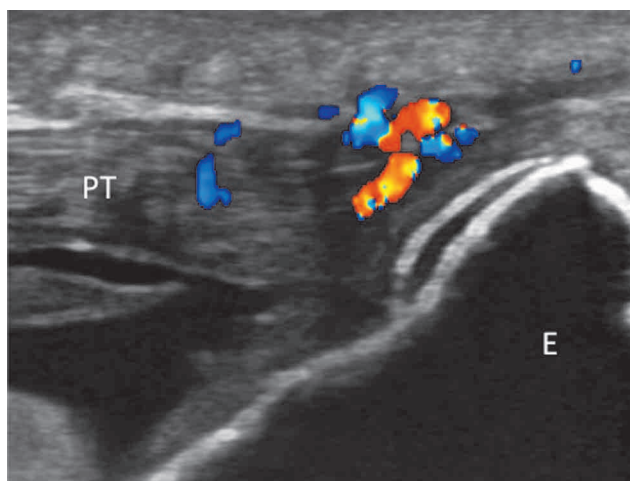
Jumper's knee is an insertional tendinopathy of the extensor apparatus of the knee, which may affect athletes participating in various sports at every level. This syndrome is characterized by pain at the insertion of the quadriceps tendon at the upper pole of the patella (20%), the insertion of the patellar tendon at the lower pole of the patella (70%), or the tibial tuberosity (10%) (7). Diagnosis is typically based on medical history and clinical findings.

Received for publication December 10, 2014 ; accepted February 8, 2015.

Address correspondence and reprint requests to Naoto Suzue, MD, PhD, Department of Orthopedics, the University of Tokushima 3-18-15 Kuramoto, Tokushima 770-8503, Japan and Fax : +81-88-633-0178.



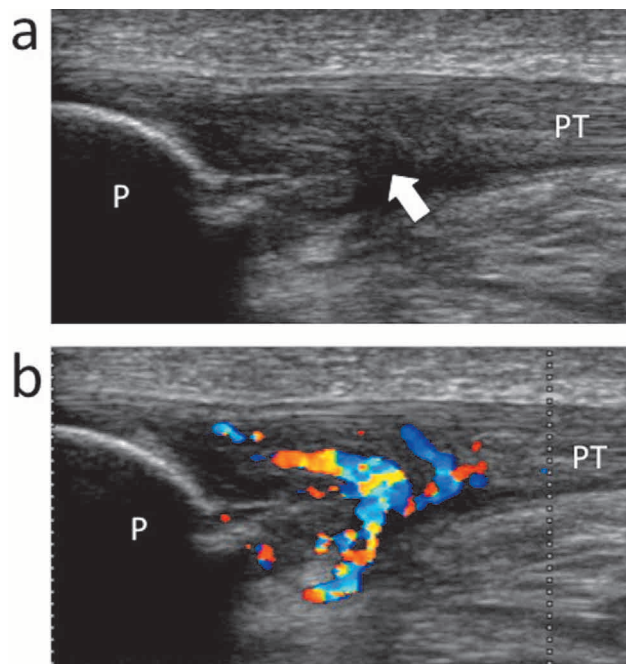
**Figure 1.** Osgood-Schlatter disease, longitudinal ultrasonographic images. (a) : type 1. A clean delamination tear of the ossification center (12 year-old male, soccer). *Arrow heads*, the delaminated layer of the ossification center. (b) : type 2. A significant anterior displacement of the attachment of the patellar tendon (13 year-old male, soccer). *Double arrow*, distance of anterior displacement of the fractured cartilage. (c) : type 3. An irregular deformation of the tuberosity (13 year-old male, baseball). *Arrow*, an ectopic ossification formed within patellar tendon. *PT*, patellar tendon, *E*, epiphysis, *asterisk*, bursitis.



**Figure 2.** Neovascularization at the insertion of the tuberosity (12 year-old male, soccer). Color Doppler ultrasonography shows neovascularization surrounding the insertion of patellar tendon. *PT*, patellar tendon, *E*, epiphysis.

Imaging techniques such as grayscale and color Doppler sonography are valuable tools for confirming the diagnosis and providing guidance for treatment. Grayscale ultrasonography shows thickening and a hypoechoic area at the proximal part of the patellar tendon (5, 8) (Fig. 3a). Alterations in the tendon structure at its insertion on the bone may also be seen, which are correlated to mucoid degeneration (3). Furthermore, Weinberg *et al.* (9) and Terslev *et al.* (10) showed that the presence of neovessels can be demonstrated by color Doppler ultrasonography in some patients with jumper's knee (Fig. 3b).

Treatment of jumper's knee is mainly conservative in the first and second stages of severity, relying on the administration of non-steroidal anti-inflammatory drugs for 1-2 months, dry ice compresses three times a day, and bandages. This condition heals in about 6-12 months; however, if the symptoms do not resolve, surgical therapy might be necessary (3).



**Figure 3.** Jumper's knee, longitudinal ultrasonographic images (25 year-old male, soccer). (a) : Grayscale ultrasonography shows thickening and a hypoechoic area (*arrow*) at the proximal part of the patellar tendon. (b) : Color Doppler ultrasonography shows the vascular flow. *PT*, patellar tendon, *P*, patella.

Recently, several new conservative therapies, such as platelet-rich plasma (PRP), extracorporeal shock wave therapy (ESWT), sclerosing, and fenestration, have been introduced. In these cases, ultrasonography can be a useful tool. Autologous growth factors are delivered locally in the form of PRP by injection to the tendon repair site, and PRP has gained popularity as a potentially useful regenerative therapy for jumper's knee. When PRP injection is performed, ultrasonography is helpful for accurate identification of the injection site, which shows pathological changes such as a hypoechoic or hypervascular area (7, 11-14). ESWT has also become a widely used treatment (7, 15, 16). While the mechanisms underlying its effects on tendinopathies remain unclear, analgesic and stimulating effects of ESWT on tissue regeneration have been suggested. Recent advances in ESWT machines enable identification of the treatment target using ultrasonographic guidance. With respect to sclerosing treatments, immunohistochemical analyses of tendon biopsies from hypervascular regions have shown nerves located close to blood vessels, which is possibly why ultrasound-guided sclerosing treatments have been effective (17-20). In addition, treatment by ultrasound-guided patellar tendon fenestration or arthroscopic shaving has also been reported (17, 18, 21).

### SINDING-LARSEN-JOHANSSON DISEASE

Sinding-Larsen-Johansson disease is a juvenile osteochondrosis and its predilection age tends to slightly younger than that of Osgood-Schlatter disease. The former affects the distal pole of the patella at the proximal insertion of the patellar tendon. Consequently, the symptoms of Sinding-Larsen-Johansson disease are similar to those of jumper's knee. Sinding-Larsen-Johansson disease is clinically characterized by pain localized at the distal pole of the patella, increasing during flexion combined with loading of the knee joint. Other clinical features include swelling of the infrapatellar soft tissues and functional limitations (3, 22). The disease

is caused by repetitive microtraumas and excessive prolonged stress occurring on a specific skeletal region that is both mechanically and biologically weak, when the stress exceeds the intrinsic resistance.

In Sinding-Larsen-Johansson disease, ultrasonography shows cartilage and patellar tendon swelling at its proximal insertion and fragmentation at the patellar distal pole (22, 23) (Fig. 4). Some types of fragmentation may also be seen. Although Sinding-Larsen-Johansson disease is a relatively common injury in adolescent athletes, few reports have examined it in detail.

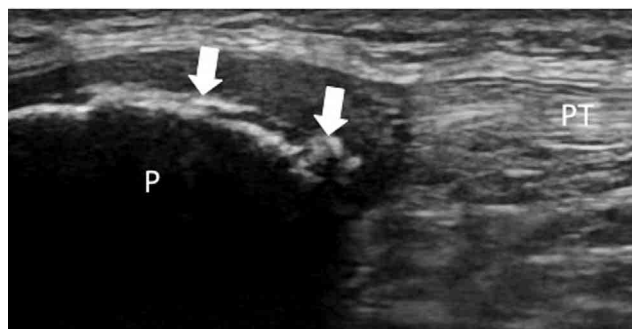


Figure 4. Sinding-Larsen-Johansson disease, longitudinal ultrasonographic image (10 year-old male, soccer). Fragmentation at the patellar distal pole (arrows). PT, patellar tendon, P, patella.

## BIPARTITE PATELLA

Bipartite patella is also a juvenile osteochondrosis, with a predilection age even younger than that of Sinding-Larsen-Johansson disease. In 1975, Green described the cases of three boys with painful bipartite patella in whom pain was relieved by excision of the accessory ossification centers (24). Since this report was published, bipartite patella has been observed as a cause of anterior knee pain in adolescents and young athletes. Bipartite patella is classified into three groups. In the first group, the patella is divided by a transverse split line into an upper large bone fragment and a lower small bone fragment. In the second group, the patella is divided by a longitudinal split line into an outer one-fourth bone fragment and an inner three-fourths bone segment. In the third group, the patella is divided into a relatively large inner lower bone fragment and small upper outer bone fragment (25). The most common symptom is pain at the separated fragments during or after strenuous activity. Localized tenderness over the separated fragments is the most common physical finding.

Ultrasonographic examination of the bipartite patella shows an irregularity in the bony contours, with occurrence of a cleft between the main part of the patellar body and the large superolateral accessory ossicle. The signal detected in the interface between bones is less echogenic than bone, reflecting its fibrocartilaginous nature (26). Furthermore, neovascularization can be noted on color Doppler ultrasonography surrounding the ossicle (Fig. 5), at the insertion of the vastus lateralis muscle or the area between the fragment and the patella. While bipartite patella is also a common injury, few reports have described it in detail.

## OSTEOCHONDRITIS DISSECANS OF THE KNEE

Osteochondritis dissecans (OCD) has been defined as a localized process wherein a focus of subchondral bone and adjacent articular cartilage separates from the surrounding bone (27-31). Given that the knee is the most common location for OCD development

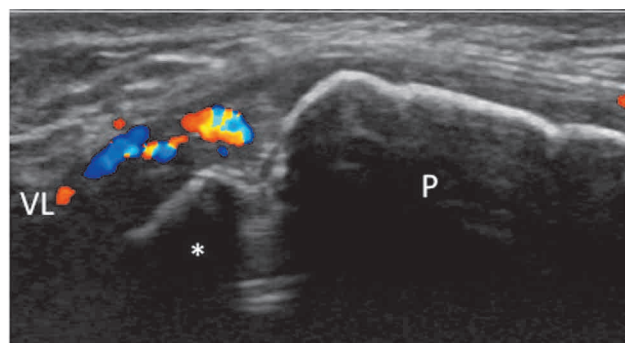


Figure 5. Bipartite patella, longitudinal ultrasonographic image (10 year-old male, basketball). Color Doppler ultrasonography shows neovascularization surrounding the ossicle. VL, vastus lateralis muscle, P, patella, asterisk, accessory ossicle.

and that this lesion is typically found in individuals who participate in sports, the hypothesis of repetitive microtrauma as the causative pathology has gained favor. However, the cause of OCD remains controversial, as does the most appropriate treatment for the varying degrees of OCD lesions (29). The yearly incidence of OCD is reportedly between 0.02% and 0.03% (27), with a male to female ratio of 2 : 1 (32). This is one of the severest injuries affecting athletes because if fragmentation has progressed to the terminal stage, structural regeneration is not possible.

OCD is detected using radiography, CT, and MRI. MRI is considered the most useful modality because the immature condyle of the femur can sometimes shows ossification variants (33). Ultrasonography can show the fragmentation and discontinuity of the subchondral bone of the femoral condyle (34) (Fig. 6); however, it is difficult to distinguish between various degrees of OCD and its ossification variants using ultrasonography. Therefore, further study and research are needed to clarify these differences.

On the other hand, ultrasonography can be used in the treatment of OCD, as reported by Berná-Serna *et al.*, who showed good results using ultrasonography-guided percutaneous drilling (35).

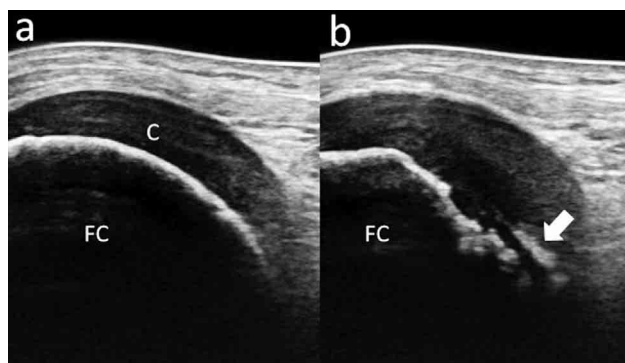


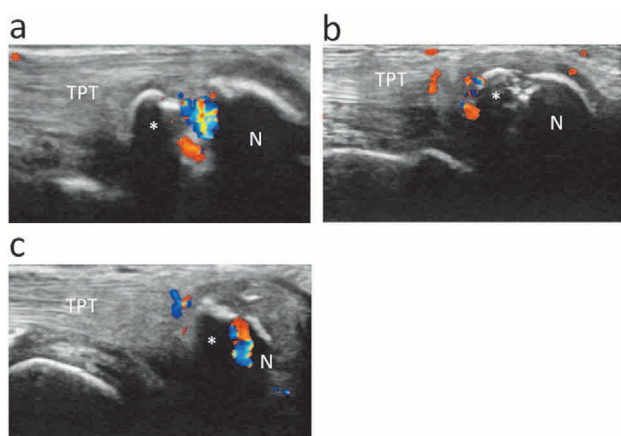
Figure 6. Osteochondritis dissecans of the lateral femoral condyle, longitudinal ultrasonographic image (12 year-old male, soccer). (a) : Normal femoral condyle. (b) : ultrasonography shows the fragmentation of the subchondral bone (arrow). FC, femoral condyle, C, cartilage.

## SYMPTOMATIC ACCESSORY NAVICULAR

Generally, the accessory navicular is one of the most common accessory ossicles of the foot. The prevalence of the injury is thought to be 4-21% in the asymptomatic population. This condition has a higher incidence in women, and 50-90% of cases have bilateral ossicles (36). This entity is usually asymptomatic, and

pain may occur following a sprain in many cases. The accessory navicular is classified into three types (37). Type 1 is defined as a small accessory bone within the distal posterior tibialis tendon with no cartilage connection to the navicular tuberosity, appearing to be a sesamoid bone. Type 2 refers to a triangular secondary ossification center of the navicular tuberosity, which is connected to the navicular by fibrocartilage. Many cases of symptomatic accessory navicular belong to type 2. Type 3 is considered to result from osseous fusion of the ossification center, resulting in a prominent navicular tuberosity.

Occasionally, the posterior tibialis tendinitis is the cause of medial foot pain (38). Ultrasonography is a highly effective method for the evaluation of tendinous abnormalities, since evidence of a diffusely edematous tendon with surrounding fluid or frank rupture can easily be detected with high-resolution equipment (39). Thus, ultrasonography can show not only the shape of the accessory navicular and navicular tuberosity but also the presence of swelling of the tibialis posterior tendon or inflammation of the surrounding tissues (38). Several types of inflammation are observed as abnormal blood flow in ultrasonography. For example, abnormal blood flow may be noted between the accessory navicular and the navicular tuberosity as well as at the enthesis of the tibialis posterior tendon. Ultrasonography allows the discrimination of various conditions in the symptomatic accessory navicular (Fig. 7).



**Figure 7.** Symptomatic accessory navicular, longitudinal ultrasonographic images. (a) : Neovascularization between the accessory navicular (asterisk) and the navicular tuberosity (N) (12 year-old male, soccer). (b) : Neovascularization at the enthesis of the tibialis posterior tendon (TPT) (11 year-old male, soccer). (c) : Neovascularization at the both site of the accessory navicular (11 year-old female, soccer).

## CONCLUSION

Ultrasonography can reveal characteristic findings in overuse sports injuries that occur not only in adolescents but also in adults. To date, radiography, CT, and MRI have been the primary imaging modalities for these injuries ; however, recent advances have allowed ultrasonography to be considered in their ranks. Despite the rapid advances in ultrasonography, some injuries need further study. Certainly, ultrasonography has some limitation. For example, it depends on the operator's skill whether clear images can be described. Moreover ultrasonography cannot show the inside of bony cortex or the parts surrounded with bones. However in consideration of these limitations, given the usefulness of ultrasonography, especially in treatment, it is expected to become an essential for overuse injuries affecting the lower limb in athletes.

## CONFLICT OF INTEREST

We have no conflict of interests to disclose.

## REFERENCES

- Osgood RB : Lesions of the tibial tubercle occurring during adolescence. *Clin Orthop Relat Res* 1993 ; 6, 1903
- Czyrny Z : Osgood-Schlatter disease in ultrasound diagnostics-a pictorial essay. *Med Ultrason* 12(4) : 323-335, 2010
- Draghi F, Danesino GM, Coscia D, Precerutti M, Pagani C : Overload syndromes of the knee in adolescents : Sonographic findings. *J Ultrasound* 11(4) : 151-157, 2008
- Chiang Y-P, Wang T-G, Hsieh S-F : Application of Ultrasound in Sports Injury. *J Med Ultrasound* 21(1) : 1-8, 2013
- Blankenbaker DG, De Smet AA : The role of ultrasound in the evaluation of sports injuries of the lower extremities. *Clin Sports Med* 25(4) : 867-897, 2006
- Saïly M, Whiteley R, Johnson A : Doppler ultrasound and tibial tuberosity maturation status predicts pain in adolescent male athletes with Osgood-Schlatter's disease : a case series with comparison group and clinical interpretation. *Br J Sports Med* 47(2) : 93-97, 2013
- Vetrano M, Castorina A, Vulpiani MC, Baldini R, Pavan A, Ferretti A : Platelet-rich plasma versus focused shock waves in the treatment of jumper's knee in athletes. *Am J Sports Med* 41(4) : 795-803, 2013
- Gisslèn K, Gyulai C, Söderman K, Alfredson H : High prevalence of jumper's knee and sonographic changes in Swedish elite junior volleyball players compared to matched controls. *Br J Sports Med* 39(5) : 298-301, 2005
- Weinberg EP, Adams MJ, Hollenberg GM : Color Doppler sonography of patellar tendinosis. *Am J Roentgenol* 171(3) : 743-744, 1998
- Terslev L, Qvistgaard E, Torp-Pedersen S, Laetgaard J, Danneskiold-Samsøe B, Bliddal H : Ultrasound and Power Doppler findings in jumper's knee-preliminary observations. *Eur J Ultrasound* 13(3) : 183-189, 2001
- Tok F, Özçakar L, De Muyck M, Kara M, Vanderstraeten G : Musculoskeletal ultrasound for sports injuries. *Eur J Phys Rehabil Med* 48(4) : 651-663, 2012
- Charoussat C, Zaoui A, Bellaïche L, Bouyer B : Are multiple platelet-rich plasma injections useful for treatment of chronic patellar tendinopathy in athletes? a prospective study. *Am J Sports Med* 42(4) : 906-11, 2014
- Ferrero G, Fabbro E, Orlandi D, Martini C, Lacelli F, Serafini G : Ultrasound-guided injection of platelet-rich plasma in chronic Achilles and patellar tendinopathy. *J Ultrasound* 15(4) : 260-266, 2012
- Smith J, Sellon JL : Comparing PRP injections with ESWT for athletes with chronic patellar tendinopathy. *Clin J Sport Med* 24(1) : 88-89, 2014
- van Leeuwen MT, Zwerver J, van den Akker-Scheek I : Extracorporeal shockwave therapy for patellar tendinopathy : a review of the literature. *Br J Sports Med* 43(3) : 163-168, 2009
- Vulpiani MC, Vetrano M, Savoia V, Di Pangrazio E, Trischitta D, Ferretti A : Jumper's knee treatment with extracorporeal shock wave therapy : a long-term follow-up observational study. *J Sports Med Phys Fitness* 47(3) : 323-328, 2007
- Willberg L, Sunding K, Forssblad M, Fahlström M, Alfredson H : Sclerosing polidocanol injections or arthroscopic shaving to treat patellar tendinopathy/jumper's knee? A randomised controlled study. *Br J Sports Med* 45(5) : 411-415, 2011
- Sunding K, Willberg L, Werner S, Alfredson H, Forssblad M, Fahlström M : Sclerosing injections and ultrasound-guided

- arthroscopic shaving for patellar tendinopathy : good clinical results and decreased tendon thickness after surgery-a medium-term follow-up study. *Knee Surg Sports Traumatol Arthrosc* 6, 2014
19. Hoksrud A, Bahr R : Ultrasound-guided sclerosing treatment in patients with patellar tendinopathy (jumper's knee). 44-month follow-up. *Am J Sports Med* 39(11) : 2377-2380, 2011
  20. Hoksrud A, Torgalsen T, Harstad H, Haugen S, Andersen TE, Risberg MA : Ultrasound-guided sclerosis of neovessels in patellar tendinopathy : a prospective study of 101 patients. *Am J Sports Med* 40(3) : 542-547, 2012
  21. Kanaan Y, Jacobson JA, Jamadar D, Housner J, Caoili EM : Sonographically guided patellar tendon fenestration : prognostic value of preprocedure sonographic findings. *J Ultrasound Med* 32(5) : 771-777, 2013
  22. De Flaviis L, Nessi R, Scaglione P, Balconi G, Albisetti W, Derchi LE : Ultrasonographic diagnosis of Osgood-Schlatter and Sinding-Larsen-Johansson diseases of the knee. *Skeletal Radiol* 18(3) : 193-197, 1989
  23. Valentino M, Quiligotti C, Ruggirello M : Sinding-Larsen-Johansson syndrome : A case report. *J Ultrasound* 15(2) : 127-129, 2012
  24. Green WT : Painful bipartite patellae. A report of three cases. *Clin Orthop Relat Res* 1975 (110) : 197-200, 1975
  25. Oohashi Y : Developmental anomaly of ossification type patella partita. *Knee Surg Sports Traumatol Arthrosc* 15, 2014
  26. Blankstein A, Cohen I, Salai M, Diamant L, Chechick A, Ganel A : Ultrasonography : an imaging modality enabling the diagnosis of bipartite patella. *Knee Surg Sports Traumatol Arthrosc* 9(4) : 221-224, 2001
  27. Crawford DC, Safran MR : Osteochondritis dissecans of the knee. *J Am Acad Orthop Surg* 14(2) : 90-100, 2006
  28. Moretti B, Notarnicola A, Moretti L, Giordano P, Patella V : A volleyball player with bilateral knee osteochondritis dissecans treated with extracorporeal shock wave therapy. *Chir Organi Mov* 93(1) : 37-41, 2009
  29. Grimm NL, Tisano B, Carey JL : Three osteochondritis dissecans lesions in one knee : a case report. *Clin Orthop Relat Res* 471(4) : 1186-1190, 2013
  30. Swain JH, Grimm NL, Shea KG : Juvenile osteochondritis dissecans of the knee. *J Orthop Sports Phys Ther* 40(8) : 534, 2010
  31. Eismann EA, Pettit RJ, Wall EJ, Myer GD : Management strategies for osteochondritis dissecans of the knee in the skeletally immature athlete. *J Orthop Sports Phys Ther* 44(9) : 665-679, 2014
  32. Lindén B : The incidence of osteochondritis dissecans in the condyles of the femur. *Acta Orthop Scand* 47(6) : 664-667, 1976
  33. Jans L, Jaremko J, Ditchfield M, De Coninck T, Huysse W, Moon A : Ossification variants of the femoral condyles are not associated with osteochondritis dissecans. *Eur J Radiol* 81(11) : 3384-3389, 2012
  34. Gregersen HE, Rasmussen OS : Ultrasonography of osteochondritis dissecans of the knee. A preliminary report. *Acta Radiol* 30(5) : 552-554, 1989
  35. Berná-Serna JD, Martínez F, Reus M, Berná-Mestre JD : Osteochondritis dissecans of the knee : sonographically guided percutaneous drilling. *J Ultrasound Med* 27(2) : 255-259, 2008
  36. Mosel LD, Kat E, Voyvodich F : Imaging of the symptomatic type II accessory navicular bone. *Australas Radiol* 48(2) : 267-271, 2004
  37. Veitch JM : Evaluation of the Kidner procedure in treatment of symptomatic accessory tarsal scaphoid. *Clin Orthop Relat Res* Mar(131) : 210-213, 1978
  38. Chuang Y-W, Tsai W-S, Chen K-H, Hsu H-C : Clinical use of high-resolution ultrasonography for the diagnosis of type II accessory navicular bone. *Am J Phys Med Rehabil* 91(2) : 177-181, 2012
  39. Chen YJ, Hsu RW, Liang SC : Degeneration of the accessory navicular synchondrosis presenting as rupture of the posterior tibial tendon. *J Bone Joint Surg Am* 79(12) : 1791-1798, 1997