

CASE REPORT

Transient severe hypotension with once-weekly subcutaneous injection of teriparatide in osteoporotic patient : a case report and insight for the drug interaction between hypotensive agents and teriparatide

Tetsuya Enishi¹, Hirokazu Uemura², Shinsuke Katoh¹, Masanori Inatsugi³, Sho Minato³, Kei Inatsugi³, Mikiko Inatsugi³, Nori Sato¹, and Koichi Siryo⁴

¹Departments of Rehabilitation Medicine, The Tokushima University Hospital, Tokushima, Japan, ²Department of Preventive Medicine, Institute of Health Biosciences, University of Tokushima Graduate School, Tokushima, Japan, ³Departments of Orthopedics and Rehabilitation Medicine, The Inatsugi rehabilitation clinic, Tokushima, Japan, ⁴Departments of Orthopedics, The Tokushima University Hospital, Tokushima, Japan

Abstract : Teriparatide, a recombinant form of parathyroid hormone, were well recognized as a useful option for the treatment of the osteoporosis. Although some side effects of teriparatide include headache, nausea, dizziness, and limb pain were reported. Here we present a 80-year-old woman of transient asymptomatic hypotension with once-weekly subcutaneous injection of teriparatide for the treatment of osteoporosis with hypertension disease as acute-phase reactions. Systolic blood pressure decreased in both 30 min and 60 min after injection compared with before injection. Heart rate increased with passage of time. Statistically significant were observed among before, 30 min, 60 min after injection of teriparatide. Slight nausea was seen as subjective symptoms with the first and second injection after 30 min. This case indicates careful attention, at least 1 hr, was recommended with weekly subcutaneous injections of teriparatide in the treatment for osteoporotic patient with hypertension decreases. This is a first report, to the best of our knowledge, to demonstrate the transient asymptomatic hypotension after once-weekly injection of teriparatide with hypertension disease. Transient hypotension occurred after injection of teriparatide during the treatment period and was asymptomatic except for the first 2 injections. *J. Med. Invest.* 62 : 93-96, February, 2015

Keywords : osteoporosis, teriparatide, blood pressure, hypotension, side effect

INTRODUCTION :

Teriparatide, a recombinant form of parathyroid hormone, were well recognized as a useful option for the treatment of the osteoporosis (1-3). Intermittent injection of teriparatide activates osteoblasts and results in increase in bone mineral density (1, 3). It has been demonstrated to effectively reduce vertebral and non-vertebral fractures, and back pain in postmenopausal osteoporotic patients (3-6). Some side effects of teriparatide include headache, nausea, dizziness, and limb pain were reported as "common" to "very common" by the European Medicines Agency (3, 7, 8). Although reports of decreased blood pressure after injection of teriparatide were present, there is no detailed case report about the severe reduction in blood pressure of each injection and suggesting drug interaction between hypotensive agents and teriparatide. This potential drug interaction and its clinical consequences have not been discussed.

Here we present a 80-year-old woman of transient asymptomatic hypotension as acute-phase reactions with once-weekly subcutaneous injection of teriparatide for the treatment of osteoporosis with hypertension disease. Systolic, diastolic blood pressure and heart rate after injection were studied. To the best of our knowledge, this is the first report about the severe reduction in blood

pressure of each injection of once-weekly teriparatide and suggesting drug interaction with hypotensive agents.

CASE PRESENTATION :

A 80-year-old woman with hypertension disease had a chronic low back pain due to spondylolisthesis at L4/5 and old lumbar compression fractures at L2, L3, and L4 (Figure 1). She consulted our clinic to relief of her low back pain. She was 54 kg and 144 cm ; body mass index was 26.0 kg/m². Bone metabolic markers, P1NP and TRAcP-5b, and bone mineral density at spine and femoral neck were evaluated before and after treatment (Table 1). She had not been receiving anti-osteoporotic medical therapy, although the patient had hypertension disease treated with hypotensive agents, valsartan (80 mg/day), hydrochlorothiazide (12.5 mg/day), atenolol (25 mg/day), and amlodipine besilate (6.93 mg/day), once a day in the morning. The physical examination was normal without neurological signs, except for an apparent slight thoraco-lumbar kyphosis. All laboratory findings were within normal limits. She has no history of autonomic dysfunction and transient hypotensive reaction.

Once-weekly subcutaneous injection of teriparatide (hPTH (1-34), teriparatide acetate, TERIBONE™, 56.5 µg, Asahi Kasei Pharma, Tokyo, Japan), injected at 14 O'clock, was applied to the patient for 24 weeks. As a safety management, systolic, diastolic blood pressure and heart rate were measured before, 30 min. after, and 60 min. after every subcutaneous injection of teriparatide. Blood pressure was measured using automatic devices (AC 05P, SUZUKEN CO., LTD. Aichi, Japan.) in sitting position with the

Received for publication November 19, 2014 ; accepted December 16, 2014.

Address correspondence and reprint requests to Tetsuya Enishi, M.D. PhD., Department of Rehabilitation Medicine Tokushima University Hospital 2-50-1 Kuramoto, Tokushima 770-8503, Japan and Fax : +81-88-633-0178.

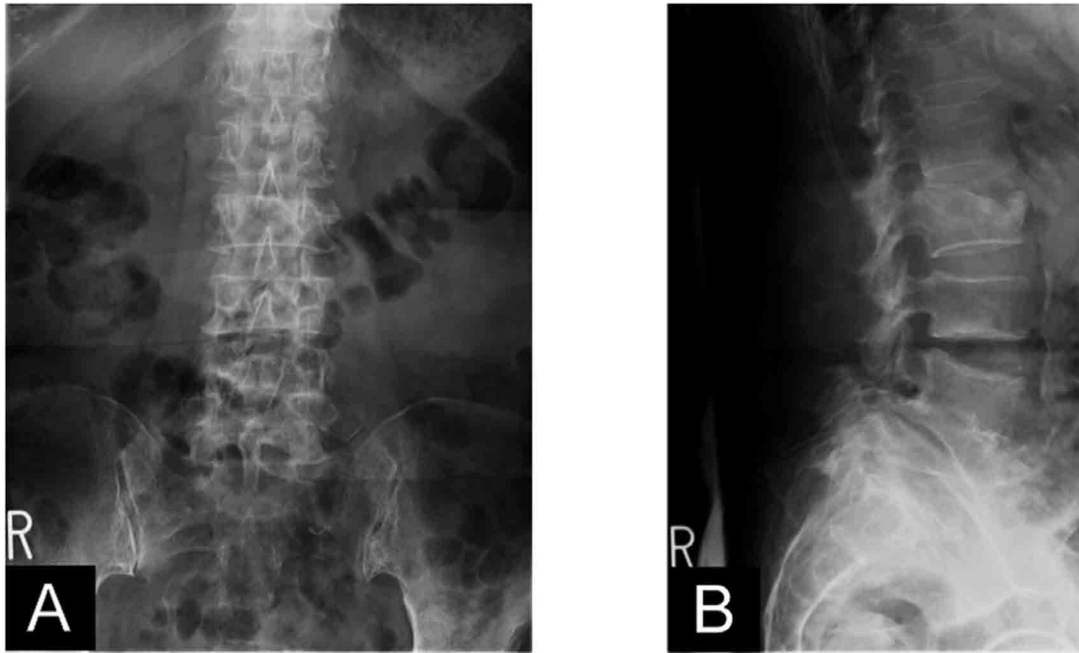


Figure 1. Anteroposterior (A) and lateral (B) radiographs. Spondylolisthesis (natural fusion) at L4/5 and old lumbar compression fractures at L2, L3, and L4 were observed.

arms supported precisely at the right atrium level. The subjective symptoms were also interviewed at every blood pressure measurement.

Transient asymptomatic hypotension was observed each time of subcutaneous injection of teriparatide. Slight nausea was seen as subjective symptoms with the first and second injection after 30 min. Systolic blood pressure, diastolic blood pressure, and heart rate were shown in Figure 2. Systolic blood pressure decreased

in both 30 min and 60 min after injection compared with before injection. Systolic blood pressure was still low after 60 min, but slightly recovered. Diastolic pressure decreased after 30 min injection, but recovered in 60 min. There were no significant difference between before and 60 min after injection. Heart rate slightly increased with passage of time. Statistically significant in heart rate were observed among before, 30 min, 60 min after injection of teriparatide. This slight tachycardia was intended to compensate for the decrease in blood pressure. However, these increase were small and considered to be less clinical significance. The changes in bone metabolic markers and bone mineral density in this case were also small and clinically not significant (Table 1). These results were consistent with previous report (9). At one-year follow-up, low back pain decreased and no other side effect of the treatment was observed.

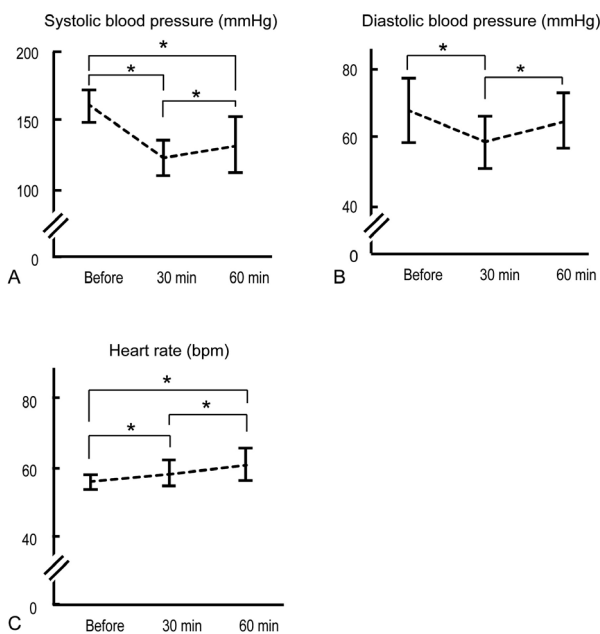


Figure 2. Line graphs demonstrating systolic blood pressure (A), diastolic blood pressure (B), and heart rate (C). Statistical analyses were performed using SPSS v. 21.0. Values of $p < 0.05$ were considered significantly different. The effects of teriparatide were analyzed using a Friedman test. The homogeneity of variances was analyzed using the Shapiro-Wilk normality test. *, statistically significant difference.

Table 1. The change in bone mineral density and bone metabolic markers.

	Before treatment	After treatment
BMD at spine (T-score)	0.982 g/cm ² (0.97)	1.002 g/cm ² (0.99)
BMD at femoral neck (T-score)	0.487 g/cm ² (0.62)	0.485 g/cm ² (0.62)
P1NP	46.6 µg/l	56.3 µg/l
TRAcP-5b	448 mU/dl	402 mU/dl

Bone metabolic markers were evaluated one week before the first injection of teriparatide and after the last injection of teriparatide. Bone mineral density (BMD).

DISCUSSION

According to the formally prescribing information (10), the maximum decrease of systolic and diastolic blood pressure during their clinical pharmacological test was 4.6 mmHg and 8.8 mmHg, respectively. In this case, the maximum decrease of systolic and diastolic blood pressure was 66 mmHg and 32 mmHg, respectively. These

strikingly decreases were observed after 30 min injection compared with the maximum decrease in blood pressure prescribed in the formal information (8). This is the first report describing such a severe transient hypotension after once-weekly injection of teriparatide.

The mechanism of hypotension after injection of teriparatide was generally believed due to the vasodilating action through the vascular smooth muscle relaxant activity, accompanied by pulse increase (11, 12). Hypotension has multiple possible causes, and hypotensive agents such as Ca²⁺ antagonist reduce vascular smooth muscle tone with increase of vessel diameter and decrease of the blood pressure (13). Transient hypotension reaction in this case may have reflected the response to multiple hypotensive agents rather than the consequence of a drug interaction between hypotensive agents and teriparatide (14). However, hypotensive reaction had never been observed without injection of teriparatide during follow up period. This case indicates the necessity considering the drug interaction between hypotensive agents and teriparatide, although there is no such description in the formal information and no report suggesting the drug interaction between hypotensive agents and teriparatide.

This case also showed that most hypotensive side effects did not cause the subjective symptom. Although systolic and diastolic blood pressure decreased after each injection of teriparatide, transient hypotension was usually asymptomatic except for the first 2 injections. The decrease of systolic blood pressure after first injection and second injection was 17 mmHg and 28 mmHg, respectively. As far in this patient, these decreases were the average changes for her. Given the results from this case, there is a possibility that asymptomatic decrease in blood pressure might occur in acute phase after injection of teriparatide.

CONCLUSION

Here we show a severe transient asymptomatic hypotension with once-weekly subcutaneous injection of teriparatide for the treatment of osteoporosis with hypertension disease as acute-phase reactions. This is a first report showing transient severe hypotension after once-weekly injection of teriparatide in acute phase, and suggesting the drug interaction between hypotensive agents and teriparatide. This case indicates careful attention, at least 1 hr, was recommended with injections of teriparatide in the treatment for osteoporotic patient with hypertension decreases. There is a possibility that transient hypotension might occur without symptoms in acute phase after injection of teriparatide.

CONSENT

Written informed consent was obtained from the patient for publication of this Case report and accompanying images. A copy of the written consent is available for review by the Editor-in-Chief of this journal.

COMPETING INTERESTS

The authors declare that they have no competing interests.

ACKNOWLEDGEMENTS

The authors thanks to Dr. Yuichiro Goda, MD from the Department of Orthopedics of the Tokushima University Hospital, Tokushima, for kind advises.

REFERENCES

- Okimoto N, Tsurukami H, Okazaki Y, Nishida S, Sakai A, Ohnishi H, Hori M, Yasukawa K, Nakamura T : Effects of a weekly injection of human parathyroid hormone (1-34) and withdrawal on bone mass, strength, and turnover in mature ovariectomized rats. *Bone*. 1998 ; 22(5) : 523-31. Epub 1998/05/26. PubMed PMID : 9600787.
- Miki T, Nakatsuka K, Naka H, Masaki H, Imanishi Y, Ito M, Inaba M, Morii H, Nishizawa Y : Effect and safety of intermittent weekly administration of human parathyroid hormone 1-34 in patients with primary osteoporosis evaluated by histomorphometry and microstructural analysis of iliac trabecular bone before and after 1 year of treatment. *Journal of bone and mineral metabolism*. 2004 ; 22(6) : 569-76. Epub 2004/10/19. doi : 10.1007/s00774-004-0525-z. PubMed PMID : 15490267.
- Neer RM, Arnaud CD, Zanchetta JR, Prince R, Gaich GA, Reginster JY, Hodsman AB, Eriksen EF, Ish-Shalom S, Genant HK, Wang O, Mitlak BH : Effect of parathyroid hormone (1-34) on fractures and bone mineral density in postmenopausal women with osteoporosis. *The New England journal of medicine*. 2001 ; 344(19) : 1434-41. doi : 10.1056/NEJM200105103441904. PubMed PMID : 11346808.
- Tanaka S, Kuroda T, Sugimoto T, Nakamura T, Shiraki M : Changes in bone mineral density, bone turnover markers, and vertebral fracture risk reduction with once weekly teriparatide. *Current medical research and opinion*. 2014. Epub 2014/01/08. doi : 10.1185/03007995.2013.879440. PubMed PMID : 24392946.
- Fujita T, Fukunaga M, Itabashi A, Tsutani K, Nakamura T : Once-Weekly Injection of Low-Dose Teriparatide (28.2 mug) Reduced the Risk of Vertebral Fracture in Patients with Primary Osteoporosis. *Calcified tissue international*. 2014 ; 94(2) : 170-5. Epub 2013/08/22. doi : 10.1007/s00223-013-9777-8. PubMed PMID : 23963633 ; PubMed Central PMCID : PMC3899450.
- Sugimoto T, Shiraki M, Nakano T, Kishimoto H, Ito M, Fukunaga M, Hagino H, Sone T, Kuroda T, Nakamura T : Vertebral fracture risk after once-weekly teriparatide injections : follow-up study of Teriparatide Once-Weekly Efficacy Research (TOWER) trial. *Current medical research and opinion*. 2013 ; 29(3) : 195-203. Epub 2012/12/25. doi : 10.1185/03007995.2012.761956. PubMed PMID : 23259702.
- Rizzoli R, Reginster JY, Boonen S, Breart G, Diez-Perez A, Felsenberg D, Kaufman JM, Kanis JA, Cooper C : Adverse Reactions and Drug-Drug Interactions in the Management of Women with Postmenopausal Osteoporosis. *Calcified tissue international*. 2011 ; 89(2) : 91-104. doi : Doi 10.1007/S00223-011-9499-8. PubMed PMID : WOS : 000292743700001.
- Agency EM : Teriparatide. Summary of product characteristics. 2008. Available from : <http://www.emea.europa.eu>.
- Sugimoto T, Nakamura T, Nakamura Y, Isogai Y, Shiraki M : Profile of changes in bone turnover markers during once-weekly teriparatide administration for 24 weeks in postmenopausal women with osteoporosis. *Osteoporosis international : a journal established as result of cooperation between the European Foundation for Osteoporosis and the National Osteoporosis Foundation of the USA*. 2014 ; 25(3) : 1173-80. Epub 2013/10/11. doi : 10.1007/s00198-013-2516-1. PubMed PMID : 24108429 ; PubMed Central PMCID : PMC3923119.
- Pharma AK : Package insert Available from : <http://www.asahikasei.co.jp/asahi/en/aboutasahi/pharma/index.html>.
- Mok LL, Nickols GA, Thompson JC, Cooper CW : Parathyroid hormone as a smooth muscle relaxant. *Endocrine reviews*. 1989 ; 10(4) : 420-36. doi : 10.1210/edrv-10-4-420. PubMed PMID : 2693082.

12. Care AD, Abbas SK, Harmeyer J, Boivin R : The relaxant effects of parathyroid hormone(1-34) and parathyroid hormone-related protein(1-34) on ovine reticulo-ruminal smooth muscle in vivo. *Experimental physiology*. 1999 ; 84(4) : 665-75. PubMed PMID : 10481224.
13. Ahmed A, Kobayashi S, Shikasho T, Nishimura J, Kanaide H : Differential effects of Ca²⁺ channel blockers on Ca²⁺ transients and cell cycle progression in vascular smooth muscle cells. *European journal of pharmacology*. 1998 ; 344(2-3) : 323-31. PubMed PMID : 9600669.
14. Elliott WJ : Drug interactions and drugs that affect blood pressure. *Journal of clinical hypertension*. 2006 ; 8(10) : 731-7. PubMed PMID : 17028488.