

CASE REPORT

Successful Emergency Carotid Endarterectomy after Thrombolysis with Intravenous Recombinant Tissue-Type Plasminogen Activator

Yoko Yamamoto¹, Toshiyuki Okazaki¹, Keishi Yoda¹, Yoshiteru Tada², and Shinji Nagahiro²

¹Department of Neurosurgery, Tokushima Prefectural Miyoshi Hospital, Tokushima, Japan, ²Department of Neurosurgery, Institute of Biomedical Biosciences, Tokushima University Graduate School, Tokushima, Japan

Abstract : Acute internal carotid artery (ICA) occlusion may result in severe disability or death. Revascularization by carotid artery stenting after treatment with intravenous (iv) recombinant tissue-type plasminogen activator (rt-PA) has been documented. However, there are few reports on emergency carotid endarterectomy (CEA) within 24 hours after the iv administration of rt-PA. We treated a 58-year-old man with right ICA occlusion with iv rt-PA. Although partial recanalization of the ICA was obtained, severe stenosis at the origin of the ICA persisted and he developed fluctuating neurological deficits. To prevent progressive stroke he underwent CEA 10.5 hours after rt-PA treatment. Thereafter his blood pressure was strictly controlled under sedation. During and after CEA there were no hemorrhagic complications. Our findings suggest that emergency CEA may be an option to address symptomatic severe residual ICA stenosis even after iv rt-PA therapy delivered in the acute stage. *J. Med. Invest.* 63 : 300-304, August, 2016

Keywords : recombinant tissue-type plasminogen activator, internal carotid artery stenosis, carotid endarterectomy, internal carotid artery occlusion

INTRODUCTION

The morbidity and mortality rates after acute ischemic stroke from internal carotid artery (ICA) occlusion are high (1, 2). Only 18-26% of patients with acute ICA occlusion who received intravenous (iv) recombinant tissue-type plasminogen activator (rt-PA) therapy alone showed early recanalization (3-6).

The addition of endovascular-to iv rt-PA therapy was suggested to be effective in patients with acute ICA occlusion (7-9). However, when carotid artery stenting (CAS) is the salvage method in patients with cervical ICA stenosis who had undergone iv rt-PA treatment, antithrombotic- including antiplatelet agents are required during and after CAS to prevent stent thrombosis. The administration of such agents within 24 hours after rt-PA may increase the risk for major bleeding, in particular of intracerebral hemorrhage.

There are few reports of emergent carotid endarterectomy (CEA) within 24 hours after rt-PA treatment in patients with acute ICA occlusion. We report a patient who underwent emergent CEA after iv rt-PA treatment and whose outcome was good.

CASE REPORT

A 58-year-old man was referred to our emergency room 90 minutes after the sudden onset of left hemiplegia and dysarthria during the consumption of alcohol. His lifestyle included smoking and drinking and he had a history of hypertension, diabetes mellitus, and dyslipidemia. At the time of his admission he was confused (Glasgow Coma Scale ; E4V4M6) ; neurological findings were consciousness disturbance, conjugate deviation to the right, dysarthria,

left facial palsy, and left severe hemiparesis (manual muscle testing : upper 1/5 lower 3/5). His initial National Institute of Health Stroke Scale (NIHSS) score was 14. Neither an abnormal cardiac rhythm nor congestive heart failure was noted. Diffusion-weighted imaging (DWI) showed multiple high-intensity lesions in the right frontal lobe and insular cortex (Figure 1A). Magnetic resonance angiography (MRA) revealed occlusion of the cervical portion of the right ICA, there was faint flow in the right middle- and anterior cerebral arteries via the anterior- and posterior communicating artery providing collateral circulation (Figure 1B). Echo lucency was low on ultrasound images of a carotid atherosclerotic plaque. He was treated with iv rt-PA (0.6 mg/kg) 3 hours post-onset.

MRA images obtained immediately after the iv administration of rt-PA demonstrated no recanalization of the right ICA. On DWI scans an ischemic region was clearly visualized ; the area had not expanded (Figure 2). The conjugate deviation to the right disappeared, his level of consciousness improved, and his NIHSS score was 9. As it was unclear whether MRA indicated complete- or pseudo-occlusion of the ICA we performed cerebral angiography to determine his hemodynamic status. Based on North American Symptomatic Carotid Endarterectomy Trial (NASCET) criteria it showed 95% stenosis of the proximal ICA ; the blood flow was antegrade and slow (Figure 3) without supplementary flow from other arteries. He subsequently developed unstable neurological deficits and his NIHSS score fluctuated between 7 and 11. To prevent stroke progression we decided to perform CEA 10.5 hours after the administration of iv rt-PA. Coronary angiography did not identify coronary artery disease and we considered him able to tolerate general anesthesia.

Under general anesthesia he underwent CEA with intraoperative shunting because the blood flow was antegrade and faint. The procedure was uneventful and there were no bleeding complications. The atherosclerotic soft plaque harboring cholesterol was fragile and led to thrombus formation.

He was kept under continuous sedation with dexmedetomidine for 4 days after CEA to avoid intracerebral hemorrhage related to

Received for publication October 19, 2015 ; accepted March 14, 2016.

Address correspondence and reprint requests to Yoko Yamamoto, MD, Department of Neurosurgery Tokushima Prefectural Miyoshi Hospital 815-2, Ikeda-cho Shima Miyoshi-shi, Tokushima, Japan 778-8503 and Fax : +81-8-8372-6910.

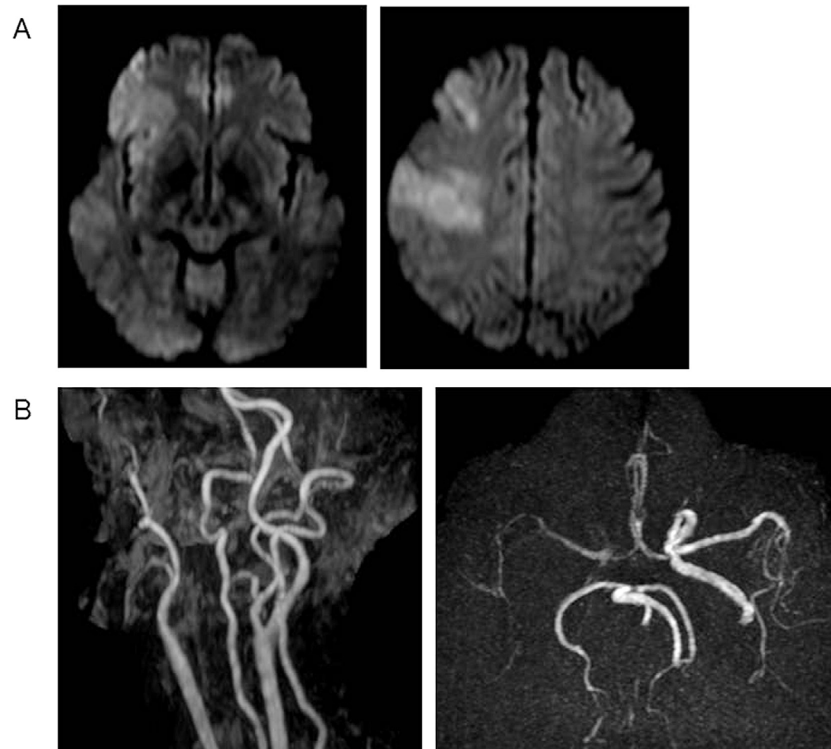


Figure 1

Imaging studies performed at the time of admission.

A. Diffusion-weighted image (DWI) showing multiple high-intensity lesions in the right frontal lobe and insular cortex.

B. Magnetic resonance angiography (MRA) showing occlusion of the cervical portion of the right internal carotid artery (ICA) and faint flow in the right middle- and anterior cerebral arteries via the anterior- and posterior communicating artery providing collateral circulation.

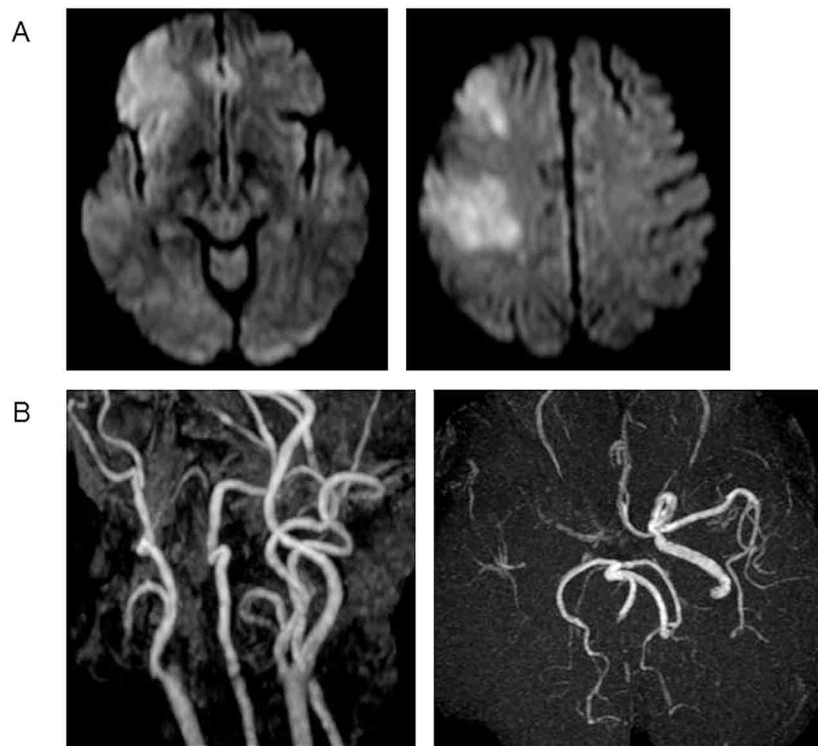


Figure 2

Imaging studies performed after the iv administration of recombinant tissue-type plasminogen activator (rt-PA).

A. DWI showing multiple high-intensity lesions in the right frontal lobe and insular cortex. The ischemic region is clearly depicted. Comparison with the image acquired at the time of admission showed no expansion of the region.

B. After the administration of rt-PA, no recanalization of the right ICA was observed.

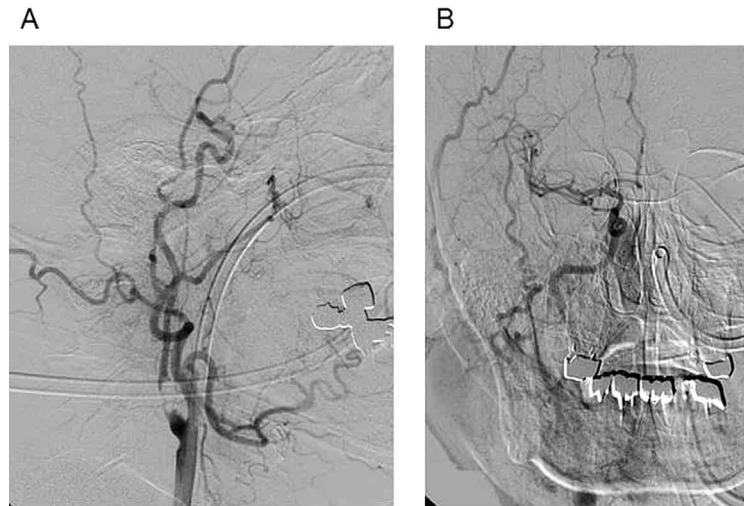


Figure 3

Digital subtraction angiogram showing 95% stenosis of the proximal ICA. Although recanalization of the right ICA occlusion was obtained, the blood flow was very slow and antegrade without supplementary flow from other arteries.

hyperperfusion syndrome and his blood pressure was strictly controlled. In addition, we administered the free radical scavenger edaravone for two weeks. Postoperatively his left severe hemiparesis improved slowly ; his NIHSS score was 5. MRA performed one day post-CEA revealed that his ICA was free of stenosis ; DWI revealed

no new ischemic lesions (Figure 4). Computed tomography performed 3 and 10 days post-CEA showed no intracerebral hemorrhage. One month post-CEA he could walk with a stick and was discharged. His modified Rankin scale (mRS) score 3 months after CEA was 3.

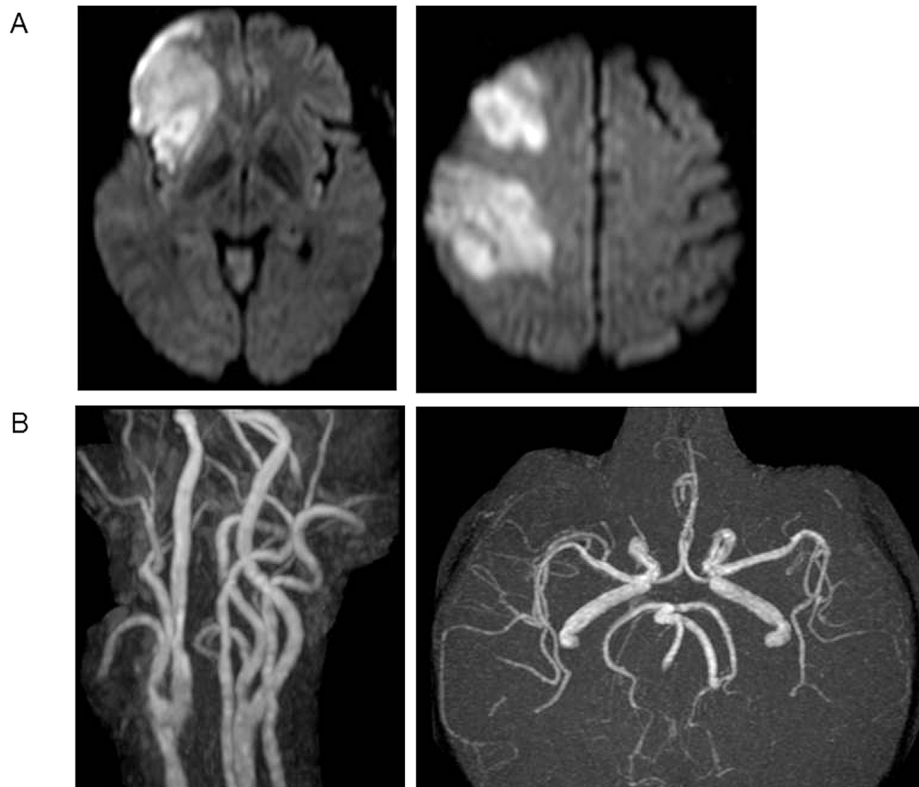


Figure 4

Postoperative imaging studies

A. DWI showing multiple high-intensity lesions in the right frontal lobe and insular cortex, but no new ischemic lesions. Comparison with the image acquired at the time of admission showed no expansion of the ischemic area.

B. MRA showing the ICA free of stenosis. The intracranial ICA and the middle cerebral artery are clearly depicted.

DISCUSSION

We reported a patient with acute ICA occlusion who underwent CEA 10.5 hours after the administration of iv rt-PA. We paid careful attention to stop intraoperative bleeding, we controlled his postoperative blood pressure under sedation, and administered edaravone to prevent hyperperfusion. There were no hemorrhagic complications.

In patients with acute ICA occlusion it is difficult to obtain recanalization after the administration of iv rt-PA alone (3-6). Even after recanalization severe extracranial ICA stenosis may persist, increasing the risk for progressive stroke or ICA reocclusion in the acute phase. Salvage methods for severe residual stenosis at the origin of the ICA include CAS and CEA.

CAS can be performed non-invasively and immediately after evaluation of the cerebral hemodynamic status on cerebral angiographs. It may help to address a critical stenosis resulting in a reduction in the cerebral blood flow in the affected hemisphere during the intervention. Some patients who underwent emergent CAS after rt-PA have been reported (10-12); however, this procedure requires the administration of anticoagulants during and after the operation and may elicit hemorrhagic complications. According to Kimura *et al.* (13), recanalization between 1 and 24 hours after rt-PA therapy was a strong predictor of intracerebral hemorrhage. Consequently, they argued against the administration of antithrombotic agents. Villwock *et al.* (14) reported that CAS plus the administration of rt-PA increased the odds for complications and death. In addition, in the presence of vulnerable carotid plaques or tortuous carotid lesions, and when it is difficult to access the ICA, CAS may not be appropriate.

On the other hand, some patients underwent early CEA after thrombolysis (12, 15-17). Yong *et al.* (15) who assessed the safety of CEA performed 0-54 days after thrombolysis for acute ischemic stroke found that the incidence of intracerebral hemorrhage within the first 30 days was 3%. They suggested that CEA after thrombolysis would be safe.

Patients who undergo emergency CEA within 24 hours after rt-PA are at high risk for intracerebral hemorrhage and only 3 such patients have been reported (18-20). They underwent the procedure 4.2-, 2-, and 6 hours after the iv administration of rt-PA for ICA pseudo-occlusion or occlusion of the common carotid artery and the ICA. Their NIHSS score before CEA was 22, 19, and 5 and none suffered peri-operative hemorrhagic complications. These reports indicate that careful patient selection and post-CEA management are extremely important. Patients with mild neurological deficits, without significant ischemic areas, and those with good collateral flow may be candidates for emergency CEA after rt-PA. Although our patient manifested unstable neurological deficits, angiographs acquired immediately after the administration of iv rt-PA showed good collateral flow that may have contributed to his good outcome.

To avoid post-CEA intracerebral hemorrhage, we administered edaravone and paid special attention to avoid postoperative hypertension. According to Yagi *et al.* (21), while rt-PA induced the up-regulation of matrix metalloproteinase-9 (MMP-9) and elicited intracerebral hemorrhage in rats subjected to 3-hour middle cerebral artery occlusion, edaravone inhibited rt-PA-induced cerebral hemorrhage by inhibiting the expression of MMP-9. In our patient, edaravone plus strict blood pressure control under sedation appears to have prevented post-CEA intracerebral hemorrhage.

Pharmacokinetically, iv rt-PA is very short acting; its serum half-life is only about 5 minutes and C_{max} is reached 55 minutes after the start of its administration. At 90 minutes the blood level decreases to 10% of C_{max} , and at 4 hours it is 1% of C_{max} (18, 20). We posit that at 10.5 hours the effects of iv rt-PA had worn off sufficiently to render CEA safe in our patient. However, plasma markers

to confirm this hypothesis have not been established yet and, further study is needed.

To prevent perioperative complications, in most cases CEA should not be performed less than 24 hours after thrombolysis. However, when the patient is neurologically unstable and the institution has enough experience with CEA, it may be considered as an optional treatment. In our patient, emergency CEA for residual severe ICA stenosis after iv rt-PA treatment resulted in the improvement of his neurological signs and there were no complications. As this report presents our experience with a single patient, further investigations are needed to determine the safety and efficacy of emergency CEA after iv rt-PA treatment and to identify patients who are candidates for emergency CEA.

CONCLUSION

We reported a patient with acute ICA occlusion who underwent successful CEA 10.5 hours after the administration of iv rt-PA. Emergency CEA may be an option to address post-treatment severe residual ICA stenosis. Additional studies are needed to confirm the safety and efficacy of emergency CEA.

CONFLICTS OF INTEREST DISCLOSURE

The authors have no personal financial or institutional interest in any of the drugs, materials, or devices cited in this article.

REFERENCES

- Gertler JP, Blankensteijn JD, Brewster DC, Moncure AC, Cambria RP, LaMuraglia GM, Darling RC Jr, Abbott WM: Carotid endarterectomy for unstable and compelling neurologic conditions: Do results justify an aggressive approach? *J Vasc Surg* 19: 32-42, 1994
- Golledge J, Cuming R, Beattie DK, Davies AH, Greenhalgh RM: Influence of patient-related variables on the outcome of carotid endarterectomy. *J Vasc Surg* 24: 120-126, 1996
- Christou I, Felberg RA, Demchuk AM, Burgin WS, Malkoff M, Grotta JC, Alexandrov AV: Intravenous tissue plasminogen activator and flow improvement in acute ischemic stroke patients with internal carotid artery occlusion. *J Neuroimaging* 12(2): 119-123, 2002
- Mendonça N, Rodríguez-Luna D, Rubiera M, Boned-Riera S, Ribo M, Pagola J, Piñero S, Meler P, Alvarez-Sabin J, Montaner J, Molina CA: Predictors of tissue-type plasminogen activator nonresponders according to location of vessel occlusion. *Stroke* 43: 417-421, 2012
- Gur AY, Shopin L, Bornstein NM: Lessons learned from 2 years experience in interavenous thrombolysis for acute ischemic stroke in a single tertiary medical center. *Isr Med Assoc J* 11(12): 714-718, 2009
- Rubiera M, Alvarez-Sabin J, Ribo M, Montaner J, Santamarina E, Arenillas JF, Huertas R, Delgado P, Purroy F, Molina CA: Predictors of early arterial reocclusion after tissue plasminogen activator-induced recanalization in acute ischemic stroke. *Stroke* 36: 1452-1456, 2005
- Campbell BC, Mitchell PJ, Kleinig TJ, Dewey HM, Churilov L, Yassi N, Yan B, Dowling RJ, Parsons MW, Oxley TJ, Wu TY, Brooks M, Simpson MA, Miteff F, Levi CR, Krause M, Harrington TJ, Faulder KC, Steinfors BS, Priglinger M, Ang T, Scroop R, Barber PA, McGuinness B, Wijeratne T, Phan TG, Chong W, Chandra RV, Bladin CF, Badve M, Rice H, de Villiers L, Ma H, Desmond PM, Donnan GA, Davis SM;

- EXTEND-IA Investigators : Endovascular therapy for ischemic stroke with perfusion-imaging selection. *N Engl J Med* 372(11) : 1009-1018, 2015
8. Goyal M, Demchuk AM, Menon BK, Eesa M, Rempel JL, Thornton J, Roy D, Jovin TG, Willinsky RA, Sapkota BL, Dowlatshahi D, Frei DF, Kamal NR, Montanera WJ, Poppe AY, Ryckborst KJ, Silver FL, Shuaib A, Tampieri D, Williams D, Bang OY, Baxter BW, Burns PA, Choe H, Heo JH, Holmstedt CA, Jankowitz B, Kelly M, Linares G, Mandzia JL, Shankar J, Sohn SI, Swartz RH, Barber PA, Coutts SB, Smith EE, Morrish WF, Weill A, Subramaniam S, Mitha AP, Wong JH, Lowerison MW, Sajobi TT, Hill MD ; ESCAPE Trial Investigators : Randomized assessment of rapid endovascular treatment of ischemic stroke. *N Engl J Med* 372(11) : 1019-1030, 2015
 9. Saver JL, Goyal M, Bonafe A, Diener H-C, Levy EI, Pereira VM, Albers GW, Cognard C, Cohen DJ, Hacke W, Jansen O, Jovin TG, Mattle HP, Nogueira RG, Siddiqui AH, Yavagal DR, Baxter BW, Devlin TG, Lopes DK, Reddy VK, du Mesnil de Rochemont R, Singer OC, Jahan R, for the SWIFT PRIME Investigators : Stent-Retriever Thrombectomy after Intravenous t-PA vs. t-PA Alone in Stroke. *N Engl J Med* 372(24) : 2285-2295, 2015
 10. Dembo T, Deguchi I, Fukuoka T, Nagoya H, Maruyama H, Kato Y, Horiuchi Y, Ohe Y, Tanahashi N : Additional endovascular therapy in patients with acute ischemic stroke who are nonresponsive to intravenous tissue plasminogen activator : Usefulness of magnetic resonance angiography-diffusion mismatch. *J Stroke and Cerebrovascular Disease* 22(7) : 1056-1063, 2012
 11. Sallustio F, Koch G, Rocco A, Rossi C, Pampana E, Gandini R, Meschini A, Diomedi M, Stanzione P, Di Legge S : Safety of early carotid artery stenting after systemic thrombolysis : A single center experience. *Stroke Res Treat* 2012 : 1-5, 2012
 12. Hernan A, Nicolas Z, Bethany J, Taylor A, Gabriel V : Urgent carotid intervention is safe after thrombolysis for minor to moderate acute ischemic stroke. *J Vasc Surg. Dec* 62(6) : 1529-1538, 2015
 13. Kimura K, Iguchi Y, Shibazaki K, Kobayashi K, Uemura J, Aoki J, Yamashita S, Terasawa Y, Matsumoto N : Recanalization between 1 and 24 hours after t-PA therapy is a strong predictor of cerebral hemorrhage in acute ischemic stroke patients. *J Neurol Sci* 270 : 48-52, 2008
 14. Villwock MR, Singla A, Padalino DJ, Ramaswamy R, Deshaies EM : Optimum timing of revascularization for emergent admissions of carotid artery stenosis with infarction. *Clin Neurol Neurosurg* 127 : 128-33, 2014
 15. Yong YP, Saunders J, Abisi S, Sprigg N, Varadhan K, MacSweeney S, Altaf N : Safety of carotid endarterectomy following thrombolysis for acute ischemic stroke. *J Vasc Surg* 58(6) : 1671-1677, 2013
 16. Bartoli MA, Squarcioni C, Nicoli F, Magnan PE, Malikov S, Berger L, Lerussi GB, Branchereau A : Early carotid endarterectomy after intravenous thrombolysis for acute ischaemic stroke. *Eur J Vasc Endovasc Surg* 37(5) : 512-518, 2009
 17. Crozier JE, Reid J, Welch GH, Muir KW, Stuart WP : Early carotid endarterectomy following thrombolysis in the hyperacute treatment of stroke. *Br J Surg* 98(2) : 235-238, 2011
 18. Tei R, Uranishi R, Kobayashi J, Nishi N, Fukuda T, Sinomiya K, Asada K : A case of a carotid endarterectomy for atheromatous pseudo-occlusion of the internal carotid artery immediately after rt-PA therapy : A case report. *Jpn J Stroke* 33 : 451-457, 2011 (in Japanese)
 19. Curtze S, Putaala J, Saarela M, Vikatmaa P, Kantonen I, Tatlisumak T : Carotid Embolectomy and Endarterectomy for Symptomatic Complete Occlusion of the Carotid Artery as a Rescue Therapy in Acute Ischemic Stroke. *Case Report. Neurology* 3(3) : 301-308, 2011
 20. McPherson CM, Woo D, Cohen PL, Pancioli AM, Kissela BM, Carrozzella JA, Tomsick TA, Zuccarello M : Early carotid endarterectomy for critical carotid artery stenosis after thrombolysis therapy in acute ischemic stroke in the middle cerebral artery. *Stroke* 32(9) : 2075-2080, 2001
 21. Yagi K, Kitazato KT, Uno M, Tada Y, Kinouchi T, Shimada K, Nagahiro S : Edaravone, a free radical scavenger, inhibits MMP-9-related brain hemorrhage in rats treated with tissue plasminogen activator. *Stroke* 40(2) : 626-631, 2009