

## ORIGINAL

# Ambulatory Surgery for Pilonidal Sinus : Tract Excision and Open Treatment Followed by At-Home Irrigation

Yutaro Yamashita<sup>1,2</sup>, Hiroaki Nagae<sup>1</sup>, and Ichiro Hashimoto<sup>2</sup>

<sup>1</sup>Department of Plastic Surgery, Tokushima Red Cross Hospital, Komatsushima, <sup>2</sup>Department of Plastic and Reconstructive Surgery, Tokushima University Graduate School, Tokushima, Japan

**Abstract :** Pilonidal sinus is a cystic disease that occurs most often in the sacrococcygeal region. Surgical excision and coverage with a skin flap require postoperative bed rest. Most affected patients are young adults who find it difficult to obtain adequate postoperative bed rest owing to their work. The purpose of this study is to review the effectiveness of our ambulatory surgery procedure for pilonidal sinus, which involves tract excision and open treatment followed by at-home irrigation. We reviewed the 9 cases of chronic pilonidal sinus treated at our out-patient clinic by ambulatory surgery consisting of open excision without skin closure. Patients were sent home after careful observation for hemostasis at the surgical site. Postoperative wound treatment and irrigation were performed at home by the patients themselves. The mean immediate postoperative follow-up period was 22.3 days (13 to 31 days), and the mean number of follow-up visits was 3.3. No serious complication and recurrence was noted during the long-term follow-up period of 26.3 months (1 to 60 months). Although the healing time following our ambulatory procedure was not short, no postoperative rest was required, and the recurrence rate was zero. We believe this procedure is useful for selected patients with pilonidal sinus. *J. Med. Invest.* 63 : 216-218, August, 2016

**Keywords :** pilonidal sinus, ambulatory surgical procedures, therapeutic irrigation

## INTRODUCTION

Pilonidal sinus is a disease that most commonly arises in the hair follicles of the natal cleft of the sacrococcygeal region. The cause is uncertain but relates to an invagination of loose hair into the skin of the natal cleft. The invaginated hair leads to a foreign body reaction that results in inflammation and abscess formation. The disorder affects males twice as often as females and predominantly young adults of working age.

Many surgical treatments have been reported, including simple incision and drainage (1, 2), unroofing and marsupialization (3, 4), excision with secondary healing (5, 6), excision and primary closure (7, 8), and excision and flap closure (9). However, none has emerged as the best treatment option. Open treatment after excision of the pilonidal sinus has a low recurrence rate, but healing time is longer than with primary closure (8). We have performed ambulatory surgery that includes tract excision without skin closure, which are followed by at-home irrigation. The aim of this study was to review the effectiveness of this simple procedure, which requires no postoperative hospitalization.

## METHODS

### Patients

Between 2008 and 2013, 11 patients were treated for chronic pilonidal sinus at Tokushima Red Cross Hospital. One patient had a large lesion (8×12 cm) that had recurred twice and was treated with tract excision and flap closure. Each of the other 10 patients

had a narrow, simple, non-recurrent pilonidal sinus (width < 3 cm). The first of these 10 patients was hospitalized for lesion excision without skin closure. The postoperative course in this case was uneventful, so we began to perform the same procedure on an out-patient basis, treating the other 9 patients accordingly after obtaining informed consent from each patient. We conducted a retrospective study of the effectiveness of the procedure in this patient group, which comprised 8 men and 1 woman.

### Surgical technique

The procedure was performed under local anesthesia by two operators (Y.Y. and H.N.). After the roof of the tract was incised, the tract wall was completely removed including debris, hair, and granulation tissue. Hemostasis was obtained with electrocoagulation. The wound was not closed with suture but simply covered with calcium alginate (Kaltostat, ConvaTec, Tokyo, Japan) with the dual aim of hemostasis and pain relief. Follow-up treatments were performed daily by the patients at home. The patients were instructed to irrigate the ulcers with shower water and apply white petrolatum to the wound and to contact us immediately when continuous bleeding occurred. No postoperative antibiotic medication was prescribed. The patients were instructed to keep the sacrococcygeal region shaved. We let the patients return to work on the first day after the surgery. The patients visited our hospital for follow-up examinations approximately once a week. Medical examinations were discontinued when the ulcer became sufficiently narrow (width < 5 mm) or fully healed. Every patient was directed to report to us if the lesion recurred.

### Data collection

Data were collected from patients' clinical records and included the following : number of times the patient visited our office after the surgery, date of the final visit, status of the wound at the final visit, any short- or long-term complications, any recurrence, and the total follow-up period. Information about any recurrence was

Received for publication November 9, 2015 ; accepted March 30, 2016.

Address correspondence and reprint requests to Ichiro Hashimoto, MD, PhD, Department of Plastic and Reconstructive Surgery, Tokushima University Graduate School, 3-18-15 Kuramoto, Tokushima 770-8503, Japan and Fax : +81-88-633-7297.

gathered via telephone interview when contact with the patient was possible.

**RESULTS**

Patients and follow-up details are shown on the Table. Patients' mean age was 24.5 years (17 to 34 years). The final examination was performed 13 to 31 days (mean : 22.3 days) after the surgery. The mean number of office visits was 3.3 (2 to 5) including the final examination. Upon the final visit, the ulcer was narrow and linear in 6 patients and fully healed in 2 (Figure). One patient (Patient 4) ceased visiting our hospital when the ulcer was mid-sized (5×1 cm). No complications were found in 6 patients. A little bleeding from the postoperative wound was found in 2 patients. One patient had a continuous, slight feeling of discomfort at the sacrococcygeal region. The follow-up period ranged from 1 to 60 months (average : 26.3 months), and there was no recurrence in any patient.

**DISCUSSION**

Two kinds of laying open methods for pilonidal sinus have been reported thus far. One is the marsupialization method (4), in which the residual cavity is sutured to the edges of the slit skin. The other is excision of the whole sinus followed by secondary healing (7, 10). Marsupialization requires several days of postoperative rest because of the sutures. So the patients in whom marsupialization is performed must remain absent from their work for several days. Disadvantages of the laying open method over the primary closure and flap reconstruction methods are the longer healing time and longer time off work (11). Our method is similar to the laying open method without suturing (7, 10), but it is characterized by the fact that it is an outpatient procedure, by the non-necessity of postoperative rest, by the permission we give the patient to return to work on the day after surgery, and by the at-home showering/cleansing of the postoperative wound.

Concepts regarding wound care have changed over the past 10 years. It is generally accepted that tap water is effective for wound cleansing (12). In fact, a significant reduction in infection of acute adult wounds has been reported with the use of tap water versus

Table. Patient characteristics and postoperative follow-up details

Patient		1	2	3	4	5	6	7	8	9
Age (years) & sex		31 M	19 M	28 F	21 M	17 M	34 M	23 M	24 M	24 M
Postoperative follow-up	No. of days	24	26	21	14	13	17	35	31	20
	No. of postoperative clinic visits	3	2	2	4	3	3	4	5	4
	Wound status	Linear ulcer	Healed	Linear ulcer	Mid-sized ulcer	Linear ulcer	Linear ulcer	Linear ulcer	Healed	Linear ulcer
Complication		None	None	None	Slight bleeding	None	None	Slight discomfort	None	Slight bleeding
Long-term follow-up period (months)		10	60	1	45	43	43	15	10	10

M, male ; F, female

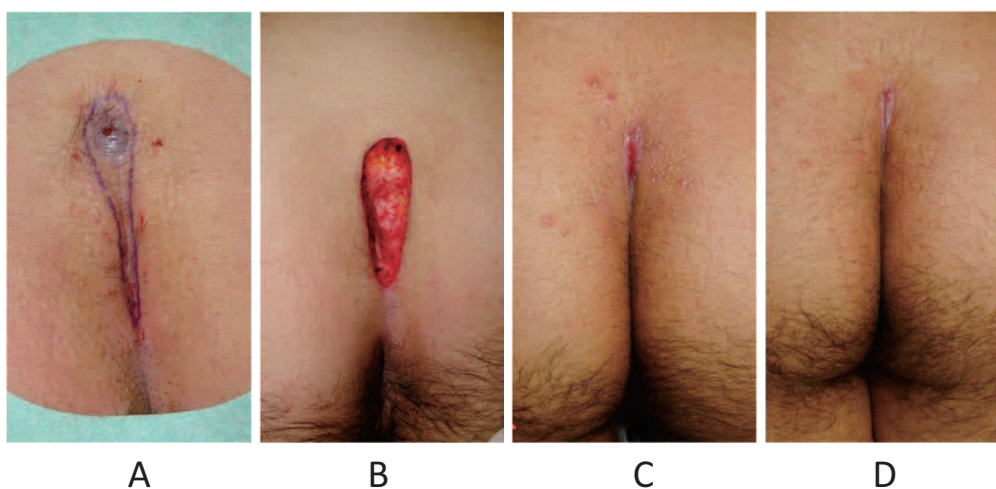


Figure : Pilonidal sinus in a 19-year-old man (Case 2).

(A) Intraoperative view. Incisional skin margin is marked. (B) Intraoperative view. The sinus and diseased skin are excised. Careful hemostasis is performed. (C) Appearance of the surgical wound on postoperative day 15 (first follow-up visit after surgery). A small linear ulcer remains. (D) Appearance on postoperative day 26 (second follow-up visit after surgery). The ulcer has healed.

saline solution (12). Together, tap water cleansing and petrolatum application were shown to be effective for open treatment of pilonidal sinus in our study patients. The at-home postoperative wound treatment shortens a patient's time off work and lowers medical expenses.

The ideal treatment of pilonidal sinus will yield minimal patient inconvenience, a short time off work, quick healing, and a low recurrence rate. The recurrence rate reported for the laying open method is lower than or the same as that reported for the primary closure method (8, 13). Our method appears to satisfy the requirement for minimal patient inconvenience, a short time off work, and a low recurrence rate. The disadvantage of our method is the long time needed for healing of the postoperative wound. However, because of the self-care that is established, the patient does not need frequent clinic visits.

Our study was limited by the small number of cases and the unvaried indications for surgical treatment. All of our patients had a simple, small pilonidal sinus. We have not yet experienced cases of severe infection. A complex and large pilonidal sinus, which has branched or is severely infected, may influence the healing time and complications encountered after our ambulatory procedure.

In summary, ambulatory tract excision and open treatment followed by at-home irrigation appears to be effective for simple pilonidal sinus. The method avoids the need for time off work after the operation and it minimizes other patient inconveniences.

#### CONFLICT OF INTERESTS

The authors have indicated no significant interest with commercial supporters.

#### REFERENCES

1. Khalil NP, Brand D, Siebeck M, Hallfeldt K, Mutschler W, Kanz KG : Aspiration and injection-based technique for incision and drainage of a sacrococcygeal pilonidal abscess. *J Emerg Med* 36 : 60-63, 2009
2. Tsoraidis SS, Pearl HR, Stanfill BA, Wallace LJ, Vegunta RK : Incision and loop drainage : a minimally invasive technique for subcutaneous abscess management in children. *J Ped Surg* 45 : 606-609, 2010
3. Lawrence BK, Baker JW : The marsupialization operation for pilonidal sinus : A comparison with other surgical methods in 359 cases. *N Engl J Med* 245 : 134-139, 1951
4. Karakayali F, Karagulle E, Karabulut Z, Oksuz E, Moray G, Haberal M : Unroofing and Marsupialization vs. rhomboid excision and Limberg flap in pilonidal disease : a prospective, randomized, clinical trial. *Dis Colon Rectum* 52 : 496-502, 2009
5. Rogers H, Dwight WR : Pilonidal sinus : Observations on one hundred forty cases treated by cautery excision. *Ann Surg* 107 : 400-418, 1938
6. Marks J, Harding G, Hughes EL, Ribeiro CD : Pilonidal sinus excision-healing by open granulation. *Br J Surg* 72 : 637-640, 1985
7. Lorant T, Ribbe I, Mahteme H, Gustafsson UM, Graf W : Sinus excision and primary closure versus laying open in pilonidal disease : a prospective randomized trial. *Dis Colon Rectum* 54 : 300-305, 2011
8. McCallum I, King PM, Bruce J : Healing by primary closure versus open healing after surgery for pilonidal sinus : systematic review and meta-analysis. *BMJ* 336 : 868-871, 2008
9. Altintoprak F, Gundogdu K, Ergonenc T, Dikicier E, Cakmak G, Celebi F : Retrospective review of pilonidal sinus patients with early discharge after Limberg flap procedure. *Int Surg* 99 : 28-34, 2014
10. Kepenekci I, Demirkan A, Celasin H, Gecim IE : Unroofing and Curettage for the treatment of acute and chronic pilonidal disease. *World J Surg* 34 : 153-157, 2010
11. Allen-Mersh TG : Pilonidal sinus : finding the right track for treatment. *Br J Surg* 77 : 123-132, 1990
12. Cooper DD, Seupaul AR : Is water effective for wound cleansing? *Ann Emerg Med* 60 : 626-627, 2012
13. Aydede H, Erhan Y, Sakarya A, Kumkumoglu Y : Comparison of three methods in surgical treatment of pilonidal disease. *ANZ J Surg* 71 : 362-364, 2001