

## CASE REPORT

# Revision percutaneous endoscopic lumbar discectomy under the local anesthesia for the recurrent lumbar herniated nucleus pulposus in a high class athlete : A case Report

Kazuta Yamashita, Kosaku Higashino, Toshinori Sakai, Yoichiro Takata, Mitsunobu Abe, Masatoshi Morimoto, Akihiro Nagamachi, and Koichi Sairyo

*Department of Orthopedics, Tokushima University Graduate School, 3-18-15 Kuramoto, Tokushima 770-8503, Japan*

**Abstract :** Percutaneous endoscopic discectomy (PED) is a minimally invasive spinal technique and has several advantages compared with open surgery. We describe repeat PED surgery for recurrent herniated nucleus pulposus (HNP). The patient was a 33-year-old handball high level player. Previously, he underwent transforaminal PED under local anesthesia for intracanalicular HNP at L4-5 level about 2 years ago. He could return to his original competitive level. Two years later, he felt low back and right leg pain again when he was playing handball. Magnetic resonance imaging revealed the recurrence of HNP at the same level. We conducted transforaminal PED again using the exact same route as the previous surgery. Although there was a little adhesion around the L5 nerve root, we could easily identify and remove the herniated mass using endoscopic forceps. Immediately after the surgery, the low back and leg pain disappeared. Repeat PED surgery for recurrence of lumbar disc herniation is effective especially for athletes because of the benefits of PED, including surgery under local anesthesia, preservation of normal posterior structures, less postoperative pain, early discharge, and faster return to sports. *J. Med. Invest.* 63 : 135-139, February, 2016

**Keywords :** *Percutaneous endoscopic discectomy, Revision surgery, Recurrence, Athlete*

## INTRODUCTION

Percutaneous endoscopic discectomy (PED), a type of minimally invasive spinal surgery, has several advantages, including less paravertebral muscle damage, preservation of bony structures, and rapid recovery. PED surgery under local anesthesia is possible. Hijikata (1) first introduced the transforaminal approach called percutaneous lumbar discectomy. Kambin (2) was another pioneer of this approach. Kambin (3) and Schreiber and Leu (4) have utilized an endoscope or arthroscope in the transforaminal approach. Thanks to their efforts, the technique and instrumentation of PED have significantly improved (5, 6).

One of the complications after disc surgery is recurrence of the herniated nucleus pulposus (HNP). The generally accepted surgical management for recurrence of HNP is open lumbar surgery. However, complications caused by the surgical approach itself should be considered. The initial open discectomy surgery causes epidural scarring surrounding the nerve root and dura mater. Thus, dural tear and nerve root damage are possible complications during the second open surgery (7). Facetectomy and spinal fusion may be required to make a safe approach to the HNP fragments in recurrent disease (8).

For recurrent disc herniation after primary open lumbar discectomy, PED using the transforaminal approach has several advantages over repeat open lumbar discectomy. In the transforaminal approach of PED, the cannula and endoscope does not need to pass through the epidural scar. Furthermore, it may not require additional facetectomy. Some studies have reported that PED showed

favorable outcomes for recurrent disc herniation (9, 10).

HNP can reoccur after PED surgery. However, to our knowledge, no report has described repeat PED for recurrence of HNP that had been treated once by PED. In this paper, we describe repeat PED for recurrent HNP in a high-level, male handball player.

## CASE REPORT

The patient was a 33-year-old man who was a high-level handball player. He had a past medical history of PED transforaminal surgery for HNP at L4-5 in 2013. The magnetic resonance imaging (MRI) findings before the first PED are shown in Figure 1. He had undergone PED surgery at L4/5 under local anesthesia in August 2013, during which the HNP fragment was successfully removed endoscopically (Fig. 2). The MRI findings after the surgery (Fig. 3) showed that the fragment had been removed. He resumed sporting activity 2 months later and returned to his original competitive level. However, in February 2015, he felt discomfort in the lower back on landing after a jump, and low back and right leg pain gradually returned.

Physical examination demonstrated a positive straight leg raise test at 70 degrees on the right side. There was neither muscle weakness nor abnormal reflexes. He felt pain at the lower back and right leg on lumbar flexion. MRI revealed right paracentral HNP at L4/5 level, which was at the same place as the initial episode (Fig. 4). The patient's symptoms did not improve after 3 months of conservative treatment ; thus, we repeated the transforaminal PED surgery using the exact same route as the previous PED surgery.

### *Surgical technique*

The procedure was performed under local anesthesia with the patient in the prone position on a radiolucent table and under the

Received for publication August 19, 2015 ; accepted November 9, 2015.

Address correspondence and reprint requests to Kazuta Yamashita, MD, Department of Orthopedics, Tokushima University Graduate School, 3-18-15 Kuramoto, Tokushima 770-8503, Japan and Fax : +81-88-633-0178.

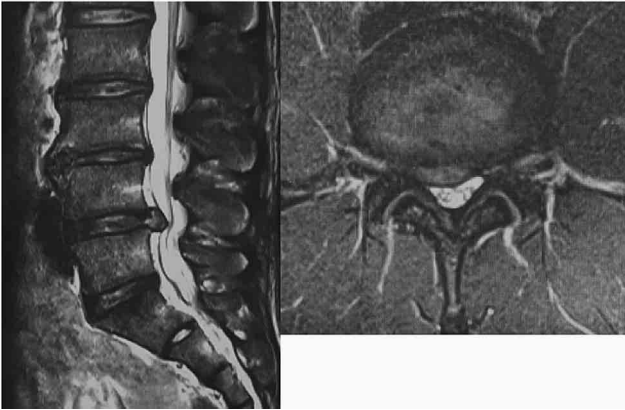

Figure 1. Magnetic resonance imaging (MRI) (T2-weighted sagittal and axial view at L4/5 level) before the first surgery. MRI showed the right paracentral disc protrusion at L4/5 level compressing the L5 root.

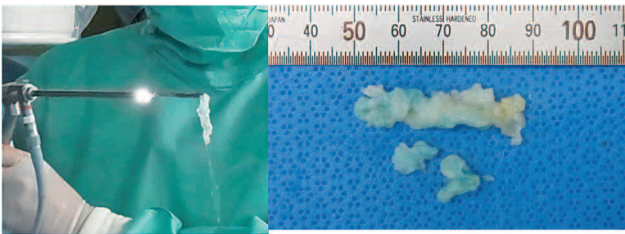


Figure 2. In the first percutaneous endoscopic discectomy (PED), the herniated nucleus pulposus (HNP) fragment was endoscopically removed.

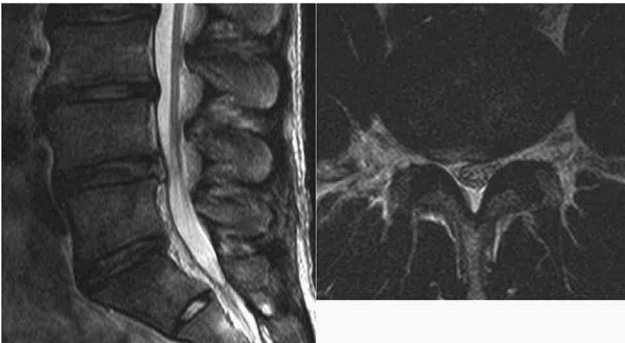


Figure 3. MRI (T2-weighted sagittal and axial view at L4/5 level) after the initial PED. The HNP was removed by PED using the transforaminal approach.

guidance of C-arm fluoroscopy. Since the location of the present HNP was almost the same as the HNP before the initial PED, we selected the transforaminal approach using the same entry point. The skin entry point was about 10 cm from the midline at L4-5 level, which was the same as that in the first PED. After local anesthesia (1% lidocaine) was administered about 10 ml around the skin entry point, an 18-gauge spinal needle was introduced under fluoroscopic imaging. Following insertion of a spinal needle into the disc, an intraoperative discogram with a mixture of indigo carmine and contrast medium was made. We confirmed the leakage of the contrast medium through the tear in the annulus and epidural

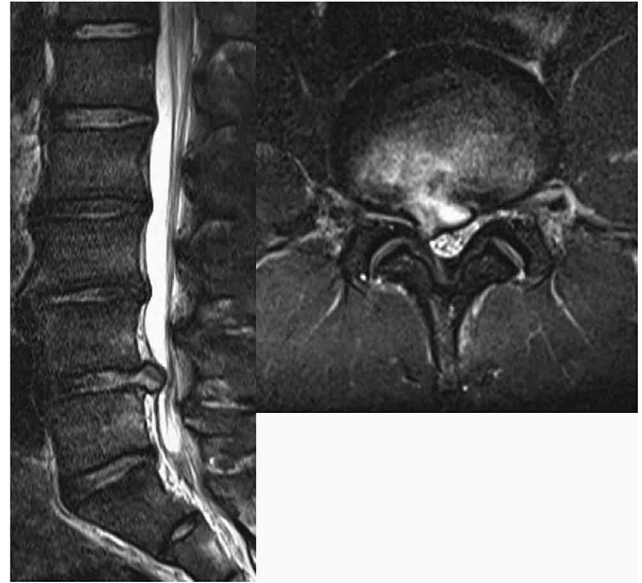


Figure 4. Recurrence of the lumbar disc herniation on the right side of L4/5. MRI revealed right paracentral disc protrusion at L4/5 level. PED had been performed 2 years ago for disc herniation on the same side and at the same level.

space, indicating that the herniated fragment of the nucleus pulposus should be stained blue, helping to identify the herniated fragment. A guide wire was then inserted through the spinal needle, and the needle was removed. An 8-mm skin incision was made at the site of the incisional scar of the previous PED (Fig. 5). A tapered cannulated obturator followed by a bevel-type cannula were inserted. The percutaneous endoscope was inserted at the affected disc space through the cannula. The blue-stained nucleus pulposus was removed using small forceps. After securing a subannular working cavity, delicate epidural exploration and selective removal of the extruded nucleus were performed.

There was a little adhesion around the L5 root and epidural space. The endoscope was positioned at the site where we could simultaneously visualize both the epidural and intradiscal space in a single endoscope frame (Fig. 6). All fragments were stained blue, which was very helpful for differentiating them from neural tissue (Fig. 7).

The endoscope and instruments were removed, and any remaining fluid was discharged by manually squeezing the skin around the portal, followed by placement of the catheter, wound closure using a single stitch, and application of a sterile dressing. The duration of the PED surgery was 57 min and there was limited blood loss. We did not encounter any surgery-related complications such as nerve root damage, dural tear, hematoma, neck pain, or infection (11).

The patient's symptoms completely subsided immediately after the procedure. The patient was able to stand and walk about 2 h after the surgery. Postoperative MRI revealed sufficient removal of the herniated disc (Fig. 8).

## DISCUSSION

HNP is the most common disorder of the lumbar spine, and it is occasionally treated surgically. Highly successful results have been obtained with traditional open discectomy including microdiscectomy (12), microendoscopic discectomy (13), and percutaneous

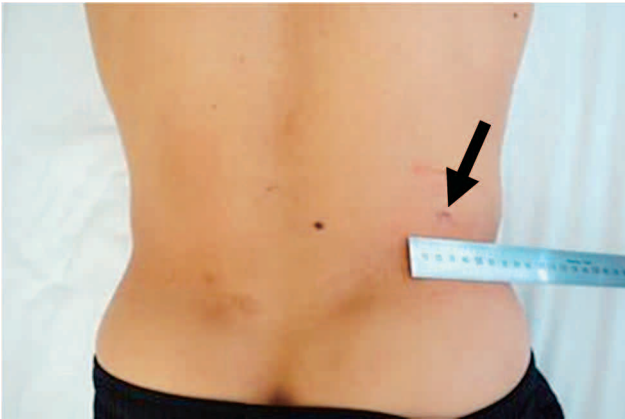


Figure 5. Appearance of the surgical scar. An 8-mm surgical incisional scar was present, which was where the incision was made in the first PED.

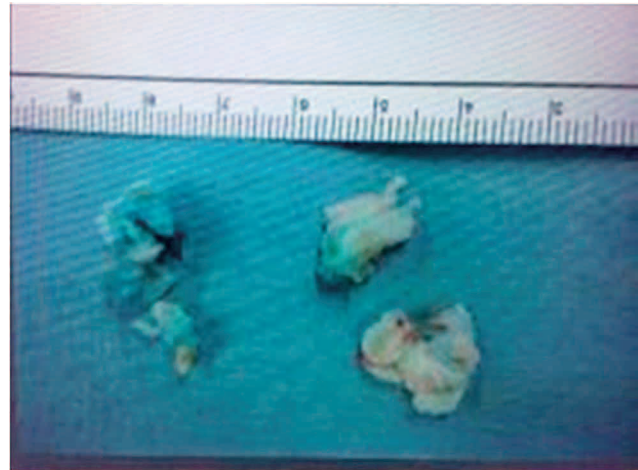

Figure 7. The appearance of the removed HNP, which was stained in blue.

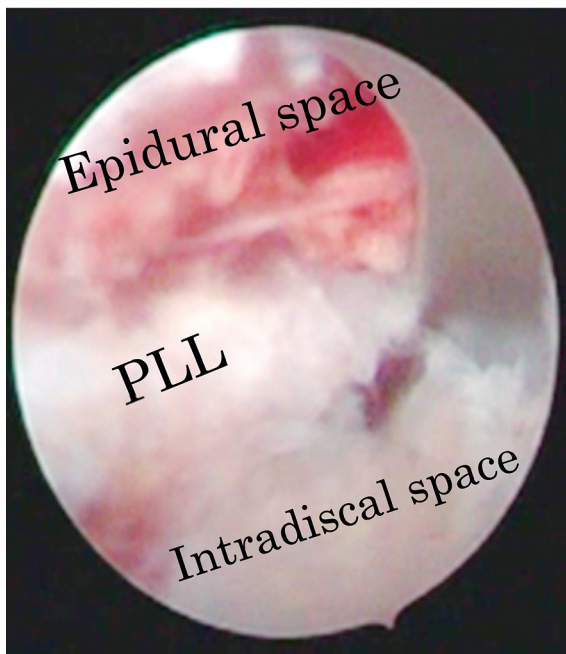


Figure 6. Endoscopic view. The endoscope was positioned at the site where we could simultaneously visualize both the epidural and intradiscal spaces in a single endoscope frame. PLL : posterior longitudinal ligament.

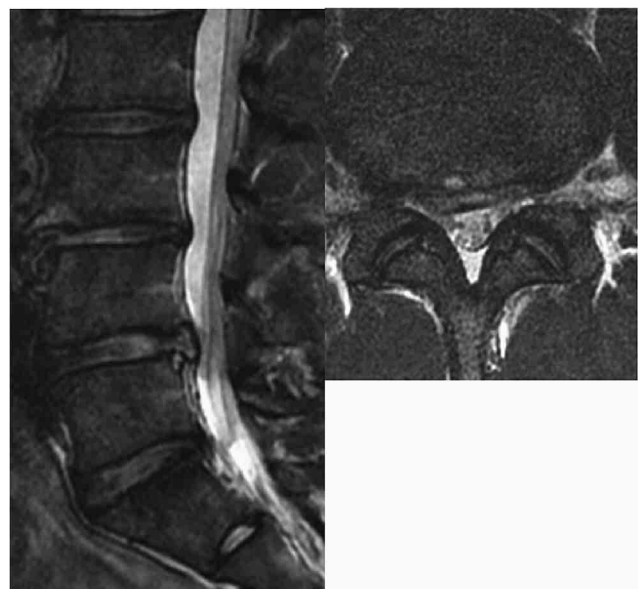


Figure 8. MRI (T2-weighted sagittal and axial view at L4/5 level) after repeat PED. The HNP was removed by PED using a transforaminal approach.

endoscopic discectomy (14). However, recurrence of HNP is one of the problems with these procedures. Recurrent disc herniation has been reported in 5-18% of patients after initial surgery (15, 16). Open microdiscectomy is the most commonly recommended surgical option for recurrent lumbar disc herniation. Although open microdiscectomy for recurrent disc herniation shows favorable results, approach-related complications due to epidural scar tissue and segmental instability caused by further damage to vertebral motion segments including the facet joints are major concerns (17).

PED is a form of minimally invasive surgery and has many advantages over conventional open lumbar surgery. These advantages include the possibility of local anesthesia, preservation of normal posterior and paraspinal structures, less postoperative pain,

and early discharge. Following the evolution of surgical instruments including development of the high-speed drill, different types of HNP can be removed by PED (18) such as far-lateral HNP (19), migrated intracanalicular HNP (20), and hidden zone HNP (21). On the other hand, PED has a disadvantage of radiation exposure by fluoroscopy. During insertion of a spinal needle into the disc, the surgeon has to use fluoroscopy to view the internal anatomy.

There are some studies which have discussed the use of PED for patients with recurrence of disc herniation following open discectomy. Ahn *et al.* (5) reported a retrospective study of 43 consecutive patients who underwent PED for recurrent disc herniation. After a mean follow-up duration of 31 months, the mean VAS score significantly decreased and 81.4% of the patients showed excellent or good outcomes based on Macnab criteria. Hoogland *et al.* (10) performed a prospective evaluation of a cohort of 262 patients who received PED for recurrence of disc herniation. Both leg pain and back pain significantly improved, and the results of their



surgeries were rated as excellent or good in 85.71% of the patients at the 2-year follow-up.

HNP can recur after PED surgery. Sairyo (22) reported that the recurrence rate of HNP after PED surgery was about 10%, which was similar to that of open surgery and MED. However, there are only a few articles in the literature describing the surgical technique and endoscopic findings. In this case, we performed PED surgery again via the ipsilateral transforaminal route for recurrence of HNP. We used the same transforaminal approach from the same insertion point on the skin as the initial surgery. Although there was a little adhesion in the epidural space around the L5 root, the herniated mass could be removed easily. The scarring around the exiting L4 nerve root was also a concern; however, cannulation of the disc space could be performed without any irritation of the exiting nerve. Based on this experience, we confirmed that transforaminal PED surgery would be favorable for recurrent HNP, even if the initial surgery was also transforaminal PED.

The major concern in repeat surgery for recurrent disc herniation is approach-related complications. Scar tissue usually makes repeat surgery more difficult and increases the risk of dural tear and nerve root injury. The incidence of dural tear during repeat open lumbar surgery was reported to be up to 20% (23). It was suggested that dural tear during lumbar disc surgery was associated with long-term clinical sequelae and poorer clinical outcomes (24). Lee *et al.* (25) reported that there was 1 (3.4%) patient who developed persistent voiding disturbance along with dysesthesia after repeated open lumbar surgery in a series of 28 consecutive patients.

Regarding the complications of PED for patients with recurrence of disc herniation following open discectomy, Ahn *et al.* (5) reported that dural tear did not occur in their cohort of 43 consecutive patients. Hoogland *et al.* (10) also reported no definite dural leakage after surgery in 262 consecutive patients, but 3 patients (1.1%) had nerve root irritation. Xia *et al.* (26) reported 1 patient (2.3%) with transient dysesthesia. No patient suffered permanent injury of the nerve root in either series.

Regarding postoperative spinal stability, discectomy through the transforaminal route has advantages over that through the posterior route. As mentioned above, paravertebral and posterior spinal structures such as lamina, facet joint, ligaments, and muscles could be preserved by means of the transforaminal approach in PED. Osman *et al.* (27) reported a comparative study regarding postoperative stability of the transforaminal and posterior approaches using cadavers. After transforaminal decompression, there was minimal anatomic damage to the spine and there was no change in flexibility. In contrast, there was significant increase in extension and axial rotation flexibility after posterior decompression.

The current case involves a high-level athlete, so a minimally invasive technique was employed to avoid damage to the back muscles, facet joints, and ligaments. Furthermore, surgery-related instability should be prevented. Therefore, repeat PED should be the procedure of choice based on the above conditions. The patient returned to his original activity level 8 weeks after the initial surgery and resumed his position. Now 6 months has passed after the repeat surgery. He plays handball without any evidence of recurrence.

## CONCLUSION

We demonstrated that repeat PED for recurrence of lumbar disc herniation is effective, especially for athletes, because of the benefits of PED, namely, surgery under local anesthesia, preservation of normal posterior and paraspinal structures, less postoperative pain, fewer surgery-related complications, early discharge, and faster return to sports.

## CONFLICT OF INTEREST

No funds were received in support of this study.

## REFERENCES

- Hijikata S : Percutaneous nucleotomy. A new concept technique and 12 years' experience. *Clin Orthop Relat Res* 238 : 9-23, 1989
- Kambin P, Schaffer JL : Percutaneous lumbar discectomy. Review of 100 patients and current practice. *Clin Orthop Relat Res* 238 : 24-34, 1989
- Kambin P : Arthroscopic microdiscectomy. *Mt Sinai J Med* 58(2) : 159-164, 1991
- Schreiber A, Leu H : Percutaneous nucleotomy technique with discoscopy. *Orthopedics* 14(4) : 439-444, 1991
- Ahn Y, Lee SH, Park WM : Posterolateral percutaneous endoscopic lumbar foraminotomy for L5-S1 foraminal or lateral exit zone stenosis. Technical note. *J Neurosurg* 99 : 320-323, 2003
- Ruetten S, Komp M, Merk H : Surgical treatment for lumbar lateral recess stenosis with the full-endoscopic interlaminar approach versus conventional microsurgical technique : A prospective, randomized, controlled study. *J Neurosurg Spine* 10 : 476-485, 2009
- Wang JC, Bohlman HH, Riew DK : Dural tears secondary to operations on the lumbar spine : Management and results after a two-year-minimum follow-up of eighty-eight patients. *J Bone Joint Surg Am.* 80 : 1728-1732, 1998
- McGirt MJ, Ambrossi GL, Dato G : Recurrent disc herniation and long-term back pain after primary lumbar discectomy : review of outcomes reported for limited versus aggressive disc removal. *Neurosurgery* 64(2) : 338-344, 2009
- Ahn Y, Lee SH, Park WM : Percutaneous endoscopic lumbar discectomy for recurrent disc herniation : surgical technique, outcome, and prognostic factors of 43 consecutive cases. *Spine* 29 : E326-E332, 2004
- Hoogland T, van den Brekel-Dijkstra K, Schubert M : Endoscopic transforaminal discectomy for recurrent lumbar disc herniation : a prospective, cohort evaluation of 262 consecutive cases. *Spine* 33 : 973-978, 2008
- Sairyo K, Matsuura T, Higashino K, Sakai T : Surgery related complications in percutaneous endoscopic lumbar discectomy under local anesthesia. *J Med Invest* 61 : 264-269, 2014
- Gibson JN, Waddell G : Surgical interventions for lumbar disc prolapse. *Cochrane Database Syst Rev* 18(2) : CD001350, 2007
- Huang TJ, Hsu RW, Li YY : Less systemic cytokine response in patients following micro endoscopic versus open lumbar discectomy. *J Orthop Res* 23(2) : 406-411, 2005
- Yeung AT, Tsou PM : Posterolateral endoscopic excision for lumbar disc herniation : surgical technique, outcome, and complications in 307 consecutive cases. *Spine* 27 : 722-731, 2002
- Carragee EJ, Spinnickie AO, Alamin TF : A prospective controlled study of limited versus subtotal posterior discectomy : short-term outcomes in patients with herniated lumbar intervertebral discs and large posterior annular defect. *Spine* 31 : 653-657, 2006
- Javedan S, Sonntag VK : Lumbar disc herniation : microsurgical approach. *Neurosurgery* 52 : 160-164, 2003
- Ozgen S, Naderi S, Ozek MM : Findings and outcome of revision lumbar disc surgery. *J Spinal Disord* 12 : 287-292, 1999
- Sairyo K, Egawa H, Matsuura T, Higashino K : State of the Art : Transforaminal Approach for percutaneous endoscopic

- lumbar discectomy under local anesthesia. *J Med Invest* 61 : 217-225, 2014
19. Kitagawa Y, Sairyo K, Shibuya I : Minimally invasive and simultaneous removal of herniated intracanal and extracanal lumbar nucleus pulposus with a percutaneous spinal endoscope. *Asian J Endosc Surg* 5(4) : 183-186, 2012
  20. Kitahama Y, Sairyo K, Dezawa A : Percutaneous endoscopic transforaminal approach to decompress the lateral recess in an elderly patient with spinal canal stenosis, herniated nucleus pulposus and pulmonary comorbidities. *Asian J Endosc Surg* 6(2) : 130-133, 2013
  21. Dezawa A, Mikami H, Sairyo K : Percutaneous endoscopic translaminar approach for herniated nucleus pulposus in the hidden zone of the lumbar spine. *Asian J Endosc Surg* 5(4) : 200-203, 2012
  22. Sairyo K, Matsuura T, Higashino K : Percutaneous endoscopic lumbar discectomy for Athletes. *J Spine S5* : 006, 2013
  23. Morgan-Hough CVJ, Jones PW, Eisenstein SM : Primary and revision lumbar discectomy. *J Bone Joint Surg Br* 85 : 871-874, 2003
  24. Saxler G, Kramer J, Barden B : The long-term clinical sequelae of incidental durotomy in lumbar disc surgery. *Spine* 30 : 2298-2302, 2005
  25. Lee DY, Shim CS, Ahn Y : Comparison of percutaneous endoscopic lumbar discectomy and open lumbar microdiscectomy for recurrent disc herniation. *J Korean Neurosurg Soc* 46 : 515-521, 2009
  26. Xia XP, Chen HL : Prevalence of adjacent segment degeneration after spine surgery : a systematic review and meta-analysis. *Spine* 38 : 597-608, 2013
  27. Osman SG, Nibu K, Panjabi MM : Transforaminal and posterior decompressions of the lumbar spine. A comparative study of stability and intervertebral foramen area. *Spine* 22 : 1690-1695, 1997