

CASE REPORT

Successful treatment of mixed (mainly cancer) pain by tramadol preparations

Shinji Kawahito¹, Tomohiro Soga¹, Naoji Mita¹, Shiho Satomi¹, Hiroyuki Kinoshita¹, Tomoko Arase², Akira Kondo², Hitoshi Miki³, Kazumi Takaishi⁴ and Hiroshi Kitahata⁴

¹Department of Anesthesiology, Tokushima University Hospital, Tokushima, Japan, ²Division of Palliative Medicine, Kondo Hospital, Tokushima, Japan, ³Division of Palliative Medicine, Taoka Hospital, Tokushima, Japan, ⁴Department of Dental Anesthesiology, Tokushima University Hospital, Tokushima, Japan

Abstract : The patient, a 70-year-old Japanese woman diagnosed with parotid gland cancer, underwent wide excision and reconstruction (facial nerve ablation, nerve transposition). At 1 month after the surgery, she was brought to our hospital's pain medicine department because her postoperative pain and cancer-related pain were poorly controlled. She had already been prescribed a tramadol (37.5 mg)/acetaminophen (325 mg) combination tablet (5 tablets/day). However, in addition to the continuous pain in her face and lower limbs, she was troubled by a trigeminal neuralgia-like prominence ache. Because this pain could not be controlled by an increase to eight combination tablets per day, we switched her medication to a tramadol capsule. At 11 months post-surgery, we then switched her medication to an orally disintegrating tramadol tablet to improve medication adherence of the drug. From 14 months post-surgery, the patient also used a sustained-release tramadol preparation, and she was then able to sleep well. Her current regimen is an orally disintegrating sustained-release tablet combination (total 300 mg tramadol) per day, and she achieved sufficient pain relief. Because tramadol is not classified as a medical narcotic drug, it widely available and was shown here to be extremely useful for the treatment of our patient's mixed (mainly cancer) pain. *J. Med. Invest.* 64 : 311-312, August, 2017

Keywords : cancer pain, mixed pain, neuropathic pain, opioid, tramadol

INTRODUCTION

Tramadol is a weak opioid analgesic used clinically at 'step 2' of the World Health Organization (WHO) three-step cancer pain relief ladder. It is available in Japan for non-cancer-related chronic pain including neuropathic pain. Tramadol is a racemate, and its enantiomers and their active metabolites can act as a weak agonist for μ -opioid receptors and a weak reuptake inhibitor for noradrenaline and serotonin (1–4).

Various tramadol preparations have been developed, and they have become an effective therapeutic approach to chronic pain including cancer pain. In this case report, we describe the usefulness of some tramadol preparations for mixed (mainly cancer) pain.

CASE REPORT

The patient was a 70-year-old Japanese woman. She had a history of hypertension, diabetes mellitus, multiple sclerosis and lumbar spinal canal stenosis. Following the diagnosis of a parotid gland tumor (adenocarcinoma), the patient underwent wide excision and reconstruction (facial nerve ablation, nerve transposition) at another university hospital. At 1 month after this surgery, she was brought to our hospital's pain medicine department because her postoperative and cancer-related pain were poorly controlled. She was taking five tramadol (37.5 mg)/acetaminophen (325 mg)

combination tablets (Tramcet[®] Combination Tablets) per day, but in addition to the continuous pain in her face and lower limbs, she was troubled by a trigeminal neuralgia-like prominence ache that lasted for approx. 10 minutes several times a day.

We switched the patient's pain medication to a tramadol capsule (Tramal[®] Capsule) because although her pain medication had been increased to eight of the above-named combination tablet per day, her pain was not well-controlled. The initial dosage was a total of 300 mg/day, and we added an adjuvant agent, i.e., an anti-inflammatory analgesic : cerecoxib (Cerecox[®]).

At 11 months post-surgery, we switched the patient's pain medication to a daily tramadol orally disintegrating tablet (Tramal[®] OD Tablet) to improve medication adherence of the drug. At 14 months post-surgery, she was also given a tramadol sustained-release preparation (Onetram[®] Tablet) to use daily in addition to the Tramal[®] OD Tablet, and she was then able to sleep well at night. The combination of the orally disintegrating tablet and the sustained-release preparation provides a total of 400 mg tramadol per day, and she then achieved sufficient pain relief.

One month after the start of the new medication regimen, the patient underwent lumbar spinal surgery. Her lumbago and the lower extremity pain were then relieved, and the dose of tramadol was decreased to 300 mg/day. She was prescribed a prophylactic antiemetic (prochlorperazine maleate [Novamin[®]]) and a laxative (sennoside [Pursennid[®]]) together, and no side effects were observed.

DISCUSSION

Various opioid preparations are now authorized in Japan for the treatment of chronic pain. As we have described in this case report, various tramadol preparations can be very effective against mixed

Received for publication June 1, 2017 ; accepted June 28, 2017.

Address correspondence and reprint requests to Dr. Shinji Kawahito, Department of Anesthesiology, Tokushima University Hospital, 3-18-15, Kuramoto, Tokushima 770-8503, Japan and Fax : +81-88-633-7182.

pain, including pain due mainly to cancer. The WHO's three-step analgesic ladder – which was originally proposed for cancer pain relief – is now widely used for all types of pain, including chronic pain from musculoskeletal disease. Tramadol, an analgesic that has monoaminergic activity and weak opioid receptor affinity, has proved suitable for use at Step 2 of the WHO ladder (1–4). As a centrally acting analgesic structurally related to codeine and morphine, tramadol consists of two enantiomers, which contribute to the analgesic activity via different mechanisms (Figure). It has been shown that (+)-tramadol and the metabolite (+)-O-desmethyl-tramadol (M1) act against the μ -opioid receptor. The enantiomer (+)-tramadol inhibits serotonin reuptake, whereas (-)-tramadol inhibits norepinephrine reuptake, enhancing tramadol's inhibitory effect on pain transmission in the spinal cord.

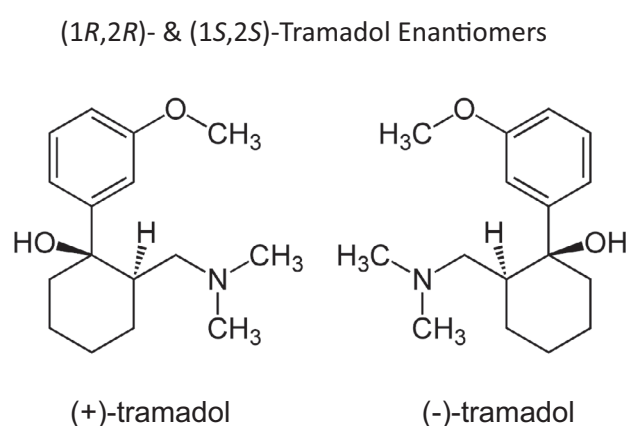


Figure : The structure of tramadol hydrochloride.

The complementary and synergistic actions of the two enantiomers improve the analgesic efficacy and tolerability profile of the racemate. Tramadol is metabolized mainly by O- and N-demethylation and by conjugation reactions forming glucuronides and sulfates. Tramadol and its metabolites are excreted mainly via the kidneys. The mean elimination half-life is approx. 6hr.

Several tramadol preparations were developed recently, and tramadol has become an effective therapeutic approach to chronic (including cancer-related) pain (4). In Japan, tramadol is available as a capsule, an orally disintegrating tablet, an injection, and a compounded agent with acetaminophen. An oral once-daily extended-release dosage form has also been reported to be effective for severe pain (5). The tramadol sustained-release preparation Onetram[®] is a tablet with a dual-bicarbonate nature, providing both an immediate effect and controlled release characteristics. With Onetram[®] we can obtain an effect that is equivalent to that of Tramal[®] (which is administered 4 \times /day) by a 1 \times /day administration.

Tramadol has a low incidence of adverse effects, particularly regarding respiratory depression, constipation and abuse potential, and it has never been a scheduled drug. The abuse of tramadol has remained very low despite new branded and generic formulations (6). The most common side effects of tramadol are somno-

lence, constipation, dizziness, nausea, and orthostatic hypotension, which occur more frequently with rapid dosage escalation (7). Tramadol can cause or exacerbate cognitive impairment and gait disturbances in elderly patients. It can also precipitate seizures in individuals with a history of seizures or in those receiving medications that reduce seizure threshold. Concurrent use of other serotonergic medications may increase the risk of serotonin syndrome, and combination therapy with these medications must be undertaken cautiously (8). We can control the side effects of tramadol such as nausea, constipation, sleepiness, and withdrawal signs. In our patient, no signs of dependence were observed over the entire course of treatment.

CONCLUSION

Tramadol offers an important alternative to other opioids, because the complementary and synergistic actions of the two enantiomers (μ -opioid and serotonin reuptake inhibitor of norepinephrine and serotonin) enhance its analgesic effects and improve its tolerability profile. Because tramadol is not a scheduled medical narcotic drug, it is widely available in outpatient pain medicine departments. Here, tramadol was extremely useful for our patient's mixed (mainly cancer) pain. We expect tramadol to provide a useful contribution to palliative medicine in the future.

We presented aspects of this paper at the 21st Congress of the Japanese Society for Palliative Medicine (2016, Kyoto, Japan).

CONFLICT OF INTEREST

None of the authors have any conflict of interest to declare.

REFERENCES

- Gibson TP : Pharmacokinetics, efficacy, and safety of analgesia with a focus on tramadol HCl. *Am J Med* 101 : 47S-53S, 1996
- Shipton EA : Tramadol-present and future. *Anaesth Intensive Care* 28 : 363-374, 2000
- Dworkin RH, O'Connor AB, Backonja M, Farrar JT, Finnerup NB, Jansen TS, Kalso EA, Loeser JD, Miaskowski C, Nurmikko TJ, Portenoy RK, Rice AS, Stacey BR, Treede RD, Turk DC, Wallace MS : Pharmacologic management of neuropathic pain : evidence-based recommendations. *Pain* 132 : 237-251, 2007
- Grond S, Sablotzki A : Clinical pharmacology of tramadol. *Clin Pharmacokinet* 43 : 879-923, 2004
- Mariconti P, Collini R : Tramadol SR in arthrosic and neuropathic pain. *Minerva Anesthesiol* 74 : 63-68, 2008
- Cicero TJ, Inciardi JA, Adams EH, Geller A, Senay EC, Woody GE, Muñoz A : Rates of abuse of tramadol remain unchanged with the introduction of new branded and generic products : results of an abuse monitoring system, 1994-2004. *Pharmacoepidemiol Drug Saf* 14 : 851-859, 2005
- Reig E : Tramadol in musculoskeletal pain – a survey. *Clin Rheumatol* 21 : S9-S12, 2002
- Boyer EW, Shannon M : The serotonin syndrome. *N Eng J Med* 352 : 1112-1120, 2005