

ORIGINAL

Risk factors for an additional port in single-incision laparoscopic cholecystectomy in patients with cholecystitis

Kenichiro Araki^{1,2}, Ken Shirabe¹, Akira Watanabe^{1,2}, Norio Kubo^{1,2}, Shigeru Sasaki², Hideki Suzuki², Takayuki Asao³, and Hiroyuki Kuwano²

¹Department of Hepatobiliary and Pancreatic Surgery, Gunma University Graduate School of Medicine, Gunma, Japan, ²Department of General Surgical Science, Gunma University Graduate School of Medicine, Gunma, Japan, ³Department of Oncology Clinical Development, Gunma University Graduate School of Medicine, Gunma, Japan

Abstract : Although single-incision laparoscopic cholecystectomy is now widely performed in patients with cholecystitis, some cases require an additional port to complete the procedure. In this study, we focused on risk factor of additional port in this surgery. We performed single-incision cholecystectomy in 75 patients with acute cholecystitis or after cholecystitis between 2010 and 2014 at Gunma University Hospital. Surgical indications followed the TG13 guidelines. Our standard procedure for single-incision cholecystectomy routinely uses two needlescopic devices. We used logistic regression analysis to identify the risk factors associated with use of an additional full-size port (5 or 10 mm). Surgical outcome was acceptable without biliary injury. Nine patients (12.0%) required an additional port, and one patient (1.3%) required conversion to open cholecystectomy because of severe adhesions around the cystic duct and common bile duct. In multivariate analysis, high C-reactive protein (CRP) values (>7.0 mg/dl) during cholecystitis attacks were significantly correlated with the need for an additional port ($P = 0.009$), with a sensitivity of 55.6%, specificity of 98.5%, and accuracy of 93.3%. This study indicated that the severe inflammation indicated by high CRP values during cholecystitis attacks predicts the need for an additional port. *J. Med. Invest.* 64 : 245-249, August, 2017

Keywords : Single-incision laparoscopic cholecystectomy, cholecystitis, additional port

INTRODUCTION

In 1985, Muhe performed the first laparoscopic cholecystectomy using a modified laparoscope(1), and laparoscopic cholecystectomy has since emerged as the gold-standard surgical treatment for cholecystitis and gallbladder attack. In 1997, Navarra reported a single-incision laparoscopic cholecystectomy(2). Since then, reports have shown that the procedure is neither less invasive nor more efficacious, but that it offers a good cosmetic outcome compared with conventional four-port laparoscopic cholecystectomy (3-9). Thus, we should clarify that the indication of this procedure is dependent on patient characteristics and the condition of the gallbladder.

When performing laparoscopic cholecystectomy in patients with cholecystitis, some cases require an additional port or conversion to open surgery because of severe inflammation or adhesion around the gallbladder. Laparoscopic cholecystectomy carries the potential risk of bile duct injury ; therefore, surgeons should proactively manage cases to avoid this serious complication. As few previous reports exist(10), the aim of the present study was to evaluate the risk factors associated with the need for an additional port in single-incision cholecystectomy in patients with cholecystitis. In this study, we focused on additional port in single-incision laparoscopic cholecystectomy, and evaluated risk factors of additional port in this procedure.

PATIENTS AND METHODS

Patient series and ethical statement

Seventy-five patients with acute cholecystitis or after acute cholecystitis underwent single-incision cholecystectomy at the Department of General Surgical Science, Gunma University Hospital, Gunma, Japan, between September 2010 and September 2014. Information on gender, age, physical data, laboratory data, surgical procedures, postoperative complications, outpatient course, and histological factors was extracted from medical records. Each laboratory data was extracted at the highest value in the periods of cholecystitis. Acute cholecystitis was diagnosed according to the updated Tokyo Guidelines for the management of acute cholangitis and cholecystitis (TG13), and we graded the severity of cholecystitis (grade I to III) according to these guidelines(11, 12). All patients underwent either preoperative magnetic resonance cholangiopancreatography (MRCP) or drip infusion cholangiographic-computed tomography (DIC-CT) for investigation of the cystic duct and common bile duct. Patients with signs of bile duct stones underwent preoperative endoscopic retrograde cholangiopancreatography (ERCP). Exclusion criteria of this single-incision cholecystectomy procedure is that the patient had severe cardiovascular disease or pulmonary disease as the American Society of Anesthesiologists (ASA) Physical Status classification : grade III or more. We also excluded the indication of poly-open surgeries' history expected severe adhesion.

The protocol for this research project was approved by the institutional review board of Gunma University Hospital (approval No. 699), within which the work was undertaken, and it conforms to the provisions of the Declaration of Helsinki established in 1995 (as revised in Brazil in 2013). All patients signed informed consent forms according to our institutional guidelines.

Received for publication March 14, 2017 ; accepted May 22, 2017.

Address correspondence and reprint requests to Kenichiro Araki, M.D., Ph.D. Department of Hepatobiliary and Pancreatic Surgery, Gunma University Graduate School of Medicine, 3-39-22 Showa-machi, Maebashi, Gunma 371-8511, Japan and Fax : +81-27-220-8802.

Surgical procedure

Surgical indication was determined according to the TG13 guidelines, depending on the severity grade(13). The operation started with a skin incision at the umbilicus, which was 1.5 cm long for patients with a body mass index (BMI) of less than 25 kg/m², and 2.0 cm long for those with a higher BMI. Subcutaneous dissection was not performed in any patient. Subsequently, an Alexis wound retractor (XS size ; Applied Medical, Rancho Santa Margarita, California, USA) was installed in the umbilical wound and used to dilate the wound, creating a single free ovoid hole approximately 2.5 × 2.0 cm in diameter. The tips of a glove's thumb, middle, and small fingers were cut, and four 5-mm Yelloports (Amco Inc., Japan) were attached into the echo probe cover and confirmed to be airtight. From April 2011 on, we used the EZ access system (Hakko Co., Ltd., Japan) for the single-access port. We routinely used a mini loop retractor II with a 2.2-mm diameter shaft (Covidien Co., Ltd., Minnesota, USA), and a needle device to grasp the fornix and neck of gallbladder, which we had previously developed(14). We also used an Endo Relief needle forceps device with a 2.4-mm diameter shaft (HOPE DENSHI Co., Ltd., Japan), depending on the severity of gallbladder inflammation. Our standard procedure was single-access via the umbilicus with one or two needle devices via the right intra- or sub-coastal regions (single-incision with one or two punctures). After cholecystectomy, 2-0 bladed absorbable thread was used for closure of the fascia to prevent umbilical hernia.

Statistical analysis

Logistic regression analysis was used to identify risk factors that were independently associated with conversion to an additional port during surgery. We performed a receiver operating characteristic (ROC) curve analysis for correlation of the C-reactive protein (CRP) values and an additional port. We obtained the area under the curve (AUC) to distinguish continuous variables. The Mann-Whitney *U* test, Pearson's χ^2 test, and Fisher's exact test were used to compare continuous and categorical variables respectively, with two-sided *P* < 0.05 indicating significance. All statistical analyses were performed using SPSS software version 21.0 (IBM SPSS Inc., Chicago, USA).

RESULTS

Preoperative characteristics and clinical findings

Patient characteristics and clinical findings are detailed in Table 1. Preoperatively, four patients (5.3%) had common bile duct stones, and acute pancreatitis occurred in four patients (5.3%). Three patients (3.0%) had undergone previous surgery of the upper abdomen. Computed tomography findings in acute patients with cholecystitis revealed enhancement of the surrounding fat in 33 patients (44.0%), and fluid collection around the gallbladder in four patients (5.3%). Histological findings of the gallbladder revealed fibrosis of the muscularis and/or subserosa in 38 cases (53.3%), and gangrenous cholecystitis in one case (1.3%).

Operative outcome and postoperative course

Surgical outcome and postoperative course are shown in Table 2. The median operative time and blood loss were 126.8 ± 44.4 min and 19.5 ± 38.4 ml, respectively. The median length of hospital stay after surgery was 3.5 ± 2.8 days. No intraoperative massive bleeding or intraoperative transfusions occurred. Nine patients required an additional port (12.0%), and one patient required conversion to open cholecystectomy because of strong adhesions around the cystic duct and common bile duct.

Major complications, defined as grade II or higher according to

Table 1. Patient characteristics and clinical findings (N = 75)

Age (years)	57 (21-87)
Sex ratio (male : female)	37 : 38
BMI (kg/m²)	23.8 (16.5-36.0)
Past surgery of upper abdomen	3 (4.0%)
Preoperative complication	
Diabetes mellitus	2 (2.7%)
Common bile duct stone	4 (5.3%)
Acute pancreatitis	4 (5.3%)
Laboratory data on attack of cholecystitis	
WBC (per/l)	7971 (2700-18900)
CRP (mg/dl)	2.9 (0.01-25.9)
T-Bil (mg/dl)	1.3 (0.2-6.8)
AST (IU/l)	125 (15-1003)
ALT (IU/l)	121 (8-874)
CT findings on attack of cholecystitis	
Enhancement of surrounding fat tissue	33 (44.0%)
Fluid collection around GB*	4 (5.3%)
Histopathological findings	
Fibrosis of muscularis or/and subserosa	38 (50.7%)
Gangrenous cholecystitis	1 (1.3%)

*GB, Gallbladder

Table 2. Operative outcome and postoperative course

Operative time (min)	126.8 ± 44.4
Bleeding amount (ml)	19.5 ± 38.4
Hospitalization after surgery (days)	3.5 ± 2.8
Perioperative events	
Gallbladder perforation	14 (18.7%)
Additional port	9 (12.0%)
Conversion to open surgery	1 (1.3%)
Postoperative complications	
Bile leak	1 (1.3%)
Intra-abdominal bleeding	1 (1.3%)
Common bile duct stone dropped from GB*	1 (1.3%)
Umbilical hernia	0 (0%)
SSI* (Including wound infection)	0 (0%)

*SSI, Surgical site infection ; *GB, Gallbladder

Clavien-Dindo classification, occurred in three patients (4.0%) after surgery. Bile leakage from the cystic duct occurred in one patient (1.3%), and it was treated with an endoscopic retrograde bile duct stent. One patient had intra-abdominal hemorrhage from the additional port site in the upper abdomen, which was successfully managed with conservative therapy. Common bile duct stones dropped from the gallbladder were found in one patient (1.3%), and treatment with endoscopic stone retrieval was successful. No patients experienced biliary injury, umbilical hernia, surgical site infection, or mortality.

Analysis for risk factors for an additional port

We evaluated the risk factors for an additional port in this series. Logistic regression analysis for the risk of an additional port requirement is shown in Table 3. In univariate analysis, operative

Table 3. Logistic regression analysis for the risk of additional port

Risk Factors	Variables	Univariate Analysis			Multivariate Analysis		
		P value	Odds ratio	95% CI*	P value	Odds ratio	95% CI*
Age (years)	≤65 vs. > 65	0.134	2.824	0.727-10.973			
Sex	male vs. female	0.053	4.966	0.978-25.213	0.299	3.307	0.346-31.632
BMI (kg/m ²)	≤30 vs. > 30	0.803	1.333	0.139-12.758			
Past surgery of upper abdomen	negative vs. positive	0.326	1.149	0.871-1.517			
Preoperative complication							
Diabetes mellitus	negative vs. positive	0.999	0.116	-			
Common bile duct stone	negative vs. positive	0.999	0.116	-			
Acute pancreatitis	negative vs. positive	0.492	1.097	0.843-1.427			
Operation time (min)	≤125 vs. > 125	0.003	1.338	1.106-1.619	0.500	1.1	0.834-1.449
Bleeding amount (ml)	≤15 vs. > 15	< 0.001	1.416	1.187-1.690	0.002	1.559	1.185-2.05
Laboratory data on attack of cholecystitis							
WBC* (/ μ l)	≤10000 vs. > 10000	0.052	3.923	0.986-15.611	0.867	0.813	0.072-9.171
CRP (mg/dl)	≤7.0 vs. > 7.0	< 0.001	63.000	6.116-648.917	0.006	109.281	3.782-3157.262
T-Bil (mg/dl)	≤3.0 vs. > 3.0	0.442	2.542	0.235-27.467			
AST (IU/l)	≤100 vs. > 100	0.319	1.090	0.920-1.290			
ALT (IU/l)	≤100 vs. > 100	0.596	1.046	0.886-1.235			
CT findings on attack of cholecystitis							
Enhancement of surrounding fat tissue	negative vs. positive	0.81	1.179	0.309-4.492			
Fluid collection around GB*	negative vs. positive	0.102	5.857	0.705-48.676			
Histopathological findings							
Fibrosis of muscularis or/and subserosa	negative vs. positive	0.821	0.857	0.226-3.248			
Gangrenous cholecystitis	negative vs. positive	0.989	-	-			

*CI, confidence interval ; *WBC, white blood cell ; *GB, Gallbladder

time (<125 min), bleeding amount (>15 ml), and CRP values (>7.0 mg/dl) during attacks of cholecystitis were significantly correlated with the requirement of an additional port. In multivariate analysis, bleeding amount (>15 ml) and CRP values (>7.0 mg/dl) were significantly correlated with an additional port. CT findings in attacks of cholecystitis and histological findings like gangrenous cholecystitis were not significantly correlated. Using the Fisher's test, a significant correlation between an additional port and CRP values was found (Table 4). Indeed, elevated CRP values correlated with an additional port with a sensitivity of 55.6%, specificity of 98.5%, and accuracy of 93.3%. We then used ROC curve analysis to select for the optimized cutoffs by correlating the values of high CRP, WBC counts, and the need for an additional port (Figure 1).

Table 4. Relationship between high CRP values and additional port

	Port added	Single incision	
High CRP (> 7.0 mg/dl)	5	1	<i>P</i> < 0.001 (Fisher's exact test)
Low CRP (≤7.0 mg/dl)	4	65	

Only one patient with a high CRP value (23.1 mg/dl) completed the procedure with a single-incision method. This patient had severe inflammation in the body and tail of the gallbladder only, so the cystic duct could be divided and dissected without an additional port. Four patients without high CRP values needed an additional port and the reasons included severe inflammation of the cystic

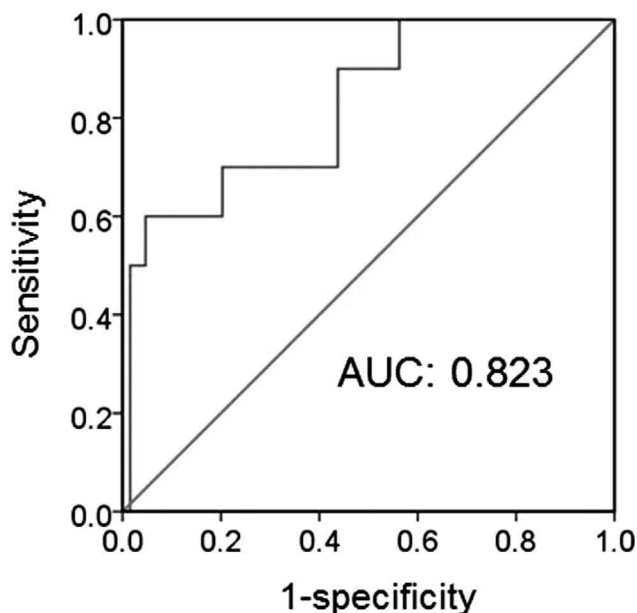


Figure 1. Receiver operating characteristic (ROC) curve for additional port by high CRP values (>7.0 mg/dl) during a cholecystitis attack. A value of CRP = 7.0 mg/dl predicted the need for an additional port with a sensitivity of 0.556 and a specificity of 0.985. Area under the ROC curve (AUC) was 0.823.

duct and neck of gallbladder (n = 2), requirement for suture closure of a short cystic duct stump (n = 1), and intra-abdominal adhesion due to four previous abdominal surgeries (n = 1).

DISCUSSION

This study showed that although single-incision laparoscopic cholecystectomy is feasible and safe with acceptable operative outcomes for patients with cholecystitis, 19% of our patients required an additional full-size port to complete the procedure. High CRP values, reflective of severe inflammation, are an independent risk factor for the requirement of an additional port.

Since single-incision laparoscopic cholecystectomy was first reported(2), it has been shown to be a feasible and efficacious procedure that is comparable to conventional multi-port laparoscopic cholecystectomy(3-6). To date, a few meta-analyses, including several randomized trials of highly variable quality, have compared single-incision cholecystectomy with conventional laparoscopic cholecystectomy(15-17). While several reports described no advantage in terms of patient satisfaction after single-incision procedures, they did describe an advantage in terms of cosmetic outcomes. However, postoperative morbidity tended to be higher after single-incision cholecystectomy, whereas postoperative pain and hospital stay were similar between single-access and conventional laparoscopic procedures(17).

Although expected complications include severe inflammation of the gallbladder, Mirizzi syndrome, and confluent stones, few reports have analyzed the difficulties and risk factors associated with an additional port in single-incision laparoscopic cholecystectomy(10). The results of the present study suggest that single-incision cholecystectomy might be safely performed for patients with cholecystitis with acceptable operative outcomes. This study also clarified that high CRP values (>7.0 mg/dl) are indeed a significant risk factor for conversion to an additional port. When a single-access procedure is elected for patients with cholecystitis with high CRP values, the likelihood of the need for an additional port should be considered for the patient's safety. If the patients with high CRP value are elected single-incision cholecystectomy, these cases should be performed by experienced surgeon. The results of this study may help senior surgeons to decide whether young surgeons or residents perform this surgery.

Another concern associated with single-incision cholecystectomy is the appropriate selection of either a pure incision port method or a single-access method using needlescopic devices. In contrast to the single-access technique, the surgical approach of pure single-incision cholecystectomy has been criticized for violating important surgical principles, such as triangulation (co-axial setup) and tissue tension when Calot's triangle is dissected. These results potentially make it more difficult to identify the cystic artery and cystic duct, and to achieve a 'critical view' in order to avoid biliary duct injury(18). In our hospital, single-incision cholecystectomy with one or two needlescopic devices is now the standard procedure for patients with cholecystitis, except in cases of severe systemic preoperative complications or large scars of the upper abdomen. This single-incision procedure is feasible with similar outcomes compared with the conventional multiport method. Moreover, since laparoscopic cholecystectomy is a good training procedure for residents, it is easier to adapt this surgery for young candidates. Therefore, we use needlescopic devices in all cases and no longer perform any operations using the pure single-incision method. A mere 2 to 3-mm incision is necessary using needlescopic devices, and the resulting scars are almost invisible. Only one randomized trial has compared needlescopic cholecystectomy with pure single-incision cholecystectomy, reporting a positive effect of the single-incision technique in terms of pain and cosmetic

outcomes(19). However, that trial was not blinded.

The limitations of this study include the small number of patients and the use of clinical data from a single center. Further analysis with a larger population and multiple centers should be performed in the future. Additionally, our hospital has more than 15 years of needlescopic laparoscopic cholecystectomy (two ports and two puncture method) experience. Naturally, surgeons should have adequate experience with single-incision surgery, needlescopic surgery, and conventional laparoscopic cholecystectomy before attempting this surgery.

In conclusion, this study suggests that single-incision laparoscopic cholecystectomy is adoptable for patients with cholecystitis, but that the severe inflammation as indicated by elevated CRP values during cholecystitis attacks may require consideration of conversion to an additional port.

ACKNOWLEDGEMENT

The authors have no conflict of interest.

REFERENCES LIST

1. Reynolds W, Jr : The first laparoscopic cholecystectomy. *JLS*. 5 : 89-94, 2001
2. Navarra G, Pozza E, Occhionorelli S, Carcoforo P, Donini I : One-wound laparoscopic cholecystectomy. *Br J Surg* 84 : 695, 1997
3. Romanelli JR, Roshek TB 3rd, Lynn DC, Earle DB : Single-port laparoscopic cholecystectomy : initial experience. *Surg Endosc* 24 : 1374-1379, 2010
4. Yu WB, Zhang GY, Li F, Yang QY, Hu SY : Transumbilical single port laparoscopic cholecystectomy with a simple technique : initial experience of 33 cases. *Minim Invasive Ther Allied Technol* 19 : 340-344, 2010
5. Rivas H, Varela E, Scott D : Single-incision laparoscopic cholecystectomy : initial evaluation of a large series of patients. *Surg Endosc* 24 : 1403-1412, 2010
6. Elsey JK, Feliciano DV : Initial experience with single-incision laparoscopic cholecystectomy. *J Am Coll Surg* 210 : 624-626, 2010
7. Phillips MS, Marks JM, Roberts K, Tacchino R, Onders R, DeNoto G, Rivas H, Islam A, Soper N, Gecelter G, Rubach E, Paraskeva P, Shah S : Intermediate results of a prospective randomized controlled trial of traditional four-port laparoscopic cholecystectomy versus single-incision laparoscopic cholecystectomy. *Surg Endosc* 26 : 1296-1303 2012
8. Ma J, Cassera MA, Spaun GO, Hammill CW, Hansen PD, Aliabadi-Wahle S : Randomized controlled trial comparing single-port laparoscopic cholecystectomy and four-port laparoscopic cholecystectomy. *Ann Surg* 254 : 22-27, 2011
9. Sasaki A, Ogawa M, Tono C, Obara S, Hosoi N, Wakabayashi G : Single-port versus multiport laparoscopic cholecystectomy : a prospective randomized clinical trial. *Surg Laparosc Endosc Percutan Tech* 22 : 396-399, 2012
10. Chuang SH, Yang WJ, Chang CM, Lin CS, Yeh MC : Is routine single-incision laparoscopic cholecystectomy feasible? A retrospective observational study. *Am J Surg* 210 : 315-321, 2015
11. Kimura Y, Takada T, Strasberg SM, Pitt HA, Gouma DJ, Garden OJ, Büchler MW, Windsor JA, Mayumi T, Yoshida M, Miura F, Higuchi R, Gabata T, Hata J, Gomi H, Derveniz C, Lau WY, Belli G, Kim MH, Hilvano SC, Yamashita Y : TG13 current terminology, etiology, and epidemiology of acute cholangitis and cholecystitis. *J Hepatobiliary Pancreat Sci* 20 : 8-23,

2013

12. Yokoe M, Takada T, Strasberg SM, Solomkin JS, Mayumi T, Gomi H, Pitt HA, Garden OJ, Kiriya S, Hata J, Gabata T, Yoshida M, Miura F, Okamoto K, Tsuyuguchi T, Itoi T, Yamashita Y, Dervenis C, Chan AC, Lau WY, Supe AN, Belli G, Hilvano SC, Liau KH, Kim MH, Kim SW, Ker CG ; Tokyo Guidelines Revision Committee : TG13 diagnostic criteria and severity grading of acute cholecystitis (with videos). *J Hepatobiliary Pancreat Sci* 20 : 35-46, 2013
13. Yamashita Y, Takada T, Strasberg SM, Pitt HA, Gouma DJ, Garden OJ, Büchler MW, Gomi H, Dervenis C, Windsor JA, Kim SW, de Santibanes E, Padbury R, Chen XP, Chan AC, Fan ST, Jagannath P, Mayumi T, Yoshida M, Miura F, Tsuyuguchi T, Itoi T, Supe AN : Tokyo Guideline Revision Committee : TG13 surgical management of acute cholecystitis. *J Hepatobiliary Pancreat Sci* 20 : 89-96, 2013
14. Asao T, Yanagita Y, Nakamura J, Hosouchi Y, Takenoshita S, Nagamachi Y : Usefulness of a visceral mini-retractor accessible without trocar port during laparoscopic surgery. *Surg Endosc* 13 : 91, 1999
15. Markar SR, Karthikesalingam A, Thrumurthy S, Muirhead L, Kinross J, Paraskeva P : Single-incision laparoscopic surgery (SILS) vs. conventional multiport cholecystectomy : systematic review and meta-analysis. *Surg Endosc* 26 : 1205-1213, 2012
16. Pisanu A, Reccia I, Porceddu G, Uccheddu A : Meta-analysis of prospective randomized studies comparing single-incision laparoscopic cholecystectomy (SILC) and conventional multiport laparoscopic cholecystectomy (CMLC) : *J Gastrointest Surg* 16 : 1790-1801, 2012
17. Garg P, Thakur JD, Garg M, Menon GR : Single-incision laparoscopic cholecystectomy vs. conventional laparoscopic cholecystectomy : a meta-analysis of randomized controlled trials. *J Gastrointest Surg* 16 : 1618-1628, 2012
18. Strasberg SM, Hertl M, Soper NJ : An analysis of the problem of biliary injury during laparoscopic cholecystectomy. *J Am Coll Surg* 180 : 101-125, 1995
19. Lee PC, Lo C, Lai PS, Chang JJ, Huang SJ, Lin MT, Lee PH : Randomized clinical trial of single-incision laparoscopic cholecystectomy versus minilaparoscopic cholecystectomy. *Br J Surg* 97 : 1007-1012, 2010