

ORIGINAL

The Posterior Condylar Cartilage Affects Rotational Alignment of the Femoral Component in Varus Knee Osteoarthritis

Daisuke Hamada¹, Keizo Wada¹, Hiroshi Mikami², Shunichi Toki², Tomohiro Goto¹, Takahiko Tsutsui¹, Tomoya Takasago¹, Akihiro Nagamachi¹, and Koichi Sairyo¹

¹Department of Orthopedics, Institute of Biomedical Sciences, University of Tokushima Graduate School, Tokushima, Japan, ²Department of Orthopedic Surgery, Yoshinogawa Medical Center, Tokushima, Japan

Abstract : Rotational alignment of the femoral component in total knee arthroplasty (TKA) is important for patellar tracking and ligament balance. Preoperative planning based on radiography might have a potential risk for over-rotation because these X-ray based measurements can not detect asymmetric cartilage wear on posterior condyle. The purpose of this study is to evaluate the effect of the posterior condylar cartilage of varus osteoarthritic knee on rotational alignment of the femoral component in TKA. We established two different condylar twist angles (CTA) from intraoperative multiplanar reconstruction (MPR) images and intraoperative information of navigation system. The CTA measured by a navigation system that includes the cartilage ($4.8 \pm 2.0^\circ$) was smaller than those measured by MPR images, which does not include the cartilage ($6.6 \pm 2.1^\circ$) ($p < 0.05$). The difference between these two angles that corresponds to the remaining posterior condylar cartilage was $1.7 \pm 1.2^\circ$. This result demonstrated that the posterior condylar cartilage might lead to over-rotational of the femoral component in varus osteoarthritic knee. Therefore, when determining rotational alignment of the femoral component, surgeons should consider the effect of the remaining posterior condylar cartilage to avoid the over-rotation of the femoral component, especially in severe varus knees. *J. Med. Invest.* 64 : 24-29, February, 2016

Keywords : Total knee arthroplasty, posterior condylar cartilage, condylar twist angle, navigation system, femoral rotation

INTRODUCTION

Rotational alignment of the femoral component is important for patellofemoral kinematics and knee stability during flexion (1). Rotational malalignment causes patellofemoral complications and poor ligament balancing which, in turn, result in failures in total knee arthroplasty (TKA) (2). A number of anatomical landmarks have been proposed to achieve correct rotational alignment, such as the posterior condylar axis (PCA), surgical transepicondylar axis, clinical transepicondylar axis (CEA), and anteroposterior trochlear axis (i.e., Whiteside's anteroposterior axis) (3, 4). The transepicondylar axis has been demonstrated, in theory, to be a reliable rotational reference line for properly placing the femoral component (5-7), but identifying it intraoperatively is difficult in some cases because of the low-profile geometry of and/or soft tissues covering the epicondyles (8, 9). Therefore, surgeons typically estimate the transepicondylar axis from the PCA by using the twist angle determined on preoperative X-rays or computed tomography (CT) scans and set the cutting guide based on these measurements. Although the PCA is the most obvious landmark during surgery (10), radiography and CT cannot detect the posterior condylar cartilage. In most osteoarthritic knees, the cartilage thickness of the posterior condyle differs between the medial and lateral condyles because of asymmetric cartilage wear (11) (Fig. 1). Recently, a few studies have reported the effect of residual cartilage on rotational alignment of the femoral component (12-14). In particular, they demonstrated that the twist angle measured on X-rays

or CT scans, which do not include the cartilage, would be overestimated compared with the true twist angle that does include the cartilage in the osteoarthritic knee.

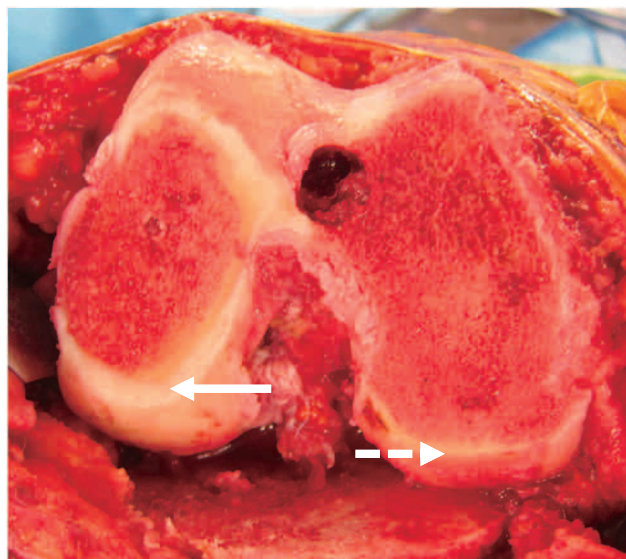


Fig. 1. Axial cross section of the distal femur. The cartilage on the posterolateral condyle is preserved (solid arrow). The subchondral bone is exposed as a result of cartilage wear on the posteromedial condyle (dashed arrow).

Received for publication July 19, 2016 ; accepted August 2, 2016.

Address correspondence and reprint requests to Daisuke Hamada M.D., Ph.D., 3-18-15 Kuramoto, Tokushima 770-8503, Japan and Fax : +81-88-633-1780.

The purpose of this study was to evaluate the effect of the posterior condylar cartilage on rotational alignment of the femoral component in a larger population of arthritic patients. We evaluated the effect using a newly developed method involving a navigation system and intraoperative fluoroscopy-based multiplanar reconstruction (MPR) images obtained using a motorized mobile C-arm. We also investigated whether the effect of the posterior condylar cartilage differs between male and female or the magnitude of varus deformity.

MATERIALS AND METHODS

Patients

A total of 98 OA knees in 86 consecutive patients scheduled for primary TKA from January 2007 to August 2008 at Oe-kyodo hospital were assessed in this study. Patients with a history of osteotomy of the affected knee, valgus deformity or rheumatoid arthritis were excluded. Subjects were 67 women and 19 men with a mean age of 74.6 years (range, 60-88 years). Subject characteristics are

summarized in Table 1. All cases were treated with standard cruciate-retaining TKA or posterior-stabilized TKA [Scorpio NRG (Stryker, Kalamazoo, MI), NexGen (Zimmer, Warsaw, IN)] using the navigation system. The relevant institutional review boards reviewed and approved the study protocol, and each patient provided informed consent to participate.

Measurement method using MPR images

The Arcadis Orbic 3D (Siemens Medical Solutions, Erlangen, Germany), a motorized mobile C-arm which provides fluoroscopic images during a 190° orbital rotation, was used to acquire MPR images of the distal femur. Before taking fluoroscopic images, suture anchors (STATAK, Zimmer) were inserted into the most prominent points of the medial and lateral epicondyles by a senior surgeon. Then, 100 fluoroscopic images were acquired at equidistant angles. The 3D dataset, a cube covering a volume of approximately 12×12×12 cm, was generated by scanning and displayed on the monitor as MPR slices in coronal, sagittal, and axial views (Fig. 2A). The acquired images were used to make a cross section perpendicular to the mechanical axis of the femur in the coronal

Table 1 Subject characteristics

	Total	Male	Female
Number of patients	86 patients 98 kees	19 patients, 23 knees	67 patients, 75 knees
Age, years (range)	74.6±5.5 (60-93)	74.9±6.6 (63-93)	74.5±5.2 (60-88)
FTA, degree (range)	189.6±6.9 (178-211)	189.3±6.2 (178-203)	189.8±7.1 (178-211)

Data are expressed as means±SD, FTA : femorotibial angle

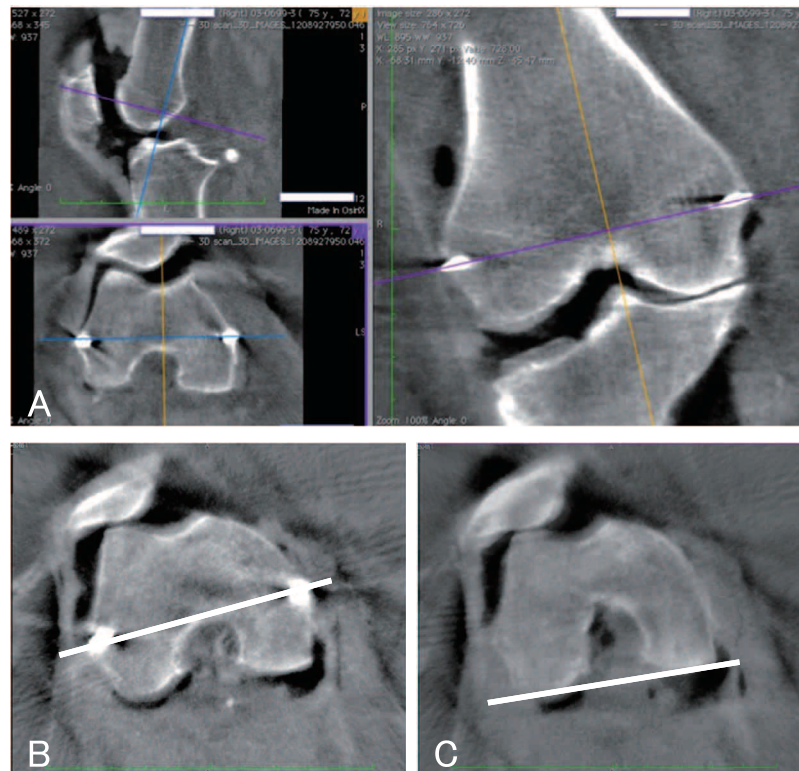


Fig. 2. Multi-planar reconstruction (MPR) images of the distal femur (A) showing the sagittal (upper right), axial (lower right), and coronal (left) slices obtained with the Arcadis Orbic 3D. The line across the STATAKs represents the clinical epicondylar axis (CEA) (B). The line tangent to the posterior condyle represents the posterior condylar axis (PCA) on the slice including the most posterior point of the medial and lateral posterior condyles (C). This PCA does not include the posterior condylar cartilage. Note that the MPR condylar twist angle (CTA) calculated by these lines does not include the cartilage.

plane and perpendicular to the tangent line of the distal femur in the sagittal plane. The valgus angle to the anatomical femoral axis was calculated on preoperative long-standing X-rays. On simulated cross sections of the distal femur, a line connecting the STATAKs was drawn to represent the CEA, and a line representing the PCA was drawn on the axial images by connecting the most posterior points of the medial and lateral posterior condyles. We then calculated the condylar twist angles (CTA: the angle between the CEA, created by connecting the STATAKs inserted into the prominences of the medial and the lateral condyles, and the PCA) using an angular measuring tool in an open-source DICOM viewer OsiriX (Pixmeo SARL, Geneva, Switzerland) (Fig. 2B, C). This CTA, which excluded the posterior condylar cartilage, was termed “MPR-CTA”. These measurements were performed three times on three different days and then took the average as a true value.

Measurement method using the navigation system

The navigation system used for the measurements was the Stryker Image Enhanced Knee Navigation Ver. 2.0 (Stryker). Before bone resection, infrared intraoperative devices that can transmit continuous anatomical data to the computer were rigidly attached through bicortical bone screws to the distal femoral shaft and proximal tibial shaft. The CEA was recorded by the navigation system by selecting the top of the suture anchors with the instrumented

pointer. It should be noted that the CEA did not differ between the measurements obtained from the MPR images and those obtained from the navigation system. Other landmarks such as the hip center, knee center, anteroposterior axis, and condylar surfaces were also registered in this system. A senior surgeon performed these processes in each case.

A distal femoral cut was performed using the surface-mapping guides of the image-free navigation system. Tracking devices were fixed to a universal positioning block. Bone resection was performed perpendicular to the mechanical axis in the coronal plane (Fig. 3A). Then, an anteroposterior measurement tool with infrared intraoperative devices was placed on the distal femoral cut surface to calculate the difference between the input CEA and PCA (Fig. 3B, C). This CTA, which included the posterior condylar cartilage, was termed “Navi-CTA”. Thus, the angle between the MPR-CTA and the Navi-CTA corresponds to the angle resulting from the cartilage remnant (Fig. 3A).

Statistical analysis

All measurement values are reported as the mean \pm standard deviation. The paired *t*-test was used to compare the MPR-CTA and Navi-CTA. The unpaired *t*-test was used to compare the MPR-CTA-Navi-CTA in male and female. Cases were divided into mild or severe varus deformity using a median FTA of 189° and compared the

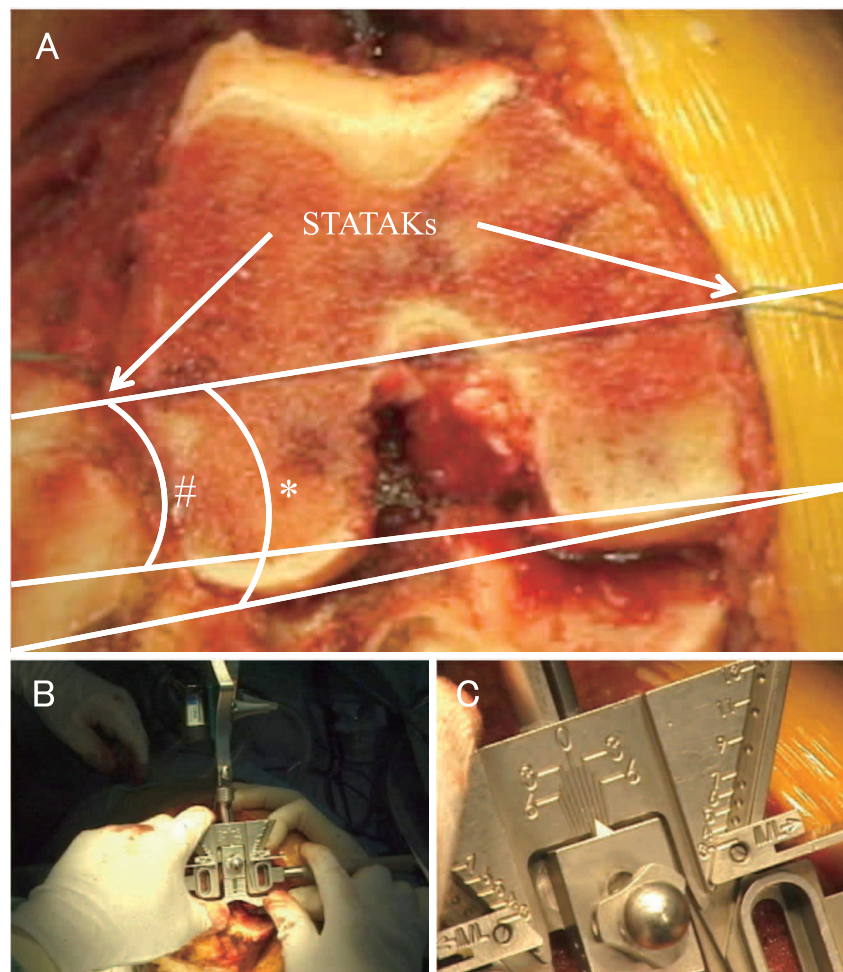


Fig. 3. Two STATAKs were temporarily inserted into the medial and lateral epicondylar prominences (A). The tops of the STATAKs were recognized in the navigation system to establish the CEA. An anteroposterior measurement tool with an instrumented tracker was used to calculate the Navi-CTA (*) that corresponds to the difference between the input CEA and PCA including the posterior condylar cartilage (B and C). The MPR-CTA does not include the posterior condylar cartilage (#).

MPR-CTA-Navi-CTA using unpaired *t*-test. Analysis was performed using GraphPad Prism 6 (GraphPad Software, San Diego, CA). A *P* value of 0.05 or less was considered significant.

To evaluate the reproducibility of our measurement method, intra- and inter-rater correlation coefficients (ICC) were accessed. The MPR-CTA measurement repeated three times in first 25 cases by two independent observers who were blinded to the measurements of each other. Then The ICC (1, 1), as an intra-rater ICC, and ICC (2, 1), as an inter-rater ICC, were calculated using IBM SPSS statistical software v.21.0 for Mac OS (IBM Japan, Tokyo, Japan).

RESULTS

In regard to intra-rater reliability with MPR-CTA, the ICC was 0.98 for the first observer and 0.95 for the second observer respectively. On the other hand, inter-rater reliability was also excellent (ICC : 0.845). These results indicating that our measurement methods demonstrated almost perfect reliability according to the thresholds suggested by Landis *et al.* (15)

The distributions of the MPR-CTA, Navi-CTA, and MPR-CTA-Navi-CTA are shown in Fig. 4. The CTA measured from the MPR images (MPR-CTA) was $6.6 \pm 2.1^\circ$, while the CTA calculated by the navigation system (Navi-CTA) was $4.9 \pm 2.0^\circ$. The difference between the two is $1.7 \pm 1.2^\circ$, which corresponds to the effect of the remaining cartilage of the posterior condyle. This result suggested that the asymmetrical cartilage wear in varus OA knees might affect the rotational alignment of the femoral component in measured

resection technique.

In addition, the MPR-CTA-Navi-CTA did not differ between male and female (Fig. 5A). Note that the femorotibial angle (FTA) was not statistically different between male and female (Fig. 5B). When we divided the cases into mild varus deformity group (FTA < 189) and severe varus deformity group (FTA $\geq 189^\circ$), the MPR-CTA-Navi-CTA is significantly larger in severe varus group compared to mild varus deformity ($p < 0.05$) (Fig. 5C). This result demonstrated that the effect of posterior condylar cartilage become larger in severe varus knees.

DISCUSSION

Intraoperative identification of the medial and lateral epicondyles is difficult to achieve in a reproducible manner (8, 16, 17) Furthermore, the anatomical variability between patients especially in their degree of arthritic change may impair the correct measurements (18). It is difficult to synchronize the CEA seen in the radiograph with that seen intraoperatively. The advantage of this study is that the CEA in the navigation system can be completely reproduced in the MPR images by using STATAKs. For this reason, the discrepancy between MPR-CTA and Navi-CTA can be considered as the difference of the two different PCAs resulting from the remaining cartilage of the posterior condyle. The Navi-CTA in our study might not completely same as the true CTA because STATAKs might not inserted into the prominences correctly in some cases, however, the Navi-CTA in this study was very close to previously published CTAs (7, 19, 20), indicating the validity of our measurement method.

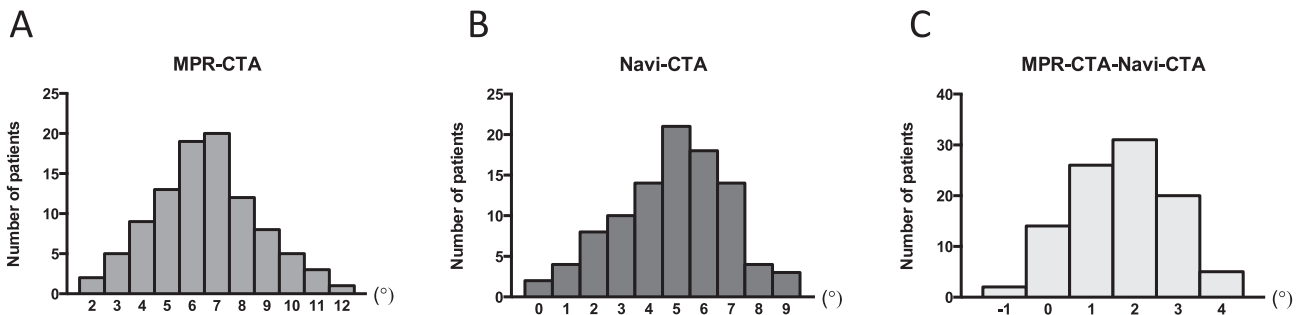


Fig. 4. Distribution of MPR-CTA (A), Navi-CTA (B), and MPR-CTA-Navi-CTA (C)

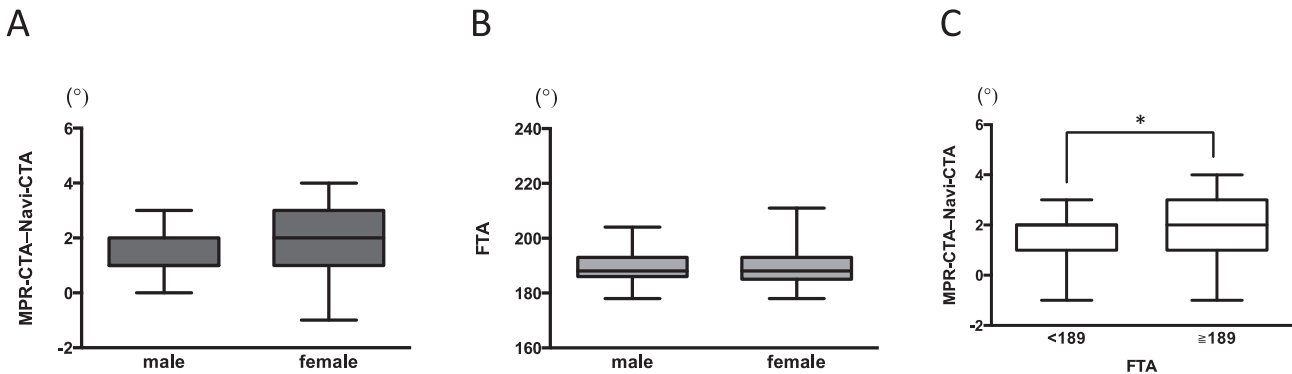


Fig. 5. Comparison of MPR-CTA-Navi-CTA between male and female (A), limb alignment between male and female (B), and MPR-CTA-Navi-CTA between patients with mild varus deformity (FTA < 189) and severe varus deformity (FTA ≥ 189) **p* < 0.05.

In most varus arthritic knees, the articular cartilage of the medial posterior condyle is usually worn away and sclerotic subchondral bone is exposed. Conversely, in the lateral posterior condyle, full-thickness or slightly degenerated cartilage tends to be preserved. Because CT or radiography cannot detect this preserved cartilage, the PCA measured by these modalities tends to show internal rotation compared with that of determined intraoperatively, meaning that the CTA measured by CT or radiography would be overestimated in determining the rotational alignment of the femoral component.

In this study, we showed that the CTA measured on MPR images was larger than that calculated by the navigation system, indicating that the CTA measured by preoperative CT or radiography is larger than that measured intraoperatively. If the cutting block is set along the posterior condyle and rotational alignment is determined from the preoperative measurement, external rotation of the femoral component would be larger than expected due to the effect of the remaining posterior condylar cartilage.

Ishimaru *et al.* reported that there is a gender difference in distal femoral morphology in Japanese patients (21). Thus we compared the MPR-CTA-Navi-CTA between the male and female patients. However, the MPR-CTA did not differ significantly between two groups. We also investigated the association between the magnitude of the varus deformity and the MPR-CTA-Navi-CTA. Interestingly, the MPR-CTA-Navi-CTA is significantly larger in severe varus group.

Some studies that analyzed the effect of the posterior cartilage on the rotational alignment of the femoral component have been reported (12-14). Asada *et al.*, the first to investigate the effect of the cartilage on femoral component rotation in varus knee OA using CT arthrography, reported that the mean and maximum differences between the CTAs including and excluding cartilage were 1.1° and 2.1°, respectively (12). Our measurement method differs entirely from previously reported methods, although the differences between these CTAs in other reports were very close to our findings (13, 14).

According to Matsuda *et al.*, the lateral condyle is hypoplastic in valgus OA knees while varus arthritic knees show no major differences compared with normal knees (22). In the present study, we only investigated the varus osteoarthritic knees. This is the limitation of our study, and we can therefore conclude only that our result is applicable to varus knees at this time. As we did not analyze the effect of the posterior condylar cartilage in valgus deformity cases, further investigation is needed to determine the trends in valgus knees. Another limitation of this study is that the analyzed population was limited to Japanese patients, and different results might be obtained for other populations such as Caucasians.

In conclusion, we evaluated the effect of the posterior condylar cartilage on rotational alignment of the femoral component using a newly developed method in the larger population compared to the previous studies. Surgical planning without considering the posterior condylar cartilage may lead to overrotation of the femoral component especially in severe varus knees. Therefore, when determining rotational alignment of the femoral component using radiographic information in varus osteoarthritic knees, surgeons should consider the effect of the remaining cartilage of the posterior condyle.

CONFLICT OF INTERESTS

All authors have nothing to disclose.

REFERENCES

1. Merkow RL, Soudry M, Insall JN : Patellar dislocation following total knee replacement. *J Bone Joint Surg Am* 67(9) : 1321-1327, 1985
2. Berger RA, Crossett LS, Jacobs JJ, Rubash HE : Malrotation causing patellofemoral complications after total knee arthroplasty. *Clin Orthop Relat Res* 356 : 144-153, 1998
3. Arima J, Whiteside LA, McCarthy DS, White SE : Femoral rotational alignment, based on the anteroposterior axis, in total knee arthroplasty in a valgus knee. A technical note. *J Bone Joint Surg Am* 77(9) : 1331-1334, 1995
4. Griffin FM, Insall JN, Scuderi GR : The posterior condylar angle in osteoarthritic knees. *Journal of Arthroplasty* 13(7) : 812-815, 1998
5. Berger RA, Rubash HE, Seel MJ, Thompson WH, Crossett LS : Determining the rotational alignment of the femoral component in total knee arthroplasty using the epicondylar axis. *Clin Orthop Relat Res* 286 : 40-47, 1993
6. Poilvache PL, Insall JN, Scuderi GR, Font-Rodriguez DE : Rotational landmarks and sizing of the distal femur in total knee arthroplasty. *Clin Orthop Relat Res* 331 : 35-46, 1996
7. Akagi M, Yamashita E, Nakagawa T, Asano T, Nakamura T : Relationship between frontal knee alignment and reference axes in the distal femur. *Clin Orthop Relat Res* 388 : 147-156, 2001
8. Jerosch J, Peuker E, Philipps B, Filler T : Interindividual reproducibility in perioperative rotational alignment of femoral components in knee prosthetic surgery using the transepicondylar axis. *Knee Surg Sports Traumatol Arthrosc* 10(3) : 194-197, 2002
9. Siston RA, Patel JJ, Goodman SB, Delp SL, Giori NJ : The variability of femoral rotational alignment in total knee arthroplasty. *J Bone Joint Surg Am* 87(10) : 2276-2280, 2005
10. Victor J, Van Doninck D, Labey L, Van Glabbeek F, Parizel P, Bellemans J : A common reference frame for describing rotation of the distal femur : a ct-based kinematic study using cadavers. *J Bone Joint Surg Br* 91(5) : 683-690, 2009
11. Clarke HD : Changes in posterior condylar offset after total knee arthroplasty cannot be determined by radiographic measurements alone. *J Arthroplasty* 27(6) : 1155-1158, 2012
12. Asada S, Akagi M, Matsushita T, Hashimoto K, Mori S, Hamanishi C : Effects of cartilage remnants of the posterior femoral condyles on femoral component rotation in varus knee osteoarthritis. *Knee* 19(3) : 185-189, 2011
13. Tashiro Y, Uemura M, Matsuda S, Okazaki K, Kawahara S, Hashizume M, Iwamoto Y : Articular cartilage of the posterior condyle can affect rotational alignment in total knee arthroplasty. *Knee Surg Sports Traumatol Arthrosc* 20(8) : 1463-1469, 2012
14. Fujii T, Kondo M, Tomari K, Kadoya Y, Tanaka Y : Posterior condylar cartilage may distort rotational alignment of the femoral component based on posterior condylar axis in total knee arthroplasty. *Surg Radiol Anat* 34(7) : 633-638, 2012
15. Landis JR, Koch GG : The measurement of observer agreement for categorical data. *Biometrics* 33(1) : 159-174, 1977
16. Yoshino N, Takai S, Ohtsuki Y, Hirasawa Y : Computed tomography measurement of the surgical and clinical transepicondylar axis of the distal femur in osteoarthritic knees. *J Arthroplasty* 16(4) : 493-497, 2001
17. Jenny J-Y, Boeri C : Low reproducibility of the intra-operative measurement of the transepicondylar axis during total knee replacement. *Acta orthopaedica Scandinavica* 75(1) : 74-77, 2004
18. Winemaker MJ : Perfect balance in total knee arthroplasty : the elusive compromise. *Journal of Arthroplasty* 17(1) : 2-10, 2002

19. Takai S, Yoshino N, Isshiki T, Hirasawa Y : Kneeling view : a new roentgenographic technique to assess rotational deformity and alignment of the distal femur. J Arthroplasty 18(4) : 478-483, 2003
20. Kanekasu K, Kondo M, Kadoya Y : Axial radiography of the distal femur to assess rotational alignment in total knee arthroplasty. Clin Orthop Relat Res 434 : 193-197, 2005
21. Ishimaru M, Hino K, Onishi Y, Iseki Y, Mashima N, Miura H : A three-dimensional computed tomography study of distal femoral morphology in Japanese patients : gender differences and component fit. Knee 21(6) : 1221-1224, 2014
22. Matsuda S, Miura H, Nagamine R, Mawatari T, Tokunaga M, Nabeyama R, Iwamoto Y : Anatomical analysis of the femoral condyle in normal and osteoarthritic knees. J Orthop Res 22(1) : 104-109, 2004