

## CASE REPORT

# Therapeutic effects of one-year alendronate treatment in three cases of osteoporosis with parietal thinning of skull

Shinjiro Takata<sup>1)</sup>, Shoichiro Takao<sup>2)</sup>, Shusaku Yoshida<sup>3)</sup>, Fumio Hayashi<sup>1)</sup>, and Natsuo Yasui<sup>1)</sup>

<sup>1)</sup>Department of Orthopedics, <sup>2)</sup> Department of Radiology, Institute of Health Biosciences, the University of Tokushima Graduate School, Tokushima, Japan ; and <sup>3)</sup> Department of Radiology, Tokushima Prefectural Miyoshi Hospital, Tokushima, Japan

**Abstract :** We studied the therapeutic effects of one-year alendronate treatment in three cases (two males and one female) of osteoporosis with parietal thinning of skull. Plain radiography and three dimensional computed tomography revealed asymmetric external thinning of the posteromedial part of the bilateral parietal bones. Technetium-99m methylenediphosphate bone scintigraphy did not show any changes in these three cases. Pretreatment levels of urinary type I collagen cross-linked N-telopeptides (NTX) in all three cases were high compared to the normal range. Pretreatment levels of serum bone-specific alkaline phosphatase (BAP) in the two male patients were high in contrast to the normal values in the female patient. Pretreatment mean bone mineral density (BMD) values of the 2nd to 4th lumbar vertebrae (L2-4BMD), head BMD, femoral neck BMD, and whole body BMD of all three patients were low compared with the respective normal ranges.

One-year alendronate treatment decreased both urinary NTX and serum BAP in all three cases to normal values. Treatment also increased the whole body BMD in all three cases, the L2-4BMD of the female patient, the femoral neck BMD of the female patient and one male patient, and the head BMD of the female patient when compared to pretreatment levels. *J. Med. Invest.* 55 : 297-302, August, 2008

**Keywords :** parietal thinning, osteoporosis, bone mineral density, bone mineral metabolism, alendronate

## INTRODUCTION

Parietal thinning is defined as external thinning of the parietal bone of the skull. The characteristic site of parietal thinning is the posteromedial part of the parietal bone (1-4). Two types of parietal thinning have been described : flat and grooved (1,

4). The prevalence rate has been estimated to be 0.25-0.8% (4). Cederlund, *et al.* (1) showed that unequivocal parietal thinning was found in 86 (2.37%) of 3636 consecutive patients, and that the male/female sex ratio was 1 : 1.9. Parietal thinning is more common in women than men. At this time, the reason for excessive bone resorption in the skull, especially in the posteromedial part of the parietal bone in osteoporotic patients, remains unclear.

We studied the morphologic characteristics of the skull and therapeutic effects of one-year alendronate treatment on bone mineral metabolism in Japanese osteoporotic patients with parietal thinning. Im-

Received for publication February 4, 2008 ; accepted March 4, 2008.

Address correspondence and reprint requests to Shinjiro Takata, MD, PhD, Department of Orthopedics, Institute of Health Biosciences, the University of Tokushima Graduate School, Kuramoto-cho, Tokushima 770-8503, Japan and Fax : +81-88-633-0178.

aging characteristics of the skulls of these patients were visualized using modalities such as radiography, three-dimensional computed tomography (3D-CT), and technetium-99m methylenediphosphate ( $^{99m}\text{Tc}$  MDP) bone scintigraphy. Bone mineral metabolism was evaluated by urinary type I collagen cross-linked N-telopeptides (NTX) and serum bone-specific alkaline phosphatase (BAP). Whole body and regional bone mineral density (BMD) was measured by dual energy X-ray absorptiometry (DXA).

#### Case 1.

A 74-year-old male was referred to us because of a low BMD. His height was 159.5 cm and weight 45.0 kg. The body mass index (BMI) was 17.7 kg/m<sup>2</sup>, indicating that he was thin. There was no past history of fragile fracture.

Anteroposterior plain radiography revealed asymmetric bilateral parietal thinning of the skull (Fig. 1A). The lateral view of the plain radiograph of the skull showed striking radiolucency at the convexity of the parietal bones (Fig. 1B). 3D-CT and coronal sectioning of the skull revealed asymmetric external thinning of the posteromedial part of the bilateral parietal bones and the disappearance

of diploe at the depressed area of the bilateral parietal bones (Fig. 1C-E). Anteroposterior and lateral views of  $^{99m}\text{Tc}$  MDP bone scintigraphy did not show any changes in the parietal bone (Fig. 1F, G).

The mean BMD values of the 2nd to 4th lumbar vertebrae (L2-4BMD), femoral BMD, whole body BMD, and head BMD were measured by DXA using a Delphi densitometer (Hologic Inc., Waltham, MA, USA) in array beam scanning mode. Regional BMDs were measured for the head, upper extremities, lower extremities, ribs, thoracic spine, lumbar spine and pelvis. L2-4BMD and femoral BMD of this patient were low compared to the normal range, indicating osteoporosis (Table 1).

The levels of serum BAP and urinary NTX were high compared with normal ranges, indicating high bone turnover and acceleration of bone resorption. The level of serum alkaline phosphatase was high compared to the normal range. The level of serum intact PTH was within the normal range (Table 2).

The whole body BMD was increased, whereas L2-4BMD, femoral neck BMD and head BMD decreased after a one-year alendronate treatment (Fig. 2A-D). Both urinary NTX and serum BAP in case 1 decreased to normal ranges after one-year alendronate treatment (Fig. 3A, B).

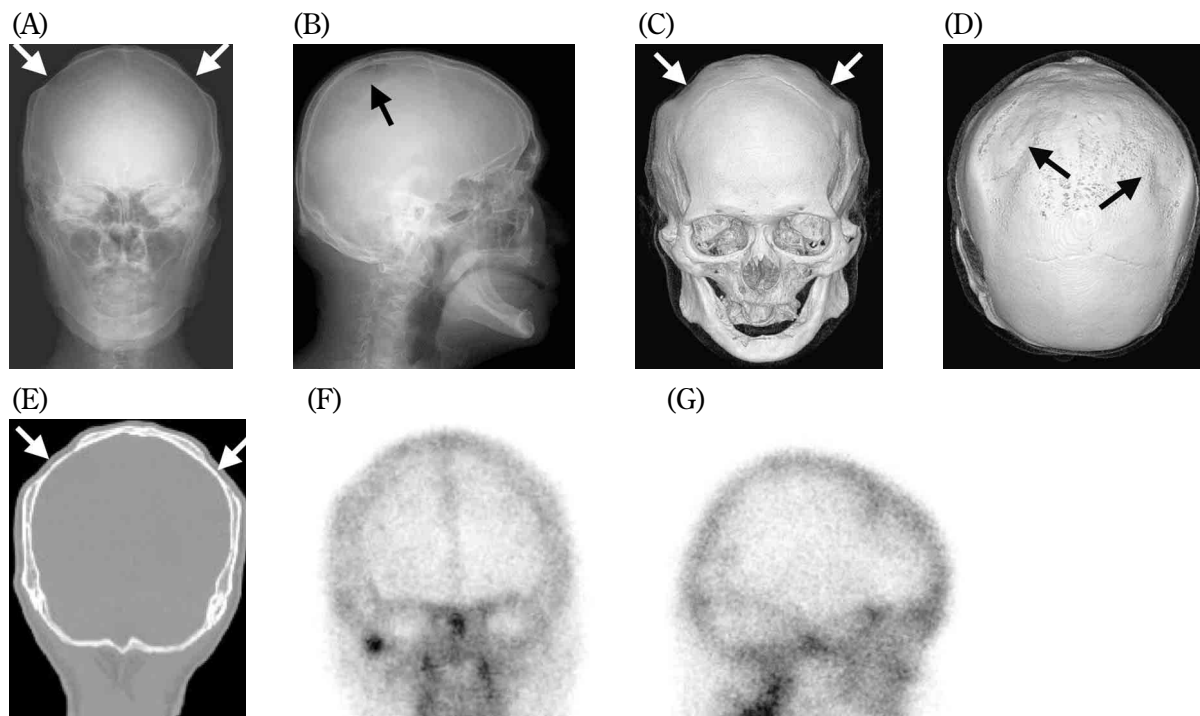


Fig. 1. Imaging Diagnosis of Case 1.

Anteroposterior plain radiography revealed bilateral parietal thinning (white arrows) (A). Lateral view of the plain radiograph of the skull showed an apparent radiolucent band at the convexity of the parietal bones (black arrow) (B). 3D-CT revealed asymmetric thinning of the parietal bones (black and white arrows) (C, D). Coronal section at the level of the lesion showed asymmetric external thinning of the bilateral parietal bones and the complete disappearance of diploe (white arrows) (E). Anteroposterior and lateral views of  $^{99m}\text{Tc}$  MDP bone scintigraphy did not show any changes in the parietal bones (F, G).

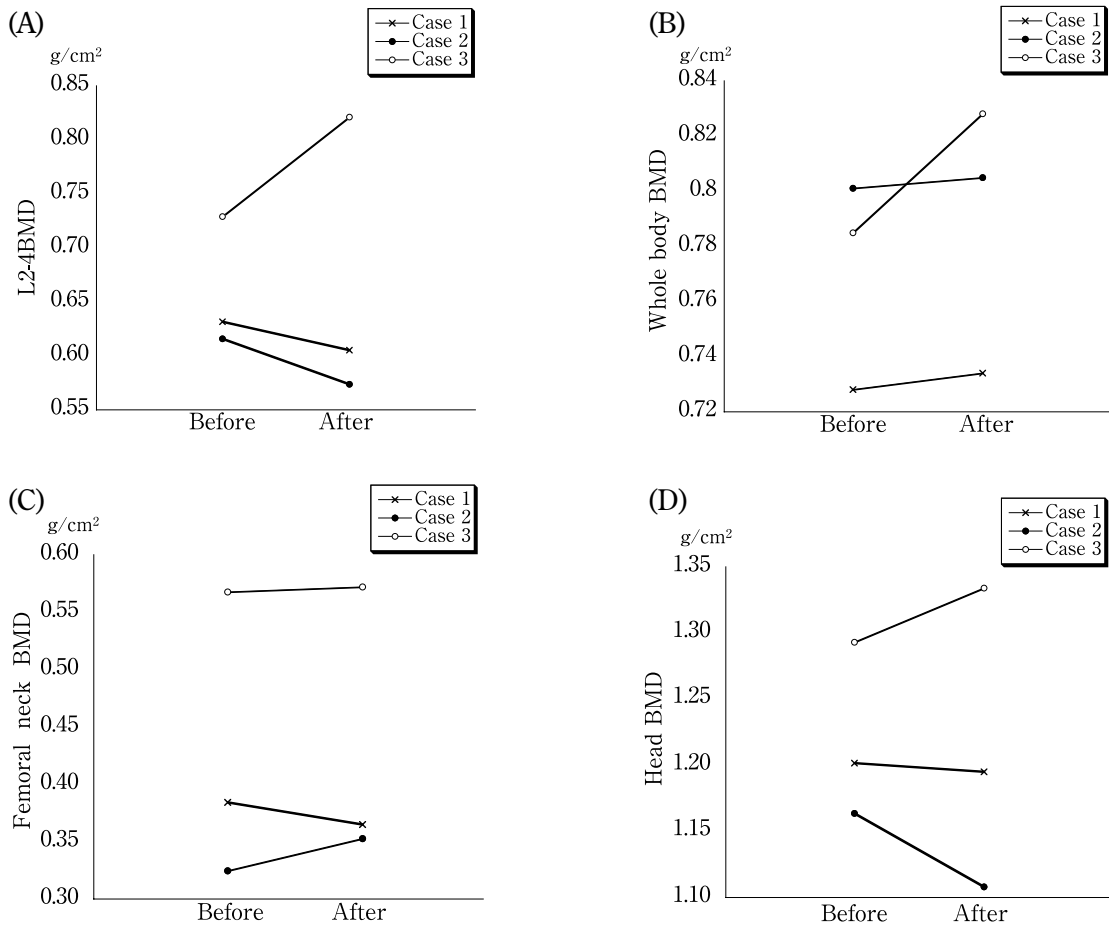


Fig. 2. Regional and whole body BMDs before and after one-year alendronate treatment. Whole body BMD of all patients increased after treatment (A). L2-4BMD of case 3 increased after one-year alendronate treatment. In contrast, L2-4BMD of case 1 and 2 decreased (B). Femoral neck BMD of case 2 and 3 increased after treatment, whereas femoral neck BMD of case 1 decreased (C). Head BMD of case 3 increased after treatment. In contrast, head BMD of case 1 and 2 decreased (D). BMD, bone mineral density ; L2-4BMD, the mean BMD values of the 2nd to 4th lumbar vertebrae

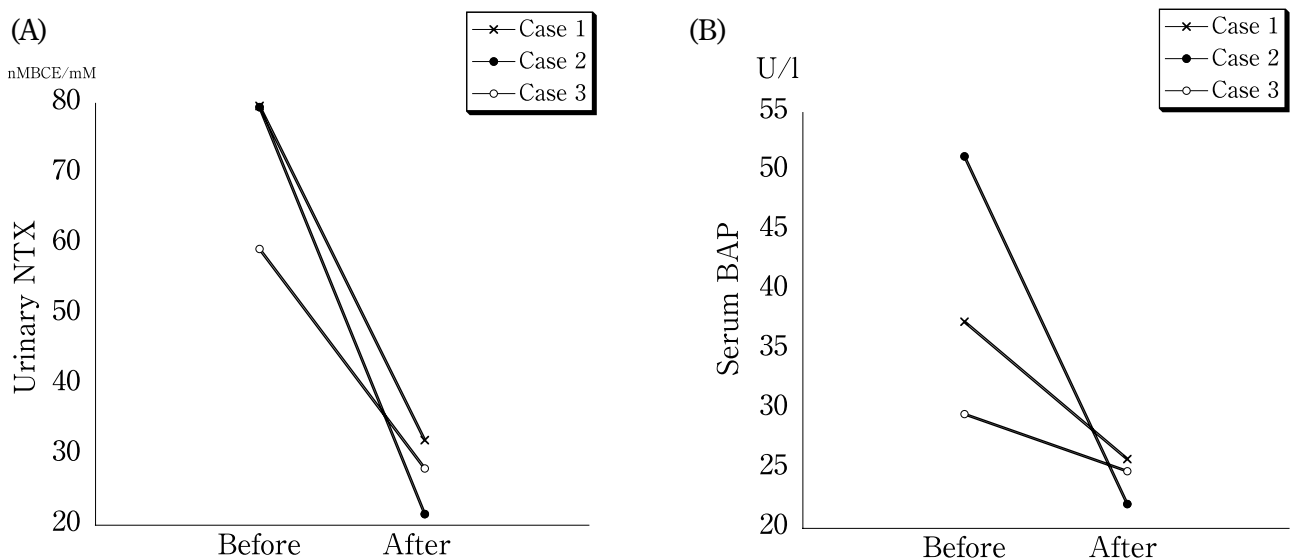


Fig. 3. Urinary NTX and serum BAP before and after one-year alendronate treatment. Urinary NTX of all patients were high compared to the normal range. One-year alendronate treatment decreased the urinary NTX of all three patients to normal levels (A). Serum BAP of case 1 and 2 were high compared to the normal range. In contrast, the serum BAP of case 3 was within the normal range. One-year alendronate treatment decreased the serum BAP of case 1 and 2 to within the normal range. The serum BAP of case 3 decreased compared to the pretreatment level of serum BAP (B). Urinary NTX, urinary type I collagen cross-linked N-telopeptides ; Serum BAP, serum bone-specific alkaline phosphatase

**Table 1.** Bone mineral density (BMD) before one-year alendronate treatment.

	Case 1	Case 2	Case 3
L2-4 BMD (g/cm <sup>2</sup> )	0.632	0.583	0.729
TS	-3.5	-3.9	-2.54
Femoral Neck BMD (g/cm <sup>2</sup> )	0.384	0.325	0.568
TS	-3.6	-4.1	-2.01
Head BMD (g/cm <sup>2</sup> )	1.202	1.164	1.334
TS			
Whole body BMD (g/cm <sup>2</sup> )	0.728	0.801	0.828
TS			-3.25

L2-4 BMD, the mean BMD values of the 2nd to 4th lumbar vertebrae ; TS, T score

There is no TS for Head BMD in Japan.

There is no TS for whole body BMD in males in Japan.

**Table 2.** Markers of bone mineral metabolism in the three cases before one-year alendronate treatment.

	Case1	Case 2	Case 3	Normal range
Serum Ca (mg/dl)	9.7	8.8	9.0	8.8~10.1
Serum P (mg/dl)	3.6	2.7	3.9	2.4~4.6
Serum AP (IU/l)	428	286	262	110~354
Intact PTH (pg/ml)	23.2	28.0	32.0	10~65
Serum BAP (U/l)	37.1	51.3	29.6	13.0~33.9
Urinary NTX (nMBCE/mM)	79.6	79.5	59.3	9.3~54.3

AP, alkaline phosphatase ; PTH, parathyroid hormone ; BAP, bone-specific alkaline phosphatase ; NTX, type I collagen cross-linked N-telopeptides

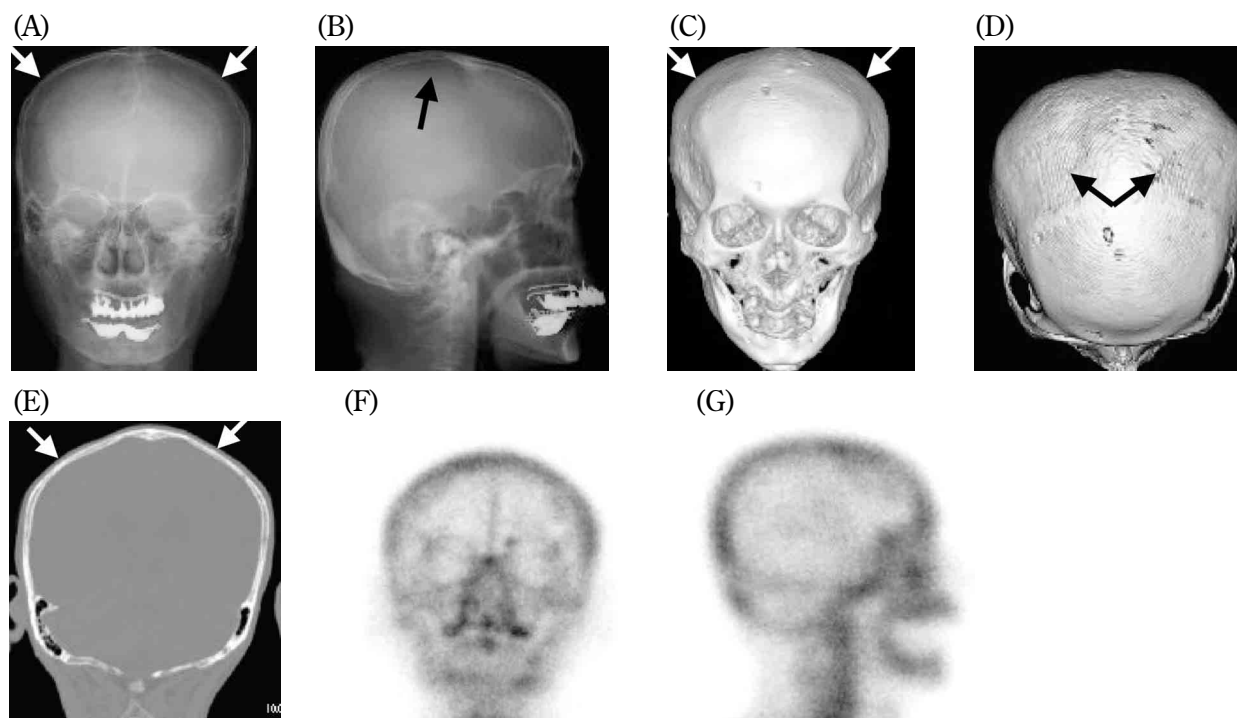
**Case 2.**

This case was a 73-year-old male. His height was 162.3 cm and weight 43.0 kg. The BMI was 16.4 kg/m<sup>2</sup>, indicating that he was thin. There was past history of vertebral fractures of the thoracic and lumbar spine.

L2-4BMD and femoral BMD values were low compared with normal ranges, indicating osteoporosis (Table 1).

Plain radiography of the skull revealed asymmetric and bilateral thinning of the parietal bones (Fig. 4A). Lateral view of the plain radiograph of the skull showed a radiolucent area at the convexity of the parietal (Fig. 4B). 3D-CT and coronal sectioning of the skull revealed asymmetric external thinning of the posteromedial part of the bilateral parietal bones and the disappearance of diploe at the depressed area of the bilateral parietal bones (Fig. 4C-E). The area of parietal thinning in the parietal bones of case 2 were greater than in the other cases. Internal lamina seemed to be intact. The anteroposterior and lateral views of <sup>99m</sup>Tc MDP bone scintigraphy did not show any changes in parietal bone (Fig. 4F, G).

Levels of both urinary NTX and serum BAP for

**Fig. 4.** Imaging Diagnosis of Case 2.

Anteroposterior plain radiography revealed asymmetric parietal thinning (white arrows) (A). Lateral view of the plain radiograph of the skull showed a radiolucent area at the convexity of the parietal bones (black arrow) (B). 3D-CT revealed asymmetric thinning of parietal bones (black and white arrows) (C, D). Coronal section showed asymmetric external thinning of the bilateral parietal bone. Diploe at the left parietal bone disappeared (E). Anteroposterior and lateral views of <sup>99m</sup>Tc MDP bone scintigraphy did not show any changes in the parietal bone (F, G).

case 2 were high compared to the normal ranges, indicating high bone turnover and acceleration of bone resorption. The level of serum intact PTH was within the normal range (Table 2).

The whole body BMD and femoral neck BMD increased, whereas the L2-4BMD and head BMD decreased after one-year alendronate treatment (Fig. 2A-D). Treatment decreased both urinary NTX and serum BAP to normal ranges (Fig. 3A, B).

### Case 3.

The patient was a 68-year-old female. Her height was 146.8 cm and weight 47.2 kg. The BMI was 22.1 kg/m<sup>2</sup>. She was referred to us because of persistent back pain. There was a past history of atraumatic vertebral fracture.

L2-4BMD and femoral BMD values were low compared with the normal ranges, indicating osteopenia (Table 1).

Plain radiography of the skull revealed asymmetric and bilateral flattening of the parietal bones

(Fig. 5A). Lateral view of the plain radiograph of the skull showed no radiolucency at the convexity of the parietal (Fig. 5B). 3D-CT and coronal sectioning of the skull revealed the asymmetric external thinning of the posteromedial part of the bilateral parietal bones. The right parietal bone was thinner than the left one (Fig. 5C-E). The anteroposterior and lateral views of <sup>99m</sup>Tc MDP bone scintigraphy did not show any changes in parietal bone (Fig. 5F, G).

The level of urinary NTX was high compared to the normal range, indicating acceleration of bone resorption. In contrast, the level of serum BAP was within the normal range, indicating a normal level of bone turnover. The level of serum intact PTH was within the normal range (Table 2).

One-year alendronate treatment increased the L2-4, whole body, femoral neck, and head BMD (Fig. 2A-D). Urinary NTX decreased to the normal range. Serum BAP was within the normal range, and it decreased after treatment. (Fig. 3A, B).

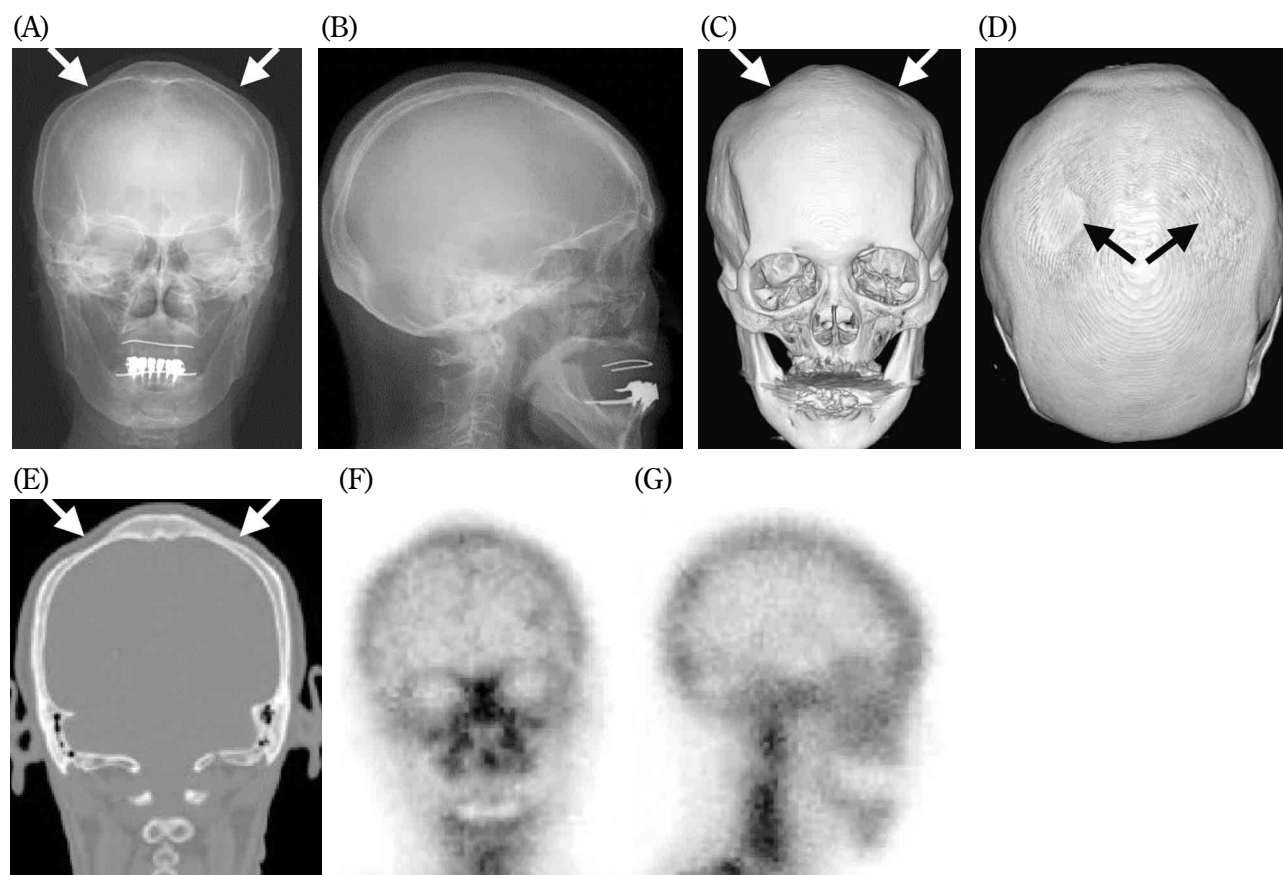


Fig. 5. Imaging Diagnosis of Case 3.

Anteroposterior plain radiography revealed bilateral parietal thinning (white arrows) (A). Lateral view of the plain radiograph of the skull showed no radiolucency at the convexity of the parietal bones (B). 3D-CT revealed asymmetric thinning of the parietal bones (black and white arrows) (C, D). The degree of thinning of the parietal bones on the right side was greater than that on the left side. Coronal sectioning showed asymmetric external thinning of the parietal bones (E). The diploe at the right parietal bone disappeared. In contrast, the diploe at the left parietal bone was preserved (white arrows). Anteroposterior and lateral views of <sup>99m</sup>Tc MDP bone scintigraphy did not show any changes in the parietal bone (F, G).

## DISCUSSION

External thinning of the posteromedial part of the bilateral parietal bones is a morphological characteristic of the skulls of osteoporotic patients with parietal thinning. Previous studies (1, 4) have shown that the most common site of parietal thinning is the posteromedial part of the parietal bones, and that there are two types of parietal thinning of the skull, flat and grooved. Most cases of parietal thinning are of the flat type (1). Parietal thinning of our three cases was of the flat type.

As shown by the imaging modalities, the degree of bone resorption at the external lamina and diploe of the parietal bone seemed to be greater than at the internal lamina, resulting in external thinning of the parietal bones. Seok, *et al.* (5) observed an absence of external lamina and diploe of the parietal bones in a patient with parietal thinning, although the internal lamina of the parietal bone was intact. In case 1, the diploe at the area of depression of the bilateral parietal bones disappeared. In case 2, the diploe at the area of depression of the left parietal bone disappeared, whereas diploe at the area of depression of the right parietal bone was preserved. In contrast, in case 3, the diploe was preserved at the depressed area of the left parietal bone, although it was not seen at the depressed area of the right parietal bone.

The anteroposterior and lateral views of  $^{99m}\text{Tc}$  MDP bone scintigraphy did not show any changes in thin parietal bone of our three cases. The degree of radiotracer uptake is thought to depend on blood flow and rate of bone formation (6, 7). This result suggests that there are no changes in blood flow and rate of bone formation in thin parietal bones of our three cases.

Pretreatment levels of urinary NTX for our three cases were high compared to the normal range, indicating acceleration of bone resorption. In contrast, two of our three cases showed a high level of serum BAP (Table 2), suggesting high bone turnover.

One-year alendronate treatment decreased both urinary NTX and serum BAP to normal ranges and

increased the whole body BMD of all three patients, indicating that this treatment improved the bone mineral metabolism (Fig. 2A-D, Fig. 3A, B). These results suggest that acceleration of bone resorption is one of the causes of parietal thinning in osteoporotic patients.

One-year alendronate treatment showed different therapeutic effects in the whole body and regional BMDs. The whole body BMD of all patients increased after treatment. In contrast, the regional lumbar, femoral, and head BMDs showed differences in therapeutic benefit (Fig. 2A-D).

At this time, the reasons for excessive bone resorption in the skull, especially in the posteromedial part of the parietal bone in osteoporotic patients, as well as the reasons for enhanced external lamina bone resorption remain unclear. Further studies are required to elucidate the biochemical mechanism of parietal thinning in these patients.

## REFERENCES

1. Cederlund DG, Andren L, Olivecrona H : Progressive bilateral thinning of the parietal bones. *Skeletal Radiol* 8 : 29-33, 1982
2. Wilms G, Van Roost W, Van Russelt J, Smits J : Biparietal thinning : correlation with CT findings. *Radiologie* 23 : 385-386, 1983
3. Farrell B, Gerard PS : Imaging of parietal thinning. *NY State J Med* 91 : 509-510, 1991
4. Bruyn GW, Bots GTAM : Biparietal osteodystrophy. *Clin Neurol Neurosurg* 80 : 125-128, 1978
5. Seok TL, Myung-Hee S : Bilateral symmetric photon defects in the parietal bones on Tc-99m MDP bone scintigraphy. *Bilateral Parietal Thinning. Clin Nucl Med* 26 : 570-571, 2001
6. Genant HK, Bautovich GJ, Singh M, Lathrop KA, Harper PV : Bone-seeking radionuclides : an *in vivo* study of factors affecting skeletal uptake. *Radiology* 113 : 373-382, 1974
7. Galasko CSB : The pathological basis for skeletal scintigraphy. *J Bone Joint Surg Br* 57 : 353-359, 1975