

## CASE REPORT

# Laparoscopy and intersex : report of 5 cases of male pseudohermaphroditism

Mohamed Gad El-Moula<sup>a,b</sup>, Hirofumi Izaki<sup>a</sup>, Fathy El-Anany<sup>b</sup>, Alaa Abd El-Moneim<sup>b</sup>, Abd El-Moneim El-Haggagy<sup>b</sup>, Yasser Abdelsalam<sup>b</sup>, Ahmad Abolyosr<sup>b</sup>, Tomoteru Kishimoto<sup>a</sup>, Natsuo Oka<sup>a</sup>, Masayuki Takahashi<sup>a</sup>, Tomoharu Fukumori<sup>a</sup>, and Hiro-omi Kanayama<sup>a</sup>

<sup>a</sup>Department of Urology, Institute of Health Biosciences, The University of Tokushima Graduate School Tokushima, Japan ; and <sup>b</sup>Department of Urology, Assiut University, Egypt

**Abstract :** From May, 1999 to August, 2006, we performed laparoscopic diagnosis and treatment for 103 cases of impalpable testes. Among those we found 5 cases of male pseudohermaphroditism of different etiologies. Three males presented by impalpable testes with ambiguous genitalia and 2 females presented by primary amenorrhea. All of them have 46-XY normal male chromosomal pattern. In the first 3 cases, the etiology was complete gonadal dysgenesis, and 2 cases with persistent Mullerian syndrome. Timed gonadectomy for the first case and laparoscopic orchiopexy for the other 2 cases were performed. For the other 2 female cases, the etiology was complete androgen insensitivity syndrome and laparoscopic bilateral orchiectomy was performed for both of them. All the procedures were done without complications with satisfactory results. *J. Med. Invest.* 55 : 147-150, February, 2008

**Keywords :** laparoscopy, male pseudohermaphroditism, persistent mullerian duct structures, androgen insensitivity syndrome, gonadectomy

## INTRODUCTION

Laparoscopy was recently introduced as a method of evaluation and treatment of intersex patients presented by impalpable testes. Besides its advantage as a minimally invasive approach, its better cosmetic result is an important factor for those patients with psychological and/or social problems (1-3).

Male pseudohermaphroditism (MPH) is the most diverse type of sexual disorders, in which the gonads are testes with 46-XY chromosomal pattern but phenotypically there are variable degrees of feminization. It has several causes including inborn errors of testosterone biosynthesis, Leydig cell aplasia or

hypoplasia, androgen insensitivity syndrome (AIS) and persistent Mullerian duct structures (PMDS).

PMDS or sometimes referred as hernia uterine inguinale is a rare syndrome resulting from failure of paracrine secretion of anti-Mullerian hormone by the sertoli cells or failure of the Mullerian ducts to respond to its secretion. In this case a phenotypically normal male subject has a fallopian tubes and a uterus along with testes and Wolffian duct derivatives. A genetic mutation of chromosome 19 seems to be implicated in this condition. Patients with gonadal dysgenesis either unilateral or bilateral require removal of their streak gonad(s) because of their malignant potential (4, 5).

AIS or testicular feminization is also a rare condition causing complete or incomplete androgen insensitivity in the target tissues. In recent studies, mutations of the androgen receptor gene, especially in the hormone-binding domain, were observed in those patients (6). Herein we present our experience

Received for publication August 17, 2007 ; accepted November 22, 2007.

Address correspondence and reprint requests to Hiro-omi Kanayama, M.D., Ph.D., Department of Urology, Institute of Health Biosciences, The University of Tokushima Graduate School, Kuramoto-cho, Tokushima 770-8503, Japan and Fax : +81-88-633-7160.

in laparoscopic management of 5 cases of MPH with different etiologies.

## CASE STUDY

### Case (1)

Three-year-old children presented by ambiguous genitalia in the form of microphallus with severe chordee and persistent urogenital sinus. Chromosomal pattern was 46-XY. Hormonal assay revealed raised Follicle stimulating hormone (FSH) level. Laparoscopy revealed bilateral indefinite gonads together with PMDS. Laparoscopic guided gonadal biopsy revealed normal testis and the other is disgenetic. The diagnosis was male pseudohermaphroditism (MPH) with partial gonadal dysgenesis. Male sex assigned with bilateral laparoscopic orchiopexy, Figure 1.

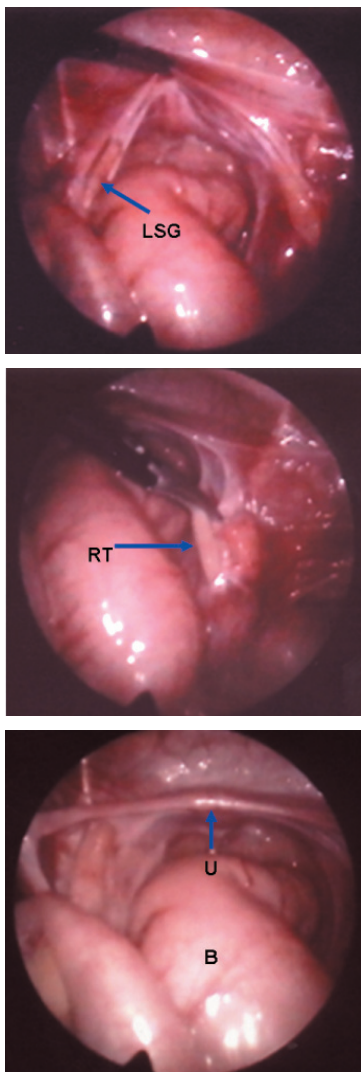


Figure 1 Patient with partial gonadal dysgenesis. LSG ; left streak gonad - RT ; right testis - U ; uterus - B ; bowel.

### Case (2)

A 12-year-old male child presented by bilateral impalpable testes. Chromosomal pattern was 46-XY normal male with normal hormonal assay. On laparoscopy, bilateral abdominal testes and PMDS were found. Biopsy from these gonads was taken and confirmed prepubertal testicular tissue. The diagnosis was hernia uterine inguinale or PMDS. Bilateral laparoscopic orchiopexy were performed in two sessions using our previously published technique (7). In brief, the gubernacular attachments are grasped and transected as far distally as possible using electro-surgical instruments. Dissection proceeds by incision of the peritoneum caudal to the vas deferens and then lateral to the spermatic vessels. At the superior extent of the dissection, the peritoneum overlying the spermatic vessels is incised, with care taken to avoid injury to the artery or vein. This step serves to free the testicular vessels from the posterior peritoneal attachments, and often provides additional length. The testis is brought as far down as possible via a scrotal trocar through the neo-hiatus, which is positioned medial to the medial umbilical ligament and just over the pubic tubercle. The testis is then fixed in position in the subdartos pouch. The PMDS was not removed to avoid injury of the vasa deferentia during dissection.

### Case (3)

Another 12-year-old male child presented by bilateral impalpable testes together with scrotal hypospadias. Chromosomal study was 46-XY normal male. On laparoscopy, bilateral abdominal testes and PMDS were found. Biopsy was taken and revealed prepubertal testicular tissue. The diagnosis was PMDS. Laparoscopic orchiopexy and hypospadias repair were performed. The Müllerian duct derivatives were not removed.

### Case (4)

A 19-year old patient reared as female presented by primary amenorrhea. The external genitalia appeared entirely female. No intersexual glands or uterus was observed by computed tomography (CT) or magnetic resonance imaging (MRI). Chromosomal study revealed 46-XY normal male. Hormonal assay revealed ; normal testosterone level (7.0 ng/ml). Luteinizing hormone LH (34.9 mIU/ml) and follicle stimulating hormone FSH (19.2 mIU/ml) were slightly higher than that of the age-matched reproductive men. Under general anesthesia pneumoperi-

toneum was created through an open Hasson technique below the umbilicus (Figure 2). Laparoscopy showed bilateral high abdominal testes and no uterus. The diagnosis was complete androgen insensitivity syndrome (CAIS) or testicular feminization syndrome and laparoscopic bilateral orchiectomy was performed. Histopathology of the removed gonads showed spermatogonial arrest and Leydig cell focal hyperplasia.

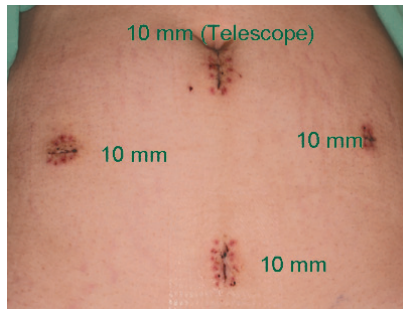


Figure 2 -Early postoperative photo of the patient with testicular feminization syndrome showing the trocars positions and the cosmetic outcome.

#### Case (5)

A 22-year old patient reared as female presented by primary amenorrhea with feminine external genitalia and secondary sexual characters. Chromosomal study revealed 46-XY normal male. Hormonal assay revealed normal testosterone level (6.0 ng/ml), but high free testosterone (13.1 ng/ml). Luteinizing hormone LH (14.5 mIU/ml) and follicle stimulating hormone FSH (6.5 mIU/ml) were normal. Laparoscopy showed bilateral high abdominal testes and no uterus. The diagnosis was CAIS and laparoscopic bilateral orchiectomy decided. For that, three more trocars 10 mm each were introduced in the midline midway between the umbilicus and the symphysis pubis and in the both iliac fossae (Figure 3).

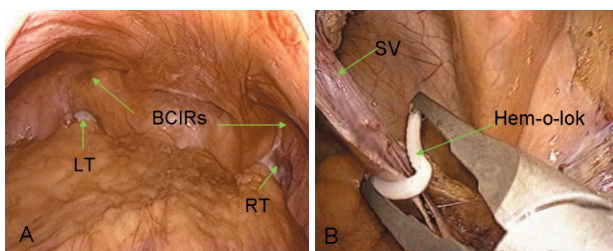


Figure 3 A-Laparoscopic view of the same patient showing bilateral abdominal testes. BCIRs; bilateral closed internal rings, LT; left testis, RT; right testis  
B-Laparoscopic view showing control of the spermatic vessels by hem-o-lok during bilateral laparoscopic orchiectomy for the same patient.  
SV; spermatic vessels.

Bilateral laparoscopic orchiectomy was successfully completed with the use of hem-o-lok to control the spermatic vessels. Histopathology of the removed gonads showed spermatogonial arrest, Leydig cell focal hyperplasia and thickened basement membrane. Informed consent was taken from all patients for the risk of surgery and sex reassignment. All the procedures completed without complications. During follow up, the testes were of good size, viable and in the bottom of the scrotum.

## DISCUSSION

During the last two decades laparoscopy progressively replacing open surgery in many procedures in urology. Cortesi, *et al.* first performed laparoscopic diagnosis for impalpable testis in 1976, since that time many series published describing the various laparoscopic techniques for both diagnosis and treatment of impalpable gonads (8). The use of laparoscopy to diagnose and/or treat intersex disorders first reported in 1986 when Portuondo, *et al.* first performed laparoscopic gonadal biopsy to establish the diagnosis in a case of MPH (9). Laparoscopic gonadectomy for gonadal dysgenesis was first performed in 1990 by Droesch, *et al.* (10).

MPH is the commonest indication for laparoscopic diagnosis and treatment among intersex patients. Laparoscopy in these cases can identify the gonads, the persistence of the Mullerian structures, besides gonadal biopsy can be performed to define whether they are normal or dysgenetic. In the current study we present 5 cases of MPH, laparoscopic gonadal biopsy was very effective in establishing the final diagnosis especially in the case of dysgenetic gonads (11, 12).

There is controversy whether to remove the Mullerian derivatives (MD) or not. Two cases of malignant degeneration of these remnants were reported and the authors strongly recommend their removal, others did not (13, 14). We have 3 cases of PMDS but we did not remove the MD. Our concept is to avoid injury of the vasa deferentia or the testicular vessels. We report here also the rare association between PMDS and hypospadias in one of our cases (15).

The testes in patients with CAIS and those with PAIS, raised female, should be removed to prevent malignancy in adulthood. The availability of estrogen replacement therapy allows for the option of early removal at the time of diagnosis which also

takes care of the associated hernia, psychological problems with the presence of testes and the risk of malignant change (16). We have 2 cases of CAIS, for them we performed bilateral laparoscopic orchiectomy followed by estrogen replacement therapy. The streak gonad in a patient with mixed gonadal dysgenesis raised male should be removed laparoscopically (or by laparotomy) in early childhood.

## CONCLUSION

Laparoscopy is a mandatory tool for diagnosis and treatment of intersex cases because of its minimal invasiveness, its better visualization of the gonads, the possibility of taking gonadal biopsy and performing orchiectomy or orchiopexy and finally its excellent cosmetic results.

## REFERENCES

1. Denes FT, Mendonca BB, Arap S : Laparoscopic management of intersexual states. *Urol Clin North Am* 28 : 31-42, 2001
2. Yu TJ, SHU K, Kung FT, Eng HL, Chen HY : Use of laparoscopy in intersex patients. *J Urol* 154 : 1193-1196, 1995
3. Fahlenkamp D, Winfield H, Schonberger B, Mueller W, Loening SA : Role of laparoscopic surgery in pediatric Urology. *Eur Urol* 32 : 75-84, 1997
4. Berkmen F : Persistent Mullerian duct syndrome with or without transverse testicular ectopia and testis tumors. *Br J Urol* 79 : 122-126, 1997
5. Manuel M, Katayama PK, Jones HW : The age of occurrence of gonadal tumors in intersex patients with a Y chromosome. *Am J Obstet Gynecol* 124(3) : 293-300, 1976
6. Sultan C, Lumbroso S, Poujol N, Belon C, Boudon C, Lobaccaro JM : Mutations of androgen receptor gene in androgen insensitivity syndrome. *J Steroid Biochem Mol Biol* 46 : 519-530, 1993
7. El-Anany F, Gad El-Moula M, AbdelMoneim A, Abdallah A, Takahashi M, Kanayama H, El-Haggagy A : Laparoscopy for impalpable testis : classification-based management. *Surg Endosc* 21(3) : 449-54, 2007
8. Cortesi N, Baldini A, Ferrari P, Manenti A, Morano FP, zambarda E : Diagnosis of bilateral abdominal cryptorchidism by laparoscopy. *Endoscopy* 8 : 33-34, 1976.
9. Portuondo J, Neyro J, Barral A, Gonzalez GF, Benito JA : Management of phenotypic female patients with an XY karyotype. *J Reprod Med* 31 : 611-615, 1986
10. Droesch K, Droesch J, Chumas J, Bronson R : Laparoscopic gonadectomy for gonadal dysgenesis. *Fertil Steril* 53 : 360-361, 1990
11. Bardeguez AD, De Ziegler D, Weiss G : Multifetal pregnancy in a gonadal dysgenesis mosaic. *Obstet Gynecol* 76 : 502-4, 1990
12. Sauer MV, Lobo RA, Paulson RJ : Successful twin pregnancy after embryo donation to a patient with XY gonadal dysgenesis. *Am J Obstet Gynecol* 161 : 380-1, 1989
13. Shinmura S, Yokoi T, Tsutsui Y : A case of clear cell adenocarcinoma of the Mullerian duct in persistent Mullerian duct syndrome. *Am J Pathol* 26(12) : 1231-4, 2002
14. Thiel DD, Erhard MJ : Uterine adenosarcoma in a boy with persistent Mullerian duct syndrome : first reported case. *J Pediatr Surg* 40 : E29-E31, 2005
15. Chertin B, Koulikov D, Alberton J : The use of laparoscopy in intersex patients. *Pediatr Surg Int* 22 : 405-408, 2006
16. Grumbach MM, Hughes IA, Conte FA : Disorders of sex differentiation. In : Larsen PR, Kronenberg HM, Melmed S, Polonsky KS, eds. *Williams Textbook of Endocrinology*. 10th ed. Saunders, USA, 2003