

## CASE REPORT

# An autopsy case of adrenal insufficiency 20 years after Hypophysectomy: Relation between stress and cause of death

Shin-ichi Kubo, Akiko Ishigami, Takako Gotohda, Itsuo Tokunaga, and Osamu Kitamura

*Department of Forensic Medicine, Institute of Health Biosciences, The University of Tokushima Graduate School, Tokushima, Japan*

**Abstract :** A 63-years-old man was found dead with the body soaking in water lying face up on a riverbank. Autopsy and diatom examination demonstrated that the cause of death was drowning. He had undergone hypophysectomy 20 years earlier. Autopsy, pathological and endocrinological findings demonstrated secondary and chronic hypothyroidism, hypogonadism, and adrenal insufficiency. The cadaver had fallen into the river, and received numerous wounds such as abrasions and subcutaneous hemorrhage. Moreover, it was suspected that he had developed hypothermia before death. Cortisol in the blood and 17-OHCS in urine were within the reference range. We suspect that the adrenocortical hormone was secreted into the blood as a result of various stresses due to wounds and hypothermia. However, it was suspected that sufficient hormone might not be secreted due to chronic adrenal insufficiency. This insufficient cortisol causes the decrease in the stress resistance, and might influence his cause of death. Moreover, as hypothyroidism decreases thermogenesis, he might have fallen into hypothermia easily. In addition, because both adrenocortical insufficiency and hypothyroidism caused the hypoglycemia, he might have fallen into the loss of consciousness. Therefore, it was considered that he had died by drowning, in relation to the adrenocortical insufficiency and panhypopituitarism. *J. Med. Invest.* 53 : 183-187, February, 2006

**Keywords :** *cause of death, adrenal insufficiency, panhypopituitarism, hypophysectomy, endocrinology*

## INTRODUCTION

After hypophysectomy, if the treatment is insufficient, patients are known to fall into the hypopituitarism. Hypopituitarism induces growth hormone, gonadotrophin, thyroid stimulating hormone and adrenocorticotrophic hormone insufficiency (1). When sufficient adrenal steroid hormones, glucocorticoids (cortisol), mineralcorticoids (aldosterone), and adrenal androgen

cannot be secreted, the condition is called adrenocortical insufficiency (2, 3). When a patient with chronic adrenocortical insufficiency is exposed to stress, and, therefore, has an increased requirement for glucocorticoids, blood pressure falls and hypovolemic shock develops (4, 5). Moreover, as hypothyroidism decreases thermogenesis, patient might have fallen into hypothermia easily. In addition, because both adrenocortical insufficiency and hypothyroidism caused the hypoglycemia, the loss of consciousness might be induced before death (6).

An autopsy case involving a man who died 20 years after hypophysectomy is reported. The cause of death and relation to hypopituitarism and adrenal insufficiency are discussed in detail.

Received for publication November 8, 2005 ; accepted December 2, 2005.

Address correspondence and reprint requests to Shin-ichi Kubo, Department of Forensic Medicine, Institute of Health Biosciences, The University of Tokushima Graduate School, Tokushima 770-8503, Japan and Fax : +81-88-633-7084.

## CASE REPORT

A 63-year-old man was reported missing at the end of October. Three days later, he was found dead with the lower half of the body soaking in water lying face up on a riverbank in the vicinity of his own house. Medical history : The patient had undergone hypophysectomy due to pituitary adenoma 20 years ago. Post operatively, he regularly attended the hospital for follow-up medical treatment, but he had stopped attending the hospital and had not received any medical treatment for several years. The details of his clinical history remain uncertain.

## AUTOPSY FINDINGS

The subject was 157cm in stature and 51kg in weight. Numerous small discolorations and abrasions were observed in various sites on the body surface. A surgical scar crossed the frontal region of the head skin, and connected the right and left auricle. A surgical track covered with wire and resin was also observed on the bones of the skull just under the surgical scar on the head skin. The pubic hair did not grow, and the penis remained infantile. Trauma was not observed in the brain or other internal organs. The hypophysis was not found on the turkish saddle, the pituitary was totally extracted (Fig. 1). The thyroid gland weighed 14.3 g (normal range ;  $16.6 \pm 5.43$  g) (7), and was slightly atrophic. Both adrenal glands had severely thinned (Fig. 2). The left adrenal gland weighed 1.67 g (normal range;  $5.7 \pm 2.07$ g), and that on the right weighed 1.73 g(normal range ;  $5.1 \pm 1.65$ g)(7). The testis was relatively soft. The weight of the left testis with epididymidis was 10.8 g (normal weight of testis ; 8.45 g, epididymidis;2.33 g) and that on the right was 11.8g (normal weight of testis;8.39g, epididymidis; 2.16g)

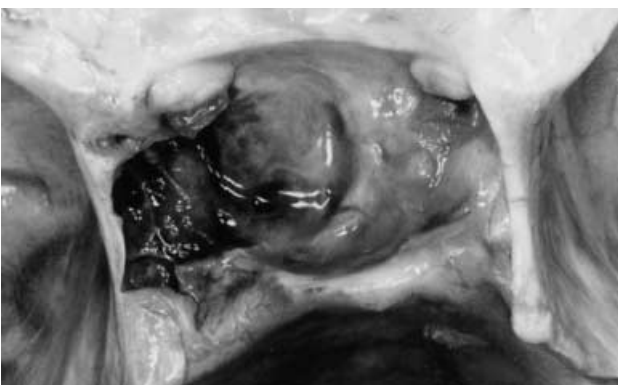

Fig.1 . Pituitary fossa after hypophysectomy

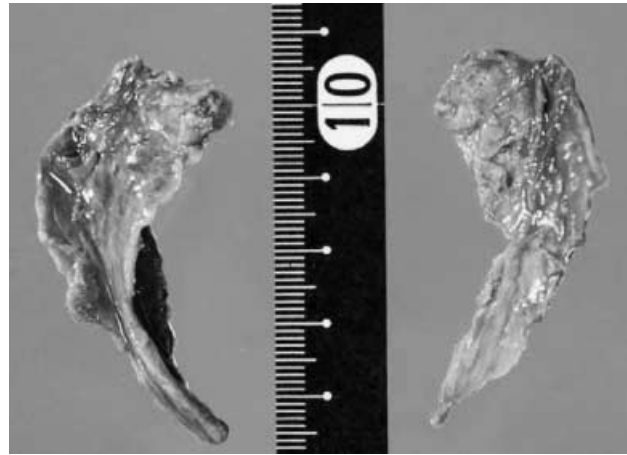


Fig. 2 . Severe atrophy of adrenal glands

(8). In the heart, a color tone difference was noted between the right and left atrial blood. The color of the left cardiac blood was redder than that on the right side. The left lung was 495.0 g(normal range ;  $443 \pm 125.2$ g) in the weight of the lung, and the right lung was 525.0g(normal range; $525 \pm 142.5$ g)(7). The storage of with pleural effusion was admitted in the pleural cavity, 7.0ml on the left side, and 36.0 ml on the right side. Diatom method : A small number of diatoms was detected in the lung.

## ENDOCRINOLOGICAL FINDINGS

Table 1 shows the concentrations of endocrine hormones in serum or urine(9). Both T3 and T4 thyroid-hormones had fallen below the reference values. There was a slight decrease in 17-KS. There were no clearly anomalous values observed in adrenal hormones or their metabolites, such as 17-OHCS, cortisol and aldosterone.

Table 1. Quantitative endocrinological analysis of hormones

hormones	Concentration	(normal range)
T 3	0.5	(0.8-1.8 ng/ml)
T 4	2.5	(4.6-12.6 $\mu$ g/dl)
17-KS	3.9	(4.6-18 mg/l)
17-OHCS	4.0	(3.4-12 mg /l)
Cortisol	10.3	(4.0-18.3 $\mu$ g/dl)
Aldosterone	150	(35.7-240 pg/ml)

## PATHOLOGICAL FINDINGS

The adrenal cortices were markedly atrophic, especially in the zona fasciculata (Fig. 3).

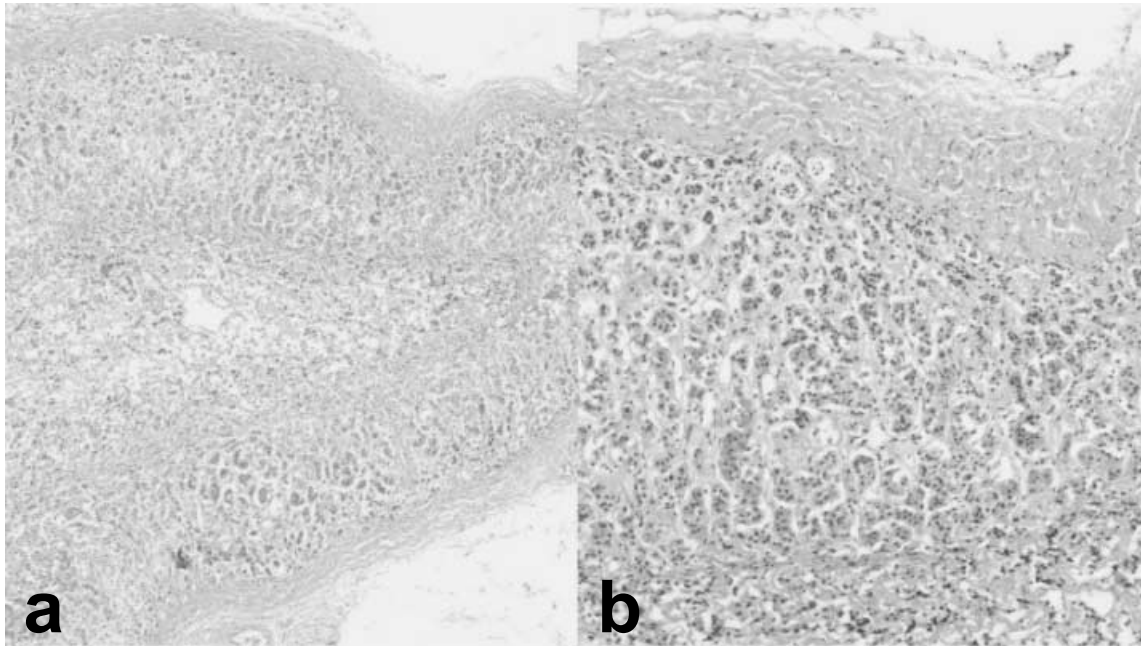


Fig. 3 . Atrophy of the adrenal cortex (HE stain, a ;  $\times 4$ , b ;  $\times 10$ )

In the thyroid gland, isolated minute follicles, follicles lacking colloid, and numerous lymphoid follicles were observed.

In the testis, there was marked thickening and hyalinization of the tubular membranes, absence of spermatogenesis, rare Sertoli cells, and clusters of intestinal cells (Fig. 4). These changes presented a typical image of shrunken testis. Moreover, both efferent ductules of the testes and ducts of the epididymes had shrunk in the vas deferens.

The lungs were edematous and emphysematous, as well as congested.

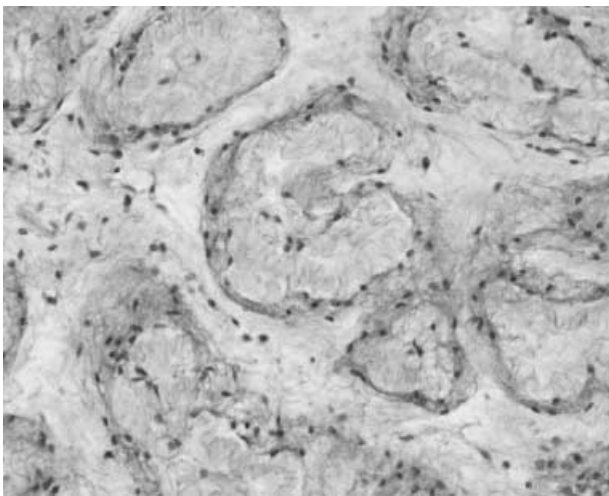


Fig. 4 . Severe atrophy of testis (HE stain,  $\times 20$ )

## DISCUSSION

The cadaver was found having put the upper half of the body on the shore in the river, and having gone out of water. From this finding situation, his cause of death was not able to be judged easily to be a death from drowning. Moreover, the wounds on his body were not considered enough to be the cause of death, too. Then, he was anatomized for the elucidation of cause of death.

Autopsy demonstrated that the pituitary had been extracted by hypophysectomy (Fig. 1). Post operatively, the subject regularly attended the hospital to receive medical treatment (details uncertain), he had stopped attending the hospital and had not received medical treatment for several years. Therefore, endocrinological disorder due to hypopituitarism was suspected to be involved in the cause of death. On postmortem biochemical examination, hormones are comparatively stable, and postmortem examination of the hormone concentration is effective for diagnosis (9). Then, not only autopsy and pathological examination but also postmortem endocrinological inspection was executed for the diagnosis.

In the thyroid gland, the appearance of isolated minute thyroid follicles and lymphoid follicles were observed, and both T3 and T4 were decreased. Both adrenal glands had severely thinned, and the weight was also severely decreased, adrenal cortices had markedly shrunk. Atrophy of the testes was also observed and pathologically the tubular membranes were thickened and hyalinized. The weight of the thyroid and testis

was almost within the normal weight range. However, it was considered that these organs had become dysfunctional because pathological damage was observed in both organs. It was considered that hypopituitarism had been caused by hypophysectomy. In addition, it was considered that secondary and chronic hypothyroidism, sex hormone deficiency (hypogonadism), and adrenal insufficiency were present.

The cadaver had fallen into the river from about 1 m in height, and sustained numerous small wounds such as abrasions and subcutaneous hemorrhage. There was no trauma observed in the brain or other internal organs. Therefore, trauma was not considered directly related to the cause of death. Moreover, it was suspected that he developed hypothermia before death because the color of the left cardiac blood was redder than that on the right side. However, there were no other autopsy findings related to hypothermia (10).

The left lung weighted 495.0g, and the right lung weighted 525.0g. Pleural effusion in the pleural cavity was 7.0 ml on the left side, and 36.0 ml on the right side. Aqueous pulmonary edema was not considered to be severe (7). However, diatom was detected in the lungs. So, his " direct cause of death " was thought to be death from drowning based on the findings described above.

On endocrinological examination, thyroid function,

based on T3 and T4 findings, had decreased, while adrenocortical function, based on cortisol in blood and 17-OHCS in urine, metabolites of cortisol, was within the standard range. It was considered that the unbridgeable gulf in the examination results between thyroid and adrenocortical function reflected the physiological condition of this subject. Glucocorticoid (cortisol) is known as an anti- stress hormone, because cortisol defends against stress. Cortisol synthesis and secretion increase correspond to stress. That is, we suspect that the adrenocortical hormone was secreted into the blood as a result of various stresses due to wounds and hypothermia, causing the concentration to reach in the standard range. However, it was suspected that sufficient hormone might not be secreted due to chronic adrenal insufficiency (4, 5).

This insufficient cortisol causes the decrease in the stress resistance, and might influence his cause of death, the death by drowning. Moreover, as hypothyroidism decreases thermogenesis, he might have fallen into hypothermia easily. In addition, because both adrenocortical insufficiency and hypothyroidism caused the hypoglycemia, he might have fallen into the loss of consciousness before his death (2, 3, 6).

Therefore, it was considered that he had died by drowning, in relation to the adrenocortical insufficiency and panhypopituitarism (Fig. 5).

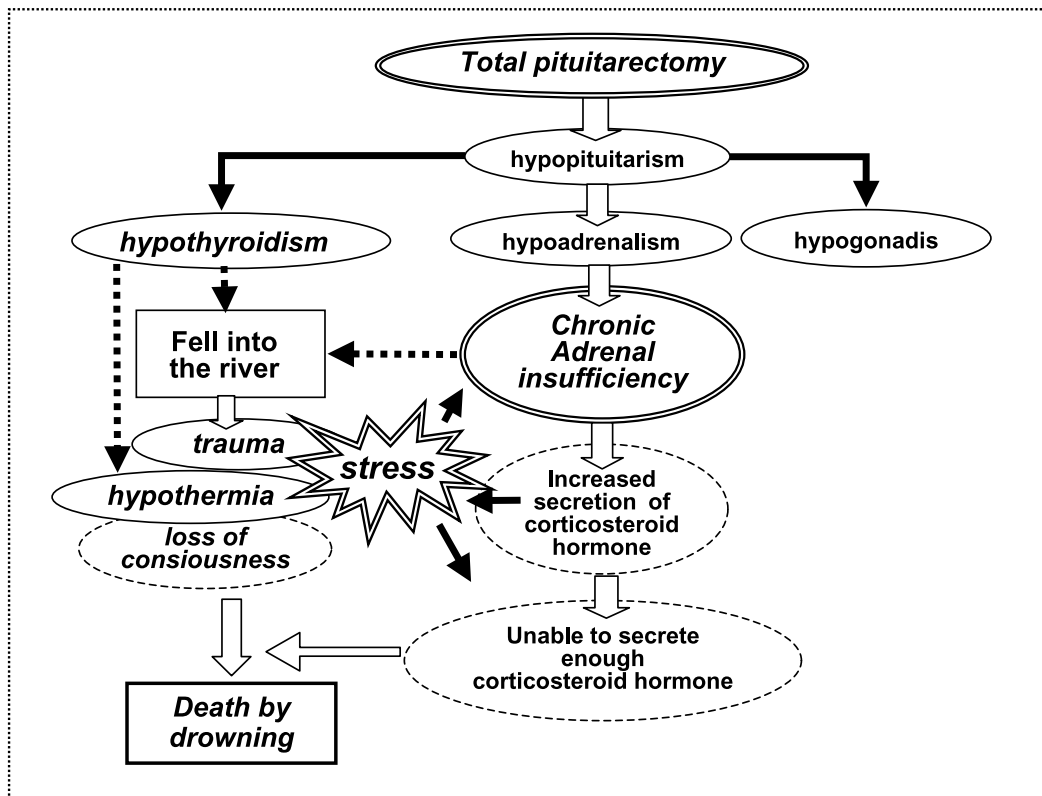


Fig. 5 . Summary of the cause of death

## ACKNOWLEDGEMENT

This work was partly supported by a Grant-in-Aid for Scientific Research from the Ministry of Education, Science, Sports and Culture of Japan No. 15390215.

## REFERENCES

1. Kohler PO : Disease of the hypothalamus and anterior pituitary. In : Harrison's principles of internal medicine;9th ed, McGraw-Hill, Auckland, 1981, pp. 1667-84
2. Baxter JD : Adrenocortical hypofunction. In : Cecil textbook of medicine;17th ed, W. B. Saunders, Philadelphia, 1985, pp. 1310-3
3. Williams GH, Duhy RG, Thorn GW:Hypofunction of adrenal cortex. In : Harrison's principles of internal medicine;9th ed, McGraw-Hill, Auckland, 1981, pp. 1729-33
4. de Herder WW, van der Lely AJ: Addisonian crisis and relative adrenal failure. Rev Endocr Metab Disord 4(2) : 143-7, 2003
5. Kubo S, Kitamura O, Orihara Y, Tsuda R, Hirose W, Nakasono I : Isolated adrenocorticotrophic hormone deficiency:An autopsy case of adrenal crisis. Am J Forensic Med Pathol 18(2) : 202-5, 1997
6. Ingbar SH, Woeber KA : Disease of the thyroid. In: Harrison's principles of internal medicine ; 9 th ed, McGraw-Hill, Auckland, 1981, pp. 1694-711
7. Investigation committee of medico-legal society of Japan. Reports on medico-legal data from massive investigation performed by the medico-legal society of Japan. Weight and size of internal organs of normal Japanese today. Jpn J Leg Med 46(3): 225-35, 1992
8. Hieda G, Mori M : Testis and epididymidis. In: Anatomy ; 11 th ed, Kanehara-Shuttupan, Tokyo, 1985, pp. 302
9. Coe JI:Postmortem chemistry update;emphasis on forensic application. Am J Forensic Med Pathol 14(2) : 91-117, 1993
10. Ishigami A, Gotohda T, Kitamura O, Tokunaga I, Kubo S : One autopsy case of fatal hypothermia in Tokushima. Shikoku Acta Medica 56(4) (in Japanese) : 145-9, 2000