

ORIGINAL

Effects of thrombus suction therapy on myocardial blood flow disorders in males with acute inferior myocardial infarction

Yuji Ozaki^{1,3}, Masahiro Nomura², Toru Nakayama¹, Tatsuro Ogata³, Kimiko Nakayasu², Yutaka Nakaya⁴, and Susumu Ito³

¹Department of Internal Medicine, Kochi Red Cross Hospital; ²Faculty of Integrated Art and Sciences, Department of Human and Social Sciences, The University of Tokushima ; ³Department of Digestive and Cardiovascular Medicine, and ⁴Department of Nutrition and Metabolism, Institute of Health Biosciences, The University of Tokushima Graduate School, Tokushima, Japan

Abstract : Several studies have reported that the use of a distal protection device decreases the incidence of slow-flow and/or no-reflow in patients with myocardial infarctions. In the present study, we investigated the influence of a RESCUE/Thrombuster system and a PercuSurge GuardWire catheter on coronary microcirculation disorders in patients with acute myocardial infarction using the natriuretic polypeptide (ANP), the brain natriuretic peptide (BNP), and ^{99m}Tc-tetrofosmin myocardial scintigraphy (TF). The group consisted of a 77 patients with initial inferior myocardial infarction who had undergone emergency coronary angioplasty. The patients were randomly divided into : Group D (n=28), in which a direct stent alone was inserted, Group R/T (n=25), in which a stent was inserted after RESCUE system or a Thrombuster system was performed, and Group P (n=24), in which a stent was inserted after thrombus suction using a PercuSurge GuardWire catheter. Patients with coronary slow-flow/no-reflow were 3, 2 and 0 cases in Group D, Group R / T and Group P, respectively. In the present study, patients with good-reflow were enrolled in order to investigate the coronary microcirculation disorder in patients with visually similar coronary blood flow obtained in coronary angiography after percutaneous coronary reperfusion therapy. TF myocardial scintigraphy was performed 10 ± 3 days after admission. Bull's eye images were divided into 8 sections, and each section was evaluated in 4 grades. The grade of each segment was regarded as the defect score. The results were compared with the database prepared based on bull's eye maps from 50 healthy adults in our hospital, and count areas of - 2 × SD (standard deviation) or less were calculated as the extent score (%), reflecting the area in which myocardial blood flow was decreased. The extent and severity scores in Groups P and R/T were significantly lower than those in Group D. Coronary angiography at the chronic stage (6 months after surgery) showed the patency of the responsible vascular lesion in all patients. However, the ANP, BNP, cardiac index, and pulmonary capillary wedge pressure (PCWP) were significantly improved in Groups R/T and P, compared to Group D (p<0.01). These results suggest that the use of a RESCUE/Thrombuster system and a PercuSurge GuardWire catheter system in patients with acute inferior wall infarction improves coronary microcirculation disorders and acute- to chronic-phase cardiac function. *J. Med. Invest.* 53 : 167-173, February, 2006

Keywords : acute myocardial infarction; coronary microcirculation; thrombus suction therapy, TF myocardial scintigraphy

Received for publication October 20, 2005 ; accepted January 23, 2006.

Address correspondence and reprint requests to Yuji Ozaki,

M.D., Department of Digestive and Cardiovascular Medicine, Institute of Health Biosciences, The University of Tokushima Graduate School, Tokushima, Japan and Fax : +81-88-633-9235.

INTRODUCTION

A thrombus of the coronary artery exists in many lesions in acute myocardial infarctions, and a thromboembolism may occur in a distal area during treatment of the infarction. A peripheral embolism or no-reflow phenomena also sometimes occurs (1-7). Therefore, the presence of a thrombus in the coronary artery is important with respect to myocardial salvage (8-10). In addition, in many patients with marked thrombosis, treatment by catheter intervention is difficult. Several studies have reported that thrombus suction therapy decreases the incidence of slow flow or no-reflow of the coronary artery (11-13), but the question of whether coronary microcirculation disorders improve after thrombus suction therapy in patients in whom good-reflow of Thrombolysis in Myocardial Infarction (TIMI) grade 3 has been achieved, using myocardial scintigraphy has not been investigated.

A purpose of the present study is to investigate the coronary microcirculation disorder in patients with visually similar coronary blood flow obtained in coronary angiography after percutaneous coronary reperfusion therapy. Therefore, the issue of whether thrombus suction therapy improves cardiac load and coronary microcirculation disorders in males with acute inferior myocardial infarction was studied, using the atrial natriuretic polypeptide (ANP), the brain natriuretic peptide (BNP), and nuclear medical parameters, such as the extent and severity scores of ^{99m}Tc -tetrofosmin myocardial scintigraphy (TF).

PATIENTS AND METHODS

1) Patients

The study group consisted of 77 males with an initial acute inferior myocardial infarction (age: 65.5 ± 12.1 years) in whom reperfusion therapy was successful at the Emergency Center of the Kochi Red Cross Hospital, Kochi City, Japan, between September 2000 and December 2004.

We employed the following criteria for acute myocardial infarction: chest pain persisting for 30 minutes or more; more than 1-mm increases in ST at 2 or more leads on standard 12-lead electrocardiograms; a plasma creatinine (CK) level more than 2 times higher than the normal value; abnormalities in left ventricular wall motion on echocardiography; and an interval of 6 hours or less from

the development of chest pain. Patients who had undergone fibrinolytic treatment with tissue plasminogen activator (t-PA) or urokinase before admission, those with cardiogenic shock, and those in whom aspirin or ticlopidine was contraindicated were excluded from the study. Patients with coronary no-reflow/slow flow and chronic-stage restenosis were excluded. Written informed consent was obtained from all patients before the study.

Each of the subjects were assigned to one of three groups by the envelope method with respect to the procedures for coronary reperfusion therapy: Group D, in which only a direct stent was used ($n=28$), Group R/T, in which a stent was inserted after thrombus suction using a RESCUE system (Boston Scientific Scimed, Inc., Maple Grove, Minnesota, USA) or a Thrombuster system (Kaneka Medix Corp, Japan) ($n=25$), or Group P, in which a stent was inserted after thrombus suction using a PercuSurge GuardWire catheter (Medtronic AVE, Santa Rosa, California, USA) ($n=24$). A MultiLink Trister[®] stent was used in all patients. Restenosis was not observed for 6 months after reperfusion, except in 12 cases.

2) Coronary angiography and percutaneous coronary reperfusion therapy

Prior to coronary reperfusion therapy, 162 mg of aspirin and 200 mg of ticlopidine hydrochloride were administered, along with an intra-arterial administration of heparin at 10,000 units, as antiplatelet therapy.

Intervention for the coronary artery responsible for myocardial infarction was performed by puncture of the femoral artery using a 7Fr guiding catheter. Coronary angiography was performed using a MODEL CAS 210-A device (TOSHIBA Co., Ltd., Japan) and a polygraph (RMC-2000, NIHON KOHDEN Co., Ltd., Tokyo, Japan).

Three or more cardiologists evaluated the success or failure of the acute-stage coronary reperfusion; in patients in whom the lesion was evaluated as good-reflow on coronary angiography, reperfusion was considered successful. Similarly, 3 or more cardiologists evaluated chronic-stage restenosis; patients with 50% or more stenosis on coronary angiography according to the classification described by the American Heart Association were regarded as having restenosis. For the analysis of coronary angiography findings, the diameter and minimum lumen diameter (MLD) of the infarct-related artery was measured using the direct cali-

per method before and after reperfusion therapy and 6 months after the onset of acute myocardial infarction.

For antiplatelet therapy after coronary reperfusion therapy, heparin at 20,000 units/day was administered intra-venously, and aspirin at 162 mg/day and ticlopidine hydrochloride at 200 mg/day were orally administered in each group.

3) Measurement of ANP and BNP

We measured the levels of ANP and BNP immediately after reperfusion and 6 months after reperfusion. Venous blood through the cubital vein was collected after the end of percutaneous transluminal coronary angioplasty (PTCA). In the chronic stage, blood was collected through the cubital vein after fasting early in the morning on the day before catheterization. ANP was measured by a radioimmunoassay (RIA), and BNP by a sandwich immunoradiometric assay (IRMA).

4) Evaluation of hemodynamics using left ventriculography and a Swan-Gantz catheter

Left ventriculography was performed 1 and 6 months after reperfusion therapy. The left ventricular end-systolic volume index (ESVI), end-diastolic volume index (EDVI), and ejection fraction (EF) were obtained from 30-degree right anterior oblique left ventriculograms according to Simpson's method. Using a Swan-Ganz catheter, we evaluated the hemodynamics immediately after reperfusion therapy and 6 months after the onset of myocardial infarction based on heart rate (HR), pulmonary capillary wedge pressure (PCWP), pulmonary arterial pressure (PAP), right ventricular pressure, right atrial pressure, cardiac output (CO), cardiac index (CI), and left ventricular end-diastolic pressure (LVEDP).

5) Myocardial scintigraphy with ^{99m}Tc-tetrofosmin

Myocardial scintigraphy with ^{99m}Tc-tetrofosmin was performed on all patients 10 ± 3 days after reperfusion therapy, at rest after fasting. Single photon emission computed tomography (SPECT) was performed 15 minutes after an intravenous injection of 600 MBq of ^{99m}Tc-tetrofosmin through the cubital vein. A 3-head rotating gamma camera (GCA, 7200 A, Toshiba, Japan) with a low-energy all-purpose collimator was used for the imaging. The collection time was 30 seconds per frame, and 360-degree data were taken by 72 image stops (5° step; 24 directions × 3 heads) for SPECT imaging. A data

processing super computer (GMS, 5000A, Toshiba, Japan) was used for analysis of the SPECT data.

From a bull's eye map, an area counting 2 × standard deviation (SD) or less in comparison to a database prepared from 50 normal adults in our hospital (25 men, 25 women) was calculated. The area of reduced ^{99m}Tc-tetrofosmin uptake (extent score) and severity of deficiency (severity score) were calculated. That is, the extent score (%) and severity score reflect an area in which myocardial blood flow is decreased using a bull's eye map prepared from SPECT transverse images.

6) Statistical analysis

All values are expressed as the mean ± standard deviation (SD), and statistical analyses were performed using StatView 5.0 software (SAS Institute, Inc., U.S.A.). The values were compared between two groups using an unpaired t-test and chi square test. P < 0.05 was regarded as significant.

RESULTS

1) Patient characteristics

The incidence of coronary circulation disorder in each group was shown in Table 1. Patients with coronary no-reflow/slow-flow were 3, 2 and 0 cases in Group D, Group R/T, and Group P, respectively. The incidences of no-reflow/slow-flow in Group D and Group R/T were significantly higher than Group P (p < 0.05).

Table 2 shows the characteristics of coronary good-flow patients in the present study. There were no significant differences in age, number of affected vessels, presence of concurrent diseases, such as ischemic heart disease, hypertension, and diabetes, lipid levels, fasting blood sugar, blood pressure, combination therapy with ACE inhibitors, interval to obtaining peak CK, post reference vessel diameter, or post minimal diameter among Group D, Group R/T, and Group P. However, the

Table 1. Incidence of coronary circulation disorder in each group

	Group D	Group R/T	Group P
no-reflow/slow flow (cases)	3*	2*	0
good-reflow (cases)	20	20	20
restenosis 6 months after reperfusion (cases)	5	3	4

*p < 0.05 vs Group P

Table 2. Patient characteristics

	D group	R/T group	P group
age (yrs)	66 ± 13	68 ± 9	60 ± 18
number of lesion branch	1.8 ± 0.8	1.5 ± 0.5	1.7 ± 0.8
ischemic heart disease	4 / 20 (20%)	3 / 20 (15%)	4 / 20 (20%)
hypertension	10/20 (50%)	9 / 20 (45%)	10/20 (50%)
smoking	13/20 (65%)	10/20 (50%)	11/20 (55%)
diabetes mellitus	8 / 20 (40%)	9 / 20 (45%)	9 / 20 (45%)
hyperlipidemia	13/20 (65%)	11/20 (55%)	13/20 (65%)
T-cho(mg/dl)	182 ± 32	190 ± 49	187 ± 30
TG(mg/dl)	139 ± 83	115 ± 62	142 ± 100
HDL-cho(mg/dl)	48 ± 8	53 ± 12	44 ± 6
FBS (mg/dl)	125 ± 32	157 ± 84	132 ± 55
ACE-Inhibitor	15/20 (75%)	14/20 (70%)	14/20 (70%)
sBP(mmHg)	115 ± 22	123 ± 32	118 ± 18
dBp(mmHg)	75 ± 15	72 ± 12	76 ± 8
peak CK (IU/l)	3151 ± 2467	1956 ± 2036*	2010 ± 1278*
time to peak CK (hrs)	14 ± 6	12 ± 6	13 ± 6
Post ref. (acute phase)	3.4 ± 0.4	3.3 ± 0.3	3.6 ± 0.3
Post MLD (acute phase)	3.1 ± 0.2	3.2 ± 0.2	3.3 ± 0.3

* p<0.01 difference between D group.

T-cho, total cholesterol ; T-G, triglyceride ; HDL-cho, high-density lipoprotein cholesterol ; FBS, fasting blood sugar ; ACE, angiotensin converting enzyme ; sBP, systolic blood pressure ; dBp, diastolic blood pressure ; CK, creatine kinase ; post ref., post reference vessel diameter ; post MLD, post minimal lumen diameter

peak CK levels in Group P and Group R/T were significantly lower than that in Group D (p<0.01).

2) Comparison of ANP and BNP concentrations on admission and six months after reperfusion therapy

Table 3 shows the serum levels of ANP and BNP on admission (at the onset of acute myocardial infarction) and 6 months after reperfusion therapy. There were no significant differences in the level of ANP on admission among Groups D, R/T, and P. However, 6 months after admission, the levels of ANP in Group P and Group R/T were significantly lower than that in Group D (p<0.05).

The level of BNP on admission in Group R/T was significantly higher than the values in Groups

D and P (p<0.01). However, 6 months after admission, the levels of BNP in Groups P and R/T were significantly lower than that in Group D (p<0.01).

3) Myocardial scintigraphy with ^{99m}Tc-tetrofosmin in Groups D, P, and R/T.

Fig. 1 shows an extent score map for a 64-year-old subject in Group D. In this patient, reperfusion therapy with a stent was performed, regarding the right coronary artery #3 as a responsible coronary lesion. The area of the defect involved the inferior wall, the anterior wall septum, and the posterior lateral wall. His extent score was 49.2, and the severity score was 34.4.

Fig. 2 shows an extent score map for a 72-year-old subjects in Group P. In this patient, distal protection with a PercuSurge GuardWire catheter and reperfusion therapy were performed, regarding the right coronary artery #3 as a responsible coronary lesion. The defect area involved the inferior wall and the anterior wall septum. His extent score was 23.5, and the severity score was 12.5.

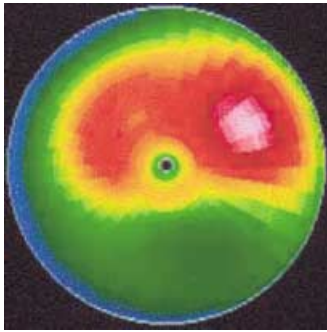
Fig. 3 shows an extent score map for a 68-year-old subject in Group R/T. In this patient, distal protection with the RESCUE system and reperfusion therapy were performed, regarding the right coronary artery #3 as a responsible coronary lesion. The defect area involved the inferior wall. His extent score was 30.6, and his severity score

Table 3. Serum levels of ANP and BNP on admission and 6 months after reperfusion

	D group	R/T group	P group
ANP (pg/ml)			
admission	85 ± 72	86 ± 118	78 ± 64
6 months	53 ± 30	25 ± 15**	30 ± 28**
BNP (pg/ml)			
admission	58 ± 59	121 ± 191*	65 ± 95
6 months	133 ± 127	62 ± 50*	82 ± 76*

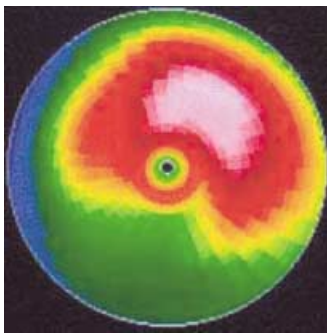
*p<0.01, **p<0.05 difference between D group.

ANP, A type natriuretic peptide; BNP, B type natriuretic peptide



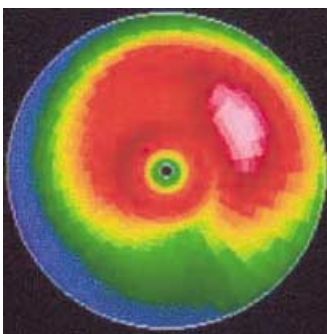
Direct stent
64y.o.#3
extent score 49.2
severity score 34.4

Fig. 1 . Extent score map in a 64-year-old man in Group D.



PercuSurge
72y.o.#3
extent score 23.5
severity score 12.5

Fig. 2 . Extent score map in a 72-year-old man in Group P.



RESCUE
68y.o.#3
extent score 30.6
severity score 15.6

Fig. 3 . Extent score map in a 68-year-old man in Group R/T.

was 15.6.

4) Comparison of scintigraphic scores among Groups D, P, and R/T.

As shown in Table 4, the extent and severity scores were compared among Groups D, P, and R/T. The extent and severity scores in Groups P and R/T were significantly lower than those in Group D.

5) Pressure study and ejection fraction in the chronic stage

Table 5 shows the pressure study and EF on heart catheterization 6 months after the onset of myocardial infarction. No significant differences were found in PCWP, mean PAP, CI, EDVI, or EF among the 3 groups.

Table 4. Comparison of scintigraphic scores among D, R/T and P groups

	D group	R/T group	P group
extent score	42 ± 9	30 ± 6*	31 ± 5**
severity score	36 ± 7	25 ± 3*	26 ± 4*

*p<0.01, **p<0.05 difference between D group.

Table 5. Pressure study and ejection fraction on heart catheterization 6 months after the onset of myocardial infarction

	D group	P group	R group
PCW(mmHg) (6 months)	18 ± 7	16 ± 3	18 ± 8
mPA(mmHg) (6 months)	38 ± 12	34 ± 2	36 ± 16
CI(l/min/ml) (6 months)	3.0 ± 1.0	2.9 ± 0.8	2.6 ± 0.6
EDVI(ml/m ²) (6 months)	77 ± 32	82 ± 18	80 ± 20
EF(%) (6 months)	50 ± 8	54 ± 11	52 ± 12

PCWP, pulmonary capillary wedge pressure ; mPA, mean pulmonary artery pressure; C.I., cardiac index; EDVI, end-diastolic volume index ; EF, ejection fraction

DISCUSSION

It has been reported that thrombus suction therapy decreases the incidence of slow flow or no-reflow during coronary artery perfusion therapy in patients with acute myocardial infarctions (14). However, the question of whether thrombus suction therapy improves coronary microcirculation disorders by myocardial scintigraphy in patients in whom good-reflow is achieved after thrombus suction therapy has not been investigated. In the present study, there was no difference between Groups D and R/T in the incidence of slow-flow/no-reflow, but the improvement of microcirculation at the chronic stage in good-reflow patient of Group R/T was more frequent than that of Group D. Moreover, thrombus suction therapy with a RESCUE system, a Thrombuster system, or a PercuSurge GuardWire catheter significantly improved ANP, BNP, and peak CK levels and myocardial scintigraphic parameters in comparison to direct stenting, indicating the usefulness of these therapies on myocardial coronary microcirculation disorders.

The use of direct stent therapy has decreased in treatment of acute myocardial infarctions. However, it continues to be performed in some hospi-

tals. We previously reported differences in cardiac function of the chronic stage between POBA and stent therapy in acute myocardial infarctions (15). Therefore, patients who had received direct stent therapy were enrolled in this study in order to standardize the control subjects.

For percutaneous transluminal coronary angioplasty for acute myocardial infarction, TIMI grade 3 blood flow in the early stage is required, for to a good prognosis (16-18). However, coronary reperfusion at the site of the lesion, where many thrombi are present, causes peripheral embolism related to rupture of the thrombus or the no-reflow phenomena (19). According to previous reports, the combination of distal protection with a balloon and thrombus suction therapy in patients with acute myocardial infarction resulted in high-grade TIMI blood flow, suggesting the usefulness of this combination therapy in marked thrombotic lesions (11-13).

In the present study, myocardial scintigraphic findings as well as the ANP and BNP levels were significantly improved in patients in whom a PercuSurge GuardWire catheter or a RESCUE system/Thrombuster system was employed as a protective device for preventing peripheral embolisms, even among patients with good-reflow. Thus, among patients in whom direct stent therapy without distal protection achieved TIMI grade 3 blood flow, and coronary angiography confirmed good circulatory reconstruction, a significant improvement was achieved in patients in whom thrombus suction therapy with a RESCUE system/Thrombuster system or a PercuSurge GuardWire catheter was performed, suggesting that the combination of distal protection with a balloon and thrombus suction therapy is effective regardless of the presence of a visually recognizable thrombus.

However, there were no significant differences in cardiac function (EF) among Groups D, R/T, and P 6 months after the onset of the myocardial infarction. Possible reasons for the discrepancy between EF and ANP/BNP levels are as follows. First, EF values were almost normal or slightly decreased in all patients because of successful reperfusion therapy, second, ANP and BNP are more sensitive markers of cardiac function than EF, third, ANP and BNP affect the left ventricular diastolic function.

Significant changes were found in myocardial scintigraphic findings and ANP, BNP levels in patients in whom visually high-grade TIMI blood

flow was achieved. The following mechanism is assumed. Platelets are usually activated after percutaneous transluminal coronary angioplasty (20). However, the removal of a peripheral microthrombus using a distal protection device inhibits platelet activation enhancement after percutaneous transluminal coronary angioplasty.

In the present study, we investigated only male with inferior myocardial infarction, because myocardial infarction is less frequent in woman, and because most women with a myocardial infarction are older and suffer a severe infarction. Because of these gender-related differences, the study was limited to males. Furthermore, we focused on acute inferior myocardial infarction, because a thrombosis is involved in right coronary infarction in many cases (21). In the future, left coronary lesions should be investigated.

In conclusion, it has been recently reported that the use of drug-eluting stents is associated with the reduction of coronary artery restenosis compared with the bare thin-strut stent (22-24). These results suggest that thrombus suction therapy prior to stenting may improve coronary microcirculation disorders in the acute to chronic stages in males with inferior myocardial infarction.

REFERENCES

1. Kragel AH, Gertz SD, Roberts WC: Morphologic comparison of frequency and types of acute lesions in the major epicardial coronary arteries in unstable angina pectoris, sudden coronary death and acute myocardial infarction. *Am Coll Cardiol* 18 : 801-808, 1991
2. Fuster V, Badimon L, Badimon JJ, Chesebro JH: The pathogenesis of coronary artery disease and the acute coronary syndromes (1). *N Engl J Med* 326 : 242-250, 1992
3. Dorros G, Cowley MJ, Simpson J, Bentivoglio LG, Block PC, Bourassa M, Detre K, Gosselin AJ, Gruntzig AR, Kelsey SF, Kent KM, Mock MB, Mullin SM, Myler RK, Passamani ER, Stertz SH, Williams DO: Percutaneous transluminal coronary angioplasty: report of complications from the National Heart, Lung, and Blood Institute PTCA Registry. *Circulation* 67 : 723-730, 1983
4. Grube E, Gerckens U, Yeung AC, Rowold S, Kirchhof N, Sedgewick J, Yadav JS, Stertz S: Prevention of distal embolization during

- coronary angioplasty in saphenous vein grafts and native vessels using porous filter protection. *Circulation* 104 : 2436-2441, 2001
5. Braunwald E : Unstable angina. A classification: *Circulation* 80 : 410-414, 1989
 6. Topol EJ, Yadav JS : Recognition of the importance of embolization in atherosclerotic vascular disease. *Circulation* 101 : 570-580, 2000
 7. Erbel R, Heusch G : Coronary microembolization. *J Am Coll Cardiol* 36 : 22-24, 2000
 8. Kloner RA, Ganote CE, Jennings RB : The "no-reflow" phenomenon after temporary coronary occlusion in the dog. *J Clin Invest* 54 : 1496-1508, 1974
 9. Rezkalla SH, Kloner RA : No-reflow phenomenon. *Circulation* 105 : 656-662, 2002
 10. Reffelmann T, Kloner RA : The "no-reflow" phenomenon : basic science and clinical correlates. *Heart* 87 : 162-168, 2002
 11. Yip HK, Wu CJ, Chang HW, Fang CY, Yang CH, Chen SM, Hung WC, Chen CJ, Cheng CI, Hsieh YK : Effect of the PercuSurge GuardWire device on the integrity of microvasculature and clinical outcomes during primary transradial coronary intervention in acute myocardial infarction. *Am J Cardiol* 92 : 1331-1335, 2003
 12. Rogers C, Huynh R, Seifert PA, Chevalier B, Schofer J, Edelman ER, Toegel G, Kuchela A, Woupio A, Kuntz RE, Macon ND : Embolic protection with filtering or occlusion balloons during saphenous vein graft stenting retrieves identical volumes and sizes of particulate debris. *Circulation* 109 : 1735-1740, 2004
 13. Bonderman D, Teml A, Jakowitsch J, Adlbrecht C, Gyongyosi M, Sperker W, Lass H, Mosgoeller W, Glogar DH, Probst P, Maurer G, Nemerson Y, Lang IM : Coronary no-reflow is caused by shedding of active tissue factor from dissected atherosclerotic plaque. *Blood* 99 : 2794-2800, 2002
 14. Stone GW, Webb J, Cox DA, Brodie BR, Qureshi M, Kalynych A, Turco M, Schultheiss HP, Dulas D, Rutherford BD, Antoniucci D, Krucoff MW, Gibbons RJ, Jones D, Lansky AJ, Mehran R : Enhanced Myocardial Efficacy and Recovery by Aspiration of Liberated Debris (EMERALD) Investigators. Distal microcirculatory protection during percutaneous coronary intervention in acute ST-segment elevation myocardial infarction : a randomized controlled trial. *JAMA* 293 : 1063-1072, 2005
 15. Nakayama T, Nomura M, Fujinaga H, Ikefuji H, Kimura M, Chikamori K, Nakaya Y, Ito S : Does coronary artery stenting for acute myocardial infarction improve left ventricular overloading at the chronic stage? *Jpn Heart J* 45 : 217-29, 2004
 16. An international randomized trial comparing four thrombolytic strategies for acute myocardial infarction. The GUSTO investigators. *N Engl J Med* 329 : 673-682, 1993
 17. Lee KL, Woodlief LH, Topol EJ, Weaver WD, Betriu A, Col J, Simoons M, Aylward P, Van de Werf F, Califf RM : Predictors of 30-day mortality in the era of reperfusion for acute myocardial infarction. Results from an international trial of 41,021 patients. GUSTO-I Investigators. *Circulation* 91 : 1659-1668, 1995
 18. ISIS-2 (Second International Study of Infarct Survival) Collaborative Group. Randomised trial of intravenous streptokinase, oral aspirin, both, or neither among 17,187 cases of suspected acute myocardial infarction. *Lancet* 2 (8607) : 349-360, 1988
 19. Mawson JB, Gavin JB, Herdson PB : A comparison of the effects of ischemia and of selective occlusion of capillaries, pre-capillaries and terminal arterioles on coronary reperfusion. *Pathology* 14 : 369-373, 1982
 20. Topol EJ, Byzova TV, Plow EF : Platelet GPIIb-IIIa blockers. *Lancet* 353(9148) : 227-231, 1999
 21. Nagata Y, Usuda K, Uchiyama A, Uchikoshi M, Sekiguchi Y, Kato H, Miwa A, Ishikawa T : Characteristics of the pathological images of coronary artery thrombi according to the infarct-related coronary artery in acute myocardial infarction : *Circ J* 68 : 308-314, 2004
 22. Pache J, Dibra A, Mehilli J, Dirschinger J, Schomig A, Kastrati A : Drug-eluting stents compared with thin-strut bare stents for the reduction of restenosis : a prospective, randomized trial. *Eur Heart J*, 2005 Feb 28 ; [Epub ahead of print]
 23. Katritsis DG, Karvouni E, Ioannidis JP : Meta-analysis comparing drug-eluting stents with bare metal stents. *Am J Cardiol* 95 : 640-3, 2005
 24. Chieffo A, Stankovic G, Bonizzoni E, Tsagalou E, Iakovou I, Montorfano M, Airoidi F, Michev I, Sangiorgi MG, Carlino M, Vitrella G, Colombo A : Early and mid-term results of drug-eluting stent implantation in unprotected left main. *Circulation* 111 : 791-5, 2005