

CASE REPORT

Photodynamic therapy for submucosal tumor of the central bronchus

Kazuya Kondo, Takanori Miyoshi, Hiromitsu Takizawa, Koichiro Kenzaki, Shoji Sakiyama, and Akira Tangoku

Department of Oncological and Regenerative Surgery, Institute of Health Biosciences, The University of Tokushima Graduate School, Tokushima, Japan

Abstract : A 75-year-old man was referred to our hospital because of the emphysema and tumor of the right intermediate bronchus. Thoracic CT scan and bronchoscopic examination demonstrated a spherical tumor of the right intermediate bronchus covering a normal mucosa. The biopsy specimen obtained from this tumor was histologically diagnosed as "glandular type of adenocarcinoma in the bronchus". Surgical treatment was not feasible because of poor pulmonary function. Therefore, the patient underwent Photodynamic therapy (PDT) using porfimer sodium (Photofrin) and an excimer dye laser. After 4 months, the tumor disappeared and there has been no recurrence for 3 years 3 months. PDT can affect a submucosal tumor of the central airway, and is safe for patients with poor pulmonary function. Our report recommends that PDT should be applied not only to early lung cancer but also submucosal tumor of the central bronchus. *J. Med. Invest.* 52 : 208-211, August, 2005

Keywords : photodynamic therapy, lung cancer, submucosal tumor, central airway

INTRODUCTION

Photodynamic therapy (PDT) utilizes photosensitizing agents that are selectively retained within tumor cells. The agents remain inactive until exposed to light of the proper wavelength. When activated by light, these compounds generate toxic oxygen radicals that promote tumor necrosis (1). In Japan, PDT has frequently been used for early lung cancer of the central airway (2). In Europe and U.S.A, it has frequently been used for advanced lung cancer with airway obstruction, although Neodymium-doped Yttrium Aluminum Garnet (Nd-YAG) laser is used for this procedure in Japan (3, 4). Recently, several reports demonstrated that bronchial disobliteration achieved with PDT is equally good but has a longer lasting

effect compared to that with Nd-YAG laser (5, 6). And it can safely be applied to obstructive tumors.

In this paper, we performed PDT for a glandular type of adenocarcinoma of the central bronchus which showed submucosal growth in the bronchus. PDT was very effective for this tumor.

CASE REPORT

A 75-year-old man was referred to our hospital because of the emphysema and tumor of the right intermediate bronchus. He was diagnosed as having emphysema at 72 years old, and was receiving home oxygen therapy at the time of referral. Brinkman index was 1500 (30 cigarettes/day × 50 years). On admission, he was experiencing severe dyspnea. Chest x-ray film demonstrated radiolucency of the bilateral lung fields and lower diaphragm, which are findings specific to emphysema. Thoracic CT scan demonstrated a homogenous tumor of the right intermediate bronchus and the maximal size of the tumor was 1.3 cm (Figure

Received for publication May 2, 2005 ; accepted May 30, 2005.

Address correspondence and reprint requests to Kazuya Kondo, Department of Oncological and Regenerative Surgery, Institute of Health Biosciences, The University of Tokushima Graduate School, Kuramoto-cho, Tokushima, 770-8503, Japan and Fax : +81-88-633-7144.

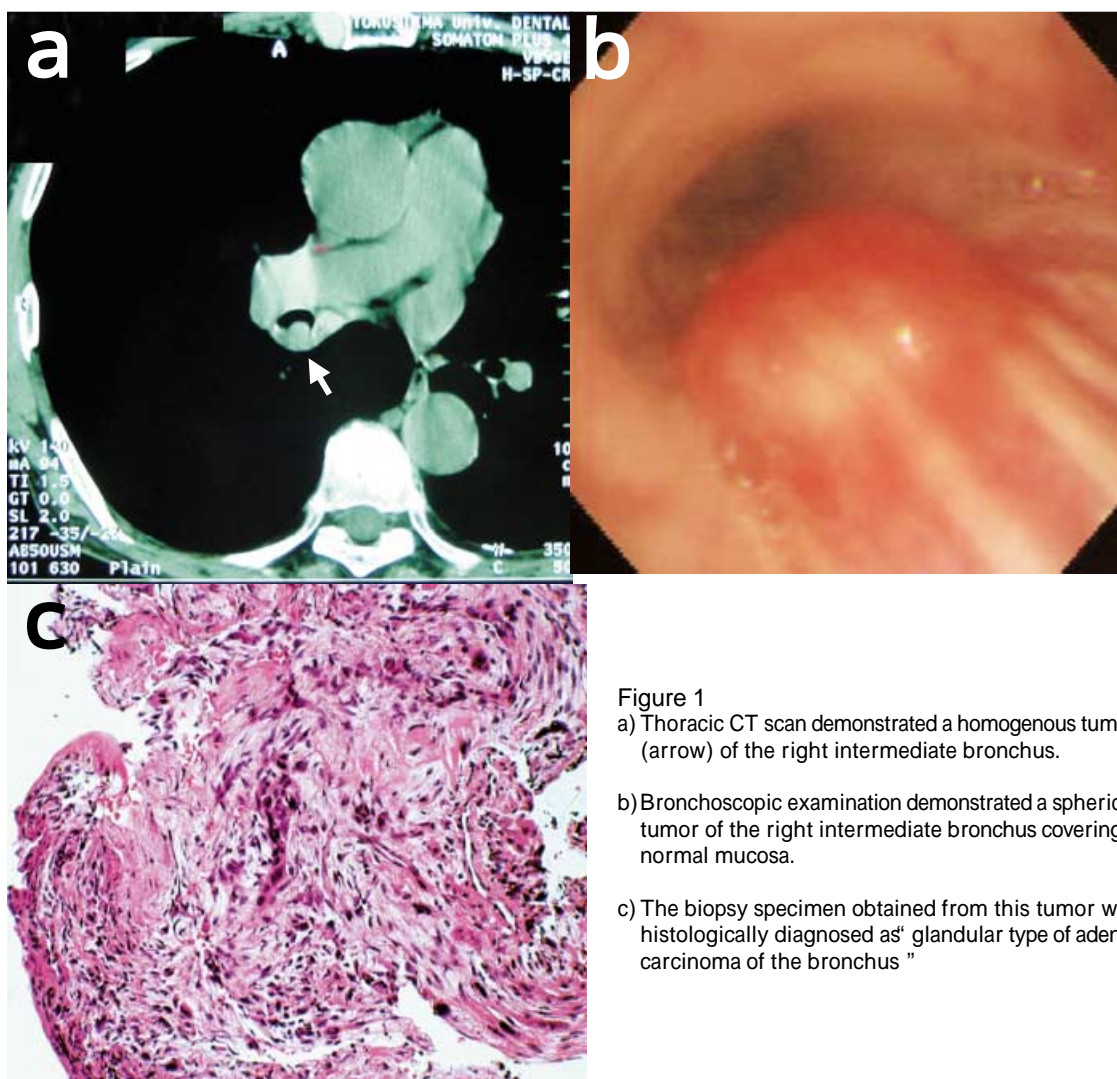


Figure 1

- a) Thoracic CT scan demonstrated a homogenous tumor (arrow) of the right intermediate bronchus.
- b) Bronchoscopic examination demonstrated a spherical tumor of the right intermediate bronchus covering a normal mucosa.
- c) The biopsy specimen obtained from this tumor was histologically diagnosed as "glandular type of adenocarcinoma of the bronchus"

1-a). There were no elevated tumor markers (SCC, syfra, CEA, NSE, proGRP). Bronchoscopic examination demonstrated a spherical tumor of the right intermediate bronchus covered by normal mucosa (Figure 1-b). The biopsy specimen obtained from this tumor was histologically diagnosed as "glandular type of adenocarcinoma of the bronchus" (Figure 1-c). The patient was staged as clinical T1N0M0, stage IA. On pulmonary function test, Vital Capacity was 2100 ml (63%) and Forced Expiratory Volume_{1.0} was 730 ml (40%). The blood gas was pH 7.394, PaCO₂ 41.7 mmHg, and PaO₂ 80.4 mmHg. Since surgical treatment was not feasible because of poor pulmonary function, we selected photodynamic therapy (PDT). The patient was informed about "PDT for the advanced lung cancer with endoluminal obstructive lesions of the airway" and signed consent.

Photosensitizer, porfimer sodium (Photofrin) was intravenously administered at a dose of 2 mg/kg body weight. After an interval of 48 h bronchoscopic illu-

mination of the tumour was carried out using an excimer dye laser. The amount of illumination was 100 J using a terminal lens diffuser and 200 J using a terminal cylindrical diffuser. After 2 weeks and again after 1 month of illumination, bronchoscopic examination showed a necrotic tumor coated with black debris (Figure 2-a, b). After 4 months the tumor disappeared (Figure 2-c). The biopsy obtained from the lesion site demonstrated "no malignancy".

Bronchoscopic examination 9 months after PDT found a polypoid tumor arising from the right B6 bronchus, which was diagnosed as squamous cell carcinoma by biopsy. However, tumor of the right intermediate bronchus did not recur. For lung cancer in B6 bronchus, we periodically performed several sessions of Nd-YAG laser therapy, PDT and radiotherapy with 60 Gy over the subsequent 2 years 6 months. The patient died of respiratory failure due to the tumor of B6 bronchus. However, there was no recurrence of the tumor of the right intermediate bronchus for

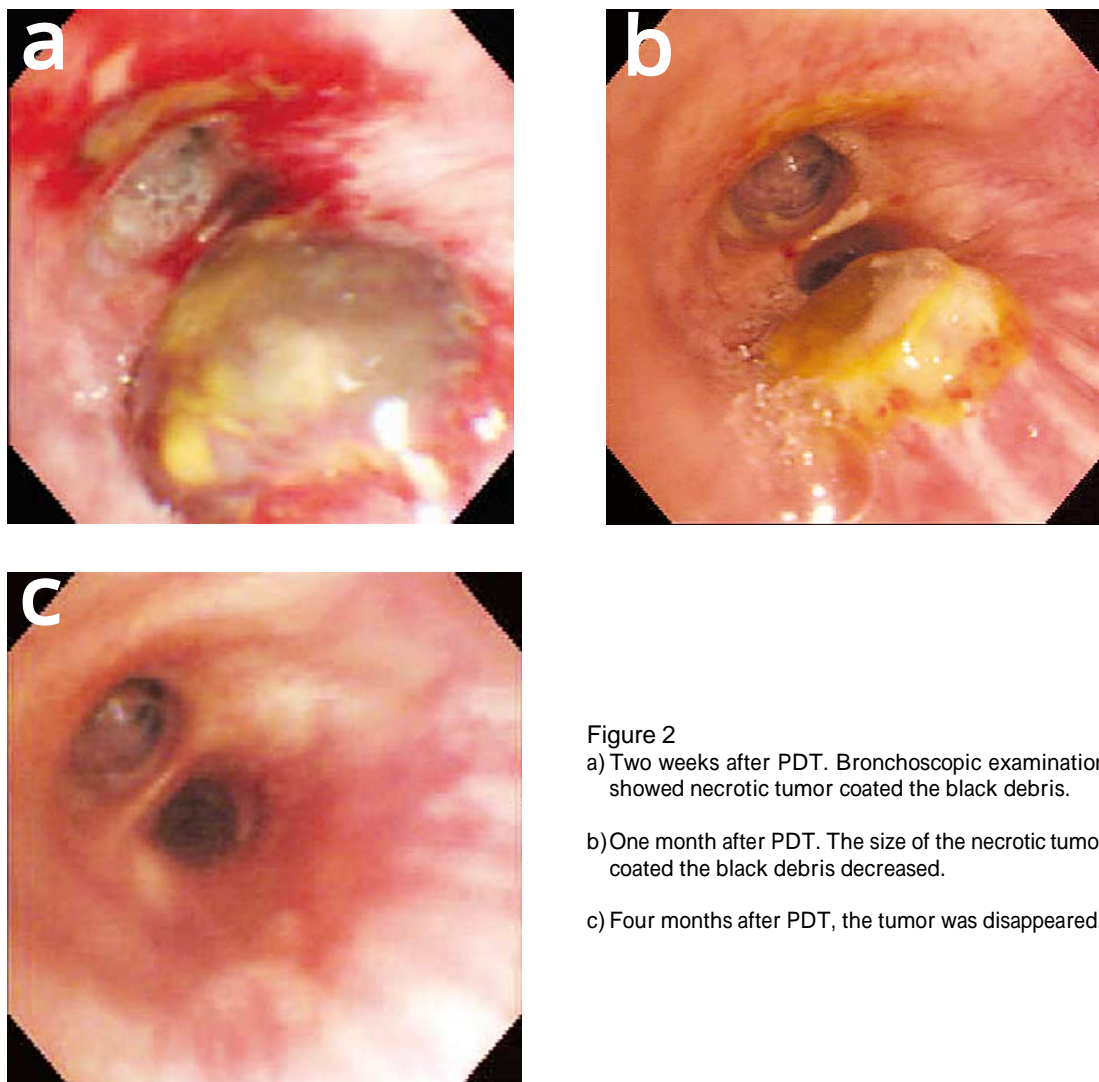


Figure 2

- a) Two weeks after PDT. Bronchoscopic examination showed necrotic tumor coated the black debris.
- b) One month after PDT. The size of the necrotic tumor coated the black debris decreased.
- c) Four months after PDT, the tumor was disappeared.

3 years 3 months.

DISCUSSION

In lung cancer, PDT can be applied as a curative therapy for early cancer of the trachea and central bronchi and as a palliative therapy for treatment of nonresectable disease with endobronchial obstruction (6). It is very rare for submucosal tumor of the bronchus to be treated using PDT. We presented a patient with submucosal tumor of the right intermediate bronchus, who was considered a candidate for bronchoplasty. As he had severe emphysema (FEV1.0 730 ml (40%)), we selected PDT as a palliative therapy. This tumor did not meet for the criteria for early lung cancer of the central airway proposed by the Japan Lung Cancer Society (7). The tumor was not squamous cell carcinoma, and was suspected of invading through the bronchial wall to the lung parenchyma. However,

PDT for this tumor was very effective, and the tumor showed complete response for about 3 years.

In recent years, some patients with substantial endoluminal obstructive lesions of the airway have been treated by endobronchial therapies, such as PDT, electrocautery, Nd-YAG laser, cryotherapy, or endobronchial brachytherapy (8). In Japan, PDT is frequently used for early lung cancer of the central airway (2). In Europe and the U.S.A, this procedure is frequently used for advanced lung cancer with airway obstruction (3, 4). Moghissi reviewed 24 articles describing PDT for lung cancer (9). Cases included 636 advanced lung cancers and 517 early lung cancers. In the patients with advanced lung cancer, there was no procedure-related mortality and almost all patients had symptomatic relief, indicating that PDT is effective for palliation of inoperable advanced lung cancer. Moghissi *et al.* also concluded that endoscopic PDT for patients with advanced lung cancer causing major airway obstruction is more effective than Nd-YAG laser

treatment with respect to percent of luminal patency and pulmonary functions at 1 month, and that it may be superior in terms of duration of response (5). Furthermore, it may be applied safely to small segmental (and even subsegmental) tumors (10). Nd-YAG laser is contraindicated in patients with submucosal lesions because of the potential for perforation of a bronchus or major vessel. However, PDT can be applied to these lesions safely, shown by the case presented in this paper.

Moreover, Moghissi *et al.* reported combined therapy using Nd-YAG laser and endoscopic photodynamic therapy, which is an effective palliative treatment for patients with inoperable endotracheobronchial cancer (10). Initially patients underwent bronchoscopic Nd-YAG laser treatment to debulk the tumor, followed six weeks later by photodynamic therapy to treat the residual tumor. PDT often needs to be used in conjunction with other techniques, such as airway stenting, Nd-YAG, or cryotherapy. For PDT to be used effectively, it should be integrated into a multimodal approach with chemotherapy and radiation (11). The optimal sequencing of these treatment modalities remains an area for further investigation.

In conclusion, PDT can affect a submucosal tumor or small airway tumor, as well as various other tumors causing airway obstruction. Patients with inoperable malignant and tracheobronchial obstruction (irrespective of the histological type), may well benefit from the expanding the application of PDT. Our report recommends that PDT should be applied not only to early lung cancer but also to submucosal tumor of the central bronchus.

REFERENCES

1. Dougherty TJ, Marcus SL : Photodynamic therapy. *Eur J Cancer* 28 A : 1734-1742, 1992
2. Kato H, Okunaka T, Shimatani H : Photodynamic therapy for early stage bronchogenic carcinoma. *J Clin Laser Med Surg* 14 : 235-238, 1996
3. McCaugham J Williams T : Photodynamic therapy for endobronchial malignant disease. A prospective fourteen years study. *J Thorac Cardiovasc Surg* 114 : 940-947, 1997
4. Moghissi K, Dixon K, Stringer M, Freeman T, Thorpe A, Brown S : The place of bronchoscopic photodynamic therapy in advanced unresectable lung cancer : experience of 100 cases. *Eur J Cardio Thorac Surg* 15 : 1-6, 1999
5. Moghissi K, Dixon K, Parsons R : A controlled trial of Nd : YAG laser vs. photodynamic therapy for advanced malignant bronchial obstruction. *Lasers Med Sci* 8 : 269-273, 1993.
6. Ost D : Photodynamic therapy in lung cancer. *Oncology (Huntingt)* 14 : 379-386, 2000
7. The Japan Lung Cancer Society : General rule for clinical and pathological record of lung cancer, 5 th ed, Kanehara-shuttpan, Tokyo, 1999, pp. 74-75
8. Moro-Sibilot D, Brambilla C : Photodynamic therapy : where do we go from here? *Eur Respir J* 22 : 399-400, 2003
9. Moghissi K, Dixon K : Is bronchoscopic photodynamic therapy a therapeutic option in lung cancer? *Eur Respir J* 22 : 535-541, 2003
10. Moghissi K, Dixon K, Hudson E, Stringer M, Brown S : Endoscopic laser therapy in malignant tracheobronchial obstruction using sequential Nd YAG laser and photodynamic therapy. *Thorax* 52 : 281-283, 1997
11. Ost D : Photodynamic therapy in lung cancer. A review. *Methods Mol Med* 75 : 507-526, 2003