

REVIEW

Surgery Related Complications in Percutaneous Endoscopic Lumbar Discectomy under Local Anesthesia

Koichi Sairyo, Tetsuya Matsuura, Kosaku Higashino, Toshinori Sakai, Yoichiro Takata, Yuichiro Goda, Naoto Suzue, Daisuke Hamada, Tomohiro Goto, Toshihiko Nishisho, Ryosuke Sato, Takahiko Tsutsui, Ichiro Tonogai, and Kazuaki Mineta

Department of Orthopedics, the University of Tokushima, Tokushima, Japan

Abstract : The minimally invasive percutaneous endoscopic discectomy (PED) as the postero-lateral approach with the local anesthesia was started in the late 20th century. The procedure only requires 8 mm of skin incision ; thus, it is the least invasive disc surgery presently. The surgery related complications were reviewed in the initial 100 cases from the single surgeon (K.S., first author). Two cases showed exiting nerve irritation, and complained of leg paresthetic pain for 6 to 12 weeks after the surgery (2.0%). The symptoms got better with medicines. One showed post-surgical epidural hematoma, and required surgical removal of the mass (1.0%). Two cases complained neck pain during surgery (2.0%). Surgeons would be aware of the specific complications for the postero-lateral approach of PED procedure. *J. Med. Invest.* 61 : 264-269, August, 2014

Keywords : *herniated nucleous pulposus, lumbar spine, surgery, percutaneous endoscopic discectomy, local anesthesia, complication*

INTRODUCTION

Historically, the percutaneous technique for the lumbar herniated nucleus pulposus (HNP) was initiated by Hijikata (1). His technique is called percutaneous discectomy. The benefit of the approach is to be conducted with local anesthesia, and minimal invasiveness. Kambin was also one of the pioneers of this approach (2). However, without an endoscope, it was difficult to remove the HNP located inside of canal. Based on their technique, percutaneous endoscopic discectomy (PED) was developed. From the late 1980', the trial to utilize the endoscope or arthroscope for the transforaminal approach was

started (3, 4). The establishment of the current single portal endoscopic discectomy would be possible by great efforts of Yeung *et al.* (5-7). By utilizing a spinal endoscope, the reliability to remove the HNP is improved as comparing to the traditional Hijikata's technique (1).

To access the intra-canal, intra-foraminal and far-lateral HNP, we need to insert a cannula from posterolateral aspect (usually 8 to 10 cm away from the midline) and to pass near the exiting nerve root. The approach is completely different from the traditional disc surgery called interlaminar technique. Therefore, it is not difficult to assume that there would be special surgery-related complications in this technique. The senior author (K.S.) started the postero-lateral PED surgery in 2010, and we reviewed the surgery related complications in his initial 100 cases for the single surgeon, and discussed the complications in the PED technique.

Received for publication March 28, 2014 ; accepted April 23, 2014.

Address correspondence and reprint requests to Koichi Sairyo, MD and PhD, Professor and Chairman, Department of Orthopedics, the University of Tokushima, 3-18-15 Kuramoto, Tokushima 770-8503, Japan and Fax : +81-88-633-0178.

METHODS

Figure 1 indicates two kinds of posterolateral PED approach. For the far-lateral HNP in all the lumbar levels, the far-lateral (FL) approach is suitable. For the standard intra-canalicular HNP, transforaminal (TF) approach is used, since the cannula needs to pass through the intervertebral foramen. In case, subjects have a high iliac crest, it is very hard to access intra-canal HNP at L5-s level through the foramen, TF approach is the contra-indication. Almost HNP at the lumbar spine would be indication for PED. However, in this series, there would be contra-indications for the PED TF and FL as follows.

- 1) Intracanalicular HNP at L5-s with high iliac crest
- 2) Severely migrated HNP at the hidden zone

Surgery is conducted according to the review article of the PED procedure (8). About 8 mm skin incision is required about 8-10 cm laterally from the midline. After the sufficient local anesthesia around the disc, a needle is inserted into the disc through the safety triangle. Next, discography is conducted with indigo carmine to dye the nucleus pulposus (NP) and displaced fragment blue. A guide pin is inserted into the disc through the puncture needle, and the obturator and cannula are inserted sequentially. After inserting the cannula, PED procedure is performed through the cannula.

One hundred cases underwent PED surgery with FL or TF approach under local anesthesia. All surgeries were performed by a single surgeon (K.S.)

at Teikyo University Mizonokuchi Hospital and its affiliated hospitals. Their age was from 15 to 81 years old. Among them, 88 underwent TF surgery for their intra-canalicular HNP, and 11, FL surgery for far-lateral HNP. The remaining one case showed both of intra-canalicular and far-lateral HNPs, and both of TF and FL approaches were used to remove the HNPs at both locations.

Nerve root injury, dural tear, surgical site infection, cauda equina injury, hematoma and major vessel injury are the possible general complication. For the specific complication in the PED surgery with TF and FL approach, exiting nerve root injury intracranial hypertension (neck pain, headache, convulsion, seizure, death) and kidney/colon injury would be considered.

We reviewed such complications in the initial 100 cases.

RESULTS

We had two cases of exiting nerve irritation after the surgery (2.0%). Since they did complain of the paresthetic leg pain and did not show motor weakness. If it is the nerve root injury, the symptom should occur just after the surgery. For both cases, these symptoms appeared 2-3 days after the PED surgery. Thus, we use "irritation" not "injury". Figure 2 indicates one case having the complication. For his far-lateral HNP at left L5-s level, we conducted PED surgery with far-lateral approach.

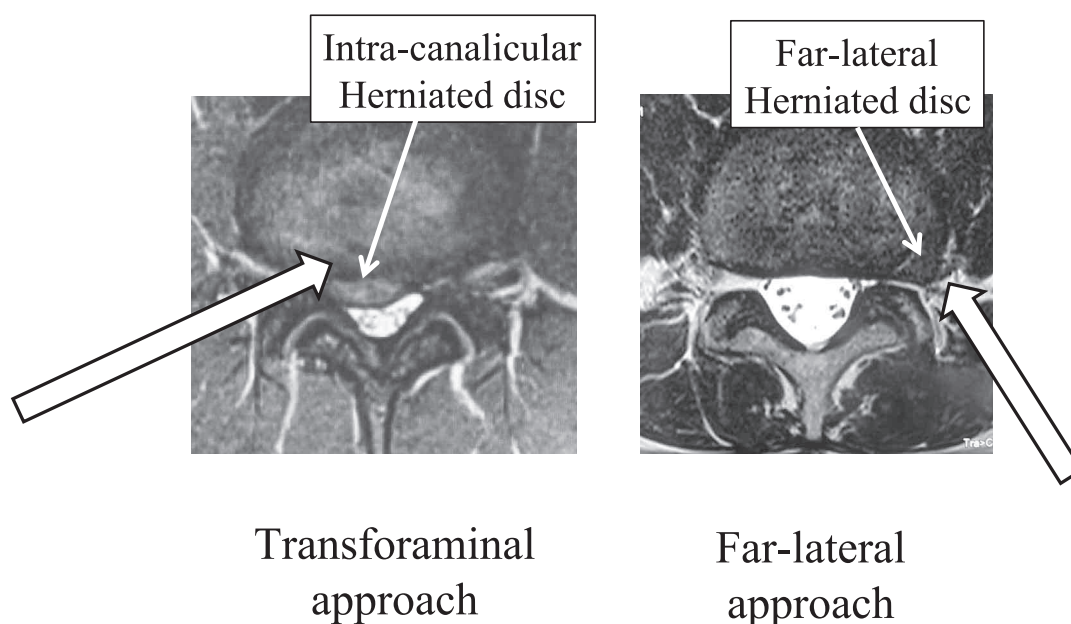


Figure 1 : Two kinds of posterolateral PED approach. Transforaminal (TF) and far-lateral (FL) approach.

After the surgery, his pain disappeared and was discharged on the next day. Two days after the surgery, he noticed strong leg pain with strange paresthetic sensation along with L5 dermatome. No motor weakness was found. L5 exiting nerve root irritation was diagnosed and MRI was taken (Figure 2). It indicates left L5 nerve root swelling and edema. With 3 months conservative treatment, the symptom disappeared.

One case experienced post-surgical epidural hematoma. Since the HNP migrated caudally, pediculotomy was conducted before the HNP removal (Figure 3). Two days after the surgery, he noticed strong leg pain with standing, and MRI revealed

epidural mass (Figure 4 left), which was not seen before the surgery. HNP prolapse and/or hematoma was suspected. Three days later, decompression was conducted using microendoscopic discectomy (9, 10) system. During the surgery, we found epidural hematoma and disc fragments, and they were successfully removed (Figure 4 right).

Two cases complained neck pain during the surgery, and to avoid further severe scenario such as seizure and convulsion, we sooner completed the surgery. They complained neck pain around 35 and 55 min. after starting the surgery. The surgery was almost completed for these cases at that time.

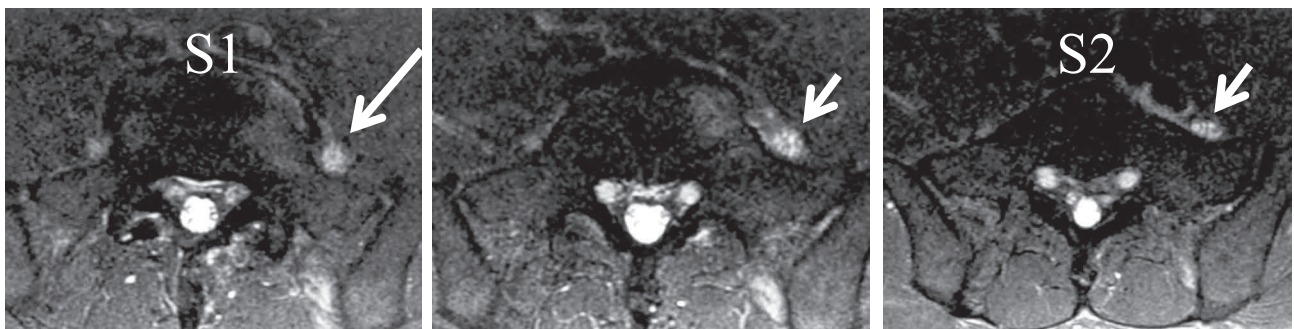
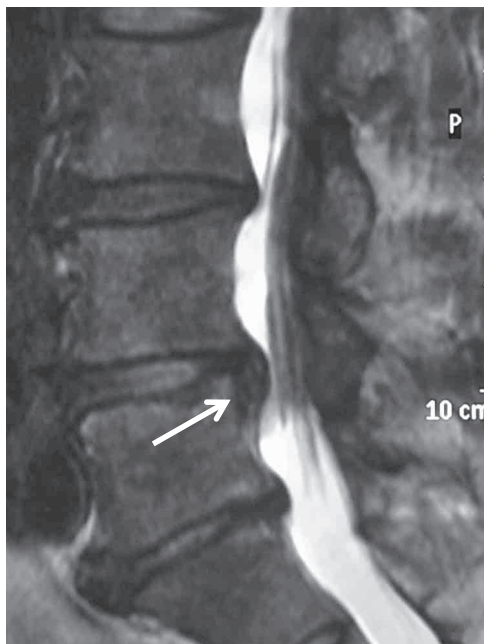
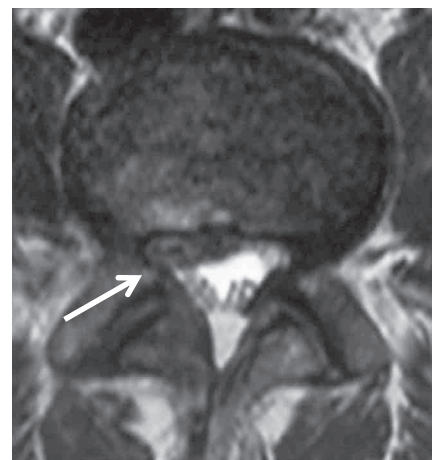


Figure 2 : STIR-MRI for a case showing exiting nerve irritation. It indicates left L5 nerve root swelling and edema.



Right para-sagittal
T2-Wt image



Axial T2-Wt image
through the L5 pedicle

Figure 3 : MRI before surgery in patient having a post-surgical epidural hematoma.

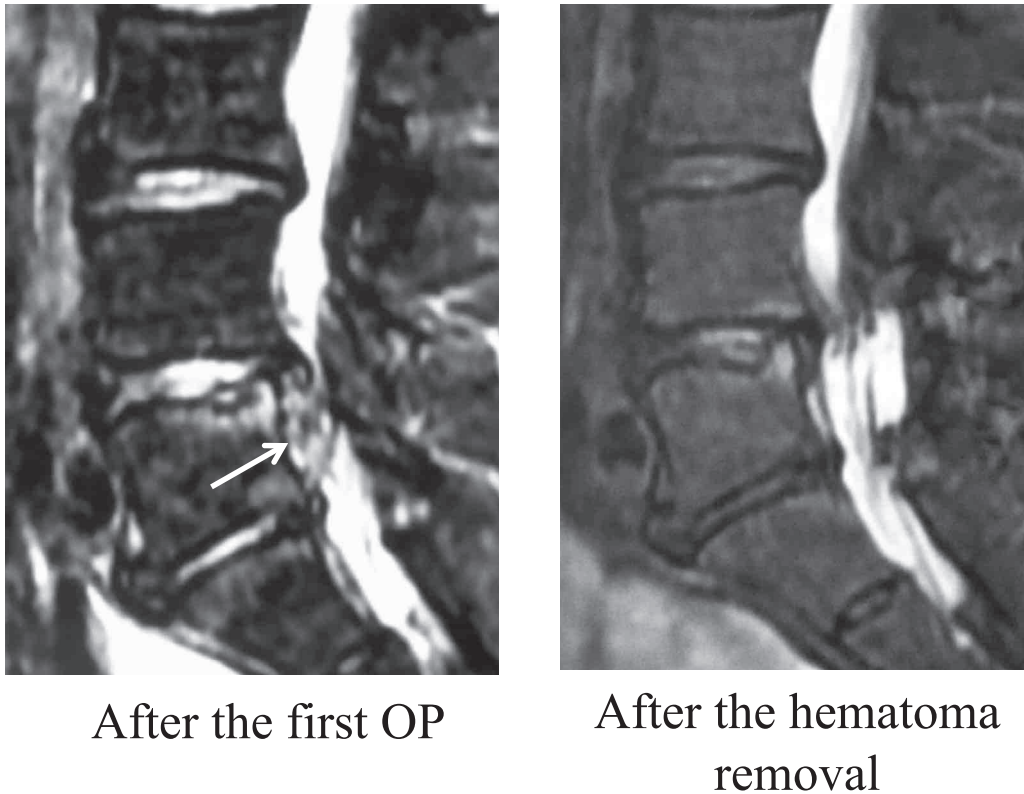


Figure 4 : MRI after the initial and second surgery. Note the epidural hematoma (left) and its removal (right).

DISCUSSION

We have reviewed PED related complication in the initial 100 cases by a single surgeon, and found 2 (2%) cases showed exiting nerve irritation (injury), and 1 (1%) of post-surgical epidural hematoma. Actually, this is not a complication, but 2 cases (2%) complained neck pain during the surgery.

In the literature, many PED-related complications have been reported. Among them, exiting nerve root injury, that is postoperative dyesthesia (POD), is special complication in the transforaminal approach. It has been reported to be occurred 1.0 to 8.9% in the literature (11). Even if the traversing root has been successfully decompressed, the POD would inhibit the quick recovery and delays the return to daily life. Thus, prevention of POD is the most important key factor for PED to be successful. Cho *et al.* (12) came up with their original technique to avoid the POD, which is called floating retraction technique. However, there is still in controversy on the optimum technique to avoid the POD.

There are 2 possibilities to injure the exiting nerve root. The first possibility is the direct injury by a cannula. When the lidocaine infiltrates the exiting nerve root, a patient does not feel any pain even though the nerve would be injured. Dyesthesia and

motor paresis would be occurred just after the surgery. To carefully conduct the local anesthesia, this kind of complication can be avoided. Actually, in our early 100 cases, no patient had such complication.

The second possibility is irritation of the dorsal root ganglion due to compression by the cannula during surgery. For such cases, the leg dyesthesia would be occurred couple of days after the surgery. We experienced 2 such cases among 100 cases. Both of them started complaining leg pain and dyesthesia 2 days after the surgery ; however, the pain could be healed by medicines within 3 months. Choi *et al.* (11) experienced 20 cases having an exiting nerve injury among 233 cases. They analyzed such 20 cases, and concluded that prolonged operation time could be a factor of the injury. They assumed the cannula may compress the exiting nerve root during the surgery, thus, prolonged operation time is one of the risk factors for the irritation. Clinical demonstration in our 2 cases is supported their hypothesis.

There are two types of the post-operative hematoma : epidural and retroperitoneal hematoma (13). Ahn *et al.* (13) performed transforaminal PED for 412 cases, and experienced 4 (0.97%) cases of symptomatic retroperitoneal hematoma. In 2 cases, the volume was over 500 (ml) ; i.e. 1274 and 704 (ml),

and open evacuation was required by a general surgeon. The injury of the terminal branch of the lumbar artery would be the reason. In our series, we did not experience such hematoma, but post-surgical epidural hematoma for 1 case (1%), which is common in the traditional spine surgery. The incidence of postoperative symptomatic epidural hematoma occurring after all spinal procedures requiring surgical intervention ranges from 0.2% to 2.9% (14). The incidence in our series was not very high as comparing to the previous reports.

Another important complication, which surgeons must be aware of, would be intra-cranial hypertension during surgery, which may result in headache, seizure or even death. Choi *et al.* (15) reported 4 cases of seizure among 16.725 cases of PED. They complained neck pain before seizure; thus, it must be the indicator of the consequent seizure. Joh *et al.* (16) monitored the cervical epidural pressure (EP) during the PED procedure for 28 patients. Among them, 8 cases complained of neck pain, and the high EP was monitored as the neck pain occurred. They concluded that the neck pain is induced by the high epidural pressure with continuous infusion. The cervical epidural pressure and intracranial pressure has the positive relationship; thus, it is not difficult to assume that when patient complains of neck pain, intracranial pressure would be high. The neck pain would be a good indicator for the consequent headache and seizure. In our earliest 100 cases, two patients complained neck pain during surgery. Thus, we completed surgery as soon as possible, then, we did not have any further complications such as seizure. The neck pain would be very important warning sign for us to prevent serious complication by high cranial pressure.

In this series, we have experienced comparatively fewer complications. Especially, incidence of the exiting nerve injury was low (2%). This may be due to the education system which the senior surgeon (K.S.) received. Before he started, he received PED education session with a model bone and an animal spine; thereafter, he attended PED surgery of the best PED surgeon in this nation, who has a lot of experiences of PED surgery (17-20), 5 times. In the initial 15 cases, he conducted with guidance by the specialist. Thanks to this sufficient education, the surgeon gained the surgical skill with a fewer complications.

REFERENCES

1. Hijikata S : Percutaneous nucleotomy. A new concept technique and 12 years' experience. *Clin Orthop Relat Res* 238 : 9-23, 1989
2. Kambin P, Schaffer JL : Percutaneous lumbar discectomy. Review of 100 patients and current practice. *Clin Orthop Relat Res* 238 : 24-34, 1989
3. Kambin P : Arthroscopic microdiscectomy. *Mt Sinai J Med* 58(2) : 159-64, 1991
4. Schreiber A, Leu H : Percutaneous nucleotomy : technique with discoscopy. *Orthopedics* 14(4) : 439-44, 1991
5. Yeung AT : The evolution of percutaneous spinal endoscopy and discectomy : state of the art. *Mt Sinai J Med* 67 : 327-32, 2000
6. Yeung AT, Tsou PM : Posterolateral endoscopic excision for lumbar disc herniation : Surgical technique, outcome, and complications in 307 consecutive cases. *Spine* 27 : 722-31, 2002
7. Yeung AT, Yeung CA : Minimally invasive techniques for the management of lumbar disc herniation. *Orthop Clin North Am* 38(3) : 363-72, 2007
8. Sairyo K, Egawa H, Matsuura T, Takahashi M, Higashino K, Sakai T, Suzue N, Hamada D, Goto T, Takata Y, Nishisho T, Goda Y, Sato R, Tsutsui T, Tonogai I, Kondo K, Tezuka F, Mineta K, Sugiura K, Takeuchi M, Dezawa A : State of the Art : Transforaminal Approach for Percutaneous Endoscopic Lumbar Discectomy under Local Anesthesia. *J Med Invest*. In press
9. Foley KT, Smith MM : Microendoscopic discectomy. *Tech Neurosurg* 3 : 301-307, 1997
10. Dandaneau J : Technical features of endoscopic surgery for lumbar disc herniation : 191 patients. *Neurochirurgie* 50(1) : 6-10, 2004
11. Choi I, Ahn JO, So WS, Lee SJ, Choi IJ, Kim H : Exiting root injury in transforaminal endoscopic discectomy : preoperative image considerations for safety. *Eur Spine J* 22(11) : 2481-7, 2013
12. Cho JY, Lee SH, Lee HY : Prevention of development of postoperative dysesthesia in transforaminal percutaneous endoscopic lumbar discectomy for intracanalicular lumbar disc herniation : floating retraction technique. *Minim Invasive Neurosurg* 54(5-6) : 214-8, 2011
13. Ahn Y, Kim JU, Lee BH, Lee SH, Park JD, Hong DH, Lee JH : Postoperative retroperitoneal hematoma following transforaminal percutaneous endoscopic lumbar discectomy. *J*

- Neurosurg Spine 10(6) : 595-602, 2009
14. Kanayama M, Oha F, Togawa D, Shigenobu K, Hashimoto T : Is closed-suction drainage necessary for single-level lumbar decompression? : review of 560 cases. Clin Orthop Relat Res 468(10) : 2690-4, 2010
 15. Choi G, Kang HY, Modi HN, Prada N, Nicolau RJ, Joh JY, Pan WJ, Lee SH : Risk of developing seizure after percutaneous endoscopic lumbar discectomy. J Spinal Disord Tech 24(2) : 83-92, 2011
 16. Joh JY, Choi G, Kong BJ, Park HS, Lee SH, Chang SH : Comparative study of neck pain in relation to increase of cervical epidural pressure during percutaneous endoscopic lumbar discectomy. Spine (Phila Pa 1976) 34(19) : 2033-8, 2009
 17. Dezawa A, Sairyo K : New minimally invasive endoscopic discectomy technique through the interlaminar space using a percutaneous endoscope. Asian J Endosc Surgery 4(2) : 94-98, 2011
 18. Dezawa A, Mikami H, Sairyo K : Percutaneous endoscopic translaminar approach for herniated nucleus pulposus in the hidden zone of the lumbar spine. Asian J Endosc Surgery 5(4) : 200-203, 2011
 19. Kitahama Y, Sairyo K, Dezawa A : Percutaneous endoscopic transforaminal approach to decompress the lateral recess in an elderly patient with spinal canal stenosis, herniated nucleus pulposus and pulmonary comorbidities. Asian J Endosc Surg 6(2) : 130-3, 2013
 20. Sairyo K, Kitagawa Y, Dezawa A : Percutaneous endoscopic discectomy and thermal annuloplasty for professional athletes. Asian J Endosc Surg 6(4) : 292-7, 2013